This is a digital copy of a book that was preserved for generations on library shelves before it was carefully scanned by Google as part of a project to make the world's books discoverable online.

It has survived long enough for the copyright to expire and the book to enter the public domain. A public domain book is one that was never subject to copyright or whose legal copyright term has expired. Whether a book is in the public domain may vary country to country. Public domain books are our gateways to the past, representing a wealth of history, culture and knowledge that's often difficult to discover.

Marks, notations and other marginalia present in the original volume will appear in this file - a reminder of this book's long journey from the publisher to a library and finally to you.

Usage guidelines

Google is proud to partner with libraries to digitize public domain materials and make them widely accessible. Public domain books belong to the public and we are merely their custodians. Nevertheless, this work is expensive, so in order to keep providing this resource, we have taken steps to prevent abuse by commercial parties, including placing technical restrictions on automated querying.

We also ask that you:

+ *Make non-commercial use of the files* We designed Google Book Search for use by individuals, and we request that you use these files for personal, non-commercial purposes.

+ *Refrain from automated querying* Do not send automated queries of any sort to Google's system: If you are conducting research on machine translation, optical character recognition or other areas where access to a large amount of text is helpful, please contact us. We encourage the use of public domain materials for these purposes and may be able to help.

+ *Maintain attribution* The Google "watermark" you see on each file is essential for informing people about this project and helping them find additional materials through Google Book Search. Please do not remove it.

+ *Keep it legal* Whatever your use, remember that you are responsible for ensuring that what you are doing is legal. Do not assume that just because we believe a book is in the public domain for users in the United States, that the work is also in the public domain for users in other countries. Whether a book is still in copyright varies from country to country, and we can't offer guidance on whether any specific use of any specific book is allowed. Please do not assume that a book's appearance in Google Book Search means it can be used in any manner anywhere in the world. Copyright infringement liability can be quite severe.

About Google Book Search

Google's mission is to organize the world's information and to make it universally accessible and useful. Google Book Search helps readers discover the world's books while helping authors and publishers reach new audiences. You can search through the full text of this book on the web at `http://books.google.com/`

HARVARD
MEDICAL LIBRARY

IN THE
Francis A. Countway
Library of Medicine
BOSTON

ANNUAL SUBSCRIPTION: UNITED STATES AND CANADA, $10.00; FOREIGN, $12.00 (£2 10s.)

Volume XXVIII JANUARY, 1919 Number 1

Surgery, Gynecology and Obstetrics

WITH

International Abstract of Surgery

EDITORIAL STAFF

FOR AMERICA

William J. Mayo, M.D.

E. Wyllys Andrews, M.D. J. Clarence Webster, M.D.

L. L. McArthur, M.D. E. C. Dudley, M.D. Frederic A. Besley, M.D.

A. J. Ochsner, M.D. C. S. Bacon, M.D. Carl Beck, M.D.

Thomas J. Watkins, M.D. John L. Porter, M.D. William R. Cubbins, M.D.

FOR THE BRITISH EMPIRE

Sir Arthur Mayo-Robson, C.B., C.V.O., D.Sc., F.R.C.S.

Sir Berkeley Moynihan, C.B., M.S., F.R.C.S. Thomas W. Eden, M.D., F.R.C.S.

Sir Harold J. Stiles, M.B., F.R.C.S. (Edin.) Henry Jellett, M.D., F.R.C.P.I.

James Rutherford Morison, M.B., F.R.C.S.

Franklin H. Martin, M.D., Managing Editor

Allen B. Kanavel, M.D., Associate Editor

EDITORIAL AND BUSINESS OFFICES: 30 N. Michigan Ave., Chicago, Illinois, U. S. A.

PUBLISHERS FOR GREAT BRITAIN: Bailliere, Tindall & Cox, 8 Henrietta St., Covent Garden, London, W. C., England

United States Army Number

The Medical Clinics of North America

Devoted entirely to the work done at several of the large Base Hospitals of this country

SAUNDERS, *Publishers*

SEE PAGE 13

Entered as second-class matter May 22, 1913, at the postoffice at Chicago, Ill., under the Act of Congress, March 3, 1897.

Published monthly. Copyright, 1919, by The Surgical Publishing Company of Chicago.

EVERY X-RAY USER

Needs Some of These Supplies

X-Ray Plates. Three brands in stock for quick shipment. **Paragon Brand** for finest work; **Universal Brand** where price is important.

Barium Sulphate. Highest grade, prepared especially for abdominal X-ray work. Try it, and you will use no other. None better at *any* price. 10 lbs., $3.50; 25 lbs., $7.50; 50 lbs., $12.50; 100 lbs., $24.00.

Dental Film Mounts. Black or gray cardboard with celluloid window, or all celluloid types, one to ten film openings. (Special list on request.)

Developer Chemicals. METOL (American or Holland), ounce, $1.70; 4 oz., $6.00; 8 oz., $11.50; pound, $22.00. Hydroquinone, 5 lbs., $14.50; per lb., $3.00. Hypo, 100 lbs., $4.00.

Dental X-Ray Films. Fast or slow emulsion, regular or oval shapes. (Ovals for lower molars.) Small size, 50c per dozen. The new lead backed films, 85c per doz.

Filing Envelopes with printed X-ray form. (For used plates.)

Intensifying Screens for reducing exposures to ¼ or less. Immediate delivery.

Developing Tanks. End your dark room troubles; economical, rapid. Four or six compartment stone, or single porcelain enameled. Glass tank for dental films.

Only highest grade goods at fair prices. Ask for complete list with discounts.



Your name should be on our mailing list for free technical information.

GEO. W. BRADY & CO.

809 S. Western Avenue **Chicago, Illinois**

SAVE TWO-THIRDS

Sherman's Bacterial Vaccines, when administered early, will reduce the average course of acute infections like Pneumonia, Broncho-pneumonia, Sepsis, Erysipelas, Mastoiditis, Rheumatic Fever, Colds, Bronchitis, etc., **to less than one-third their usual mortality and duration.**

Sherman's Bacterial Vaccines are prepared in our specially constructed Laboratories, devoted exclusively to the manufacture of these preparations and are marketed in standardized suspensions.

Write for literature.

MANUFACTURERS OF BACTERIAL VACCINES

G. H. SHERMAN, M.D.

Detroit, Mich. U.S.A.

Surgery, Gynecology and Obstetrics

An International Magazine
Published Monthly

EDITORIAL STAFF

FOR AMERICA

WILLIAM J. MAYO, M.D.
E. WYLLYS ANDREWS, M.D. J. CLARENCE WEBSTER, M.D.
L. L. MCARTHUR, M.D. E. C. DUDLEY, M.D. FREDERIC A. BESLEY, M.D.
A. J. OCHSNER, M.D. C. S. BACON, M.D. CARL BECK, M.D.
THOMAS J. WATKINS, M.D. JOHN L. PORTER, M.D. WILLIAM R. CUBBINS, M.D.

FOR THE BRITISH EMPIRE

SIR ARTHUR MAYO-ROBSON, C.B., C.V.O., D.Sc., F.R.C.S.
SIR BERKELEY MOYNIHAN, C.B., M.S., F.R.C.S. THOMAS W. EDEN, M.D., F.R.C.S.
SIR HAROLD J. STILES, M.B., F.R.C.S. (Edin.) HENRY JELLETT, M.D., F.R.C.P.I.
JAMES RUTHERFORD MORISON, M.B., F.R.C.S.

FRANKLIN H. MARTIN, M.D., Managing Editor
ALLEN B. KANAVEL, M.D., Associate Editor

Volume XXVIII
January to June, 1919

PUBLISHED BY
THE SURGICAL PUBLISHING COMPANY OF CHICAGO
30 NORTH MICHIGAN AVENUE, CHICAGO
1919

HARVARD MEDICAL LIBRARY
IN THE
FRANCIS A. COUNTWAY
LIBRARY OF MEDICINE

COPYRIGHT BY
THE SURGICAL PUBLISHING COMPANY
OF CHICAGO
1919

CONTRIBUTORS TO VOLUME XXVIII

ALBEE, FRED H. 422
ARCHIBALD, EDWARD 529
BALFOUR, DONALD C. 465
BASTIANELLI, RAFFAELE 5
BECK, EMIL G. 379
BEHREND, MOSES 601
BISSELL, DOUGAL 138
BLACK, WILLIAM T. 473
BLAND, P. BROOKE 83
BOARDMAN, W. W. 615
BOVEE, J. WESLEY 117, 514
BRAASCH, W. F. 555
BROW, MR. 529
BUBIS, J. L. 33
BUERGER, Leo 183
BUGBEE, H. G. 97
BURNAM, CURTIS F. 440
CHURCHMAN, JOHN W. 518
CLEMENSEN, PETER C. 323
CLEVELAND, MATHER 282
COLEY, WILLIAM B 452
COLLINS, CLIFFORD U 404
COLP, RALPH 309
CONNELL, F. GREGORY 583
CUPLER, RALPH C 317
DAVIS, CARL B 525
DEAVER, JOHN B 433
DIEDERICH, VICTOR P 362
DONOVAN, M. 615
DOUGLAS, JOHN 76
DUVAL, PIERRE 1
EGGERS, CARL 348
ELIOT, ELLSWORTH, JR. 309
ELSE, J. EARL 467
FARR, R. E. 322, 327
FRANK, JACOB 524
FULD, JOSEPH E. 320
GALLAGHER, J. F. 482
GASK, G. E. 12, 24
GETTLER, ALEXANDER O 58
GILROY, EARL W. 327
GREEN, THOMAS M. 159
GREY, ERNEST G. 36
GROSS, GEORGES 603
GROSS, WILLIAM A. 324
GUILD, STACY 612
HARRIGAN, ANTHONY H. 561
HARRINGTON, S. W. 446
HEALD, C. L. 326
HEPBURN, THOMAS N. 316
HINMAN, FRANK 495
JACKSON, CHEVALIER 201
JOHNSON, FREDERICK W 418
JOHNSON, WILLIAM M 58
JUDD, E. S. 446
KELLOGG, EDWARD L 174
LANDSMAN, ARTHUR A 276
LAROQUE, G. PAUL 522
LEWIS, BRANSFORD 459
LOSEE, J. R. 97
LOWE, HORACE A 319
MACLEAN, NEIL JOHN 190
MAGIE, W. H. 402
MARTIN, E. DENEGRE 91
MARTLAND, HARRISON S. 486
MAYO, WILLIAM J. 28
MCKENNA, HUGH 303
MEYER, ARTHUR WILLIAM 293
MORRIS, ROBERT T. 331, 472
MOSCHCOWITZ, ALEXIS V. 337
NEWELL, Q. U. 68
O'CROWLEY, C. R. 486
O'DAY, J. CHRISTOPHER 375
OLSON, F. A. 555
PEMBERTON, J. DEJ. 262
PERLSTEIN, ISIDOR 43
PHANEUF, LOUIS E. 418
PITZMAN, MARSH 329
PORTER, MILES F. 431
PRINCE, E. M. 509
PRITZKER, LOUIS J 325
RICHARDSON, EDWARD H. 146
RICHTER, H. M. 399
ROBINS, CHARLES R. 516
RYAN, LAWRENCE 526
SAGE, E. C. 68
SCHOEMAKER, J. 528
SCHWYZER, A. 428
SHARPE, WILLIAM 407
SHERRILL, J. GARLAND 371
SIDBURY, J. BUREN 159
SIMPSON, BURTON T. 153
SISTRUNK, W. E. 436
STOOKEY, BYRON 612
SYMMERS, DOUGLAS 58
TALBOT, JOHN E. 165
TURNER, G. GREY 17
VAN BEUREN, F. T., JR. 278
VAN HOOK, WELLER 598
VINEBERG, HIRAM N. 123
WATSON, ERNEST M. 569
WILLEMS, C. 546
WILSON, PHILIP D 478
WRIGHT, FRANKLIN R 56
YOUNG, HUGH HAMPTON 84

SUBJECT INDEX TO VOLUME XXVIII

ABDOMEN, The acute, 583; pendulous, the extreme, and its surgical treatment by a new Three-flap operation, 190
Abdominal, incision, A simple and expeditious method of performing the, 83; viscera, Acute perforations of the, 28
Acute abdomen, The, 583
American College of Surgeons, 95, 195, 334
Amputations, War, 478
Anæsthesia, Accidents from local, cor. 528
Aneurism, Arteriovenous, affecting the brachial plexus, tr. 526
Anorectal fistula, The treatment of certain types of, 276
Anthrax, report of a case, 325
Antitoxin, Simplified technique for the intravenous injection of salvarsan or, in combination with normal salt solution, 323
Apparatus, Transfusion, 327
Appendectomy, Acute intestinal obstruction following, 561
Appendicitis, Acute, Immediate surgical management of, in military surgery suggesting a possible relationship between the onset of this condition in those cases with a history of previous attacks and the present method of administering the triple typhoid vaccine, 303; Acute, complicating epidemic influenza, with report of 8 cases, 601; chronic, Notes on two signs in, 472
Arteriovenous aneurism affecting the brachial plexus, tr. 526
Arthritis, Treatment of purulent, by wide arthrotomy followed by immediate active mobilization, 546
Arthrotomy, Treatment of purulent arthritis by wide, followed by immediate active mobilization, 546

BLADDER, A simple method of draining the, after suprapubic prostatectomy, 91; A gauze sponge spontaneously expelled from the urinary, 522; Stone in the, tr. 524
Blood transfusion, 262
Bowel, Papilloma of the large, tr. 524
Brachial plexus, Arteriovenous aneurism affecting the, tr. 526

CARCINOMA of the stomach; report of three cases with no recurrence five years after operation, 76
Case records and their use, 195, 334
Chest wounds, Treatment of, with special reference to artificial pneumothorax, 5; The early treatment of gunshot, 12; The later stages of gunshot, 17
Chicago Surgical Society, 524, 525
Cholecystectomy, Are we justified in removing a comparatively healthy gall-bladder, 402
Cholecystitis, The rôle of the cystic duct in recurring, 467
Chondrosarcoma of the endometrium, The mesodermal mixed tumors of the uterus, report of a case of botrioid, 43
Chorio-epithelioma, Clinical data on, with end-results of operative treatment, 123
Chronic appendicitis, Notes on two signs in, 472
Cirrhosis of the liver, The operation of omentopexy in, 309
Clavicle, Osteomyelitis of the, tr. 525
Colostomy, Lowe's, receptacle, 319
Colostomies, Practical considerations with regard to permanent, 436
Common duct sphincter, The experimental production of pancreatitis in animals as the result of the resistance of the, 529
Complication, Parotitis as a postoperative, 404
Congenital, anomalies, The clinical significance of, of the kidney and ureter, with notes on the embryology and fœtal development of the kidney, 97; diverticula, of the intestines; report of a case of a tumor growing from the tip of an apparently congenital diverticulum in the lower sigmoid region, 473
Convulsions, A theory on the etiology of the toxæmia of pregnancy, with or without, 165
Cranial decompression, Observations regarding the indications for the operation of, 407
Cutaneous neoplasms, A practical classification of, 278
Cystic duct, The rôle of the, in recurring cholecystitis, 467
Cystocele, Interposition operation for the cure of prolapsus uteri, 418

DECOMPRESSION, cranial, Observations regarding the indications for the operation of, 407
Dislocation of the hip, The use of continued extension by means of a new extension frame in the bloodless reduction of congenital, 518
Diverticula, Congenital, of the intestines, report of a case of a tumor growing from the tip of an apparently congenital diverticulum in the lower sigmoid region, 473
Drainage, Negative pressure versus free open, in thoracic empyema, 375; Peritoneal, indications, methods and materials, 326; Gynecological and pelvic, 514
Duct, The rôle of the cystic, in recurring cholecystitis, 467
Duodenal obstruction, Diagnosis and treatment of chronic, 174; ulcers, Perforated gastric and, 399
Duodenectomy, its effect upon the life of an animal, transplantation of the pancreatic duct, 36

ECTOPIC or pelvic kidney, 446
Empyema, The surgical treatment of, 337; analysis of 70 cases at Base Hospital, Camp Jackson, South Carolina, 348; Observations on, 371; Negative pressure versus free open drainage in thoracic, 375; The, problem, 379
End-results, of operative treatment, Clinical data on chorio-epithelioma with, 123; Operative treatment of undescended or mal-descended testis with especial reference to, 452
Experimental production of pancreatitis in animals as the result of the resistance of the common duct sphincter, 529
Extension frame, The use of continued extension by means of a new, in the bloodless reduction of congenital dislocation of the hip, 518
Extra-uterine, pregnancy, Tubal and ovarian hæmorrh its etiological relation to pelvic hæmatocele and,

FISTULA, anorectal, The treatment of certain typ 276
Food passages, Observations on the pathology of for bodies in the air and, based on alysis of cases, 201
Forceps, A new, for the contro of after t removal of the tonsils, 324

Foreign bodies, Observations on the pathology of, in the air and food passages based on an analysis of 628 cases, 201
Fracture, Ununited, of the patella and of the olecranon, 422

GALL-BLADDER, Are we justified in removing a comparatively healthy, 402
Gastric and duodenal ulcers, Perforated, 399
Gastro-enterostomy, Some technical points in, and gastroplication, 428
Gastroplication, Some technical points in gastro-enterostomy and, 428
Goiter, Pathology of, based upon specimens received at the State Institute for the Study of Malignant Disease, Buffalo, New York, 153; surgical treatment of, A summary of the, 431
Gunshot wounds, of the chest, The early treatment of, 12; The later stages of, 17; of the lungs, and their treatment at the Front, 1
Gynecological and pelvic drainage indications, methods and materials, 514

HÆMATOCELE, pelvic, and extra-uterine pregnancy, Tubal and ovarian hæmorrhage, its etiological relation to, 117
Hæmorrhage, A new forceps for the control of, after the removal of the tonsils, 324
Hernia, tr. 524
Herniotomy, Suggested step in the technique of inguinal, 329
Hip, The use of continued extension by means of a new extension frame in the bloodless reduction of congenital dislocation of the, 518
Hodgkin's disease, The treatment of, 440
Hydatiform degeneration in tubal pregnancy, a report of 48 new cases, 293
Hypertrophied prostate, Shall operation for, be done in two stages, 56
Hysterectomy, The effect of, upon ovarian function, 146; A vaginal, technique for the cure of prolapse of the uterus when the removal of the uterus is necessitated, with special reference to lapping of the vaginal fascia in all forms of vaginal prolapse, 138

INCISION, abdominal, A simple and expeditious method of performing the, 83
Incontinence of urine, An operation for the cure of, 84
Indications for the operation of cranial decompression, Observations regarding the, 407
Infants, Hypertrophic stenosis of the pylorus in, 159
Infection of a fused kidney with duplication of the left renal pelvis, 183
Influenza epidemic, Acute appendicitis complicating, with report of 8 cases, 601
Inguinal herniotomy, Suggested step in the technique of, 329
Inserts, Foreign bodies in the air and food passages (Jackson) opposite, 224, 226; The empyema problem (Beck) 392, 393; The experimental production of pancreatitis in animals as the result of the resistance of the common duct sphincter (Archibald) opposite, 529
Interposition operation for the cure of prolapsus uteri and cystocele, 418
Intestinal, Acute, obstruction following appendectomy, 561; resection, A simple method of excluding the septic end of the bowel during, 322
Intestines, Congenital diverticula of the, report of a case of a tumor growing from the tip of an apparently congenital diverticulum in the lower sigmoid region, 473.
Intravenous injection of salvarsan or antitoxin in combination with normal salt solution, Simplified technique for the, 323

JAUNDICE, Pancreatic lymphangitis, with and without, 433

KIDNEY, and ureter, The clinical significance of congenital anomalies of the, with notes on the embryology and fœtal development of the, 97; Infection of a fused, with duplication of the left renal pelvis, 183; Ectopic or pelvic, 446

LAPAROPLASTY by a new method, 598
Liver, The operation of omentopexy in cirrhosis of the, 309
Local anæsthesia, Accidents from, cor. 528
Lowe's colostomy receptacle, 319
Lung, Gunshot wounds of the, and their treatment at the Front, 1
Lymphangitis, Pancreatic, with and without jaundice, 433

MALIGNANT Disease, Pathology of goiter, based upon specimens received at the State Institute for the Study of, Buffalo, New York, 153
Mixed tumors, The mesodermal, of the uterus, report of a case of botrioid chondrosarcoma of the endometrium, 43
Mobilization, Treatment of purulent arthritis by wide arthrotomy followed by immediate active, 546
Musculospiral, A method of exposing the, and the posterior interosseous nerves, 612

NEOPLASMS, A practical classification of cutaneous, 278
Nerves, A method of exposing the musculospiral and posterior interosseous, 612
New-growths of the testis, their symptomatology, pathology, diagnosis, and treatment, 486

OBSTRUCTION, chronic duodenal, Diagnosis and treatment of, 174; Acute intestinal, following appendectomy, 561; Incompetency of the ureterovesical valves not due to, 316
Olecranon, Ununited fracture of the patella and of the, 422
Omentopexy, The operation of, in cirrhosis of the liver, 309
Omentum, Torsion of the great, during pregnancy, 33
Operation for the production of sterility, 317
Osteomyelitis of the clavicle, tr. 525
Ovarian, function, The effect of hysterectomy upon, 146; hæmorrhage, Tubal and, its etiological relation to pelvic hæmatocele and extra-uterine pregnancy, 117

PANCREATIC duct, Duodenectomy, its effects upon the life of an animal, transplantation of the, 36
Pancreatic lymphangitis, with and without jaundice, 433
Pancreatitis, The experimental production of, in animals as a result of the resistance of the common duct sphincter, 529
Papilloma of the large bowel, tr. 524
Parotitis as a postoperative complication, 404
Patella, Ununited fracture of the, and of the olecranon, 422
Pathology, Observations on the, of foreign bodies in the air and food passages based on the analysis of 628 cases, 201; of goiter, based upon specimens received at the State Institute for the Study of Malignant Disease, Buffalo, New York, 153
Pelvic, hæmatocele, Tubal and ovarian hæmorrhage, its etiological relation to, 117; drainage, Gynecological and, 514; kidney, Ectopic or, 446

Pendulous abdomen, The extreme, and its surgical treatment by a new three-flap operation, 190
Perforations, Acute, of the abdominal viscera, 28
Peritoneal drainage, 326
Plasty, Laparo-, by a new method, 598
Pleuritis (empyema), A review of the treatment of purulent, at Camp Pike Base Hospital, 362
Pneumonitis, Further studies in postoperative, 282
Pneumothorax, Treatment of chest wounds with special reference to artificial, 5
Pocket method, The, of closing skin defects, 320
Polyposis of the stomach, 465
Posterior interosseous nerves, A method of exposing the musculospiral and the, 612
Postoperative, complications, Parotitis as a, 404; pneumonitis, Further studies in, 282; treatment, Prostatectomy, with its preparatory and, 459
Pregnancy, A theory on the etiology of the toxæmia of, with or without convulsions, 165; Hydatiform degeneration in tubal, a report of 48 new cases, 293; Torsion of the great omentum during, 33
Preparatory and postoperative treatment, Prostatectomy, with its, 459
Primary suture of wounds, 603
Prolapse of the uterus, A vaginal hysterectomy technique for the cure of, when the removal of the uterus is necessitated, with special reference to lapping of the vaginal fascia in all forms of vaginal prolapse, 138; and cystocele, Interposition operation for the cure of, 418
Prostate, Shall operation for hypertrophied, be done in two stages, 56
Prostatectomy, suprapubic, A simple method of draining the bladder after, 91; With its preparatory and postoperative treatment, 459; The status of the vesical sphincter after, 569
Purulent, arthritis, Treatment of, by wide arthrotomy followed by immediate active mobilization, 546; pleuritis (empyema), A review of the treatment of, at Camp Pike Base Hospital, 362

RECONSTRUCTION of the uterus, 516
Renal, pelvis, Infection of a fused kidney with duplication of the left, 183; tuberculosis, Roentgenographic diagnosis in, 555
Resection, A simple method of excluding the septic end of the bowel during intestinal, 322
Retrodisplacement, of the uterus, The treatment of, at the Washington University Out-Patient Department and Barnes Hospital, 68
Roentgenographic, diagnosis in renal tuberculosis, 555; study of shoulder cases, Necessity for special positions in the, 615

SALVARSAN, Simplified technique for the intravenous injection of, or antitoxin in combination with normal salt solution, 323
Septic end of the bowel, Simple method of excluding the, during intestinal resection, 322
Shoulder cases, Necessity for special positions in roentgenographic study of, 615
Skin defects, The pocket method of closing, 320
Sphincter, vesical, The status of the, after prostatectomy, 569
Splenectomy, in diseases of the spleen, reporting 4 operative recoveries, 509
Splenomegaly, A variety of massive syphilitic, attended by remarkable vascular changes, 58
Sponge, A gauze, spontaneously expelled from the urinary bladder, 522
Stenosis, Hypertrophic, of the pylorus in infants, 159
Sterility, An operation for the production of, 317
Stomach, Carcinoma of the, report of three cases with no recurrence five years after operation, 76; Polyposis of the, 465
Stone in the bladder, tr. 524
Suprapubic prostatectomy, A simple method of draining the bladder after, 91
Surgical, The, treatment of empyema, 337
Synovial fluid, Artificial, cor. 331
Syphilitic, induration of the vulva, report of 4 cases, 482; splenomegaly, A variety of massive, attended by remarkable vascular changes, 58

TECHNICAL points, Some, in gastro-enterostomy and gastroplication, 428
Technique, Suggested step in the technique of inguinal herniotomy, 329
Teratoma testis, The radical operation for, with report of 5 cases, 495
Testis, Operative treatment of undescended or maldescended, with especial reference to end-results, 452; New-growths of the, their symptomatology, pathology, diagnosis, and treatment, 486; teratoma, The radical operation for, with the report of 5 cases, 495
Thoracic empyema, Negative pressure versus free open drainage in, 375
Three-flap operation, The extreme pendulous abdomen and its surgical treatment by a new, 190
Tonsils, A new forceps for the control of hæmorrhage after the removal of, 324
Torsion of the great omentum during pregnancy, 33
Toxæmia of pregnancy, A theory on the etiology of the, with or without convulsions, 165
Transactions, Chicago Surgical Society, 524, 525
Transfusion, Blood, 262; apparatus, 327
Transplantation of the pancreatic duct, Duodenectomy, its effect upon the life of an animal, 36
Tubal, and ovarian hæmorrhage, its etiological relation to pelvic hæmatocele and extra-uterine pregnancy, 117; pregnancy, Hydatiform degeneration in, a report of 48 new cases, 293
Tuberculosis, Roentgenographic diagnosis in renal, 555
Tumor, Congenital diverticula of the intestine, report of a case of a, growing from the tip of an apparently congenital diverticulum in the lower sigmoid region, 473
Typhoid vaccine, Immediate surgical management of acute appendicitis in military surgery suggesting a possible relationship between the onset of this condition in those cases with a history of previous attacks and the present method of administering triple, 303

ULCERS, Perforated gastric and duodenal, 399
Undescended or mal-descended testis, Operative treatment of, with especial reference to end-results, 452
Ureterovesical valves, Incompetency of the, not due to obstruction, 316
Ureter, The clinical significance of congenital anomalies of the kidney and, with notes on the embryology and fœtal development of the kidney, 97
Urinary bladder, A gauze sponge spontaneously expelled from the, 522
Urine, An operation for the cure of incontinence of, 84
Uterus, The mesodermal mixed tumors of the, report of a case of botrioid chondrosarcoma of the endometrium, 43; The treatment of retrodisplacement of the, at the Washington University Out-Patient Department and Barnes Hospital, 68; Reconstruction of the, 516

VACCINE, triple typhoid, Immediate surgical management of acute appendicitis in military surgery suggesting a possible relationship between the onset of this condition in those cases with a history of previous attacks and the present method of administering the, 303
Vaginal hysterectomy technique for the cure of prolapse of the uterus when the removal of the uterus is necessitated, with special reference to lapping of the vaginal fascia in all forms of vaginal prolapse, 138
Vascular changes, A variety of massive syphilitic splenomegaly attended by remarkable, 58
Vesical, sphincter, The status of the, after prostatectomy, 569; uretero-valves, Incompetency of the, 318
Viscera, Acute perforations of the abdominal, 28
Vulva, Syphilitic induration of the, report of 4 cases, 482

WAR, amputations, 478; wounds, Early treatment, 24 Wounds, chest, Treatment of, with special reference to artificial pneumothorax, 5; The early treatment of gunshot, 12; The later stages of gunshot, 17; of the lung, Gunshot, and their treatment at the Front, 1; war, The early treatment of, 24; The primary suture of, 603

BOOK REVIEWS

Modern Urology. In original contributions by American Authors. Vol. ii. Edited by Hugh Cabot, M.D., F.A.C.S., 93
Diseases of Women. By Harry Sturgeon Crossen, M.D., F.A.C.S., 4th ed., 333
Tumors of the Nervus Acusticus and Syndrome of Cerebellopontile Angle. By Harvey Cushing, M.D., 93
La Suspension dans le Traitement des Fractures. By Desfosses and Charles-Robert, 93
Surgery of the Spine and Spinal Cord. By Charles H. Frazier, M.D., Sc.D., 92
Gynecology. By William Graves, A.B., M.D., 2d ed., 333
A Textbook of Obstetrics. By Barton Cooke Hirst, A.B., M.D., LL.D., F.A.C.S., 8th ed., 333
Talks on Obstetrics. By Rae Thornton LaVake, M.D., 333
Fibroids and Allied Tumors. By Cuthbert Lockyer, M.D., B.S., F.R.C.P., F.R.C.S., 332
Obstetrics, Normal and Operative. By George Peaslee Shears, B.S., M.D., and E. E. Shears, M.D., 2d ed., revised, 333
Oxford Loose Leaf Surgery. By Various Authors. Edited by F. F. Burghard, M.S. (Lond.), F.R.C.S. (Eng.), Colonel A.M.S., and Allen B. Kanavel, A.B., M.D., F.A.C.S., Colonel, M.C., U.S.A., 92
Abstracts of War Surgery. An Abstract of War Literature of General Surgery that has been published since the declaration of war in 1914. Prepared by the Division of Surgery, Surgeon General's Office, 93

"Sutures fit for Surgery!"
Surgeons of Discernment
care not who WAS first in the Suture field, but who has BECOME first
DAVIS & GECK, INC.
217-221 Duffield Street, Brooklyn, N.Y.
Seattle San Francisco London
© 1918, DAVIS & GECK, INC.

CONTENTS—JANUARY, 1919

ORIGINAL ARTICLES

Symposium on Surgical Treatment of Gunshot Wounds of the Lungs

1. GUNSHOT WOUNDS OF THE LUNG AND THEIR TREATMENT AT THE FRONT. *Major Pierre Duval, Paris, France* 1

2. TREATMENT OF CHEST WOUNDS WITH SPECIAL REFERENCE TO ARTIFICIAL PNEUMOTHORAX. *Lieutenant Colonel Raffaele Bastianelli, Rome, Italy* 5

3. THE EARLY TREATMENT OF GUNSHOT WOUNDS OF THE CHEST. *Colonel G. E. Gask, D.S.O., London, England* 12

4. THE LATER STAGES OF GUNSHOT WOUNDS OF THE CHEST. *Major G. Grey Turner, R.A.M.C. (T.), Newcastle-upon-Tyne, England* 17

---

5. THE EARLY TREATMENT OF WAR WOUNDS. *Colonel G. E. Gask, D.S.O., London, England.* 24

6. ACUTE PERFORATIONS OF THE ABDOMINAL VISCERA. *William J. Mayo, M.D., F.A.C.S., Rochester, Minnesota* 28

7. TORSION OF THE GREAT OMENTUM DURING PREGNANCY. *J. L. Bubis, M.D., Cleveland, Ohio* 33

CONTENTS CONTINUED OPPOSITE NEXT PAGE

The Auscultation Method

The Nicholson Princo Sphygmomanometer

Portable Mercurial Instrument with the Steel Reservoir

Price { Type A (260 mm.), $22.50 / Type B (300 mm.), $24.00

Accurate Systolic and Diastolic Pressures can be obtained only by the use of the Mercurial Instrument and the Auscultation Method.

Read what they say

Dr. Cabot—"Physical Diagnosis." Pages 107-110.
Dr. Norris — "Blood Pressure, its Clinical Application." Page 68.
Dr. Goodman —"Blood Pressure in Medicine and Surgery." Page 56.

"Blood Pressure," a booklet which describes the Auscultation Method and contains a complete description of this Instrument, mailed free upon request along with a pamphlet on the Clinical Significance of Diastolic and Pulse Pressure.

Precision Thermometer & Instrument Co., 1434 Brandywine Street PHILADELPHIA - PA.

Economy of Gas Control of Flow
Simplicity of Operation

Use S. S. White Nitrous-Oxid and Oxygen. Always reliable. For sale by dealers in surgical or dental supplies.

You should know more about these features of S. S. White Nitrous-Oxid-Oxygen equipment (with ether attachment) for surgical anesthesia.

—

Fully described in Catalog R—mailed free upon request.

The S. S. White Dental Manufacturing Company

"Since 1844 the Standard"

PHILADELPHIA



Dr. Charles Geiger's

Electro-Operative Surgical Bone Instruments and Accessories

These instruments are made especially for transplanting bone, dowel making and cranial work. **Water is not required** to keep the cutters from burning the bone when using these instruments, **because of their slow speed.**

A few of the many advantages not found in any other motor bone instruments are: Slow speed, sterilization of motor, its great power, simplicity of chuck, and firmness with which it can be held. Sterilizable shell is included in the set.

Write F. A. Davis Pub. Co., Philadelphia, Pa., for Dr. Charles Geiger's book on **"MODERN OPERATIVE BONE SURGERY."**

The Charles Geiger Mfg. Co.
St. Joseph, Missouri, U. S. A.

CONTENTS—JANUARY, 1919—CONTINUED

ORIGINAL ARTICLES — CONTINUED

8. DUODENECTOMY—ITS EFFECT UPON THE LIFE OF AN ANIMAL; TRANSPLANTATION OF THE PANCREATIC DUCT. *Ernest F. Grey, M.D., Baltimore* 36

9. THE MESODERMAL MIXED TUMORS OF THE UTERUS; REPORT OF A CASE OF BOTRIOID CHONDROSARCOMA OF THE ENDOMETRIUM. *Isidor Perlstein, M.D., Chicago* 43

10. SHALL OPERATION FOR HYPERTROPHIED PROSTATE BE DONE IN TWO STAGES? *Franklin R. Wright, M.D., F.A.C.S., Minneapolis, Minnesota* 56

11. A VARIETY OF MASSIVE SYPHILITIC SPLENOMEGALY ATTENDED BY REMARKABLE VASCULAR CHANGES. *Douglas Symmers, M.D., Alexander O. Gettler, Ph.D., and William M. Johnson, New York* 58

12. THE TREATMENT OF RETRODISPLACEMENT OF THE UTERUS AT THE WASHINGTON UNIVERSITY OUT-PATIENT DEPARTMENT AND BARNES HOSPITAL. *E. C. Sage, M.D., Omaha, Nebraska, and Q. U. Newell, M.D., St. Louis, Missouri* 68

13. CARCINOMA OF THE STOMACH; REPORT OF THREE CASES WITH NO RECURRENCE FIVE YEARS AFTER OPERATION. *John Douglas, M.D., F.A.C.S., New York* 76

DEPARTMENT OF TECHNIQUE

14. A SIMPLE AND EXPEDITIOUS METHOD OF PERFORMING THE ABDOMINAL INCISION. *P. Brooke Bland, M.D., Philadelphia* 83

CONTENTS CONTINUED OPPOSITE NEXT PAGE

PANTOPON "ROCHE"
PANTOPIUM HYDROCHLORICUM

IN WAR SURGERY
RECENT LITERATURE

Lieut.-Colonel Harvey Cushing, M.C., U. S. A.
Director U. S. Army Base Hospital No. 5.

"Notes on Penetrating Wounds of the Brain."—*British Medical Journal*, February 23, 1918; reprinted in *Review of War Surgery and Medicine*, issued by the Surgeon General's office, July, 1918.

Colonel H. M. W. Gray, C.B., A.M.S.

"Surgical Treatment of Penetrating Wounds of Thorax."—*N. Y. Medical Journal*, June 8, 1918.
"Treatment of Gunshot Injuries of the Spinal Cord."—*N. Y. Medical Journal*, May 18, 1918.
"Treatment of War Wounds of the Brain and Its Coverings at Casualty Clearing Stations."—*N. Y. Medical Journal*, March 2 and April 20, 1918.
"Surgical Treatment at Advanced Units."—*N. Y. Medical Journal*, Dec. 1, 1917.

Captains Lockwood, Kennedy, MacFie and Lieutenant Charles, R.A.M.C.

"Gunshot Wounds of the Abdomen."—*British Medical Journal*, March 10, 1917.

Reprints and Abstracts on Application.

THE HOFFMANN-LA ROCHE CHEMICAL WORKS, New York

THE
RADIUM INSTITUTE

1604 Mallers Bldg., 59 E. Madison St.
Cor. Wabash Ave., Telephone Randolph 5794
C H I C A G O

DR. FRANK E. SIMPSON

COUNCIL

DR. F. A. BESLEY — DR. E. C. DUDLEY
DR. A. R. EDWARDS — DR. O. T. FREER
DR. M. HERZOG — DR. L. E. SCHMIDT
DR. G. F. SUKER

TREATMENT of Malignant and Benign Growths with Radium; Postoperative Prophylactic Radiations following the Surgical Treatment of Cancer.

Radium is indicated in inoperable malignant conditions. By its use an inoperable case may become operable.

We desire to confer and co-operate with surgeons, assuring them adequate amounts of Radium to meet the requirements of patients referred to us.

READY FOR EMERGENCIES

With a Lilly Ampoule Case and a Few Lilly Ampoules You Are Ready for Emergencies

The Lilly Ampoule Line

LILLY AMPOULES include a wide range of sterile solutions specially intended for use in PNEUMONIA—INFLUENZA—BRONCHITIS—ACUTE RHEUMATIC ARTHRITIS—ANEMIA; also the STANDARD CARDIAC and RESPIRATORY STIMULANTS—ANESTHETICS and SEDATIVES used in emergencies.

Send for catalog illustrated in colors showing these improved Lilly Aseptic Metal Pocket Cases in various sizes, nickel and gold plated.

Supplied Through the Drug Trade

ELI LILLY & COMPANY, Indianapolis, U.S.A.

NEW YORK CHICAGO ST. LOUIS KANSAS CITY NEW ORLEANS

CONTENTS—JANUARY, 1919—CONTINUED

DEPARTMENT OF TECHNIQUE — CONTINUED

15. AN OPERATION FOR THE CURE OF INCONTINENCE OF URINE. *Hugh Hampton Young, M.D., F.A.C.S., Baltimore, Maryland* 84

16. A SIMPLE METHOD OF DRAINING THE BLADDER AFTER SUPRAPUBIC PROSTATECTOMY. *E. Denegre Martin, M.D., F.A.C.S., New Orleans* 91

BOOK REVIEWS

Oxford Loose-Leaf Surgery. By various authors. Edited by F. F. Burghard, M.S. (Lond.), F.R.C.S. (Eng.), Colonel A.M.S., and Allen B. Kanavel, A.B., M.D., F.A.C.S., Colonel, M.C., U.S.A 92

Surgery of the Spine and Spinal Cord. By Charles H. Frazier, M.D., Sc.D. With the collaboration of Alfred Reginald Allen, M.D 92

Modern Urology. In original contributions by American Authors. Vol. II. Edited by Hugh Cabot, M.D., F.A.C.S... 93

Abstracts of War Surgery. An Abstract of the War Literature of General Surgery that has been published since the declaration of war in 1914. Prepared by the Division of Surgery, Surgeon General's Office 93

Tumors of the Nervus Acusticus and the Syndrome of the Cerebellopontile Angle. By Harvey Cushing, M.D..... 93

La Suspension dans le Traitement des Fractures. By Desfosses and Charles-Robert..... 93

Books Received..... 94

AMERICAN COLLEGE OF SURGEONS

PROPOSAL FOR MEMBERSHIP IN COLLEGE 95

HOSPITAL SERVICE BUREAU 95

HONORARY FELLOWSHIPS CONFERRED IN NEW YORK 95

CANADIAN FELLOWS EXPRESS THEIR EQUATION 96

MILITARY SERVICE OF CANADIAN FELLOWS 96

DOUBLE SERVICE
"UNDER PRESSURE"

NATIONAL HIGH PRESSURE STERILIZER

has maintained its reputation for instant and efficient service by meeting the most pressing demands of surgical practice in army hospitals, furnishing

STERILIZED "BONE DRY" DRESSINGS IN HALF THE USUAL TIME

Lessening of war demands enables us to begin supplying peace requirements, but to get reasonably prompt delivery you should order now and secure the next place in the waiting list.



Three Sizes: Doctor's, $60; Medium, $85; Hospital, $145

Embodies simplicity, low cost and high efficiency, doing all the work of the autoclave. Operates under steam pressure of 1 to 30 pounds at temperatures of 112 to 260 degrees. Equipped with gas or gasoline burner or steam coil as required. In successful service in over 2000 American hospitals and offices.

Write for full particulars and name of your nearest National dealer

NORTHWESTERN STEEL & IRON WORKS
880 Spring Street, EAU CLAIRE, WIS.

Capital $200,000

WAPPLER

Electrically Lighted Diagnostic Instruments and Electro-Medical Apparatus are Used by the U. S. Government

X-Ray Equipments

High Frequency Apparatus

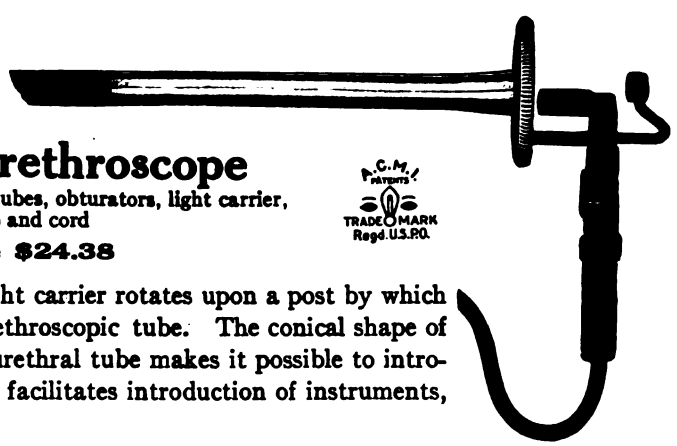

Young Urethroscope

Complete in case with 3 tubes, obturators, light carrier, lamp and cord

Price $24.38

U.S. & C. Pat. Pending
TRADE MARK Regd. U.S.P.O.

In this instrument the light carrier rotates upon a post by which it is attached to the urethroscopic tube. The conical shape of the proximal end of the urethral tube makes it possible to introduce more light, and also facilitates introduction of instruments, swabs, etc.

A valuable instrument at low cost for the Urologist and the General Practitioner. Send for one today

WAPPLER ELECTRIC COMPANY, Inc.

Dept. S, 173 East 87th Street, NEW YORK, U. S. A.

Chloretone Produces Natural Sleep

Administered internally, **CHLORETONE** passes unchanged into the circulation, inducing (in efficient therapeutic doses) profound hypnosis. It does not depress the heart or respiratory centers. It does not disturb the digestion. It is not habit-forming. **CHLORETONE,** in a word, *produces natural sleep.*

◆ ◆ ◆

In addition to its primary function as a hypnotic, **CHLORETONE** has a wide range of therapeutic applicability as a sedative. It is useful in alcoholism, delirium tremens, cholera, colic; epilepsy, chorea, pertussis, tetanus and other spasmodic affections; nausea of pregnancy, gastric ulcer and seasickness; mania (acute, puerperal and periodic), senile dementia, agitated melancholia, motor excitement of general paresis.

CHLORETONE: Ounce vials.
CHLORETONE CAPSULES: 3-grain, bottles of 100 and 500.
CHLORETONE CAPSULES: 5-grain, bottles of 100 and 500.
Dose, 3 to 15 grains.

SEE THAT YOUR DRUGGIST IS ABLE TO SUPPLY YOU.

Home Offices and Laboratories,
Detroit, Michigan.

PARKE, DAVIS & CO.

INDEX TO ADVERTISING

Surgical Instruments and Apparatus

Bauer & Black 32
Burdick Cabinet Co 16
Electro Surgical Instrument Co 15
Feick Brothers Co 37
Charles Geiger Mfg. Co 3
Goodwill Electric Co 17
Kimble Glass Co 14
Kny-Scheerer Corporation 10
McIntosh Battery & Optical Co 9
V. Mueller & Co 14
Northwestern Steel & Iron Works . 6
Harvey R. Pierce Co 12
John D. Pollard 34
Precision Thermometer & Instrument Co 2
Prometheus Electric Co 30
Sharp & Smith 28
Taylor Instrument Companies 15
Truax, Inc 34
Victor Electric Co 26
Wappler Electric Co 6

Hospital Supplies

Bauer & Black 32
Burdick Cabinet Co 16
General Laboratories 16
Good Mfg. Co 32
Kny-Scheerer Corporation 10
V. Mueller & Co 14
Northwestern Steel & Iron Works . 6
Harvey R. Pierce Co 12
Prometheus Electric Co 30

Rubber Goods, Gloves, Etc.

E-Z Patch Co 30
L. T. Kinney & Co 32

X-Ray Apparatus, Tubes, Plates, Etc.

American Photo Chemical Co 33
Geo. W. Brady & Co ..... 2nd cover
Campbell Electric Co 28
Eastman Kodak Co 29
General Electric Co 31
McIntosh Battery & Optical Co ... 9
Wm. Meyer Co 30
Victor Electric Co 26
Wappler Electric Co 6

Catgut — Ligatures

Armour & Co ..... 4th Cover
Davis & Geck, Inc 1
Hollister-Wilson Laboratories 11
Johnson & Johnson 25
C. DeWitt Lukens Co 24

Anæsthesia Apparatus

Foregger Co 15
Safety Anæsthesia Apparatus Concern 14
Scientific Apparatus Co 27
S. S. White Dental Mfg. Co 2

Corsets, Bands, Etc.

Earnshaw Knitting Co 32
Katherine L. Storm 32

Miscellaneous

Battle Creek Sanitarium 36
Gradwohl Biological Laboratories .. 16
Medical Protective Co 37
Quaker Oats Co 27

Medical Books

P. Blakiston's Son & Co 17
Lea & Febiger 23
Macmillan Co 22
Medicine and Surgery Pub. Co 17
C. V. Mosby Co 20
Oxford University Press 19
Rebman Company 21
W. B. Saunders Co ..... Cover and 13

Pharmaceuticals

Abbott Laboratories 8
Armour & Co ..... 4th Cover
Cutter Laboratory ..... 3rd Cover
General Laboratories 16
Greeley Laboratories 14
Hoffman-LaRoche Chemical Works 4
Hynson, Westcott & Dunning, 4th Cover
Lilly & Co ..... Insert and 5
H. A. Metz Laboratories, Inc 35
Parke, Davis & Co 7
Sharp & Dohme 34
Dr. G. H. Sherman ..... 2nd Cover
E. R. Squibb & Sons 15
Standard Oil Co 39

Radium

Physicians' Radium Association ... 37
Radium Chemical Co 9
Radium Company of Colorado 25
Radium Institute 4

Post-Graduate Instruction

Laboratory of Surgical Technique . 36
New York Post-Graduate Medical School and Hospital 40

EVERY DOCTOR in the UNITED STATES

should try this remarkable, new time, money and pain saving Lace-Mesh Surgical Dressing

Take Advantage of Our Special Offer Below

NON-ADHERENT **NON-OCCLUSIVE**

Read what Lt.-Col. Edward Martin said in an address before the Sixth Conference of Industrial Physicians and Surgeons held in Philadelphia, April 9th, 1918, and reported in the *Pennsylvania Medical Journal* for August, 1918:—

> "The technic is as simple as that of iodine. The wound is brushed with a 3 to 5 per cent solution of dichloramine-chlorcosane. If it is a raw surface, such as a burn, with destruction of the skin, it is protected against the removal of a sticking dressing by putting over it a piece of paraffined mosquito netting with a wide mesh. Abbott's mosquito netting is fine. Over that is applied the dressing, which should be as thin as circumstances will admit of. This is fastened lightly in place. That is the whole dressing. It may be applied to a burn or to a deep wound leading down into a focus, but in all instances all dead parts should be removed. It is repeated once a day. Under this dressing we can bring broad granulating surfaces together, and have them hold; and the secretion is cut down to a minimum."

NOTE THESE ADVANTAGES — PARRESINED LACE-MESH IS

1. **ECONOMICAL, saving 50% to 75% of gauze, absorbent cotton and roller bandages.**
2. **NON-ADHERENT, saving the agony of removing sticking secretion-stiffened dressings.**
3. **TIME SAVING—it is easier and speedier to apply.**
4. **NON-OCCLUSIVE—permits continuous drainage and free access to antiseptics.**
5. **Comfortably soft and pliable.**
6. **NON-INJURIOUS to new epithelial cells.**

Use This Special Offer Order Form

THE ABBOTT LABORATORIES

Home Office and Laboratories
Dept. 82 CHICAGO

New York Seattle San Francisco
Los Angeles Toronto Bombay

I enclose $2.50. Please send me:

1 Package, six envelopes, Parresined Lace-Mesh	$1.20	**Total $2.50**
1 Ounce Dichloramine-T	0.65	
4 Ounces Chlorcosane	0.65	
1 Free Trial Tube Chlorazene Tablets	No charge	
1 Free Trial Bottle Digipoten Tablets	No charge	

Complete Literature.

Doctor_____ Address_____

Treatment *of* Lobar Pneumonia *with* Partially Autolyzed Pneumococci

IN THE *Journal of the American Medical Association* (pages 759 to 763—March 16th, 1918) Dr. E. C. Rosenow has reported results in the treatment of lobar pneumonia with partially autolyzed pneumococci.

His work has established the harmlessness of this antigen and apparently indicates that it has a definite beneficial action on the disease, especially when given early.

Supplied through the regular drug trade in five mil (c. c.) rubber-capped ampoule vials. Order as V-903.

ELI LILLY & COMPANY
INDIANAPOLIS, U. S. A.

NEW YORK CHICAGO ST. LOUIS
KANSAS CITY NEW ORLEANS

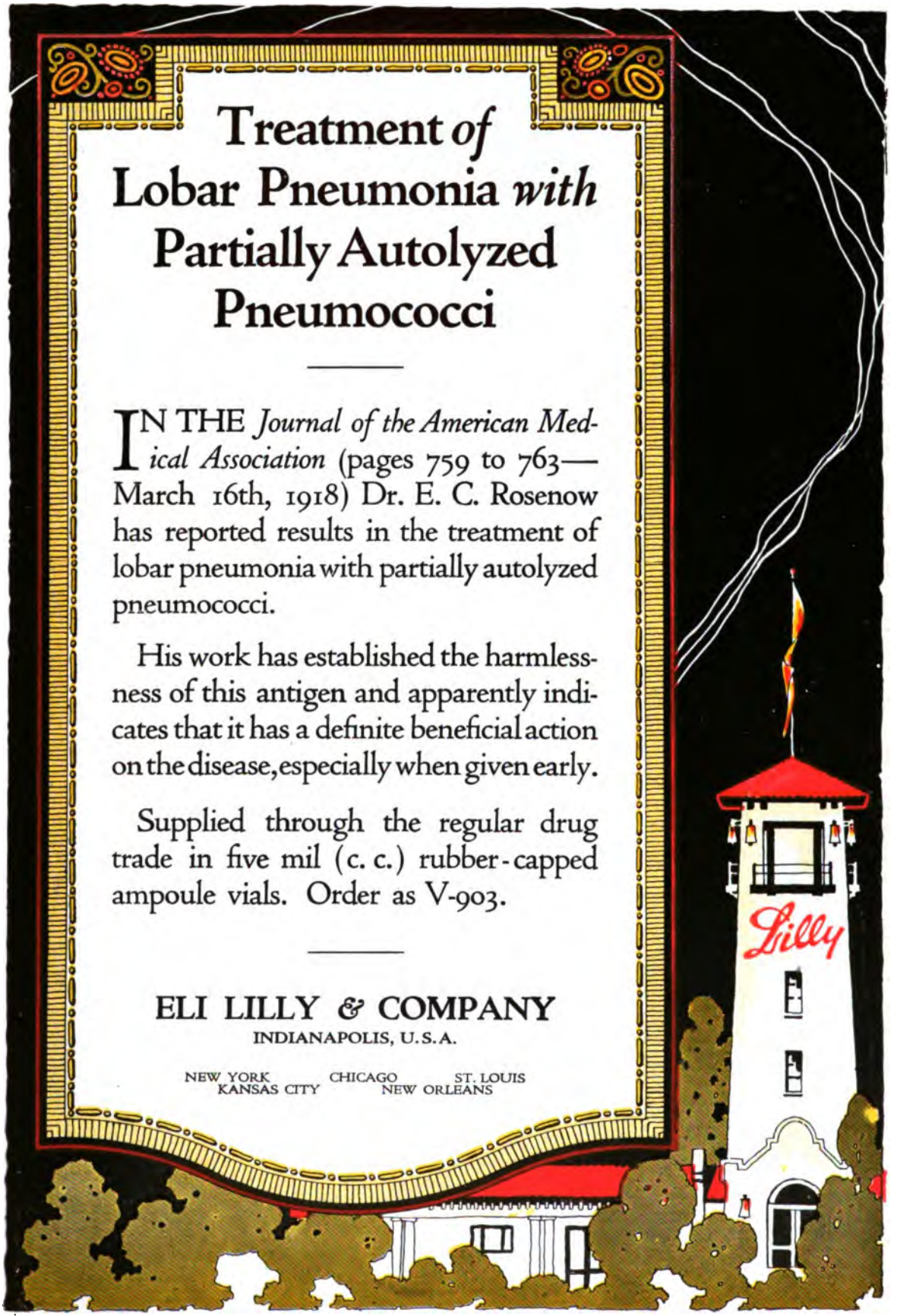

Diphtheria Antitoxin

For the Treatment and Prevention of Diphtheria

Carefully Tested
Accurately Standardized

A PRODUCT of high potency, small bulk and low solid content, prepared under strictly aseptic conditions by improved methods of concentration and purification.

LOWER PRICES

It has been the custom of manufacturers to offer Diphtheria Antitoxin in packages of two types—the "Regular" and the "Board of Health" packages, the latter at reduced prices. We have decided to supply the "Regular" type of packages only and at prices that are practically the same as the so-called "Board of Health" package.

We offer the following strengths of Diphtheria Antitoxin, Purified, Concentrated, (Globulin)

Package A-14— 1000 units in syringe
" A-20— 3000 " " "
" A-27— 5000 " " "
" A-33—10000 " " "
" A-34—20000 " " ampoule with apparatus for intravenous injection.

Specify "Lilly" on Your Diphtheria Antitoxin Orders

ELI LILLY & COMPANY

INDIANAPOLIS, U. S. A.

New York Chicago St. Louis Kansas City New Orleans

A Vaccine Virus

That Gives the Maximum Percentage of "Takes" in Primary Vaccinations

THE PREPARATION of this Vaccine Virus is carefully supervised from the first veterinary inspection of the calf to be used, to the sealed capillary tube. EACH LOT IS SUBJECTED to rigid bacteriological examinations and control before it is finally passed. SEARCHING TESTS are made to determine its potency.

This Vaccine Virus kept at 50° F. (ordinary refrigerator temperature) will retain its activity FOR AT LEAST THREE MONTHS. Virus will deteriorate rapidly at usual room temperature. It should not be carried in the vest or inside coat pocket. Comparatively brief exposure to body temperature will render it useless.

THE ABOVE FACTS EMPHASIZE the necessity of proper refrigeration, and the advantage, except in the presence of epidemics, of vaccinating in the cooler weather.

PROPERLY STORED AND PROPERLY USED, THIS VACCINE VIRUS will give the maximum percentage of "takes" in primary vaccinations. Specify "Lilly" on your Vaccine Virus orders.

Supplied Through the Drug Trade

ELI LILLY & COMPANY

INDIANAPOLIS, U. S. A.

New York **Chicago** **St. Louis** **Kansas City** **New Orleans**

RABIES VIRUS

HARRIS' MODIFICATION *of the* PASTEUR TREATMENT

A Safe Treatment for Administration by the Patient's Physician

THERE is no cure for rabies, once the symptoms have developed, but the disease may be prevented, during the incubation period, in persons bitten by rabid animals, by prophylactic injections of attenuated rabies virus.

WHAT THE VIRUS IS. The brains and spinal cords of animals dead from fixed virus inoculation are ground to a paste, frozen, pulverized and rapidly dried in vacuo. The powder is tubed in vacuo and stored in the cold.

ADVANTAGES OF RABIES VIRUS, LILLY

1. A high degree of immunity is established in a short time.
2. The virus is practically non-toxic (treatment free from complications, lessened reactions).
3. The virus is uniformly distributed through the vaccine.
4. The patient's time and money are economized.
5. It is available for prompt institution of treatment at home by the family physician.
6. The dosage is standardized in units according to the Harris Method (the early doses increasing to a maximum unitage, and this maximum unitage repeated to the end of treatment).

HOW RABIES VIRUS, LILLY, IS SUPPLIED

Lilly's Rabies Virus is supplied in syringe containers, emulsified and ready for use. Your druggist can secure the first three doses from the nearest Lilly depot; the remaining eleven doses will be supplied from Indianapolis, one daily, until the complete treatment of fourteen doses has been administered.

Write for Booklet on Rabies and Its Treatment

ELI LILLY & COMPANY

INDIANAPOLIS, U.S.A.

New York Chicago St. Louis Kansas City New Orleans

RADIUM

Radium in proper dosage has proven valuable in the treatment of Benign and Malignant Growths, and in Post-Operative Prophylactic Radiations.

Information as to dosage, technique, necessary equipment, etc., sent upon request.

Radium Chemical Company

General Offices and Laboratories, Pittsburgh, Pa.

501 Fifth Ave. New York — **Marshall Field Annex Bldg., Chicago** — **Little Bldg., Boston** — **Butler Bldg. San Francisco**

Messrs. Watson & Sons (Electro-Medical) Ltd.
43 Parker Street, Kingsway, London, W. C. 2, England

1919 40 Years of Service 1879

To the Medical Profession

On February 4, 1919, this Company will celebrate its Fortieth Anniversary

McIntosh No. 4 Polysine Generator

Special Red-Letter Anniversary Offer

You will not regret having filled out the coupon attached. Help us celebrate!

McINTOSH BATTERY & OPTICAL CO.
217-223 N. Desplaines St. CHICAGO, ILL.

The McIntosh No. 4 Polysine Generator

is typical of the high-class apparatus which many progressive physicians are daily employing with profit to their patients and—not least—to their prestige in the community. Wherever a galvanic and faradic wall plate is indicated, this apparatus is one step in the lead. Affords galvanic and sinusoidal currents on A. C., or D. C., without rectifier. Adopted by U. S., and Canadian Governments for military hospitals.

GENTLEMEN:—
Kindly send me particulars of your 40th anniversary; also send me free souvenir booklet and make me your special Red-Letter Offer.

Name_____

Address_____

Hawley New Fracture and Orthopedic Operating Table

Hundreds of these tables are in use in our Government Hospitals in this country and abroad as there is no other table which will answer the same purposes.

IT IS INDISPENSABLE IN FRACTURE WORK AS IT MAINTAINS THE REUNITED FRACTURE PERFECTLY UNTIL THE PLASTER IS SET OR THE GRAFT IS COMPLETED.

Head end is movable to facilitate easy and free access to the back and shoulders for jackets or spicas. Movable sections overlap to prevent soft parts of the body becoming wedged and injured.

Foot plates hold the foot at right angle to the limb and prevent toe drop. Foot plates rotate to any angle for hyper-abduction, hyper-extension, inward rotation and traction; also brings pressure against ball of foot to force the foot into dorsal flexion.

ACCEPT NO IMITATION; write for bulletin showing the genuine Hawley and Albee Surgical Apparatus and Instruments.

The Kny-Scheerer Corporation *Manufacturers of Surgical and Therapeutic Instruments and Apparatus*

404-410 West 27th Street, New York, U. S. A.

Preparing Perfect Surgical Gut

No. VIII—Sterilization

THE sterilization of Hollister Catgut Ligatures is practically a continuous process from the moment of the animal's slaughter. Bacterial development in the material itself is inhibited always, while the process of Peroxide and Sulphur bleaching through which each individual strip of tissue passes before spinning results in its actual sterilization at this stage of manufacture; though here considered as merely contributing to the final aseptic result.

Preliminary sterilization was considered in detail in the preceding issue, which is briefly: subjection of the finished raw gut to a temperature of not less than 150° C. on each of two successive days, and immediate immersion in antiseptic hydrocarbon, which effectually protects the gut from moisture during subsequent operations.

Cut into the standard suture lengths of twenty and sixty inches, the catgut is now tubed in our patented solution (a highly purified Hydrocarbon of the Paraffin series) and immediately sealed.

Dehydration being absolute, the sealed sutures may now be subjected to a temperature in steam under pressure far in excess of any pressure generally accepted as insuring absolute sterilization—and this repeated on the second day as a margin of safety.

Hollister Ligatures can be obtained wherever surgical supplies are sold

HOLLISTER-WILSON LABORATORIES

4444-46-48 So. Ashland Ave. CHICAGO, U. S. A.

"TUBES OF DISTINCTION"

Pratt-Lowman
Self-Retaining Retractor

for use in the open method of repairing fractures especially in connection with the Albee Motor Saw method.

Devised by Major John B. Lowman, M.C., and Captain R. B. Pratt, M.C., U. S. Base Hospital No. 38.

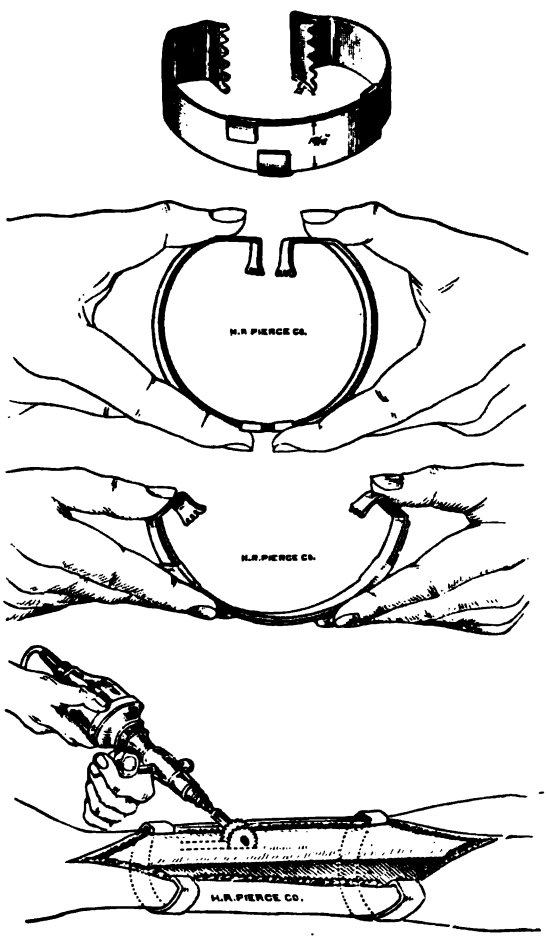

It affords the following advantages:

SIMPLICITY

No parts to be lost. Easy to clean, sterilize, manipulate.

DURABILITY

It not only gives RETRACTION of tissues, but also DEPRESSION of them with an uncomplicated automatic lock in any degree of retraction. Pressure upon its lower surface by the weight of the limb forcing it against the operating table only serves to increase retraction and locking.

It does away with retraction by assistants and with this the danger of extra hands in the operative field and leaves the operator unhindered in the use of the electric saw and drill.

It leaves the bone in a higher plane than the surrounding tissues and so obviates the danger of the saw, drill or spinning shaft engaging with the soft tissues or toweling.

In conjunction with an orthopedic table, assistants can be dispensed with during that stage of the operation in which the saw or drill is in use.

It is a useful addition in a teaching clinic in that it renders the field of operation more visible to spectators.

Made in several sizes.

Manufactured by

HARVEY R. PIERCE COMPANY

1801 Chestnut Street *The Modern Surgical Instrument Store* PHILADELPHIA

PITTSBURGH SALES OFFICE: 3030, 3031, 3032, 3033 JENKINS ARCADE

U. S. Army Number

The Medical Clinics of North America

MAJOR-GENERAL WM. C. GORGAS, Surgeon-General, U. S. Army.
Clinical Research in United States Army Base Hospital.

MAJORS W. W. HAMBURGER, M.C., and HERBERT FOX, M.C., Camp Zachary Taylor.
Study of the Epidemics of Pneumococcus and Streptococcus Infections, and Measles.

CONTRACT SURGEON W. G. MACCALLUM, M.D., Johns Hopkins University.
Pathology of the Streptococcal Pneumonias in the Army Camps.

LIEUT.-COL. CHANNING FROTHINGHAM, M.C., Camp Devens.
Function of a Base Hospital in a National Army Cantonment.

MAJOR EDWARD H. GOODMAN, M.C., Camp Jackson.
Results of Examination of 23,943 Drafted Men by Cardiovascular Board.

MAJOR W. W. HERRICK, M.C., Camp Jackson.
Meningococcic Pericarditis.

LIEUT. MORRIS H. KAHN, M.C., Camp Zachary Taylor.
Paroxysmal Tachycardia in Soldiers.

MAJORS E. P. JOSLIN, M.C., and HOMER GAGE, M.C., Camp Devens.
Postoperative Pneumonia.

MAJOR HARLOW BROOKS, M.C., Upton.
Neurocirculatory Asthenia.
Epidemic Parotitis as Military Disease.

MAJOR F. W. PEABODY, M.C., FIRST LIEUT. J. T. WEARN, M.C., and EDNA H. TOMPKINS, General Hospital No. 9.
Basal Metabolism in "Irritable Heart in Soldiers."

MAJOR LAWRENCE LITCHFIELD, M.C., Camp Grant.
Diagnosis of Acute Infections of the Thorax.

LIEUT.-COL. JOS. L. MILLER, M.C., and CAPTAIN FRANK B. LUSK, M.C., Camp Dodge.
Empyema.

MAJOR JOS. C. FRIEDMAN, M.C., and CAPTAIN WARREN T. VAUGHAN, M.C., Camp Sevier.
Subacute and Chronic Mediastinal Complications of Measles.
Comments on Methods Used in Preventing Measles Complications.

MAJOR RUSSELL L. CECIL, M.C., Camp Upton.
Pneumonia and Empyema.

MAJOR CHAS. L. MIX, M.C., Camp Mills.
Anthrax.

MAJOR DONALD J. FRICK, M.C., Camp Beauregard.
Cardiovascular Diseases.

MAJOR J. M. W. SCOTT, M.C., Camp Lee.
Drug Addiction.

FIRST LIEUT. MACY L. LERNER, M.C., Camp Joseph E. Johnston.
Marie's Disease. Infantilism. Hyperkeratosis. Subclavian Aneurysm.

MAJOR T. D. COLEMAN, M.C., and CAPTAIN E. F. HORINE, M.C., Camp Hancock.
Clinical Significance of Cardiac Murmurs.

MAJOR CHAS. SPENCER WILLIAMSON, M.C., Camp Greenleaf.
Prevention of Communicable Respiratory Diseases.

Issued serially, one octavo of about 300 pages, illustrated, every other month. Per Clinic Year (July to May): Cloth, $14.00 net; Paper, $10.00 net

W. B. SAUNDERS COMPANY, West Washington Sq., Phila.

London: 9, Henrietta St., Covent Garden Australian Agcy: Centreway, 263 Collins St., Melbourne

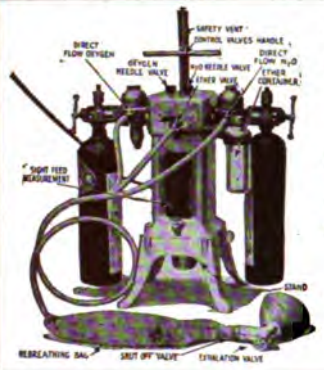

SAFETY GAS-OXYGEN APPARATUS

Simplifies the administration of
NITROUS OXIDE and OXYGEN
with or without an Ether Sequence
Major or Minor Surgery—Obstetrics—Dentistry

Positive mixtures instantly obtained, accurately maintained and clearly shown by the New Sight-Feed-Measurement, which is controlled by a simple water column. No gauges or springs to get out of order.
Complete outfits for Private and Hospital use.

Write for booklet containing full information

SAFETY ANAESTHESIA APPARATUS

CONSOLIDATED
Ogden Ave. and Randolph St., Chicago, Ill.



Positive Sight-Feed Measurement

7010 7020 9175

SPECIFY "KIMBLE" AMPULES

Made of special glass—non-corrosive and free from alkaloids.

The best ampules are none too good to act as containers for the vaccines, bacterins and hypodermics that you introduce into the blood stream of your patient.

In our product you are assured of first quality not only in workmanship but in material as well.

Easily closed over the ordinary Bunsen burner thereby furnishing a hermetically sealed, accurately measured dosage ready for use at any time.

Supplied in all sizes, 1cc. to 100cc. (flint or amber glass), and in any of the three styles illustrated above.

Rosenow Vaccine Ampule—Made of either flint or amber glass, hermetically sealed. Designed by Dr. E. C. Rosenow of Memorial Institute for Infectious Diseases, of Chicago. Consists of a ground top screw cap vial, fitted with a pure gum rubber washer, six hole perforated aluminum cap and aluminum slip over cap. (See cut at right.)

Capacity 1cc. to 25cc.

9200

Order direct or through your dealer. Specify sizes and styles desired.

KIMBLE GLASS COMPANY

Chicago, Ill. Vineland, N. J. New York, N.Y.

GREELEY HYPODERMIC UNIT

TRADE MARK

To Leave With Your Patient

At times you have cases where it is desirable to leave a hypodermic with the patient. For such cases the Greeley Hypodermic Unit is ideal. There is no piston or plunger to stick. There is no question of dose. There is absolute accuracy. It is so easily manipulated that any one can give it. Simply twist off a cap, pull out a stylet and it is ready.

10c in stamps will bring you a Unit that you may see just how easily it works. Send for it today.

GREELEY LABORATORIES, Inc.

659 Huntington Ave. BOSTON, MASS.

THE GREAT DEMAND FOR SURGEONS' INSTRUMENTS AND EQUIPMENT CAUSED BY THE WAR

has made it necessary to increase considerably our facilities for production, both as regards improved machinery and the number of men.

Now that the emergency has passed and Army work is no longer so urgent, we will again be in a position to offer to the medical profession our unequaled facilities and long experience in the construction of new instruments and special apparatus.

Through our representatives in England, France and the Orient, we are also in a position to secure for our customers any new devices which may have been introduced and found valuable by the profession abroad.

TRADE MARK

V. MUELLER & COMPANY 1771-83 Ogden Ave., Chicago

Makers of Instruments for Every Branch of Surgery

Liquid Petrolatum Squibb

Heavy (Californian)

THE mineral oil for infants, and children of all ages. It is the palatable, safe and efficacious regulator of the bowels and needs no menstruum or flavoring. It will not form a habit.

Refined under our control, and exclusively for us, only by the *Standard Oil Company of California* which has no connection with any other Standard Oil Co.

E·R·SQUIBB & SONS. NEW YORK
MANUFACTURING CHEMISTS TO THE MEDICAL PROFESSION SINCE 1858

Gwathmey Apparatus

The advantage of the "Sight Feed"
is not—to set the proportion,
it is—to get the proportion.
Nor is it—to know the amounts in liters or gallons,
but it is—to know what you are doing.



As an indicator for the quick obtainance and safe maintenance of uniform anesthetic conditions the visible gas flow of the "Sight Feed" is absolutely reliable and permanently so.

Write for Our 1919 Catalog

THE FOREGGER CO.
47 West 42nd Street NEW YORK

No comparative tests necessary. A glance *proves* its accuracy.

Dr. Rogers'
Tycos
Self-Verifying
Sphygmomanometer

Send postal for 40-page Blood Pressure Manual

Taylor Instrument Companies
Rochester, N. Y.

Electrically Lighted Instruments

From the best material obtainable and by skilled workmen E. S. I. Co. instruments are made. Not alone are we the originators, but, as well, we are exclusive manufacturers of the most valuable diagnostic instruments in use. Their position is firmly established among the profession and their usefulness is unquestioned.

All our instruments may be operated upon our tungsten battery or upon commercial current by means of the socket current controller here illustrated.

Koch, Swinburne, Young, Gordon and MacGowan Urethroscopes
Braasch Cystoscopes, E. S. I. Co. Vaginal Specula

These and many other instruments are described and illustrated in our Catalogue, a copy of which will be mailed upon request.

For your own protection be sure every instrument is marked "E. S. I. Co."

ELECTRO SURGICAL INSTRUMENT CO.
ROCHESTER, N. Y.

HYCLORITE

HYCLORITE

In Empyema

The use of Hyclorite in 1:1000 dilution for irrigating empyema cases after lobar pneumonia is enabling surgeons to discharge their patients in much shorter time than with previous methods of treatment. Hyclorite acts promptly, yet without irritation.

Hyclorite is always ready for immediate use.

Just add water and apply.

Hyclorite is prepared to a definite hypochlorite strenght and alkalinity.
Solutions made from Hyclorite keep much longer than ordinary Dakin's solutions.
There is no waste, testing, or waiting in making a Dakin's solution from Hyclorite.

Price, 32 oz., $1.25

Order From Your Supply House

Accepted by the Council on Pharm. and Chem. for inclusion in N.N.R.

GENERAL LABORATORIES
4709 South Dickinson St.
MADISON - - - WISCONSIN

Do You Want the Highest Order of Serological Diagnosis?

Send Your Specimens to us for

Wassermann and Hecht-Gradwohl Tests,
Gonorrheal Complement Fixation,
Tuberculosis Complement Fixation.

All other Laboratory Tests.

Gradwohl Biological Laboratories.
R. B. H. GRADWOHL, M.D., Director.
928 N. Grand Ave. ST. LOUIS, MO.

MODERN PAIN RELIEVING METHODS

MOST effective method of relieving the pains of Neuritis, Rheumatism, Arthritis, Neuralgia, Lumbago, Gastritis, etc., is obtained by the use of

Burdick Radio-Vitant Applicators

Treating a Case of Neuritis

We will send Free a concise and comprehensive treatise on light therapy and a copy of our new illustrated catalogue in three colors on receipt of post card request.

Extensively used in both the surgeon's office and hospital.

Specially adapted for use in the patient's home under supervision of the surgeon.

Standardized in the Surgeon-General's Office for use in the Military Reconstruction Hospitals.

Proven by practical experience to be far superior to vibrators, high frequency currents, "high candle-power lamps," etc., for local application in the relief of pain and inflammation.

Type L-4 Applicator, $27.50

5% discount for cash with order. Our guarantee, entire satisfaction or money back.

BURDICK CABINET CO., 200 Madison Ave., MILTON, WIS.

Paper Work of the Medical Department, U. S. Army

Containing a full description of the blanks, reports, instructions, etc., and numerous fac-similes of properly filled-in forms for use as a guide.

RALPH W. WEBSTER, M.D., Ph.D.

Major Medical Corps, U. S. Army; Instructor, Basic Military Course, and Adjutant, Camp Greenleaf, Chickamauga Park, Georgia; formerly Instructor at the Medical Officers' Training Camp, Fort Riley, Kansas; Author of Diagnostic Methods, Chemical, Bacteriological and Microscopical.

Approved for publication by direction of the Surgeon-General, U. S. Army

8 vo., 570 pages. Cloth, $5.00 Post-Paid

NOTE: This book will be forwarded for examination, subject to return if not suitable to readers of Surgery, Gynecology and Obstetrics who mention the journal in letter.

P. BLAKISTON'S SON & CO., *Publishers*

1012 Walnut Street **PHILADELPHIA**

The
Pad Without a Fault

It has none of the drawbacks of other electric pads. It is so near perfection that it is

Guaranteed For One Year

The Goodwill Thermostatic control gives positive temperatures ranging from 100° to 180°. Used and endorsed by leading hospitals and physicians. *Money back if not satisfied.* Price $7.00. Order to-day.

GOODWILL ELECTRIC CO.

59 E. VAN BUREN ST. DEPT. A CHICAGO

JUST OUT!

Quarterly Medical Clinics

"The Clinic Carried to the Busy Practitioner"

A New and Unique Publication of Extraordinary Merit

Volume I, No. 1, September-December, 1918

These Clinics are a Series of Consecutive Clinical Demonstrations and Lectures for Practitioners and Students given at Augustana Hospital by

FRANK SMITHIES, M.D., F.A.C.P.

Associate Professor of Medicine, School of Medicine, University of Illinois; Gastro-Enterologist to Augustana and U. S. Marine Hospitals; formerly Gastro-Enterologist to Mayo Clinic; Fellow of the American Gastro-Enterological Association, Etc.

Down-to-the-minute Clinical Facts (Diagnosis and Complete Treatment) Practically and Scientifically Told. *Folder setting forth contents furnished on application.*

Annual Subscription	Single Copies
Five Dollars, Paper	One Dollar and a Half, Paper
Eight Dollars, Cloth	Two Dollars and a Quarter, Cloth

Sign and mail coupon today. ***You can't afford to miss a number.***

Medicine and Surgery Publishing Company, Inc.
METROPOLITAN BUILDING
ST. LOUIS, MO.

Gentlemen: Enclosed find $ for an annual subscription to QUARTERLY MEDICAL CLINICS beginning December, 1918.

Name_____ Street_____

City_____ State_____

Advance Information

Original articles which are to appear in early issues

Ununited Fracture of the Patella and of the Olecranon....FRED H. ALBEE, M.D., New York

Acute Appendicitis Complicating Epidemic Influenza; with Report of Eight Cases.....MOSES BEHREND, M.D., Philadelphia

A Vaginal Hysterectomy Technique for the Cure of Prolapse of the Uterus when the Removal of the Uterus is Necessitated; with Special Reference to Lapping the Vaginal Fascia in all Forms of Vaginal Prolapse.....DOUGAL BISSELL, M.D., New York

Necessity for Special Positions in the Radiographic Study of Shoulder Cases.....W. W. BOARDMAN, M.D., and M. DONOVAN, M.D., San Francisco

Tubal and Ovarian Hæmorrhage; Its Etiological Relation to Pelvic Hæmatocele and Extra-Uterine Pregnancy.....J. WESLEY BOVÉE, M.D., Washington

Radiographic Diagnosis in Renal Tuberculosis.....W. F. BRAASCH, M.D., and F. A. OLSON, M.D., Rochester, Minn.

Infection of a Fused Kidney with Duplication of the Left Renal Pelvis.....LEO BUERGER, M.D., New York

The Clinical Significance of Congenital Anomalies of the Kidney and Ureter; with Notes on the Embryology and Fœtal Development of the Kidney.....H. G. BUGBEE, M.D., New York

Intrinsic Trifid or Double Hour-Glass Stomach...JOSEPH P. F. BURKE, M.D., Buffalo, N. Y.

The Use of Continued Extension by Means of a New Extension Frame in the Bloodless Reduction of Congenital Dislocation of the Hip.....JOHN W. CHURCHMAN, M.D., New Haven, Conn.

Simplified Technique for the Intravenous Injection of Salvarsan or Antitoxin in Combination with Normal Salt Solution.....PETER C. CLEMENSEN, M.D., Chicago

Further Studies in Postoperative Pneumonitis.CAPTAIN MATHER CLEVELAND, M.C., U. S. A.

The Operation of Omentopexy in Cirrhosis of the Liver.....RALPH COLP, M.D., New York

An Operation for the Production of Sterility.....R. C. CUPLER, M.D., Chicago

The Rôle of the Cystic Duct in Recurring Cholecystitis..J. EARL ELSE, M.D., Portland, Ore.

A Simple Method of Excluding the Septic End of the Bowel during Intestinal Resection.....R. E. FARR, M.D., Minneapolis

Choice of Method in Operations upon the Pituitary Body.....CHARLES H. FRAZIER, M.D., Philadelphia

The Pocket Method of Closing Skin Defects.....JOSEPH E. FULD, M.D., New York

Syphilitic Induration of the Vulva.....JOSEPH F. GALLAGHER, M.D., Nashville, Tenn.

Hypertrophic Stenosis of the Pylorus in Infancy.....THOMAS H. GREEN, M.D., and J. BUREN SIDBURY, M.D., Wilmington, N. C.

A New Forceps for the Control of Hæmorrhage after the Removal of Tonsils.....WILLIAM A. GROSS, M.D., Chicago

Acute Intestinal Obstruction Following Appendectomy.....ANTHONY H. HARRIGAN, M.D., New York

Peritoneal Drainage.....C. L. HEALD, M.D., Cedar Rapids, Iowa

Incompetency of the Uterovesical Valves Not Due to Obstruction.....THOMAS N. HEPBURN, M.D., Hartford, Conn.

The Radical Operation for Teratoma Testis; with Report of Five Cases.....FRANK HINMAN, M.D., San Francisco

Treatment of Purulent Arthritis by Wide Arthrotomy Followed by Immediate Active Mobilization.....PROF. CH. WILLEMS, Ghent, Belgium

War Amputations.....CAPTAIN PHILIP D. WILSON, M.C., U. S. A.

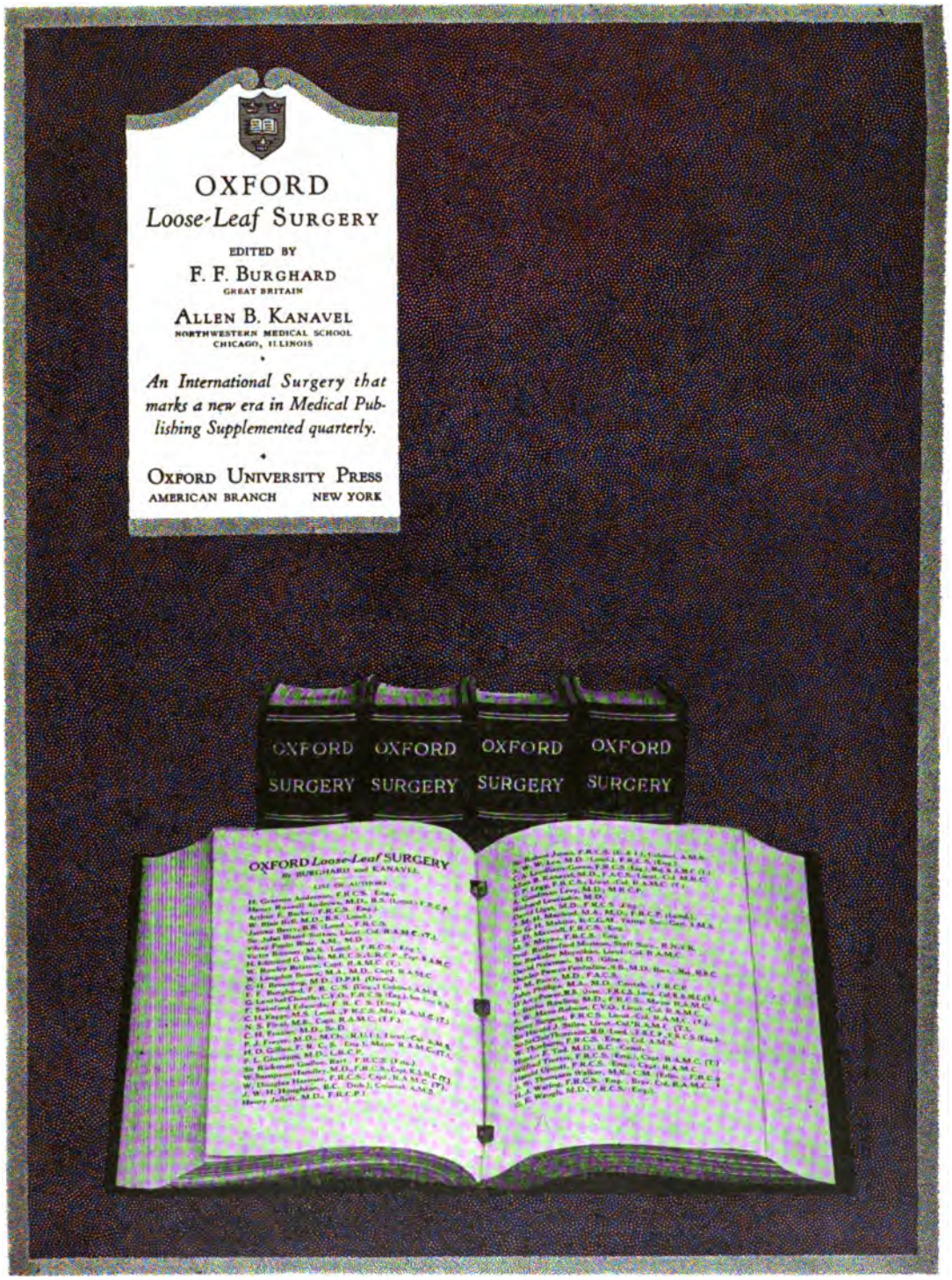
OXFORD
Loose-Leaf SURGERY
EDITED BY
F. F. BURGHARD
GREAT BRITAIN
ALLEN B. KANAVEL
NORTHWESTERN MEDICAL SCHOOL
CHICAGO, ILLINOIS
An International Surgery that marks a new era in Medical Publishing Supplemented quarterly.
OXFORD UNIVERSITY PRESS
AMERICAN BRANCH NEW YORK
OXFORD SURGERY
OXFORD SURGERY
OXFORD SURGERY
OXFORD SURGERY
OXFORD Loose-Leaf SURGERY

Just the Books for the Surgeon

Cystoscopy and Urethroscopy

By *Georges Luys*, Paris; Translated by *Abr. L. Wolbarst, M.D.*, New York. 386 pp., 6¾x9¾, 217 text illustrations, and 76 color plates. Cloth, $7.50

Genito-Urinary Diseases and Syphilis

By *Henry H. Morton, M.D., F.A.C.S.*, New York. 816 pp., 6 x 9, 330 text illustrations and 36 color plates. 4th edition, revised and enlarged. Cloth, $7.00

Abstracts of War Surgery

Prepared under direction of *Surgeon-General* of U. S. Army. 430 pp., 6 x 9, beautifully printed and bound. Cloth, $4.00

Roentgen Diagnosis of Diseases of the Head

By *Dr. Arthur Schuller*, Vienna; Translated by *Fred. F. Stocking, M.D., M.R.C.* 310 pp., 6 x 9, 97 illustrations. Cloth, $4.00

Cavernous and Plexiform Angiomata

By *Francis Reder, M.D., F.A.C.S.*, St. Louis; introduction by *Dr. John A. Wyeth*, New York. 80 pp., 5½ x 8, 26 text illustrations and 3 color plates. Covers treatment of tumors by injection of boiling water. Cloth, $1.50

Headaches and Eye Disorders

By *Greenfield Sluder, M.D.*, St. Louis. 272 pp., 120 illustrations. 6½ x 9½. Cloth, $7.00

No need of writing a letter—just indicate the volumes desired, tear off the coupon and mail. Do it today—NOW—before you lay aside this journal.

C. V. Mosby Co.—Medical Publishers

801-809 Metropolitan Building, St. Louis

Canadian Agency: McAinsh & Co., Ltd., Toronto
London Agency: Hirschfeld Bros., Ltd., London

The Hodgen Wire Cradle Splint

By *Frank G. Nifong, M.D., F.A.C.S.* 250 pp., 6 x 9, 124 illustrations. The extension suspension splint and other appliances for civil and war practice described. Cloth, $3.00

Tropical Surgery and Diseases

By *John R. McDill, M.D., F.A.C.S.*, Major, M.R.C. 275 pp., 6 x 9, 75 illustrations. Cloth, $4.50

Operative Gynecology

By *H. S. Crossen, M.D., F.A.C.S.*, St. Louis. 670 pp., 6½ x 9½, 770 engravings. Cloth, $7.50

Diseases of Women

By *H. S. Crossen, M.D., F.A.C.S.*, St. Louis, 1160 pp., 6½ x 9½, 800 engravings and color plates. 4th revised and enlarged edition. Cloth, $7.50

Blood Vessel Surgery

By *J. Shelton Horsley, M.D., F.A.C.S.*, Richmond. 305 pp., 6 x 9, 89 engravings. Cloth, $4.00

Surgery of Mouth and Jaws

By *Vilray P. Blair, M.D., F.A.C.S.*, Lieut.-Col. M. C., U. S. Army. 764 pp., 6 x 9, 450 illustrations. 3rd revised and enlarged edition. Cloth, $6.00

CUT HERE AND MAIL TODAY

Date.....

C. V. MOSBY CO.
Metropolitan Bldg., St. Louis, Mo.

GENTLEMEN:

Please send me the books checked with (X) below, for which I enclose check for $..... or you may charge to my account:

Luys-Wolbarst	$7.50	McDill	$4.50
Morton-G. U.	7.00	Crossen-O. G.	7.50
War Surgery	4.00	Crossen-D. W.	7.50
Schuller-Stocking	4.00	Horsley	4.00
Reder	1.50	Blair	6.00
Nifong	3.00	Sluder	7.00

Name.....

Street.....

Town.....State .....
Surg., Gyn. & Obstet.

REBMAN COMPANY

141 W. 36th St.
NEW YORK

NOTED BOOKS

CORNWALL—A Clinical Treatise on Diseases of the Heart. Price.....$1.50

FLUHRER—Principles of Treatment of Broken Limbs. 21 half-tone plates and 11 textual figures. Price.....$3.00

FOSTER—Diagnosis from Ocular Symptoms. Price.....$6.00

HART—The Diagnosis and Treatment of Abnormalities of the Myocardiac Function. 248 Illustrations. Price.....$4.50

KAUFFMANN—Care of the Mouth and Teeth. Price.....$0.60

MITCHELL—The Doctor in Court. 2d edition, much enlarged. Price.....$1.50

STERN—Fasting and Under-Nutrition in the Treatment of Diabetes. Price.....$2.00

STRONG—Modern Electro-Therapeutics. New edition, 95 illustrations. Price.....$2.00

BARDELEBEN and HAECKEL—Applied Anatomy. In colors. One volume, 204 woodcuts with explanatory text. Price.....$8.00

TOLDT—Atlas of Anatomy for Students and General Practitioners. Revised edition. 1505 illustrations.

VOLUME I

A.—The Regions of the Human Body (Figures 1 to 5).
B.—Osteology (Figures 6 to 377). With Index.
C.—Arthrology (Figures 378 to 498). With Index.....$6.00

VOLUME II

D.—Myology, with a Supplement on the Anatomy of Hernia (Figures 499 to 640). With Index.
E.—Splanchnology (Figures 641 to 932). With Index....$7.00

VOLUME III

F.—Angeiology (Figures 933 to 1123). With Index.
G.—Neurology.
H.—The Organs of the Senses (Figures 1124 to 1505. With Index.....$11.00

Three Volumes complete, $24.00.

KRAUSE—Surgery of the Brain. With 199 (17 of which are in colors) illustrations in the text, 122 figures on 60 Plates in colors and 2 half-tone plates, over 1200 pages. 3 vols., Art. Lea. Price.....$20.00

TANZI—Mental Diseases. 132 illustrations. Price.....$7.50

BIRK—Diseases of Infancy. Price.....$3.50

SHEFFIELD—The Backward Baby. Price..$1.50

ADAM—Ophthalmoscopic Diagnosis. 18 illustrations in the text. 86 colored figures. Price.....$7.00

TIBBLES—The Theory of Ions. Price.....$1.00

GREEFF—External Diseases of the Eye. 84 colored illustrations. (New Edition). Price...$7.00

ROEMER—A Text-Book of Ophthalmology in the Form of Clinical Lectures. 186 black and white illustrations in the text and 58 figures in colors. 896 pages. (New Edition). Price.....$6.00

GOURAUD—What Shall I Eat? Price.....$2.00

ASCH—Gonorrhea (New Edition). Price...$1.50

OPPENHEIMER—Practical Points in Gonorrhea. Price.....$1.25

RUMPEL—Cystoscopy. 107 illustrations (85 in colors). Price.....$6.00

CARLSON—Obstetrical Quiz for Nurses. Price.....$1.75

KISCH—Sexual Life of Woman. Illustrated. Price.....$6.00

KRAUSE (RUDOLPH)—Normal Histology, Including Microscopical Anatomy. 502 pages, 30 figures in the text, 208 magnificent illustrations in many colors on 98 plates. Part I.....$0.75
Part II..... 5.50

KRAUSE (RUDOLPH)—Textbook of Histology. Illustrated. Price.....$3.00

SENATOR-KAMINER—Health and Disease in Marriage and the Married State. Price...$6.00

KLOPSTOCK and KOWARSKY—Clinical Chemistry, Microscopy and Bacteriology. 70 illustrations (27 in colors). Price.....$3.50

McBRIDE—Alcoholism—Drug Narcotism. Price.....$2.50

WOODRUFF—Effects of Tropical Light on White Men (Medical Ethnology). Price.....$3.50

FOREL—The Sexual Question. Illustrated. Price.....$5.00

KRAFFT-EBING—Psychopathia Sexualis. Price.....$4.00

New Macmillan Books on Reconstruction

Wallace and Fraser's War Surgery

Surgery at a Casualty Clearing Station. Adopted by the U. S. Army

This volume has been written from the experience of several years' service as a surgical specialist in a casualty clearing station on the Western Front. It is intended to present in collected form the various procedures which have become of established value in the treatment of war wounds. War surgery differs in many respects from the art as it is practiced in civilian life, and it is believed that the volume will prove of value to surgeons who are now attending our many wounded.

Possibly, too, it may be useful to surgeons who are already experienced in this variety of work. Chapters are devoted to the various problems with which the surgeon is called upon to deal, and none but methods of proved value are detailed in the work.

By CUTHBERT WALLACE, C.M.G., F.R.C.S., Surgeon, St. Thomas' Hospital; Consulting Surgeon British Armies in France; and JOHN FRASER, M.B., Ch.M., M.D., F.R.C.S. (Edin.), Assistant Surgeon, Sick Children's Hospital, Edinburgh. Crown, 8vo., with numerous illustrations. Price $4.00.

McMurtrie's Disabled Soldier

A New Work on a Vital Subject

This book for the first time describes the whole modern principle of rehabilitating disabled soldiers, so injured that they would have been condemned, in the past, to a future of idleness and uselessness. It gives, in particular detail, the vocational training of disabled men for occupations which they can follow in spite of their handicaps.

By DOUGLAS C. MCMURTRIE, Director, Red Cross Institute for Crippled and Disabled Men; President, Federation of Associations for Cripples; Editor, American Journal of Care for Cripples. 12mo. Profusely illustrated. Price $2.25.

McKenzie's Reclaiming the Maimed

Adopted by the U. S. Army

The Surgeon-General's Office, the highest national authority on reconstruction of wounded soldiers, has placed the stamp of its approval on this handbook by adopting it for the Army.

Not only does Major McKenzie explain what has been done but *he offers many new methods*, together with brand new apparatus, while the text is supplemented by an unusual collection of photographs and drawings which make his material instantly applicable for use by the medical man or masseur.

Major McKenzie's methods of treatment are now actually being taught and practically applied in the hospitals of the Invalid Hospitals Commission of Canada along the lines described. It is, therefore, particularly timely, not only for practical use in war work, but in the rehabilitation of those crippled by accidents in industrial plants.

By R. TAIT MCKENZIE, M.D., Major, Royal Army Medical Corps; Professor and Director of the Department of Physical Education, University of Pennsylvania. Pocket handbook size; with 115 photographs and diagrams. Price $2.00.

Yealland's Hysterical Disorders of Warfare

The Treatment of Mental Disturbances Resulting from Modern Warfare

In this work Dr. Yealland has evolved an intensive method of treatment which gives better results than the more prolonged measures generally adopted, in that he bases his principles on the belief that a disorder originating in suggestion should yield to counter-suggestion; that the precise method of counter-suggestion is really immaterial so long as it is strong enough, and that the line of treatment must be varied according to the mental attitude of the patient. He has had great success in the use of the faradic battery as opposed to the old methods of hypnosis or ether anesthesia. He lays particular stress on the fact that success does not depend so much upon the implement as upon the personality of the medical man who employs it and that sympathy, understanding, tact, imperturbable good temper and determination, together with a sense of humor, are the greatest essentials.

By LEWIS R. YEALLAND, M.D., Resident Medical Officer, National Hospital for the Paralyzed and Epileptic, London. With Preface by E. Farquhar Buzzard, M.D., F.R.C.P., Lieut. Colonel, R.A.M.C. Price $2.75.

Send for New Medical Catalogue of Other Important New Books

The Macmillan Company, Publishers

NEW YORK	SAN FRANCISCO	CHICAGO
64-66 Fifth Avenue	609 Mission Street	25th St. and Prairie Ave.

NEW BOOKS *for* SURGEONS

Cabot — Modern Urology. Two octavo volumes of over 700 pages each, 649 illustrations. Cloth, per volume $7.00

Lumb — Systematic Treatment of Gonorrhea. 12mo, 119 pages. Cloth.....$1.50 net

Crotti — Thyroid and Thymus. Imperial octavo, 570 pages, 96 engravings, 33 colored plates. Half Morocco, De Luxe.....$10.00

Treves — Surgical Applied Anatomy. *New (7th) Edition.* 12mo, 702 pages, 153 illustrations, 74 in colors. Cloth.....$3.00 net

Gray — Anatomy. *New (20th) Edition.* Imperial octavo, 1396 pages. 1247 large and elaborate engravings, many in color. Cloth.$7.50 net
Three-fourths leather..... 9.00 net

Hare — Practical Therapeutics. *New (17th) Edition.* Octavo, 1023 pages, 145 engravings, 6 plates. Cloth .....$5.50 net

Brown — Oral Surgery. *New (3d) Edition.* Octavo, 734 pages, 570 engravings and 20 plates. Cloth.....$7.00 net

Bacon — Otology. *New (7th) Edition.* 12mo, 583 pages, 206 illustrations. Cloth...$3.00 net

Aaron — Diseases of the Digestive Organs. *New (2d) Edition.* Octavo, 818 pages, 172 illustrations. Cloth.....$7.00

Vedder — Syphilis and Public Health. 12mo, 315 pages. Cloth.....$2.25

Cushny — Pharmacology and Therapeutics. *New (7th) Edition.* Octavo, 712 pages, 71 engravings. Cloth.....$4.50 net

Simon — Clinical Diagnosis by Means of Laboratory Methods. *New (9th) Edition.* Octavo, 854 pages, 235 illustrations. Cloth.....$6.00

McCombe and Menzies — Medical Service at the Front. 12mo, 128 pages, illustrated. Cloth.....$1.25

THE WAR MANUALS

Manual No. 1, Second Edition

Sanitation for Medical Officers

12mo, 246 pages, thin paper, illustrated. By EDWARD B. VEDDER, Lieutenant-Colonel, Medical Corps, U. S. A. Price $1.50 net

Manual No. 2

Notes for Army Medical Officers

12mo, 112 pages, illustrated. By COL. T. H. GOODWIN, R.A.M.C., with an Introduction by SURGEON-GENERAL WILLIAM C. GORGAS, U. S. A.
Price, $1.00 net

Manual No. 3, Second Edition

Military Ophthalmic Surgery

12mo, 131 pages, illustrated with engravings and colored plates. By MAJOR ALLEN GREENWOOD, M.R.C., MAJOR GEORGE E. DE SCHWEINITZ, M.R.C., and MAJOR WALTER R. PARKER, M.R.C.
Price, $1.50 net

Manual No. 4, Second Edition

Military Orthopedic Surgery

12mo, 256 pages, illustrated. By the ORTHOPEDIC COUNCIL of the Surgeon-General's Office.
Price, $1.50 net

Manual No. 5

Lessons from the Enemy: How Germany Cares for Her War Disabled

12mo, 262 pages, with 145 illustrations. By J. R. MCDILL, Major, M.R.C., U. S. A. Price, $.150 net

Manual No. 6

Laboratory Methods of the United States Army

12mo, 256 pages, illustrated. By the DIVISION OF INFECTIOUS DISEASES AND LABORATORIES of the Surgeon-General's Office. Price, $1.50 net

Manual No. 7

Military Surgery of the Zone of the Advance

12mo, 330 pages, illustrated. By GEORGE DE TARNOWSKY, M.D., F.A.C.S., Surgeon to Cook County and Ravenswood Hospitals, Chicago; Major, M.C., U. S. A., American Expeditionary Force, France, 1917–18. Price, $1.50 net

Manual No. 8

Military Surgery of the Ear, Nose and Throat

By MAJOR HANAU W. LOEB, M.R.C. 12mo, 176 pages. Price, $1.25 net

LEA & FEBIGER, *Publishers*

706-8-10 Sansom Street
PHILADELPHIA

2 W. 45th Street
NEW YORK

Lukens Sterile Catgut

TRADE (Bartlett Process) MARK

Make the Test Yourself

Compare It Point for Point
With Any Other Catgut
We Will Send the Samples

It is sterile, antiseptic, strong, supple, elastic; free from excess oil; will not untwist in using and is more than usually resistant to absorption.

Sizes 00-4 Plain *Sizes 00-4 Tanned*

C. DE WITT LUKENS CO.
4908 Laclede Avenue
ST. LOUIS MO., U. S. A

FOR SALE BY ALL DEALERS.

Catgut Safety

the elimination of the ligature and suture hazard—is the main factor in the progress of operative technique. Surgeons, therefore, who use

"Van Horn" CATGUT

not only safeguard the quality of their results, but also materially broaden their technical possibilities. Thus, there is a wealth of significance in the statement of one of America's leading surgeons to the effect that "The dependability of "Van Horn" Catgut not only makes possible the highest degree of surgical efficiency—but *goes far to assure it.*"

Johnson & Johnson

VAN HORN & SAWTELL DEPARTMENT

15 & 17 E. 40TH STREET, NEW YORK, U.S.A.

RADIUM

Salts of Any Desired Purity

STANDARD APPLICATORS

Guaranteed by U. S. Bureau of Standards Certificate

RADIUM EMANATION STATIONS

We furnish Scientific Installations designed to efficiently separate the Emanation from Radium.

The Emanation can be readily put into applicators, leaving the entire supply of Radium Intact.

Write us for information and estimates.

THE RADIUM COMPANY OF COLORADO

DENVER *Incorporated* COLORADO

PURVEYORS TO HIS BRITANNIC MAJESTY'S GOVERNMENT

VICTOR CENTRIFUGES

ARE DESIGNED AND BUILT FOR DURABILITY

THOSE who have used Victor Centrifuges for extensive analytical work for years past, invariably state that they have realized practically an uninterrupted service and a minimum expenditure for maintenance.

Our Own Product: Victor Centrifuges are built in our own plant—with the most modern facilities and equipment, which is equal to every requirement in centrifuge construction.

Almost Any Range Desired by the hospital and physician's laboratory, is found amongst the four models offered, with the extensive line of accessory equipment listed with same.

Write for Descriptive Literature

VICTOR ELECTRIC CORPORATION

Manufacturers of a Complete Line of Roentgen and Electro-Medical Apparatus

CHICAGO
236 SO. ROBEY ST.

CAMBRIDGE, MASS.
66 BROADWAY

NEW YORK
131 E. 23RD STREET

Sales Offices and Service Stations in all principal cities

The CONNELL
METER MEASURE
Gas Oxygen Apparatus

and its many exclusive features are fully described in this booklet.



May we send a copy?

Please address your card to

Scientific Apparatus Company
162 W. 34th St.
NEW YORK

Food Cost
Per 1000 Calories

5 Cents

57 Cents

60 Cents

20 Cents

Quaker Oats yields 1,810 calories of energy per pound. Round steak yields 890.

Eggs today, per energy unit, cost 14 times Quaker Oats. Meats average 10 times oat cost. Chicken runs up to 20 times the cost.

Ten people can breakfast on Quaker Oats at the cost of one meat breakfast of same energy value.

And they breakfast better, as every doctor knows. The oat is almost a complete food. It is nearly the ideal food. It is about 16 per cent protein, 8 per cent fat, and rich in minerals.

Quaker Oats

Exquisite flavor has made Quaker Oats the dominant oat food the world over. It is flaked from queen grains only — just the rich, plump, flavory oats. We get but ten pounds from a bushel. Yet it costs no extra price.

The Quaker Oats Company
Chicago (3010)

Campbell

EXPERIMENT AND UNCERTAIN RESULTS ARE ELIMINATED WHEN YOU INSTALL

Campbell Roentgen Apparatus

Sure-X Interrupterless Transformer
Tube Tilt Table
Stereoscopic Tube Table
High Frequency Coils
Electro-Therapeutic
and Roentgen Accessories

Send for Literature

CAMPBELL ELECTRIC CORPORATION
LYNN, MASSACHUSETTS

Sharp & Smith in New Location

SHARP & SMITH, dealers in Surgical Instruments, Deformity Apparatus, Artificial Limbs, and all kinds of surgical elastic goods, are now occupying new quarters at 65 East Lake Street, Chicago, between Wabash and Michigan Avenues.

They were formerly located at 155-157 North Michigan Avenue but when Chicago decided to broaden Michigan Avenue, it became necessary to tear away part of the building occupied by Sharp & Smith. Arrangements were immediately made for a new location, which was promptly decided upon.

The five floors and basement of the building are completely occupied by Sharp & Smith with their various departments.

Sharp & Smith was organized in 1844 at 144 Lake Street, which would be at the present location at 118 West Lake Street, so that Sharp & Smith have returned to the street they originally started on seventy-four years ago.

Sharp & Smith are highly complimented by many of their friends on their new location, all considering that the present store is the best one ever occupied by the firm.

All branches of the business are in full operation and the firm extends a most hearty invitation to all its friends, both local and out-of-town, to call and inspect their new quarters at

65 EAST LAKE STREET, between Wabash and Michigan Avenues

Courtesy New York X-Ray and Pathological Laboratories

Photography's Aid in the Mending of Men

FROM the sinister tumult of battle arises at least one comforting note—the record of a great salvage in wounded men. For each brave life charged to war's grim account, ten broken soldiers are brought back to health through the merciful agencies of surgery. Among these agencies the X-Ray holds a necessary place in the prognosis of wounds and fractures, in locating bullets and in reading the condition of internal tissues.

Photography discovered the X-Ray; and when the dangers lurking in its injudicious use threatened to discredit the X-Ray, photography devised safeguards and reclaimed it for the good of humanity. Moreover, it is upon photographic negatives that the X-Ray publishes its secrets for the appraising eye of the surgeon, so clearing the way for correct treatment and care.

Here again, science, through photography, looks to the Eastman Kodak Company for much that is of constructive value. Eastman probably supplies the larger proportion of the entire world output of X-Ray plates and films; and while these form but one among many classes of Eastman products, the sponsors of the business regard with a peculiar pride this definite contribution to a great and humane achievement.

EASTMAN KODAK COMPANY, Rochester, N. Y.

THE MEYER MULTOSCOPE



The Meyer Multoscope is furnished complete with Self Contained Aerial and High Tension Switch, eliminating the stringing of wires in a room and making the placing of the apparatus a flexible one—changeable as desired. No current wasted in excess wiring. The last word in classiness.

It covers every phase of Modern X-Ray Work.

Send for the
MULTOSCOPE BULLETIN

Price complete $1100.00

THE WM. MEYER COMPANY

817 WASHINGTON BLVD. **CHICAGO, ILL.**

The PROMETHEUS
ELECTRIC STERILIZER
With Latest Conveniences

Tray Supported from Body in Raised Position—Not Attached to Cover.

Tray and Contents Freely Removable. Inside Unobstructed. Side Handle on Cover Away from Steam. Drawing-off Faucet on Side. Made in Four Sizes.

THE ONLY ELECTRIC STERILIZER EQUIPPED WITH WIRE-LESS HEATER. Has Automatic Cut-Out. Heat Regulation in Three Degrees at Sterilizer.

The Prometheus Electric Co.
511 West 42d St. New York

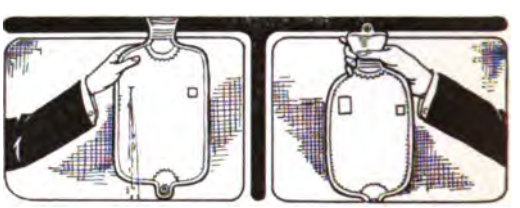

Patch— All Your Leaking, Punctured
HOT WATER BOTTLES
With the Never-Failing, Cleanly

E-Z SELF CEMENTING SELF VULCANIZING PATCH

WIDELY used in hospitals everywhere, because so easy and clean to apply—no tedious, sticky messes of glue or cement—just a little touch of gasoline and on goes E-Z patch to STAY. During sterilization or boiling it becomes actually vulcanized to the bag; can't peel or tear off. Have some handy—they will save time and money.

PRICES
E-Z Patches for Hot Water Bottles, Four for 25c; Hospital Size Pkg., Twenty for $1.00.

THE E-Z PATCH CO.
Manufacturers of Patches for Surgical and Household Rubber Goods
AKRON - - OHIO

The Radiator Type, Coolidge X-Ray Tube adopted by the Medical Service of the Army and Navy is available now to all Roentgenologists. Immediate shipment can be made.

This Radiator Type, Coolidge X-Ray Tube for fluoroscopic and radiographic work was developed specially for the Field and Base Hospitals of the Service.

It is suited admirably for use with existing apparatus.

The bulb is but 3¼ inches in diameter.

The tube has an exceptionally fine focal spot which results in a sharply defined image. This limits the energy to a maximum current of 10 milliamperes and a voltage corresponding to a 5 inch spark between points.

The anode consists of a tungsten button set in a solid bar of copper which is brought out through the glass of the anode arm to a copper radiator. This construction allows the target to cool rapidly between exposures.

Lead glass shields affording a maximum of protection can be supplied for these tubes.

General Electric Company

General Office Schenectady, N.Y.

35B-7

"Vanta" Abdominal Binder

KNITTED of soft wool—firm but elastic—it gives just the protection and abdominal support needed, yet always adjusts itself to the full or empty stomach.

A big improvement on the old-fashioned inelastic strip of flannel. Ties with three little bows of *twistless* tape—no dangerous pins—no troublesome sewing.

We would like you to know, Doctor, what an excellent binder this is. Mail us your card, or write on professional letterhead, and we will gladly send you a sample binder free.

EARNSHAW KNITTING COMPANY
1461 West Jackson Blvd - Chicago

The Abdominal Binder illustrated above is only one of the many Vanta Garments that enable baby to be dressed from top to toe without a single pin or button. Our booklet, "Baby's Outfit," describes and illustrates the entire line. May we send you a copy?

Storm Binder and Abdominal Supporter

(Patented)

Adapted to use of men, women and children, for any purpose for which an abdominal supporter is needed. **High and Low Operations, Ptosis, Pregnancy, Obesity, Hernia, Relaxed Sacro-Iliac Articulations, Floating Kidney, etc.**

Folder on request—with prices, materials and physicians' testimonials

Mail Orders filled at Philadelphia—within 24 hours

Katherine L. Storm, M. D.
1541 Diamond Street, Philadelphia

Cash for Back Numbers

Will pay 50 cents each for copies of the following back numbers of *Surgery, Gynecology and Obstetrics*, if in good condition for binding.

August, 1905
January, 1906
March, 1906

Surgical Publishing Company
30 No. Michigan Ave. CHICAGO

NEW LIVE RUBBER

Kinney's "WELL-NOWN" Surgeons' Gloves fit perfectly. Their construction guarantees repeated sterilizations.

SEND YOUR ORDER TODAY

Medium weight, Plain		Medium Weight, Pebbled, Non-Slip	
2 pairs	$1.20	2 pairs	$1.40
6 "	3.60	6 "	4.20
12 "	6.00	12 "	6.75

Above styles come in sizes 6 to 10

Extra Heavy Smooth Gloves (Sizes 7 to 9), per pair $1.00

Tissue cots, assorted sizes, 3 dozen lots (no less) ..... .50

All Goods Sent Prepaid on Receipt of Price

Elastic Goods Prices Sent on Request

L. T. KINNEY & CO.
57 E. Randolph St., Chicago, Ill.

B&B Surgical Dressings

The Standard for 25 years

BAUER & BLACK
Chicago New York Toronto

WE CAN SUPPLY YOU WITH

Gauze and Bandages

Prices upon request

The Good Manufacturing Co.
156 N. Wells Chicago

Equally Excellent

Diagnostic X-Ray Plates are equally excellent for both direct and screen work. Their exclusive use standardizes your technique.

The Diagnostic is the fastest X-Ray Plate made — 20% faster than any other —50% to 100% faster than most. That means a big saving in tubes and apparatus—a worth while saving in the time of the operator.

Diagnostic X-Ray Plates are made from only new selected glass of the highest quality. They develop simply with any well balanced developing formula—fix out stain free and absolutely clear.

Unsurpassed in their capacity for brilliant contrast and crisp detail.

AMERICAN PHOTO CHEMICAL COMPANY
ROCHESTER NEW YORK

For Sale by Leading Supply Houses

DIAGNOSTIC

Dr. Pollard's High Tension Stethoscope

A 'scope with which you can hear the heart sounds through an overcoat, coat and vest, and with which you can easily hear the fetal heart sound. The regulation binaurals are used on this stethoscope.

Try it a week; if not satisfied return and your money will be cheerfully refunded.

Price, postpaid in the U. S., $5.00

John D. Pollard, M. D.

2755 Jackson Blvd. CHICAGO, ILL.

SKELETONS

We have secured a large stock of

Selected Skeletons

■

Prices and descriptions gladly furnished on application

TRUAX

CHARLES TRUAX, INCORPORATED

141 N. Wabash Ave. CHICAGO

other things being equal

the more porous the hypodermic tablet, the more soluble it is. But those "other things"—they are equally essential.

For instance:—the selection of the most soluble, least irritating form of the drug; the delicate adjustment of the diluent to suit each drug or combination.

And then there's the "know how"—that imponderable thing that makes you the successful surgeon, the chosen consultant, the favorite family physician.

"S & D specifiers" all declare that we have that "know how" and that that's why we are the "hypodermic tablet people."

SINCE 1860 *Sharp & Dohme*

CAREFUL CONSCIENTIOUS CHEMISTS

American Made
NOVOCAIN
(*Procaine-Metz*)
In the Service

WE have furnished the U. S. Government with practically the entire output of our factory, including Novocain Powder, Novocain Tablets and Novocain-Suprarenin Tablets.

This fact has restricted our output to the profession, but our increased production now enables us to supply Novocain through the regular trade channels promptly.

Insist on N-S Tablets! No Harrison Narcotic Blank required.

Send Us the Name of Your Dealer!

H. A. METZ LABORATORIES, INC.
122 HUDSON STREET
NEW YORK



THE BATTLE CREEK SANITARIUM AND HOSPITAL—Established 1866

Medical	Surgical	Orthopedic
Neurological	Obstetrical	Reconstructive

Educational Departments

Training School for Nurses **Normal School of Physical Education** **School of Home Economics and Dietetics**
Students received on favorable terms **Registered trained nurses, dietitians and physical directors supplied**

Descriptive literature mailed free upon request

THE BATTLE CREEK SANITARIUM
Box 243, BATTLE CREEK, MICHIGAN

Surgical Technique: Instruction and Practice

AN ORIGINAL plan of teaching Surgical Technique, giving the instruction, and enabling the doctor to do the operations over and over, until he has mastered all details. Particular attention is given to the table toilet, and the work is performed as humanely as if the operations were being done upon an anaesthetized human. *The operations are all performed by the student.*

Each table is furnished with the same instruments that are to be found in any well-equipped operating room, and gowns and gloves are supplied to each student.

The Laboratory is open daily from 8:30 to 5 o'clock, which makes it possible for the man whose time away from his practice is limited, to get the work in the shortest possible time.

Special courses may be had in surgical anatomy on the cadaver.

Northeast Corner of Operating Room

Personal Instruction, Actual Practice, and Exceptional Equipment. Course Completed in 7 Days (50 hours), Minimizing Time Away from Practice.

As to the Plan, Time, Fee, etc., Address

The Laboratory of Surgical Technique

Phone Midway 4896 **7629 Jeffery Ave., CHICAGO**

The L. of S. T. of Chicago

Gentlemen: Send me information regarding the above.

Name.....
City.....
State.....

RADIUM FOR RENT

By The Physicians' Radium Association of Chicago

(Incorporated under laws of Illinois, "Not for Profit")

BOARD OF DIRECTORS

William L. Baum, M.D.
N. Sproat Heaney, M.D.
Frederick Menge, M.D.
Thomas J. Watkins, M.D.
Albert Woelfel, M.D.

MANAGING DIRECTOR

Albert Woelfel, M.D.

ESTABLISHED to make Radium more available for approved therapeutic purposes in the Middle West. Has the large and complete equipment needed to meet the special requirements of any case in which Radium Therapy is indicated. Radium loaned on request from any responsible physician, the case having been passed on after receipt of adequate information by us. Advice given about the use of Radium. Moderate rental fees charged.

For Full Particulars Address

THE PHYSICIANS' RADIUM ASSOCIATION

1104 Tower Bldg., 6 N. Michigan Ave., Chicago Telephone, Randolph 6897-6898



The Surgeon

is generally called upon for advice as to

Artificial Limbs

Why not recommend one that is sure to be SATISFACTORY?

Our Latest Model

with Adjustable Leather Socket, Cordless Ankle, Felt or Sponge Rubber Foot, Ball-bearing Joints

assure the patient of comfort and perfect locomotion.

Our GUARANTEE Covers All Repairs

Write for Catalogue

FEICK BROS. COMPANY

809 Liberty Ave. Pittsburgh, Pa.

50% Better

Prevention Defense Indemnity

1 All claims or suits for alleged civil malpractice, error or mistake, for which our contract holder,

2 Or his estate is sued, whether the act or omission was his own

3 Or that of any other person (not necessarily an assistant or agent).

4 All such claims arising in suits involving the collection of professional fees.

5 All claims arising in autopsies, inquests and in the prescribing and handling of drugs and medicines.

6 Defense through the court of last resort and until all legal remedies are exhausted.

7 Without limit as to amount expended.

8 You have a voice in the selection of local counsel.

9 If we lose, we pay to amount specified, in addition to the unlimited defense.

10 The only contract containing all the above features and which is protection per se. *A sample upon request.*

The MEDICAL PROTECTIVE CO.
of Fort Wayne, Indiana

Professional Protection, Exclusively

BOUND VOLUMES

Surgery, Gynecology and Obstetrics is especially designed for binding in book form. Our standard volumes are substantially bound in an extra good grade of blue art canvas, stamped in gold. Each volume consists of six numbers: two volumes to the year, January to June and July to December.

Surgery, Gynecology and Obstetrics with International Abstract of Surgery, per volume **$7.50**

Surgery, Gynecology and Obstetrics *without* the Abstract, per volume **4.00**

International Abstract of Surgery, per volume . . . **4.00**

We Can Supply All Back Numbers in Bound Volumes Except Vol. II

Back Numbers Returned for Binding

Where copies are returned by subscribers in exchange for bound volumes, the charge per volume for binding will be as follows:

Surgery, Gynecology and Obstetrics with International Abstract of Surgery, per volume **$2.75**

Surgery, Gynecology and Obstetrics, per volume . . . **1.75**

International Abstract of Surgery, per volume . . . **1.75**

The prices quoted above include carriage charges on shipments to points in the United States and Canada. Express or freight charges on journals returned for binding must be prepaid.

Stanolind

Reg. U. S. Pat. Off.

Surgical Wax

For Injuries to the Skin

While it is more generally used in the treatment of burns, it also is employed successfully in the treatment of all injuries to the skin, where, from whatever cause an area has been denuded—or where skin is tender and inflamed—varicose ulcers, granulating wounds of the skin, etc.

Surgeons will find it useful to seal wounds after operations instead of collodion dressings.

It maintains the uniform temperature necessary to promote rapid cell growth.

It accommodates itself readily to surface irregularities, without breaking.

Stanolind Petrolatum

A New, Highly Refined Product

Vastly superior in color to any other petrolatum heretofore offered.

The Standard Oil Company of Indiana guarantees, without qualification, that no purer, no finer, no more carefully prepared petrolatum can be made.

Stanolind Petrolatum is manufactured in five grades, differing one from the other in color only.

Each color, however, has a definite and fixed place in the requirements of the medical profession.

"Superla White" Stanolind Petrolatum.

"Ivory White" Stanolind Petrolatum.

"Onyx" Stanolind Petrolatum.

"Topaz" Stanolind Petrolatum.

"Amber" Stanolind Petrolatum.

The Standard Oil Company, because of its comprehensive facilities, is enabled to sell Stanolind Petrolatum at unusually low prices.

STANDARD OIL COMPANY

(Indiana)

Manufacturers of Medicinal Products from Petroleum

910 S. Michigan Avenue Chicago, U. S. A.

767

New York Post-Graduate

Medical School and Hospital

Courses arranged for the general practitioner in all branches of medicine. Separate courses on every subject and Special Practical Courses, where individual instruction is given in the following subjects:

Anaesthesia; Colon and Rectal Diseases; Complete Eye Seminar, embracing seven Special Courses; Ear Operations (Cadaver); Nose and Throat Operations on the Cadaver and in the Operating Rooms; Bronchoscopy; Nose and Throat Pathology; Abdominal Diagnosis; Physical Diagnosis; Diagnosis and Treatment of Constitutional Diseases of the Adult; Dietetic and Metabolic Problems; Infectious Diseases; Neurology; Stomach Diseases; Infant Feeding and Diagnosis; Intubation and Lumbar Puncture; Practical Pediatrics; Cystoscopy—Male and Female; Diagnosis and Office Treatment of Gynecological Cases; Gynecological Operations on the Cadaver; General Surgery on the Cadaver; Genito-Urinary Surgery on the Cadaver; Military Orthopedic and Bone and Joint Surgery; Treatment and Care of Fractures; X-Ray and Laboratory Work.

The Hospital has a bed capacity of over 400. The average number of patients admitted daily to the Dispensary is 800. The Hospital and teaching facilities are as extensive during the summer months as during the winter session. Cadaver courses omitted during June, July, August and September.

Through the courtesy of the Secretary, a two-day complimentary ticket is given, which enables the visiting physician to decide upon the courses best suited to his purpose and to meet the instructors in the various departments before registering for any work.

For Further Particulars Address

SECRETARY OF THE FACULTY

305 East Twentieth Street **NEW YORK CITY**

SURGERY, GYNECOLOGY AND OBSTETRICS

AN INTERNATIONAL MAGAZINE, PUBLISHED MONTHLY

VOLUME XXVIII JANUARY, 1919 NUMBER 1

SYMPOSIUM ON SURGICAL TREATMENT OF GUNSHOT WOUNDS OF THE CHEST[1]

MAJOR PIERRE DUVAL, Paris, France
LIEUTENANT COLONEL RAFFAELE BASTIANELLI, Rome, Italy
COLONEL G. E. GASK, D.S.O., London, England.
MAJOR G. GREY TURNER, R.A.M.C. (T.), Newcastle-upon-Tyne, England.

GUNSHOT WOUNDS OF THE LUNG AND THEIR TREATMENT AT THE FRONT

BY MAJOR PIERRE DUVAL, PARIS, FRANCE
Consulting Surgeon to the Seventh French Army

UP to August, 1916, gunshot wounds of the lung were not treated by surgical operation. Out of a series of 3,000 cases, the general mortality in the advanced ambulances and in the hospitals of evacuation was on an average 30 per cent, this percentage not taking into account a large number of deaths which occurred in the advanced posts and in the base hospitals. The predominant causes of death were: hæmorrhage, mechanical troubles of respiration from open thorax, and, above all, infection of the lung and pleura. Therefore, it must be agreed that wounds of the lung are among the most serious of injuries.

My investigations show clearly that a gunshot wound of the lung presents exactly the same lesions as does any other war wound, and is subject to the same evolution. Anatomically, a wound of the lung like any other wound shows, a more or less considerable mass of damaged tissue devitalized by the actual injury. Surrounding the zone of cellular mortification, there is a zone of interstitial hæmorrhage. The wound of the lung may contain foreign bodies, such as fragments of shell or portions of clothing; and this is almost always so when there is a fracture of the ribs or of the scapula, splinters of bone being driven in the wound.

A lung wounded by a fragment of shell is always contaminated and later on infected by the same anaerobic germs which infect all war wounds; e.g. bacillus perfringens, vibrion septicus. There are also often present streptococci, as well as those organisms which are the normal inhabitants of the bronchial passages.

A wound of the lung has the same period of infection as any other wound. Associated with it, however, is a serious complication; namely, infection of the pleural cavity. Infection of the lung develops from one or more foci of pulmonary congestion, either in the injured lung or on the opposite side; and these lesions of the lung may vary in extent from

[1] Prepared for presentation before the Ninth Annual Meeting of the Clinical Congress of the American College of Surgeons.

a small focus of congestion to gangrene of the entire lung. Infection of the pleural cavity arises either from the passage of the projectile or secondarily from the thoracic wound, or from the wound of the lung. A very rapid infection of the pleural cavity, e. g., traumatic gangrenous pleurisy, which kills in 48 to 72 hours, is probably due to organisms carried in by the missile itself. Infection of the hæmothorax, which commences as a rule about the fifth day, is due, we believe, to infection starting within the lung and invading the pleural cavity secondarily. The lung can, it is true, defend itself to a certain extent against infection, but it is not wise to forget that the mortality of wounds of the lung from portions of shell[1] is 28 per cent (personal statistics from the Battle of the Somme, 1916). According to certain French statistics, the mortality in cases of infection of the pleura is more than 30 per cent. Taking into account this terrible mortality and the similarity of wounds of the lung to all other wounds of the war, it appeared to us right to apply to wounds of the thorax that logical surgical treatment which we apply to the other wounds. Since 1916 we have treated all wounds of the lung by mechanical excision of the wound, complete cleansing of the pleural cavity, excision of the parietal wound, and primary suture of the chest.

INDICATIONS FOR OPERATION

Surgical intervention in thoracic wounds is required under the following conditions:

1. Operations of urgency. (a) Serious external hæmorrhage. (b) Open thorax and mechanical difficulties in respiration.

2. Early operation for wounds of the lung.

1. *a. Serious external or internal hæmorrhage.* Immediate thoracotomy; suture of the bleeding wound of the lung; or ligature of the bleeding point. The general condition of the wounded man allows the complete surgical treatment of the wound of the lung and of the parietal wound, and complete closure of the chest after cleansing of the pleural cavity.

1. *b. Open thorax.* Some surgeons are content to suture the skin wound without treating the injury of the chest cavity. Statistics show that this method of combating asphyxia is good, but it does not protect the patient from those complications which follow the normal evolution of the lung wound, and the mortality of open chests treated by suture alone is about 20 to 24 per cent. In our opinion it is not logical to close the thoracic cavity and not treat the wound of the lung; and even when the condition of the patient is serious it is best to perform the complete operation.

2. *Early operations for wounds of the lung.* Apart from those of urgency, the indications for operation for wounds of the lung are difficult to define. The following, however, may be cited:

All foreign bodies retained in the lung, unless they are very small, should be removed. All wounds of the lung complicated by a fracture of the ribs should be operated upon because they contain splinters of bone. (Intrapulmonary splinters are visible only by roentgenography and not by the fluoroscopic screen.) Every wound of the lung which, on fluoroscopic examination, shows a large intrapulmonary hæmatoma should be operated upon because this hæmatoma almost always becomes infected. Every tangential wound of the thorax with pulmonary lesion should be submitted to the same treatment.

Apart from these cases, through-and-through wounds by rifle bullet without serious hæmorrhage and wounds containing very small fragments should not be operated upon. It is important to remember, however, that the comparative freedom of danger in surgical intervention renders the indications for operation more and more frequent.

According to our latest statistics for operations not of urgency, we have operated upon 18 cases out of 118. The favorable time for operation on the lung is as soon as possible after the injury. After thirty hours it is as a rule not advisable to perform any operation.

Results of operation. In operations of urgency in cases with hæmorrhage and open thorax, we have cured 66 per cent of our wounded. It will be seen, therefore, that two thirds of the men in peril from severe hæmorrhage or asphyxia can be saved.

In 35 prophylactic operations for infection

[1] With retention of the projectile.

of the lung and pleural cavity, there were no deaths.

Altogether our personal statistics from the Battle of the Somme where, excluding operations of urgency, cases were treated medically, show a mortality of 20 per cent in 300 cases. In a later series when the operative treatment was employed, we had 18 cases operated on out of 118 and no deaths; 100 cases treated immediately with 1 death from empyema.

In a total of 136 cases—118 not urgent and 18 urgent—the general mortality was 9 per cent.

It will be seen, therefore, that surgical treatment lowers the mortality very considerably. What is more, when septic complications do occur, they are less serious. In the above series we had 11 cases of empyema with 1 death.

Surgical treatment of the lung should, therefore, be considered as the logical prophylactic procedure to prevent sepsis. Nothing is more suggestive on this point than the following. A man is wounded in the lung by two portions of shell, one of which is not located. By operation one of these fragments is removed. The wounded man dies at the end of three weeks from infection; the lobe operated on is perfectly well, while the lobe not operated on has become gangrenous and has caused death.

OPERATIVE TECHNIQUE

This will be considered under the headings of thoracotomy, treatment of the lung, treatment of the pleural cavity, and treatment of the thoracic wall. Our practice has always been to perform the thoracotomy by resection of 10 centimeters of one rib and wide opening of the pleural cavity. The site of election is through the fourth rib in the anterior axillary line. Complete pneumothorax is not associated with any particular danger, and, indeed, it is necessary for the manipulation of the lung. Complete pneumothorax does not cause any respiratory trouble or increase of arterial pressure, and causes less shock than a laparotomy. All our observations prove this. If one takes a blood pressure reading during the thoracotomy one finds that neither the opening of the pleural cavity nor complete pneumothorax nor handling of the lung causes any lowering of the blood pressure. Complete pneumothorax is necessary because it causes complete collapse of the lung; and this collapse is necessary in order to expose and handle the wound. The thorax being opened and the ribs widely separated by the rib spreader (type of Willy Meyer), the lung is seized by a pair of forceps. The lobes of the lung are examined one by one, just as one would examine a coil of intestine outside the abdomen in the course of a laparotomy. Protected by a saline pack, each lobe is examined and palpated for any foreign bodies which it may contain; the hilum of the lung and the mediastinum are all easy of access.

The treatment of the wound of the lung itself consists in the complete removal of all foreign bodies, whether portions of missile, splinters of bone, or bits of clothing. The extraction of these foreign bodies is made either through the wound of entry or through a separate incision through the lung tissue. It is an advantage, also, to operate on a fluoroscopic table because missiles in the lung are sometimes hard to find. The next step in the treatment theoretically is the complete excision of all dead and damaged tissues. Practically this excision is possible only when the wounds are on the surface of the lung or close to the edge. A wound on the surface is excised usually with curved scissors, if at the edge a triangular wedge can easily be removed, and a through-and-through wound can be slit up and then excised. Any bleeding which may occur from this procedure can easily be stopped by suture. In two instances we have been able to remove a third of one lobe of the lung with complete success. Long through-and-through wounds of the lung can not be treated so thoroughly, and one has to resort to swabbing. A wound of the lung treated in this manner is then sutured in two layers, one deep and one superficial. It is necessary to suture the lung in the same way as one would suture the peritoneum. One, two, or even six wounds of the lung can be sutured in this manner. Cleansing of the pleural cavity should be carefully carried out. All the blood should be sponged out with swabs on long handles; and every little cul-

de-sac should be entered and cleaned. Finally, we have been in the habit of washing with ether.

Wounds of the parietes should be completed by excision of the muscles and removal of all splinters of bone whether from the rib or the scapula. This is important, because if the wound of the thoracic wall has not been mechanically cleansed infection may pass from it into the pleural cavity. If the thoracotomy has not been done through the wound of entry, then this must be treated as well. If, on the contrary, the thoracotomy has been done through the wound of entry, then that wound is excised first. Suture of the thorax must be complete. No drain is to be inserted into the pleural cavity nor in the thoracic wall. The chest wall should be closed immediately and completely. We have been in the habit of aspirating the air contained in the pleural cavity, and we have proved, with the help of Henri Bèclere, by fluoroscopic examinations that aspiration of the pleural air is followed by immediate expansion of the lung and restoration of function. If this is not done, a pneumothorax often persists for eight or ten days.

The results of operation are as follows: We have had no deaths apart from those operations performed for urgency, and the general mortality has been lowered to 9 per cent. It is very important, however, to notice that the degree of recovery is infinitely better after operation. We have been able to follow our cases and screen them at repeated intervals. Following surgical operation the lung recovers its function completely; the chest is transparent to the X-rays; and the pleura is normal. There is no thickening of the pleura, or very little, and the diaphragm functionates normally. One does not notice those diminutions of the respiratory movements which are so common after chest wounds. One can see that not only is the patient cured, but that in the majority of cases the respiratory function has returned to normal.

Surgery of the lung has undergone complete revolution during this war. The lung is no longer an organ inaccessible to the surgeon. One can open the chest widely, expose the lung, lobe by lobe, manipulate it, resect it, suture it, and treat it as one would a coil of intestine in a laparotomy. Surgery of the lung does not require any of those pressure chambers which the genius of the Germans invented and their persuasion made us think necessary. The French practice of making a wide opening in the chest allows any manipulation of the lung without danger.

War surgery has rendered surgery of the lung easy and without any particular danger. It is our earnest hope that the new field opened to surgery by the horrors of war may be utilized for the benefit of mankind.

TREATMENT OF CHEST WOUNDS

With Special Reference to Artificial Pneumothorax

By Lieutenant Colonel RAFFAELE BASTIANELLI, Rome, Italy
Chief Surgeon, First Pavillion Hospital Policlinico Umberto I

IT is my purpose to present to you briefly the principles and the results of the treatment of chest wounds in general, and especially by means of artificial pneumothorax. We are indebted to Forlanini and to J. B. Murphy for the introduction of this method in the treatment of tuberculosis and other diseases of the lung and pleura, and to Major Morelli, Forlanini's pupil, for its application to war wounds of the chest. As the method has had a steady development under my eyes in a hospital attached to my surgical unit, I feel that I can speak from my personal experience.

Classical teaching caused surgeons during the beginning of the war to adhere faithfully to the principle of expectation in the treatment of chest wounds. But soon it became clear that this principle was not tenable in the face of the new facts observed. Truly, for the small, puncture-like wounds produced by rifle bullets, without severe bone lesion, the principle of expectation may be adhered to, at least in regard to life, but not always if function is to be considered. Expectant treatment should be followed more rarely for shrapnel wounds, and even less frequently for shell splinters.

Consequently, little by little the surgeons came to the point of treating actively such wounds, and some considered, and do consider even now, that with few exceptions, active treatment should be the rule.

Let us consider first the parietal and then the lung wounds. In the summer of 1916 we came to the conclusion that parietal wounds, unless puncture-like, should be laid open, excised, and sutured, and fractured bones treated as in the limbs. When the pleura is open, suture should include it in order to obtain an airtight closure. Suture of the pleura alone is not reliable; it is essential that the stitches include the pleura and the muscles in one layer, then the skin is stitched separately. But whenever a hermetical closure seems impossible, our advice is to put a gauze plug on the first layer, and to suture the skin over it, removing the stitches later as the circumstances permit. This is the best means of avoiding aspiration of air, subcutaneous emphysema, and pus collection. As a rule, we try to avoid plugging of the pleural opening itself, though as an emergency measure it may undoubtedly be necessary in some cases.

Sauerbruck, Duval, Gask, and others treat lung wounds directly by thoracotomy. This method is especially valuable in checking hæmorrhage or avoiding infection, and it affords at the same time an opportunity to inspect the pleural cavity, to suture the diaphragm, and to remove foreign bodies, clots, etc. That this ideal treatment, which strongly appeals to surgical minds, has been followed by good results, and that it has opened a new field of action in the treatment of chest wounds, nobody doubts. But whether thoracotomy should be applied as a general method or strictly limited to special circumstances is a matter of discussion. Before answering this question let me present to you the pneumothorax treatment in its principles and results, so that we may come more easily to a quite different conclusion.

The lung may suffer a *contusion* by nonperforating or perforating missiles, or a *wound* which may be *superficial, deep, or perforating.* In a penetrating lesion the parietal wound may be closed to the air immediately, or it may close after a short time, or it may remain open. In the first instance, if blood and air are in the pleural cavity, there is no communication with the atmosphere (closed hæmo- respectively pneumothorax). In the second instance, there is free communication (open hæmo- pneumothorax) with the atmosphere, small or large according to the wound. We believe that in almost every lung wound there is pneumothorax, but such as can be

demonstrated in only about 90 per cent of the cases; and if it is closed it originates more from the lung than from the external wound in the act of penetration of the missile or soon afterward. This closed pneumothorax may be of various volume and its pressure may be negative, or near that of the atmosphere or higher; but even a moderate pneumothorax may be under high pressure if the air has been inspirated at a low temperature and a large amount of blood has been extravasated.

The open pneumothorax is always at atmospheric pressure. Similarly the hæmorrhage in the pleura we believe to be constant but naturally not always demonstrable because of its small amount, or because the classical signs are not clear in consequence of various and not always perceptible reasons. The origin of the hæmorrhage is also commonly from the lung, and if a large vessel, especially near the hilus, has been severed, the hæmorrhage will almost always prove fatal; and these cases we almost never see. In the other cases, it is either immediately abundant, or moderate, or small at the beginning. But it is very usual to see the hæmorrhage increased in the next few days; that means that a hæmorrhage can go on continually and slowly for hours and days far beyond the limits of time which are generally admitted. This prolonged hæmorrhage is due to the fact that in these cases the pressure in the pleural cavity is negative, the lung continues to expand, and because of these continuous movements and of the suction induced by the negative pressure at each inspiration, the vessels are kept open and the blood sucked out, until they are closed either by thrombosis, or by the closure of the wound, or by collapse of the lung induced by the hæmo- and pneumothorax.

If no untoward complication arises, the air is first absorbed, and then the blood, and a cure results, either complete without functional impairment, or incomplete and with functional consequences of great importance. That these last should be reckoned in judging of the efficiency of a method of treatment must be highly emphasized, as generally the results are given in figures of death and cures, which by no means can be accepted as sufficient.

In the checking of hæmorrhage and in bringing about the closure of the lung wound, the most effective agent is the pressure to which the lung is subjected by the blood and by the air accumulated in the pleura. As these therapeutic agents are started by nature, so we see cures occur in very severe cases. On these is based the expectant therapy and the principle that the blood should not be removed except in some cases after the danger that the lung wound may open again, has passed. We believe, on the contrary, that this principle is totally erroneous for the following reasons: The pressure which the collected blood alone may exercise on the lung has a relative importance; only a great amount of fluid may be efficient, and we estimate that 1500 to 2500 cubic centimeters or more, according to the chest capacity are required. Besides, a fluid collection does not induce complete lung collapse and immobility. Every time the chest expands the liquid can not follow it, nor be compressed during expiration; so that the lung unless totally collapsed must follow the chest movements. The lung in such condition of incomplete expansion will remain for days and weeks facing points and surfaces of the parietal pleura not corresponding anatomically to the point and surfaces of the lung when expanded. Adhesions occurring in these conditions when firm and old will not allow a complete pulmonary expansion but only of limited zones; hence there results incomplete pulmonary function, displacement of the diaphragm and mediastinum, and permanent damage to the lung. Besides, the blood is frequently absorbed slowly, fibrinous deposits are formed, and the complementary spaces obliterated. Sometimes a blood collection remains encysted, and there is a continuous source of pleural irritation with effusion of pleuritic liquid, and not rarely a reason for infectious complications. Whereas if air alone is in the pleural cavity, the lung is totally collapsed as soon as the atmospheric pressure is reached, and if the pressure is positive, the lung is compressed. That means immobility of the lung, pressure on the walls of

the wound, and their mechanical coaptation. Any hæmorrhage except from large vessels is effectively checked, and the wound is easily brought to healing with less probability of complications. The air in the pleural cavity means that the lung is completely surrounded by it; hence, contact with the parietal pleura is impossible and there are no adhesions in abnormal zones of the retracted lung. And, when it does expand later, even if through inflammatory conditions of the parietal pleura adhesions occur, these are on the surface of the totally expanded lung, so that the function is perfect even if a complete pleural symphysis occurs. Besides, a compression produced by a gas is an elastic one, consequently it can follow the chest expansions, because the gas is easily rarefied and compressed. When a large amount of fluid is collected on one side, the opposite one suffers in its expansion because of the relative immobility of the affected side. Instead it can functionate better when gas is present, because gas is easily rarefied and compressed, so that from a purely functional point of view, the pneumothorax pressure is innocent. And even after weeks the lung can reach a complete expansion. All that we have learned from the observations made in applying the therapeutic pneumothorax in civil practice.

When blood together with air is collected in the pleural cavity, the pressure of this pneumothorax, we said, is variable. As a rule, we may say that blood and air quantity are inversely proportional; the larger the amount of air or its pressure, the less the amount of blood, because the hæmorrhage is sooner checked. Consequently the hæmothorax associated with pneumothorax is a condition more favorable than a pure hæmothorax, as the air surrounding the lung brings it to collapse, checks the hæmorrhage, and prevents at least partially unfavorable adhesions of the incompletely retracted lung.

The presence of air in the chest is then to be considered the most favorable condition for the cure of lung wounds, and we have only to follow and imitate nature in treating them. That means: remove the blood which is dangerous, and put in its place air which is favorable.

When we are confronted with open pneumothorax, our conduct is clearly indicated. We must change the open pneumothorax into a closed one, so that we may later effect the introduction of air as a therapeutic measure. Besides, an open pneumothorax induces severe functional symptoms, which are commonly resumed as traumatopnœa, so that the closure of the wound is necessary. We believe that this is necessary so that a complete airtight closure results. If the hæmorrhage is severe, it means that a large vessel has been severed, and that the atmospheric pressure can not check it. Then it is safer to enlarge the wound and deal with it surgically. But in other cases we can safely resort to the complete closure followed by introduction of air, as this will invariably stop all the non-immediately-fatal hæmorrhages. These cases give a high death rate, through either functional disturbance, hæmorrhage, or septic complications. The more prompt and complete the surgical intervention, the less will be the bad consequences, and we believe that in these cases, too, the airtight closure of the wound followed by artificial pneumothorax is the best and the simplest measure to be resorted to. But if there is a large parietal wound with rib fractures and depression of the chest wall, then it is quite necessary that the lung be inspected and the wound treated accordingly by hermetical closure if possible, at least of the deep layers, resorting to partial plugging as seldom as necessary. The very severe functional symptoms which these cases not infrequently present, must be treated as soon as possible. In the advanced dressing stations we have found the Morelli rubber bags very efficient. These bags are of different sizes (Fig. 1) which can be introduced empty into the wound and then blown up with air, so that they completely fill the opening. The advantages, especially in double wounds and in crowded days, are clear, and we believe that the introduction of the bags as an emergency measure should be favored, as it may save lives and give immediate relief and prepare better conditions for the definitive treatment which can even be delayed without damage.

The preceding considerations make clear the importance of the following three points:

1. Airtight closure of the parietal wounds.
2. Evacuation of blood.
3. Introduction of air.

I have dealt sufficiently with the certain damages and with the imperfect results which the blood collection may produce. I have now to prove that the removal of the blood is not dangerous. This opinion is still erroneously held by the surgeons who do not know the advantages of artificial pneumothorax because they fear the possibility of a new hæmorrhage after removal of the blood present and re-establishment of the suction power of the pleura and the mobility of the lung. But if we can maintain in the pleural cavity an atmospheric or a positive pressure, the lung will necessarily be kept in a state of collapse and immobility. This is easily accomplished by introducing in the pleural cavity a quantity of air corresponding to the amount of blood we remove; or if we fear the possibility of a prompt hæmorrhage, we may introduce a certain amount of air previous to the extraction of the blood, so as to be sure of a permanent positive pressure on the chest. With these rules the removal of blood is a safe procedure, and as we have demonstrated the dangers and the inutility of its presence, there is no reason why its removal and the induction of an artificial pneumothorax should not be advised as a general indication.

Consequently, we believe that every penetrating chest wound with closed hæmo- and pneumothorax should be treated in this way and, if the blood is removed, even in cases in which its amount is small, the results will be better. For that reason we advise the use of explorative puncture to clear the physical diagnosis which is not always easy, remembering that the puncture has to be made high because of the high position of the diaphragm in these cases, and the procedure may be repeated if necessary.

Moreover, cases apparently mild, of sure pulmonary lesion, whether a contusion or a wound, must be treated by the introduction of air, for it is not unusual to see in such cases when left to nature, the occurrence of hæmothorax forming slowly in the next few hours or days in consequence of the negative pressure sucking blood from the vessels and keeping the wound open. Besides, not seldom we have seen bronchopulmonary complications and abscesses in cases of pulmonary contusions and secondary hæmorrhages from lung wounds left to nature, which by artificial pneumothorax could have been avoided.

There are naturally different clinical and physical conditions in a chest wound, and consequently various indications for treatment which may be summarized as follows:

1. Closed parietal wound with no demonstrable hæmo- and pneumothorax, or if present, very moderate. In this group of cases the production of a pneumothorax is indicated and it should be progressively increased as a preventive measure. If, instead, a pneumothorax is demonstrable without noticeable hæmothorax, we should test its pressure, and if it is too high and producing functional disturbances, the pressure should be diminished. Abundant hæmothorax with moderate spontaneous pneumothorax requires withdrawal of the blood and introduction of air so as to increase the pleural pressure to a positive one. But if with large blood collection there is spontaneous pnuemothorax under high pressure, this means that a high pressure has to be maintained to keep the hæmorrhage in check, and we have the indication for the withdrawal of blood and the introduction of as much air as is necessary to keep the pressure at the same height.

2. In an open parietal wound, airtight closure is indicated, after letting the blood out and favoring the entrance of air. The pressure is increased with a further introduction more or less according to the hæmorrhage. It should be remembered as a thing of great importance that pneumothorax is of great value, so that should we be working under crowded conditions, having no time for a complete study and for the systematic evacuation of blood, it will be enough in the first few hours or days to perform an artificial pneumothorax or to increase the existing one, and to postpone the extraction of liquid to a better time. We consider the

artifical pneumothorax as a powerful means of treatment, capable of giving good immediate and the best definitive results, and consequently we recommend it, not for few and special cases, but as a general measure.

These extensive indications for artificial pneumothorax are admissible only if we can prove that it is a safe and easy procedure. The dangers attributed to it, i. e., the spontaneous air embolism, or that due to the technique, are matters for long theoretical discussion. I will say only that theory and practice combine in the conclusion that with proper technique these dangers can be easily avoided, and Major Morelli claims that in his unique practice these never happened. It is easy to understand that when blood or air is present in the pleural cavity, the needle can not enter the lung, so that an error seems to be impossible, but in cases of pulmonary contusion or absence of a demonstrable quantity of air or blood in the pleural cavity, or when adhesions exist, the technique is more delicate and comparable to that of the ordinary therapeutic pneumothorax, and naturally experience and prudence are required.

Anybody who wishes to adopt this method of treatment should be familiar with the principles of therapeutic pneumothorax and understand its application in chest wounds. For this reason there have been introduced in Italy special courses for medical officers in one of the hospitals specializing in the treatment of chest wounds.

The original Forlanini apparatus or some of its many modifications may be used. We prefer the one devised by Major Morelli, as being easily transported and making impossible air embolism through technical faults. A glance at the figure (Fig. 2) will explain its use. The main feature is that the air cannot be blown into the pleural cavity, but it is automatically aspirated by the chest from the bag which has previously been filled up with air. The pleural cavity will, according to the pressure existing in itself, aspirate or expirate into this bag as if it were the surrounding atmosphere, and in this way there is no possibility of air embolism even if the needle had entered the lung. When blood has to be removed, Major Morelli uses the apparatus shown in Figure 3, which lets out the blood, puts air in the pleural cavity, and washes the cavity if desired, and so makes certain the removal of all blood from the chest.



Fig. 1. The upper rubber bags are used to plug a chest opening. The lower rubber bags with interior drain are for suction treatment of empyema (Major Morelli).

The artificial pneumothorax must be continued for 12 to 15 days, by the successive introduction of air, measuring each time the manometric pressure.

The results are shown by the following statistics which I have compiled from figures kindly collected for me by Captain Vercesi, including all cases treated in Field Hospital No. 79, under the direction of Major Morelli, up to the end of June last.

The chest wounds coming from one section of the firing line, regardless of their severity, are all brought directly to this hospital, which is specially dedicated to the treatment of these cases, so that it collects all of the

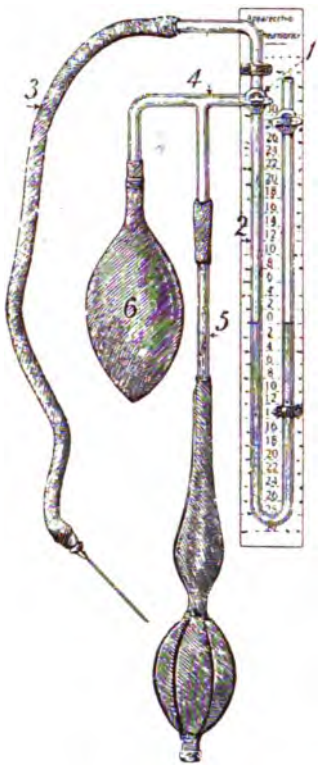

Fig. 2.

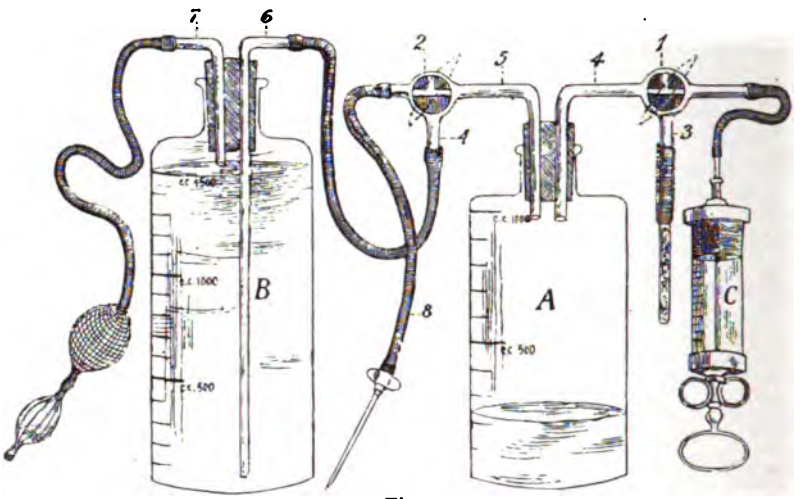

Fig. 3.

Fig. 2. The apparatus consists of a three-way cock *1*, one branch of which communicates with a water manometer *2*, one with the pleural cavity *3*, and the third with a Richardson bulb *6*, and a filter *5*. (Morelli, *Policlin., Sez. Prat.*, 1917, xxiv, 1292.)

Fig. 3. The apparatus consists of a bottle *A* of about one liter capacity. The bottle is closed by means of a rubber stopper through which passes two glass tubes. One of these tubes marked *4* communicates with a three-way cock, two branches of which communicate respectively with a syringe *C* of 100 cubic centimeters capacity, and a filter *3*. The second glass tube out of bottle *A* forms one branch of a three-way cock marked *2*. One of the other branches of the cock is attached by means of a rubber tube to a thoracentesis needle *8*, and the other communicates with the bottle *B* containing the lavage fluid. Bottle *B* is also closed by means of a rubber stopper through which are two glass tubes, one of which *6* communicates with the three-way cock *2*, the other the shorter tube *7* communicates with a double Richardson bulb. (Morelli, *Policlin., Sez. Prat.*, 1917, xxiv, 1152.)

chest wounds of the corresponding zone. Besides, the hospital can keep the patients until the cure has been completed. These circumstances are of great importance in judging the value of statistics.

Total number of chest wounds	370
To be subtracted because non-penetrating and without lung lesion	43
To be subtracted because non-penetrating but with lung contusion	37
Remainder, the penetrating wounds	290

The lung contusions offer an interesting field for study and for treatment, but I prefer not to deal with these now. Of the 290 penetrating chest wounds, there were with closed chest, 206; with open chest, 84.

1. Closed chest. This is the category of cases which gives the most occasion for discussion, as in these there is frequently no apparent reason for intervention. We believe that in these cases especially, the evacuation of blood and the production of a pneumothorax are most extensively if not generally indicated. However, these cases are usually not operated on except when the patient has suffered a very severe injury when thoracotomy is too often done.

Of these 206 cases, there were 88 treated by pneumothorax, and 118 treated by thoracentesis and pneumothorax, with a mortality of 7 or 3.4 per cent. Of these, 3 were due to empyema, 1 to pulmonary abscess, 3 to septicæmia.

2. Open chest. Total cases, 84. Deaths, 19 or 22.6 per cent. Of the 19 dead, 1 died before reaching the hospital, 7 had bled and were shocked so severely that nothing but perhaps transfusion could have helped them; they died in the first 24 to 48 hours.

Admitting that it is fair to subtract these 8 cases, we have remaining 76 in which the treatment could be tried.

In these 76, there were 11 deaths or 14.4 per cent. Of these, 7 were due to empyema, 4 to septicæmia. Empyema occurred altogether 11 times. I must specify the fact that empyema occurred only in the cases treated by permanent closure of the parietal wound with the rubber bag. Since this procedure has been resorted to for emergency only and the wound has been sutured airtight according to my principles, we have had in 35 cases, 2 deaths or 5.7 per cent.

Altogether, the results of the treatment of penetrating wounds with pulmonary lesions were:

Total cases	290
Total deaths	26

or 8.96 per cent.

If we subtract the 8 cases above mentioned, we have

Total cases	282
Total deaths	18

or 6.2 per cent.

The results of a method of treatment can not be estimated only under the headings of cured and dead; the definitive conditions of function and disability must also be considered. The great majority, even of the most severe cases, which were cured had a perfect integrity of function as shown by X-rays and by late examination. Many patients could get up on the eighth, twelfth, or fifteenth day and in a short period were fit for service.

There are conditions in which pneumothorax can not be performed, and I like to summarize these under this principle: Whenever air cannot be introduced into the pleural cavity because of adhesions, or because the air escapes from it either through the parietal wound or through the lung wounds, then it is natural to resort to the complete operation. We resort to it whenever the chest wall is largely and badly shattered, for it is the shortest part of the operation to inspect and to treat the lung directly, and if the chest wall can be closed airtight, it is advisable to maintain the natural pneumothorax by introducing air later. When there is threatening emphysema and it is due to adhesions, we advise that the wound be enlarged, and to detach it and suture it completely. And, finally, if foreign bodies are in the pleural cavity, we believe that these must be removed, for very frequently they do cause infection, while foreign bodies in the lung do not need to be systematically removed, but only those of a certain size or when the complete operation is required. The lung can take care of foreign bodies very well and in a quite different way if it is collapsed and immovable for many days than when it is left free to expand.

In my experience and Morelli's it has never been necessary to resort to an open operation to check lung bleeding, but naturally this may be an absolute indication.

So that, answering now the question first proposed, I would say that the complete operation has rather limited indications, while the removal of blood followed by pneumothorax has a most extensive, almost a general, indication in closed chest wounds and less frequently in open chest cases. The treatment of the chest wall wound must be the rule. Local anæsthesia has proved sufficient and perhaps superior to ether or chloroform.

Thoraco-abdominal wounds are not discussed in this paper as they require quite different methods of treatment. Certainly they may often require intervention from the thoracic side for the treatment of the lung lesion or of the abdominal organs, and this is certainly true in injuries of the diaphragm especially on the left side. I wish to call attention to the fact that suture of diaphragm through a thoracotomy incision was first practised more than 25 years ago by Dr. Postempski of Rome.

THE EARLY TREATMENT OF GUNSHOT WOUNDS OF THE CHEST

By Colonel G. E. GASK, D. S. O., London, England
Consulting Surgeon, British Expeditionary Forces in France

DURING the last two years there have been great changes in the treatment of gunshot wounds of the chest. During the first two years of war very little was done. The usual treatment afforded was to put the patient to bed, give him some morphia, and a cough mixture and hope for the best. If an empyema formed then a portion of rib was excised and the pleural cavity was drained by means of a tube. As might be expected the mortality was great and in non-fatal cases convalescence was often prolonged.

The reasons for the non-interference were three: (1) experience of the South African war where the ground was dry and clean, and where wounds were largely due to rifle bullets, led our surgeons to the belief that chest wounds were best left alone; (2) it was believed that it would be fatal to open up the chest cavity without the aid of some form of pressure chamber; (3) it was thought that handling of the lung would provoke fast and fatal bleeding. Experience has proved that these assumptions were wrong, and a complete change has been made in our practice, not from the discovery of any new method but by the application to these injuries of the general principles of surgery which govern the correct treatment of all wounds; namely, their early mechanical cleansing by operation, followed by early closure.

Types of wounds. The types of wounds which are most commonly met with in a Casualty Clearing Station are as follows: (1) through-and-through wound caused by rifle bullet; (2) through-and-through wound caused by shell fragment; (3) lodging wound with retention of large foreign body; (4) lodging wound with retention of small foreign body; (5) open sucking wound of thorax with or without retention of foreign body.

Causes of death and prolonged illness. If the complicating wounds are disregarded the causes of death from pure chest wounds may be divided into 3 groups: (1) deaths on the battlefield or in a few hours after admission to a medical unit due to injury to large vessels or extensive lesion which cannot be aided surgically; (2) deaths after 48 hours — these are almost always due to sepsis of the pleural cavity and its contents; (3) deaths at the Base after 7 days. In these again the cause of death is almost invariably sepsis. Therefore, the guiding principles in treatment of chest wounds, as in any other wound, must be the elimination of contamination before organisms have had time to invade the tissues.

Channels of infection. Granted that the chief danger to a man wounded in the chest is infection, it is necessary to see how organisms reach the chest cavity.

The pleural cavity may be infected: (1) by the missle and portions of the clothing or equipment carried in by it. (2) Through the wound in the chest wall. A wound that opens directly into the pleural cavity through which air is constantly sucked will always lead to infection and unless dealt with is often fatal. Further, a wound, even of moderate dimensions, through which air is not being sucked, unless adequately dealt with may suppurate in the course of a few days, and, if the thoracic cavity is not sealed off, organisms gain entrance to the pleural cavity where they find the blood a convenient medium for growth. This accounts for many cases which exhibit septic changes only after an interval of five or six days. (3) From the wound of the lung in which missile, splinter of bone or portion of clothing may be retained.

The principle, therefore, to be aimed at is the early mechanical cleansing of the wound, both of the chest wall and of the injured viscera, the evacuation of all foreign bodies and of effused blood from the pleural cavity; the repair or suture of the damaged lung and the closure of the chest cavity by suture.

How to arrive at this. When a patient suffering from a chest wound is admitted to a Casualty Clearing Station he is put to bed

and allowed to rest undisturbed to recover from shock.

The only exception to this rule is when there is a large open blowing wound of the chest. In such a case the opening is immediately closed, by temporary skin suture. The relief given is immediate; so much so that there is now a general order to the effect that a blowing chest wound should be sewn up at the earliest possible moment in the advanced medical units. A survey is then made of the whole patient, and all wounds examined, evidence of hæmothorax, pneumothorax or collapse of lung is sought. Much may be gained by careful examination of the movements of the chest and the position of the heart. The whole body should be searched for complicating wounds, especially with regard to abdominal and spinal injury.

X-rays. Patients with retained missiles should be submitted to X-ray examination for information concerning: (1) the position and size of the foreign body; (2) the existence and extent of hæmothorax and pneumothorax; (3) the condition of the opposite lung, cardiac displacement and movement of the diaphragm.

Indications for early operation are: (1) a ragged wound of the soft parts; (2) bleeding from the parietal wound; (3) compound fracture of the ribs; (4) suction of air into the pleural cavity; (5) retention within the chest of a large foreign body; (6) great pain due to in-driven splinters of bone; (7) rapidly increasing pneumothorax due to a valve-like opening into the pleural cavity which allows air to be sucked in and prevents expulsion; (8) a large hæmothorax which cannot be evacuated by aspiration.

When none of these indications are present, that is, when the wounds of the chest wall are small and clean, such as made by a rifle bullet, when the ribs are not splintered, when the foreign body retained is small, the patient is treated on general medical principles.

Treatment by operation — time of operation. The best time is as soon as possible after the receipt of the wound, provided the patient has recovered from the initial shock.

Anæsthetic. Patients bear operation well and take a general anæsthetic satisfactorily. It is unnecessary to use any form of pressure chamber. My own predilection is for chloroform, either by itself or combined with oxygen given through a Shipway's apparatus. Gas and oxygen is very good and the French commonly use ether, and many British surgeons employ local anæsthesia. It is evident, therefore, that the anæsthesia so long as it is administered skilfully presents no difficulty.

Wounds of the soft parts of the chest-wall. Wounds of the soft parts, unless small and clean, should always be excised even if nothing further is done, because otherwise they suppurate and infection is liable to spread along the track of the missile into the pleural cavity.

Fracture of ribs. Excision of the soft parts leads the surgeon to the ribs. More often than not the ribs or scapula are broken, and whether or not the chest is to be opened, the splinters of bone should at least be removed, ragged ends of rib cut clearly off and all dead tissue excised.

That is to say the first step in the treatment of a chest wound is to make a careful complete excision of the parietal wound. In some cases this is as far as the surgeon should go. Careful excision of the wound allows a careful examination, which may reveal either a bleeding intercostal artery or a large hole, hitherto unsuspected, leading into the chest, and a finger introduced into the pleural cavity may discover splinters of bone either free or sticking into the lung. Such splinters ought to be removed for they play a great part in the production and maintenance of sepsis.

At this stage the case has been converted into one of open hæmothorax. Two courses are now open to the surgeon: (a) he may do what is called the complete operation, opening the chest, repairing the lung, cleansing and closing the pleural cavity, or (b) he may content himself with the excision or suturing the parietes after evacuation of the blood from the pleural cavity either by rolling the patient or by aspiration. The decision may be difficult. My belief is that if any operation is undertaken for a penetrating wound of the chest it should be done completely, as yielding in the long run the best results.

Retention of a large foreign body. By a large foreign body is meant a shell fragment of about 1 inch by ½ inch. Such a fragment not

only injures tissue, but carries in with it fragments of clothing which unfailingly cause contamination. Therefore, it should be a rule that all large missiles should be removed at an early date. The operation may be done either by enlarging the original wound or by a fresh incision and the surgeon is guided in his choice by the position of the missile as seen by the X-ray relatively to the wound. Where possible thoracotomy through the wound is preferred, but in any case the original wound or wounds must be completely excised. A fresh thoracotomy may be done by resection of four inches of rib or by an incision in the intercostal space. The easiest route is probably via the fifth rib in the anterior or mid-axillary line; through such an incision with the use of a retractor or rib-spreader any part of the pleural cavity can be reached. On looking into a chest thus opened, the first thing seen is a quantity of blood, the majority of which is unclotted — at any rate at the stage of which I am writing, namely the first 2 or 3 days after injury. This must be removed by mopping. The cavity of the chest is now visible, the chief objects seen being the collapsed lung, the dome of the diaphragm and the mediastinum.

The missile may be evident at once, but if not it may be sought by inserting the hand into the pleural cavity; if it is lying in the lung it can be felt with the fingers, and removed either through the wound of entry in the lung or by fresh incision into lung tissue.

Lung tissue may be excised without fear, because any fresh bleeding following incision is easily controlled by suture. Continued bleeding from the lung is exceedingly rare. *Arrest of bleeding follows spontaneously from collapse of the lung; and early operation within 12 hours after injury does not cause recrudescence of bleeding.* In the few cases observed in which bleeding did continue, the cause was due to old adhesions which prevented the lung from collapsing. The wound in the lung itself should be excised when possible in the same way as a wound of the soft parts. That is to say it should be cleaned mechanically and sutured. It should be sutured for two reasons: (a) even if not completely freed from organisms, there is evidence that the lung is capable of dealing with a considerable amount of infection, as evidenced by the rarity of gas gangrene infection; (b) restoration of function is hastened.

Abdomino-thoracic injuries. Injuries involving both the chest and abdomen are not infrequent, either as the result of a single or multiple injuries.

When a missile has traversed both chest and abdomen the diaphragm is necessarily injured, and abdominal viscera may herniate into the pleural cavity. This is more commonly found on the left rather than on the right side because on the latter the liver gives protection.

The diaphragm can only be repaired efficiently from above, therefore it is wise to open the chest first, replace the abdominal viscera, suture the diaphragm, deal with the chest as already indicated and then if there is evidence of injury to the hollow viscera, laparotomy may be performed. The passage of a small missile through the diaphragm may not necessitate repair; in such a case with evidence of injury to hollow viscera the abdomen is afforded preferential treatment.

Hæmothorax. The question often arises as to the correct treatment for a patient with hæmothorax of moderate dimension, and in whom there is no retained missile and no large wound of the parietes: that is to say a case of uncomplicated hæmothorax. The majority of these cases recover with aspiration. A certain proportion, however, become infected. If it were possible to foretell which case would become infected then there is no doubt that these should be operated on at an early state, the hæmothorax evacuated, the damaged lung repaired and the chest closed. So far as I know there is no way of foretelling this and to prevent any possible infection it would be necessary to operate on every case, and that I am not prepared to advocate at this moment, seeing that many of them get well by themselves.

At the present time we content ourselves with aspirating the hæmothorax as completely as possible and making every effort to detect signs of infection at the earliest possible moment.

The only certain evidence of infection is either a positive bacteriological finding or the

removal of stinking fluid. By clinical signs it is often possible to diagnose the existence of infection before organisms can be detected by the bacteriologist.

The essential treatment, as soon as infection is proved or suspected, is to empty the chest of all blood and clots. This cannot be done by aspiration and must be done by open operation. The common practice has been the resection of an inch of rib and insertion of a tube. Provided the operation is done within a few days after receipt of wound it is better to do a wider resection, cleanse the pleural cavity and close the chest, subsequently keeping the pleural cavity dry by aspiration. This method offers the following advantages: (a) the chest may remain closed; (b) the lung is allowed to expand and adhesions may form which will prevent complete collapse, even if the pleural cavity is subsequently drained; (c) respiratory distress is much less with a closed chest; (d) if infection persists and the chest has to be drained, it is very easy to take out a few stitches and insert a tube. Drainage of a chest, like amputation of a limb, should be regarded as a surgical failure.

Contra-indications for operation. (1) Shock and collapse such as would be contra-indicative for any surgical procedure. (2) Small clean wounds without evidence of serious intra-thoracic injury. (3) Collapse of the opposite lung as indicated by inspirating retraction of the chest wall on the side opposite to the wound. In this case an anæsthetic on opening of the chest may be fatal.

OPERATIVE TECHNIQUE

Thoracotomy through the wound. The first essential is the complete excision of the wound including the skin, muscles, and broken ends of rib. This having been completed, the chest should be opened with fresh instruments. An incision is made from the edge of the wound through the skin along the line of the broken rib, either forward or backward, to obtain the best access to the cavity of the chest. Then the muscles are incised down to the rib, retracted, and the periosteum incised along the middle line of the exposed rib. Along this line the periosteum is stripped off with a rugine. A Doyen's periosteal rib elevator is then slipped in and the periosteum entirely separated. The bone is then cut through with a pair of rib shears or bone forceps and removed. To allow free access to the pleural contents and insertion of the hand it is necessary to take away four inches of rib. The posterior layer of periosteum of rib with the parietal pleura attached is next incised with a pair of scissors along the middle of the gap. Then a retractor or rib spreader is inserted and the chest opened widely.

Thoracotomy by fresh incision. As previously stated, this operation may become necessary when thoracotomy through the wound will not allow access to the injured portion of the lung, for instance, when the wound is in the lower and posterior part of the thorax and the foreign body near the hilum or in the upper lobe of the lung.

Choice of route. Resection of four inches of the fifth or sixth rib in the anterior axillary line gives a good exposure of the thoracic contents, and if there are no other considerations this is probably the best and easiest route to follow. It has to be remembered, though, that if drainage of the pleural cavity has to be performed later on, it cannot be done effectively through this incision. Therefore, if the nature of the wound and missile is such as to indicate probable future infection, it may be advisable to choose a lower rib and make the incision more posteriorly.

Operation. A six-inch incision is made along the line of selected rib, and continued down to the periosteum, which is stripped off the anterior surface with a rugine. With rib elevator and shears four inches of the rib is resected. The posterior layer of periosteum with the parietal pleura attached is then incised along the whole length of the middle of the gap, and the retractor or rib spreader inserted.

ALTERNATIVE METHODS OF OPENING THORAX BY FRESH INCISION

1. Incision through intercostal space, with or without section of one or two costal cartilages. A good exposure may be obtained by this method, provided the patient is young and has elastic ribs.

2. Before the war the pleuro-costal flap method was advocated. This is unnecessary and prolongs the operation.

3. Cowell has suggested that the rib should be split along its longitudinal axis. This method merits trial.

PROCEDURE WITHIN THE THORACIC CAVITY

After the chest has been widely opened, either through the wound or by fresh incision, it is advisable to remove the blood from the pleural cavity, first, because it is easier to see what has to be done, and, secondly, because removal of the blood relieves respiratory difficulties by lessening pressure on the mediastinum. The blood can be removed by rolling the patient on to his side. Probably, however, it is better to do it by swabbing with gauze and scooping out the clot with the gloved hand; less disturbance is caused to the patient by this method.

This done, the gloved hand should be inserted into the pleural cavity and swept around in order to detect and remove any splinters of bone which may be lying free, or the missile and portions of clothing. These are most likely to be found in the pleuro-diaphragmatic reflexion.

Next, the foreign body, if retained in the lung, may be detected by the fingers, and with the aid of two pairs of lung forceps the affected area is brought into the opening of the chest. The lung can be handled as easily as a coil of intestine, and without causing a great fall of blood pressure.

TREATMENT OF THE WOUNDED LUNG

A foreign body, when present, seems to lie generally near the surface of the lung, and can easily be removed; if necessary, a small incision may be made through the lung substance.

The hole in the lung should now be explored for splinters of bone and shreds of clothing, and cleansed as far as possible by swabbing. When there is a large ragged wound, and it is anatomically possible, a wedge of lung may be removed, or the edges of the hole clipped with scissors.

In any case, whether the wound is excised or not, it should be closed by catgut sutures, in either one or two layers, according to the depth of the wound. Bleeding is easily controlled by such suture.

CLEANSING OF THE PLEURAL CAVITY

In most cases it is only necessary to cleanse the pleural cavity by swabbing it dry and clean. If, however, there has been much soiling, it is advisable to wash it out with either warm saline or eusol. In any case, however, the chest should be left dry, an essential factor in the early expansion of the lungs.

CLOSURE OF THE CHEST

Whether the operation has been performed through the wound or by fresh incision, the chest should always be closed. The relief afforded the patient is instant and marked. An attempt should be made to repair the chest wall in layers — pleura to pleura, muscle to muscle, and skin to skin.

Where a large hole has been blown through the chest wall it may be impossible to make the edges of the pleura meet; in that case muscle should be made to cover the gap, even if a flap has to be cut. Finally, the skin should be closed by interrupted sutures. In the majority of cases healing will be by primary union.

POSTOPERATIVE TREATMENT

Regular postoperative aspiration is generally required to keep the pleural cavity dry for usually after a big operation there is a fluid exudate which if not removed may become infected. I believe this plan of treatment is thoroughly sound and in accordance with the principle of surgery; and if it could always be carried out I believe that many lives would be saved and much prolonged illness avoided.

THE LATER STAGES OF GUNSHOT WOUNDS OF THE CHEST

By Major G. GREY TURNER, R.A.M.C. (T.), Newcastle-upon-Tyne, England

MY interest in these cases was first aroused soon after the beginning of the war by the numbers of men who arrived at home hospitals wounded in the chest and complaining either of persistent shortness of breath with cough and other irritative symptoms, or only suffering from the knowledge that they harbored foreign bodies.

In those days it was the rule to look upon chest wounds as beyond the scope of legitimate surgical enterprise and the rule which guided the practice of those at the front was extended to the quiet areas behind the battle line. It soon became obvious that a great many of the cases labeled as gunshot wound of the chest were only suffering from injuries of the parieties. In others though the wound of entrance was on the surface of the chest, the missile was lodged in some part outside, such as the scapula, the neck, or even the abdominal cavity. I therefore determined to look into all chest wounds from the point of view of the surgeon with a view of determining if anything could be done for their relief, and I soon learned that this was a profitable line of investigation.

These cases reach us either direct from France or as return cases, that is to say, men who have rejoined their regiments or who have reported at Command Depôts and who have broken down under the strain of duty or graduated training. It is surprising what a large group these latter cases form and it teaches that in attempting to estimate the time necessary for recovery after war wounds, it is not enough to state that a man was "returned to duty" but that it is necessary to know of his progress for months or years afterward. Lastly there are those who come to us as pensioners — men discharged from the army — for whom special provision is being made at our civil hospitals and who are seeking relief in increasing numbers.

For some considerable time now it has been the practice in some of the armies in the field to treat gunshot wounds of the chest by early operation. These men reach us in various stages of recovery and the results are very much better than in those treated by expectant methods. The fewer cases coming to England for operation is an evidence that the first line of surgical defense is moving still nearer to the battle front and that this earlier and more complete treatment is rapidly diminishing the need for secondary operations. Among the total number of cases arriving from overseas the mortality is exceedingly small.

The Grouping of Cases

The cases can be conveniently arranged in the following groups:

I. Primary injuries of the chest wall.

II. Penetrating wounds with retained foreign bodies in the pleura or lung.

III. Infected hæmothorax with or without retained foreign bodies.

IV. Through-and-through wounds with impairment of movement and expansion.

V. Injuries involving the mediastinum or diaphragm.

Injuries involving the heart and pericardium are so infrequent that they are merely mentioned for completeness.

The Investigation of Cases

Every chest casualty arriving at the base requires to be as carefully investigated as any other type of wound. The symptoms have often changed since the last note, and the X-ray findings made nearer the front constantly require revision, as the absorption of blood alters the shadow. The most important and useful method of examination is by the fluorescent screen, for it shows so well the dark shadow due to blood in the pleura, the outline of the lung, and of the diaphragm and the movement of both, while comparison with the sound side furnishes an admirable standard. If a foreign body is present its position, movement on respiration, and rela-

tion to heart beats can all be determined. Localization should be by the simplest methods and the surgeon himself should verify the findings, remembering that it is really more important to have accurate localization of the foreign bodies in the parieties than in the lung, for in the latter case when the chest is opened a wide area may readily be palpated. We especially want some method which will give us information as to the presence and the extent of adhesions. On the operating table I have made use of a simple plan which has proved useful. A straight needle three inches long is thrust into the lung and its excursion noted. In the absence of adhesions this follows an up and down line, for one-half to one inch with each respiration, but in other circumstances movement is absent or much limited. I have never found portions of cloth or metallic débris in the sputum. Fluid from the pleural cavity must be subjected to microscopical and bacteriological examination, but the temperature chart and pulse ratio will often give an indication of a low-grade infection when no fluid is to be obtained.

The Features of the Various Groups

I. Primary Injuries of Chest Wall

These injuries are caused by fragments of shell or bullets or secondary missiles. Their principal interest lies in the fact that they are so commonly entirely left alone on the assumption that the wounds are penetrating and therefore not demanding interference, and because for one reason or another they are so often allowed to lead to months of disability. The patients often complain of soreness or tenderness when lying on the affected side or whenever they are called upon to exert themselves. Injuries of the rib with foreign bodies or sequestra are a common cause of sinuses on the chest wall. They may also be associated with sinuses on the upper arm, about the shoulder, at the root of the neck, or on the abdominal wall. Their origin is not likely to be overlooked if it is constantly borne in mind that a sinus is not a disease but a symptom the cause of which must be discovered. Sometimes men who only harbor foreign bodies in the parieties complain of shortness of breath or of pain on respiration and may present some limitation of movement of the side. Under these circumstances it must be remembered that there may be concomitant injury to the lung, and this is borne out by the frequent history of blood spitting at the time of the casualty and by the findings at operation and postmortem examination. Whenever there is the least suspicion, screen examination must be employed. Bullets and shell fragments have a wonderful knack of lodging snugly in an intercostal space or becoming actually imbedded in the rib and unless this latter point is remembered a useless search may be made for what is correctly looked upon as a comparatively superficial foreign body.

Osteomyelitis of the rib is not an infrequent result of an infected wound of the parieties and the multiple sequestra which may result can best be dealt with by excision of practically the whole of the affected rib. Costal cartilage readily dies and when it is necessary to interfere with it at all, it is best to remove the whole of the cartilage. Gutter wounds — contour wounds — of the chest are less likely to give rise to late trouble than the other varieties, because foreign bodies and bone fragments are not so often buried, but on the other hand they are more often multiple. In operations for parietal injuries steps must be taken to prevent the lighting up and distribution of old sepsis for re-infection of the cut bone is very liable to occur.

II. Penetrating Wounds with Retained Foreign Bodies in the Pleura or Lung

This is a most interesting group for it at once raises the question of the fate of foreign bodies retained in the lung. After four years' experience of war surgery, I am more and more impressed with the general truth of the proposition that sooner or later a foreign body wherever situated, tends to give rise to trouble. In the lung we know that many foreign bodies become safely encapsulated, others are extruded into the pleural cavity, usually into an already infected hæmothorax or they become the nidus for a localized empyema. Possibly in some cases foreign bodies are extruded into the air passages

and are coughed up with spontaneous cure, but this method must be largely limited by their size, and I have never come across an example. When operating on these cases I have found small localized collections of pus in association with the foreign body; the missile loosely held in an area of consolidation or a larger area of consolidation with the foreign body in its center and a purulent infiltration round about it.

In the absence of naked eye evidence of infection, often no growth has followed the immersion of the foreign body in culture media, and this is in keeping with the proved power of the lung to resist war wound infections. Sometimes there are shreds of cloth around the foreign body, but even in these cases a singular absence of any evidence of inflammation. In no case can I say that an old infection in the lung has been lighted up by surgical interference but I have always the feeling that the pleura and the cellular tissue are less favored and may have been infected.

The symptoms of which these men complain can be arranged in two definite groups: first those with a physical basis such as pain, cough, pus spitting, and hæmoptysis, and second, those in whom the symptoms are largely nervous. In both groups complaint of shortness of breath is invariable.

Chronic cough with intermittent slight hæmoptysis is the commonest symptom in the first group and both are much worse on exertion. The blood is usually small in amount but may be as much as three or four ounces. Sometimes these symptoms almost entirely disappear during complete rest, but recurrence is the rule and I have patients which show that this sequence may continue for even two years. I must here just mention the importance of excluding tubercle which may be lighted up by lung traumatism, though it is undoubtedly infrequent. Cough with pus spitting is less common and I have been surprised at the very few cases in which the expectoration suggests localized abscess or bronchiectasis. When it does occur the expectoration is characteristically foul, abundant, and continuous. It rapidly follows the hæmoptysis attending the casualty and continues until the foreign body is removed. Pain is commonly referred to a localized area and often only present after exertion. Not infrequently there is tenderness over the same spot.

In the second group the nervous symptoms either occur alone or are predominant and it is amazing to find what a large number of men complain of the mere presence of the foreign body which causes them much mental misery. An analysis shows that these men dread the ultimate consequences of the presence of the foreign body and no amount of assurance relieves their anxiety. At first I used to think that it was perhaps because they feared further military service, but the increasing numbers of pensioners who come for relief has altered my view. It was this latter group which first made me seriously consider the advisability of operative interference because I saw so many men who lived a life of apprehensive misery consisting of short periods in and out of the hospital.

The correct interpretation of the shortness of breath is difficult and I cannot help thinking that it is not entirely mechanical. Old hæmothorax with thickened pleura and marked shrinkage of the side, adhesions with little evidence of shrinkage, and interstitial changes in the lung resulting from the traumatism inflicted when the foreign body lodged, may all be causative factors, but in addition there seems to be some sort of inhibition suggesting a nerve origin.

In the patients who complain of pain and tenderness, I have been struck by the association of a localized area of adhesions in the track of the missile. On the other hand a general diffuse adhesion between the pleural surfaces is not attended with pain and indeed may be a means of preventing it.

The signs in this group are almost limited to those due to associated old hæmothorax and to the very valuable help derived from the examination by the fluorescent screen. Want of movement of the foreign body is not conclusive evidence that it is outside the lung, for in the presence of adhesions there may be no recognizable movement when the foreign body is near the posterior border of the lung or in any part with a lung diffusely adherent.

When considering the question of surgical interference we must never forget that these patients have fortuitously recovered from what has often been a most dangerous casualty and we ought not to subject them to further risk without good reason. In intrathoracic operations there must always be an element of uncertainty and I have to regret a death which I am at a loss to explain and to admit that in some few cases the convalescence has given cause for anxiety. The very readiness of our men to submit to operation increases the responsibility, and their "love and faith which failure cannot quell" is to me an abiding wonder while it is a constant stimulus to increased effort on their behalf.

I have now come to a position in which I would advise operation in this group if there are definite irritative symptoms leading to disability or continued discomfort and in which I would be willing to undertake operation if the removal of the foreign body would rid the patient of an incubus preying on his mind detrimentally. Unless symptoms are very definite I would hesitate to operate when localization shows the foreign body in or near the hilus, for experience has taught me that it is often difficult or even impossible to distinguish at operation between a small foreign body and a bronchus or the calcareous glands which are so frequent in this situation. It may be well worth while to open the thorax and to deal with some band of offending adhesions, even though anatomical considerations and prudence forbid any search for the foreign body.

The method of approach. There are two definite plans for approaching the lung. The first consists in excising or displacing the anterior part of the fourth rib and opening the thorax. The space gained is then enlarged by the use of the rib separator so that either the lung can be withdrawn or the hand introduced and the foreign body dealt with *in situ*. This method has the able advocacy of Major General Sir Berkeley Moynihan and those who have witnessed his brilliant operations are much impressed by the great beauty of the technique as practiced in his hands.

The other plan aims at reaching the affected part of the lung by the most direct route, that is to say nearest the site of localization of the missile and this is the method which I have usually practiced.

Technique. Beyond some reliable type of rib separator and a good head light, no special instruments are required. For anæsthesia the intratracheal method is not essential and is often a disadvantage. I employ ordinary inhalation anæsthesia with $CH Cl_3$ and ether preceded by morphia and atropine. It is now established that a free pneumothorax is perfectly safe and that in most cases it is much better to work with the lung completely collapsed.

After the thorax is opened band-like adhesions should be separated by the fingers or with scissors. When the foreign body is in the borders of the lung, and especially the lower border, the portion in which it is situated can easily be brought outside for its removal. When near the middle of the lung or in the posterior surface, the missile is better removed without any attempt to withdraw the viscus. Diffuse adhesions completely shutting off the pleura need not be separated, the lung being incised *in situ* over the foreign body.

Complete closure of the incision in the lung is the ideal method and when this can be carried out the pleura may be completely closed. In other circumstances I use a small tube drain which is removed in 48 hours. Secondary aspiration for fluid has never been necessary. It is an advantage that the pneumothorax should not be rapidly removed so that the incision in the lung may be sealed before it expands.

Difficulties and complications. It would be unfair to give the impression that the operation under consideration is invariably a simple matter. It must always be an important operation and it may be very difficult, especially in deeply chested, powerful men in whom respiratory movements are very vigorous. Under these circumstances air is sucked into the cellular tissues in an embarrassing manner and it may also be very difficult to steady the portion of lung which is to be incised. When the foreign body is on the inner surface of the lung the beat of the heart against the fingers may be disconcerting.

It is easy to tear into the pericardium while separating adhesions and though I have seen no harm follow, it is clearly an accident to be avoided.

Surgical emphysema may be an immediate sequel, but it is unusual and when it does occur is principally limited to the region of the wound though it may be widespread and I have seen it extend up into the neck and down into the scrotum. It always clears up without treatment.

Some few patients suffer considerable respiratory distress just after the operation, but it is surprising how smooth convalescence usually is. There is often a little blood spitting which may continue for some days and there may be quite marked bronchitis affecting the opposite lung. Patients are often well enough to be out of bed in from ten days to a fortnight, and I had one man who was up on the eleventh day and rejoined for duty on the twenty-first day following the operation, but the period of convalescence varies with the gravity of the condition demanding interference and where there has been much destruction of lung tissue, the period may be prolonged.

Results. Interference in these cases has been exceedingly encouraging though it will require observation over months or years to determine the final results. Some of the patients have so completely recovered as to return to duty at the front, many have been allocated to home service, and others have been invalided out of the army but are able to earn a livelihood with the assistance of their state pension. Some of the neurasthenic patients have relapsed, but this is only in keeping with the results of operations in general on these unfortunate sufferers. As your President[1] says: "Surgery is a bad form of suggestive therapeutics," but I always feel that it must give the physician a better chance to let him have his patient with such tangible sources of mental worry removed.

Though nearly all continue to complain of some shortness of breath, this symptom has been greatly improved in practically every case.

[1] Dr. W. J. Mayo.

III. INFECTED HÆMOTHORAX WITH OR WITHOUT RETAINED FOREIGN BODIES

These cases either come to us already draining or requiring incision. They are much more serious than ordinary empyemata and often demand more drastic means for their cure. The pathology is essentially different, for here we are dealing with a serous sac filled with masses of blood clots which have become infected and are slowly disintegrating and there are often sequestra and foreign bodies. Every case of draining hæmothorax arriving from the front should be carefully X-rayed and screened and if recovery is at all delayed should be explored under anæsthesia. The original opening should be enlarged by resection of several inches of one or more ribs and foreign bodies and all masses of decomposing blood clot must be thoroughly removed. The final stage should consist in a dry mopping of as much of the cavity as can be reached. Two large tubes should be used for drainage.

Quite often the temperature does not come down at once and some patients are very much upset and may suffer from vomiting and abdominal pain at first. When the temperature has remained normal four days the patients are encouraged to get up and a day or two later begin the use of blowing bottles to help expansion of the lung. Some of the later stages of these cases I have treated by Moorhof's bone filling simply using it as a plug without any attempt at secondary suture.

Cases are frequent in which cavities have not healed or have broken down, but these are nearly always due to retained foreign bodies or to inadequate rib resection, and they yield to thorough exploration. This should not be delayed because of negative X-ray examination, for the small sequestra, bits of cloth, etc., which may be keeping up the suppuration, will not show in the presence of the obscurity caused by much thickened pleura. In these cases and in fact in all cases of gunshot wounds of the chest, it is important to be alive to the possibility of concomitant injuries such as those involving the diaphragm or the neighboring viscera, for operative interference may disturb the favorable progress of some such complicating condition.

Small localized empyema are very apt to be overlooked. Shortness of breath, sweating, and tachycardia are very suggestive symptoms and in their presence very careful physical and screen examination should be employed. Negative exploration with the needle is not conclusive because the contents are often so much inspissated that they cannot be withdrawn in this way. Cases with sinuses require careful investigation and it must not be assumed that they are always connected with a demonstrable foreign body, for I have been surprised to find that the latter was outside the cavity and safely shut off by its thick wall, the sinus being due to imperfect obliteration of the cavity. Small sinuses without a demonstrable cause may be cured by the use of Beck's paste.

IV. THROUGH-AND-THROUGH WOUNDS WITH IMPAIRMENT OF MOVEMENT AND EXPANSION

Some few men so completely recover from these injuries and are so thoroughly restored that there are no signs or symptoms by which their casualty may be recognized, but in a great many recovery is very long delayed and incomplete. The invariable complaint is of varying degrees of shortness of breath either constantly present or set up by the least exertion. When such cases are investigated by ordinary methods they may only show a little general retraction of the affected side with corresponding diminution in air entry and breath sounds, but screen examination may furnish most valuable information.

There is often an obvious shadow or a general mottling due to an unabsorbed hæmothorax, while the edge of the retracted lung may be outlined as a well defined dark line. The diaphragm is often flattened, higher than its fellow and shows limited movement, or there may be obliteration of the costodiaphragmatic angle, the diaphragm being pulled up to the chest wall so that its upper surface is like an inclined plane instead of a dome. These conditions are constantly found after infected hæmothorax, but the revelation is often surprising in the absence of infection. In other cases the shrinking and flattening is entirely limited to the lower part of the thorax particularly well marked if the left side is affected. The lower ribs may be almost concave. The great shrinking may be present in the absence of any evidence of unabsorbed hæmothorax. As in the last group it is necessary to be constantly on the lookout for localized empyema of low-grade infection.

The foreign body having traversed the lung is often lodged in the parietes or in some more distant part. As a rule it is not difficult to locate and to remove such foreign body and this may bring a certain amount of mental relief, but the symptoms are due to the damage caused to the thoracic contents and it is futile to remove the foreign body without an endeavor to cure the other symptoms.

Graduated exercises, gymnastic measures, especially directed to expansion of the chest and the use of blowing bottles and other plans for expanding the lung have in my experience proved disappointing in their results, but I am sure that these methods can be further developed and that much can be done by their aid. It is in this class of case that I have had some most encouraging results from thoracotomy. When there is old hæmothorax, masses of organizing clot can be removed. The lung will commonly be found imprisoned in a sort of sheath formed of organizing blood clot and this extends on to the diaphragm interfering with its proper movement. Under these circumstances decortication is indicated.

It is most interesting to see the lung reappear from its coat of mail and to realize that it again has the chance to expand normally. In dealing with these particular cases, I feel the want of an anæsthetic apparatus which will easily allow of a change from ordinary inhalation anæsthesia to a positive intrapulmonary pressure in order to demonstrate the capacity of the lung for expansion and enabling the thorax to be closed with the air expelled from the pleura. I believe these indications are met by the Schumacher apparatus, but I have not had the opportunity of using it. In the cases in which there are only adhesions they can be separated either with the fingers or with long curved scissors. To completely liberate the lung those between the base and the diaphragm must be

thoroughly dealt with. The thorax is completely closed and as full breathing exercises as possible are carried out from the beginning. In those cases in which there has been suppuration, the visceral covering is not easily separated and the underlying lung is easily torn. To meet this difficulty a series of longitudinal incisions with or without cross cuts appears to allow enough room for expansion. The results in a limited number of cases have been surprisingly good.

Many of the cases which we have just been considering have been repeatedly aspirated for hæmothorax and there can be no question that recovery after this method frequently stops short of complete success. I have often wondered if a more thorough emptying of the pleura by thoracotomy at the time of the casualty would not lead to a greater proportion of complete cures.

VI. INJURIES INVOLVING THE MEDIASTINUM OR DIAPHRAGM

In this group are collected the cases in which foreign bodies in the mediastinum are associated with injuries of the lungs and pleura or in which the casualty has primarily involved the mediastinum only. Small foreign bodies may be safely imbedded and without symptoms or they may lie on the trachea or bronchi and give rise to dyspnœa or to cough and sense of suffocation. Larger foreign bodies are likely to be associated either with persistent sinuses or with recurring breaking down of the wound. As a rule they can be safely reached anywhere in the anterior mediastinum by a lateral approach after removal or displacement of one or more costal cartilages.

In all cases with sinuses wherever situated care must be taken to explore and to clear the track itself, for sequestra and bits of cloth are so likely to lie there where they are certain to cause mischief even after the successful removal of the foreign body. Foreign bodies embedded in the pericardium are not uncommon and I have removed them from both the anterior and the posterior surface of the sac.

When in the diaphragm foreign bodies may be associated with symptoms which suggest a casual relationship though I believe that such symptoms are more likely to be due to damage produced during transit of the chest.

SUMMARY

For the sake of clearness I would like to recapitulate what I consider to be the indications for operation in these late cases:

1. Foreign bodies in the parieties with or without sinuses.
2. Foreign bodies in the lung irrespective of size if associated with persistent cough. hæmorrhage, or suppuration.
3. Large foreign bodies in the lung even if the symptoms are purely nervous.
4. All foreign bodies lodged in the pleura with or without empyema.
5. All cases of infected hæmothorax.
6. All cases of through-and-through wounds with shrinking of the side, lessened lung expansion, and interference with movements of the diaphragm in which treatment by exercises, etc., has failed.

The object of this paper has been to draw attention to what I conceive to be a neglected group of cases and to suggest that the later stages of gunshot wounds of the chest not only form important subjects for study but offer a large field for restorative surgery in which the rewards are commensurate with the risks.

On going through my notes I find many cases that I now feel would have been benefited by operation, for as in all other branches of surgical enterprise, increasing experience brings increasing confidence and a desire to extend the benefits of operation.

The success of thoracic surgery in this war is a pleasing recognition of the importance of general surgical principles in military surgery for which so many of us have contended.

THE EARLY TREATMENT OF WAR WOUNDS[1]

By Colonel G. E. Gask, D. S. O., London, England
Consulting Surgeon, British Expeditionary Forces in France

In the British service the Casualty Clearing Station is the most advanced unit in which efficient hospitalization can be given to the wounded. In the early days of the war it was not contemplated that much surgery should be done in these units, which, as their name implied, were intended as centers for the evacuation of wounded to the base where the surgery was to be done.

Experience has shown that this was a mistake, for the sooner a man can be operated upon and his wound excised and cleaned, the better the result. The natural sequence has been the development of the Casualty Clearing Station to be an important surgical center.

In order to make things clear, let me describe quite briefly the position and constitution of a Casualty Clearing Station. The hospital is placed usually from six to ten miles behind the firing line so as to be out of danger of all but long range gunfire. It is always adjacent to a railhead up to which ambulance trains can come to evacuate the patients to the base.

The medical staff consists of a commanding officer and six medical officers with from ten to fifteen trained nursing sisters. This staff may be augmented by surgical teams sent from other parts of the army, so that during a battle twelve or fifteen teams may be at work.

The essential medical elements of a Casualty Clearing Station are:

1. Reception ward,
2. Dressing room,
3. Pre-operation ward,
4. Resuscitation ward,
5. X-ray room,
6. Operating theater,
7. Postoperative wards,
8. Acute medical ward,
9. Evacuation wards.

The patients are accommodated in tents, huts, or buildings according to the position and character of the fighting, and material available.

Reception ward. Here the wounded are offloaded from the ambulance cars and the clerks take the particulars from which the casualty lists are compiled.

Dressing ward. From the reception ward the men go into the dressing ward, through which every single patient is passed and where the future course and treatment of each patient is decided. This is what the French term *triage* and we call "reception" or "sorting." It is most important work, requiring sound experience and cool rapid judgment.

Here orderlies cut down the dressings, exposing the wound ready for the officer-in-charge to make his examination. This officer looks at the field medical card, notes the entry, e. g., gunshot wound of buttock, or gunshot wound of thigh with fracture of femur; he assures himself that antitetanic serum has been given and noted and then he examines the nature and extent of the wound and the physical condition of the patient and makes his diagnosis.

He has now to decide what shall be done, and the following courses are open: (1) A man with a trifling wound may be returned to duty. (2) A man with a wound not requiring operation but yet incapacitating him from duty is dressed and sent straight to the evacuation ward to go away by the next train. (3) Patients requiring operation are sent to the pre-operation ward, if necessary via the X-ray room. (4) Very seriously wounded, suffering from shock or loss of blood, who owing to their condition are unfit to stand immediate operation, are sent to the resuscitation ward.

The officer in charge of the reception department must be very familiar with the working of his hospital and have full knowledge of the capacity and number of the surgeons, for during times of stress it is useless to send more cases for operation than the surgeons can deal with. It becomes his duty to estimate the number of operations that can be done, select

[1] Prepared for presentation before the ninth annual session of Clinical Congress of the American College of Surgeons.

those cases that are most suitable or most urgent, and evacuate the others to the base.

Pre-operation ward. Here cases are made ready for the operating theater. Strippers are at work taking off the mud-caked and blood-soaked clothes, washing the patients, and putting them into pajamas.

Resuscitation ward. In this ward are gathered the wounded who from cold, fatigue, loss of blood, or shock are unfit for operation. It is a pitiable and heartrending sight on which it does not do to dwell. Better is it to grip the spirit of a motto which appeared over the entrance of one of these wards: "Dum spiro — cheerio." Active bodies of men have been working on the "shock problem." Much has been done already to bring apparently hopeless cases back to life and more is being done day by day, now that transfusion of blood is coming into general use. This is largely owing to the influence of the American surgeons who came to supply our need and earn our love, gratitude, and admiration working with us and for us in our hospitals.

Operating theater. These are not the beautiful marble palaces we contrived in civil practice. During mobile warfare they are in tents with meagre furnishings. The average theater contains eight tables and is so arranged that each surgical team is self-contained, with its own sisters, orderlies, and instruments, all arrangements being designed to promote rapid and efficient work.

Postoperative wards. In these are gathered those pateints who from the severity of wounds or nature of operation are considered unfit to travel. These wards are equipped with beds and made as comfortable as possible.

Treatment of wounds. During the four years of war so much has been written on the treatment of wounds, so many methods have been advanced, lauded to the skies, and practiced for a time only to be discarded, that it is difficult to remember them all, discuss them intelligently, or give credit where credit is due. For this reason I propose only to tell you what I myself now believe to be the best treatment, realizing that many surgeons differ from me, and knowing full well that excellent results may be obtained by many different methods.

The basis of all successful treatment of wounds is early mechanical cleansing by surgical operation conducted under aseptic precautions. By this is meant the removal of all dead or damaged tissue, together with all foreign bodies such as the missile, portions of clothing, or splinters of wood. If this is done and is followed by closure of the wound either immediately by "primary suture" or a few days later by "delayed primary suture," then a very large percentage of wounds heal by first intention, with a resultant saving of a great many lives and an immense reduction in the period of convalescence, labor of medical officers and of dressing material.

Excision and suture have caused quite a revolution in the general treatment of gunshot wounds.

Antiseptics. Little has been said in this paper about antiseptics, the reason being that it is my firm conviction that they are of little importance. The important thing is that a wound should be subjected to a complete, early, mechanical cleansing *before organisms have time to multiply and invade tissues.* If this is done, it matters little whether a wound is swabbed with ether, flushed with Carrel-Dakin solution, smeared with "bipp" paste, or packed with flavine. As long as the wound is cleansed mechanically and no more organisms put in, then the wound will remain clean and may be closed at an early date.

An interesting experiment was made during last winter. One entire Casualty Clearing Station was set apart for the purpose of ascertaining the possibility of excising and suturing wounds on a large scale. Previous to this it was well known that many wounds had been excised and sutured successfully. It was the routine treatment to excise and suture the scalp in head wounds; it was the same for wounds of the knee-joint, of the abdomen, and more latterly, of the chest. It had never been demonstrated, however, that the method could be applied on a large scale to all manner of wounds.

The experiment was conducted on the following lines: A bacteriological examination was made of every wound selected for the purpose. It was found that the large majority

were infected, and most of them with a great variety of organisms, both aerobic and anaerobic. The patient was then sent for surgical treatment. There were three sets of surgeons, and each of the three sets treated the wounded in three different ways. In each case the wound was first excised and then it was treated with either saline, or ether, or "bipp" paste.

The results by all methods were extraordinarily good. Primary union was obtained in over 80 per cent of the cases, among which were many compound fractures. Between the three methods used there was very little choice to be made. It is true that some surgeons leaned more to one method than the other, but the main fact that stood out clearly was that the essential treatment consists in early complete mechanical cleansing of the wound followed by early closure.

This method is described by some as a surgical revolution. Of course it is not; it is rather a return to sanity. We have been blinded by the advocacy of all sorts of antiseptics which instilled into wounds were supposed to kill off all organisms.

The following facts have emerged from this experiment:

1. Over 80 per cent of the wounds treated by excision and suture healed by first intention.

2. Gas gangrene, one of our great bugbears in the early years of the war, is no longer to be feared, provided that early and efficient surgery can be rendered.

3. The most dangerous organism to the patient and the one that defeats our efforts up to the present is the hæmolytic streptococcus. Primary suture failed in practically every case infected with this organism.

4. Patients whose wounds had been excised and sutured at once, if put on the train and sent down to the base, did badly. The reason appears to be that the operative treatment does not get rid of all organisms, and though the tissues are capable of dealing with them if conditions are favorable, the commotion and shaking of the train causes a little fresh bleeding and provides the remaining organisms with conditions favorable for their growth.

The result was the establishment of the following routine: If a wound is excised and sutured, the patient is kept in the hospital under the care of his surgeon until all risk of suppuration is over. During quiet times it is possible to retain such cases in the casualty clearing stations, but in busy times, in times of battle, the holding capacity of these hospitals is not nearly enough; they must be cleared.

To meet this difficulty the following practice has been evolved: At the casualty clearing station the wound is cleansed by excision. It is then lightly packed with either dry gauze or gauze soaked in flavine or paraffin. The patient is then sent down to the base, having attached to him a distinctive label, "For Delayed Primary Suture." At the base the patient is taken to the theater, placed under anæsthetic, and the wound if considered suitable is then sutured. Following this plan thousands of wounds have been sutured this year.

This "delayed primary suture" or *suture primitive retardeé*, as the French term it, has shown itself even more successful than the primary suture for the reason that if a case is going to go wrong from infection with the hæmolytic streptococcus, it will do so early and such a case will be reserved for secondary suture.

Favorable time for operation. The best time is as soon as possible, provided that the patient can stand the operation. The average time between receipt of the wound and arrival at the casualty clearing station is twelve to eighteen hours, and wounds excised about this time usually do well. It has been shown though that a wound can be excised and sutured successfully even up to and after forty-eight hours.

Technique. There is nothing difficult or complicated about this; cleanliness and care are the requisites. The essential is to remove every scrap of dead or badly injured tissue and every foreign body, whether a bit of shell, splinter, or cloth. In order to make a complete removal of all dead tissue, it is necessary to expose every recess and corner of the wound. This often involves a long incision, which should be planned to allow of

free exposure and subsequent closure. This closure of the wound is often difficult on account of loss of substance, and calls for ingenuity on the part of the surgeon. Much may be done by undercutting and insertion of deep tension sutures. Drainage tubes are in disfavor. As a rule they do not drain and act only as foreign bodies. Considerable use is made of filiform drains, a few strands of fishing gut or a bit of pewter wire giving sufficient room for the exit of any collected serum

After suture rest is necessary, but it must always be borne in mind that the object of the surgeon is not only to get union of his wound; he desires to *establish restoration of function.* It is likely that we have been too conservative in our methods and have rested limbs and fixed joints for too long a time, giving rise to all sorts of contractures. It is my belief that after closure, very few wounds other than fractures require splinting for more than two or three days. The patient himself is the best judge, he will never hurt himself by movement and it is a safe rule to allow movement up to the limit of the patient's toleration.

The psychological side of the soldier is worth studying, too. He is much more likely to get well quickly if allowed to move about and be encouraged to move about at an early date. These remarks apply to every type of wound, whether of the soft parts, of the abdomen, or of the chest or skull. The earlier, more careful, and more complete the surgery, the better the result. That is the reason why Casualty Clearing Stations have become important surgical centers. In other words, the surgeons are taken to the wounded and not the wounded to the surgeon.

The lightly wounded men. The previous remarks have related rather to the seriously wounded to whom all our humanitarian instinct goes out. It is only right and proper that all our efforts should go to succor them and save their lives and limbs. From a military standpoint, from the standpoint of reducing wastage of man power, which in the long run is also humanitarian, the treatment of the lightly wounded men is of the greatest importance. In the past there has been rather a tendency to neglect these men as not requiring urgent operation. During a battle they arrive at the Casualty Clearing Station in large numbers. Supposing for instance that during a battle one thousand wounded arrive at a Casualty Clearing Station, roughly six hundred will be walking wounded and four hundred stretcher cases. The walking wounded suffer from all variety of wounds, from light scratches to moderately severe injuries with or without retention of foreign body. Naturally when there are many more wounded than can be dealt with, the irresistible tendency is to treat those cases most in need of treatment; life saving must come first. Therefore the lightly wounded must be evacuated, and they go to the base as quickly as they can be got away by the train. If these cases are not treated at the base, many of them suppurate, and a man with a small, almost negligible wound may be incapacitated for two or three months or more.

To remedy this we have recently organized large hospitals at the base, to which the lightly wounded are sent as quickly as possible. These hospitals are organized to get as many surgeons as possible into action at once, and all efforts made to pass as many wounded as possible through the operating theater before the wounds suppurate. Here the wounds are excised and sutured. The results have been most happy; in our particular hospital during recent fighting they had 90 per cent of success from suture under these conditions. One of the hospitals was under the direction of Colonel George Crile, to whose brilliant inspiration we owe much. Colonel Crile made some very interesting and important observations. He made composite temperature charts from patients whose wounds had been excised, treated with ether, alcohol, saline solution, flavine, or "bipp" paste. The best temperature charts were obtained from those patients whose wounds had been treated with saline only.

Battle technique. It has been suggested a battle technique should be developed; that instead of doing good surgery for a comparatively small number of men, a larger quantity of unfinished surgery should be done. In my opinion this is absolutely wrong. As it is, it is hard enough during battle to

maintain a high standard, but let us always aim at the ideal.

The main principles of surgery are as true in war surgery as in civil practice. The great advances which surely have been made in war surgery are not due to the discovery of any new principles, but are due to the development of a medical organization which permits the application of surgery near the front and enables surgeons to treat the wounds before infecting organisms have time to invade the tissues.

It is the aim of this paper to speed the coming of that ideal medical organization which will permit the treatment of each wounded man in such a way that suppuration will become as rare in military as in civil practice.

ACUTE PERFORATIONS OF THE ABDOMINAL VISCERA[1]

By WILLIAM J. MAYO, M.D., F.A.C.S., Rochester, Minnesota
Colonel, Medical Corps, United States Army

THERE is a certain surgical philosophy which not only interprets disease conditions from the clinical and pathologic standpoint, but also endeavors to arrange facts in orderly array, to follow the natural history of the disease and its relations to other disease processes of which it either is a part or with which it may become associated as a cause or an effect. Such philosophy does not follow a direct pathway, textbook fashion, but strives rather to secure a perspective of the devious paths along which knowledge of disease in general has advanced; its ultimate goal is the full exploration of the breadth as well as the length of the road. In this manner, I believe, we may acquire wisdom.

Our knowledge of acute perforations of the abdominal viscera had its origin largely in perforative appendicitis, although the first perforations studied were those of the stomach. To the late Reginald Fitz, of Boston, we owe our earliest organized knowledge of three most important surgical conditions: The relation of appendicitis to general septic peritonitis, of perforations of the pancreas to fat necrosis, and of the diverticulum of Meckel, its infections and perforations, its frequent occurrence in the young, and the ironing-out process of development and gas pressure by which Meckel's diverticulum becomes less evident in the old. The work of Fitz was done largely postmortem. His investigations connected cause with effect, but as they began in the dead and ended in the grave, an exaggerated notion of the fatality of acute perforations in general was obtained. The evidences of perforations were almost lost in the peritonitis which ensued and which caused the death of the patient. In speaking of acute perforations, we visualized the dead man with a general septic peritonitis.

The slow process of developing a living pathology was taken up by the surgeon, and little by little the ravages of the fatal septic peritonitis were separated from the cause. We began to see that not all perforations ended fatally and that many factors came into play which might permit of spontaneous recovery from any particular perforation. These factors concerned the quantity and virulence of the leakage from the perforating organ, the general resistance of the patient, and the local anatomic situation of the perforation with relation to the prospects of limiting, by adhesions, the spread of the contamination and resulting peritonitis. The mechanical relations of the perforated viscus to the omentum, colon, and other peritoneal covered organs as well as to the abdominal wall, which would permit of barricades against further spreading, and especially those mechanical factors which prevent contamination of the small intestine with its peristalsis, received merited attention. The dictum that "cathartics kill the patient with acute perforation" was generally accepted. The fact

[1]Prepared for presentation as the Presidential Address before the Ninth Annual Meeting of the Clinical Congress of the American College of Surgeons.

that restriction in diet, the washing out of the stomach, and water by rectum lessened the danger of the spreading of contamination and infection by peristalsis was established by Ochsner and Murphy. Even the most conservative surgeon began to wake up to the fact that after contamination had passed into peritonitis the most important factor was the peritonitis, and that the so-called early operation was not related in time to when the surgeon saw the patient but to the time when the perforation took place. How well we remember those great debates on appendicitis, when the surgeon in the heat of argument said that he "always" did so and so, when he meant "often," and the safety of his patient depended on the fact that he was a better surgeon at the operating table than on the rostrum. When contamination was allowed to pass on to peritonitis, the surgeon had lost his great opportunity, and the second dictum was reached: If you must operate in peritonitis for a local lesion, "get in quick and get out quicker," choosing a time when intervention can be safely made rather than to bring a surgical catastrophy on a patient who has only a narrow margin of safety. We learned that the peritoneum had marvelous powers of resistance to infection, and that the surgeon could act only in the capacity of an aid to those natural processes which led to recovery.

It can no longer be said that we are operating for perforation when we do a laparotomy on from the third to the sixth day of a generalized peritonitis. An operation, however, may be wise in order to remove a still active primary focus or secondary deposits of virulent infection, in the hope of limiting the spread of the disease. Acute perforations of the abdominal viscera then, so far as the peritoneum is concerned, may be divided into three stages: (1) The stage of contamination, shown by more or less shock and localized pain and tenderness. This is followed by (2) the stage of reaction; we might well say the fatal stage of reaction, because so many patients with acute perforations slip by the stage of contamination in which they could have been safely operated on, into (3) the stage of general peritonitis. The apparent improvement which takes place in the period of reaction leads to the belief that the patient is better. Muscular rigidity and tenderness are usually present but may be absent in the middle-aged, fleshy man whose peritoneum has become anæsthetic by reason of fat deposited behind it.

The anatomic situation of the appendix is such that the prospects of the localization of the sepsis and spontaneous recovery are usually good. Recovery, yes, from that particular attack. It is probable that not far from 70 per cent of patients with acute perforation of the appendix might recover from one attack spontaneously, but a death rate of 30 per cent is a frightful one. No battles of the present war would probably have a death rate which would exceed it, although they might have a casualty of 90 per cent. In acute perforative appendicitis we have a casualty of 100 per cent, and let us accept as probable a 30 per cent death rate. But such patients recovering spontaneously, cannot be said to be well. The majority will have future attacks in one of which they may not be so fortunate as in the first. I have seen several patients more than 60 years of age with acute intestinal obstruction from bands of adhesions that had their origin in a so-called spontaneous recovery from inflammation of the bowels when a child.

There is a curious relationship between acute perforations of the gall bladder into the free peritoneal cavity and acute perforative appendicitis. I have seen a number of simultaneous perforations of the gall bladder and appendix. In these cases the gall bladder has usually contained stones, the pus has had a strong colon odor and its bacterial flora has been similar to that in the pus escaping from the appendix. The first case of this kind under my observation resulted most unfortunately, as the condition of the appendix escaped attention. The gall bladder had perforated and a beginning septic peritonitis with a good deal of turbid fluid was present. The patient had been ill with acute symptoms for more than 72 hours. I, therefore, removed the stones as quickly as possible, drained the gall bladder, and evacuated the fluid contents of the abdomen, made a rapid toilet, and inserted drains. The patient died 48 hours

later, when I found that there had been a perforation of the appendix, with an abscess imperfectly walled off, into which a fæcal concretion had escaped. Had I discovered the true condition of the appendix at the time of operation there is little doubt that the patient would have recovered. Since that time, I have always examined the appendix in cases of acute perforations of the gall bladder, and in a number of instances have seen similar conditions. It would appear that, in such cases, the infection started in the appendix and was carried through the portal circulation to the gall bladder already infected and containing stones.

Perforations of the gall bladder into the free peritoneal cavity should and would give the best results of any, were it not for the fact that the patient has usually had previous attacks of cholecystitis and believes the present attack is similar to those that he has had before. Early operations, therefore, in such acute perforations of the gall bladder are less liable to be insisted on, and the patient dies, not because of the acuteness or character of the infection, but because of the lateness with which operative procedure is carried out.

Infection reaching the liver by way of the portal circulation is much attenuated by the action of the liver cells, and the escape of septic material from the gall bladder and bile ducts has a tendency to set up a rather mild peritonitis. On several occasions I have found a perforated gall bladder with escaping gall stones and beginning peritonitis. In two instances I have removed hundreds of stones by scooping them and the fluid exudate out of the pelvis with the gloved hand, and finally stopped without satisfying myself that I had actually removed all the stones. Such patients operated on in the first 48 hours, have recovered.

The anatomic surroundings of the gall bladder are excellent from the standpoint of protection. The parietal peritoneum, the under surface of the liver, the transverse colon, and the omentum all combine to localize the contaminating material which may escape from the perforation. Free perforation, therefore, while it often takes place, is commonly limited by a rapid protective peritonitis with plastic exudate confined to the immediate vicinity of the gall bladder.

Gall stones are foreign bodies. While they may remain for long periods of time without evidence of active infection, they are a potential source of focal infection in the production of endocarditis, etc., and when acutely infected are the common cause of biliary cirrhosis, chronic pancreatitis, etc. We have found a higher percentage of so-called essential hypertensions in connection with gallstone disease than in any other surgical disorder with which we have come in contact.

The association between the diseases of the gall bladder and biliary tract and the pancreas is shown by the fact that 90 per cent or more of all the patients having acute and chronic diseases of the pancreas that we have operated on have had infected gall bladders and, usually, gall stones. To all intents and purposes, acute fat necrosis and hæmorrhagic pancreatitis are the results of perforation of the pancreas and the escape of its secretions. The area of distribution of escaping contents from the pancreas is determined by the fœtal pancreas rather than by the adult anatomy; the pancreas in fœtal life is entirely surrounded by peritoneum, the posterior layer of which in the adult has become converted into connective tissue with the formation of the capsule.

The danger of the acute processes of the pancreas which may be spoken of pictorially as acute perforations, depend almost entirely on whether or not infection co-exists. I have seen aseptic fat necrosis with a large soft pancreas, almost like pudding in a bag, and acute and subacute pancreatitis in every phase from the earliest, with free peritoneal fluid and most widespread fat necrosis, through all the stages to spontaneous recovery which is a not infrequent termination. This is also true of the pancreatic apoplexies which cause hæmorrhagic cysts. I have seen a considerable number of these aseptic, localized collections of blood in and about the pancreas; the patient gives a history as in fat necrosis of a most serious, acute illness which gradually subsides and leaves hæmorrhagic residue. It is said that activation of the pancreatic juice by the duodenal secretions is necessary to

precipitate pancreatitis with fat necrosis or hæmorrhage. Infection certainly plays the chief part in determining whether or not the patient will recover. At various times I have opened abscess cavities connected with the pancreas and on several occasions have lifted out a slough which apparently represented the whole of the pancreas, but the recovery of the patient without diabetes or other sequalæ showed that not all the pancreas had been removed.

Deaver has called attention to the possibility of the infection of the pancreas through the lymphatics. The pancreas has five sources of blood supply and lymphatic connections with each. With his usual clarity of vision, Deaver points out that the pancreas has two entirely different secretions, a lipolytic or fat splitting ferment which saponizes the fat, producing the little areas of lipase that we call fat necrosis, and tripsin which acts on the protein tissue, especially the blood vessels, causing the hæmorrhage. Whipple calls attention to a proteose substance which may be produced and cause rapid and fatal toxæmia. These observations explain the clinical conditions that we find in the acute forms of pancreatitis. I have been much interested in the recent work of Watts and others in regard to acute pancreatitis and the necessity for direct procedures on the acutely inflamed pancreas. Our experience, however, leads me to take rather a conservative view and to content myself with the anterior abdominal approach to the pancreas and drainage of collections, septic or otherwise, as they occur, rather than to anticipate their occurrence by pancreatic incisions. It would appear that, as a result of our early postmortem knowledge and tragic experience with an occasional acute pancreatitis, we have been inclined to underestimate the ability of the tissues concerned to localize or cure a large number of the acute pancreatic inflammations.

Perforations of the duodenum into the free abdominal cavity are the most common of all types of acute perforations, but, fortunately, the duodenal content is more or less sterile, small in quantity, and has a tendency to gravitate into the region of the appendix. For this reason the preoperative diagnosis is often appendicitis, and a high percentage of patients make a spontaneous recovery from that particular attack. Not infrequently the appendix is removed showing evidences of peritonitis on its surface but without disease of the mucosa, and the true cause of the trouble is not discovered. The patients recover in most instances in spite of the removal of the appendix at an inopportune time, and later they have a recurrence of the duodenal trouble, eventually coming to operation for its cure. In nearly all of our earliest operations for acute perforations of the duodenum a negative exploration of the appendix was first made and the perforation of the duodenum was found during further exploration. It is fortunate indeed that an incision one inch to the right of the midline through the rectus muscle enables the surgeon to make a comprehensive examination of the appendix, gall bladder, pancreas, duodenum and stomach, and gives him ample opportunity to do whatever is necessary without regard to the preoperative diagnosis. We have operated on perforating duodenal ulcers in almost every stage of recovery. The duodenum is unusually well situated, anatomically, for the formation of protective adhesions to the gall bladder, gastrohepatic omentum, transverse colon, etc., which quickly limit the spread of the contamination, and after some hours of pain from protective peritonitis, there may be only muscular rigidity and localized pain to mark what was in the beginning a free perforation.

Whether or not a certain condition would be called free perforation might depend, to a large extent, on whether the operation is done in the first ten or twelve hours, before limiting adhesions are formed, or in the subacute or chronic stage when the perforation is closed by plastic lymph and the peritonitis has become limited. In a large number of cases of acute perforations in the stage of contamination or localized infection, we have operated in the first eight or ten hours, and recovery has nearly always occurred. The results, however, have been much less fortunate when the operations were done between 10 and 30 hours; a general spreading septic peritonitis quickly brings many of the patients to a condition in which an operation as a last resort

will probably be unsuccessful; a number, however, will, after 48 hours, be greatly improved and operation can be done safely. When it is possible to operate on an acute free perforation in the first 10 hours, not only will the perforation be closed and the contamination prevented from passing into a peritoneal infection, but a gastro-enterostomy may be done which means a cure of those conditions that depend on the ulcer and that probably would not have been cured by a mere closure.

What has been said about acute perforations in chronic ulcers of the duodenum applies to ulcers of the pyloric end of the stomach, and, to a considerable extent, to perforation of ulcers on its posterior wall. Perforations of the stomach are much less favorably situated than ulcers of the duodenum in relation to the prospects that the spread of contamination will be quickly limited by neighboring structures. The stomach often has a considerable quantity of contents, at the time of perforation, in a more or less septic condition as contrasted with the rather sterile duodenum, so that there is a greater prospect of an escape of a large amount of septic material into the area of the small intestine instead of gravitating, as from the duodenum, down through Morison's space in front of the right kidney to the iliac fossa. Ulcers of the posterior wall of the stomach frequently become adherent to the pancreas, and along the lesser curvature the gastrohepatic omentum is a good protection. Anterior perforations have a high mortality unless operated on early for the reasons I have outlined. Fortunately, free perforations of the stomach are the least common of all perforations.

SUMMARY.

1. It may be said that a considerable percentage of free perforations are spontaneously closed and that the area of peritonitis is limited through natural processes; the death rate is possibly about 30 per cent but the 70 per cent of patients who may recover spontaneously from the attack are not cured.

2. An exploration through a longitudinal incision just to the right of the midline gives the surgeon an opportunity to make a careful exploration and to deal with any or all varieties of perforation.

3. Early operation, that is within the first 8 hours, barring accident, means recovery, because the stage of contamination has not yet passed on to infective peritonitis, and measures may still be taken for the permanent cure of the condition which leads to the perforation.

4. Chronic conditions usually precede perforation and give ample warning of their presence before it takes place. While this is accepted, so far as the appendix is concerned, it has not been so generally recognized that gall stones are foreign bodies which need only infection to lead to the most widespread peritonitis, cholangitis, biliary cirrhosis and pancreatitis.

5. Chronic ulcers of the stomach and duodenum, after a reasonable attempt has been made at medical cure, should be looked on as surgical maladies.

TORSION OF THE GREAT OMENTUM DURING PREGNANCY

By J. L. BUBIS, M.D., Cleveland, Ohio
Assistant in Obstetrics, Mt. Sinai Hospital

TORSION of the great omentum, *per se*, is considered an infrequent pathological condition, only 131 cases having been reported in medical literature prior to 1914. I have found no report of its occurring during pregnancy. The following case is therefore reported:

Mrs. S., age 26, married two and a half years. The patient has had the usual diseases of childhood. She has never had any bowel trouble previous to her last pregnancy. Six months after her marriage, she had a four months' miscarriage following a fall, from which recovery was uneventful. Since then, her menstruation has been regular, lasting three days, with the usual amount of flow, and accompanied by very little pain. Fifteen months later she again became pregnant.

On March 2, 1916, examination at my office showed the following: Her heart and lungs were negative. There were no tender points on abdominal palpation, and pelvic measurements showed a male type pelvis. The uterus was found enlarged to the size of a four months' pregnancy. It was smooth, regular, movable, but pushed to the right side by a distended bladder. The other classical signs of pregnancy were also present. The urine was negative and the blood-pressure 110–76. She was feeling well and complained only of a slight constipation, for which liquid paraffin was prescribed.

On April 5, 1916, when she was about five months' pregnant, the patient came to my office complaining of slight abdominal distention, constipation, and some fullness in the right lower abdomen. Temperature, pulse and respiration were normal. An enema and aromatic cascara were prescribed.

April 7, 1916. She complained of an increasing tenderness just above the uterus about half way between the umbilicus and the right cornua of the uterus. A milk diet, rest in bed, and an enema were advised.

April 8, 1916. No relief was obtained from the above treatment. Temperature, pulse, and respiration were normal. An ice bag was then applied.

April 9, 1916. The pain at the tender spot was gradually increasing. There was no nausea or vomiting. The bowels were kept open with enemata. At 4 p. m. her temperature and pulse had risen to 99.1 and 110° respectively, and she complained of feeling "sick." The abdomen was regularly distended, the lower part being occupied by a five months' pregnant uterus which was distinctly palpable and easily outlined. Fœtal movements could be felt. No abdominal distention of the stomach or of the intestines was demonstrated, nowere peristaltic movements observed.

Along the anterior upper right surface of the uterus, extending almost in a straight line, from above downward, four small nodules could be palpated. There was slight abdominal rigidity but not in proportion to the severe pain caused by pressure on the tender spot described above. No definite mass was palpated, nor was there evidence of fluid in the flanks.

An operation was advised and accepted for the following reasons: the pain, temperature, and pulse were increasing and delay meant increased danger to mother and fœtus. Although no definite diagnosis could be made, the clinical history, the symptoms and progress of the case warranted an immediate exploratory examination.

The operation was performed under ether anæsthesia. A right rectus incision, three inches long, was made at the level of the umbilicus. After incising the peritoneum, a considerable amount of uncoagulated, bloody fluid escaped. A thickened discolored mass, slightly adherent to the posterior wall of the uterus and extending down to the cul-de-sac was then loosened and delivered through the incision. This proved to be the large omentum, swollen, œdematous, twisted a number of times on its long axis, and gangrenous at the lower part. The veins were swollen, enlarged and some contained blood-clots. The whole omentum was removed close to the transverse colon, after tying it off with interrupted plain catgut. A small, slightly adherent, firm appendix with its tip pointing upward and inward, was then removed. Section showed an obliterating appendix. There was also a marked Jackson's membrane present. On the upper, anterior surface of the uterus were four small fibroids ranging in size from one-half to one centimeter in diameter. The abdominal incision was closed in layers without drainage, and the patient was removed to her room in good condition. The convalescence was perfectly normal and the patient was out of bed at the end of two weeks.

The pregnancy progressed smoothly until July 23, 1916. The membranes ruptured about noon and labor pains began within an hour. At 7 p.m. the cervix was completely dilated, the labor pains were very strong and regular and occurring about every two minutes. The fœtal head was in the R. O. P. position. Under anæsthesia, the head was rotated to the R. O. A. position, and an eight months' fœtus was easily delivered with medium forceps. The child weighed six pounds four ounces. A normal, intact placenta and membranes were expelled fifteen minutes later. The uterus contracted

firmly and examination showed a second degree laceration of the perineal body. This was immediately repaired with No. 2 chromic catgut sutures. One drachm of the fluid extract of ergot was given when the patient awoke from the anæsthetic.

The next morning the patient complained of abdominal distention, pain, and inability to void. Examination showed the uterus enlarged, relaxed and extending up to the right costal margin. Vigorous uterine massage expressed two very large blood-clots and 500 cubic centimeters of urine. A firm abdominal binder was applied and 2 drachms of the fluid extract of ergot were given. No further trouble was encountered during the lying-in period.

January 9, 1917. Vaginal examination showed the uterus in good condition and freely movable. No nodules on the anterior surface of the uterus could be palpated. The patient was feeling very well and suffered no abdominal pains.

Causes. Some of the conditions which may give rise to torsion of the omentum are tuberculous peritonitis, hernias, malignancy, appendicitis, pelvic inflammation, adhesions, hæmorrhage within the abdomen (1), and accessory omentum which becomes strangulated by torsion (2). Sudden severe strain, increased peristalsis, forcible attempts at reduction of a hernia (3), are also mentioned as causes of this condition.

Mechanism. The following theories suggest possible explanations of the mechanism of this condition:

1. There may be a matting of the free extremity of the omentum into a ball which is easily rotated (8).

2. There may be a band of omentum adherent to the colon which acts as an axis (4).

3. The omentum may be made to roll or flow by the peristaltic movements of the intestines and by the unequal degree of pressure within the abdomen caused by the transit of gas through the intestinal loops (10).

4. The omentum may act like a semi-fluid body and forced by the unequal pressure, passes among the abdominal contents in the line of least resistance (10).

5. The twisting may be due to the fact that the overdistended veins of the omentum wrap themselves, and incidentally the omentum, about the shorter and stiffer arteries (11).

6. The omentum is compared to a handkerchief, folded triangularly, which is fastened at two corners, allowing the third to rotate (9).

Types. 1. Torsion of the omentum without a co-existing hernia, involving only the omentum or involving other adherent abdominal structures (1).

2. Torsion with a pre-existing hernia when there may be (a) intra-abdominal torsion involving the hernia strangulated or inflamed; (b) intra-abdominal torsion without involving the hernia; (c) omental torsion within the hernial sac only; (d) complicated cases in which there exists both intra-abdominal and hernial twisting of the omentum, or in which either intra-abdominal or intra-hernial torsion is associated with retrograde incarceration.

The amount of congestion or anæmia varies and may be accompanied by gangrene and even infection, which is generally from a hæmatogenous source. The gangrene is due to strangulation of the blood-vessels. Thrombi may also form from which emboli may be liberated and carried in the circulation to distant organs, especially the lungs.

Occurrence. In twelve cases reported (10), torsion of the omentum occurred seven times in the male and five in the female, the average age being 36 years. In five cases the entire omentum was involved. Ten of the cases were acute, one was chronic and no mention was made of the other.

Symptoms. 1. Pain is a constant symptom and is generally located in the right iliac region (5). However, it may also be referred to the epigastrium (7), to the posterior right kidney region, to the right hip, or the patient may complain of a slight uneasiness and bound-down sensation in the region of the appendix (2). It may also be a constant, dull, aching, localized pain in the lower abdomen. Neither rest in bed, bowel movements nor food have any effect on its severity.

2. Bowels. In a series of cases (6), it was found that two complained of diarrhœa, sixteen were reported as having normal bowel movements, eleven were constipated, and five passed flatus.

3. Nausea and vomiting. These are not constant symptoms. In the above series, they were present in 35.8 per cent and absent in 26.4 per cent. When present, however, they were frequent and violent, occasionally alternating with diarrhœa (7). At times, the

vomiting may even suggest obstruction of the bowels (1).

4. Temperature and pulse. In the early stage, before complications arise, the temperature and pulse may or may not be affected. The highest temperature recorded was 102° F. (2), and the highest pulse-rate was 120 (6).

5. Blood pressure and examinations have no special significance. Veitor's patient had 12000 white blood corpuscles of which 81 per cent were polymorphonuclear.

6. Headache and backache occasionally occur (1).

7. Prostration may be present (2).

8. Flushed face was also noted by Hale.

Clinical signs. A tumor was present in all but three of the cases (6). The margins were generally ill-defined and the tumor may extend from one and one-half inches below the costal margin to the crest of the right ilium (10), from the right kidney to the appendix region (2), or there may be a large swelling on the left side above the pubis, attached to the uterus and palpable through the vagina (12). In one case reported (5), no mass or hernia could be felt, but the whole right side of the abdomen extending to the median line was dull and flat on percussion.

Abdominal distention was noted in 13.2 per cent of the cases (6). Spasm of the abdominal muscles may be present (1). Ascites is rarely demonstrated.

Diagnosis. Bookman states that purely abdominal torsion of the great omentum cannot be diagnosed. There are no definite symptoms until sufficient torsion has occurred to interfere with the return circulation. However, in the absence of a hernia, the presence of a painful spot, which gradually increases in severity in the right side of the abdomen, the mildness of the symptoms in contradiction to the appendiceal or other serious intra-abdominal conditions, may point to the diagnosis. If, in addition to the above, there is an early or sudden appearance of an abdominal tumor with indefinite margins and dull on percussion, which is sensitive but not especially painful, or if there is a large resistant area, then a diagnosis of torsion of the omentum may be safely made.

Differential diagnosis. Some of the conditions which simulate torsion of the omentum are acute and chronic appendicitis, obstruction of the bowels, extra-uterine pregnancy, abdominal abscess, kidney stones, tumor of the mesentery, volvulous, mesenteric thrombi.

Prognosis. The prognosis is fairly good if an early operation is per ormed. The mortality and risk increases with the delay in diagnosis and operation.

Treatment. An operation should be performed as soon as a diagnosis is made. In the absence of a diagnosis, it is advisable to do an exploratory operation in cases where the symptoms point to an intra-abdominal condition which is getting worse.

The incision is made over the most prominent part of the tumor if there is one felt, or over the *spot* of tenderness. On opening the peritoneum, there is generally an escape of free fluid, of variable amount and color. It may vary from a serous, straw-colored fluid (2) to a dark blue suggesting an extra-uterine hæmorrhage. The mass is easily palpable and can be readily separated from the surrounding tissues. Hale describes a peculiar crepitant sensation which is felt when breaking up the light adhesions. In Veitor's case, the mass was blue-black in color and contained numerous pulsating arteries, and was twisted from right to left eight or nine t mes. In neglected cases necrosis or gangrene of the omentum will be found. It is best to remove the omentum close to the transverse colon, so as to prevent the extension of thrombi or the formation of abscesses of the omentum (3). The appendix should be removed at the same time and the abdomen closed in layers without drainage unless infection is present.

Complications. Infections, adhesions, thrombi and emboli are the most common complications. During pregnancy, the expulsion of the fœtus may occur.

COMMENT

There have been very few cases of intra-abdominal torsion of the omentum without a co-existing hernia. I have been unable to find any record of a successful operation for this condition during pregnancy.

The primary cause of the torsion of the great omentum in this case was probably an adhesion of the tip of the omentum to the cul-de-sac. The pressure from the growing uterus and the peristaltic action of the intestines together with the congestion of the veins of the great omentum were undoubtedly secondary causes of this condition. When the veins of the omentum become engorged and swollen, they tend to wrap themselves, and incidentally the omentum, about the shorter and stiffer arteries (11).

A localized point of tenderness, normal temperature, pulse and respiration, and the absence of nausea and vomiting in the early stages of pregnancy are a group of symptoms very suggestive of torsion of the great omentum.

BIBLIOGRAPHY.

1. Bookman, R. Am. J. Surg., 1915, xxix, 304.
2. Hale, K. J. Am. M. Ass., 1917, lxviii, 977.
3. Veitor, J. A. Med. Record, 1917, Jan., 172.
4. Noble, T. B. Am. J. Obst., N. Y., 1904, xlix, 364.
5. Wiener, J. Jr. Ann. Surg., Phil., 1900, xxxii, 648.
6. Corner, E. M. Am. J. M. Sc., 1905, cxxx, 314–29.
7. Cullen, T. C. Johns Hopkins Bull., 1905, xvi, 401; Am. J. Obst., N. Y., 1907, lxi, 799, case xii.
8. Richardson. Quoted in Am. J. Obst., N. Y., 1907, lxi, 799.
9. Lejars. Quoted in Am. J. Obst., N. Y., 1907, lxi, 799.
10. Am. J. Obst., N. Y., 1907, lxi, 799.
11. Payr. Quoted by Scudder, Am. J. Obst., N. Y., 1907, lxi, 799.
12. Riedel. Ibid.

DUODENECTOMY—ITS EFFECT UPON THE LIFE OF AN ANIMAL

Transplantation of the Pancreatic Duct[1]

By ERNEST G. GREY, M.D., Baltimore
From the Surgical Division of the Hunterian Laboratory, The Johns Hopkins University.

UNLIKE the stomach, jejunum, ileum, and colon, the duodenum has long been regarded as a most important organ in the human economy. Before the dawn of the modern surgical era, this view probably was fostered by the anatomical knowledge that the great digestive glands—the pancreas and the liver—discharge their respective secretions into this segment of the intestinal tract. More recently the shocking death rate attending the extirpation of duodenal cancers has worked to elicit respect for this organ, even from the surgeon.

Perhaps the greatest interest, however, was awakened in regard to the functions of the duodenum when Pflueger[2] linked this organ with the pancreas in his neurogenic theory of diabetes. Pflueger and his school, it will be recalled, contended, even up to the former's death, that a nerve mechanism in the wall of the duodenum governs the activity of the pancreas, in so far as its antidiabetic function is concerned, and accordingly, that extirpation of the duodenum causes diabetes. This conception, of course, lost recognition when Minkowski in[3] 1907 exhibited a dog apparently in good health with full carbohydrate tolerance from which the duodenum (together with the greater portion of the pancreas) had been extirpated four weeks previously. Subsequent to the demonstration the animal was again operated upon to remove the remaining fragment of pancreas. Five hours later sugar appeared in the urine and the dog became diabetic.

Pflueger's experiments, then, have served not only to demonstrate the absence of a duodenal control over the antidiabetic function of the pancreas but also to lessen our conception of the importance of the duodenum in the life of an animal. They do not, however, warrant any conclusion being drawn as to the remote effects of duodenectomy. Whether a duodenectomized animal will succumb in the course of a few months from inanition or other disturbances has remained an unsettled

[2] Pflueger. See Allen, Glycosuria and Diabetes. W. M. Leonard, 1913, p. 468.

[3] Minkowski. Totolextirpation des Duodenums. Deutsche med. Wchnschr., 1908, xxxiv, 45.

[1] Read before The Johns Hopkins Medical Society, January 7, 1918. Received for publication August 3, 1918.

question; and subsequent studies in this field have failed to settle the matter.

The reason for this becomes more or less obvious when one considers the anatomical relationships of the duodenum and the pancreas in the dog. The ducts of the pancreas emerge from the main portion of the gland which lies closely approximated to the duodenum. The pancreaticoduodenal vessels lie between the two organs. When the duodenum is resected not only is the blood supply of the pancreas greatly affected but the ducts are severed as well. It is these conditions which have made it necessary—in all of the experiments recorded—to extirpate the greater portion of the pancreas along with the segment of intestine.

The problem connected with the biliary tract has been met successfully by diverting the bile into the intestine (cholecystenterostomy). The problem of pancreatic digestion, on the other hand, still awaits solution since in Pflueger's experiments and in those subsequently recorded, the supply of pancreatic juice had been withdrawn permanently from the intestines.

In order to determine then whether the presence of the duodenum is essential to the continued good health of a dog it will be necessary to devise a surgical technique by means of which (1) the pancreas may be left intact with an unimpaired blood supply, and (2) the pancreatic secretion may be discharged into the digestive tract. It is with these problems that the experiments detailed in this report are concerned.

In the course of some work [1] having to do with the effects of pancreatic juice upon the level of gastric acidity, the major pancreatic duct with a small segment of neighboring duodenum was successfully transplanted into the gastric wall. As the study progressed it became desirable to resect the greater portion of the duodenum in order that the pancreas might be left with but one channel of communication with the digestive tract; namely, the major duct opening into the stomach. A review of the literature, however, revealed no investigations in which these experimental conditions had been met. From these considerations it is evident how what at first appeared to be merely a subsidiary phase of the work on gastric acidity, subsequently developed into a separate problem.

[1] Grey. The diversion of the pancreatic juice from the duodenum into the stomach. Its effects upon the level of gastric acidity and upon the pancreas. J. Exp. Med., 1917, xxvi, 825.

LITERATURE

In 1907 Minkowski[2] extirpated the entire duodenum. This was the first successful duodenectomy experiment recorded. Together with the duodenum, Minkowski excised the greater part of the pancreas, that is, the main body of the gland, including the pancreatic ducts, which lies adjacent to the intestine. The bile stream was diverted into the jejunum by means of a cholecystenterostomy. A gastro-enterostomy re-established the channel of communication between the stomach and the upper intestine. Subsequent to the operation the dog was lively and displayed a marked voraciousness. Sugar appeared in the urine only in the specimens secured immediately after the operation. A rich carbohydrate diet later led to no glycosuria. As mentioned in a preceding paragraph the dog was observed under these conditions for but four weeks, as this was regarded as a sufficient interval to establish Minkowski's contention that extirpation of the duodenum does not lead to the development of the diabetic state.

Bickel,[3] in 1909, reported the successful extirpation of the duodenum in two dogs, one of which survived for 10 days and the other for a period of 4½ weeks. In these experiments the pylorus was closed and a gastro-enterostomy performed. The common opening of the ductus choledochus and the major pancreatic duct were sewed into the skin. As it is practically impossible to carry out the latter procedure without preserving some of the mucosa adjacent to the papilla of Vater, it is questionable whether Bickel's experiments should be accepted as representing complete duodenectomies.

Bickel refers to some studies of Katzenstein carried out in his laboratory which indicate that the duodenal mucosa, when it is sutured into the gastric wall, is al-

[2] Minkowski. Loc. cit.

[3] Bickel. Beobachtungen an Hunden mit extirpiertem Duodenum. Berl. klin. Wchnschr., 1909, xlvi, 1201.

ways digested, even in the presence of a good blood supply. To these findings I must take exception since in some experiments, the results of which have already been published,[1] I noted duodenal transplants in the wall of the stomach in a healthy state of preservation many months subsequent to the operations. Mann[2] apparently has had much the same experience with jejunal transplants.

In his report of some experimental work on the upper intestine in 1910, Matthews[3] makes the statement that total extirpation of the duodenum is incompatible with life longer than 72 hours. Matthews, it would appear, was not familiar with the classical experiments of Minkowski. His findings, nevertheless, serve to emphasize the difficulties which one encounters in attempting a resection of this portion of the intestinal tract.

In 1912 Stone, Bernheim and Whipple[4] reported the results of some investigations with closed duodenal loops. The duodenum was divided just distal to the entrance of the major pancreatic duct, and again at the beginning of the jejunum. This afforded an isolated loop from 12 to 15 centimeters in length. From a number of dogs such a loop was resected. Of the latter group one animal lived for a period of 8 weeks. The investigators concluded from this experiment that the part of the digestive tract included in the loop is not essential to life.

Stassoff,[5] in 1914, published some interesting studies on intestinal compensation following the resection of different portions of the alimentary tract. While success attended his efforts to remove segments of the stomach, jejunum, ileum, and colon, all his attempts to resect the entire duodenum and transplant the bile and pancreatic ducts into the jejunum were without result. He alludes in detail to the various hypotheses found in the literature which have been advanced to explain the fatal results attending duodenectomy experiments. Bickel's[6] two duodenectomized dogs which succumbed 10 days and 4½ weeks respectively after the operation are cited. Stassoff concludes that the reason why animals cannot survive a duodenal resection for any appreciable length of time lies in the fact that the stomach and remaining intestine are unable to compensate fully for this portion of the alimentary tract. Gastric and jejunal digestive activities may for a short time, he thinks, compensate for the loss of the duodenum.

[1] Grey. Loc. cit.

[2] Mann. Effect on jejunal mucosa of exposure to gastric juice. J. M. Research, 1917, xxxv, 289.

[3] Matthews. One of the functions of the duodenum. J. Am.M.Ass., 1910, lv, 293.

[4] Stone, Bernheim, and Whipple. Intestinal obstruction: a study of the toxic factors. Bull. Johns Hopkins Hosp., 1912, xxiii, 159.

[5] Stassoff. Experimentelle Untersuchungen ueber die kompensatorischen Vorgaenge bei Darmresektionen. Beitr. z. klin. Chir., 1914, lxxxix, 527.

METHODS AND RESULTS

The results of the first few experiments sufficed to make it clear that a successful extirpation of the duodenum would depend upon the solution of three main problems, viz.: (1) the resection of the duodenum without embarrassing the blood supply of the pancreas, (2) the transplantation of the major pancreatic duct into the jejunum, (3) and the management of the operation whereby all of the reconstructive steps might be accomplished without sacrificing the life of the animal. It took some time to develop each of these steps in turn.

The first problem which concerns the blood supply of the pancreas, was met by excising the duodenum in such a manner that a narrow strip of the muscle fibers, through which the branches of the pancreaticoduodenal vessels enter the bowel, is left attached to the blood-vessels. As the main artery and vein become separated from the intestine where the tail of the pancreas bends away from the bowel, the ligation and division of the vessels supplying the distal portion of the duodenum is easily accomplished. Opposite to the body of the gland, however, it is necessary to make two incisions into the outer layer of muscle cells in the duodenal wall, in a direction parallel to the long axis of the latter and close to the peritoneal reflexions over the pancreas. A delicate sheet of muscle cells is then stripped back from the bowel between the two cuts, dividing, as the dissection continues, the branches entering the wall from the adjoining pancreaticoduodenal vessels. These branches are temporarily secured with delicate clamps.

[6] Loc. cit.

Subsequent to the resection the larger bleeders are ligated. Hæmostasis is chiefly accomplished, however, by drawing together the fragments of remaining muscle tissue with a continuous stitch of fine silk. After a little practice this procedure may be accomplished without either opening the lumen of the bowel or leaving behind the smallest trace of mucosa, and without in any way interfering with the blood supply of the pancreas.

While the principal object of this research has been to excise the duodenal mucosa in its entirety, it is clear that with the technique just described, practically all of the coats are removed, since the remaining muscular tissue is so fragmented that, at the most, only scattered nerve cells may be left behind. The question of the significance of a duodenal nerve plexus, so far as it affects the antidiabetic function of the pancreas, of course was practically settled by Minkowski.[1] Leaving this aside the function of the duodenum is strictly of a digestive nature. It is concerned with three factors: the influences which are exerted upon other parts of the digestive tract by means either of reflexes or of hormones, the digestive juices which enter it from the liver and the pancreas, and the secretion which is poured out from the intrinsic glands. All of these factors are inextricably bound up with the mucous coat.

The second problem, namely the transplantation of the major pancreatic duct into the jejunum, was successfully solved by using the following technique: After locating the duct, which lies between 2 and 3 centimeters proximal to the line of transition between the body and the tail of the pancreas, the adjoining gland for a distance of about a centimeter on all sides of the duct is gently stripped back from the duodenal wall. The gland, however, is not opened to expose any of the intrapancreatic portion of the duct. The muscular coat is now split and the duct freed down to its implantation into the mucosa. At this level it is divided flush with the outer surface of the latter. In this way no fragments of mucous membrane are left attached to it. This affords an extrapancreatic duct which measures approximately 5 to 8 millimeters in length.

[1] Minkowski. Loc. cit.

At this stage an appropriate loop of upper jejunum is approximated to the pancreas. The jejunum here must lie comfortably without causing any proximal or distal kinking and it must exert no tension on the adjoining gland. A small puncture wound is made in the jejunal wall facing the pancreas through which the duct is introduced into the lumen of the bowel. This step is facilitated by carrying the tip of a delicate needle threaded with silk into the lumen about 1½ centimeters distal to the puncture wound and bringing it out again through the latter. The thread is then attached to the end of the duct. When traction is made upon the thread the duct enters the lumen and the tip is drawn distalward in the intestine. At this time the thread is cut flush with the surface of the bowel. Fine stitches are placed so as to tack the pancreas surrounding the duct to the intestinal wall. The suture line is covered with omentum.

When animals which are otherwise normal are operated upon in this manner they continue in good health. In certain instances, however, ulcers develop, due undoubtedly to the absence of the alkaline pancreatic juice in this segment of the intestine. The occurrence of peptic ulcerations, of course, has no significance so far as the success of the transplantation itself is concerned.

Subsequent examination shows a natural appearing pancreas free, so far as can be ascertained by palpation, from any sclerotic process. Histological study corroborates this impression and discloses a normal looking gland. The gross architecture is best understood by referring to the accompanying photograph which pictures a specimen secured by sacrificing an animal 6 months after the duct had been transplanted. The portion of the duct which was left free in the intestinal lumen at the time of the operation has disappeared—presumbly a long time back. At the line of transition between the duct and the intestinal mucosa there is a very small circular fold of mucous membrane which serves to protect the former from the contents of the bowel. The duct at its termination here is very narrow, and when sought for, it is found with difficulty. Distal to the wall of the bowel, however, there is a dilatation of the duct, most

marked in the portion which traverses the body of the gland.

Patrie, Pyle and Vale [1] have recently described a technique for re-establishing a connection between the pancreatic ducts and the intestine somewhat similar to that just outlined. Apparently they were at work on this problem at approximately the time these experiments were underway. While the details of their method differ to a certain extent from those used here, their results, nevertheless, serve to emphasize the theme of the preceding paragraph, viz., that the pancreatic duct may be made to function satisfactorily when it is transplanted to another segment of the intestinal tract.

After the duodenum has been resected the continuity of the gastro-intestinal tract, of course, may be re-established by means either of a gastro-enterostomy or an end-to-end suture at the pylorus. In the experiments referred to here the latter method was used; that is, the end of the proximal jejunum was anastomosed to the open end of the stomach. To insure the complete removal of the duodenum a ring of gastric wall about 1 centimeter wide at the pyloric sphincter was excised, as well as 3 or 4 centimeters of the first portion of the jejunum.

Two methods also were available for dealing with the biliary supply to the digestive tract, viz., a cholecystenterostomy and a cholecystgastrostomy. Preference was given to the former procedure though it was shown in some earlier experiments [2] that all of the bile may be diverted permanently into the stomach without in any recognizable way affecting the health and nutrition of the animal.

The third problem concerns the general plan of attack, so far as the various operative steps are concerned. Upon this, perhaps, as much as upon any of the other features, depends the success or failure of the undertaking. The experiences of other investigators in this field, as well as the results of surgeons who have attempted duodenal resections in human cases, indicate most clearly the seriousness of any operation having to do with the proximal duodenum. Aside from any of the plastic or reconstructive steps, the resection simply of this portion of the intestine is conducive to cardiovascular and other changes which suggest or really constitute a state of shock. To undertake, then, in one operation a transplantation of the pancreatic duct and a suture of the gall-bladder subsequent to a duodenectomy is to exceed the limits of physiological reaction.

For this reason the operation was divided into three stages, leaving an interval of a number of weeks between each two steps. In the first stage the common duct was identified and divided between ligatures. The gall-bladder was then anastomosed to the proximal jejunum. After the animals had fully recovered and apparently were in good health the second step was undertaken. This consisted of a transplantation of the major pancreatic duct—also into the proximal jejunum—following the plan outlined in another section of this report. At the same time, the lesser pancreatic duct, which enters the intestine at the papilla of Vater, was dissected out and divided between ligatures. Practically the entire output of pancreatic juice was thus diverted from the duodenum into the upper jejunum.

In the concluding state of the series the duodenum was resected. The surgical difficulties encountered at this time were not inconsiderable since the proximal jejunum was adherent both to the pancreas and to the gall-bladder. Where care had been exercised, however, in the first and second stages in selecting the proper jejunal sites for the reception of the gall-bladder and the pancreatic duct, it was possible in the concluding operation to anastomose the upper end of the jejunum to the stomach.

This investigation was started in the fall of 1916. As a result of the first or the second operation many of the animals succumbed, some to distemper, others to pneumonia. Four recovered from the effects of the second stage and appeared to be in excellent condition. Of this number, however, two subsequently died from an acute peritonitis before it was considered advisable to attempt the duodenal resection. Postmortem examination, in each of these cases, disclosed a per-

[1] Patrie, Pyle and Vale. Recent experimental studies on the pancreas. Surg., Gynec. & Obst., 1917, xxiv, 479.

[2] Grey. Loc. cit.

forated peptic ulcer (in the distal duodenum in one animal, and in the first inch of the jejunum above the transplanted pancreatic duct in the other) which owed its inception, undoubtedly, to the absence of the strongly alkaline pancreatic juice from this segment of the intestine. A third dog died at the time of the concluding operation, apparently from shock.

The fourth animal, which furnishes the basis for this report, withstood the third stage well and was active and hungry on the day following the operation. Eight and one-half months later it was shown before a medical society, and at that time appeared to be in perfect health. Five weeks subsequent to this the dog died rather suddenly having shown symptoms of an acute intestinal complication. At necropsy the jejunum, about 3 centimeters distal to the line of the gastrojejunal anastomosis, was found to be collapsed and kinked by a peritoneal band which extended across it from the mesentery below to the under surface of the liver on the opposite side. Immediately above this area the intestine was considerably distended. Except for the changes incident to the obstruction, nothing abnormal was made out in the abdomen. Both the cholecystenterostomy wound and the transplanted pancreatic duct had healed perfectly. There were no discernible changes in the pancreas. Had there been no accidental complication of this nature it seems fair to assume that the animal would have continued to live in good health.

A careful consideration now of the experimental results of the series as a whole reveals nothing which would indicate that an animal prepared in this way might not live for many years. Certainly there is reason for but little doubt that had there been better facilities at hand for caring for the dogs, a much higher percentage might have been carried successfully through the three stages of the operation.

As regards the observations made on this dog, the following points may be mentioned: Sugar was never found in any of the specimens of urine obtained either shortly after the resection of the duodenum or in the course of the subsequent months. The appetite was good, in fact above the average, at all times. While

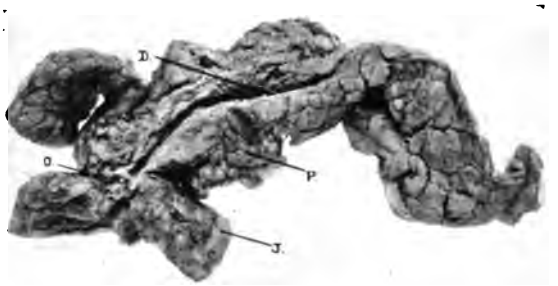

Fig. 1. Specimen showing an anastomosis between the major pancreatic duct and the jejunum. From a dog sacrificed six months after the operation. *P*, pancreas; *J*, jejunum; *D*, major pancreatic duct; *O*, opening of duct into intestine.

the stools were never examined microscopically, they were not unusual in appearance, being formed and of the usual color.

The dog was very active, perhaps unusually so, throughout the 9½ months of observation. This fact probably explains why the animal did not put on more weight. It was a rather small mongrel terrier weighing at the time of the first operation approximately 16¾ pounds. The dog was not quite full grown. Two weeks subsequent to the duodenectomy, which was carried out 7 weeks after the preliminary cholecystenterostomy, it weighed 16¼ pounds. In the course of the following 9½ months it gained 6 ounces.

In certain preliminary experiments, mentioned in another place,[1] the major pancreatic duct together with a small segment of duodenum was transplanted into the gastric wall. Two additional stages were used to accomplish an anastomosis between the gall-bladder and the stomach, and the resection of the duodenum. Each of the animals prepared in this way showed a marked and progressive disturbance of nutrition and succumbed in about 5 weeks (subsequent to the duodenectomy). This picture, one of inanition, of course affords unmistakable evidence of a great disturbance in the digestive processes at work in the stomach and intestines. A gastritis, rather advanced in degree, probably also contributed to the animals' condition. Nothing similar to this syndrome was noticed, either clinically or at necropsy, in the course of the experiments reported at this time.

[1] Grey. Loc. cit.

SUMMARY AND CONCLUSIONS

From the results of the experiments outlined above, certain definite conclusions may be drawn. In the first place they demonstrate that, so far as the surgical technique is concerned, the major pancreatic duct can be transplanted successfully into the jejunum. Many months subsequent to this operation nothing abnormal is made out in the microscopical or the gross architecture of the pancreas except a dilatation of the duct, most apparent in the third proximal to the intestine. The ostium at the lumen of the bowel remains patent.

It is evident, in the second place, that both the biliary and the pancreatic secretions may be successfully diverted from the duodenum into the upper jejunum. The withdrawal of these alkaline juices from the duodenum must profoundly affect the chemistry of duodenal digestion, since peptic ulcers not unfrequently develop here under such conditions. The subsequent resection of the duodenum and the suture of the jejunum (which now receives the pancreatic juice) to the stomach eliminates his complication. Upon the re-establishment of channels of communication between the liver and pancreas, and the gastro-intestinal tract, of course, depends the character of the nutrition of the animal since serious disturbances in intestinal digestion arise in the absence of the secretions from these glands.

The third point concerns the blood-vessels of the pancreas. It is apparent from the protocol of the duodenectomized animal that it is possible to resect the duodenum—every trace of mucosa and approximately all of the muscular coats—without embarrassing the vascular supply of the adjacent pancreas. This accomplishment does away with the necessity of excising the greater portion of the gland, a recourse to which Minkowski was forced to turn when he sacrificed the pancreaticoduodenal vessels with the duodenum.

A fourth conclusion may be advanced, concerning the plan of the various operative steps. The results of the experimental work outlined above have demonstrated that success can only be looked for in excising the duodenum and carrying out the reconstructive steps when the operation is divided into a number of stages, leaving an interval of several weeks at least between the successive steps of the procedure.

Finally, regarding the importance of the duodenum to the life of an animal the following conclusions may be drawn: Minkowski's experiments sufficed to establish the fact that the resection of the duodenum, per se, has nothing to do with the development of diabetes. The experiments reported at this time afford indisputable evidence that the presence of the duodenum is not essential to the life and comparative good health of a dog, at least for 9½ months, provided that the pancreas and the liver continue actively to discharge their respective secretions into the gastro-intestinal tract. Since the animal reported here succumbed in the end to a complication which has nothing to do with the operative measures suggested, or with the loss of the duodenum, it seems fair to assume that with a large series of animals, working under favorable conditions, a few would live for a much longer period of time. From these considerations, then, it is evident that the conclusions of Stassoff regarding the inability of the remaining gastro-intestinal tract to compensate for the loss of the duodenum are not substantiated by experiment.

THE MESODERMAL MIXED TUMORS OF THE UTERUS

Report of a Case of Botrioid Chondrosarcoma of the Endometrium

By ISIDOR PERLSTEIN, M.D., Chicago
From the Nelson Morris Memorial Institute for Medical Research and the Pathological Laboratory of Michael Reese Hospital

MIXED tumors occur more frequently in the urogenital tract than in any other portion of the human body. In the female genital organs they are quite frequently found in the ovary (dermoid, teratoma.).

They are of rare occurrence in the vagina, the cervix, and corpus uteri, and when they occur in these places, their heterogeneous components are nearly always of mesodermal origin (smooth muscle and cartilage). In the majority of cases, but not always, these growths have a grape-like structure and Pfannenstiel (31) called them "grape-like sarcoma," in a paper of 1892, entitled "*das traubige Sarcom des Cervix Uteri*," assuming that they did not occur in the corpus.

Although this class of neoplasm is very rarely found in the body of the uterus, a number of cases have been reported. In the American medical literature are found reports of two cases of uterine mixed tumors which contain striped muscle, reported by Robertson (37) and by Herb (11), but there has been recorded in this country no tumor of the uterus which contains cartilage as a heterogeneous component. On account of their rare occurrence, of their pathological interest and their clinical importance, I wish to report a new case of this type, a chondrosarcoma of the corpus uteri, originating in the endometrium.

Clinical history. Mrs. O., Hospital No. 97900, age 54, was admitted to the Michael Reese Hospital on May 8, 1917, as a private patient of J. B. De Lee, to whom I am indebted for permission to publish the case. On admission the patient complained of pain in the lower part of the abdomen, backache, headache, and vaginal discharge.

The family history is negative. There is no tuberculosis, syphilis, lues, diabetes, heart or kidney disease in the family.

Past history. The patient was born in Russia. She never had any serious illness except "typhoid malaria" at the age of 45, but she has never been very strong. Her family life was not a happy one. She is separated from her husband who maltreated her. She has always been a hard working woman, who took care of a large family and lived in poor financial circumstances.

Obstetrical history. The patient married at the age of 17. From that time up to the time of the last operation she has had leucorrhœa. Her menstruation has always been regular, every four weeks, moderate in amount and not painful. She has had twelve full-term pregnancies and one miscarriage which terminated her first pregnancy. Ten of her children are living and well.

Present illness. Her main complaint is profuse bleeding from the vagina at irregular intervals. Although she is 54 years old, she states that she is still menstruating. She takes the irregular profuse bleeding as a sign of "change of life." Up to the age of 52 her menstruation as a whole had been regular and normal. The first time she did not menstruate regularly after the birth of her last child was in September, 1911. She went then for seven weeks without menstruating and thought she was pregnant. In November, 1911, she had difficulty in urination for about one week. She did not urinate for one day at all, and when she commenced to urinate she had a bloody discharge from the vagina which continued off and on for 6 to 7 weeks. When she exerted herself the flow increased. On December 15, 1911, she had a hæmorrhage from the vagina and passed a large dark red piece of tissue of the size of a fist which looked like "rank liver." This was taken by her doctor and examined. The doctor performed a curettage and advised an "operation" (patient did not state what kind of an operation) which was refused. Then the menstruation was regular. For the last one- and one-half years it has been irregular and profuse. She would not menstruate for 3 months or 14 weeks, but when she menstruated, it lasted for a period of 18 to 21 days, and she lost much blood. In December, 1916, she flowed for about 24 days and then had a hæmorrhage. H. Ehrenfest, St. Louis, performed a curettage on January 11, 1917. She was in the hospital for 2 weeks and did not menstruate for 7 weeks after that. Since then she has had irregular bleeding. She has lost a large amount of blood. The slightest excitement would cause heavy bleeding. After the operation on January 11, 1917, she had several X-ray treatments. The patient has had backache and pain in the lower abdomen for the last one and one-half years since the bleeding started. It is of a burning character, and she has a dragging down feeling. Her headache has been present most of

the time for many years. Her leucorrhœa has not increased of late years and the discharge was not of a bad odor.

The physical examination did not reveal any pathological conditions as regards the thoracic and abdominal organs. A vaginal hysterectomy was performed on May 11, 1917. In making a digital examination De Lee removed a handful of tumor masses coming from the dilated cervix which according to his description at that time felt like "boiled sago." The patient recovered from the operation and was discharged on June 10, 1917.

Since her discharge she has been under the care of Leon Bloch, to whom I wish to express my thanks for his courtesy in helping me get the clinical history. She has made a good postoperative recovery. Her hæmoglobin has increased; she has gained in weight and looks well. She has no complaint except for some pain in the pelvis off and on. The patient was seen by me in December. No tumor masses could be felt at that time. She has had no vaginal discharge or bleeding since her operation.

Pathological report; description of gross specimen. The specimen is pear shaped. It measures from fundus to external os 11 centimeters. The corpus, which is somewhat spherical in shape, measures 11 centimeters in width when the uterus is laid open. The cervix is soft and patulous and closed by black silk sutures. When the sutures are cut, some soft and brittle tumor masses are seen extending to the external os. The cervix is markedly dilated. The serosa is smooth, glistening, and without adhesions. The uterus is opened by a sagittal section through the anterior uterine wall. The myometrium is soft and flabby. The uterine cavity is filled by a tumor mass which is partly polypoid and partly grapelike and attached mainly to the posterior wall of the corpus (Fig. 1.) The site of insertion of the tumor extends somewhat around the sides, involving a small portion of the anterior wall. The area of attachment reaches to within 3 centimeters from the lowest portion of the cervix. In the lower portion and on both sides the tumor masses overlap the area of insertion. The latter measures 5x5 centimeters while the tumor masses are 10 centimeters long and 6 centimeters wide. They hang down to the external os. The thickness of the tumor varies from a few millimeters in the peripheral portion to 2 centimeters in the central portion. It cannot be determined on gross examination if the growth is confined to the corpus, or if the cervix is involved too, for the boundary between corpus and cervix cannot be recognized on account of the marked dilatation of the entire cervix. But the growth stops rather suddenly 3 centimeters from the lowest portion of the cervix. The inner surface of the latter is uneven and shows irregular depressions and elevations, probably due to old scars, as can be expected in a XIII-para, but its surface is smooth. There are no areas of ulceration or polyps on it. The posterior wall of the cervix is thickened in its upper portion and firm. It measures 2.7 centimeters in thickness, while the anterior wall is only 1.3 centimeters thick. The latter is of a softer consistency.

The myometrium of the corpus is yellowish-red in color and measures 1.8 centimeters in thickness in the anterior wall, while the posterior wall beneath the growth is 3 centimeters thick.

The growth is macroscopically well defined from the underlying myometrium by its darker color. It forms polypoid excrescences of different shape and size which project into the uterine cavity. In places, especially in the left and in the upper portion it has a grapelike appearance and some similarity to an hydatidiform mole. Due to its irregular shape it is difficult to give a mental picture of this growth by description. Projecting from the upper posterior portion of the wall of the uterine cavity are several polypoid excrescences which are studded with minute villous projections, and here are also several "berries" which are sessile or attached by small, thin pedicles. The cores of these excrescences are of fair firmness, while the villous projections are of a softer consistency. The "berries" are round or oval in shape. They measured in the fresh specimen up to 1 centimeter in diameter, while on the preserved specimen they are somewhat shrunken. When fresh they were seen to be covered by a glistening, shiny membrane in which prominent, small, bright red vessels were branching and standing out very distinctly on the surface. The color of these berries was yellow like fat. They were found to be soft and gelatinous in the fresh specimen, and when incised some yellowish fluid exuded from the cut surface. From the upper excrescences several strands come off which meet and are attached to a polypoid projection somewhat farther down. They form a kind of network on the surface of the growth. From this network a pendulous structure hangs down by a thin cord which measures 1 to 2 millimeters in diameter. This structure is 6 centimeters long. To the thin cord are attached three berries; the upper two are dark red and hæmorrhagic, and the lower one, attached to the end of the cord, is 2 centimeters long, and reaches down to the external os. It is firm, brittle, without any elasticity, and pieces can easily be broken off from it. Its surface is irregular. By deep clefts, which extend down to the end of the cord, it is divided into three unequal portions. From the middle and especially from the right side of the posterior wall some dark red hæmorrhagic irregular, ragged and necrotic looking polypi hang down. The largest of these is 3 centimeters long. The continuous hæmorrhage probably came from these necrotic, polypous growths. At the peripheral portion, especially on the right side, are numerous minute, villous projections which measure up to a few millimeters in length. Some of these are club-shaped. In the region of the fundus the myometrium of the anterior wall is diffusely thickened. It measures here 3.5 centimeters in thickness.

There are in the container also numerous small berries and pieces of the growth which were removed

Fig. 1. Photograph of the specimen after it had been hardened in formalin. It is laid open by a median longitudinal section through the anterior wall and shows the polypoid tumor masses on the posterior wall of the uterus. In the upper portion and on the left side of the posterior wall a number of berries are seen. On the right side and in the center are several large irregular-shaped polyps. In the dilated cervix is a pendulous berry divided by deep clefts into three portions and attached by a long thin pedicle. The myometrium is thickened, especially in the right upper portion.

Fig. 2. A longitudinal section from one of the very small villous projections and a portion of a second one. It is coverd by the endometrial epithelium. The light colored areas are composed of loose connective tissue which is myxomatous in appearance, described by Wilms as undifferentiated embryonal tissue. The dark colored areas scattered about in this tissue are foci of small round cells, from which the cartilage originates. In the small focus of round cells near the upper left border a beginning of cartilage formation is observed. The slight amount of opaque intercellular ground substance deposited in it produces a lighter color of the central portion. The perichondrium has also commenced to form.

before the hysterectomy was performed. De Lee removed them manually and stated during the operation that they felt like "boiled sago."

Microscopic description. The most conspicuous feature in the microscopical appearance is the large amount of cartilage, which in a large number of the sections is the predominating tissue, and which is found in practically every section taken from the larger polypi and berries, but which is also present in the many smaller ones and even in some of the very small, villous projections. The internal surface of the tumor is covered by endometrial epithelium, which is present only in the smaller polypi and berries (Fig. 2).

The islands of cartilage are oval, round or crescent-shaped. They are surrounded by a layer of spindle cells with deeply blue stained, closely placed nuclei, the perichondrium, which is rather thick in most islands. Around some of the smaller ones these cells are heaped up and go over gradually into cartilage cells. The perichondrium of the larger islands is often thinner, less deeply stained and less conspicuous.

The cartilage is made up of rather closely placed, deeply stained round nuclei which are deposited in a homogeneous ground substance. In the older and large cartilage islands the intercellular substance is stained light purplish, in the younger and smaller islands it is stained light eosin. Cell boundaries of the cartilage cells cannot be made out as a rule, and no capsules can be recognized, but by close observation with the higher power lens in some of the purplish stained areas cell boundaries can be seen, the cells being round or oval in shape and the nuclei in places are surrounded by faintly stained or unstained areas, suggesting the formation of capsules. However, no definite capsules are present, and the cells contain not more than one nucleus each. The eosin stained ground substance, the absence of capsules and the cellular perichondrium are evidence that this is cartilage in an early stage of development. We see this kind of cartilage in the bronchi of lung-sections from autopsies of premature or newborn babies. In some sections, especially in those from the larger, brittle polypi and "berries," by far the largest portion of the tissue is cartilage. These areas are made up of cartilage islands which have grown together, as can be seen by the perichondrium which separates them (Fig. 3). Frequently these cartilage islands are separated by a tissue, composed of deep blue stained, closely placed spindle cells which look like endometrial

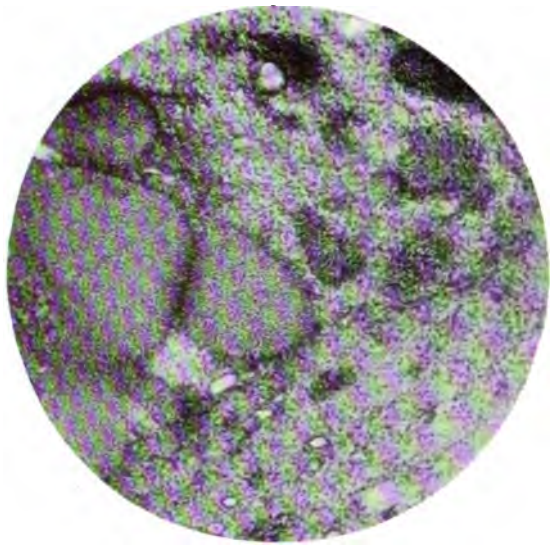

Fig. 3. A section from one of the small well preserved berries, shows a group of distinct, well-developed cartilage islands. Here also foci of small round cells are present, several of which are in a state of transition to cartilage. The young cartilage island in the left upper corner has a very thick perichondrium. The focus of small round cells near the central upper border is placed near an atrophic endometrial gland. Between the islands of cartilage and small round cells is undifferentiated embryonal tissue.

tissue. The cartilage tissue is rather poorly supplied by blood-vessels. In some places are seen thin walled blood-vessels, surrounded only by endothelium and cartilage, and in other places the cartilage encloses a tissue which is of the same character as that making up the larger portion of the tissue between the cartilage areas.

The tissue which intervenes between the cartilage islands is of different appearance in different places. In most places it is composed of widely separated cells with an intercellular substance which is granular, very faintly eosin stained or unstained. The nuclei of this type of tissue are mostly round or oval, and the cell bodies have long protoplasmic processes which give the cell a triangular or star shaped appearance. The protoplasmic processes of one cell frequently meet those of the other cells and produce thus a kind of network. Since the acetic acid test for mucin was not done in the fresh specimen I am not able to decide if this is myxomatous or œdematous tissue.

The density of this tissue varies in different places. There are gradual transitions to areas in which the cells are very closely placed, so that the nuclei which are round or oval, and deeply stained, come close together, and no cell boundaries and hardly any protoplasm are seen. In these areas the tissue has a sarcomatous appearance (Fig. 4). Where the cells are less dense, they are seen to have protoplasmic processes and look like young connective-tissue cells.

Scattered through the myxomatous (?) tissue are small accumulations of round cells which look like and are of the size of lymphocytes. They have been described by some observers, as Seydel, as embryonic cells and are said by him to originate by the heaping up of the myxomatous cells. They are seen in Figure 2. It is obvious from our sections that the cartilage must have originated from these foci of round cells, for one sees all stages of transition from these accumulated round cells to definite cartilage islands, and in some of these foci which contain a beginning of deposition of homogeneous intercellular substance, one is in doubt if the tissue is to be called cartilage or not (Figs. 2 and 3).

The tissue intervening between the cartilage islands is very vascular. The vessels are thin-walled. Many have only an endothelial wall. There are also many large dilated lymph spaces.

Scattered through the tissue are few isolated glands of the endometrial type. Their epithelium is low. Some are distended. They do not have the appearance of proliferation, but rather of atrophy. Their presence is an indication of the endometrial origin of the growth. No cervical glands are present in any of the sections of the tumor.

In sections through the deeper portions of the tumor there is endometrial stroma with spindle-shaped nuclei which are very close together and dark blue stained. There are practically no glands in the stroma. This layer is very thick, and it is difficult to decide if we have to deal here with a hypertrophy of the endometrial stroma, or if this tissue is to be regarded as sarcomatous.

The line of demarcation between the growth and the uterine muscle is rather sharp. Nowhere is the tumor tissue seen to infiltrate deeply into the myometrium. In several places some areas of tumor cells are seen beneath the superficial smooth muscle bundles, as in Figure 5.

In sections through the lower border of the tumor, which include cervical tissue, the cervix is in a state of chronic inflammation; the connective tissue is increased; there are numerous small blood-vessels; and the cervical mucosa is atrophic and thin. No tumor tissue is seen between or underneath the cervical glands and no cervical glands are present in the tumor tissue, so that we have to consider this growth as being confined to the corpus uteri.

The tissue through the diffusely-thickened area in the posterior wall has under the microscope the usual appearance of myometrial tissue. A section through the anterior wall of the body of the uterus shows that the endometrium is thin and atrophic.

Composition of tumor. It is evident that this growth is a chondrosarcoma of the endometrium of the corpus uteri. Two kinds of tissue are predominating; namely, cartilage

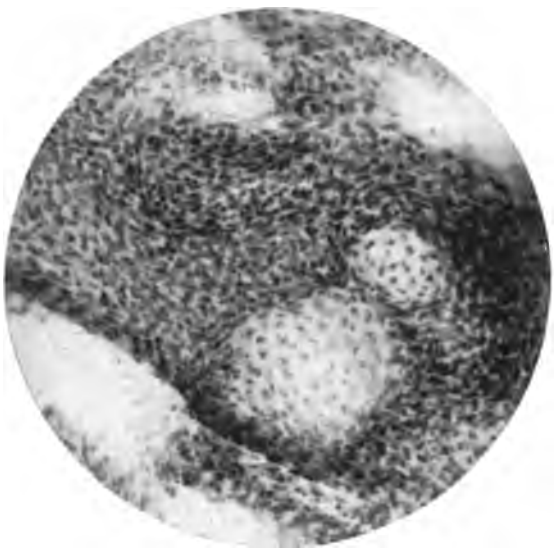

Fig. 4. Another area from the same section. It shows closely placed cells which are sarcomatous in character and two areas of young cartilage with an opaque, light eosin stained ground substance. High power magnification.

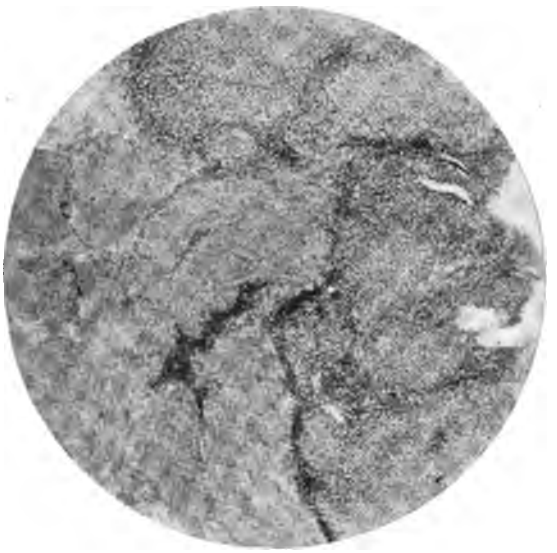

Fig. 5. A section showing the borderline of the tumor and myometrium. The line of demarcation is distinct. In one place there is a sarcomatous area in the myometrium but this is probably not deeper in the uterine muscle than one frequently finds endometrial tissue.

and a loose connective tissue. In the latter the nuclei are far apart and the tissue is myxomatous in appearance. There are also sarcomatous areas and isolated glands of the endometrial type; the latter, however, do not participate in the active proliferation but are rather atrophic. In places, especially in the smaller polypi, the endometrial covering epithelium is left. No smooth muscle and no striped muscle are present. The lymph spaces are dilated.

Nearly all writers who have published reports of these tumors have observed the loose connective tissue described in our tumor. There has been quite a difference of opinion as to the character of this tissue. Wilms (49), Seydel (40), and others try to prove that this is a kind of embryonal mesenchymal tissue, from which all the other tissues in the tumor are derived. Some say it is myxomatous tissue, as Rein (35), Mueller (24), and Pernice (30), while others take it to be œdematous tissue. Several investigators did the acetic acid test on the fresh specimen and found that this reagent produced cloudiness of the tissue; others, as Pfannenstiel (31), did the test for mucin and found it negative. Therefore, Pfannenstiel, considers this as proof that the tissue is œdematous and not myxomatous. Still others did not do the test for mucin, as Peham (28), but consider this tissue nevertheless to be myxomatous. There are also authorities, as Orth and Ziegler, who say, as stated by Pick (32), that we cannot draw a sharp line between myxomatous and œdematous tissue by the mucin test. Pick thinks it is often not possible to decide if the tissue is œdematous or myxomatous, and Keitler (14) states it is proven that myxomatous tissue may develop from œdematous tissue. In our case the tissue has a myxomatous appearance, but I am not able to decide if it is myxomatous or œdematous. The mucin test was not done.

The foci of closely-placed, small round cells which are found scattered about in the loose connective tissue in our specimen, have been observed by numerous writers, as Seydel (40), Pfannenstiel (31), Wilms (49), Spuler (41) and Thiede (42). Seydel thinks these round cells originate from the embryonal connective tissue. He saw the transition of the triangular spindle and star-shaped connec-

tive-tissue cells into foci of small round cells. He also saw all stages of transition of these round cells into cartilage, as was also observed in our case. This transformation is also proven in Kehrer's (13) case. Wilms (49) considers this loose connective tissue as the fundamental constituent of the tumor. It is according to his opinion the undifferentiated embryonal germ tissue, from which the other tissues in the tumor are derived.

Classification and nomenclature. In the following case reports I have collected those cases of uterus and cervix tumors which contain cartilage and striped muscle. Many of these have been classified as grapelike sarcoma, an appellation which for a large number is not descriptive. Most of the mixed tumors of the uterus and a good number of those of the cervix are not grapelike in structure. Pfannenstiel, who was the first to collect and describe as a clinical and histological entity the grapelike tumors of the uterus, himself included one case, that of Winkler (50), which neither had a grapelike structure nor did it contain heterogeneous tissue. Many of the grapelike sarcomata do not contain heterogeneous tissue but only sarcomatous and œdematous or myxomatous tissue, and many of the mixed tumors are not grapelike in shape.

Besides their grapelike structure and heterogeneous components their great malignancy is one of their characteristic features. In the large majority of cases this is correct, but cases have been reported without evidence of malignancy, as that of Schirokauer (38), in which the tissue was "poor in cells." The most important and characteristic feature of these growths is not their morphological structure but their histological composition. "We cannot," as Veit (43) states, "see in the sarcoma 'colli uteri hydropicum,' the grapelike sarcoma of the cervix, any proof for a certain anatomical structure. We find this form in histologically simple sarcoma and also in mixed tumors." The grapelike structure, therefore, should be a secondary consideration in the classification of these tumors; their most characteristic feature is their heterogeneous composition. For this reason I publish this case as a botrioid chondrosarcoma, to convey at the same time the information of its composition and structure.

In our case reports is included the title of the article under which these cases were reported, for in most of them the predominant component parts of the growth are indicated.

Several original reports were not accessible and I had to consult the reports of subsequent writers. Of the cases of Levitzky (20) and Gabelein (4) I found neither the original nor references. I did not include Orth (27) and Schroeder (39) in this table, because Schroeder merely states in his textbook that he has seen two cases of grapelike sarcoma, one of which had been reported by Kunert (17) and that he is in possession of a section of a polypous uterine tumor which is composed of pure cartilage.

Frequency of occurrence. The table contains eighteen tumors of heterogeneous composition of the corpus uteri and nineteen of the cervix. Of the former there are nine cases which contain cartilage and eleven which contain striped muscle. Two cases (Gebhard, 6; and Hunziker, 12) contain both cartilage and striped muscle. Penkert's (29) case contains cartilage, and he states that there are also cells which look like striped muscle, but no striation is seen. It is doubtful if a case reported by Vogler (44) is to be placed in this group. In this case, some of the smooth muscle cells looked like striped muscle.

Of the nineteen cervix tumors, fourteen contain cartilage and ten striped muscle. Four of these (Koch, 49; Pernice, 30; Peham, 28; and Mueller, 24) contain both cartilage and striped muscle. Some include Kleinschmidt's case in the mixed tumors. He reported a cervix tumor in which in one place was present a tissue which resembled hyaline cartilage.

A tumor reported by Wagner (46) in 1854 is, according to Williams, probably a chondrosarcoma. It occurred in a woman 55 years old. The uterus resembled a thin walled cyst. From its inner portion nodular ridges and many villous structures arose. On microscopical examination cartilage was found. In each lung were about 15 nodules, from the size of a pea to the size of a walnut, of the same composition as the original tumor.

This case probably belongs to the tumors of the body of the uterus.

In Rein's (35), Mueller's (24), and Pernice's (30) cases cartilage was found only in the primary tumor, not in the metastases. Girode (8) and Nehrkorn (26) found striped muscle in the myometrium without tumor formation. Gebhard (6) reports a chondrocarcinoma of the cervix, and others, among these Kworostansky (18), report cartilage formation in fibromyoma. The mixed tumors of the uterus and cervix differ from those of the vagina, for in the latter only striped muscle but never cartilage has been found.

Reason for grapelike growths. The cause of the grapelike structure, according to some writers (Kolisko, 16) is œdematous infiltration of polyps, the œdema being produced by the traction of the polyps, by torsion of their pedicles, and by pressure from the surrounding structures. Some have expressed the opinion that the grapelike structure of the vaginal tumors is produced by their growth from the papillary structure of the vaginal mucosa. For the development of the grapelike structure a pre-formed cavity is necessary. It, therefore, stands to reason that they should occur more frequently in the dilatable and elastic vagina and in the tumors of the cervix which grow down into the vagina, than in the uterine cavity with its firm resistant walls. However, they occur also in the uterine cavity. Keitler (14) has reported a case of definite grapelike structure, and the writer's case is partially grapelike. Some state that the strong and resistant uterine muscle would have to be weakened (pyometra) to make a grapelike growth possible, but this statement is not borne out by the writer's case. When these tumors infiltrate the adjoining deeper tissues, the grapelike structure of the infiltrating portion is lost.

Age. As regards the age at which these neoplasms occur, we see from our table that of the sixteen cervix tumors, those of Richter (36) and Pick (32) were in patients of about two years each; all others were in patients of 17 years or more. The oldest patient was 59 years of age and only 3 were older than 50 years. Of the corpus tumors, 13 out of the 15 patients were 50 years or over; the oldest was 75 years, the remaining two were 36 and 38 years old respectively. From this we learn that while the mixed tumors of the vagina occur chiefly in children, those of the cervix occur mainly at the prime of life and those of the uterus at the time of the menopause. In the writer's case the growth occurred at the time of the menopause. When questioned the patient stated that she was still menstruating, but that for one and one-half years the menstruation had been irregular and profuse and that she had had hæmorrhages. The exact time of the onset of the symptoms cannot be determined, for in the beginning the irregular menstruation may have been due to the beginning of the menopause. These tumors occur as well in women who have borne children as in those who have never been pregnant.

Duration. In a large number of cases the duration of the disease is not reported. In a good many cases it is difficult to state exactly when the first symptoms arose. Of the longest duration is Puech and Massabuau's (33) case. The tumor recurred five years after the operation. The patient refused operation for the recurred tumor. Among nine cases of cervix tumor which ended fatally the duration was two years or more in three cases, over one year in five cases, and less than one year in one case. Of the tumors of the body of the uterus the duration is known in seven cases. The duration of one case was three years, of two other cases over two years and in the remaining four cases less than one year.

Termination. The termination of many of these cases is not reported; in some it is stated that the tumor recurred. The cause of death in a large number was cachexia and exhaustion due to recurrence of the tumor; some patients died of exhaustion after the operation, some of peritonitis following perforation of the uterus, and some of other causes.

Metastases, local spreading, and recurrence. The malignancy of these tumors manifests itself less by metastases than by local extension and by recurrence after operative removal which often occurs very rapidly. At first they spread on the surface; the deeper tissues

are infiltrated rather late. The vaginal tumors seem to have more inclination to infiltrative growth into the deeper tissues than those of the cervix and uterus. The cervix tumors infiltrate the pelvic tissue later and those of the uterus very late. Distant metastases are infrequent and late, and as a rule do not contain heterogeneous tissue. Of special interest is Heddäus' (10) case, since a metastatic growth was found in the pleural cavity, which not only had an excessive grapelike character, but also contained the heterogeneous components of the original cervix tumor. Heddäus thinks a metastasis of undifferentiated embryonic tissue occurred.

Symptoms. Clinically it is difficult to differentiate these growths from other malignant tumors of the uterus. The most common symptom is irregular and profuse bleeding as in our case. Frequently there is a vaginal discharge, which at first is watery or blood-tinged, and which later, when decomposition of the tumor sets in, becomes purulent and very offensive. There may be pain in the pelvis. Large tumors may produce urinary symptoms by pressing on the bladder and urethra. In many cases pieces of tumors are passed by the vagina; in others especially in those of the cervix and the vagina, the tumor may appear at the introitus vulvæ. All the symptoms of malignant growths, as cachexia, anæmia, emaciation, etc., will occur in the later stage.

Diagnosis. In two cases the tumor was taken for an hydatid mole, which is suggested by the vesicular structure. A certain diagnosis can only be made microscopically. We have to remember that in quite a few cases polypi were removed which were not examined, and later the polyps returned and proved to be malignant. Or as in Malapert and Maurichau-Beauchant's (21) case, the polyp was examined and found benign. Therefore a careful microscopical examination of uterine polyps always should be done. This is especially necessary when they recur, and in these cases sections should be made from different portions of the polyps, since cases have been reported where in the primary polyps no malignant tissue was discovered, which possibly may be due to the fact that none was present, or perhaps to the fact that one section did not show malignancy while other portions may have contained areas of sarcomatous tissue.

Prognosis. The prognosis is generally considered unfavorable. Of nine of the corpus tumors we know the fatal termination. In five of these it occurred six months or less after the operation. Of the other four cases the fatal termination is reported but it is not stated how soon after the operation it occurred. The writer's case is still well eight months after the operation. The case of Murray and Littler (25) was well five months after the operation. We know that of the cervix tumors 12 ended fatally, 5 of these within a year after the operation; the time is not given in the other 7 cases. In considering these results we have to keep in mind that in many of these cases no radical operations were performed or that they were performed at a late stage, after the patient was beyond surgical help.

In spite of these rather discouraging results, I am inclined to believe that the outlook in our case is hopeful for the following reasons:

1. The patient has gained in weight and in hæmoglobin, she has generally improved, feels well, and no metastases have been observed eight months after the operation.

2. The microscopical examination showed the tumor to be confined to the endometrium. There was hardly any infiltration of the myometrium, which was thickened and surrounded the tumor like a protective capsule.

3. A radical operation (vaginal panhysterectomy) was performed.

4. Tumors of the uterus are less inclined to metastases and local infiltration than those of the cervix, since the uterus is more an isolated organ and not in so intimate contact with the surrounding tissue as the cervix.

Histogenesis. The question which arises when we see such a tumor is: How does such foreign tissue as cartilage and striped muscle get into the uterus? The histogenesis of mixed tumors, like that of tumors in general, is still unexplained. There are several theories

which try to explain the origin of these tumors. Pfannenstiel (31) and v. Franqué (45) state that the cartilage and striped muscle originate in the uterus by metaplasia. Pfannenstiel thinks the heterogeneous tissue is derived from the connective tissue of the mucosa, while v. Franqué (45) in his report tries to explain the derivation of sarcoma from the connective tissue and of the voluntary muscle from smooth muscle cells. Cartilage is derived from connective tissue in the normal development in prenatal life and also in postnatal life, but voluntary and smooth muscle are of entirely different origin and it is hard for us to imagine how the one can be transformed into the other.

According to Cohnheim these tumors are derived from misplaced embryonal cells which suddenly commence to grow, for some unexplained reason, after having been dormant for many years.

Wilms' (49) theory is a sort of combination of the two previous ones. He states that not single cells but undifferentiated embryonal germ tissues are split off and misplaced. He assumes a common mother tissue from which cartilage as well as striped muscle may commence to grow, while Cohnheim's theory presupposes the displacement of the single components.

Process of germ displacement. The frequency of the occurrence of these mixed tumors in the urogenital region is explained by the complicated growth in the embryonal development. According to Wilms the mother tissue comes from the region behind the kidney anlage. In the early embryonal development we find here the prevertebræ or myotomes, from which cartilage as well as striped muscle may originate. Their middle portion produces the voluntary muscle and their ventral portion, the sclerotome, is the beginning in the formation of the vertebræ. In this region appears at an early stage in the embryonal development the nephrotome and the wolffian duct. The latter grows progressively backward toward the cloaca. In its backward growth it takes some of the embryonal germ tissue with it. Its terminal portion atrophies and persists along the vagina and uterus as Mueller's duct. These embryonal germs remain dormant until they wake up suddenly at some later period, commence to grow, and produce a malignant growth.

This theory explains the site of the tumor, its heterogeneous composition and also the embryonal character of the tissue which is found in many of them, but it does not explain why these cells remain dormant for forty or fifty years and then suddenly commence to grow. It also does not explain how germs for mixed tumors get into the parotid gland or other places. Wilms' theory is probably today recognized more generally than any other, but we should not forget that it is merely a theory, not based on scientific proof, and that at present it is entirely impossible to give a satisfactory scientifically proven explanation for the origin of these tumors.

SUMMARY

The mesodermal mixed tumors of the corpus and cervix uteri contain striped muscle and cartilage or both as heterogeneous products. In many of them a loose connective tissue, which is myxomatous in appearance and contains foci of small round cells, is observed. The mixed tumors of the vagina contain smooth muscle only and no cartilage, and occur chiefly in children; those of the cervix occur chiefly at the prime of life; those of the corpus uteri occur at the time of the menopause or later. Nineteen mesodermal mixed tumors of the cervix and seventeen of the corpus were found reported in the literature. To the latter the author adds a report of a botrioid chondrosarcoma of the endometrium. The grapelike structure of some of these growths is no proof for a certain histological composition.

Clinically these neoplasms are characterized by their tendency to local recurrence after removal and to local extension. Distant metastases are infrequent. Their symptoms do not differ from those of other malignant growths in this region.

The diagnosis can only be made by histological examination. The prognosis is generally considered unfavorable, and the treatment consists in early and radical operative procedure.

CASES OF MESODERMAL MIXED TUMORS OF THE CERVIX UTERI

CASE 1. Reported by Weber (47) in 1867, in an article entitled "*Ueber die Neubildung quergestreifter Muskelfassern.*" The patient, age 45, IX-para, had, extending from the cervix, a polyp which recurred repeatedly after removal. Recurrence followed amputation of the cervix, the uterus became invaded and there were polypoid masses in the uterine cavity. The condition persisted for a year and nine months. Death resulted from peritonitis following spontaneous perforation of the uterus. Histological findings: Embryonal cross striped muscle cells, spindle cells, and smooth muscle.

CASE 2. Reported by Kunert (17) in 1874, in an article entitled "*Ueber Sarcoma Uteri.*" The patient was 35 years of age and had had no pregnancies. The vagina was filled by a tumor extending from the vaginal portion of the cervix. The growth was repeatedly removed; the cervix amputated; but there was a recurrence after each operation. The condition persisted for one year and nine months and there were metastases in the pelvis, vagina, pleura, and seventh and eighth ribs. Death resulted from cachexia and exhaustion six weeks after operation. Histological findings: Large round cells, striated muscle.

CASE 3. Reported by Thiede (42) in 1877, in an article entitled "*Ueber ein Fibroma papillare cartilagenescens der Portio vaginalis.*" The patient, age 45, II-para, had a pediculated, lobulated, soft tumor which filled the vagina. The tumor originated on the cervix. It was removed but recurred. The condition lasted more than three years. The patient died from exhaustion. Histological findings: Myxomatous and fibrous tissue with cartilage.

CASE 4. Reported by Rein (35) in 1880, in an article entitled "*Myxoma enchrondromatodes arborescens colli uteri.*" The patient was 21 and had had no pregnancies. She suffered from a grape-like tumor extending from the anterior and posterior lips. Growths were removed twice, but recurred. She had had the trouble for more than a year and 8 months. There were metastases in the left parametrium, pelvic lymph-nodes, and wall of the vagina. The patient died from peritonitis following the operation Histological findings: Mostly round and spindle cells, cartilage and myxomatous tissue.

CASE 5. Reported by Mueller (24) in 1887, in an article entitled "*Ein Beitrag zur Kenntniss der cystoiden Uterus-tumoren.*" The patient, age 24, no pregnancies, had a tumor the size of a hen's egg on the cervix. The cervix was amputated. A grape-like recurrence in the lower portion followed. There were metastases in the broad ligament, pelvis, and vagina. Death occurred one year after operation from recurrence and peritonitis. Histological findings: The primary tumor contained cross-striated spindle cells (a myxosarcoma). The recurrent tumor contained myxomatous tissue, spindle and round cells (sarcoma) and cartilage.

CASE 6. Reported by Pernice (30) in 1888, in an article entitled "*Ueber ein traubiges myosarcoma striocellulare uteri. Uterus inverted.*" The patient, age 17, no pregnancies had a grape-like tumor in the vagina, extending from the cervix. The cervix was amputated and repeated operations were done for recurrent tumors. Laparotomy. The condition persisted for two years and there were metastases in the abdomen and parametrium. The patient had hypostatic pneumonia; death resulted one month after operation. Histological findings: Œdematous and myxomatous connective tissue, young cross striped muscle cells, hyaline cartilage.

CASE. 7 Reported by Pfannenstiel (31) in 1892, in an article entitled "*Das traubige Sarcom des Cervix uteri.*" The patient, age 53, IV-para, had a cervical polyp which was removed but recurred. The uterus was removed. The growth persisted for three and one-half years. The patient died from cachexia. Histological findings: Œdematous tissue, hyaline cartilage.

CASE 8. Reported by Richter (36) in 1892, in an article entitled "*Ueber einen proliferierenden Schleimpolypen.*" The patient had had two operations for recurrence of a tumor arising from the cervix. The growth had been present for more than two years before the patient's death. Histological findings: Round cells, myxomatous tissue, striated spindle cells.

CASE 9. Reported by Pick (32) in 1894, in an article entitled "*Ueber Sarcoma des Uterus und der Vagina im Kindesalter, etc.*" The patient 2 years and 3 months old, had a rapidly growing, pediculated polypoid growth extending from the posterior wall of the cervix, and infiltrating the uterus. The growth had been present for six months and had extended into the paracervical, parametrial tissue, broad ligament, vaginal wall, and pelvic lymph-nodes. The patient died from exhaustion. Histological findings: Round and spindle cell sarcoma; cross-striped spindle cells.

CASE 10. Reported by Wilms (49) in 1899, in an article entitled "*Zur Kasuistic der traubigen Sarkome der Cervix uteri* (1896)." The patient, age 41, had had repeated operations to remove a tumor extending from the cervix. The operations were followed by recurrences. Autopsy showed a tumor the size of a child's head, extending from the cervix. The tumor was polypoid in its lowest portion. The tumor had been present for a year and a half and there were metastases in the mesentery and parametrium. Death followed peritonitis and perforation of the uterus. Histological findings: Round and spindle cell sarcoma, fibrous tissue, cartilage, fatty tissue, embryonic myxomatous tissue.

CASE 11. Reported by Seydel (40) in 1901, in an article entitled "*Ein Enchondrom des Uterus.*" The patient, age 42, had a cervical polyp which was removed, but recurred. Histological findings: Cartilage, embryonal connective tissue, round and spindle cells.

CASE 12. Reported by Peham (28) in 1903, in an article entitled "*Das traubige Sarcom der Cervix uteri.*" The patient, age 19, had had removed repeatedly polypi and tumors extending from the cervix and uterus. Autopsy showed the uterus to be almost entirely a polypoid tumor mass. A polypoid mass hung down into the vagina. The condition had persisted for a year and ten months and there were metastases into the pelvis. The patient died from exhaustion. Histological findings: Sarcoma, cartilage, embryonic striped muscle, myxomatous tissue. The polyps of the first operation did not show malignancy.

CASE 13. Reported by Spuler (41) in 1905, in an article entitled "*Zur Histologie des Rhabdomyoma.*" The patient had undergone hysterectomy for cervical polyp. Histological findings: Round and spindle cell sarcoma, well developed striped muscle cells, elastic tissue, fat.

CASE 14. Reported by Kehrer (13) in 1906, in an article entitled "*Ueber heterologe mesodermale Neubildungen der weiblichen Geschlechtsorgane* (*chrondromyxofibrosarcoma*)." The patient, age 38, V-para, had had uterine polys removed three times. Complete hysterectomy had been done. A lobulated soft pediculated polyp was attached to the cervix. The growths had existed for more than a year. The patient died from intestinal obstruction. Histological findings: Cartilage, smooth muscle, connective tissue, embryonic myxomatous tissue, embryonic striped muscle, bone.

CASE 15. Reported by McCann (22) in 1907, in an article entitled "Grape-like Sarcoma of the Cervix Uteri."

The patient, age 52, VI-para, had a polypoid, pediculated growth in the vagina extending from the cervical canal. Growths recurred although they had been removed twice. Histological findings: Cartilage, mixed cell sarcoma, infiltrated by lymph.

CASE 16. Reported by Puech and Massabuau (33) in 1908, in an article entitled "*Les tumeurs mixtes du col de l'uterus. Adenofibromyxochondrosarcome du col.*" The patient age, 59, had a pediculated, grape-like tumor in the vagina, extending from the cervix. The patient was well for five years when the growth recurred and she refused operation. The condition lasted for more than six years from the beginning of the symptoms until publication of paper. Histological findings: Embryonic myxomatous tissue, hyaline cartilage, fibrous tissue, fusiform cells (sarcoma), glandular tissue.

CASE 17. Reported by Heddäus (10) in 1911, in an article entitled "*Metastatischer Pleuratumor nach primaeram traubigem Cervixsarcom.*" The patient, age 48, the mother of several children, had a uterine polyp which recurred. Hysterectomy was done. Her trouble lasted for two years. She had a grape-like tumor in the pleural cavity. The patient died four weeks after operation. There was hæmorrhage, exudate in the thorax, and dyspnœa. Histological findings: Chondrosarcoma of the mucosa uteri. Irregular celled sarcoma, hyaline cartilage, gland tissue, myxomatous tissue, and perhaps fat. The pleural tumor has the same composition as the cervical tumor.

CASE 18. Reported by Levitzky (20) in 1900, in an article entitled "*Chilosarcoma enchondromateuse arborescent du col uteri.*"

CASE 19. Reported by Michel and Hoche (23) in 1907, in an article entitled "*Sur un cas de tumeur chondosarcomateuse du col uterin-sarcome en grappe.*" The patient, age 35, had recurrence of a cervical polyp after it had been removed two months. There was extensive polypoid proliferation. Complete hysterectomy was done and the patient recovered. Histological findings: Sarcoma with numerous cartilage islands.

CASES OF MESODERMAL MIXED TUMORS OF THE CORPUS UTERI

CASE 1. Reported by Anderson and Erdmannson (1) in 1869, in an article entitled "*Rhabdomyoma und mehrere andere Geschwuelste in einem Uterus.*" The patient, age 50, had a polypoid tumor in the vagina, which extended by pedicle from the uterus. The growth recurred twice after operation. It showed clubs and cysts. A hysterectomy was performed. Death resulted from hæmorrhage two months after operation. Histological findings: Striped muscle in tumor removed with uterus at autopsy, none in uterine tumor removed by operation.

CASE 2. Reported by Bystroumoff and Eckert (2), in 1874. The patient had a polypoid pediculated tumor extending from the fundus. Histological findings: Completely developed striped muscle cells. There are also spindle cells with 1, 2, and 3 nuclei, some very large.

CASE 3. Reported by Colomiatti (3) in 1882. The patient had a tumor the size of a child's head, which probably originated in the corpus uteri. There were three recurrences. There were probably metastases in the lungs. Death from "pleurisy." Histological findings: Large round cells, striated muscle.

CASE 4. Reported by Geissler (7), in 1891, in an article entitled "*Ueber Sarcoma Uteri.*" The patient, age 50, had had two abortions. She had a tumor arising from the posterior and lateral walls of the uterus. Histological findings: Spindle and round cell sarcoma arising from endometrium-cartilage.

CASE 5. Reported by v. Franqué (45) in 1899, in an article entitled "*Myosarcoma striocellulare corporis uteri hydropicum.*" The patient, age 49, XI-para, had a growth the size of a man's head, hanging from the fundus. There were lobulated, polypoid masses in the uterine cavity growing on top of a myoma. Hysterectomy was done. The patient died from exhaustion one week after operation. Histological findings: Striated muscle, spindle cell sarcoma.

CASE 6. Reported by Reid (34) in 1902, in an article entitled "Clinical Notes on Myxochondrosarcoma of the Uterus." The patient, age 59, VI-para, had a lobulated tumor which filled the uterine cavity. The uterus was the size of a four months' pregnancy. Vaginal hysterectomy was performed. Histological findings: Myxomatous tissue, hyaline cartilage.

CASE 7. Reported by Gebhard (5) in 1903, in an article entitled "*Eine Mischgeschwulst des Uterus. Endotheliom mit Fett und Knorpelgewebe.*" The patient, age 36, had had eleven or twelve pregnancies. She suffered from a pedunculated tumor hanging from a dilated cervix. The tumor probably originated from the fundus uteri. Hysterectomy was done. Histological findings: Cartilage, spindle cell, sarcoma. Striated muscle. Proliferation of endothelial cells, resembling carcinoma.

CASE 8. Reported by Penkert (29) in 1905, in an article entitled "*Eine Teratoide Mischgeschwulst des Uterus. Carcinoma corporis uteri polyposum mit myxomatoesem sarcomatoesem und knorpeligem Stroma.*" The patient, age 62, X-para, had a complete hysterectomy following diagnostic curettage. The uterus was filled with pediculated, partly soft, partly cystic tumors. The tumors originated on the anterior wall of the fundus. Histological findings: Cartilage developing from myxomatous tissue, spindle cell sarcoma, fat, smooth muscle, looking like young striped muscle, but no striation was seen. Nests of cells appeared to be carcinoma and endothelioma.

CASE 9. Reported by Laewen (19) in 1905, in an article entitled "*Rhabdomyosarcoma des uterus mit traubigen Wuckerungen.*" The patient, age 60, had a polypoid growth originating from the posterior uterine wall. Hysterectomy was done. The condition had been present for three years. Metastases were found in the peritoneal cavity. General peritonitis followed perforation of the uterus, and the patient died. Histological findings: Spindle cell sarcoma. Smooth and striated muscle, large multinuclear cells.

CASE 10. Reported by Malapert and Maurichau-Beauchant (21), in 1905, in an article entitled "*Tumeur conjonctive mixte (myxochondrosarcome).*" The patient, age 41, no pregnancies, had tumor masses which extended throughout the uterus and vagina. The tumors recurred after repeated operations for removal. The patient suffered a year and one month and died from cachexia. Histological findings: First tumor removed was diagnosed as fibromyoma. In the second one was cartilage, sarcomatous and myxomatous (?) tissue.

CASE 11. Reported by Hunziker (12) in 1907, in an article entitled "*Die Rhabdomyoma des Corpus Uteri.*" The patient, age 58, II-para, had pediculated, nodular tumors filling the uterine cavity. The tumors originated in the anterior wall of the uterus. Hysterectomy was done, the trouble recurred, and the pelvis became invaded. The trouble lasted for five months. Metastases occurred involving the rectum and bladder. The patient died from cachexia four months after operation. Histological findings: Cartilage, striated muscle, smooth muscle, myxomatous tissue.

CASE 12. Reported by Robertson (37) in 1909, in an article entitled "Rhabdomyosarcoma of the Uterus." The patient, age 69, II-para, had a pinkish, soft, lobulated tumor, probably primary in the corpus. She had not been

operated upon. The trouble had been present for eight months. The patient suffered from renal calculus and pyelonephritis, from which she died. Histological findings: Spindle cells, large multinucleated cells, striated muscle, myxomatous tissue.

CASE 13. Reported by Herb (11) in 1910, in an article entitled "Mixed Tumors of the Uterine Body (Rhabdomyosarcoma)." The patient, age 55, III-para, had a polypoid mass, extending from the fundus, and through the entire uterine wall. The tumor had been present for a year and two months. The patient died from regional recurrence six months after operation. Histological findings: Spindle cells, round and polygonal cells, striated muscle.

CASE 14. Reported by Murray and Littler (25) in 1914, in an article entitled "A Case of Mixed Tumor of the Uterus (Adenochrondrosarcoma)." The patient, age 46, no pregnancies, had a soft polyp removed, containing cartilage. Panhysterectomy was done. The patient was operated upon four weeks after the onset. She was well five months after operation. Histological findings: Spindle and irregular celled sarcoma resembling myxoma, hyaline cartilage, gland tissue and perhaps fat.

CASE 15. Reported by Glynn and Blair-Bell (9), in 1914, in an article entitled "Rhabdomyosarcoma of the Uterus." The patient, aged 62, II-para, had a growth originating in the corpus uteri. A polypoid growth was passed by vagina. Hysterectomy was done. The growth had been present ten months. There were metastases in the lungs, determined only clinically. The patient died from pulmonary lesions six months after operation. Histological findings: Small round and spindle cell sarcoma, embryonic muscle cells, some being striated (Grimsdale and Glynn's Case).

CASE 16. (Same reference as Case 15, Blair-Bell's Case.) The patient, age 75, no pregnancies, had a tumor of the corpus uteri. A polypoid growth was passed by vagina. The trouble had been present for six months, with abdominal and vaginal metastases. The patient died three months after operation from sarcomatous adhesions producing intestinal obstruction. Histological findings: Small, round, spindle and giant cell sarcoma. Embryonic muscle cells, a few being striated. Myxomatous tissue. Recurrence closely resembled myxosarcoma.

CASE 17. Reported by Perlstein, 1918, in an article entitled "Botrioid Chrondrosarcoma of the Endometrium." The patient, age 54, XIII-para, had a tumor mass partly polypoid, partly grape-like, attached to the posterior wall of the uterus. Hysterectomy was performed. The patient was hysterectomized. The trouble had been present probably a year and a half. There were no metastases and the patient was well eight months after operation. Histological findings: Tumor originated in endometrium. Large amount of cartilage. Loose connective tissue (myxomatous) with foci of small round cells. Round and spindle cell sarcoma.

CASE 18. Reported by Gabelein (4), in 1909, in an article entitled "*Eine heterologe Mischgeschwulst des Uterus. Myosarcoma myxomatodes et enchondromatodes polyposum uteri.*"

ADDENDUM

Following is an extract of a letter, dated January 11, 1918, for which I am indebted to Dr. Hugo Ehrenfest, St. Louis. It was received after this article had been sent to the editor and gives additional information regarding the clinical history.

"My records on the case of Mrs. S. Ox. are not very complete; however, I shall give you everything I have.

"The patient was seen by me for the first time on January 11, 1917, sent by a physician who had made the diagnosis of inoperable carcinoma. At the time she was 54 years old, married 37 years, had given birth to twelve children at full term, the last eleven years ago. Menstruation was perfectly regular up to approximately two years ago; from then on it would appear somewhat delayed until, finally, it would come in intervals of from three to four months. The previous seven to eight day flow gradually had lengthened out to from fourteen to sixteen days, however, never being very free. About three months ago she had a rather normal menstrual flow of eight days' duration, after that, as usual, she was perfectly free of any vaginal discharge until five weeks ago when another flow started, at that time (as never before) with labor-like pain. This flow started unusually free, gradually lessened and has persisted ever since. At present she complains only of very slight pain in the region of the symphysis and back. The patient is well nourished and the visible mucous membranes are approximately normal in color.

"On examination I found the vagina filled with a soft, lobular mass as big as a fist. High up the intact edge of a dilated smooth-surfaced cervix was palpable; within the cervix a thick pedicle, perfectly free all around, which run up into the greatly enlarged, irregular-surfaced uterus which apparently contained several subserous fibroids. The diagnosis of pedunculated, necrotic, bleeding, submucous fibroid was made and the patient advised to go to the hospital. On January 15, under ether anæsthesia, this mass was removed with forceps and curettes. It was soft, mushy, ill-smelling, about the size of a fist and seemed attached to the posterior uterine wall just above the internal os. No sutures or ligatures were required. The uterine cavity was packed tightly with iodoform gauze. The laboratory report unfortunately stated briefly that the tissue examined was in such a decayed condition that it was impossible to determine whether it was malignant, but nothing even suggesting malignancy was discovered. The patient made an uninterrupted recovery without rise in temperature, and was given two massive doses of X-ray before leaving the hospital on January 28.

"She remained free of any bloody discharge up to the first few days in March. I saw her only once more on April 3, just before she left for Chicago and made the notation that there was a slight bloody discharge continuing for the last several weeks. I found the uterus greatly enlarged filling posteriorly the sacral cavity. Within the cervix a large blood-clot was seen protruding from the uterine cavity.

"This is all the information I am able to give you. The surprising outcome of your further histologic study of the case, of course, is exceedingly interest-

ing and made me feel that I probably could have recognized the true state of affairs by a more careful study of the tissue removed at the first operation. However, clinically, the case surely did not suggest any malignancy and in every detail offered the typical picture of a half-expelled submucous fibroid."

I am sorry to state that my favorable prognosis with regard to the recurrence of the tumor was incorrect. The patient had been well after the operation up to April 5, 1918, when a slight pinkish discharge from the vagina occurred. She consulted a physician immediately and Emil Ries performed a curettage on April 9. Only a small piece of granulation tissue of about the size of a small nut was found in the vault of the vagina and removed. Microscopical examination did not reveal malignancy. The discharge discontinued after the curettage but recurred on June 1, and on June 4 a laparotomy was performed by Ries, to whom I wish to express my thanks for the information and for the specimens which were removed.

The right ovary and tube formed a tumor of about the size of an egg adherent to the vault of the vagina. The left ovary and tube formed a tumor of about one half that size. Both tumors were removed. I saw the specimens after they had been hardened in alcohol. In places, probably at the site of the attachment to the vault of the vagina, there was loose tissue of irregular structure having polyplike projections measuring up to 2 centimeters in length which were similar in appearance to the original tumor.

Microscopical examination showed this to be chondrosarcomatous tissue of the same character as described in the original tumor. Sections were taken of different portions of ovary and tubes and these structures themselves were not found invaded by the malignant growth.

Several writers called attention to the extraordinary malignancy of this class of tumors. In spite of this I was inclined to believe that the tumor would not recur since, as stated previously, it was limited to the corpus uteri, since a complete hysterectomy was performed and the patient was well and gained weight after the operation. That a recurrence followed this radical operation is a further evidence of the unfavorable prognosis which should be made in this kind of neoplasm.[1]

BIBLIOGRAPHY

1. ANDERSON and ERDMANNSON. Nord. med. Ark., i, No. 4, cited from Jahresb. d. Med., 1869, i, 187.
2. BYSTROUMOFF and ECKERT. Rudnew's J., 1874, p. 442, cited from Arch. f. path. anat., etc., 1876, lxviii, 556.
3. COLOMIATTI. Arch. sc. Med., v, 1, cited from Robertson (37).
4. GABELEIN. Inaugural Dissertation, Halle, 1909.
5. GEBHARD. Ztschr. f. Geburtsh. u. Gynaek., 1903, xlviii, 111.
6. GEBHARD. Path. Anat. d. weibl. Geschlechtsorgane, 1899.
7. GEISSLER. Inaugural Dissertation, Breslau, 1891, cited from Williams (48).
8. GIRODE. Semaine méd., 1892, iii, 48, cited from Kehrer.
9. GLYNN and BLAIR-BELL. J. Obst. & Gynæc. Brit. Empire, 1914, xxv, 1.
10. HEDDÄUS. Arch. f. Chir., 1911, xciv, 117.
11. HERB. Surg., Gynec. & Obst., 1910, x, 463.
12. HUNZIKER. Beitr. z. Geburtsh. u. Gynaek., 1907, xii, 316.
13. KEHRER. Monatsschr. f. Geburtsh. u. Gynaek., 1906, xxiii, 646.
14. KEITLER. Monatsschr. f. Geburtsh. u. Gynaek., 1903, xviii, 231.
15. KLEINSCHMIDT. Arch. f. Gynaek., 1890, xxxix, 1.
16. KOLISKO. Wien. klin. Wchnschr., 1889, ii, 109.
17. KUNERT. Arch. f. Gynaek., 1874, vi, 111.
18. KWOROSTANSKY. Beitr. z. path. Anat. u. z. allg. Path., Jena, 1902, xxxii, 117.
19. LAEWEN. Beitr. z. path. Anat. u. z. allg. Path., Jena, 1905, xxxviii, 177.
20. LEVITZKY. J. Akush. i Zhensk. Boliez., 1900.
21. MALAPERT and MAURICHAU-BEAUCHANT. Bull. et mém. Soc. anat. de Par., 1905, lxxx, 391.
22. MCCANN. Proc. Roy. Soc., med. Lond., Sect. Obst. and Gynec., 1907-8, ii, 253.
23. MICHEL and HOCHE. Compt. rend. Soc. d'obst. de Par., 1907, ii, 44.
24. MUELLER. Arch. f. Gynaek., 1887, xxx, 260.
25. MURRAY and LITTLER. J. Obst. & Gynæc., Brit. Empire, 1914, xxv, 26.
26. NEHRKORN. Arch. f. path. Anat., etc., 1898, cli, 52.
27. ORTH. Lehrb. d. spec. path. Anat., 1893, ii, 485.
28. PEHAM. Monatsschr. f. Geburtsh. u. Gynaek., 1903, xviii, 191.
29. PENKERT. Beitr. z. Geburtsh., u. Gynaek., 1904, ix, 488.
30. PERNICE. Arch. f. path. Anat., etc., 1888, cxiii, 46.
31. PFANNENSTIEL. Arch. f. path. Anat., etc., Berl., 1892, cxxvii, 305.
32. PICK. Arch. f. Gynaek., 1894, xlvi, 191.
33. PUECH and MASSABUAU. Gaz. de gynéc., xxiii, 145.
34. REID. Glasgow M. J., 1902, lvii, 371.
35. REIN. Arch. f. Gynaek., 1880, xv, 187.
36. RICHTER. Inaugural Dissertation, Greifswald, 1892, cited from Peham (28).
37. ROBERTSON. J. M. Research, 1909, xx, 297.
38. SCHIROKAUER. Inaugural Dissertation, 1902, cited from Peham (28).
39. SCHROEDER. Handb. d. Krankh. d. weibl. Geschlechtsorgane, 1889, 341.
40. SEYDEL. Ztschr. f. Geburtsh. u. Gynaek., 1901, xlv, 237.
41. SPULER. Centralbl. f. allg. Path. u. path. Anat., 1905, xvi, 337.
42. THIEDE. Ztschr. f. Geburtsh., u. Gynaek., 1877, i, 460.
43. VEIT. Handb. d. Gynaek., 1908, iii, 563.
44. VOGLER. Beitr. z. klin. Chir., 1898, xxi, 173.
45. v. FRANQUÉ. Ztschr. f. Geburtsh. u. Gynaek., xl, 214.
46. WAGNER. Leipzig, 1854, cited from Williams (48).
47. WEBER. Arch. f. path. Anat., etc., 1867, xxxix, 216.
48. WILLIAMS. Am. J. Obst., N. Y., 1894, xxix, 721.
49. WILMS. Mischgeschwuelste, 1899, 125, reported by Koch, Inaugural Dissertation, Giessen, 1896.
50. WINKLER. Arch. f. Gynaek., 1883, xxi, 309.

[1] Two months after the operation the patient commenced to bleed again. At present, November 25, 1918, according to the statement of Emil Reis, under whose treatment the patient is, there is a large tumor mass in the pelvis. The tumor fills the vagina, and appears at the introitus vulvae. The patient is losing weight rapidly.

SHALL OPERATION FOR HYPERTROPHIED PROSTATE BE DONE IN TWO STAGES

By FRANKLIN R. WRIGHT, M.D., F.A.C.S., Minneapolis, Minnesota
Assistant Professor of Urology, University of Minnesota

ALL surgical procedures are gradually developed. The operation for the relief of hypertrophied prostate is no exception to this rule. We first learned that the condition was amenable to operation. Suprapubic and perineal operations were developed. We had to decide which of these two operations gave the best result. This question, I think, has been decided. I think I am safe in stating that every one has abandoned the perineal operation except one genito-urinary surgeon and the minority of general surgeons. We are at present deciding the question whether the operation shall be done in one or two stages.

When a patient comes to us asking for relief from an hypertrophied prostate two questions must be decided: (1). Can this patient be safely operated upon? (2). If so, when? The first question is answered by a general physical examination of the patient. The second, by a study of the urine and its secretion. In order that we may judge the condition of the urine with reasonable accuracy, a comprehensive knowledge of the pathology of the hypertrophied prostate and its effect on the anatomy and physiology of the kidney is necessary. In few conditions can cause and effect be more clearly followed.

Briefly stated, the pathology is the development of a fibro-adenoma in that part of the prostate lying between the verumontanum and the internal sphincter of the bladder. As this tumor develops it causes a mechanical obstruction at the outlet of the bladder, and at the same time causes such an alteration in the shape of the bladder that it can no longer spontaneously empty itself, and residual urine results.

Whenever the bladder contains 100 cubic centimeters of residual urine, the urine backs up into the pelvis of the kidney. The pressure of the urine on the surface of the kidney causes a flattening of the pyramids and a broadening of the calyces. This must cause a more or less marked distortion of the urinary tubules. The kidney reacts to this pressure by passing large quantities of low specific gravity urine. Just how long this pressure and distortion must exist before the function of the kidney is modified we do not know, but we do know that where a large quantity of low specific gravity urine is found a change in the structure of the kidney has occurred. We know that the kidney of some individuals will continue to secrete apparently normal urine although a large amount of residual may be present. If, however, we drain the bladder of one of these patients, we find, just as in those patients who are passing low specific gravity urine, a fall in blood pressure, and, if the drainage is made continuous, a large percentage of them will develop uræmia. We are, therefore, justified in assuming that, although they are passing apparently normal urine, changes have occurred in the kidney tubules of these men.

The pressure of the urine in the pelvis of the kidney is mild but continuous because these patients never empty their bladders completely. The alteration in the shape, or the distortion of the tubules occurs so slowly that they retain their function somewhat modified as they gradually assume their new position. The reverse is true when we suddenly relieve the pressure in the pelvis of the kidney by completely emptying the bladder. The compressed kidney tissue returns to its normal shape very rapidly and the tubules which have become accustomed to an abnormal position are not able to perform their function in the normal position. If the drainage of this bladder is made continuous, the amount of urine passed is rapidly diminished and the patient becomes uræmic in three to eight days. If, now, we discontinue drainage and allow the pelvis of the kidney to refill with urine, again

applying pressure to the surface of the kidney, that is, return the tubules to the abnormal position which they have occupied, they again take up their function and the uræmia immediately begins to disappear.

My objection to doing suprapubic cystotomy as a preliminary to a prostatectomy is that if the patient becomes uræmic after having established continuous drainage by cystotomy, we cannot refill the pelvis of the kidney and replace the kidney tubules to abnormal position under which they formerly functionated. On the other hand, if we do the preliminary drainage with a catheter and our patient begins to show signs of uræmia we can withdraw the catheter and in a few hours the pelvis of the kidney will refill and the kidney tubules, being replaced to their abnormal position, will again functionate. The operation of prostatectomy is in itself not a serious undertaking. It is the sudden emptying of the pelvis of the kidney that makes it dangerous. Where death occurs following a prostatectomy the death certificate reads: "Renal insufficiency." If death follows a suprapubic drain age the certificate is made to read: "Uræmia." The cause is the same: the sudden emptying of the renal pelvis.

In an article entitled "Blood Pressure and Prostatectomy," published in *Annals of Surgery*, December, 1916, A. H. Peacock, of Seattle, gives an analysis of a series of seven prostatectomies. Six of these were preceded by preliminary cystotomy; therefore, we will only consider these six.

CASE 1. Patient, aged 64. The condition of urine is not mentioned. The man made an uneventful recovery.

CASE 2. Patient, aged 64, passing urine of 1,010 specific gravity; cystotomy was done with a local anæsthetic. The man died on the fourth day of uræmia; prostatectomy was never done.

CASES 3 to 6. Ages of patients varied from 58 years to 84 years; all passing urine of specific gravity varying from 1,020 to 1,024. A preliminary cystotomy was done in the four cases; prostatectomy was done on the third day following cystotomy in three cases and on the fourth day in one. Of these four cases, all passing apparently normal urine, one made an uneventful, recovery; one died seven days after preliminary cystotomy and four days after prostatectomy from uræmia; the other two became uræmic, but recovered. The amount of residual urine is not given in all of the cases, but the report shows that the patient who died from cystotomy had an overflow bladder, while the two who became uræmic, but recovered, had a residual of 45 cubic centimeters and 100 cubic centimeters respectively. (Peacock notes in his report that in the three which developed uræmia there was great diminution in the amount of the urine secreted.)

So from the six cases treated by preliminary cystotomy, two died; two became uræmic, and recovered; two made uneventful recoveries. Peacock says the deaths of the two and uræmias in the other two are due to what he has called hidden nephritis. To me it means that when the pelvis of the kidney was completely emptied the compressed kidney tissues returned so rapidly to normal position that the uriniferous tubules which had been for a long time in an abnormal position were not able to perform their functions when suddenly returned to normal position.

A patient, Mr. V., age 93 years, came under my care at the Minneapolis City Hospital on June 23, 1916, suffering from hypertrophied prostate and acute retention of urine. He had blood pressure, 168 – 170; catheter drainage was introduced; and his blood pressure promptly fell to 120. At the end of four days the old man became uræmic. The catheter was taken out and from that time he was catheterized twice a day. His blood pressure promptly rose to 148 and his uræmia cleared up. At the end of the fifth day, in attempting to catheterize him, the interne was unable to pass a soft catheter and undertook to use a metal catheter and made a false passage. Being unable to get a catheter into his bladder, I made a suprapubic cystotomy. The old man's blood pressure promptly dropped to 100. He became uræmic and died of uræmia on the nineteenth day after cystotomy was performed. His death, I believe, was due to permanently relieving the kidney of the pressure to which it had for years been accustomed.

CONCLUSIONS

1. All cases, including those cases where only a small amount of residual urine is present, should be given several days of preliminary drainage before prostatectomy is done.

2. Since cystotomy, which gives permanent drainage to the bladder and the pelvis of the kidneys, has been followed by death, I believe that it is better that drainage should be made by the use of the catheter.

3. Cystotomy should be reserved for use in those cases where catheterization, for any

reason, is impossible; or, for use in those cases of acute cystitis that do not do well with permanent catheter.

4. Since uræmia has been known to follow the opening of a bladder which contained only 45 cubic centimeters of residual urine, if compelled to do a cystotomy, it should only be performed after catheterization or aspiration of the bladder has been carried on for several days.

A VARIETY OF MASSIVE SYPHILITIC SPLENOMEGALY ATTENDED BY REMARKABLE VASCULAR CHANGES[1]

By DOUGLAS SYMMERS, M.D., New York
Professor of Pathology, University and Bellevue Hospital Medical College; Director of Laboratories, Bellevue and Allied Hospitals

Chemical Report
By ALEXANDER O. GETTLER, Ph.D., New York
Pathological Chemist, Bellevue Hospital

Technical Work
By WILLIAM M. JOHNSON, New York

THE purpose of this communication is to call attention to a form of syphilitic splenomegaly attended by naked eye changes which are readily indentified and by extraordinary microscopic alterations referable particularly to the smaller arteries of the splenic substance. In addition to its size, the organ is remarkable in that, on section, the naked eye detects pin-head sized, ochre colored bodies which, upon microscopic examination, are found to correspond to thickening and hyalinization of the walls of the smaller arteries with extensive deposits of mineral salts in the fibromuscular and elastic coats. The vascular apparatus of the spleen is further compromised by mineral-free, hyaline deposits in or around the small veins, and by hæmorrhagic extravasations in various stages of organization. Only two cases of a similar description have been found in the literature of medicine. In neither of them was syphilis mentioned as a possible etiological factor.

In the case recorded by Sprunt (1) the liver was the seat of an infective biliary cirrhosis and the abdomen was distended by fluid. The spleen weighed 775 grams. Small ochre colored bodies, which were visible to the naked eye, were found, on microscopic examination, to represent selective impregnation of the elastic tissues in the smaller arteries by salts of calcium and iron.

In the case described by Marini (2) the spleen weighed 1,900 grams and similar, but less extensive microscopic changes were found in the smaller vessels. Marini regarded his case as an example of the splenomegaly of the so-called Banti's disease. This, according to the views of the Italian school, is equivalent, of course, to a denial of syphilis as the causative factor, since this school holds that Banti's disease constitutes an entity of unknown etiology. According to the investigations of Norris, Symmers, and Shapiro (3), however, the splenomegaly of Banti is to be explained exclusively as a syphilitic process, and Banti's disease, as an independent clinical and anatomical entity, does not exist. This conception is based on the fact that, of those cases of clinically typical Banti's syndrome investigated by them at Bellevue Hospital over a period of twelve years, all, when pursued to a conclusion, were found to occur in subjects in whom syphilis was determined with certainty, not only by the histological alterations in the spleen—which, incidentally, are not to be distinguished from those enumerated by Banti—but by

[1] From the Pathological Laboratories of Bellevue Hospital.

the presence of syphilitic changes in other parts of the body. Since these observations were published, I have investigated 3 additional cases of clinically typical so-called Banti's disease occurring in Bellevue Hospital, and all were in syphilitic subjects. Moreover the cases described in the present paper correspond, from a clinical viewpoint, to one or another stage of so-called Banti's disease as originally outlined by the Italian pathologist, and, in fact, three of them were so diagnosed during life, and yet there can be no doubt, I think, that every one in the entire series was syphilitic in origin.

The argument that relief after splenectomy in the so-called Banti's disease is confirmation of the independent nature of the condition is, indeed, spurious. In the first place, removal of the enlarged spleen of syphilis not infrequently is followed by relief of certain symptoms, notably the anæmia. In a case operated on by Dr. John A. Hartwell, the patient who, previous to splenectomy, was intolerant of antisyphilitic treatment, now improved under specific therapy. In Giffin's cases (4), splenectomy was likewise beneficial, and similar results have been recorded by others. In the same way, splenectomy in pernicious anæmia is sometimes followed by noticeable if temporary improvement, and in certain forms of hæmolytic jaundice with increased fragility of the red cells, the operation is curative. The contention that, in so-called Banti's disease, splenectomy prevents cirrhotic changes in the liver that otherwise would occur, argues a prescience vouchsafed to none. So also, the assertion that splenectomy in so-called Banti's disease is followed by cessation of an otherwise progressive cirrhosis of the liver, while it may have some basis founded on intelligent reasoning, has not been shown to be a fact as revealed by remote investigation of the patients thus treated, although, like many dialectical trickeries, the statement carries with it just enough of the probable to lend it a degree of force.

Six cases of the extraordinary variety of splenomegaly about to be described, have been studied in the Pathological Laboratories at Bellevue Hospital. Five of the cases occurred in males and one in a female. The ages were 22, 32, 38, 50, 45 and 29 years. One case occurred in a subject whose liver revealed the naked eye changes of hepar lobatum. A second case was that of a patient with a strongly positive Wassermann reaction associated with generalized superficial lymphadenopathy and bilateral symmetrical ulcerative lesions in the region of the external malleoli that appeared at intervals for 15 years, healing slowly only to break down again, finally disappearing completely after splenectomy and under antisyphilitic treatment. A third case occurred in association with hepar lobatum and a left-sided chronic interstitial orchitis with extensive fibrous replacement. A fourth case was encountered in an individual with a syphilitic scar in the liver, irregularly distributed patches of testicular fibrosis, and syphilitic cirrhosis of the lymph nodes. A fifth case was in an individual with a positive Wassermann reaction and the characteristic microscopic changes of diffuse syphilitic splenitis. The sixth case was in a man with hepar lobatum and a solitary gumma of the liver.

In one case no blood examination was made, the individual having died unattended by a physician. In a second case, examination of the blood showed no noteworthy deviations from the normal. A third case was marked by a grave secondary anæmia which, after splenectomy and under specific treatment, improved greatly. In the 3 remaining cases the count of the red cells was practically normal, but there was distinct leukopenia.

In 4 cases ascites was present, and in all of them the liver was cirrhotic. In one of these cases, however, the initial distention of the abdomen occurred with extreme rapidity and ascites recurred promptly after paracentesis, due, as shown by autopsy, to thrombosis of the portal, splenic, and superior mesenteric veins. In the two remaining cases ascites was absent and in both the liver was free from cirrhosis.

The weight of the spleen in the several cases was 3410, 1275, 1050, 1040, 1150 and 1020 grams. In one case microscopic examination showed sclerosis and mineralization of practically every one of the smaller arteries

in the substance of the spleen, as will be described in detail later. The larger vessels at the hilum were not involved. In a second case identical transformations were found in the splenic arterioles in great numbers. In this case the splenic artery and vein at, and for several centimeters beyond the hilum were extensively calcified and, in fact, death was due to rupture of a calcific focus in the splenic vein succeeded by hæmorrhage into the cavity of the abdomen. In a third case only moderate numbers of mineralized vessels were apparent to the unaided eye. In the three remaining cases comparatively few of the smaller arteries were affected. The naked eye indications of the vascular lesions in question were to be found in the form of small, rounded, oval, or angulated bodies which presented a yellowish or brownish yellow granular center, with or without a reddish halo.

In studying the cases, histologically, paraffin, celloidin, and frozen sections were employed. The sections were stained in hæmatoxylin and eosin, Van Giesen's stain, picro-erythrosin, Weigert's stain for elastic fibers, von Kossa's silver nitrate stain for calcium, polychrome methylene blue and eosin, Perl's reagents for tribasic and dibasic iron, Sudan III for fat, and the older stain of Levaditi for spirochætæ pallida.

Case 1. The patient was a 22 year old, alcoholic Italian youth, who was admitted to Bellevue Hospital with the statement that, 7 weeks previously he was seized by sharp, stabbing pains in the region of the umbilicus that lasted 2 weeks and were accompanied by vomiting of blood and bloody diarrhœa. About a month later the abdomen began to enlarge and soon became distended. At the same time the patient noted that his urine was diminishing in quantity. Paracentesis released an enormous quantity of fluid from the abdomen. The spleen was palpated at the level of the umbilicus.

The Wassermann reaction was negative, as were the blood findings.

Splenectomy was done by John A. Hartwell. At operation the abdomen was found to be filled by fluid and the liver was the seat of a cirrhosis in which the lobules were coarse and irregular in size and distribution, a characteristic syphilitic hepar lobatum.

The patient died several days later of croupous pneumonia. No autopsy was obtained.

The *spleen* measured 23 x 13 x 6 cm. and weighed 1050 grams. The shape of the organ was well preserved. The capsule was tense and smooth. On the outer surface, immediately beneath the capsule, was a small, wedge-shaped formation which was cream-colored and extended downward for a distance of less than a centimeter. On section it was surrounded by a zone of injection and presented a smooth, faintly cream-colored surface (anæmic infarction). The spleen was reddish in color. On section it cut with resistance. The cut surface was dull red in color and fleshy in appearance. Scattered over the cut surface were literally hundreds of pinhead sized or slightly larger, rounded, oval, or variously angulated bodies each of which was slightly elevated and made up of a central area of brownish or yellowish brown, granular looking material surrounded by a distinct reddish halo. The splenic substance lying between these bodies was leathery in consistence, smooth and compact. In it were numbers of small reddish splotches suggesting hæmorrhages. Scattered here and there were small vessels which stood open and presented pale, thickened, hyaline walls. The malpighian follicles were not to be distinguished.

Cultural methods for the detection of tubercle bacilli and injection into guinea pigs of emulsified splenic tissue were negative, the animals having been sacrificed after the lapse of three months.

Histology. The most striking histological change in the spleen was to be found in the blood-vessels. Enormous numbers of the smaller arteries were the seat of extraordinary thickening of the fibromuscular coat, which was arranged around the compressed lumen as a collection of coarse, poorly nucleated, hyaline fibers or as fibers whose cytoplasm was obscured, but whose distribution was clearly defined in hæmatoxylin preparations by blackish or bluish-black deposits, corresponding to calcium. In many of the vessels the calcium deposits were associated with small yellowish or golden granules lying between the fibromuscular tissues. The elastic lamina was thickened and infiltrated by bluish or bluish black material. Most of the arteries thus affected were surrounded by a zone of closely packed red cells. The veins presented a different picture. They were frequently dilated, and the endothelial lining was re-enforced by a circular layer of fairly well nucleated, cloudy, pinkish staining muscle tissue. Around the veins was sometimes to be seen a thick layer of pale, hyaline material laid down in small plaques, the individual plaques being separated from one another by delicate, spindle-shaped nuclei which were distributed at various angles. None of the veins revealed the slightest indication of mineral deposits in their walls. The trabeculæ were coarse and numerous. The ground work of the splenic substance was made up of countless numbers of dilated, endothelial lined sinuses lying in a fibrillated connective tissue. Scattered among the splenic tissues were numbers of hæmorrhagic foci, some of which were in the process of organization as indicat-

ed by the interposition among the red cells, both at the periphery and elsewhere, of minute connective-tissue fibrils and fibroblasts. That organization had, in certain instances, proceeded to completion was shown by the presence of scattered islands of dense fibrous tissue. The malpighian bodies were few in number and poor in cells. Most m them lay in the immediate vicinity of the ofineralized arterioles. (See Fig. 1.)

Spirochætæ pallida could not be identified.

Chemical Analysis. Inorganic substances only. Normal and diseased spleens. Organic material destroyed and eliminated by ashing, all work being done in platinum with 5 grams samples of dried material. If ashing was done at as low heat as possible, all the resulting material in both the normal and diseased spleens was practically soluble in hot dilute hydrochloric acid, a little carbon remaining. If, however, the ashing was performed at a higher temperature the resulting material, in the diseased spleen, would not dissolve entirely. There was left a white insoluble substance, which not only resisted solution in all strengths of hydrochloric acid, both cold and after prolonged boiling, but also three days leaching in dilute hydrochloric acid. The normal spleen yielded no such substance. Furthermore, upon treating this white insoluble residue, after thorough washing, with sodium hydroxide solution and boiling (in platinum) it dissolved, and immediately changed to a brown precipitate. If hydrochloric acid was now added this brown precipitate dissolved readily, and in its place a colorless gelatinous precipitate appeared. The solution had a yellow color and gave a strong Prussian blue test. From the above properties there can be no doubt that the white insoluble residue was produced during ashing from the iron and silica of the spleen, and was an anhydrous iron silicate compound.

Silica. To determine the amount quantitatively, the ash from 5 grams of dried material was dissolved in dilute hydrochloric acid, the white residue decomposed by sodium hydroxide solution, and added to the main portion. Then it was acidified with hydrochloric acid and evaporated to dryness, moistened with concentrated hydrochloric acid, again evaporated and heated to 120 degrees C. for two hours, again moistened with concentrated hydrochloric acid and heated to 120 degrees C. for 2 hours. Then dilute hydrochloric acid was added and boiled; this dissolved all except the dehydrated silica, which was filtered off, washed, ignited and weighed.

Phosphate. After removing the silica, the phosphate was precipitated by ammonium molybdate, dissolved and precipitated as $(NH_4)\,MgPO_4$, ignited and weighed as $Mg_2P_2O_7$.

Iron. To the filtrate from above, H_2SO_4 was added and evaporated to a syrup, heated with small flame until fumes of SO_3 were liberated, diluted with water, H_2S passed through, warmed and left standing over night. This removes all the molybdenum. The excess of H_2S was boiled out, and the iron precipitated as $Fe(OH)_3$, then ignited and weighed as Fe_2O_3.

Calcium. To some of the original solution of the ash, ammonium carbonate was added until slightly cloudy, then a few drops of hydrochloric acid to clear, then ammonium acetate and ferric chloride until all phosphates were precipitated and the solution became brown. Three hundred cubic centimeters of water were added, boiled, thus precipitating the excess iron as basic acetate; this was filtered off and evaporated to dryness, the ammonia salts driven off, dissolved in hot water plus 2 drops hydrochloric acid, and the calcium precipitated with ammonium oxalate after adding sodium acetate solution. The calcium oxalate was filtered, washed, ignited and weighed as CaO.

Magnesium. The filtrate from the above was evaporated to dryness, ignited to drive off all ammonia salts, dissolved in dilute hot HNO_3, made ammoniacal and precipitated as magnesium ammonium phosphate and weighed as $Mg_2P_2O_7$.

Sodium and potassium. The original solution of ash was used. Silica removed by dehydration, sulphates by $BaCl_2$, iron by ammonia, phosphates by $Ba(OH)_2$, calcium and magnesium by NH_4OH and $(NH_4)_2CO_3$. Filtrate evaporated to dryness, ignited to drive off ammonia salts, the residue dissolved in dilute hydrochloric acid, filtered into tared dishes, evaporated to dryness, heated with low flame and weighed as combined NaCl and KCl. After weighing it was dissolved, the potassium precipitated as K_2PtCl_6 and weighed as such.

From the combined KCl and NaCl, was subtracted the KCl calculated from the above K_2PtCl_6 thus obtaining the NaCl. All results were calculated and are reported as oxide.

RESULTS

Normal Spleen per 100 grams Dry		Enlarged Spleen per 100 grams Dry
.206	CaO	.315
.151	MgO	.141
1.149	K_2O	.385
.305	Na_2O	.216
.736	Fe_2O_3	.484
.227	P_2O_5	.228
.028	SiO_2	.240
2.802		2.009

Normal Spleen Total in Entire Fresh Organ		Enlarged Spleen Total in Entire Fresh Organ
.934	CaO	1.953
.025	MgO	0.874
.191	K_2O	2.387
.051	Na_2O	1.339
.123	Fe_2O_3	3.001
037	P_2O_5	1.413
.005	SiO_2	1.488
.466		12.455

Analysis reveals the following points of interest: The potassium in the diseased spleen is diminished by about one-third, but the sodium very little. The content of phosphate is unchanged. The calcium is increased by about a half and the iron diminished to the same extent. The latter finding is to be explained by the fact that the iron values represent the total quantity of tissue iron plus the iron of the splenic blood. Since the extensive arterial changes in the enlarged spleen indicate diminution in the quantity of circulating blood in the organ the iron content is correspondingly affected. The silica is increased ninefold. It seems not improbable that the golden granules found in such abundance in histological preparations of the diseased spleen represent some variety of silicate, either iron silicate or even a silicate of calcium. It is also interesting to note that the total inorganic material, weight for weight, of tissue, is not more in the enlarged spleen, but rather a little less. This is due to the great reduction in potassium and iron, which overbalances the increased amounts of calcium and silica. Moreover, it appears that the increase in inorganic salts is parallel with the size of the respective spleens.

CASE 2. The subject was a man who met death unattended by a physician and nothing could be learned of his history. The autopsy was done by O. H. Schultze, the medical assistant to the district attorney of the County of New York. I am indebted to Dr. Schultze for the privilege of witnessing and protocoling the autopsy and for use of the material for purposes of microscopic investigation.

The body was that of an emaciated man about 50 years of age. The skin and visible mucous membranes were blanched. On opening the peritoneum an enormous quantity of blood came into view, lying between the lower border of the stomach and the pancreas.

The spleen was huge, reaching well down into the pelvis on the left side and as far foward as the middle line. It weighed 3,410 grams and measured 28.7 x 22.5 x 8.7 centimeters. The capsule was thickened and strewn with pinhead-sized, cream colored projections. On section the organ cut with resistance. The splenic substance was smooth, looked dense, and was leathery in consistence. Scattered through it were dozens of pinhead-sized or slightly larger, rounded, oval, or angulated bodies, each of which presented a granular looking yellowish or yellowish-brown center. Many of these bodies were surrounded by a distinct reddish halo. The malpighian follicles could not be distinguished. Small hæmorrhagic splotches were numerous and easily seen. The splenic artery and vein were dissected for several centimeters. The artery was markedly calcified, stiffened and tortuous. The vein was distended and thrown into small, pouch-like dilatations, the walls of which were translucent and scarcely more than the thickness of tissue paper.

The lymph nodes were not enlarged. A group of small, grayish-red, granular looking nodes was removed from the region of the brim of the pelvis and preserved for microscopic examination.

The liver weighed 2,570 grams. The surface was smooth except for the presence in the capsule of the right lobe of a long scar, which extended downward into the substance of the organ for a distance of about a centimeter.

The base of the tongue and the testicles were well preserved. The bone marrow of the ribs was hyperplastic, soft, succulent looking, and bluish red in color.

The rest of the organs presented nothing worthy of record in the present connection.

Histology. Microscopic examination of the spleen revealed large numbers of thickened, hyaline, mineralized vessels of identical histology with those already described. Hyaline thickening of the walls of the venules occurred in only a few instances. The most extensive changes were in the form of groups of thin-walled, greatly dilated capillaries, many of which had ruptured, producing hæmorrhagic extravasations. The hæmorrhagic areas were infiltrated by fibroblasts and traversed by delicate connective-tissue fibrils. Running through the splenic tissue in all directions were intercommunicating bands of fibrillar connective tissue which stained brightly by the Van Giesen method, disclosing an extraordinary degree of replacement of the splenic substance. (See Fig. 2.) Between the connective-tissue bands there were considerable numbers of slightly dilated venous sinuses, some of them filled by red cells, others empty. The malpighian follicles were few in number. Some were small and poorly cellular, others were in various stages of connective-tissue replacement.

Spirochætæ could not be demonstrated in the spleen.

Testicle. Microscopic examination of the testicle showed patches in which the walls of the seminiferous tubules were thickened and hyalinized or in which the testicular substance had been replaced by dense fibrous tissue.

Liver. Microscopic examination of the scar in the liver showed a broad band of fibrous tissue which penetrated deep into the substance of the organ, occasionally branching in such fashion as to enclose small groups of liver cells. In places the scar was

densely fibrous, in other places it enclosed circumscribed collections of round cells.

Bone Marrow. Smears from the marrow of one of the ribs revealed immense numbers of red cells and lymphocytes. That the increased number of lymphocytes was not to be explained on the basis of leukæmia was shown by the absence of hyperplasia of the lymph nodes in any part of the body and of hyperplasia of the follicles in the spleen, by the absence of lymphocytic infiltration of the viscera and by the absence of increased numbers of lymphocytes in sections of the vessels in the different organs.

Microscopic examination of sections of the marrow of one of the ribs showed immense numbers of lymphocytes and red cells, together with myeloid giant cells in which the nuclei were arranged as twisted, stellate, or otherwise distorted masses of chromatin.

Lymph nodes: Microscopic examination of the lymph nodes removed from the brim of the pelvis revealed thickening of the capsule. Running downward from the capsule were narrow bands of dense connective tissue which, in many instances, encircled large islands of lymphoid cells. Among the lymphoid cells were to be seen groups of small, irregularly rounded, hyaline bodies, and numbers of giant cells with twisted nuclei of precisely the same type as were found in the myeloid giant cells in the marrow of the rib.[1]

Splenic vein. The splenic vein showed large deposits of calcium lying in the muscle tissue. That at least one of similar deposits had so extensively replaced the tissues in the vein as to precipitate the rupture, which was responsible for the fatal hæmorrhage, was shown by the extremely delicate rim of tissue which lay between certain of the calcific foci and the surrounding tissues.

The microscopic examination of the other organs showed nothing of interest in the present connection.

CASE 3. The patient, a man aged 38, was admitted to Bellevue Hospital complaining of rapidly increasing distention of the abdomen. He stated that, 4 years previously, a physician had told him that he had a large "tumor" in the left side of the abdomen corresponding to the location of the spleen. Operation was advised, but this the patient declined because the mass was giving him no trouble. At the time of the patient's admission to Bellevue Hospital, examination showed a large mass in the left side of the abdomen. The lower border of the mass was at the level of the anterior superior spine of the ilium and the anterior border approached the middle line of the body. The mass was firm to the touch. The abdomen was distended by fluid, and paracentesis was performed on several occasions. Enormous quantities of clear, yellow serum were removed at each tapping, but the fluid reaccumulated with rapidity.

The Wassermann reaction was negative and no anatomical signs of syphilis were detected clinically.

The red cells numbered 5,800,000, the white cells 3,600. Of the latter there were 60 per cent polynuclear neutrophiles, 38 per cent lymphocytes and 2 per cent eosinophiles.

Autopsy. (Abbreviated protocol.) On opening the abdomen a large quantity of yellow fluid was released. The parietal peritoneum was strewn with tubercles. The spleen was greatly enlarged and weighed 1,150 grams. The capsule was slate gray in color and irregularly thickened. On section the organ cut firmly and was reddish in color, fleshy in appearance and the substance was tough in consistence. The cut surface showed considerable increase in connective tissue in the form of delicate grayish streaks. Scattered here and there were small, gaping vessels with smooth, pale, hyaline walls. Numbers of small, angulated, granular looking yellowish brown bodies were apparent to the unaided eye in different parts of the splenic substance. The splenic, portal, and superior mesenteric veins were partially occluded by attached grayish red thrombi. The liver weighed 1,575 grams and and its surface was coarsely and irregularly lobulated. The cut surface showed connective-tissue bands which were distributed in such fashion as to divide the substance of the liver into nodules varying from a few millimeters to several centimeters in diameter. The left testicle was firm in consistence, diminished in size and, on section, was extensively replaced by fibrous tissue. The rest of the organs showed nothing of interest in the present connection.

Histology. In this case the histological changes in the smaller arteries of the spleen corresponded closely to those already described, and consisted of thickening and hyalinization of the fibromuscular coat with calcification of its fibers in various localities and similar infiltration of the elastic lamina, together with the deposition of amorphous, golden yellow granules between the fibers. In some cases the periphery of the vessel was marked by small collections of red cells, but a complete zone of injection was not observed in a single instance. The smaller veins were greatly dilated. In some of them the walls consisted of collections of swollen, cloudy, finely granular connective tissue through which numbers of delicate, spindle-shaped nuclei were dispersed in various directions. In others, the venous walls were re-enforced by pale, hyaline plaques between which nuclear forms were arranged without any semblance of regularity. The ground work of the spleen was composed of minute connective-tissue fibrils and great numbers of fibroblasts. This newly formed, cellular connective tissue was arranged diffusely or in whorls, and served almost completely to obliterate the venous sinuses and to

[1] The most acceptable interpretation of this finding appears to me to be that, as a result of the disturbances in the bone marrow, myeloid giant cells had been discharged into the circulation and filtered out by the lymph nodes. The same sort of reaction seems to be responsible for the presence in the lymph nodes in Hodgkin's disease of giant cells indistinguishable from those normally present in the bone marrow (5), as well as for such other marrow cells as eosinophiles and eosinophilic myelocytes, which occur in Hodgkin's disease in about a third of all cases.

replace the cellular constituents of the pulp. Innumerable small hæmorrhagic foci were present at intervals, and some were infiltrated by fibroblasts. In still other places there were small collections of thin-walled, distended vessels supported by relativelv mature connective tissue, corresponding apparently to patches of organizing granulation tissue. The lymphoid follicles were few in number and poor in cells. Spirochætæ were not found in the spleen.

Microscopic examination of the liver showed numbers of broad, moderately richly cellular bands of connective tissue which were distributed in such manner as partially or completely to surround large and small islands of liver cells.

Microscopic examination of the testicle revealed areas in which the tubules were thickened and hyalinized or obliterated and replaced by fibrous tissue.

CASE 4. The patient was a women, aged 29, who was admitted to Bellevue Hospital suffering from severe anæmia which, she said, had been present since childhood. Physical examination revealed large, punched out, sluggish ulcerative lesions on either ankle in the region of the external malleolus. The patient stated that these ulcers appeared without obvious cause at the age of 15, healing slowly only to break down again. Under antisyphilitic treatment the ulcers healed promptly. The superficial lymph nodes were universally palpable. The abdomen was asymmetrical, due to bulging in the region of the spleen. The spleen was greatly enlarged and easily palpable.

Blood. Red cells 3,500,000; many normoblasts, a few megaloblasts, polychromatophilia and anisocytosis. White cells 8,200, of which 69 per cent were polynuclear neutrophiles and 31 per cent lymphocytes. Hæmoglobin 47 per cent.

The Wassermann reaction was strongly positive.

Splenectomy was done by John A. Hartwell. The spleen was huge. It measured 27 x 14 x 9 centimeters and weighed 1,275 grams. On the upper and posterior aspect was a scar corresponding to the location of a healed infarct. The veins at the hilum were dilated and thin-walled. The substance of the spleen was firm, granular to the touch and dark red in color. No ochre-colored bodies were enumerated among the naked eye appearances. The specimen has since been misplaced, and it is impossible to say whether or not they were present and overlooked.

At the time of operation Dr. Hartwell noted that the liver was perfectly smooth.

Splenectomy and antisyphilitic treatment were followed by marked improvement in the anæmia, and the patient left the hospital.

Histology. Sections of the spleen taken from two different areas and stained by hæmatoxylin and eosin and by Van Giesen's method, are available for microscopic examination. Both of them showed the presence of small numbers of thickened and mineralized arteries of precisely the same appearance as those already described. In addition there were numbers of thickened veins the walls of which were fibrotic and hyalinized. The fibromuscular trabeculæ were numerous and thick. The venous sinuses were congested. Between them Van Giesen's stain showed overgrowth of delicate connective-tissue fibrils and fibroblasts. The follicles were fairly numerous and well preserved. Small hæmorrhagic foci, some of them infiltrated by fibroblasts, were visible at intervals.

CASE 5. The patient was a man, aged 32, who was admitted to Bellevue Hospital complaining of chilliness, sore throat and headache. Physical examination showed signs of right-sided pleuritis and of tuberculosis at the apex of the corresponding lung. The spleen was large and easily palpated. There were signs of fluid in the abdomen, and paracentesis was attended by the withdrawal of an enormous quantity. The fluid, however, rapidly, reaccumulated, and was again withdrawn.

Blood. 4,100,000 red cells, 3,500 white cells. Hæmoglobin 65 per cent.

The Wassermann reaction was positive.

Splenectomy was done by John A. Hartwell. The spleen weighed 1040 grams and measured 23 x 14 centimeters. On section the cut surface presented a meat-red appearance and the substance cut with difficulty. The surface was finely granular, and innumerable minute grayish streaks were apparent. No ochre-colored bodies were described.

At the time of operation Dr. Hartwell noted that the liver was enlarged, firm, finely granular.

Microscopic examination of the spleen revealed only an occasional small artery whose walls were thickened and mineralized in a fashion not to be distinguished from those already described. The substance of the spleen was diffusely infiltrated by delicate connective-tissue fibrils, the veins were immensely thickened, in places banked by numbers of small hyaline plaques radiate to the long axis, and the follicles were small. Hæmorrhages were not observed.

CASE 6. The patient was a man, aged 45 years, who was admitted to Bellevue Hospital complaining of swelling of the abdomen of a year's duration. The spleen was palpated at the level of the pelvis and was firm in consistence. Paracentesis was attended by the withdrawal of large quantities of clear serum.

Red cells 4,160,000, white cells 5,200, of which 74 per cent were polynuclear neutrophiles, 22 per cent lymphocytes, 3 per cent transitionals and 1 per cent eosinophiles.

The Wassermann reaction was strongly positive with both the cholesterinized and crude alcoholic antigens.

The spleen was removed by J. B. Bissell. Death occurred some days later.

At autopsy the liver was extensively gnarled and a solitary gumma was present in the right lobe. No other anatomical indications of syphilis were encountered.

Spleen. The spleen as received from the operating room measured 20 x 10 x 5 centimeters and weighed 1,020 grams. On section the cut surface was smooth,

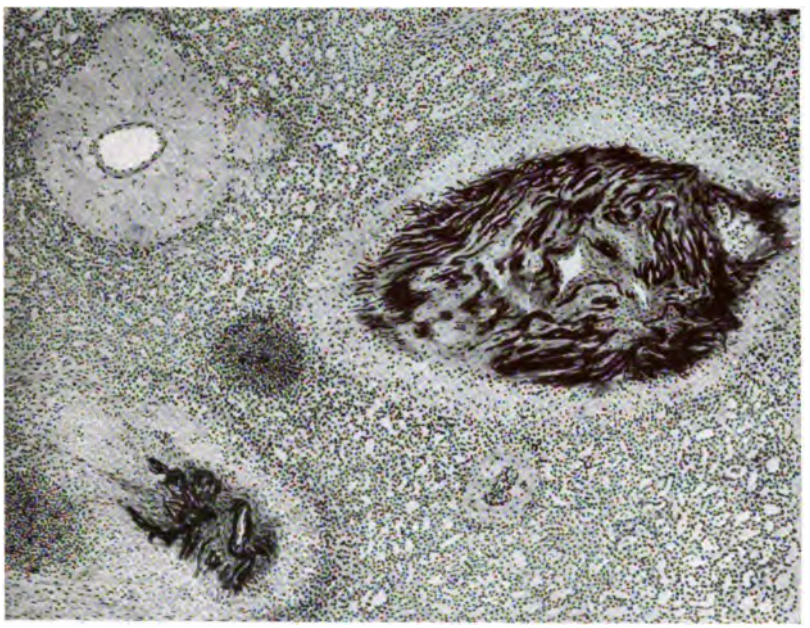

Fig. 1. Case 1. Showing the presence of two sclerotic and hyalinized arterioles with excessive infiltration of the fibromuscular and elastic coats by calcium, and a peripheral zone of red cells. The golden granules (of silicate?) are not represented. Above and to the left, a dilated venule re-enforced by a number of hyaline plaques. Diffuse sclerosis of the interstitium and dilatation of the venous sinuses. Two fairly well preserved lymphoid follicles, each in juxtaposition to a mineralized arteriole.

brick dust red in color and friable in consistence, yielding a fine grating sensation as the finger penetrated its substance. In the splenic tissue innumerable minute grayish fibrils were visible. The malpighian follicles were not seen. The smaller veins were gaping and their walls thickened. Moderate numbers of ochre-colored bodies were present, the largest approximating the size of the head of a pin.

Microscopic examination revealed abundant overgrowth of connective tissue in the form of fibrils and fibroblasts. The malpighian follicles were fairly numerous, but small. Some of them were encircled by strands of connective tissue. The fibrous trabeculæ were large and, in places, hyaline. A few of the arterioles showed the same extensive infiltration with calcium as has already been described, together with scattered collections of amorphous golden granules, or long, narrow golden yellow plaques which were transversely fissured at frequent but irregular intervals. The periphery of the calcified vessels was marked by a fairly broad zone of densely packed red cells. Large and small hæmorrhagic extravasations were found at intervals. Some of these were partially delimited or were penetrated by extravasations collections of connective-tissue fibrils and fibroblasts which resembled strands.

DISCUSSION

In attempting to elucidate the histogenesis of the changes in the smaller arteries of the spleen, one is apt to receive the impression that mechanical factors play a part, namely, that hæmorrhage is followed by disintegration of hæmoglobin and by the deposit of iron compounds in the hyalinized muscular and collagenous structures of the vascular coat. At the same time the circulation is impaired in such manner as to permit blood serum to escape through the damaged wall, and calcium is precipitated and taken up by fibers which are prepared for its reception as a result of preliminary ironization. This view, at least, is in consonance with the observations of S. Ehrlich (6), who determined the presence of calcium in ironized elastic fibrils in the immediate vicinity of hæmorrhagic foci, and with the results of experiments by Sumita (7) who found that the deposition of iron precedes that of calcium not only in pathological conditions, but

Fig. 2. Case 2. Showing extensive hæmorrhagic extravasations in different stages of organization. Just to the right of the center and slightly below it, is a calcified arteriole.

in the formation of bone in physiological circumstances, the iron acting as a sort of mordant. The same line of reasoning may be followed to explain the geographical distribution of the process of mineralization. For example, it is recognized that retrogressive changes in tissues are a *sine qua non* for calcification, and that, in areas which are to become calcified, the circulation is enfeebled. The changes in the walls of the smaller splenic arteries and the compression of their lumina certainly fulfill these prerequisites. Although the veins showed sclerotic or hyaline changes, mineral deposits were not to be found in them in a single instance, and this in spite of the fact that the structural alterations in the veins were of the sort that invite calcification. Since it is known that calcification is favored by diminution in and combated by the presence of carbon dioxide (8), it may be assumed that, in these circumstances, the increased carbon dioxide content of the venous blood and the preservation of the venous circulation, combined to prevent the deposit of calcium in the walls of the veins.

The successive steps in the process of mineralization of the arteries seem to be susceptible of explanation on the basis of histological appearances as developed by differential staining methods. The first change in the arterial wall is usually to be found in slight sclerosis of the subendothelial connective tissue, although this is neither constant nor apparently important. The elastic fibers, as shown by the orcein stain combined with Perl's reagent for trivalent iron, reveal varying degrees of hyperplasia, either in the form of thickened bundles of silk-like, wavy, straight or broken fibrils running through an arc of the vascular circumference or surrounding the lumen. These fibrils may or may not show the presence of iron. In the spleen investigated by Sprunt, where the process was apparently in an early stage of evolution, the presence of iron in the elastic lamina of the arterioles was so noticeable as to constitute the predominating change, but in our cases, all of which appear to have been of long standing, we were not able to demonstrate iron in the elastic layer, although calcification of this coat was practically constant. By means of hæmatoxylin and eosin, picro-erythrosin and Van Giesen's stain and even in unstained frozen sections, it is to be shown that the thickening of the arterial wall is due to sclerosis of the collagenous fibrils and hypertrophy of the muscle elements with subsequent hyalinization of both. Many of the hyalinized fibromuscular structures yield an exquisite Prussian blue reaction. Still others are impregnated with a substance which stains bluish or blackish with hæmatoxylin and which corresponds, therefore, to calcium. Lying between the more closely packed hyalinized structures are to be seen delicate strings of amorphous golden granules which are not only resistant to the common solvents, but to such stains as were employed. It is possible that these granules represent a salt of silica, perhaps an iron silicate or even a silicate of calcium. Where the hyalinized fibers are less compact these granular particles are arranged in clumps and stand in striking contrast to the blackish deposits of calcium.

CONCLUSIONS

There is a distinctive form of massive splenomegaly marked by the occurrence in

the splenic substance of variable numbers of pinhead-sized, rounded, oval, or angulated bodies with a brownish or yellowish brown, granular looking center, and with or without a peripheral zone of red cells. These bodies, which correspond, histologically, to sclerosis and mineralization of the smaller arteries, are characteristic and readily identified, and are distinct from anything familiarly encountered in the naked eye examination of the spleen. The substance of the spleen presents a reddish, flesh-like appearance, is leathery in consistence, and shows, on section, numerous small vessels whose walls are pale and thickened, corresponding, microscopically, to venules in or around which hyaline deposits have occurred, but which are immune from infiltration by mineral salts. Hæmorrhages may be seen by the naked eye and, histologically, are found in various stages of organization. In addition, the splenic substance is extensively replaced by the productive overgrowth of connective tissue of inflammatory origin.

The variety of splenomegaly described was encountered in syphilitic subjects only. The selective mineralization of the small arteries, while differing from the changes commonly found in syphilitic vessels, appears nevertheless to represent the deposition of salts in tissues already injured by syphilis. Whether identical changes occur in vessels in association with diseases other than syphilis, remains to be seen.

Grateful acknowledgment is tendered Drs. John A. Hartwell and J. B. Bissell, of the surgical staff of Bellevue Hospital, and Dr. O. H. Schultze, of the District Attorney's Office in the County of New York.

REFERENCES

1. SPRUNT. J. Exp. Med., 1911, v, 59.
2. MARINI. Arch. sc. méd., 1902, xxvi, 105.
3. NORRIS, SYMMERS and SHAPIRO. Am. J. M. Sc., 1917, cliv, 893.
4. GIFFIN. Ibid., 1916, clii, 5.
5. SYMMERS. Arch. Int. Med., 1917, xix, 990.
6. EHRLICH. Centralb. f. allg. Path. u. path. Anat., 1906 xvii, 177.
7. SUMITA. Arch. f. Path. u. path. Anat., Berl., 1910, cc, 220.
8. WELLS. Chemical Pathology. Philadelphia and London: W. B. Saunders Company, 1918; 3d ed., 440.

THE TREATMENT OF RETRODISPLACEMENT OF THE UTERUS AT THE WASHINGTON UNIVERSITY OUT-PATIENT DEPARTMENT AND BARNES HOSPITAL

By E. C. SAGE, M.D., Omaha, Nebraska, and Q. U. NEWELL, M.D., St. Louis, Missouri
First Lieutenants, M.C., U. S. A.

"RETRODISPLACEMENT of the uterus has been considered a clinical entity, with symptomatology, pathology, and treatment distinct from and unrelated to other conditions as early as 1895; at this time Theilhauber (1), before the Seventh Congress der Deutschen Gesellschaft fuer Gynaekologie, advanced the opinion that the symptoms which had been ascribed to retroversion, i.e., backache, abdominal pain, hæmorrhage, leucorrhœa, bladder disturbance, nervousness, dysmenorrhœa, and sterility, were in reality due to other conditions associated with the retroversion, of which the displacement was an accidental accompaniment." As Williams (2), at Harvard, pointed out in his article, this paper by Theilhauber opened the question and paved the way for reinvestigation of the subject, as his views met with a storm of opposition, with the result that his ideas met with a confirmation from many sources. Williams quotes the affirming opinions of such writers as Baldy, Bovée, Kelly, Mayo, and Schroeder.

From our work in the Washington University Out Patient Department and Barnes Hospital, we also accept these ideas and will attempt to visualize our results with this work, attacking the problem from four angles: (1) simple retroversion; (2) inflammatory retroversion — (a) with cellulitis, (b) with salpingitis; (3) acquired — (a) retroversions with new-growth, (b) resulting from childbirth; (4) congenital retroversion.

Jacoby (3) at the New York Post Graduate Medical School and Hospital found that of 300 consecutive cases 36 per cent had retroverted uteri, 15 per cent of which were uncomplicated by any other pelvic disorder, 10 per cent of which had a posterior parametritis, 5.5 per cent of which had diseased adnexa, 3 per cent posterior parametritis and decensus, 2.5 per cent decensus uteri.

Sturmdorf (4) at the New York Polyclinic estimated that 18 per cent of the gynecological patients had retrodisplacement, Barbour and Watson claiming that one-fifth of these were of the congenital type. John Van Doren Young (5), in his study of 6134 cases at St. Luke's Hospital, New York, found that 50 per cent of the cases had purely mechanical retroversion, leaving out of consideration all retrodisplacements due to posterior inflammatory peritoneal adhesions. Williams (2) at the Boston City Hospital, found that 30 per cent of 1000 cases seen there had retrodisplacements, only 13 of which were operated upon for uncomplicated retroversion.

Schroeder (2,e) examined 145 medical patients complaining of no pelvic symptoms and found the uterus in anterior position in 75 per cent, and retroverted in 25 per cent. W. J. Mayo says (2,d): "While the normal position of the uterus in the majority of women, perhaps 75 per cent, is more nearly anterior than posterior, it will be acknowledged that in at least 25 per cent, and at various ages, retrodisplacement exists." Howard A. Kelly (2,c) found 1886 retroflexions in 13,600 gynecological cases at the Johns Hopkins Hospital, 415 uncomplicated (22 per cent.)

At our clinic in four years' time 25 per cent of the 3954 cases examined had a retrodisplacement of the uterus.

We have, then, of this rather common condition seen in from 20 to 50 per cent of the gynecological patients, four classes of retrodisplacement to consider:

1. The *simple retroversion*, due to disturbances of the normal mechanics, physics, or dynamics of the pelvic organs.

2. The *inflammatory*, in which the uterus is displaced by a pus mass and afterward drawn back by adhesions.

3. The *acquired*, as the result of injury or relaxation consequent upon childbirth, with

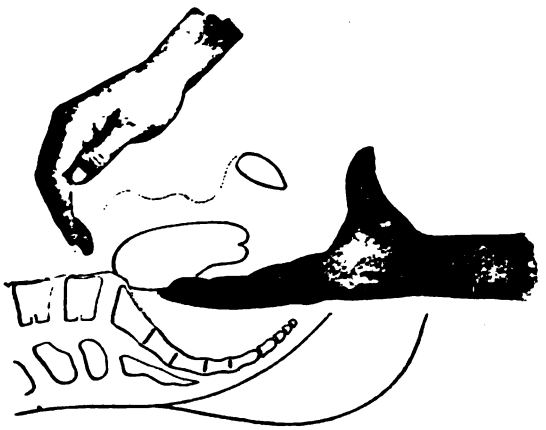

Fig. 1. Bimanual replacement. Raising the fundus uteri past the sacral promontory. (Pryor's *Gynecology*.)

subsequent subinvolution of the uterus and its supporting ligaments; or due to new-growths of the uterus or adnexa.

4. *Congenital*, where the woman has no inflammatory condition or has never borne children.

After having made the diagnosis of retrodisplacement, and having determined how far back the body is, the next point to determine is whether or not it is freely movable, and the treatment adopted depends on whether the uterus is movable or adherent.

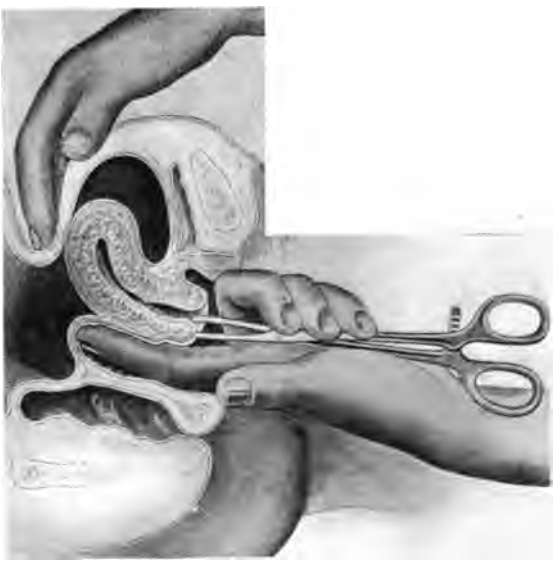

Fig. 2. Drawing the uterus down with a tenaculum forceps to bring it within the reach of the examining fingers. (Dudley, *Practice of Gynecology*.)

With a movable uterus the first step is to replace the uterus in the proper position by bimanual manipulation as illustrated in the diagram (Fig. 1). This oftentimes replaces the uterus. This is seen in recently delivered

Fig. 3. Bringing the fundus uteri forward and pushing the cervix backward and upward. (Kelly, *Operative Gynecology*.)

Fig. 4. The uterus brought forward into position. This shows also the method of taking the backward flexion out of the uterus, by bending it firmly forward over the vaginal fingers. (Kelly, *Operative Gynecology*.)

a *b* *c* *d*

Fig. 5. *a*. Introducing the pessary. First step, depressing the perineum. *b*. Introducing the pessary through the vaginal opening. The width of the pessary lies in the anteroposterior diameter of the opening, which is the long diameter, but is turned somewhat oblique to avoid the urethra. *c*. The pessary is now well within the vagina and ready for turning. *d*. The pessary is turned so the width lies transversely, for the transverse diameter is the long diameter of the vaginal canal, though not of the vaginal entrance. The pessary is then pushed in until its further progress is stopped by the cervix.

patients, where the subinvoluted structure with its relaxed supporting structures has fallen down into the hollow of the sacrum. If the corpus cannot be replaced by the ordinary bimanual examination a tenaculum forceps is used to catch the cervix, drawing down and forward, which pulls the uterus away from the promontory (Fig. 2).

The vaginal fingers then raise the fundus (Fig. 3) as high as possible so that the abdominal fingers pressed deeply into the back part of the pelvis can assist in raising the fundus, which, is being brought forward by the abdominal fingers (Fig. 4) at the same time the vaginal fingers are carrying the cervix backward and upward. All these maneuvers were described very fully in 1881 by Schultze of Jena, in a monograph. He administered anæsthesia to the patient where adhesions had to be broken up. With the patient's co-operation these manipulations can generally be carried out successfully without resorting to knee-chest posture, and we condemn the method of replacing by a sound or repositor.

We find with some patients that they are too nervous, the uterus and adjacent structures too tender, to permit the manipulations necessary for replacement on their first visit to the clinic; so they are dismissed giving them a glycerine tampon to be removed the next day, with instructions to take hot vaginal douches one-half hour, twice daily, keep the bowels open, and take knee-chest posture 15 minutes, twice daily. Such treatment at home diminishes the pelvic tenderness very much and at the next examination the uterus can generally be brought forward.

When the uterus is brought forward we select a proper fitting "Hodge" pessary No. 3, 4, or 5, and insert this as the most convenient and efficient device to keep the uterus in place, as is illustrated in the various stages in Figure 5, Figure 6 showing the pessary in place holding the uterus in its forward position.

The instruction to the patient wearing a pessary. The patient is then allowed to get off the table, walk around and squat down to see if the ring gives her any discomfort; if not, she is asked to report to the clinic one week later if the pessary is proving satisfactory, but sooner if it protrudes or slips out of position. If the uterus is in place and the patient is having no discomfort and the pessary is in proper position, it is assumed that it will prove satisfactory right along, and she is to report then every month, taking a cleansing douche every day so that no discharge can accumulate on the ring causing a concretion that might prove irritating. Then

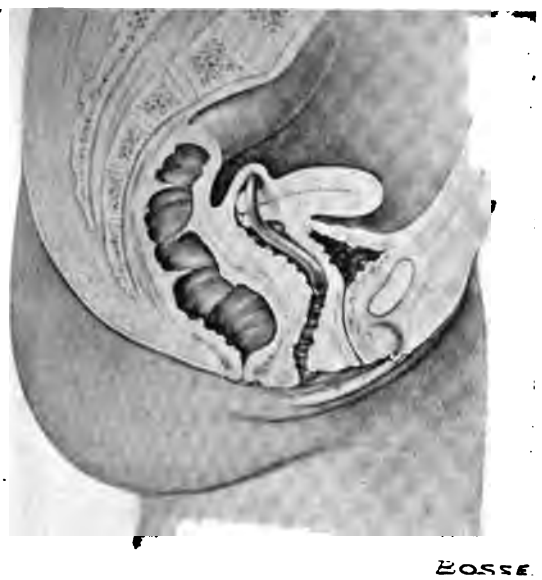

Fig. 6. Pessary in place. After the pessary is in place the patient should be told to press down as if at stool to see if the pessary is accurately fitted. There is no objection to introducing the bivalve speculum and carrying out any cervical, vaginal, or intra-uterine manipulation or intra-vaginal packing with glycerine and gauze. The presence of the pessary does not interfere with these therapeutic procedures.

when the patient returns a month later the pessary is removed, cleansed, and the vaginal walls and vault inspected to see if the long-continued pressure has caused any ulceration. If such is the case, or if injurious pressure on the wall is indicated by a distinct groove or ridge with infiltration, the pessary is left out. The patient is packed with one glycerine-

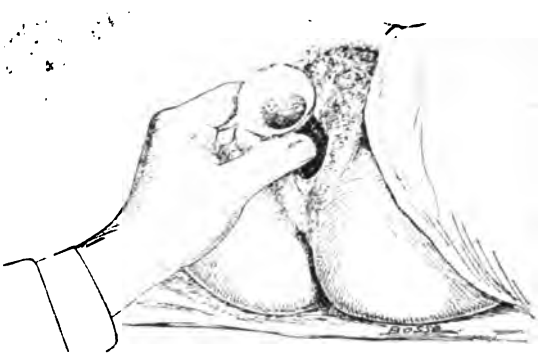

Fig. 8. Ferguson speculum in the vagina.

soaked tampon with a second dry one inserted afterwards with the patient in knee-chest posture. It is good for the patient to assume this position night and morning. It is very advantageous where patient complains of downward pressure in the pelvis.

The patient is told that the wearing of the pessary does not curtail her activities in any way; does not interfere with coitus, as in some cases of sterility they are used principally to increase the chance of pregnancy; and that if pregnancy should develop, she is to continue wearing it until the uterus has become large enough to prevent its sinking back into the pelvis.

If the uterus will not stay up after using the pessary for six months, we consider that more radical means should be employed, and send the patient to the hospital for the operation best suited for her case.

Fig. 7. Electric light cabinet for baking hospital cases.

Fig. 9. Patient in the Trendelenburg position with rubber bag inserted in vagina.

Fig. 10. Showing bag of shot upon abdomen for counter pressure.

If the retroversion is *of the second class*, that is, due to some pelvic inflammatory trouble, the treatment is directed primarily to the inflammatory process and the displacement is corrected only incidentally. The adhesions may have resulted from gonococcus infection, puerperal infection, acute appendicitis, tuberculosis, improper fitting pessaries.

If the patient can afford to enter the hospital we treat her there with hot douches, 116° F., twice a day and electric bakes one-half hour twice daily, increasing to one hour twice daily, with the electric light cabinet as pictured in Figure 7, using a Ferguson speculum in the vagina (Fig. 8) so that the heat can more effectively reach the inflammatory mass. The temperature under these cabinets is from 100° to 115°. After two weeks of such treatment, most inflammatory masses, if they are in the tubes or parametrial cellular tissues, will melt away; the pelvic tenderness will likewise disappear and then the body of the uterus becomes more movable and treatment for the displacement may be instituted.

We advise those patients, who can only be seen in the clinic, to take their hot douche at home, lying on their douche pan, having some other member of the family refill the bag with as hot water as possible, so that they use 10 or 12 bags full twice daily. They are tamponed in the clinic and carefully observed to see when the inflammatory masses have improved enough so that the adhesions can be broken up and the corpus replaced and pessary worn if need be.

Fig. 11. Cross section showing mercury bag in vagina stretching inflammatory adhesions.

For cases where posterior cellulitis seems to be the most aggravating symptom, the douches are strongly urged, but at the clinic we put the patient on the mercury bag treatment. The patient is put in the Trendelenberg position (Fig. 9) and the empty rubber bag inserted in the vagina. Then five pounds of mercury are poured in through a funnel, a clamp applied to the mouth of the bag, the free end brought up over patient's abdomen where counter pressure is brought to bear by a 5 pound bag of shot placed just over the symphysis and lower abdomen (Fig. 10). The patient is allowed to stay in this position one-half hour, returning twice or three times a week. This weight in the posterior fornix tends to iron out cellular infiltration and stretch the inflammatory adhesions from the sacrum to the fundus (Fig. 11). If the patients do not respond to this treatment by the end of two months, so that it can be plainly seen that the mobility of the uterus is increased, they are in turn given a letter of admission to the hospital for correction by some operative procedure.

The mercury bag treatment was first introduced by Freund in 1897 (7). Originally the technique was as follows: A condom was introduced over a round speculum, shot poured in, and the speculum removed, leaving

the shot in place from 2 to 10 or 16 hours, with counter pressure on the abdomen by placing a bag of shot weighing 1 or 2 kilograms. This method was first used by Funke, Freund's assistant, and independently by Pinkus. The method was popularized by Halban in Schauta's clinic, who was the first to use the mercury in a colpeurynter (as we use it in this clinic), placing the patient in the Trendelenburg position. He pointed out that he could use more weight in the colpeurynter than Funke could by means of the condom.

The Trendelenburg position favored the return flow of the blood, while the weight therapy by pressure on the pelvic organs, both from abdomen and vagina, produced enough compression of the vessels to give a venous hyperæmia, causing absorption.

Pinkus pointed out that you could use this therapy just as well by raising the foot of the bed. He also devised a combination of bags where you could release some of the mercury by letting in air, thus the circulation was not depleted as suddenly, and the patient could return home with the air colpeurynter in place, giving in addition an ambulatory form of treatment.

This mercury bag then (1) relieved the pain by stretching the adhesions as shown in Fig. 11, having quite the similar effects as massage, which is used quite intensively in the European clinics; and is (2) better in numerous cases, being simpler, and is less dangerous, not producing the discomforts that massage sometimes causes in psychic patients. We do not use massage in this clinic.

So the mercury bag method of treatment is given a trial in all affections of the parametrium as it causes inflammatory œdema to disappear, loosens structures up better, so that a more exact diagnosis can be made of adnexal masses. Careful use of the mercury bag can also be used in double pyosalpinx, using at first small amounts one-fourth to one-half pound, causing a marked decrease in the tenderness. This method is especially valuable in ironing out old scars running from cervix into parametrium. Lately we had such a case where the patient at her former delivery had her cervix incised by the attending physician to hasten the delivery, leaving her with a definite band of scar tissue that was extremely tender on any manipulation; but which responded very nicely to the constant and equal pressure exerted by the 5 pounds of mercury.

We have also a *third class of retrodisplacement* to consider; those due to new-growths of the uterus or adnexa; or those following childbirth as the result of a relaxed pelvic floor with some decensus and retrodisplacement; or due to subsequent subinvolution of the uterus and its supporting structures. In our table of cases are seen many instances of incomplete abortion, where a curettage with baking, hot douches, and possibly a ring, corrected the condition. In other cases anterior suspensions had to be done, generally by shortening the round ligaments by pulling them through the rectus muscle and sewing them together underneath the aponeurosis; or by the Venable operation. Where the perineal floor was relaxed a perineorrhaphy was done to give the proper support from below; and if the cervix needed repair this was done routinely. Whenever we could have the patient become pregnant again, she was closely watched to see that the growing uterus spontaneously corrected its position and then in her puerperal state every measure was used to keep the uterus forward — but if these measures did not suffice operative measures had to be resorted to.

It is not within the scope of this paper to discuss the different operations for retroversions; there were 131 papers written on this subject in 1913 alone. Operative gynecologic records show over a hundred detailed operations for the correction of retrodisplacement and Baldy states that the possible number of retrodisplacement operations performed in this country is limited only by the number of females in existence.

We have treated 21 cases with dilatation, curettage and pessary; 16 cases with a supravaginal or complete hysterectomy; 38 cases by anterior suspension operation — Gilliam-Crossen, Venable, Mann-Webster, Montogomery technique; this series of cases also including two instances where myomectomy for fibroid nodules was done; 7 cases with an interposition operation, and 1 case

with a perineorrhaphy, with later a pessary to correct the displacement. Two cases of pregnant uteri, retrodisplaced, corrected themselves spontaneously as the uterus grew larger.

For the choice of operations best suited to the case we followed Crossen's (8) suggestions as closely as possible — as outlined in the May number of *Journal of Missouri State Medical Association*, 1916. As Dr. McCann (9) of London has shown, most of these cases fall under four heads: (1) treatment in the childbearing period — (a) when uterus is replaceable, (b) when uterus is fixed; (2) backward displacement after menopause; (3) backward displacement associated with uterine and ovarian tumors; (4) backward displacement of the gravid uterus.

Attention should be called to Reynold's (10) idea as an expedient for radical cure of the acquired type of retroversion occurring as a result of a fall or during puerperal relaxation. He arranges the puerperium so that the supporting structures undergo a complete involution while the uterus is held in an extreme forward position; that is, on the tenth or fifteenth postpartum day when the uterus is too large to retrovert — the body is thrown into a strong anteversion by bimanual manipulation and a carefully fitted hard rubber pessary made to hold it there. Then very hot vaginal douches are given 15 or 20 minutes twice daily, causing a very rapid involution so that within a week the original pessary is generally too large and a second ring must be put in on the tenth or fourteenth day, changing to smaller ones as necessary until the uterus is little above normal size. Necessarily such practices must be done with asepsis and by those familiar with fitting pessaries to the individual cases. We have tried this method in the hospital and find it very satisfactory.

When we see a retrodisplacement in a woman who has had no inflammatory condition and who has not borne children we must consider the condition congenital, and the retroversion may be said to be the normal position of the uterus for that individual — so is usually symptomless and requires no treatment. Barbour and Watson (11) estimated one-fifth of the retrodisplacements as congenital. Sturmdorf (4) of the New York Polyclinic, by his application of the "lumbar index," estimates one-half of all cases of retroversion, complicated and uncomplicated, as congenital. He claims this index is the only pathognomonic factor that is constant, accurate, simple to apply, and which should constitute a routine part of every gynecological examination. This index is the distance in millimeters from the deepest point of the hollow between the dorsal and sacral convexity, to a ruler connecting these two points of the spine. This measurement in a large series of cases varied from 12 to 45 millimeters an excess of 45 millimeters, indicating a pathological lordosis — the kangaroo type of posture; an index of 30 millimeters, or less — the gorilla type of posture in which is seen the congenital retroversions which may be positively predicted in nearly every case prior to its bimanual verification. The cause for this displacement is a congenital retroversion of the entire pelvis, with resulting compensatory dystopia of its contents; there is a flattening of the sacrovertebral angle, regularily evidenced by a corresponding obliteration of the normal lumbar curve, and the measure of its resultant approximation to the vertical estimating an index of 30 millimeters, marks the extreme minimum compatible with normal anteversion; from 25 millimeters down, the existence of congenital retroversion. He argues that every abnormal pelvic tilt must create a correspondingly abnormal uterine tilt, so that when there is an upward and backward rotation of the pelvis, the pubes and lower sacrum are elevated, the latter forming the posterior instead of the upper wall of the pelvic cavity — necessarily altering the mechanism of the sacro-uterine ligament, their horizontal pull holding the uterus back against the depressed sacrum. Likewise the intra-abdominal pressure is inadequately deflected throwing the intestinal coils against the anterior surface of the uterus, causing the retrodisplacement.

Treatment of such cases must be on mechanical and orthopedic principles.

A uterus congenitally retroverted before conception will invariably resume its retroverted position after delivery, when the demonstration of a minus index will reveal

the congenital nature of the displacement to the exoneration of the accoucheur.

The following summary shows the duration of treatment and results obtained in 23 cases of simple retrodisplacements; 48 cases of acquired, as result of childbirth and new-growths; and 44 cases with inflammatory complications; 12 with salpingitis; 32 with cellulitis — as taken care of in the clinic. The summary includes the complaints, ages, pelvic findings, and treatment of some hundred cases in the hospital.

Tables have been compiled of 103 hospital cases, stating the principal complaints, pelvic findings, treatment and age of the patients. One hundred and seventeen clinic cases were abstracted showing the length of time the patient complained, the type of retrodisplacement, treatment, duration of treatment, and the results. The length of time the patient complained varied from one month to eight years. There were:

Thirty-five cases of retrodisplacement due to inflammatory cellulitis.

Twelve cases due to the adhesions of a salpingitis.

Forty-five cases acquired following childbirth.

Two cases acquired on account of mechanical pressure exerted by new-growths such as ovarian cysts, fibroid nodules in anterior surface of uterus.

Twenty-two cases of simple uncomplicated retrodisplacements.

The treatment used in the clinic was the glycerine tampon, mercury bag, reduction by Kustner's maneuver, pessary until corpus would remain forward, or in many cases until the patient became pregnant.

The quickest results were obtained in three or four weeks, that is reduction of the displacement after being treated that length of time with the tampon and mercury bag.

The average length of time these clinic cases were treated was three to four months. If they did not respond to these palliative measures in six or seven months, they were referred to the hospital for the performance of more radical measures—some operative interference.

The most common symptoms of the cases seen in the hospital were pain in the lower abdomen, dysmenorrhœa, menorrhagia, backache, bearing-down pains, leucorrhœa, sterility, frequent abortions, constipation, sacral backache, metrorrhagia, pain in either of the lower quadrants of the abdomen, and pain in the rectum, amenorrhœa.

Associated pelvic findings besides the displacement were relaxation of pelvic floor, chronic salpingo-oophoritis, chronic metritis, chronic posterior pelvic cellulitis, fibroid nodules in the corpus, laceration of the cervix, second and third degree perineal lacerations, ovarian cysts, marked endocervicitis with accompanying erosion, hæmorrhoids incomplete abortions, prolapse of the uterus, cystocele and rectocele, visceroptosis, rectovaginal fistula.

Necessarily the choice of operations was governed by the findings. More anterior suspensions by shortening the round ligaments by the Gilliam-Crossen technique were performed than any one other procedure. When the patient had some adnexal involvement she was baked and douched until the displacement could be properly taken care of.

When the uterus was left, curettage was almost routinely employed to scrape away the thickened endometrium which usually showed a glandular hyperplasia.

The age of the patient determined many times what was done with the adnexal pathology. If it was found that the blood supply would be too markedly interfered with to do any plastic work in the younger individual, and that both tubes and ovaries had to be removed at the time of the supravaginal or complete hysterectomy, the patient after her discharge from the hospital was asked to return to the clinic for the administration of corpus luteum which was given in 1 cubic centimeter doses intravenously two or three times a week. This organotherapy generally controlled the accompanying symptoms of an artificial menopause. The ages of the patients varied from 21 to 58. The interposition operation gave very pleasing results in the women past the childbearing age who had some cystocele or prolapse accompanying the retrodisplacement (Wertheim, Watkins technique).

Vaginal hysterectomy was performed in those cases where the patient had no history or findings of appendicitis or adnexal inflammatory disease, was past the childbearing period, or desired no more children.

It might be worth adding that it was always routine to get the patient to sign an operating permit which we feel saved us perhaps several lawsuits. The form used was that suggested by Crossen:

"I hereby give permission for the performance of the desired operation and any such additional work as found necessary at the time of operation."

REFERENCES

1. THEILHAUBER. Monatsschr. f. Gynaek., 1895, ii, 266.
2. WILLIAMS. Boston M. & S. J., 1917, clxxvi, 558–564.
   a. BALDY. Surg., Gynec. & Obst., 1908, viii, 421.
   b. BOVEE. Surg., Gynec. & Obst., 1915, xx, 606.
   c. KELLY. Surg., Gynec. & Obst., 1915, xx, 599.
   d. MAYO. J. A. M. A., 1912, lix, 1421.
   e. SCHROEDER. Quoted by Theilhauber, loc. cit.
3. JACOBY. Med. Record, 1916, lxxxix, 281.
4. STURMDORF. Am. J. Obst., N. Y., 1916, lxxiv, 386.
5. YOUNG. Am. J. Obst., N. Y., lxxiii, 1916, p. 331–335.
6. CROSSEN. Diseases of Women.
7. Physikalische Therapie der Erkrankungen der Weiblichen. 1906. Dr. Foges, p. 28.
8. CROSSEN. J. Mo. St. M. Ass., 1916, May.
9. MCCANN. Brit. M. J., July, 1916, ii, 12.
10. REYNOLDS. Boston M. & S. J., 1917, Dec. 7.
11. BARBOUR and WATSON. Gynecological Diagnosis and Pathology. 1913.

CARCINOMA OF THE STOMACH

Report of Three Cases with No Recurrence Five Years After Operation[1]

By JOHN DOUGLAS, M.D., F.A.C.S., New York.
Attending Surgeon Bellevue Hospital, Associate Surgeon, St. Lukes Hospital

MUCH of the recent literature on carcinoma of the stomach is devoted to the subject of early diagnosis, although W. J. Mayo has written: "It may be stated as an axiom that carcinoma of the stomach *per se* does not produce symptoms on which an early diagnosis can be based."

It is true that the precentage of cures can only increase when the surgeon has the opportunity of operating on early cases, and therefore, everything possible should be done to encourage early diagnosis, and especially prompt operation if the diagnosis of carcinoma seems a probable one. However, notwithstanding the brilliant statistics published by the Mayo clinic (38 per cent were shown to be well three years after operation, and 26 per cent, five years after operation) and the reports of a few other surgeons, the attitude of the medical profession in general, as well as of the laity, is one of extreme pessimism. This would appear to be fully justified when a clinician with the experience of Friedenwald states that of a series of 266 of his own cases on whom operation was performed, not a single patient was living.

If only such discouraging statistics gain currency, and if similar results are the experience of most medical men, it would seem that surgery has little to offer as a prospect of cure under present conditions, and the physician has little incentive to advise operation. Therefore, it would appear that in addition to encouraging early diagnosis and prompt operation, it is necessary to combat this attitude of pessimism and indifference both in the medical profession as well as in their patients, by demonstrating that surgery can and does give encouragement in a condition which, without operation, has a hundred per cent mortality. For this reason the following three cases are reported:

Case 1. L. S., female, age 53, complained of stomach symptoms and loss of appetite for two years. She had epigastric distress after eating or on exertion, and frequent attacks of vomiting, but vomitus contained no blood or coffee ground material. She had no acute pain. She had noticed a mass in the abdomen for 18 months, and had lost 37 pounds in weight.

Physical examination demonstrated a mass 7 to 8 centimeters in diameter, in the median line of the abdomen just above the level of the umbilicus. The tumor was movable, moving up and down with respiration. Gastric analysis showed absence of free hydrochloric acid. There was no lactic acid or blood present. Roentgenographic examination demonstrated a defect in the outline of the pyloric portion of the stomach, and a marked residue six hours after the bismuth meal.

Operation, St. Luke's Hospital, April 19, 1912. Carcinoma of the pylorus was found. Between one-half and one-third of the pyloric end of the stomach was resected by the Billroth II method. Convalescence was normal.

Pathological report No. 7292: scirrhus carcinoma of the stomach. Duodenal lymph node not involved.

A recent report, November 25, 1917, five years and seven months after operation, states that the patient is in good health, weight normal, diet practically unrestricted, no stomach symptoms.

Case 2. S. S., male, age 30, began to have "water brash" and indigestion twenty months ago. Two months later he started to vomit ten or fifteen minutes after eating. Severe pains began about a year later. The pain was so severe that he could not sleep. It was relieved by vomiting, sometimes by eating. Occasionally eating would cause severe, sharp localized pain in the epigastrium. He had lost 28 pounds in weight.

Physical examination showed no mass, or localized point of tenderness. Gastric analysis proved the absence of free hydrochloric acid. Roentgenographic examination demonstrated an hour-glass stomach due to an ulcer on the lesser curvature near the pylorus.

Operation, St. Luke's Hospital, November 28, 1912. A large callous ulcer of the lesser curvature had perforated, the perforation being closed by dense adhesions to the thinned out edge of the left lobe of the liver, which was so adherent that it could not be separated. The pyloric third of the stomach was resected by the Billroth II method, together with a wedge shaped piece of the edge of the liver forming the base of the ulcer. Convalescence was uneventful.

Pathological report No. 7921: Ulcer of the stomach with carcinoma. No invasion of the liver.

[1]Read before Bergen County Medical Society, April 9, 1918, and the Hartford, Connecticut, Medical Society April 15, 1918.

Report, November 28, 1917, five years after operation. Patient in good health, no gastric symptoms, can eat anything.

CASE 3. Female, age 71, gave a history of gastric disturbance, pain, and epigastric distress for several months, with progressive weakness and loss of flesh. Recently, vomiting had been so persistent that little nourishment was retained.

Physical examination showed an indefinite mass in the epigastric region. No gastric analysis was made. Roentgenographic examination demonstrated a carcinoma of the pylorus with marked retention of the bismuth meal.

Operation, St. Luke's Hospital, September 12, 1912. A carcinoma of the pylorus was found and about a third of the stomach was resected by the Billroth II method. The patient vomited small quantities of bile for several days after operation and there was some drainage from the wound; otherwise convalescence was normal.

Pathological report, No. 7920: Carcinoma of the stomach. Nodes not involved.

Report, December 1, 1917, five years and three months after operation, states that patient is in fair health, although she is over 76 years of age. She has symptoms of arteriosclerosis, but no gastric disturbances or signs of recurrence.

Beside the fact that these three patients have remained free from recurrence for a period of five years or more after operation, each of them presents one or more points of interest.

Case 1 is of special interest because, notwithstanding the presence of a tumor of which the patient was herself conscious for eighteen months before operation, and although microscopical examination demonstrated scirrhus carcinoma, the tumor was not adherent to the surrounding parts, the operation was not technically difficult, and the lymphatic glands in the pyloric region, although enlarged, were not the seat of malignant metastases.

Case 2 presented several unusual conditions. First, the age of the patient, as thirty is a rather early age for the appearance of carcinoma of the stomach. Second, the proof, both from the history and the pathological findings, of the development of carcinoma in the edge of a pre-existing ulcer. Third, the evidence of an old perforation which had been closed by adhesions to the liver, the capsule of which formed part of the new base of the ulcer. Fourth, the technical difficulty of the stomach resection, necessitating a resection of that part of the liver adherent to the base of the ulcer.

The chief interest in Case 3 was the age of the patient, 71 years, and demonstrated that although the patient may be emaciated and weakened as a result of the pyloric obstruction, in the absence of metastases, age is not necessarily a contra-indication to a radical operation.

Having remained free of gastric symptoms for five years or more, it may reasonably be expected that there is a good prospect of permanent cure in these patients. They represent the end-results in a small series of cases of carcinoma of the stomach, in only eleven of which an excision could be performed. Nine were pylorectomies with partial gastrectomies. Of these, two died, one with a complicating postoperative embolic gangrene of the leg. In one other case, I believe that a contributing cause of death was heat stroke, as the operation was performed on one of the hottest summer days, when the temperature was such that better judgment should have deferred any such extensive operation on a patient in poor general condition. Three patients lived for seventeen, thirteen, and six months respectively after operation, dying of recurrences, but all having gained in weight and improved in general condition and having been relieved of pain and vomiting for a considerable time after leaving the hospital. One patient, operated on eighteen months ago, was relieved of symptoms, and gained twenty-eight pounds in weight, but it is too early to foretell the ultimate result, although a recurrence is probable. In one case excision was performed without pylorectomy with a fatal result. In another patient a resection at the cardia ended fatally.

Conclusions based on such a small series of cases would be of little value, but the fact that four cases out of eleven are alive, three of them without symptoms for five years, and one for fifteen months after operation, should do something to dispel some of the gloomy prognoses and encourage further effort.

Progress in the improvement of the treatment of any disease makes its greatest advance with increased knowledge of its etiology, and while the cause of cancer is still to be

discovered, if we knew the actual relationship of ulcer of the stomach to cancer of that organ, it would, perhaps, modify our therapeutic procedure. It is generally conceded that ulcer is a factor in the etiology of gastric carcinoma, but to what degree, is a matter of the widest divergence of opinion. The evidence is exceedingly contradictory. On the one hand are the statistics of the large surgical clinics based on evidence derived from pathological examination of material removed at operation. On the other hand is the clinical evidence offered by many internists based on the absence of previous history of ulcer, and backed by the fact that postoperative histories show that after gastro-enterostomy for ulcer, cancer occurs in only 1 to 5.5 per cent (Kuttner 2 per cent, Kocher 3 per cent, Patterson 3 per cent, Gressot 2.3 per cent, Billeter less than 1 per cent).

The strongest evidence of the development of cancer from ulcer comes from the pathological department of the Mayo Clinic, where, with the passage of time and increased experience, the belief seems to be increasing. Thus, Graham, in 1906, wrote that 15 per cent of all gastric cancers had an ulcer base; while in 1909, Wilson and MacCarty wrote that 71 per cent of gastric carcinoma showed sufficient gross and microscopical evidence of ulcer to warrant labeling them cancer developing on previous ulcer; and finally in 1914, Wilson and McDowell wrote: "It seems probable from the clinical and pathological evidence of this series that gastric cancer rarely develops except at the site of a previous ulcerative lesion of the mucosa."

Of course, the obvious answer to these conclusions by those who disagree with them is to point out the work of Bullock who has shown that under the influence of chronic irritation it is possible to produce lesions in epithelial structures which resemble malignant tissue microscopically; while a removal of the source of irritation is followed by a retrogression and disappearance of the suspicious structures.

The reports from other large surgical clinics, while not all showing so high a percentage as the Mayo Clinic, still show a far higher proportion than claimed by most internists. Thus, Robson, in 1904, stated that in 59.3 per cent, gastric ulcer preceeded cancer. Moynihan, in 1909 reporting on one hundred cases of gastric cancer, states that approximately two-thirds had a history of previous ulcer; Rodman, in 1908, 50 per cent. Payr, in 1910, stated that examination of specimens removed for chronic ulcer showed that 26 per cent showed either beginning, or moderately advanced cancer formation. Kuttner, in 1910; wrote that 43.4 per cent of specimens removed with the operative diagnosis of chronic ulcer proved to be carcinoma on microscopic examination. Pauchet, in 1917, wrote that in 80 per cent of his gastric cancer cases, the cancer had developed on the basis of an ulcer, and the ulcer had seldom been recognized.

The evidence, however, when based solely on the previous history of the patient, is far lower. As a rule, these figures are published by internists, or gastro-enterologists. Thus, Friedenwald, in one thousand cases of cancer of the stomach, found only 23 per cent that gave a history of previous digestive trouble, and only 7.3 per cent in which the history could be interpreted to mean chronic gastric ulcer. Lockwood gives 7 per cent; Stockton, between 5 and 15 per cent; Lindsay, 12.5 per cent, Einhorn, less than 5 per cent; and Boas says: "Such a metamorphosis is not to be numbered among the frequent occurrences." At the same time must be included the statistics of two surgeons. Kuttner, who in 1914, reporting on eleven hundred stomach cases treated in the previous seven years, two-thirds of which were cancer, found that but 15 per cent of the latter had preceding stomach symptoms, and of these he was unable to determine whether they were ulcer, gastritis, or achylia. Peck, in an analysis of 527 cases of gastric carcinoma, treated in several of the large New York hospitals in the five or six years previous to 1917, found that only 19 per cent gave definite long histories of digestive disturbances suggestive of ulcer.

There may be included here, the theory of several German pathologists, as Hauser, Gruber, and Aschoff, who advance the idea that the explanation of the pathological find-

ing of carcinomatous changes in the edge of a stomach ulcer, is rather that the carcinoma precedes the ulcer and causes it by plugging the nutritive vessels with subsequent necrosis and digestion of the carcinomatous tissue. That this pathological process may occur is demonstrated by a report in an article by Wilensky and Thalheimer in which extensive metastases of the regional lymph nodes were found apparently secondary to an ulcer, all evidence of carcinoma in the edges and base of which had disappeared. Their article is based on the microscopical examination of 48 ulcerated lesions of the stomach including 39 chronic ulcers, 7 ulcer-like carcinomatous lesions, one mixed lesion, and the above mentioned case of ulcer with regional carcinomatous lymph nodes. The most important finding in their examination was that 18.7 per cent of these ulcer-like lesions were found to be carcinomatous microscopically, although the fact that they were malignant could in no way be determined by gross examination, and as a result of their examination they believe that these ulcers were probably malignant from the start, and that necrosis and digestion of the carcinomatous tissue is responsible for the belief that cancer is frequently grafted on the ulcer base. This, in connection with the findings of Payr and Kuttner, is of great interest.

Is there any way in which this wide difference of individual opinion can be explained, and which theories are most probably correct?

Every surgeon is familiar with the influence of irritation, ulceration, and precancerous changes in other parts of the body as an etiological factor in carcinoma formation; for example, the lip, tongue, cheek, abdominal wall, sigmoid, etc. Therefore, why is it not probable that an ulcerative process precedes the carcinoma of the stomach as well.

One theory of the development of carcinoma, from an ulcerative process, is that in the course of healing some of the epithelial cells are cut off by the contracting connective scar tissue, and taking on a new process of growth, due to irritation or some unknown cause, these cells proliferate and develop carcinoma. It is in the edges, not the base of the chronic indurated ulcers, that this condition is found. If the destructive ulceration prevents the inclusion of such cells, or if healing occurs without such inclusion, there is no reason why cancer should develop. There is also the theory that an abrasion with circulatory disturbance makes possible the implantation and subsequent growth of some living cause of the carcinomatous growth. Mayo is of the belief that the ingestion of hot fluids by civilized man is a probable explanation of the cause of gastric carcinoma.

As to previous history, the severe pain of gastric ulcer is usually associated with hyperacidity. Frequently alkalies relieve the pain. We know that ulcer of the stomach may exist without hyperacidity or hyperperistalsis. We know that the stomach wall can be incised and sutured without pain in the performance of gastrostomy or gastro-enterostomy after local anæsthesia of the abdominal wall. Is it not possible then, that a more or less passive ulcer of the stomach, if one may use such a term, may exist, without hyperacidity or much pain or other gastric symptoms in the absence of retention? If in the process of repair somewhere in the edge of the ulcer there is an inclusion of epithelial cells, or due to chronic irritation, or whatever the cause may be, carcinoma develops, then only, with the appearance of retention, more extensive ulceration, pain, vomiting, hæmorrhage, or the appearance of a mass, is the diagnosis made. That is to say, the absence of a long standing history of stomach trouble, is not proof that ulcer did not precede carcinoma.

Furthermore, the difficulty of a correct diagnosis of gastric ulcer in some cases, must be recognized. While in the majority of cases the history, physical signs, and laboratory tests make a positive diagnosis possible, every surgeon with any considerable gastric experience, must have operated, after the most careful examination and confirmation of the diagnosis by the best of internists or gastro-enterologists, and still failed to find an ulcer, the symptoms having been caused by hyperacidity, pylorospasm, cholelithiasis, or other lesions. On the other hand, in patients giving a comparatively short history of gastric disorder, an ulcer of such size and induration

may be found that it is fair to assume that it has existed for a considerable time. Also while a previous history of gastric disturbance may be elicited in the majority of cases of perforated gastric ulcer, not infrequently the ulcer may proceed to perforation without causing sufficient pain or other gastric symptoms to cause the patient to seek advice or medical treatment. Again an ulcer may exist, then heal, and a new ulcer or carcinoma develop at a different site.

In a patient upon whom operation was performed about eighteen months ago, an extensive ulcerating carcinoma of the pylorus was found, the carcinoma cells infiltrating the liver substance, which was resected with the tumor. The history in the case dates back between three and four months, and was only one of indigestion, the patient stating that he never had any pain in the epigastrium. Previous to operation a tumor was easily palpable. Whether this carcinoma originated in a callous ulcer or from a papillo-adenoma, a second tumor of which variety was found in the resected portion of the stomach about two inches from the carcinoma, it is impossible to tell. It is, however, difficult to believe that this extensive process had only been developing for less than four months during which the symptoms of indigestion had been present. It is also of interest that the patient absolutely denies ever having suffered any pain.

On the other hand I recently operated on a patient with an hour glass constriction of the stomach due to an ulcer of the lesser curvature, who showed no signs of carcinoma, although the symptoms of ulcer had been present at intervals for sixteen years, and the physician who had treated her states that she had symptoms of a small perforation sixteen years ago. This latter case merely demonstrates the long time an ulcer may have been present with periods of quiescence without becoming malignant.

May not some of these facts furnish an explanation as to why the internist fails to elicit a previous history of gastric ulcer in a large number of his cases of carcinoma of the stomach, and if so, that the surgical statistics based on operative gross and microscopical examination of the specimens removed, are probably more nearly correct? Particularly so where the work of Wilson and MacCarty has enabled them to examine those early cases in which the cell proliferation in the edge, not the base of the ulcer, is just beginning.

The fact that such a small number of cases of carcinoma of the stomach occur after gastrojejunostomy for ulcer, offered as proof of the failure of malignant degeneration, is difficult to explain, but is not absolute proof. Cancer of the stomach and of the large intestine is common, of the small intestine. very rare, although postpyloric ulcer is more frequent than prepyloric ulcer. Of course, the stomach and intestinal contents remain longer in the stomach and large intestine than in the small intestine, and are less fluid, and therefore traumatism and irritation of the mucosa is more likely to occur. It is in those portions of the stomach and of the large intestine—the pylorus, rectum, and flexures of the colon—where trauma or ulceration is most frequent that cancer is most often found. Why, however, is carcinoma of the duodenum so very rare when ulcer is so common, or does carcinoma so rarely occur elsewhere in the small intestine? May it be that some secretion contained in the small intestine has a protective or inhibitory action on the cancer development, and that its entrance into the stomach after gastrojejunostomy also has an inhibitory influence on the promotion of a malignant degeneration of the gastric ulcer, for which the gastrojejunostomy was performed. This theory has been advanced by Gressot, and while considered alone does not seem as probable as that carcinoma does not frequently follow ulcer, but considered with other evidence is not inconceivable, particularly when the Wilensky and Thalheimer case is considered.

As to the theories of Hauser, Gruber, and Aschoff that the ulcer is secondary to the cancer, while it is true that all carcinomata of the gastro-intestinal tract ulcerate, in an extensive cancer the evidence pathologically of its origin in an ulcer would largely be destroyed by the carcinomatous growth.

Moreover, their theory absolutely disregards those cases of old callous ulcer in which a malignant process is just beginning in the edge of the ulcer. As an illustration of this, Mathews reports a case in which a callous ulcer was excised by a pylorectomy. Pathological examination was made and a diagnosis of callous ulcer reported. Subsequent examination of the glands removed demonstrated carcinoma and a later examination of sections cut from the edge of the ulcer showed beginning carcinoma in an area which although very small itself had already resulted in metastases in the lymph glands. Perhaps this and the theory of the preceding paragraph are answered by the sloughing and digestion of the growth as Wilensky and Thalheimer believe account for the findings in their studies.

However, if this is accepted, how can we account for the small number of cases of cancer developing after gastro-enterostomy for ulcer, if such a large percentage of apparent ulcer as 18 per cent as shown by their series is really carcinoma, or 43 per cent of Kuttner's series, or the 26 per cent of Payr's series? One obvious explanation is that it is recognized by surgeons that gastro-enterostomy alone without excision is not curative of ulcers high on the lesser curvature, and posterior wall of the stomach and is therefore not done in these cases, but this does not account for the large number of carcinomata beginning on the lesser curvature near the pylorus.

Coffey, in an admirable review of the subject of gastric and duodenal ulcer, states: "It seems that there is a heavy burden of proof on the advocates of the theory that cancer usually develops on an ulcer base to show that the precancerous ulcer was not really cancer from the start."

This is a fair statement, and it is acknowledged that the proof is difficult; but always remembering that the claim that a large percentage of gastric carcinoma originated in ulcer, should not be interpreted to mean that a large percentage of ulcer cases necessarily develop cancer, it seems in review of the foregoing facts and theories certain conclusions are justifiable.

CONCLUSIONS

1. The conclusions reached by the pathologists of the Mayo Clinic where probably more material from excisions of ulcers and early carcinoma are examined with the greatest care than anywhere in the world, should carry great conviction, even considering the work of Bullock.

2. The considerable but not tabulated reports of cancer in a small area of the edge of an old ulcer, is proof positive that the change does occur, confirming the above statement.

3. The evidence that cancer develops from chronic irritation and ulcers in other locations, adds probability that the same metamorphosis occurs in the stomach.

4. The agreement of those opposed to the theory of carcinomatous degeneration in a large percentage of ulcers that a previous ulcer history may be obtained in from 5 to 17 per cent, together with the facts that diagnosis is not always certain, and that ulcers may perforate without previous symptoms, and that a long ulcer history is not contrary proof, would seem at least to make it a fair presumption that ulcer preceded cancer in a larger percentage of cases than their figures indicated.

5. The results after gastro-enterostomy are, it seems to me, the strongest presumptive evidence against carcinomatous degeneration of ulcers, but an explanation is not inconceivable, based on the rapid healing which usually occurs in ulcers near the pylorus after operation, and the theory of a possible inhibition of cancer formation after gastro-enterostomy according to the previously mentioned theory of Gressot, on the possible digestion of the sloughing carcinoma, and remembering the claim that a large percentage of cancers originate in ulcers does not mean that a large percentage of ulcers necessarily become malignant.

If these facts and theories then make it seem probable that ulcer precedes cancer in a fair proportion of cases, and that a considerable number of cases cannot be differentiated either by history or gross examination, what practical bearing has it on the following facts which are not contested? (1.) The mortality without operation is 100 per cent. (2.) The

percentage of deaths from cancer of the stomach in the total death rate is one per cent. (3.) More than 30 per cent of all cancers occur in the stomach. (4.) Of late years the statistics at the large clinics show an operability of 38 (Mayo) to 39 (Bloodgood) per cent of cases coming to the surgeon for operation.

In addition to combating the idea that there is no hope of even a surgical cure of cancer of the stomach and of doing everything possible to make an early diagnosis of cancer, which is admittedly difficult there is, I believe, an obligation resting on both the internist and the surgeon. A patient with gastric symptoms which does not improve rapidly under treatment should have every means of diagnosis employed to determine the nature of the lesion present. If the diagnosis of ulcer of the stomach can be made and the symptoms cannot be soon cured by medical treatment, or if they recur after treatment operation is indicated. If the patient is over forty the probability of cancer is greater and therefore in such patients a careful examination is imperative, and the X-ray is the greatest assistance in diagnosing these cases of cancer of the pylorus where operative treatment is most successful, and if such cases are referred for operation when the diagnosis is a probable and not a positive one, our operability statistics should be better than 38 or 39 per cent. In addition, unexplained secondary anæmia in a patient over forty should have a careful roentgenographic examination of the gastro-intestinal tract.

It also devolves upon the surgeon to realize that gastric ulcers are potentially cancer, and that a diagnosis macroscopically in the early stage of malignant development cannot be made, therefore, an old callous ulcer in a patient of the cancer age should, when possible, be excised. If small and not believed to be malignant, and only then, it may be destroyed by the cautery method, and a gastro-enterostomy done, or else a transgastric resection or pylorectomy performed whenever it seems even possible that carcinoma has begun at any point in the margin of the ulcer. Thalheimer and Wilensky, after investigation of the subject, conclude that when the regional lymph nodes are not involved and there are no demonstrable metastases, in small carcinomata of the stomach situated elsewhere than at the pylorus, the malignant process is so limited in extent that local resection at a distance of 1 or 2 centimeters beyond the macroscopic limits of the tumor, will in the majority of instances remove the entire tumor.

It has been argued that consistency in those who believe in the frequency of malignant development of ulcer should result in the resection of all ulcers of the stomach, but the small percentage of malignancy developing after gastro-enterostomy would seem to show that resection is not necessary in all cases, if carcinoma has not already developed.

If then, the etiological factor of ulcer as a cause of cancer, and the difficulty of differentiation macroscopically between callous ulcer and cancer even at operation, is borne in mind by both internist and surgeon, and the proper course pursued in respect to painstaking diagnosis in gastric cases, earlier operation recommended and radical procedure carried out when indicated, I believe that the operability of cases coming to the surgeon will be better than 38 to 39 per cent, our mortality will be still lower, and the percentage of final cures higher, while the total death rate from cancer of the stomach will be materially lessened.

DEPARTMENT OF TECHNIQUE

A SIMPLE AND EXPEDITIOUS METHOD OF PERFORMING THE ABDOMINAL INCISION

By P. BROOKE BLAND, M.D., Philadelphia
Assistant Professor of Gynecology, Jefferson Medical College; Gynecologist to St. Joseph's Hospital

THE favorable comments of visiting physicians upon the method we have employed during the last three years for opening the abdominal cavity have been so frequent that I feel justified in presenting an outline of the procedure. We have not the temerity, however, to claim this as a new step in surgical technique, but we have never seen the method employed, nor have we been able to find it described in the literature. This operation was first performed in my presence by Professor E. E. Montgomery about three years ago and thereafter it was utilized exclusively by him in the clinics of St. Joseph's and Jefferson hospitals. For a long time his associates failed to appreciate its merits and hesitated to adopt the method.

The advantages we claim for the operation are that it is distinctly a time saver because it economizes movement and effort on the part of the operator and therefore contributes to the safety and comfort of the one most concerned, the individual operated upon.

With the exception of the knife and the fingers of the surgeon, no instruments whatsoever take part in the incision. The tooth forceps, universally used to pick up the aponeurosis and the tissue forceps or hæmostats still routinely employed in picking or raising up the peritoneum, have been entirely discarded.

TECHNIQUE

The operation is performed as follows: Two ordinary square gauze pads or sponges are doubled or folded upon themselves. One is interposed between the fingers of the left hand of the surgeon and the skin of the patient on the left side, and the other is interposed between the right hand of the assistant and the skin of the patient on the right side. In this manner, the sterile gloved hands of the surgeon and his assistant at no time come in contact with the patient's skin. With the gauze pads in the position mentioned, pressure is made downward and outward in order to render the skin tense. A free incision of desired

Fig. 1.



Fig. 2.

Fig. 3.

Fig. 1. Showing left hand of surgeon and right hand of assistant in position, with gauze pads interposed between hands and skin.

Fig. 2. Skin, superficial fascia, fat, and aponeurosis incised exposing muscle. Fingers of operator and assistant raising layers of abdominal wall.

Fig. 3. Left rectus split in direction of fibers. Layers of abdominal wall elevated. Peritoneum being incised.

length is then made through the skin, superficial fascia and fat down to the aponeurosis. The fingers of the surgeon and his assistants then slide over the margin of the incision having the gauze pads still interposed between the skin of the patient and the thumbs of the operator and his assistant. This precludes the possibility of the fingers coming in contact at any step of the operation with the skin of the patient. The skin and superficial fascia and fat are now grasped between the thumbs and the fingers over the edge or margin of the incision and lifted upward. Free incision of the aponeurosis is made. The recti muscles may be separated in the median line or the right or left rectus may be split in the line of its fibers according to the preference of the operator. When the separation of the muscle is accomplished the fingers of the surgeon and his assistant slip underneath the separated fibers and raise the layers of the abdominal wall. This at the same time lifts and makes tense the peritoneum which can now be readily incised without any danger of injuring the underlying structures.

This method of opening the abdominal cavity is performed in the shortest possible time because it eliminates the use of numerous instruments and gives very rapid access to the organs within. Furthermore, we have used it now for more than three years and have had no instance of injury to any structure since its adoption.

AN OPERATION FOR THE CURE OF INCONTINENCE OF URINE

By HUGH HAMPTOM YOUNG, M.D., F.A.C.S., Baltimore, Maryland
James Buchanan Brady Urological Institute

In 1908 I described a new operation for the cure of incontinence of urine (1) and reported one case which was operated on now ten years ago. The result in this case is so splendid and the operation so successful that I wish again to bring it to the attention of the surgical profession with further clinical reports. As pointed out in my original paper in 1908, there are a few scattered articles bearing on the cure of incontinence of urine to be found in the literature, but no successful procedure, particularly in the male, had ever been carried out or proposed. The method which I presented was, and is, so far as I have been able to discover, quite original.

Since incontinence of urine comes from various causes, a very careful preliminary study is necessary in order to determine exactly the situation present, particularly in regard to the internal and external sphincters, as well as the condition of the posterior urethra and bladder. In the study, the ordinary cystoscope, the cysto-urethroscope, and the tubular endoscope are all quite necessary, and very careful neurological studies are desirable in order to rule out spinal cord lesions. In cases for which this operation is intended, both the internal and external sphincters are found dilated or impaired, and the operation is directed toward the plastic reformation of the injured sphincter and a restoration to normal tonic closure. The operation consists of two stages; first, a suprapubic attack upon the internal sphincter, and second, a perineal attack upon the external sphincter and triangular ligament.

TECHNIQUE OF OPERATION

Suprapubic Operation. With the patient in the Trendelenburg position, a generous incision is made in the median line so that an excellent exposure of the interior of the bladder is obtained. Examination shows the dilated internal prostatic orifice, and in both of my cases there was evidence of division of the vesical sphincter posteriorly, that is, a separation of the cut ends, covered with healed mucous membrane, but leaving a widely dilated internal orifice (Fig. 1). The trigone was also found divided, and separated almost completely into two halves.

The first step of the plastic operation consists of denuding the mucous membrane over the lateral and posterior aspects of the prostatic margin. This is done by means of a long toothed forceps, and curved scissors, and should extend into the posterior urethra and also include some of the vesical and trigonal mucous membrane, so as to leave wide muscular surfaces for approximation (Fig. 1 a).

The suturing is the most difficult part of the procedure. It is necessary that the needle should penetrate deeply into the urethra in order to get firm approximation. With the ordinary needle-holder, such as I used in my first case, the operation was accomplished, but with difficulty. In the

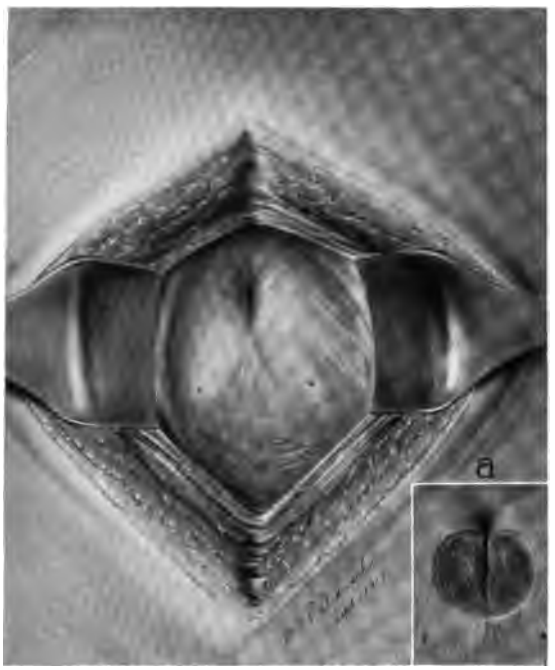

Fig. 1. View of base of bladder showing dilated internal vesical sphincter. Insert *A* shows area denuded of mucous membrane, preparatory to suturing.

second case a new needle-holder, which I have called the "boomerang" (Figs. 8 and 9), on account of its similarity of action, has been employed very effectively. This instrument greatly facilitates the passing of stitches in deep narrow localities, and is especially useful because it causes the needle to penetrate in the direction of the shaft of the needle-holder rather than at right angles, as in the case of most other instruments.

The first suture, of medium-sized chromic catgut, is placed posteriorly and, if the trigone has been divided, includes a part of this, as shown in Figures 2, 3, and 4. Subsequent sutures are placed in the same way, the operator being careful, as remarked above, to have the needle penetrate deeply, and to draw together the urethral surfaces of the internal prostatic orifice. In using my "boomerang" needle-holder, as will be seen at once, one first penetrates deeply with the needle (Fig. 2), the point of which returns like a boomerang through the tissues toward the operator, who then hooks the suture in the eye of the needle with the fingers (Fig. 3) or with a special forceps. The operator then releases the pressure upon the handle, the spring inside of which pushes the inner rod backward, thus drawing the "boomerang"

Fig. 2. Use of "boomerang" needle-holder, showing point of needle about to be inserted into tissues.

needle, with the suture attached, through its track where it is grasped and tied (Fig. 4). Subsequent stitches are placed in the same way, usually starting on the left side from within the urethra out to the bladder, and finishing on the right side, penetrating from the bladder into the urethra, when the suture is picked up and drawn back through the track, thus completing the act. Figure 5 shows finished suture line. Usually four or five sutures are desirable in order to procure a large mass of tissue posterior to the small catheter which has been placed in the urethra, and which is allowed to remain for urinary drainage. Care should be taken not to draw the stitches too tightly. The catheter should be left in place, if possible, for about ten days.

The vescial wound is then closed anteriorly with a continuous mattress suture, leaving a small space at the upper end for a medium-sized drainage tube to emerge, which is fastened to the bladder and also to the skin. The recti muscles and

Fig. 3. The needle has entered the tissues and returned, pointing toward the operator. Assistant hooks suture in eye of needle. (In deep wounds it is necessary to carry the suture down to the needle with a special forceps.)

skin are approximated with through-and-through silver wire sutures, leaving room for a small prevesical gauze drain at the lower angle of the wound. Continuous drainage is supplied by means of the Davis (2) vacuum bottle on the return of the patient to the ward, and suprapubic drainage is maintained for about a month (Fig. 6).

Perineal operation. The patient is now placed in the lithotomy position upon the Halsted perineal board, the legs being well elevated so as to furnish an excellent exposure of the perineum. The incisions are made so as to excise as much as possible of the scar tissue present in the perineum. Usually a long oval incision is made and carried down toward the triangular ligament on each side, until the urethra is approached, the presence of the rubber catheter rendering identification easy. In the dissection in the region of the triangular ligament and external sphincter, care must be taken not to excise too much tissue as it is important to be able to draw together the muscular structures of this region. It is generally desirable to open the urethra and probably excise a small portion posteriorly, as it is usually dilated. The cicatricial tissue around the urethra should be excised as far as possible so as to obtain good muscle tissue for approximation, and it may be necessary to make parallel incisions, one or two centimeters distant from the urethra, in order to liberate external adhesions and free the tissues sufficiently for suturing, care being taken that important nerves and blood vessels are avoided.

The closure of the urethra is then begun. As a rule, continuous medium-sized chromic catgut is

Fig. 4. Needle has been pulled back by released spring in handle of instrument, drawing suture back through tissues.

Fig. 5. Suture line after completion of plastic operation upon internal sphincter.

used, though occasionally interrupted sutures are preferable. After closing the urethra, a second line of sutures is placed so as to include the more muscular structures, and often a third line of sutures is advisable for reinforcement and further approximation. The skin and subcutaneous tissues may be closed completely or with partial drainage at the upper or lower angle of the wound. The external sutures are unimportant, and in fact the skin may be left open for drainage. In some of these cases very little healthy muscle is found in

Fig. 6. Davis vacuum apparatus for maintaining suprapubic drainage. The larger bottle, the air from which is exhausted with a laboratory filter pump every 48 hours, maintains a very slight but constant suction in the urine bottle, which keeps the bladder empty and the incision dry.

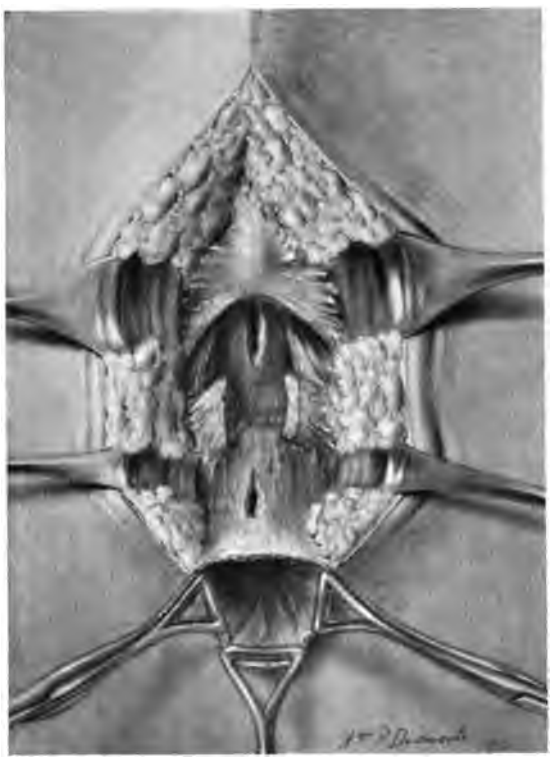

Fig. 7. Stage in the operation for the radical cure of recto-urethral fistula, as described by Drs. Hugh H. Young and Harvey B. Stone. The rectum and urethra have been separated, and the former dissected free and pulled down, showing a fistulous opening in each. This picture shows the sphincter ani temporarily divided, which procedure was not found necessary in the operation upon Case 2.

the region of the triangular ligament and external sphincter, but it is a rather remarkable fact that, after being drawn together normal function of the external sphincter occurs, regardless of the poor prospects.

POSTOPERATIVE TREATMENT

As indicated above, the retained urethral catheter is kept in place, if possible, for eight or ten days. If pronounced urethritis occurs, it may be desirable to remove the catheter sooner. If infection of the perineal wound occurs, removal of external stitches so as to avoid concealed suppuration, is desirable and frequent careful cleansing of the wound should be maintained, and the vacuum bottle and accessories devised by Dr. E. G. Davis, as shown in Figure 6 is most helpful and satisfactory in maintaining a dry suprapubic incision.

During the third week after the operation it is desirable to insert a small coudé catheter into the

Fig. 8. Photograph of "boomerang" needle-holder.

bladder through the urethra to prevent closure of the wounds in the region of the external as well as of the internal sphincter. If the coudé catheter meets obstruction, a filiform and LeFort follower may be passed, care being taken not to use any force, so as to avoid tunneling the artificial posterior median bar which has been temporarily produced by the internal sutures. Dilatation up to No. 22-F or 24-F is sufficient at first. Subsequently, passage of filiforms and followers up to No. 28-F, every three or four days, is desirable so as to avoid stricture-formation. In one of my cases there was no attempt at stricture-formation and very little dilatation was necessary.

The subsequent treatment consists in efforts on the part of the patient to educate and strengthen his sphincter system by voluntary exercises during urination (stopping urination several times during each act voluntarily so as to practice the sphincter musculature).

CLINICAL RESULTS.

CASE 1. The patient, aged 38, had complete incontinence of urine night and day, following perineal urethrotomy, which had been performed one year previously on account of frequent urination and severe pain in the bladder. The operation had not relieved the pain and had produced incontinence. The prostate was not hypertrophied, a slight stricture was present at the bulbomembranous region, but filiforms and followers were easily passed. The bladder held 325 cubic centimeters; no residual urine. The tubular urethroscope showed a dilated posterior urethra; verumontanum red and swollen. In the region of the external sphincter there was a long wide slit posteriorly, and there was no central point of closure, but the sides of the urethra were approximated loosely on each side, showing that the sphincter had been divided posteriorly.

Operation was carried out on January 6, 1907, according to the technique previously described. The vesical orifice was found to be gaping, so that the index finger could be easily introduced, and it was evident that the sphincter had been divided posteriorly, and the mucous membrane had healed over the cut. Examination showed what seemed to be the end of the sphincter on each side. These were caught up with tenaculum forceps, the mucous membrane denuded posteriorly and laterally, and two catgut sutures placed so as to draw the muscles well together and reproduce a well-closed sphincter. In so doing a small artificial median bar was produced. A large mass of scar tissue was found in the perineum, extending from the cutaneous scar, which was quite broad, to the urethra itself, and from the posterior part of the bulb along the membranous urethra to the anterior portion of the prostatic urethra. Since the median incision through this scar tissue showed no evidence of muscle adjacent to the urethra, a considerable mass was therefore excised on each side, together with

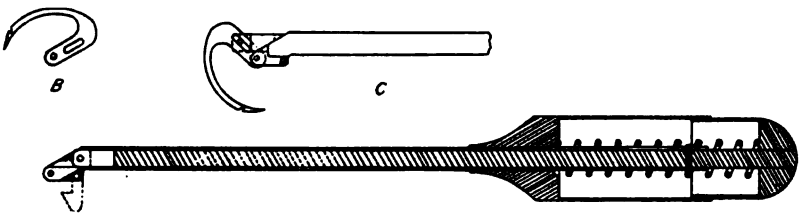

Fig. 9. *A*, Longitudinal section of "boomerang" needle-holder (with needle detached) showing spring in handle which is compressed by the hand to cause the point of the needle to penetrate into the tissues and return toward the operator, and which when released draws the needle back through its tract. *B*, Free needle; *C*, method of attachment of needle, which is held in place by means of a small clasp, shown opened in *A*.

some urethral mucous membrane which was very redundant and thick. At no place did the urethra come together as if there were sphincter surrounding it. This dissection was carried well out on each side until healthy looking muscle was reached, it being necessary to go for a distance of about one centimeter. On the left side a definite sphincter-like mass was found. On the right it was not so definite, the fibers appearing longitudinal rather than circular. Healthy looking muscle was also obtained on each side well down toward the prostatic apex. The mucous membrane was drawn together with three sutures of catgut at wide intervals, muscular tissues were then brought together with necessary sutures of catgut, care being taken in the region of the membranous urethra, to obtain good muscle for approximation. Perineal drainage was provided by means of a small catheter which emerged from the anterior angle of the wound into the bulbous urethra.

Convalescence. The patient, who was addicted to morphia required 19 to 25 grains daily, for almost a week. On the tenth day the perineal urethral drainage tube was removed, after which all urine passed through the suprapubic drainage tube. On the eighteenth day the perineal wound was entirely healed, and the patient voided a small amount of urine through the urethra. February 9, 1907. Suprapubic tube removed. Patient voiding urine through the urethra without pain, no incontinence, stream small. February 14, 1907. Suprapubic wound closed. Patient voiding through the urethra without pain. February 25, 1907. Evidence of urethral stricture present. Filiform and followers passed, after which patient voided much more freely. May 17, 1907. After dilatation on March 29, patient had slight incontinence for four days. He is now able to retain urine for six hours, voids freely, no pain, good stream, has taken no morphia for four weeks. Is discharged in good condition.

June 25, 1907. Filiform and followers passed on account of slight stricture. Patient retains urine all night without voiding. There is no incontinence. Has taken no morphine.

November 21, 1907. A letter states that the result is almost perfect. He voids urine only once at night, the stream is a little slow in starting, but urination is usually free. He is cured of the drug habit. November 25, 1916. "I have had no sounds passed during the past nine years. I can hold urine four hours, stream good, void urine more frequently at night, am in business and enjoy good health."

CASE 2. C. C. aged 25, single, was first admitted October 25, 1910, complaining of pain in the perineum. He had had gonorrhœa about eight years previously, and for one year had had symptoms of prostatic irritation and diminution in sexual power. Examination showed prostatitis and verumontanitis, for which he received local treatment.

Contrary to my advice he had a prostatectomy performed elsewhere, and returned to me a few months later complaining of greatly increased burning, and incontinence of urine. He said that an attempt had been made in Chicago to remove the prostate through the perineum, and that he had been very much worse since. There was almost continuous incontinence. The cystoscope showed that both the internal and external sphincters had been divided and had failed to close. Local treatment was given but failed to relieve the burning, and urethral dilatation and muscle exercises for the sphincters did not help the incontinence.

The patient then left me again and returned to another surgeon, who operated again through the perineum, and when he came back he not only had incontinence and burning, but also a recto-urethral fistula.

April 9, 1914, Cystoscopic examination showed the internal sphincter had been divided posteriorly. The verumontanum was not seen. The connection with the rectum could not be made out. The internal sphincter was apparently wide open, anterior part showing as a sharp semilunar curve, almost like a septum; posterior portion irregular and mucous membrane redundant. The external sphincter also failed to close, and when the patient was instructed to attempt to close his sphincters neither internal or external sphincter became completely closed. Rectal examination showed a fistulous opening about 2 centimeters within the anal margin. April 4, 1916, urethroscopy. No. 28-F, urethroscope passed with ease into the bladder. Just in front of the vesical orifice the lateral lobes were a little more rounded than normal. The median portion was depressed, and it was evident that the internal sphincter had been injured posteriorly. The floor of the urethra was irregular, and as the urethroscope was drawn outward, urine continually escaped from the bladder. The utricle and ejaculatory ducts could not be found. The external sphincter was dilated, forming a vertical slit instead of a central figure.

April 4, 1916, Cystoscopy. With the posterior cystourethroscope the internal sphincter was seen to be dilated. The lateral lobes were a little more rounded than normal. and the median portion much depressed; evidently considerable tissue absent in this region. When the instrument was withdrawn into the posterior urethra, the latter was found to be very irregular, with depressions along the floor, and the verumontanum could not be seen. There was a great deal of scar tissue present. A depression was seen in the anterior part of the posterior urethra, and another small opening just behind the external sphincter, one or both of which probably connected with the rectum.

Patient still complained of constant incontinence, escape of urine into the rectum, and gas through the urethra, and a severe burning pain.

April 5, 1916. *Operation. Young.* (1) Suprapubic cystostomy. Plastic operation to repair dilated internal sphincter. (2) Perineal excision of scar tissue. Excision of cuff of rectum with rectum with rectal fistula. Closure of opening into posterior urethra. Excision of scar tissue posterior to external sphincter. Plastic operation to repair external sphincter.

Suprapubic operation. The prostatic orifice was found to be widely dilated with loss of tissue posteriorly, and the scar extended backward in the shape of a shallow trough to the posterior line of the trigone, which had evidently been completely divided.

The muscles of the trigone and median portion of the prostate were evidently widely separated, and the index finger could be inserted with ease into the posterior urethra. With scissors the orifice was denuded of mucous membrane posteriorly and on each side, leaving only a small portion anteriorly where the mucous membrane was retained. This excision was carried deep enough to remove most of the scar tissue. With the boomerang needle-holder, four sutures of fine chromic catgut were placed, beginning posteriorly. No urethral drain was provided. The repair sutures produced a distinct median bar which elevated the prostatic orifice considerably and left a very small opening into the posterior urethra. Suprapubic drainage was provided as usual.

Perineal operation. A racquet-shaped incision was used, the posterior portion encircling the anus as in the operation for recto-urethral fistula, which has recently been reported by Dr. Harvey Stone and myself. The scar tissue in the perineum was excised until the urethra was reached, leaving a fairly large opening in the midline which extended back, and included the connection between the rectum and urethra. The sphincter ani was not divided, but was pushed backward while operating upon the urethra, and drawn forward while operating upon the rectum. The rectal cuff was freed on all sides from within the sphincter, which was well preserved, and the fistulous tract having been divided, the cuff was drawn downward until the fistula had been drawn beyond the skin level, where the cuff bearing the fistula was excised. Figure 7 shows the perineal dissection completed, the rectum and urethra separated, and a fistulous opening in each, the rectum having been freed and pulled down. Previous to this the urethra had been closed with five interrupted stitches of fine chromic catgut, and the perineal sphincter muscles had been drawn together with several stitches of chromic catgut, the anterior mucous membrane was then sutured to the skin as in the Whitehead operation and the perineal wound was partly closed, leaving a small area for drainage.

Convalescence. The patient made an uneventful recovery and was discharged from the hospital in 37 days. He was then able to retain urine for three or four hours, voided freely, and had absolutely no incontinence. No sounds, filiforms or followers were passed on the patient at any time after the operation.

About two weeks later the patient returned and examination showed continued improvement. He was able to retain urine five hours, had no incontinence, voided freely and without difficulty.

May 17, 1917. Patient returns for examination. He reports that he is able to retain urine six hours. Sometimes does not get up at all at night to urinate, occasionally once or twice, voids freely, good stream, no pain. Has had no incontinence since operation, and no evidence of rectal fistula. Still has slight burning pain in the prostatic region, and the urine is cloudy with some pus present. General health is excellent.

Remark. The operation in this case, preceded as it was by two previous perineal operations, and complicated by the presence of recto-urethral fistula, is a splendid example of what can be accomplished by this plastic operation upon both the internal and external sphincter in the cure of long-standing incontinence.

CONCLUSION

It seems definitely shown by these two cases that incontinence of urine of long duration in which both internal and external sphincters have been destroyed by previous operative trauma, can be cured by plastic operations upon the internal and external sphincters, and patients in this hopeless condition restored to health and usefulness.

REFERENCES

1. YOUNG, H. H. Suture of the urethra and vesical sphincters for the cure of incontinence of urine, with report of a case. Tr. South. Surg. & Gynec. Ass. 1908. xx, 210.
2. DAVIS, E. G. Vesical drainage—historical review and presentation of a new apparatus. J. Am. M. Ass., 1916, lxvi, 1680.

A SIMPLE METHOD OF DRAINING THE BLADDER AFTER SUPRAPUBIC PROSTATECTOMY

By E. DENEGRE MARTIN, M.D., F.A.C.S., New Orleans

In the December, 1917, issue of Surgery, Gynecology and Obstetrics, Norman H. Beal, of London, Ontario, describes a method of draining the gall-bladder after suprapubic operations. For years I used the identical apparatus which was presented at the Atlanta meeting of the Southern Surgical and Gynecological Association in 1900. A full description of it will be found in the transactions of that meeting. More recently I have used a much simpler method which works on the same principle, but does away with the paraphernalia necessary for the priming. All that is necessary is a large catheter, *A*, and a piece of rubber tubing, *B*, ½ inch in diameter, long enough to reach from the fundus of the bladder to a point one inch above the skin. Several small holes are cut in the tube near the end to be placed in the bladder, *C*, and one at the level of the skin, *D*, large enough to insert the catheter snugly so that the urine will not escape. The catheter is pulled through this opening to about ½ inch from the bottom of the large tube, *E*, the tube is introduced into the bladder and the wound closed tightly around it. As soon as the urine rises in the tube above the point where the catheter is inserted, *D*, it will prime the catheter and empty the bladder. It is simple and most effective. This apparatus, like others of its kind, needs intelligent handling. In flushing the bladder the fluid is sent through the catheter and flushes the large tube, cleansing the bladder at the same time. This drain is used until the urine is free of blood-clots and necrotic tissue. When removed a pezzer catheter is inserted and kept in the bladder as long as necessary.

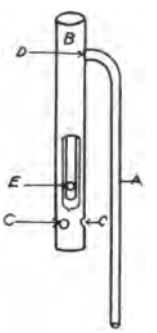

BOOK REVIEWS

A CRITIQUE OF NEW BOOKS IN SURGERY

IN the past there has been much to say regarding extensive systems presenting surgical or medical topics. The chief disadvantage to such works has been that the volumes are bulky and an almost endless amount of time is consumed in preparing an edition for the press, with the result that when finished a considerable amount of material has become antiquated and at the best the work is incomplete. Revisions were infrequent and due to expense entailed resales were few. No doubt there is a field that can be covered only by systems. The apparent solution of the problem is found in the new and novel work by the Oxford Press, volume I of which has been received.[1] The publishers have undertaken a great task and apparently have succeeded. This system is to consist of five volumes and is a complete revision of the *Burghard System of Operative Surgery*, bound in loose leaf form. It is the plan of the Oxford Press to supply quarterly supplements which can be inserted by the owner of the treatise. The pages to be replaced can be removed and the new pages supplied inserted. In this manner the publishers intend to keep the system revised to date and keep all material fresh. In due course of time many of the present chapters will be entirely replaced and the system will keep pace with the progress in surgery.

The revision shows the hand of the American editor. There is scarcely a chapter which has not seen a radical change, unless it is the one on amputations. Many new topics have been added and new illustrations procured. American methods have been introduced and the system now has the unique position of containing the best of the English and American technique. There has been considerable rearrangement of the text, and some material found in volume I of the former edition will appear revised in other volumes. The chapter on functional treatment of fractures, diseases and injuries to joints, has been placed at the close of volume I and should not be understood to represent the treatment of fractures and joint pathology. Much space will be devoted to these subjects in another volume.

The publishers should be congratulated on the unique binding. The volume appears as a handsome work bound in durable cloth with rounded back, not in any way resembling the usual loose leaf book. The arrangement for inserting new pages is very simple. The new volume appears closely bound but as one uses the book the binding loosens up and the book opens as easily as with the ordinary binding.

Now that the war is over much new literature will find its way into journals. Much that is new in technique will be revealed, many statistics and experiments will be tabulated. It would be impossible to have any extensive system under the old form which could incorporate all. With the loose leaf form, quarterly supplements which are up-to-date can be supplied to replace, revise, or supplement the text. In this manner the *Oxford System* can be kept fresh, clean, to date. The work speaks well for the American editor. J. A. W.

EVERY surgeon has been obliged to seek advice and consultation and how often has he been disappointed when he has been unable to obtain the help he so desired. This applies especially to the surgeon located in communities distant from the large medical centers, the consultant in these cases being works supposed to give complete information on the subject in question. Monographs which are exhaustive, and how few are exhaustive, are the solution of the problem. The work of Frazier[2] occupies a unique place in the surgical literature. The author states in the preface that "it has been my purpose to deal with the subject so comprehensively that it will not be necessary for the reader to consult collateral works." He has most assuredly accomplished his purpose. Every phase of the embryology, anatomy, physiology, pathology, and surgery of the spine and spinal cord, has been presented in detail. In no field of surgery is concise knowledge and information more valuable or necessary than in that of diseases and injuries of the spine and spinal cord. Many of the facts are so complex that it is beyond the mental scope of man to retain them, and a monograph which contains these in full and accurate form, is surely valuable. Neurological cases are notorious for their mysterious manifestations and ever changing characteristics. This is the realm of speculation, speculation with thought and wisdom, the latter obtained by close observation and the help derived from the experiences of the masters. The author by his endless efforts, his keen desire for knowledge and his untiring enthusiasm for neurological surgery has placed before the

[1] OXFORD LOOSE-LEAF SURGERY. By various authors. Edited by F. F. Burghard, M.S. (Lond.), F.R.C.S. (Eng.), Colonel A.M.S., and Allen B. Kanavel, A.B., M.D., F.A.C.S., Colonel, M.C., U.S.A. New York: Oxford University Press (American Branch), 1918.

[2] SURGERY OF THE SPINE AND SPINAL CORD. By Charles H. Frazier, M.D., Sc.D. With the collaboration of Alfred Reginald Allen, M.D. New York and London: D. Appleton & Co., 1918.

profession of the world a landmark in the surgical literature. There is no monograph before the profession today known to the reviewer which specifically treats a topic so thoroughly and with such striking accuracy. One might conscientiously prophesy that many years will elapse before it will be replaced or supplanted. J. A. W.

VOLUME II of the system of urology edited by Cabot[1] referred to in a previous issue comes well up to the standard adopted in volume I. This volume is devoted to the bladder, the ureter, and the kidney. It is pleasing to note that phenomena concerning the urinary act are discussed and some information ventured regarding the mechanism. The chapter devoted to functional tests of the kidney is excellently written and will afford a most valuable asset to any man even though he be a general practitioner, an internist, or a general surgeon. No organ plays a more important rôle than the kidney and to have means at hand to determine its functional activity is surely valuable. The frequency of confusion in the diagnosis of acute or subacute abdominal conditions, impresses one with the necessity of close observation to all organs lying within or adjacent to the peritoneal cavity. How often is an innocent appendix removed when the patient is suffering from urethral calculus or pyelitis. It behooves every medical man to avail himself of information which will enable him if possible to avoid such, we might say gross, errors. Every practitioner must know urology to a certain extent in order that he may call upon the urologist for that assistance which may mean the health or even life of the patient. The work can truly be called the urologist's test and the practitioner's professional aid. J. A. W.

THE rapidly terminating great war has been a tremendous stimulus to the profession to advance the sciences of medicine. No sooner was the first campaign well under way than the surgeons of France, Belgium, and England, as well as those of the enemy, were confronted with almost unsurmountable obstacles. Due to the multitude of injuries, practically all infected, many extensive and mutilating due to high explosives, it was at once realized that much had to be done to cope with such a catastrophe. Immediately the surgeon put his shoulder to the wheel. The untiring efforts of these undecorated heroes bore fruit. Many theories were put into practice; some were good, others did not come up to the expectations of the instigator. Soon there began to appear articles and papers giving the results in the various fields of study and experiences. All were intensely interesting as they told the story of gruesome destruction and of the conquering effort. It is an almost endless task to be able to obtain all the interesting documents as many appeared only in the French, Belgian, Italian, and English journals and were never translated. This brings me to the little volume[2] which was intended for the medical officer, to supply him with brief abstracts of the important war topics of the day. It consists of abstracts of articles, dealing with war surgery taken from the French, English, Italian, Belgian, and early German journals. Several articles are practically complete as they did not permit of much condensation.

The subject matter is divided into sections, devoted to general topics, wound infection and treatment, tetanus, gas gangrene, abdomen, chest, cardiovascular surgery, joints, fractures, burns, anæsthesia in warfare, trench foot, foreign bodies, peripheral nerve injuries, and jaws and face. It is the reviewer's impression that most of these abstracts are taken *in toto* from the INTERNATIONAL ABSTRACT OF SURGERY, and consequently the readers of this journal have probably read the greater part of this volume. Owing to the necessity for the civil application of many of the procedures adopted in warfare every surgeon should acquaint himself with what has been done abroad and in no way can he so easily procure the ready information as in this little volume. J. A. W.

THE volume[3] represents the highest development of the monographic type of bookmaking. The time is rapidly arriving, if it has not already arrived, when even the general worker in medicine and surgery will be obliged to rely more strongly on special monographs than on general textbooks. Of the monographs already published, none merit a more definitely fixed position in the library of the student and practitioner than the special volumes that Cushing has gotten out.

A very brief abstract outlining the material considered in this work will be found in the INTERNATIONAL ABSTRACT OF SURGERY this month, p. 39. C. B.

"SUSPENSION in the Treatment of Fractures," by P. Desfosses and Charles-Robert.[4] is one of the Horizon Series of monographs devoted to war medicine and surgery published by Masson et Cie during the present year. A preface by Pierre Duval, surgical consultant in the French medical service, adds weight to the undoubted excellence of the monograph.

There had been up to the time of its publication no complete description in French of the methods of continuous suspension and extension in the treatment of fractures accompanying war injuries, but Robert had made use of this method for a year in the service of *Auto-chir* (surgical ambulance)

[1] MODERN UROLOGY. In original contributions by American authors. vol. ii. Edited by Hugh Cabot, M.D., F.A.C.S. Philadelphia and New York: Lea & Febiger, 1918.

[2] ABSTRACTS OF WAR SURGERY. An Abstract of the War Literature of General Surgery that has been published since the declaration of war in 1914. Prepared by the Division of Surgery, Surgeon General's Office. St. Louis: C. V. Mosby Company, 1918.

[3] TUMORS OF THE NERVUS ACUSTICUS AND THE SYNDROME OF THE CEREBELLOPONTILE ANGLE. By Harvey Cushing, M.D. Philadelphia and London: W. B. Saunders Company, 1917.

[4] LA SUSPENSION DANS LE TRAITEMENT DES FRACTURES. By Desfosses and Charles-Robert. Paris: Masson et Cie, 1918.

No. 21, and was a direct pupil of Major Sinclair, R.A.M.C., the general organizer of this treatment in the British army.

While the greater part of the book is a description of methods and appliances which have been in well known use in hospitals on the western front, it is only fair to say that the description is remarkably well done, with a wealth of detail and illustration which serve to make every stage of the technique perfectly clear. All the recognized types of splints applicable to this method, and the various forms of suspension apparatus — Blake, Balkan, Sinclair frames — are treated in a concise and at the same time comprehensive way, reviewing all possible combinations necessitated by the site and nature of the fracture.

Total suspension of the patient in high fractures of the thigh or in resections of the hip-joint, as carried out by Robert in the *Auto-chir*, and the organization of a special fracture service for general treatment by suspension are new developments as is also radioscopic examination of the patient in his own bed, allowing frequent correction of the position of the bone fragments under the eye of the surgeon.

Duval agrees with the authors in preferring the Thomas splint to other types both as a means of primary immobilization and as an excellent and practical apparatus throughout the course of treatment. He aptly says: "Henceforth no more straw, spring rollers, ramrods, broomsticks or guttering to immobilize the wounded limb in the regimental formations or ambulances. All these ought to be eliminated and remain in our memory only as an unhappy recollection of their hitherto regular use. . . . The book of Desfosses and Robert" he concludes, "born of a very large experience in the army, ought to be the constant guide of all those who, at the front, are charged with the reception and evacuation of fracture cases, of all those who want to use in the treatment of fractures the excellent method of suspension, combined with continuous extension."

It is hoped that a translation of the monograph into English will soon be forthcoming. H. G. W.

BOOKS RECEIVED

Books received are acknowledged in this department, and such acknowledgment must be regarded as a sufficient return for the courtesy of the sender. Selections will be made for review in the interests of our readers and as space permits.

GENITO-URINARY DISEASES AND SYPHILIS. 4th ed., revised and enlarged. By Henry H. Morton, M.D., F.A.C.S. St. Louis: C. V. Mosby Company, 1918.

THE SURGERY OF ORAL DISEASES AND MALFORMATIONS, THEIR DIAGNOSIS AND TREATMENT. By George Van Ingen Brown, D.D.S., M.D., C.M., F.A.C.S. 3d ed. Philadelphia and New York: Lea & Febiger, 1918.

THE CANADIAN MEDICAL WEEK, HAMILTON MAY 27 TO JUNE 1, 1918. Published under the auspices of the Ontario Medical Association. Toronto: The Macmillan Company of Canada, Ltd., 1918.

THE DOCTOR'S PART. WHAT HAPPENS TO THE WOUNDED IN WAR. By James Robb Church, A.M., M.D., Colonel M.C., U.S.A., with foreword by Major General William C. Gorgas, Surgeon-General, U. S. A. New York and London: D. Appleton & Co., 1918.

THE DISEASES OF INFANCY AND CHILDHOOD. By Henry Koplik, M.D. 4th ed., revised and enlarged. Philadelphia and New York: Lea & Febiger, 1918.

ROENTGEN DIAGNOSIS OF DISEASES OF THE HEAD. By Arthur Schueller. Authorized translation by Fred F. Stocking, M.D., M.R.C. St. Louis: C. V. Mosby Company, 1918.

DISPENSARIES; THEIR MANAGEMENT AND DEVELOPMENT. A book for administrators, public health workers, and all interested in better medical service for the people. By Michael M. Davis, Jr., Ph.D., and Andrew R. Warner. M.D. New York: The Macmillan Company, 1918.

TUMORS INNOCENT AND MALIGNANT; THEIR CLINICAL CHARACTERS AND APPROPRIATE TREATMENT. By Sir John Bland-Sutton, LL.D., F.R.C.S. 6th ed. New York: Paul B. Hoeber, 1918.

TRANSACTIONS OF THE SOUTHERN SURGICAL ASSOCIATION. Vol. XXX. Thirtieth Session, St. Augustine, Florida, December 18, 19, 20, 1917. Edited by H. A. Royster, M.D. Published by the Association, 1918.

THE MEDICAL CLINICS OF NORTH AMERICA. Volume ii, Number 1. (The New York Number, July, 1918.) Philadelphia and London: W. B. Saunders Company, 1918.

PHYSIOLOGY AND BIOCHEMISTRY IN MODERN MEDICINE. By J. J. R. Macleod, M.B., assisted by Roy G. Pearce, B.A., M.D. St. Louis: C. V. Mosby Company, 1918.

AMERICAN COLLEGE OF SURGEONS

DOCKET OF THE REGENTS AND OTHER NOTES

PROPOSAL FOR MEMBERSHIP IN COLLEGE

WITH world peace in sight and the probable early return of about one-third of the Fellows of the College from military service to private practice, the Regents of the College have prepared a docket in order to consider lines of progress for the College during the coming year. This docket which will be acted upon at an early date is of interest to the entire medical profession. Two characteristics of it stand out: First, every proposal in it carries a direct aim to better the practical life of Canada and the United States as well as to advance the scientific, economic, and ethical standards of the profession; second, a wholesome readiness evidently exists on the part of the College to co-operate with other medical organizations and agencies which make for similar aims. Probably the most important proposal in the docket is one looking to membership in the College. The fact that the College has on file about 9,000 applications for Fellowship undoubtedly has a bearing in this matter. The object of the provision for membership is briefly stated as follows:

First, the encouragement of more thorough training in surgery and of higher standards of practice among younger men, most of whom will eventually become Fellows of the College. Second, extension of the direct influence of College to surgeons in the making—at a time when most of these men are not eligible to Fellowship and at a time when they will derive the greatest benefit from the influence of the College. Third, advisability of advancing the standard of efficiency for admission to Fellowship in the College without lessening its influence by a resultant tendency toward exclusiveness.

In this connection these figures are pertinent: Population in England and Wales, 40,000,000; number of doctors, 35,000; Fellows in Royal College of Surgeons, 1,581; members in Royal College of Surgeons, 16,040. Population in Canada and United States, 110,000,000; number of doctors, 159,444; Fellows in American College of Surgeons, 3,941; members in American College of Surgeons, none.

Chief points suggested in consideration of the provision for members are graduation from a creditable medical school and service as an interne for at least one year; moral and ethical fitness as required for admission to Fellowship, same to be approved by the respective provincial and state credentials committees; approval of candidates for admission to Fellowship by examination to entitle candidates to membership in the College.

Hospital Service Bureau

The work of the College during the past year among hospitals, and the hearty co-operation of the hospitals in this work, bring now the forcible proposal that the College establish a hospital service bureau. The object of this bureau is to give assistance to individual hospitals upon request, covering the sum of things which make for hospital efficiency. For example, the service of the bureau would co-operate with hospitals upon such subjects as right standards of training, faithfulness to duty, and character requisite for the privilege of practice in hospitals; plans for new hospitals, reconstructions, and additions; equipment and upkeep of hospitals; organization of the hospital board and of the staff; study of sources of hospital income; adjustment of hospital service to needs in community; cost accounting and business methods; adaptation of case records and of laboratories to needs of hospitals; encouragement of research and of helpful analyses of clinical work in the hospital.

HONORARY FELLOWSHIPS CONFERRED IN NEW YORK

BECAUSE of the prevalence of influenza throughout Canada and the United States, it was considered by the Regents imperative, on October 12, to cancel all of the meetings of the College scheduled to be held in New York for the week beginning October 21. These meetings included the Clinical Congress, the Convocation, and the hospital conference.

In the meantime, the surgeons from England, France, and Italy who accepted invitations of the College to take part in the Clinical Congress week had sailed for New York. They arrived in New York on October 19. These surgeons were:

Sir Thomas Myles, C. B., Dublin, Honorary Surgeon to His Majesty King George; Consulting Surgeon, Irish Command; Member Board of Consultants, British War Office; and Senior Surgeon, Richmond Hospital, Dublin.

Lieutenant Colonel Raffaele Bastianelli, Italian Army Medical Corps, Rome; Surgeon-in-Chief, First Pavilion, Hospital Policlinico Umberto I; Associate Professor of Clinical Surgery, Royal University.

Major Pierre Duval, French Army Medical Corps; Consulting Surgeon to Seventh Army; Honorary Professor, Faculty of Medicine, Paris.

Colonel George Ernest Gask, D. S. O., London; Consulting Surgeon, British Expeditionary Forces; Joint Lecturer on Surgery, St. Bartholomew's Hospital, University of London; Surgeon in Charge of Out-Patients, St. Bartholomew's Hospital.

Major George Grey Turner, Royal Army Medical Corps, Newcastle-on-Tyne, England; Honorary Assistant Surgeon, Royal Infirmary, Newcastle-on-Tyne; Lecturer on Surgery, University of Durham.

Major Adrien L. P. Piollet, French Army Medical Corps.

Major Henry Beclére, French Army Medical Corps.

Lieutenant Colonel George E. Brewer of New York, at the time in service in France, came with these guests of the College as the official representative of the medical corps with the American Expeditionary Forces.

In order that the value of the messages which these visitors brought from the allied lines at the front might not be lost as a result of the cancelled meetings, the College arranged promptly to have these men visit as many of the surgical centers in this country as their brief stay would permit. These visits included Washington, where the visitors were greeted by President Woodrow Wilson; Camp Greenleaf, Georgia; Minneapolis; Rochester; Chicago; Pittsburgh; Philadelphia; and New York.

On the evening of November 6 at a dinner arranged by the Fellows of New York City, through Dr. J. Bentley Squier, honorary fellowships were conferred upon Surgeon General Merritte W. Ireland, United States Army; Sir Thomas Myles, C. B.; Lieutenant Colonel Raffaele Bastianelli; Major Pierre Duval; Colonel George Ernest Gask, D. S. O.; and Major George Grey Turner. The honorary fellowships were conferred by Colonel William J. Mayo, President of the College. Dr. George David Stewart was toast-master of the occasion.

CANADIAN FELLOWS EXPRESS THEIR EQUATION

THE surgeons of the comb. ed surgical section of the Ontario Medical association and of the Canadian Medical association which met at Hamilton, Ontario, in September, took action of vital significance to the medical profession and to the welfare of life in Canada. The section as stated passed unanimously the following resolutions:

Be it Resolved, that we the Surgical Section of the combined meeting of the Ontario Medical association and the Canadian Medical association desire to go on record as approving the efforts being made by the American College of Surgeons to improve the status of surgical practice in our hospitals . . . that the right to attempt major surgery should be restricted to those who are recognized as having scientific training, experience, sound judgment, and honesty of purpose . . . that examinations for diagnosis and for treatment should be much more closely associated with clinical laboratories than they are at present. . . .

Be it Resolved, That copies of the above resolution be sent to the American College of Surgeons to the Commissioner dealing with the medical matters in the Province of Ontario; to the universities teaching medicine in Canada; and to the Dominion Medical Council and the licensing bodies in Canada.

MILITARY SERVICE OF CANADIAN FELLOWS

THE directory of the College for 1918–19 will designate the military service of the Fellows. In this connection an inspiring fact comes from Canada. Of the 176 Canadian Fellows 126, or 71.6 per cent, of them have within the past four years been in the military service of their government.

ANNUAL SUBSCRIPTION: UNITED STATES AND CANADA, $10.00; FOREIGN, $12.00 (£2 10s.)

Volume XXVIII FEBRUARY, 1919 Number 2

Surgery, Gynecology and Obstetrics

WITH

International Abstract of Surgery

EDITORIAL STAFF

FOR AMERICA

William J. Mayo, M.D.

E. Wyllys Andrews, M.D. J. Clarence Webster, M.D.

L. L. McArthur, M.D. E. C. Dudley, M.D. Frederic A. Besley, M.D.

A. J. Ochsner, M.D. C. S. Bacon, M.D. Carl Beck, M.D.

Thomas J. Watkins, M.D. John L. Porter, M.D. William R. Cubbins, M.D.

FOR THE BRITISH EMPIRE

Sir Arthur Mayo-Robson, C.B., C.V.O., D.Sc., F.R.C.S.

Sir Berkeley Moynihan, C.B., M.S., F.R.C.S. Thomas W. Eden, M.D., F.R.C.S.

Sir Harold J. Stiles, M.B., F.R.C.S. (Edin.) Henry Jellett, M.D., F.R.C.P.I.

James Rutherford Morison, M.B., F.R.C.S.

Franklin H. Martin, M.D., Managing Editor

Allen B. Kanavel, M.D., Associate Editor

EDITORIAL AND BUSINESS OFFICES: 30 N. Michigan Ave., Chicago, Illinois, U. S. A.

PUBLISHERS FOR GREAT BRITAIN: Bailliere, Tindall & Cox, 8 Henrietta St., Covent Garden, London, W. C., England

JUST OUT

Ewing's Neoplastic Diseases

Dr. Ewing discusses tumors as specific clinical entities. His aim is to bring all the weight of experimental research and clinical experience to bear upon the prevention, diagnosis, and treatment of neoplastic diseases. To show you how to recognize cancer in its incipiency, to distinguish between benign and malignant growths, to determine upon the prognosis and course of treatment—these practical, clinical points are the features upon which he has concentrated his efforts.

Octavo of 1027 pages, with 479 illustrations. By James Ewing, Sc.D., M.D., Professor of Pathology at Cornell University Medical School. Cloth, $10.00 net.

SAUNDERS, *Publishers*

SEE PAGE 13

Entered as second-class matter May 22, 1913, at the postoffice at Chicago, Ill., under the Act of Congress, March 3, 1897.

Published monthly. Copyright, 1919, by The Surgical Publishing Company of Chicago.



USE
Paragon X-Ray Plates

They are FAST, CLEAN, BRILLIANT

And if you want to see the finest results your apparatus will produce

TRY THEM

THEY MAKE GOOD, as proven by the constant increase in repeat orders received.

IF YOU are not using them, some one else may make the diagnosis you failed on by not taking every opportunity to improve the standard of your work.

Hundreds are building reputations by their use. *Why Not Join Them?* We will help you with technical advice if needed.

If your dealer has no *fresh* Paragon plates in stock, write us, for quick shipment.

We Also Supply

Lower Priced X-Ray Plates
Barium Sulphate for Stomach Work
Dental X-Ray Films and Mounts
Developing Tanks—Soapstone or porcelain enameled, 1, 4 or 6 compartments
Developer Chemicals
Intensifying Screens
Filing Envelopes
Radiator or Regular Coolidge Tubes
X-Ray Protective Materials

Complete Price List and Discount Sheet on request. YOUR NAME should be on our mailing list for monthly X-Ray Bulletin.

Geo. W. Brady & Co. 756 S. Western Avenue **Chicago**

PARAGON X-RAY PLATES

SAVE TWO-THIRDS

Sherman's Bacterial Vaccines, when administered early, will reduce the average course of acute infections like Pneumonia, Broncho-pneumonia, Sepsis, Erysipelas, Mastoiditis, Rheumatic Fever, Colds, Bronchitis, etc., **to less than one-third their usual mortality and duration.**

Sherman's Bacterial Vaccines are prepared in our specially constructed Laboratories, devoted exclusively to the manufacture of these preparations and are marketed in standardized suspensions.

Write for literature.

MANUFACTURER OF BACTERIAL VACCINES

G. H. SHERMAN M.D.
Detroit, Mich. U.S.A.

GALL BLADDER INCISION
J. MEYER'S HOCKEY STICK INCISION
BATTLE-JALAGUIER-KAMMERER-INCISION
McBURNEY INCISION
J. MEYER HOCKEY-STICK INCISION
OBLIQUE SUBCOSTAL INCISION
MEDIAN SUPRA-ABDOMINAL
MEDIAN INFRA-ABDOMINAL
M. VISCHER'S INCISION
FOWLER'S INCISION
PFANNENSTIEL'S INCISION
WOUNDS heal by nature's own device, but the linear scar of primary union is essentially the achievement of the aseptic surgical suture
DAVIS & GECK, INC.
Sterile Surgical Sutures
LABORATORIES: 217-221 Duffield Street
BROOKLYN, N.Y.
Seattle - San Francisco - London
© 1919 - DAVIS & GECK, INC.

CONTENTS—FEBRUARY, 1919

ORIGINAL ARTICLES

1. THE CLINICAL SIGNIFICANCE OF CONGENITAL ANOMALIES OF THE KIDNEY AND URETER; WITH NOTES ON THE EMBRYOLOGY AND FŒTAL DEVELOPMENT OF THE KIDNEY. *H. G. Bugbee, M.D., F.A.C.S., and J. R. Losee, M.D., New York* 97

2. TUBAL AND OVARIAN HÆMORRHAGE; ITS ETIOLOGICAL RELATION TO PELVIC HÆMATOCELE AND EXTRA-UTERINE PREGNANCY. *J. Wesley Bovée, M.D., F.A.C.S., Washington* 117

3. CLINICAL DATA ON CHORIO-EPITHELIOMA WITH END-RESULTS OF OPERATIVE TREATMENT. *Hiram N. Vineberg, M.D., F.A.C.S., New York* 123

4. A VAGINAL HYSTERECTOMY TECHNIQUE FOR THE CURE OF PROLAPSE OF THE UTERUS WHEN THE REMOVAL OF THE UTERUS IS NECESSITATED; WITH SPECIAL REFERENCE TO LAPPING OF THE VAGINAL FASCIA IN ALL FORMS OF VAGINAL PROLAPSE. *Dougal Bissell, M.D., F.A.C.S., New York* 138

CONTENTS CONTINUED OPPOSITE NEXT PAGE



Graduated Low Tone Tuning Forks

Devised by DR. W. G. REEDER

Important Announcement

WE are now able to deliver the first graduated low tone tuning forks manufactured in America. These forks are graduated in four tone intervals from 16 to 64 double vibrations per second. They are free from overtones and guaranteed to be perfect. Otologists who have been unable to obtain such a set of instruments at any figure since the war, are now offered a superior product at a nominal price. These forks are indispensable in accurate functional testing of the ear, especially in cases of incipient conduction deafness and those in which the lower tone limit is disturbed.

No. 1 Reeder's Tuning Fork, 16 to 20 double vibrations, is 23½ inches long and weighs 7½ lbs. . . . . Price $35.00

No. 2 Reeder's Tuning Fork, 24 to 28 double vibrations, is 19½ inches long and weighs 7 lbs. . . . . Price $35.00

No. 3 Reeder's Tuning Fork, 32 to 44 double vibrations, is 17 inches long and weighs 7 lbs. . . . . Price $32.50

No. 4 Reeder's Tuning Fork, 48 to 64 double vibrations, is 14 inches long and weighs 6 lbs. . . . . Price $32.50

SHARP & SMITH

Manufacturers and Exporters of High Grade Surgical Instruments and Hospital Supplies

65 E. LAKE ST. Between Wabash Ave. and Mich. Blvd. CHICAGO, ILL.

Established 1844 Incorporated 1904

WAPPLER

Electrically Lighted Diagnostic Instruments and Electro-Medical Apparatus are Used by the U. S. Government

X-Ray Equipments

High Frequency Apparatus

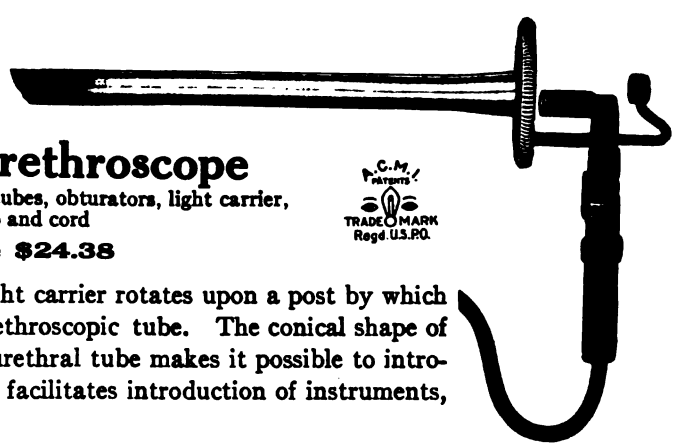

Young Urethroscope

Complete in case with 3 tubes, obturators, light carrier, lamp and cord

Price $24.38

In this instrument the light carrier rotates upon a post by which it is attached to the urethroscopic tube. The conical shape of the proximal end of the urethral tube makes it possible to introduce more light, and also facilitates introduction of instruments, swabs, etc.

A valuable instrument at low cost for the Urologist and the General Practitioner. Send for one today

WAPPLER ELECTRIC COMPANY, Inc.

Dept. S, 173 East 87th Street, NEW YORK, U. S. A.



Dr. Charles Geiger's

Electro-Operative Surgical Bone Instruments and Accessories

These instruments are made especially for transplanting bone, dowel making and cranial work. **Water is not required** to keep the cutters from burning the bone when using these instruments, **because of their slow speed.**

A few of the many advantages not found in any other motor bone instruments are: Slow speed, sterilization of motor, its great power, simplicity of chuck, and firmness with which it can be held. Sterilizable shell is included in the set.

Write F. A. Davis Pub. Co., Philadelphia, Pa., for Dr. Charles Geiger's book on **"MODERN OPERATIVE BONE SURGERY."**

The Charles Geiger Mfg. Co.

St. Joseph, Missouri, U. S. A.

CONTENTS—FEBRUARY, 1919—CONTINUED

ORIGINAL ARTICLES — CONTINUED

5. THE EFFECT OF HYSTERECTOMY UPON OVARIAN FUNCTION. *Edward H. Richardson, M.D., F.A.C.S., Baltimore, Maryland* 146

6. PATHOLOGY OF GOITER; BASED UPON SPECIMENS RECEIVED AT THE STATE INSTITUTE FOR THE STUDY OF MALIGNANT DISEASE, BUFFALO, NEW YORK. *Burton T. Simpson, M.D., Buffalo, New York* 153

7. HYPERTROPHIC STENOSIS OF THE PYLORUS IN INFANTS. *Thomas M. Green, M.D., F.A.C.S., and J. Buren Sidbury, A.M., M.D., Wilmington, North Carolina* 159

8. A THEORY ON THE ETIOLOGY OF THE TOXÆMIA OF PREGNANCY WITH OR WITHOUT CONVULSIONS. *John E. Talbot, M.D., Worcester, Massachusetts* 165

9. DIAGNOSIS AND TREATMENT OF CHRONIC DUODENAL OBSTRUCTION. *Edward L. Kellogg, M.D., F.A.C.S., New York* 174

CONTENTS CONTINUED OPPOSITE NEXT PAGE

THE MEYER MULTOSCOPE

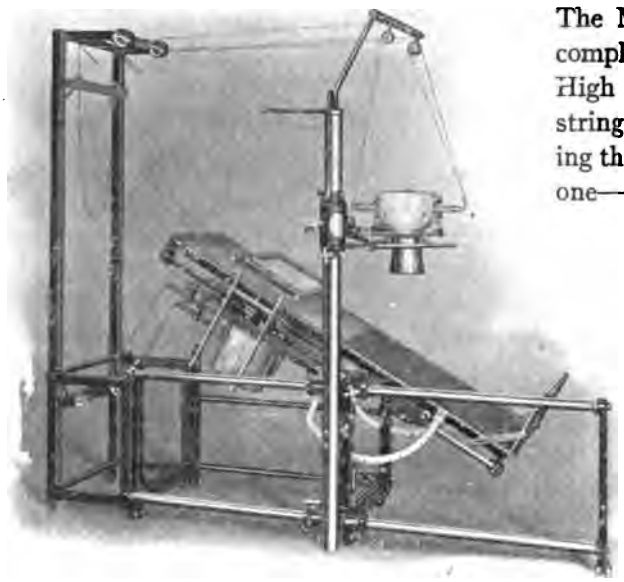

The Meyer Multoscope is furnished complete with Self Contained Aerial and High Tension Switch, eliminating the stringing of wires in a room and making the placing of the apparatus a flexible one—changeable as desired. No current wasted in excess wiring. The last word in classiness.

It covers every phase of Modern X-Ray Work.

Send for the
MULTOSCOPE BULLETIN

Price complete $1100.00

THE WM. MEYER COMPANY

817 WASHINGTON BLVD. **CHICAGO, ILL.**

MODERN PAIN RELIEVING METHODS

MOST effective method of relieving the pains of Neuritis, Rheumatism, Arthritis, Neuralgia, Lumbago, Gastritis, etc., is obtained by the use of

Burdick Radio-Vitant Applicators

Treating a Case of Neuritis

We will send Free **a concise and comprehensive treatise on light therapy and a copy of our new illustrated catalogue in three colors on receipt of post card request.**

Extensively used in both the surgeon's office and hospital.

Specially adapted for use in the patient's home under supervision of the surgeon.

Standardized in the Surgeon-General's Office for use in the Military Reconstruction Hospitals.

Proven by practical experience to be far superior to vibrators, high frequency currents, "high candle-power lamps," etc., for local application in the relief of pain and inflammation.

Type L-4 Applicator, $27.50

5% discount for cash with order. Our guarantee, entire satisfaction or money back.

BURDICK CABINET CO., 200 Madison Ave., MILTON, WIS.

Treatment *of* Lobar Pneumonia *with* Partially Autolyzed Pneumococci

IN the *Journal of the American Medical Association* (pages 759 to 763—March 16, 1918) Dr. E. C. Rosenow has reported results in the treatment of lobar pneumonia with partially autolyzed pneumococci.

His work has established the harmlessness of this antigen and apparently indicates that it has a definite beneficial action on the disease, especially when given early.

Supplied through the regular drug trade in five c. c. rubber-capped ampoule vials. Order as V-903.

ELI LILLY & COMPANY, Indianapolis, U. S. A.

CONTENTS—FEBRUARY, 1919—CONTINUED

DEPARTMENT OF TECHNIQUE

10. INFECTION OF A FUSED KIDNEY WITH DUPLICATION OF THE LEFT RENAL PELVIS. *Leo Buerger, M.D., F.A.C.S., New York* 183

11. THE EXTREME PENDULOUS ABDOMEN AND ITS SURGICAL TREATMENT BY A NEW THREE-FLAP OPERATION. *Neil John Maclean, M.D., M.R.C.S. (Eng.), F.A.C.S., Winnipeg, Canada* .. 190

BOOKS RECEIVED 194

AMERICAN COLLEGE OF SURGEONS

CASE RECORDS AND THEIR USE 195

In Relation to Hospital Success. Based on Medical Patriotism. Case Records in Army Hospitals. Check upon Character of Service. Why Meetings of Hospital Staff? Practical Points about Case Records.



McIntosh No. 4 Polysine Generator

Success in Electro-Therapy

Many a practitioner can trace the origin of his success to the purchase of some piece of good apparatus which enabled him to individualize his system of treatment and give his patients something which they were not getting elsewhere.

With the McIntosh No. 4 Polysine Generator shown you have a means of combating the long train of sequelæ to abdominal insufficiency — conditions in which the slow sinusoidal current is unexcelled.

Ask for an Interesting Booklet "Sinusoidal Therapy" and Get Our Proposition

McINTOSH BATTERY & OPTICAL COMPANY

Eastern Office and Service Station
1777 Broadway, New York

Main Office and Factory
217-223 N. Desplaines St., Chicago

THE

RADIUM INSTITUTE

1604 Mallers Bldg., 59 E. Madison St.
Cor. Wabash Ave., Telephone Randolph 5794
C H I C A G O

DR. FRANK E. SIMPSON

COUNCIL

DR. F. A. BESLEY — DR. E. C. DUDLEY
DR. A. R. EDWARDS — DR. O. T. FREER
DR. M. HERZOG — DR. L. E. SCHMIDT
DR. G. F. SUKER

TREATMENT of Malignant and Benign Growths with Radium; Postoperative Prophylactic Radiations following the Surgical Treatment of Cancer.

Radium is indicated in inoperable malignant conditions. By its use an inoperable case may become operable.

We desire to confer and co-operate with surgeons, assuring them adequate amounts of Radium to meet the requirements of patients referred to us.

Chloretone Produces Natural Sleep

Administered internally, **CHLORETONE** passes unchanged into the circulation, inducing (in efficient therapeutic doses) profound hypnosis. It does not depress the heart or respiratory centers. It does not disturb the digestion. It is not habit-forming. **CHLORETONE**, in a word, *produces natural sleep.*

◆ ◆ ◆

In addition to its primary function as a hypnotic, **CHLORETONE** has a wide range of therapeutic applicability as a sedative. It is useful in alcoholism, delirium tremens, cholera, colic; epilepsy, chorea, pertussis, tetanus and other spasmodic affections; nausea of pregnancy, gastric ulcer and seasickness; mania (acute, puerperal and periodic), senile dementia, agitated melancholia, motor excitement of general paresis.

CHLORETONE: Ounce vials.
CHLORETONE CAPSULES: 3-grain, bottles of 100 and 500.
CHLORETONE CAPSULES: 5-grain, bottles of 100 and 500.
Dose, 3 to 15 grains.

SEE THAT YOUR DRUGGIST IS ABLE TO SUPPLY YOU.

Home Offices and Laboratories,
Detroit, Michigan.

PARKE, DAVIS & CO.

INDEX TO ADVERTISING

Surgical Instruments and Apparatus

Bauer & Black 34
Bard-Parker Co 14
Burdick Cabinet Co 4
Electro Surgical Instrument Co 15
Feick Brothers Co 14
Charles Geiger Mfg. Co 3
Goodwill Electric Co 15
Kny-Scheerer Corporation 18
McIntosh Battery & Optical Co ... 6
V. Mueller & Co 14
Northwestern Steel & Iron Works .. 16
Harvey R. Pierce Co 12
Prometheus Electric Co 14
Sharp & Smith 2
Taylor Instrument Companies 9
Truax Inc 16
Victor Electric Co 28
Wappler Electric Co 2
Wm. V. Willis & Co 27

Hospital Supplies

Bauer & Black 34
Burdick Cabinet Co 4
General Laboratories 16
Good Mfg. Co 34
Goodwill Electric Co 15
Kny-Scheerer Corporation 18
V. Mueller & Co 14
Northwestern Steel & Iron Works .. 16
Harvey R. Pierce Co 12
Prometheus Electric Co 14

Rubber Goods, Gloves, Etc.

E-Z Patch Co 15
L. T. Kinney & Co 34

X-Ray Apparatus, Tubes, Plates, Etc.

American Photo Chemical Co 33
Geo. W. Brady & Co .....2nd cover
Campbell Electric Co 26
Eastman Kodak Co 29
General Electric Co 31
McIntosh Battery & Optical Co ... 6
Wm. Meyer Co 4
Victor Electric Co 28
Wappler Electric Co 2

Anæsthesia Apparatus

Foregger Co 9
Safety Anæsthesia Apparatus Concern 10
Scientific Apparatus Co 26

Corsets, Bands, Etc.

S. H. Camp & Co 30
Earnshaw Knitting Co 27
Katherine L. Storm 32

Radium

Physicians' Radium Association ... 34
Radium Chemical Co 9
Radium Company of Colorado 25
Radium Institute 6

Miscellaneous

Battle Creek Sanitarium 38
Colorado Springs 35
Gradwohl Biological Laboratories .. 16
Horlick's Malted Milk Co....4th cover
Medical Protective Co 17
Quaker Oats Co 27

Catgut—Ligatures

Armour & Co .....4th Cover
Davis & Geck, Inc 1
Hollister-Wilson Laboratories 11
Johnson & Johnson 25
C. DeWitt Lukens Co 24

Medical Books

P. Blakiston's Son & Co 17
Lea & Febiger 23
Medicine and Surgery Pub. Co 17
C. V. Mosby Co 22
Oxford University Press 20
Rebman Company 19
W. B. Saunders Co .....Cover and 13
Wm. Wood & Co 21

Pharmaceuticals

Abbott Laboratories 8
Armour & Co .....4th Cover
Cutter Laboratory .....3rd Cover
General Laboratories 16
Hynson, Westcott & Dunning 36
Eli Lilly & Co 5
H. A. Metz Laboratories, Inc 37
Parke, Davis & Co 7
Sharp & Dohme 36
Dr. G. H. Sherman .....2nd Cover
E. R. Squibb & Sons 15
Standard Oil Co 39

Post-Graduate Instruction

Laboratory of Surgical Technique . 38
New York Post-Graduate Medical School and Hospital 40

Speed of Disinfection of Standard Germicides

CHLORAZENE ▌ 5 minutes

Mercuric Chloride ▌ 7 hours

Phenol ▌ 24 hours

This tablet is adapted from a report by Dr. Edward K. Dunham, who vividly illustrates the results obtained from experiments made with cultures of staphylococcus in a blood-serum muscle-extract medium.

OTHER ADVANTAGES OF CHLORAZENE

Chlorazene is non-poisonous

(See report by Doctor Carnot in Paris Medical on the use of Chlorazene as an intestinal antiseptic.)

Mercuric Chloride and Phenol are highly toxic.

Chlorazene is non-irritating.

Hypochlorite solutions are irritating.

(See report in Experimental Medicine of tests made in Rockefeller Institute.)

Chlorazene is stable. It is supplied in convenient tablet form.

Chlorazene is being used with brilliant results in treating the eye, nose, throat and vagina and in all wounds.

Chlorazene is the ideal antiseptic for the prophylaxis of infectious diseases. These are a few good reasons why **Chlorazene** deserves a trial at your hands.

Ask Your Druggist to Stock Chlorazene

The Universal Antiseptic

Supplied in Tablets, Powder, Surgical Cream and Surgical Powder. If your druggist cannot supply you, send $0.64 for a bottle of 100 Chlorazene tablets.

Chlorazene literature on request.

Ask also for prices on Dichloramine-T, Procaine and Barbital

THE ABBOTT LABORATORIES

Home of the Dakin Products

Dept. 82 **CHICAGO**

New York Seattle San Francisco Los Angeles Toronto Bombay

RADIUM

STANDARD CHEMICAL CO.

¶ The increasing use of Radium by the medical profession can be attributed only to results obtained.

¶ Efficacious in the treatment of many Benign and Malignant Growths, and in Post-Operative Prophylactic Raying.

¶ Information as to dosage, technic and equipment sent upon request.

Sold on a basis of U. S. Bureau of Standards measurement.

RADIUM CHEMICAL CO.

GENERAL OFFICES — PITTSBURGH, PA.

Gwathmey Apparatus

The advantage of the "Sight Feed"

is not—to ***set*** the proportion,

it is—to ***get*** the proportion.

Nor is it—to know the amounts in liters or gallons,

but it is—to know what you are doing.

As an indicator for the quick obtainance and safe maintenance of uniform anesthetic conditions the visible gas flow of the "Sight Feed" is absolutely reliable and permanently so.

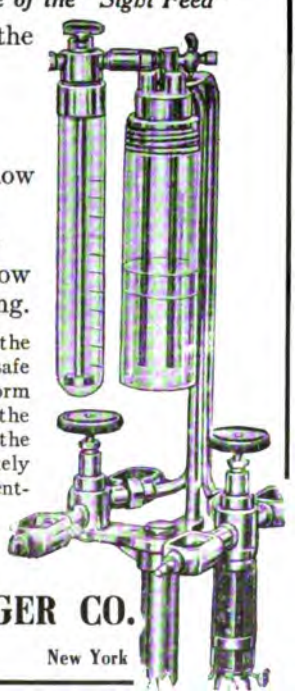

Write for Our 1919 Catalog

THE FOREGGER CO.

47 West 42nd St. New York

Meets in Full Measure the Exacting Demands of the Practitioner

SELF-VERIFYING



Tycos Fever Thermometers

Tycos Urinary Glassware

Tycos

Through the entire complex process in its manufacture, our years of experience is reflected.

$25.00

Complete with pocket carrying case and sterilizable sleeve, at your surgical instrument dealers.

A postal brings booklet on blood pressure tests which is authorative

Taylor Instrument Companies

ROCHESTER, N. Y. 30

SAFETY GAS-OXYGEN APPARATUS

SIMPLIFIES

the administration of

NITROUS OXID and OXYGEN

with or without an ETHER sequence in

MAJOR or MINOR SURGERY—OBSTETRICS—DENTISTRY

The old TROUBLE points ELIMINATED.

No high pressure bags. No spring gauges. No delicate mechanisms to get out of order.

The "Safety" employs HYDROSTATIC regulation which is *always* dependable and accurate.

Simple to operate. Minimum gas consumption. Ideal Anæsthesia and Analgesia.

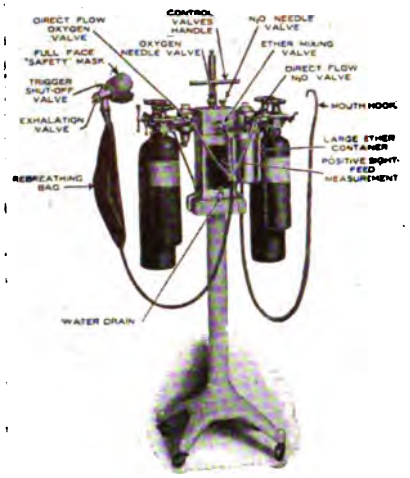

Model "F," with large ETHER Container and Mouth Hook. Style "B" and "C" Cylinders attached.

The IDEAL HOSPITAL APPARATUS. This is the outfit supplied all American Government mobile operating rooms now in France, and many Military Hospitals and Cantonments in the United States. Uses from 40 to 60 gals. of N_2O per hour of profound anæsthesia.

Perfectly controlled smooth mixtures assured by

THE NEW

Positive Sight-Feed-Measurement

YOU SEE 1 The flowing of the separate gases.
2 That you obtain the desired mixtures.
3 That your mixtures are accurately maintained as long as required.

Gases delivered *Washed*, *Moistened* and *Heated* to body temperature

Manufactured in three models, "D," "E" and "F," truly portable and complete outfits for Private and Hospital use.

Write for illustrated booklet containing full information



Cut showing Sight-Feed-Measurement, ½ actual size. The water-level "A" in the Oxygen Feed Tube, and the water-level "B" in the Nitrous Oxid feed tube fall or rise as a greater or less volume of the respective gases is admitted to the mixing chamber, by the needle valves. Accuracy of mixture and VISIBLE PROOF OF ACCURACY are thus assured.

SAFETY ANAESTHESIA APPARATUS

Ogden Ave. & Randolph St. CONCERN CHICAGO, ILLINOIS

Preparing Perfect Surgical Gut

No. IX—Testing and Standardizing Laboratories

IN the preceding installments of this series we have illustrated and described the various steps in the manufacture and sterilization of surgical gut as conducted in our Plant and Laboratories, every detail of which has been under the constant observation of competent technical workers from the moment of the animal's slaughter.

To facilitate this work we maintain a most complete series of laboratories — Physical, Chemical and Bacteriological, equipped to the last detail with apparatus calculated to insure accuracy, uniformity and the maximum of protection to the surgeon who discriminates in the selection of his surgical ligatures.

Sterility, tensile strength and elasticity are here determined for the finished product under the most favorable but exacting conditions, and to these laboratories are brought systematic reports for the bacteriological chemist in charge as the material in process of manufacture is carried through to completion.

In this brief chapter and the ones that have already appeared, we believe that we have conclusively demonstrated to the thinking surgeon that unless the source of supply of the raw material is under the immediate observation of the catgut manufacturer from the killing of the sheep to its manufacture into the twisted strand and final sterilization under the same personal control, surgical catgut will always be an enigma and a source of anxiety and controversy to operating surgeons.

A copy of our pamphlet "FROM ABBATTOIR TO TUBE" will be mailed to you on request, together with samples of Hollister "TUBES OF DISTINCTION."

Hollister Ligatures can be obtained wherever surgical supplies are sold

HOLLISTER-WILSON LABORATORIES

4444-46-48 So. Ashland Ave. CHICAGO, U. S. A.

"TUBES OF DISTINCTION"

Pratt-Lowman
Self-Retaining Retractor

for use in the open method of repairing fractures especially in connection with the Albee Motor Saw method.

Devised by Major John B. Lowman, M.C., and Captain R. B. Pratt, M.C., U. S. Base Hospital No. 38.

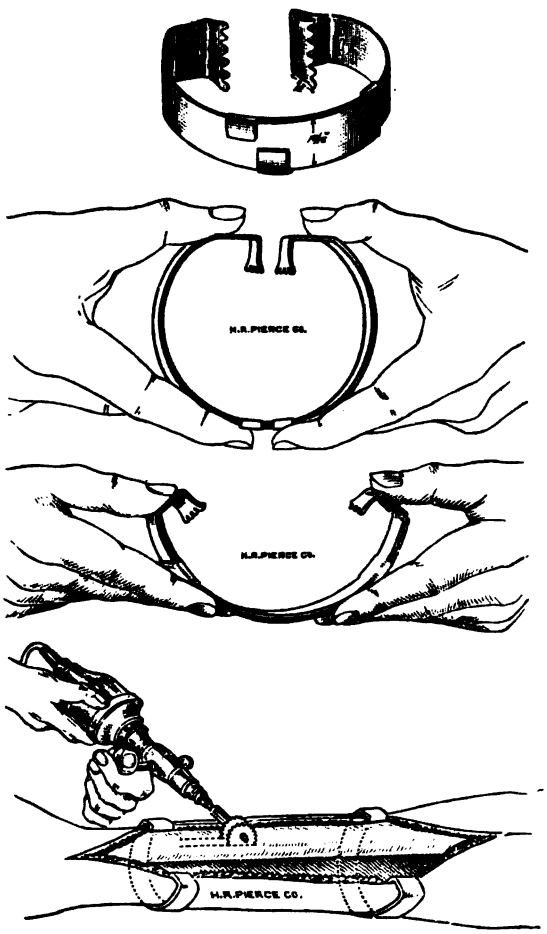

It affords the following advantages:

SIMPLICITY

No parts to be lost. Easy to clean, sterilize, manipulate.

DURABILITY

It not only gives RETRACTION of tissues, but also DEPRESSION of them with an uncomplicated automatic lock in any degree of retraction. Pressure upon its lower surface by the weight of the limb forcing it against the operating table only serves to increase retraction and locking.

It does away with retraction by assistants and with this the danger of extra hands in the operative field and leaves the operator unhindered in the use of the electric saw and drill.

It leaves the bone in a higher plane than the surrounding tissues and so obviates the danger of the saw, drill or spinning shaft engaging with the soft tissues or toweling.

In conjunction with an orthopedic table, assistants can be dispensed with during that stage of the operation in which the saw or drill is in use.

It is a useful addition in a teaching clinic in that it renders the field of operation more visible to spectators.

Made in several sizes.

Manufactured by

HARVEY R. PIERCE COMPANY

1801 Chestnut Street *The Modern Surgical Instrument Store* **PHILADELPHIA**

PITTSBURGH SALES OFFICE: 3030, 3031, 3032, 3033 JENKINS ARCADE

Medical Books

Mayo Clinic Volume *The Latest Volume*

This Mayo Clinic volume records all the important developments at the Clinic during 1917, many of the articles appearing as late as June,1918. The subjects dealt with include not only operative technic but much research work bearing on etiology, diagnosis, symptomatology, pathology.

Octavo of 866 pages, illustrated. By WILLIAM J. MAYO, M.D., CHARLES H. MAYO, M.D., and their ASSOCIATES at The Mayo Clinic, Rochester, Minn. Cloth, $6.50 net.

Mayer's Orthopedics of Gunshots *Just Out*

Dr. Mayer tells you how to manage orthopedic cases from the time the wound is received until the patient is retrained and returned to his industrial occupation. He tells you which technic has survived, the exact procedure to follow to bring about restoration of function.

12mo of 250 pages, illustrated. By LEO MAYER, M.D. Instructor in Orthopedic Surgery, New York Post-Graduate Medical School and Hospital. Cloth, $2.50 net.

Graves' Gynecology *New (2nd) Edition*

This work is based on Dr. Graves' personal experience. It is strong on differential diagnosis. Two entire sections are devoted to *non-surgical gynecology*, giving only drug and mechanical treatments. You get a large chapter on the *physiology* of the pelvic organs and on *correlated gynecology*.

Octavo of 885 pages, with 491 illustrations, 100 in colors. By WILLIAM P. GRAVES, M.D. Professor of Gynecology at Harvard Medical School. Cloth, $7.75 net.

DeLee's Obstetrics *New (3rd) Edition*

For this edition Dr. DeLee has reviewed every chapter critically. Abderhalden's pregnancy reaction, the relation of the endocrine glands to gestation, twilight sleep, the urinary tests for the toxemias of gestation have been given new evaluations. Many subjects were amplified—obstetric anesthesia and analgesia, perineorraphy, cesarean section, especially the newer methods, treatment of contracted pelvis, treatment of eclampsia by conservative methods.

Large octavo of 1089 pages, with 949 illustrations, 187 in colors. By JOSEPH B. DELEE, M.D., Professor of Obstetrics in the Northwestern University Medical School, Chicago. Cloth, $8.50 net.

Koll's Diseases of Male Urethra *Just Out*

Dr. Koll emphasizes the importance of *gonorrhea*, giving anatomy, bacteriology, pathology, symptomatology, diagnosis, and treatment, the latter being considered so thoroughly that the practitioner can treat these cases in his own office. There are chapters on stricture, non-gonorrheal urethritis, urethrorrhea, prostatorrhea, spermatorrhea, tumors, impotence, sterility, etc.

Octavo of 150 pages, illustrated. By IRVIN S. KOLL, M.D., Professor of Genito-Urinary Diseases, Post-Graduate Hospital and Medical School, Chicago. Cloth, $3.00 net.

Allen's Local Anesthesia *New (2nd) Edition*

This new edition has been subjected to a thorough revision. Many operations have been added to the already long list performed under local anesthesia. Notable among these is the removal of the prostate; sacral anesthesia; and some practical additions to abdominal surgery and to head surgery.

Octavo of 674 pages, illustrated. By CARROLL W. ALLEN, M.D., Assistant Professor of Clinical Surgery, Tulane University of Louisiana. Cloth, $6.50 net.

W. B. SAUNDERS COMPANY, West Washington Sq., Phila.

London: 9, Henrietta St., Covent Garden Australian Agcy: Centreway, 263 Collins St., Melbourne

For the Surgeon—A Sharp Knife

Patented 4

The Bard-Parker Knife



21

We can now promptly supply all sizes Bard-Parker handles, Nos. 1, 2, 3, 4; and Bard-Parker blades, Nos. 10, 11, 20, 21, 22.

If Your Dealer Cannot Supply, We Ship Direct

BARD-PARKER CO., Inc., 37 E. 28th St., New York

The Surgeon

is generally called upon for advice as to

Artificial Limbs

Why not recommend one that is sure to be SATISFACTORY?

Our Latest Model

with Adjustable Leather Socket, Cordless Ankle, Felt or Sponge Rubber Foot, Ball-bearing Joints

assure the patient of comfort and perfect locomotion.

Our GUARANTEE Covers All Repairs

Write for Catalogue

FEICK BROS. COMPANY

809 Liberty Ave. Pittsburgh, Pa.

The PROMETHEUS

ELECTRIC STERILIZER

With Latest Conveniences

Tray Supported from Body in Raised Position—Not Attached to Cover.

Tray and Contents Freely Removable. Inside Unobstructed. Side Handle on Cover Away from Steam. Drawing-off Faucet on Side. Made in Four Sizes.

THE ONLY ELECTRIC STERILIZER EQUIPPED WITH WIRE-LESS HEATER. Has Automatic Cut-Out. Heat Regulation in Three Degrees at Sterilizer.

The Prometheus Electric Co.

245 East 43rd St. New York

THE GREAT DEMAND FOR SURGEONS' INSTRUMENTS AND EQUIPMENT CAUSED BY THE WAR

has made it necessary to increase considerably our facilities for production, both as regards improved machinery and the number of men.

Now that the emergency has passed and Army work is no longer so urgent, we will again be in a position to offer to the medical profession our unequaled facilities and long experience in the construction of new instruments and special apparatus.

Through our representatives in England, France and the Orient, we are also in a position to secure for our customers any new devices which may have been introduced and found valuable by the profession abroad.

TRADE MARK

V. MUELLER & COMPANY 1771-83 Ogden Ave., Chicago

Makers of Instruments for Every Branch of Surgery

Liquid Petrolatum Squibb

Heavy (Californian)

THE mineral oil for infants, and children of all ages. It is the palatable, safe and efficacious regulator of the bowels and needs no menstruum or flavoring. It will not form a habit.

Refined under our control, and exclusively for us, only by the *Standard Oil Company* of *California* which has no connection with any other Standard Oil Co.

E·R·SQUIBB & SONS. NEW YORK
MANUFACTURING CHEMISTS TO THE MEDICAL PROFESSION SINCE 1858

Applied in a Minute and Holds Forever!

The E-Z
Self-Cementing
Self-Vulcanizing
PATCH

A Permanent, Economical Patch for Repairing Rubber Gloves

The E-Z Patch is applied so easily and quickly that its very simplicity will appeal to you — to say nothing of the many dollars it will save. A little sandpaper and a drop of gasoline are the only things required.

The moment the E-Z Patch is subjected to heat, it vulcanizes and becomes an integral part of the object. Repeated sterilization only makes the patch hold better. There's no danger of infection.

THE E-Z PATCH COMPANY
AKRON, OHIO

Send for Trial Envelope Containing 6 for 25c
Hospital Size Package, 50 for $1.00
Samples on Request

The
Pad Without a Fault

It has none of the drawbacks of other electric pads. It is so near perfection that it is

Guaranteed For One Year

The Goodwill Thermostatic control gives positive temperatures ranging from 100° to 180°. Used and endorsed by leading hospitals and physicians. *Money back if not satisfied.* Price $7.00. Order to-day.

GOODWILL ELECTRIC CO.
59 E. VAN BUREN ST. DEPT. A CHICAGO

Electrically Lighted Instruments

From the best material obtainable and by skilled workmen E. S. I. Co. instruments are made. Not alone are we the originators, but, as well, we are exclusive manufacturers of the most valuable diagnostic instruments in use. Their position is firmly established among the profession and their usefulness is unquestioned.

All our instruments may be operated upon our tungsten battery or upon commercial current by means of the socket current controller here illustrated.

Koch, Swinburne, Young, Gordon and MacGowan Urethroscopes
Braasch Cystoscopes, E. S. I. Co. Vaginal Specula

These and many other instruments are described and illustrated in our Catalogue, a copy of which will be mailed on request.

For your own protection be sure every instrument is marked "E. S. I. Co."

ELECTRO SURGICAL INSTRUMENT CO.
ROCHESTER, N. Y.

HYCLORITE
HYPOCHLORITE

HYCLORITE

Reducing Temperature and Pulse

Surgeons recognize the great value of Hyclorite in reducing temperature and pulse to normal in cases of infected tissue wounds and fractures. Hyclorite cleans the wound through solvent action and prevents toxemia through its oxidizing action on toxins as formed.

This action of Hyclorite has been demonstrated successfully in a large number of injury cases in industrial hospitals.

Hyclorite is always ready for immediate use.

Just add water and apply.

Hyclorite is prepared to a definite hypochlorite strength and alkalinity.

Solutions made from Hyclorite keep much longer than ordinary Dakin's solutions.

There is no waste, testing, or waiting in making a Dakin's solution from Hyclorite.

Price, 32 oz., $1.25

Order from Your Dealer

Accepted by the Council on Pharm. and Chem. for inclusion in N.N.R.

GENERAL LABORATORIES
4710 South Dickinson St.
MADISON - - - WISCONSIN

The War Demonstrated

That the **National High-Pressure Sterilizer,** in field and base hospital, in Red Cross and army service, actually did insure

"Bone-Dry" Dressings in Half the Usual Time

This lesson of the war will not be lost under peace conditions. There is a National for every requirement of Hospital and private practice.

Three Sizes: Doctor's $60; Medium $85; Hospital $145.

Does all the work of Autoclave. Operates under steam pressure of 1 to 30 pounds at temperatures of 112 to 260 degrees. Equipped with gas or gasoline burner or steamer oil as required.

Write for information and name of your nearest National dealer.

Northwestern Steel & Iron Works
881 Spring St.,
EAU CLAIRE, WIS.
Capital $200,000

Do You Want the Highest Order of Serological Diagnosis?

Send Your Specimens to us for

Wassermann and Hecht-Gradwohl Tests,
Gonorrheal Complement Fixation,
Tuberculosis Complement Fixation.

All other Laboratory Tests.

Gradwohl Biological Laboratories.
R. B. H. GRADWOHL, M.D., Director.
928 N. Grand Ave. ST. LOUIS, MO.

SKELETONS

We have secured a large stock of

Selected Skeletons

Prices and descriptions gladly furnished on application

TRUAX
CHARLES TRUAX, Incorporated
141 N. Wabash Ave. CHICAGO

Surgery In War

2nd Edition, Revised **Greatly Enlarged**

210 Illustrations. XV and 624 Pages. Cloth, $6.00, Postpaid.

By MAJOR A. J. HULL, R.A.M.C., F.R.C.S. (England)

Surgeon, British Expeditionary Force in France. With a Preface by T. H. J. C. Goodwin, C.B., C.M.G., D.S.O., Director General, Army Medical Service.

"It must prove helpful to all surgeons who are engaged in the treatment of the wounded at home as well as abroad."—*British Medical Journal*

"Much of the information is new and suggestive. The book is compact and well illustrated."—*Journal American Medical Ass'n.*

P. BLAKISTON'S SON & CO., *Publishers*

1012 Walnut Street **PHILADELPHIA**

50% BETTER

Prevention Defense Indemnity

1 All claims or suits for alleged civil malpractice, error or mistake, for which our contract holder,

2 Or his estate is sued, whether the act or omission was his own.

3 Or that of any other person (not necessarily an assistant or agent).

4 All such claims arising in suits involving the collection of professional fees.

5 All claims arising in autopsies, inquests and in the prescribing and handling of drugs and medicines.

6 Defense through the court of last resort and until all legal remedies are exhausted.

7 Without limit as to amount expended.

8 You have a voice in the selection of local counsel.

9 *If we lose, we pay to amount specified, in addition to the unlimited defense.*

10 The only contract containing all the above features and which is protection per se. *A sample upon request.*

The MEDICAL PROTECTIVE CO.
***of* Fort Wayne, Indiana**

Professional Protection Exclusively

JUST OUT!

Quarterly Medical Clinics

"The Clinic Carried to the Busy Practitioner"

A New and Unique Publication of Extraordinary Merit

Volume I, No. 1, September-December, 1918

These Clinics are a Series of Consecutive Clinical Demonstrations and Lectures for Practitioners and Students given at Augustana Hospital by

FRANK SMITHIES, M.D., F.A.C.P.

Associate Professor of Medicine, School of Medicine, University of Illinois; Gastro-Enterologist to Augustana and U. S. Marine Hospitals; formerly Gastro-Enterologist to Mayo Clinic; Fellow of the American Gastro-Enterological Association, Etc.

Down-to-the-minute Clinical Facts (Diagnosis and Complete Treatment) Practically and Scientifically Told. *Folder setting forth contents furnished on application.*

Annual Subscription	Single Copies
Five Dollars, Paper	One Dollar and a Half, Paper
Eight Dollars, Cloth	Two Dollars and a Quarter, Cloth

Sign and mail coupon today. You can't afford to miss a number.

S. G. O., 2-19

Medicine and Surgery Publishing Company, Inc.
METROPOLITAN BUILDING
ST. LOUIS, MO.

Gentlemen: Enclosed find $ for an annual subscription to QUARTERLY MEDICAL CLINICS beginning January, 1919.

Name_____ Street_____

City_____ State_____

Hawley New Fracture and Orthopedic Operating Table

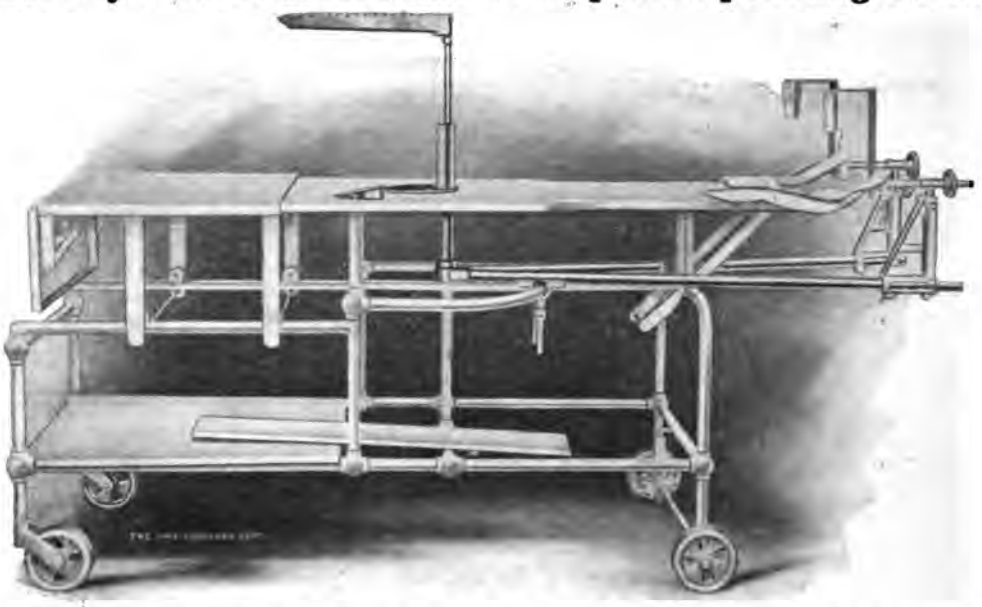

Hundreds of these tables are in use in our Government Hospitals in this country and abroad as there is no other table which will answer the same purposes.

IT IS INDISPENSABLE IN FRACTURE WORK AS IT MAINTAINS THE REUNITED FRACTURE PERFECTLY UNTIL THE PLASTER IS SET OR THE GRAFT IS COMPLETED.

Head end is movable to facilitate easy and free access to the back and shoulders for jackets or spicas. Movable sections overlap to prevent soft parts of the body becoming wedged and injured.

Foot plates hold the foot at right angle to the limb and prevent toe drop. Foot plates rotate to any angle for hyper-abduction, hyper-extension, inward rotation and traction; also brings pressure against ball of foot to force the foot into dorsal flexion.

ACCEPT NO IMITATION; write for bulletin showing the genuine Hawley and Albee Surgical Apparatus and Instruments.

The Kny-Scheerer Corporation *Manufacturers of Surgical and Therapeutic Instruments and Apparatus*

404-410 West 27th Street, New York, U. S. A.

REBMAN COMPANY

141 W. 36th St. NEW YORK

NOTED BOOKS

CORNWALL—A Clinical Treatise on Diseases of the Heart. Price.....$1.50

FLUHRER—Principles of Treatment of Broken Limbs. 21 half-tone plates and 11 textual figures. Price.....$3.00

FOSTER—Diagnosis from Ocular Symptoms. Price.....$6.00

HART—The Diagnosis and Treatment of Abnormalities of the Myocardiac Function. 248 Illustrations. Price.....$4.50

KAUFFMANN—Care of the Mouth and Teeth. Price.....$0.60

MITCHELL—The Doctor in Court. 2d edition, much enlarged. Price.....$1.50

STERN—Fasting and Under-Nutrition in the Treatment of Diabetes. Price.....$2.00

STRONG—Modern Electro-Therapeutics. New edition, 95 illustrations. Price.....$2.00

BARDELEBEN and HAECKEL—Applied Anatomy. In colors. One volume, 204 woodcuts with explanatory text. Price.....$8.00

TOLDT—Atlas of Anatomy for Students and General Practitioners. Revised edition. 1505 illustrations.

VOLUME I

A.—The Regions of the Human Body (Figures 1 to 5).
B.—Osteology (Figures 6 to 377). With Index.
C.—Arthrology (Figures 378 to 498). With Index.....$6.00

VOLUME II

D.—Myology, with a Supplement on the Anatomy of Hernia (Figures 499 to 640). With Index.
E.—Splanchnology (Figures 641 to 932). With Index....$7.00

VOLUME III

F.—Angeiology (Figures 933 to 1123). With Index.
G.—Neurology.
H.—The Organs of the Senses (Figures 1124 to 1505. With Index.....$11.00

Three Volumes complete, $24.00.

KRAUSE—Surgery of the Brain. With 199 (17 of which are in colors) illustrations in the text, 122 figures on 60 Plates in colors and 2 half-tone plates, over 1200 pages. 3 vols., Art. Lea. Price.....$20.00

TANZI—Mental Diseases. 132 illustrations. Price.....$7.50

BIRK—Diseases of Infancy. Price.....$3.50

SHEFFIELD—The Backward Baby. Price..$1.50

ADAM—Ophthalmoscopic Diagnosis. 18 illustrations in the text. 86 colored figures. Price.....$7.00

TIBBLES—The Theory of Ions. Price.....$1.00

GREEFF—External Diseases of the Eye. 84 colored illustrations. (New Edition). Price...$7.00

ROEMER—A Text-Book of Ophthalmology in the Form of Clinical Lectures. 186 black and white illustrations in the text and 58 figures in colors. 896 pages. (New Edition). Price.....$6.00

GOURAUD—What Shall I Eat? Price.....$2.00

ASCH—Gonorrhea (New Edition). Price...$1.50

OPPENHEIMER—Practical Points in Gonorrhea. Price.....$1.25

RUMPEL—Cystoscopy. 107 illustrations (85 in colors). Price.....$6.00

CARLSON—Obstetrical Quiz for Nurses. Price.....$1.75

KISCH—Sexual Life of Woman. Illustrated. Price.....$6.00

KRAUSE (RUDOLPH)—Normal Histology, Including Microscopical Anatomy. 502 pages, 30 figures in the text, 208 magnificent illustrations in many colors on 98 plates. Part I.....$0.75
Part II..... 5.50

KRAUSE (RUDOLPH)—Textbook of Histology. Illustrated. Price.....$3.00

SENATOR-KAMINER—Health and Disease in Marriage and the Married State. Price...$6.00

KLOPSTOCK and KOWARSKY—Clinical Chemistry, Microscopy and Bacteriology. 70 illustrations (27 in colors). Price.....$3.50

McBRIDE—Alcoholism—Drug Narcotism. Price.....$2.50

WOODRUFF—Effects of Tropical Light on White Men (Medical Ethnology). Price.....$3.50

FOREL—The Sexual Question. Illustrated. Price.....$5.00

KRAFFT-EBING—Psychopathia Sexualis. Price.....$4.00

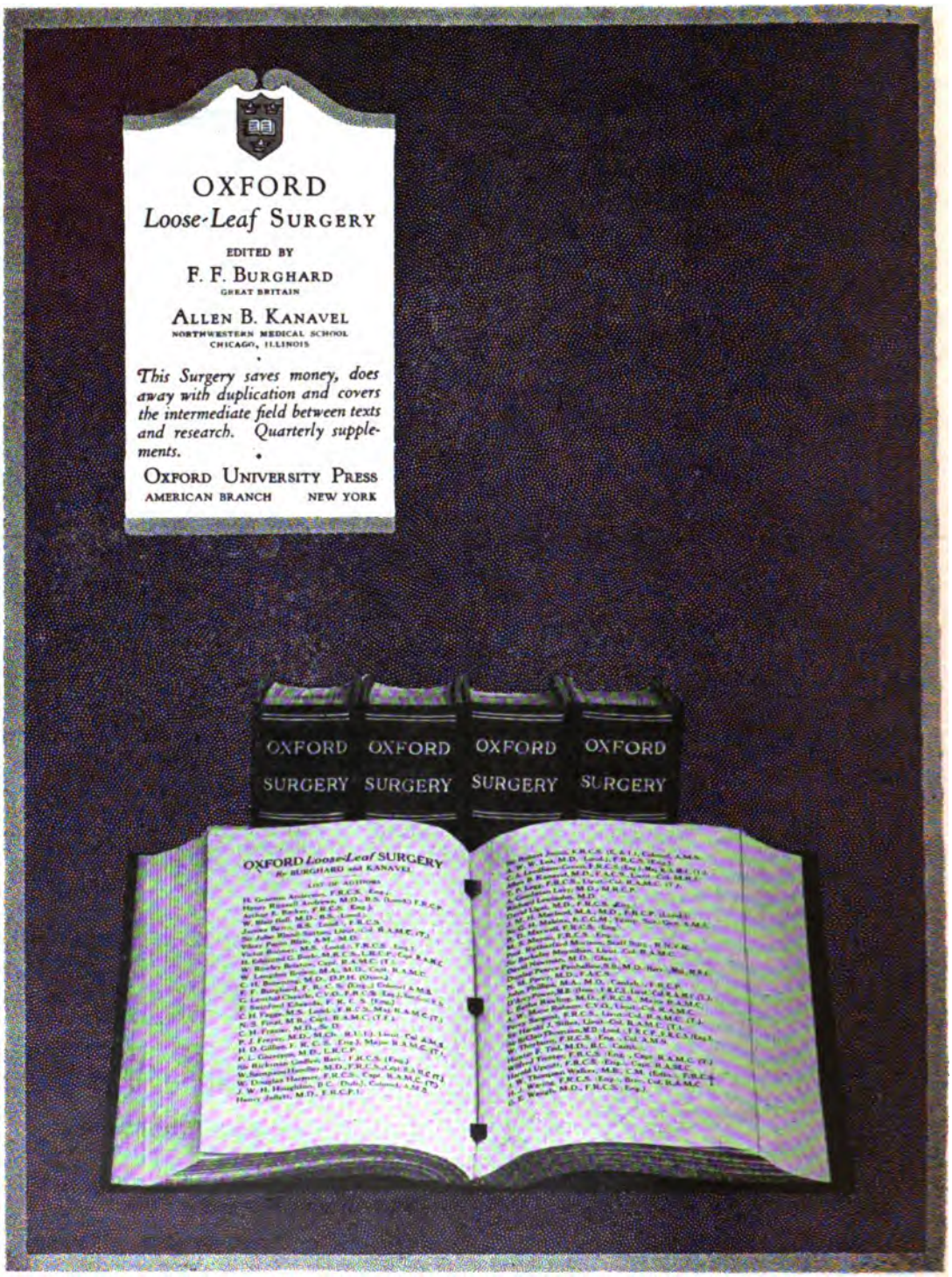
OXFORD
Loose-Leaf SURGERY
EDITED BY
F. F. BURGHARD
GREAT BRITAIN
ALLEN B. KANAVEL
NORTHWESTERN MEDICAL SCHOOL
CHICAGO, ILLINOIS
This Surgery saves money, does away with duplication and covers the intermediate field between texts and research. Quarterly supplements.
OXFORD UNIVERSITY PRESS
AMERICAN BRANCH NEW YORK
OXFORD SURGERY
OXFORD SURGERY
OXFORD SURGERY
OXFORD SURGERY
OXFORD Loose-Leaf SURGERY
BURGHARD and KANAVEL

WAR SURGERY

From Firing Line to Base

By BASIL HUGHES, D.S.O., M.A., M.B., B.C., B.Sc., F.R.C.S.,
Temporary Major, R.A.M.C. (T.F.)
and
H. STANLEY BANKS, M.A., M.B., Ch.B., D.P.H.,
Captain, R.A.M.C. (T.C.)
with Special Chapters by
Lieut.-Colonel L. F. SMITH, C.M.G., R.A.M.C., and
Miss C. BILTON, R.R.C., Q.A.I.M.N.S.
and an Introduction by
Colonel Sir T. CRISP ENGLISH, K.C.M.G., F.R.C.S., A.M.S.,
Consulting Surgeon to the British Forces in Italy: formerly to the British Salonica Force; Surgeon St. George's Hospital, London

THIS work describes as briefly as possible the treatment of wounded men from the time of the infliction of their wounds on the battlefield to the time when they leave the base hospital either for duty or for treatment at the different institutions set apart for special kinds of infirmity.

The authors describe methods of treatment whereby the stiffness and incapacity which follow wounds may be reduced to a minimum, and which will place severely wounded men in the best possible condition to benefit from subsequent orthopedic treatment. The work embodies all the newer and up-to-date methods of wound treatment and older methods have not been discussed. Short chapters on Burns, Amputations, and diseases peculiar to Airmen have been included, as little has appeared in the literature on these subjects. The treatment of Fractures has aimed at rapid sterilization and early secondary suture in order to produce the minimum of stiffness and disability.

Lieut.-Colonel L. F. Smith, C.M.G., contributes a chapter on the part played by Malaria and Dysentery in complicating wounds, as this complication in the Eastern theater has been a serious problem.

The experience of the authors is gleaned from three and a half years' work, both in the Western and Eastern theaters of war, and comprises eighteen months spent with different regiments in the firing line, eight months with a field ambulance, four months with a busy casualty clearing station in France, and one year at a base hospital in the East. The work therefore represents three and a half years of purely personal experience, being founded on practical experience in every part of the field. It is essentially practical and represents solid progressive work.

Royal Octavo, 632 pages, beautifully illustrated by 373 original engravings and 9 colored plates. Price bound in muslin, $9.00 net

WILLIAM WOOD & COMPANY, 51 Fifth Ave., New York

Standard Books for the Surgeon

Operative Gynecology

Up-to-date

By HARRY S. CROSSEN, M.D., F.A.C.S., Associate in Gynecology in Washington University Medical School, and Associate Gynecologist to the Barnes Hospital. 670 pages, 6½ x 9½, with 770 beautiful halftone engravings..... Price, cloth, $7.50

This book is devoted exclusively to operative gynecology and analyzes all the different operative procedures for any particular operation, and points out the best operative technique to elect, stating fully the reasons for so doing and the indications. A striking feature of the book is the superb series of original illustrations by Ivan F. Summers.

Diseases of Women

4th Edition

By HARRY S. CROSSEN, M.D., F.A.C.S. 1160 pages, 6½ x 9½, with 800 engravings and colored frontispiece. Fourth revised and enlarged edition .....Price, cloth, $7.50

Gives the most approved methods of gynecologic diagnosis, therapeutics, pathology and treatment, with a section on the endocrin glands. This is practically a new book. It has been the standard of teaching for years in the majority of medical schools in America. It has no equal.

Cystoscopy and Urethroscopy

New

By GEORGES LUYS, Paris; Former Interne Hospitals of Paris; Former Assistant in the Department of Urinary Diseases at the Lariboisiere Hospital; Laureate of the Faculty of the Academy of Medicine, Paris. Translated and edited with additions by ABR. L. WOLBARST, M.D., New York; Consulting Urologist, Central Islip Hospital and West Side German Dispensaries; Urologist, Beth Israel Hospital and West Side German Dispensaries, etc. 450 pages with 217 figures in the text, and 24 plates in colors, including 76 figures from original water colors ..... Price, cloth, $7.50

A valuable book for the surgeon. The most important works on the direct and indirect methods of cystoscopy and urethroscopy ever published. Translated and brought up to date by an authority, with many features added that will appeal to American readers. The 76 color plates form a distinctive feature of the work.

No need of writing a letter—just indicate the volumes desired, tear off the coupon and mail. Do it today—NOW—before you lay aside this journal.

C. V. Mosby Co.—Medical Publishers

801-809 Metropolitan Building, St. Louis

Canadian Agency: McAinsh & Co., Ltd., Toronto
London Agency: Hirschfeld Bros., Ltd., London

You should subscribe for *The Journal of Laboratory and Clinical Medicine*, edited by Victor C. Vaughan and other leading university and laboratory authorities. Published monthly. Per year, $3.00. Send for information and sample copy.

CUT HERE AND MAIL TODAY

Date.....

C. V. MOSBY CO.
Metropolitan Building, St. Louis, Mo.

GENTLEMEN:

Please send me the books checked with (X) below, for which I enclose check for $..... or you may charge to my account:

Luys-Wolbarst.....$7.50 Crossen-O. G.....$7.50
Crossen-D. W.....$7.50

Name .....

Street .....

Town.....State .....

Surg., Gyn. & Obstet

Reviewers Are Unanimous In Their Praise of

CABOT'S MODERN UROLOGY

"These two volumes will be found useful and valuable as a standard reference work. One only needs to look over the list of contributors to know that each subject is covered by an authority. The numerous engravings and plates are very instructive. One can safely state that the work accomplishes its intention, namely, that 'it gives articular expression to American urology.'"
—*Journal of the American Medical Association.*

"In spite of the fact that there are in the hands of the profession a number of volumes dealing with the subject, the new work edited by Cabot is an innovation. It is by far the most comprehensive study of its kind at present. One can unhesitatingly say that the work brings the subject of urology down to the minute. After reading Young and Pilcher on the prostate, Keys on strictures, Beer and Barney on the testicle, Corbus on syphilis and genital ulcers, one is satisfied that for the present at least the information is final."— *Surgery, Gynecology and Obstetrics.*

"Differs from certain textbooks we could name by reason of the originality and scientific acumen of the authors. These men have made their reputations by their *work* and all through the book we feel we are reading not second-hand matter, but opinions and conclusions based on practical experience." — *Medical Press & Circular, London.*

"The reviewer is impressed (1) with the absence of repetitions and overlapping of subjects, (2) the thorough and careful review of worth while literature, (3) the completeness with which each subject is discussed, (4) the general clarity of expression, (5) the perfect balance of subjects. In conclusion, the work may be placed in that Baconian classification of '. . . . some few (books) to be read wholly, and with diligence and attention.'"— *Medical Record.*

"Refinements in diagnosis and treatment in the comparatively new specialty of urology are brought up to date. No American work of greater merit has been presented on urology and it is doubtful if any recent work abroad approaches it in practical arrangement of the text or in authoritative statement of our present knowledge of genito-urinary surgery." — *Journal of Indiana State Medical Association.*

"A milestone in urology has been reached in the publication of these volumes. Dr. Cabot has gathered around him a number of the country's leading genito-urinary surgeons and these men have contributed the very latest in urological science to these volumes. Will stand for a long time to come as standards."— *Medical Times.*

CONTRIBUTORS

J. DELLINGER BARNEY, M.D.
B. S. BARRINGER, M.D.
EDWIN BEER, M.D.
HORACE BINNEY, M.D.
LEO BUERGER, A.M., M.D.
HUGH CABOT, M.D.
JOHN R. CAULK, M.D.
B. C. CORBUS, M.D.
WALTER J. DODD, M.D.
H. A. FOWLER, M.D.
JOHN T. GERAGHTY, M.D.
FRANCIS R. HAGNER, M.D.
GUY L. HUNNER, M.D.
EDWARD L. KEYS, JR., M.D.
HERMAN L. KRETSCHMER, M.D
BRANSFORD LEWIS, M.D.
RICHARD F. O'NEIL, M.D.
A. T. OSGOOD, M.D.
PAUL M. PILCHER, A.M., M.D.
WILLIAM C. QUINBY, M.D.
HENRY L. SANFORD, M.D.
GEORGE GILBERT SMITH, M.D.
J. BENTLEY SQUIER, M.D.
A. RAYMOND STEVENS, M.D.
GEORGE W. WARREN, M.D.
F. S. WATSON, M.D.
EDWARD L. YOUNG, JR., M.D.
HUGH HAMPTON YOUNG, M.D.

"We have no hesitation in declaring it the best treatise on urology in English or in any other language. There is a certain simplicity and practicalness about the work which distinguishes it favorably from the other treatises on urology. The illustrations and press work are excellent."— *American Journal of Urology and Sexology.*

"A treatise which must occupy a foremost place among the modern books on this subject. One is reminded of Morrow's great system of Genito-urinary Diseases, Syphilis and Dermatology or Frisch and Zuckerkandl's peerless classic of three volumes on the subject of Urology. The work is an enviable achievement, and is destined to be a perennial monument to the expert professional attainments of its editor and collaborators." — *American Journal of the Medical Sciences.*

"A collection of monographs, so carefully chosen as to cover the whole field by men whose opinions represent the last word in American Urology."—*Southern Medical Journal.*

"The most complete work on genito-urinary diseases we have seen. Contains the last word in the diseases discussed."— *Canada Lancet.*

"A standard American book of reference, a satisfactory exposition of urology as developed and improved by a large number of capable diagnosticians, therapeutists, surgeons, and pathologists, whose experience in genito-urinary work has given them the requisite training and background to speak authoritatively."— *American Journal of Surgery.*

Two octavo volumes of over 700 pages each, illustrated with 632 engravings and 17 plates. Cloth, per volume $7.00 net.

PHILADELPHIA
706-8-10 Sansom Street

LEA & FEBIGER

NEW YORK
2 West 45th Street

Lukens Sterile Catgut

TRADE (Bartlett Process) MARK

Make the Test Yourself

Compare It Point for Point
With Any Other Catgut
We Will Send the Samples

It is sterile, antiseptic, strong, supple, elastic; free from excess oil; will not untwist in using and is more than usually resistant to absorption.

Sizes 00-4 Plain *Sizes 00-4 Tanned*

C. DE WITT LUKENS CO.
4908 Laclede Avenue
ST. LOUIS MO., U. S. A

FOR SALE BY ALL DEALERS.

The thought behind the tube—
"the patient on the table"
Not "good enough"-but the best from every standpoint-alone assures that degree of "Catgut Safety" demanded when the patient on the table is "ONE OF MY OWN FAMILY."
Only on this peculiarly personal basis is "Van Horn" Catgut supplied to the profession.
Johnson & Johnson
VAN HORN & SAWTELL DEPARTMENT
NEW BRUNSWICK, N. J.

RADIUM

Salts of Any Desired Purity

STANDARD APPLICATORS

Guaranteed by U. S. Bureau of Standards Certificate

RADIUM EMANATION STATIONS

We furnish Scientific Installations designed to efficiently separate the Emanation from Radium.

The Emanation can be readily put into applicators, leaving the entire supply of Radium Intact.

Write us for information and estimates.

THE RADIUM COMPANY OF COLORADO

DENVER *Incorporated* COLORADO

PURVEYORS TO HIS BRITANNIC MAJESTY'S GOVERNMENT

Campbell

EXPERIMENT AND UNCERTAIN RESULTS ARE ELIMINATED WHEN YOU INSTALL

Campbell Roentgen Apparatus

Sure-X Interrupterless Transformer
Tube Tilt Table
Stereoscopic Tube Table
High Frequency Coils
Electro-Therapeutic
and Roentgen Accessories

Send for Literature

CAMPBELL ELECTRIC CORPORATION
LYNN, MASSACHUSETTS

CONNELL GAS OXYGEN APPARATUS

ANAESTHESIA
APPARATUS AND APPLIANCES

THE CONNELL GAS OXYGEN METER MEASURE APPARATUS, Four Models

THE ANAESTHETOMETER
DELIVERS AUTOMATICALLY ANY VOLUME AND PERCENTAGE OF ETHER VAPOR WITH MATHEMATICAL ACCURACY

CONNELL SUCTION INSUFFLATION APPARATUS
A MOTOR BLOWER MAINTAINING THE STANDARD OF EFFICIENCY SET FOR OUR OTHER MACHINES

SEND FOR OUR BOOKLET *Scientific Anaesthesia*
IT DESCRIBES THE VARIOUS MACHINES WE MAKE

SCIENTIFIC APPARATUS COMPANY, Inc.
162 WEST 34th STREET - - - NEW YORK, N. Y.

"Vanta" Abdominal Binder

KNITTED of soft wool—firm but elastic—it gives just the protection and abdominal support needed, yet always adjusts itself to the full or empty stomach.

A big improvement on the old-fashioned inelastic strip of flannel. Ties with three little bows of *twistless* tape—no dangerous pins—no troublesome sewing.

We would like you to know, Doctor, what an excellent binder this is. Mail us your card, or write on professional letterhead, and we will gladly send you a sample binder free.

EARNSHAW KNITTING COMPANY
1401 West Jackson Blvd - Chicago

The Abdominal Binder illustrated above is only one of the many Vanta Garments that enable baby to be dressed from top to toe without a single pin or button. Our booklet, "Baby's Outfit," describes and illustrates the entire line. May we send you a copy?

HAVE YOUR

Colostomy Patients

wear a comfortable and effective appliance which lies flat and does not show through the clothing.

Devised by DR. J. COLES BRICK

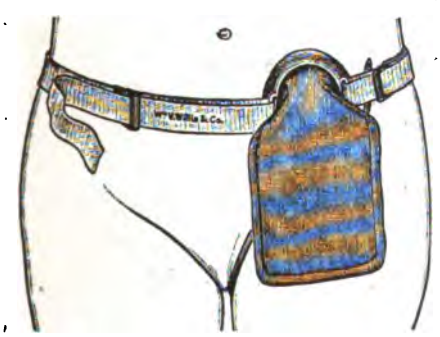

Brick's Colostomy Appliance

Price $5.00, including two rubber bags and an adjustable strap to fit any patient. Discount to physicians.

WM. V. WILLIS & CO.
Surgical Instruments
134 So. 11th St. Philadelphia, Pa.

Foods Shot From Guns

Puffed Wheat and Puffed Rice are whole grains steam exploded. They are sealed in guns, then revolved for an hour in 550 degrees of heat.

The bit of moisture inside of each food cell is thus changed to steam.

Then the guns are shot and the steam explodes. Over 100 million explosions occur in every kernel. Thus the grains are puffed to bubbles eight times normal size.

The object of this process — Prof. Anderson's process — is to attain easy, complete digestion. Probably no other cooking method breaks half so many food cells.

In addition, these airy, flaky bubble grains are delicious food confections.

Puffed Wheat **Puffed Rice**

And Corn Puffs

All Steam-Exploded Grains

The Quaker Oats Company

Sole Makers

(3012)

The Victor U. S. Army Portable X-Ray Unit

TRANSFERS ITS SERVICES FROM
MILITARY TO CIVILIAN PRACTICE

This "unit" was adopted by the Surgeon General's Office for use in the U. S. Field Hospitals in France, and up to the signing of the armistice several hundred of these "units" had been requisitioned by the government for overseas service.

As a Bedside Unit

or for the private office, the Victor U. S. Army Portable X-Ray Unit in its new and compact form will render the same consistent service as it rendered in the field.

Will Be Available In Two Sizes

The smaller unit will energize the standard self-rectifying Coolidge tube up to and including 10 milliamperes at a potential equivalent to that of a 5-inch spark gap. The capacity of the larger unit will be approximately three times greater, although the external dimensions will be identical in both outfits.

The Range of Service Is Agreeably Surprising

The rays as emitted from the tube when energized with the Victor "UNIT" will penetrate all parts of the body, which means that in addition to giving highly satisfactory radiographic service the same "unit" will give equal satisfaction in fluoroscopy.

Simple to Operate and of Rugged Construction

The VICTOR "UNIT" may be connected to any alternating current lighting socket and operated either with a foot switch or push button. (If direct current only is available, a rotary converter is required).

Attractive Prices Include Victor Service

Fair prices backed by personalized Victor Service Stations located in all principal cities suggest the advisability of investigation.

Write for Victor Bedside Unit Bulletin

VICTOR ELECTRIC CORPORATION

Manufacturers of a Complete Line of Roentgen and Electro-Medical Apparatus

CHICAGO
236 S. ROBEY ST.

CAMBRIDGE, MASS.
66 BROADWAY

NEW YORK
131 E. 23d ST.

Sales Offices and Service Stations in all principal cities

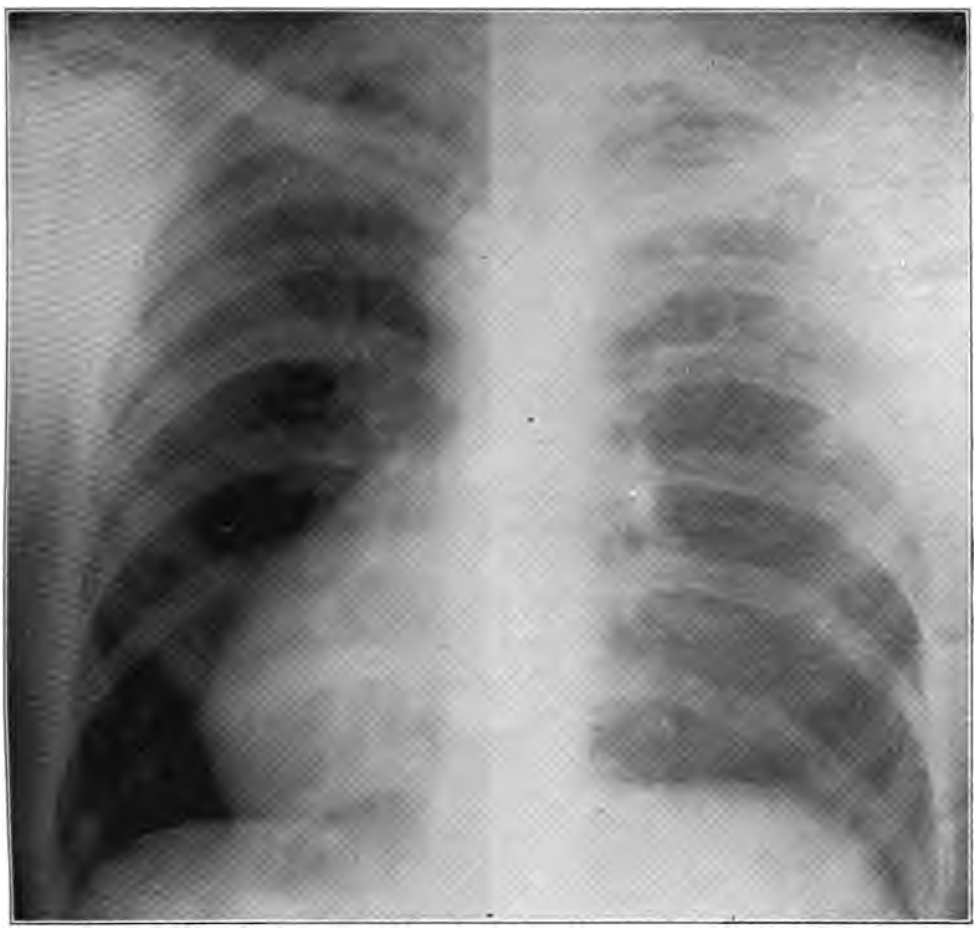

TWO SCREEN PORTION ONE SCREEN PORTION

Efficiency plus, with

Eastman Dupli-Tized X-Ray Films

THE illustration shows a comparison between the values in single and double screening, made at one exposure, on Dupli-Tized Film. This negative was made with a 10 M. A. Radiator type Coolidge tube *in one second*, with a 5-inch spark, at 28 inches. The two screen portion is *over-exposed.*

Ask your dealer for Eastman Dupli-Tized X-Ray Films.

EASTMAN KODAK CO., ROCHESTER, N. Y.

Convincing Evidence

of the Efficiency of the Goodwin Corset as an Aid in the Treatment of Ptosis

That the use of a properly designed and fitted corset will give highly satisfactory results in cases of ptosis is very clearly evidenced in the X-ray pictures of an extreme case of gastroptosis reproduced below.

In the first plate the patient is shown standing erect without abdominal support, 15 minutes after ingestion of bismuth meal. Note that the stomach has dropped low in the pelvis. The second picture, taken 10 minutes later, shows the patient standing and wearing a properly fitted Goodwin Corset. The stomach is raised and supported more than four inches above its former position.

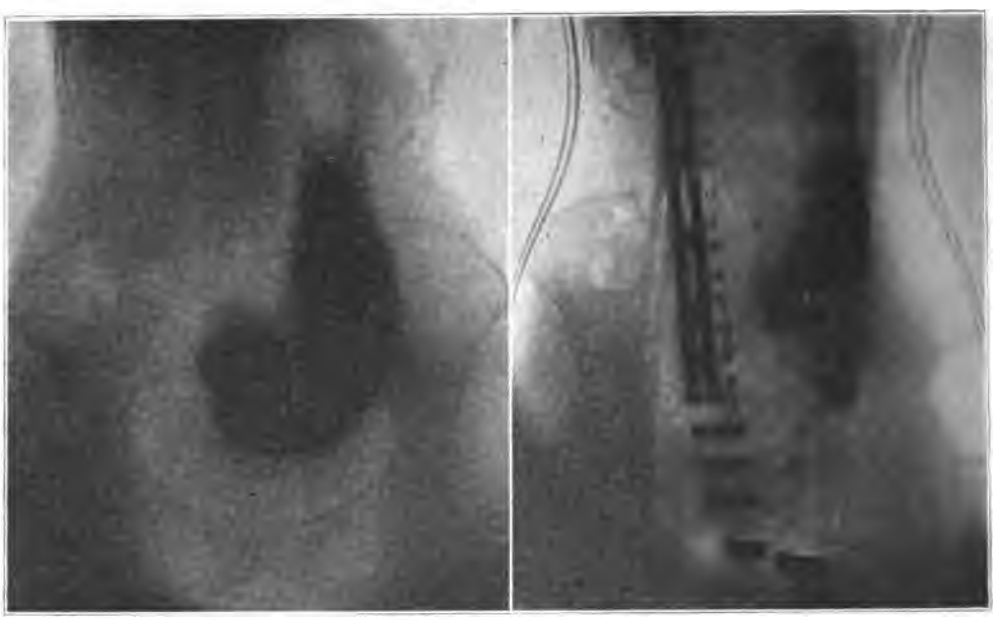

The end results of operative procedures in extreme cases of ptosis leave much to be desired. The continued use of a Goodwin Corset, carefully adjusted each day, becomes an important factor in rebuilding weakened tissues and promoting general health. It offers most effective assistance to the surgeon both in inoperable cases and in post-operative treatment in maintaining the viscera in normal position.

Constructed on scientific principles and along correct anatomical lines it affords constant upward and backward pressure without constriction

New York, 373 Fifth Ave.
San Francisco, 330 Sutter St.
Buffalo, 70 W. Chippewa St.
St. Paul, 422 Peoples Bank Bldg.
Portland, Ore., Woodlark Bldg.
Rochester, 1141 Granite Bldg.
Columbus, 104 N. High St.
Utica, 314 Kempf Bldg.
Houston, 203 Foster Bldg.

Goodwin Corset Shops

Boston, 637 Boylston St.
Los Angeles, 220 W. 5th St.
Davenport, 209 Main St.
Cincinnati, 433 Race St.
Philadelphia, 1120 Walnut St.
St. Louis, 513 Olive St.
Omaha, 1704 Douglas St.
Minneapolis, 816 Nicollet Ave.
Chicago, 57 E. Madison St.
Pittsburgh, 2006 Jenkins Arcade Bldg.
Detroit, 313 David Whitney Bldg.
Kansas City, 413 Altman Bldg.
Jamestown, 514 Prendergast Ave.
Toledo, 219 Superior St.
Spokane, 827 Sprague Ave.
Indianapolis, 55 Monument Place
Denver, 1764 Broadway

Address all correspondence to

S. H. CAMP & COMPANY, Manufacturers, Jackson, Michigan

The Radiator Type, Coolidge X-Ray Tube adopted by the Medical Service of the Army and Navy is available now to all Roentgenologists. Immediate shipment can be made.

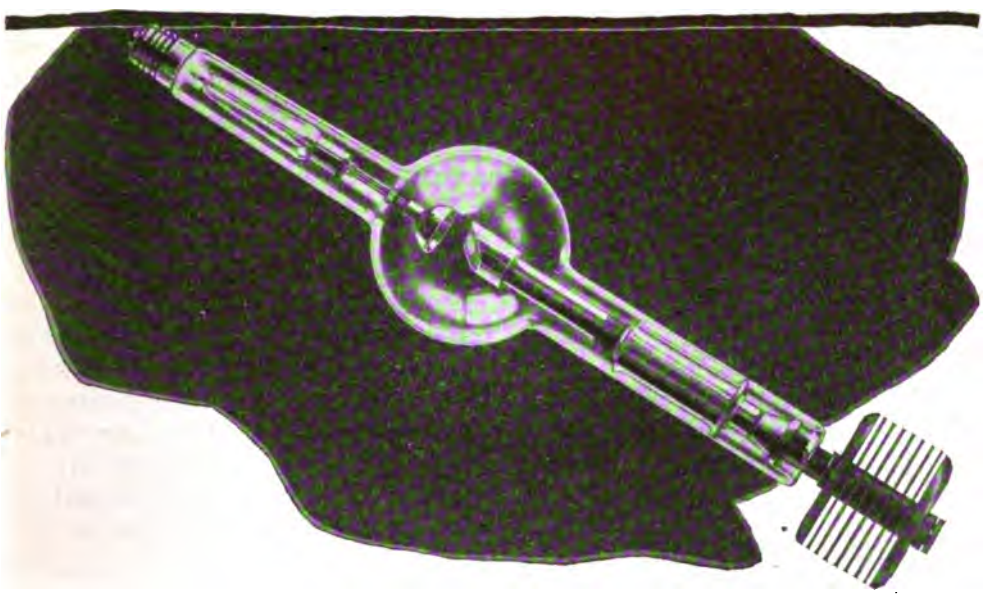

This Radiator Type, Coolidge X-Ray Tube for fluoroscopic and radiographic work was developed specially for the Field and Base Hospitals of the Service.

The bulb is but 3¼ inches in diameter.

The tube has an exceptionally fine focal spot which results in a sharply defined image. This limits the energy to a maximum current of 10 milliamperes and a voltage corresponding to a 5-inch spark between points.

The anode consists of a tungsten button set in a solid bar of copper which is brought out through the glass of the anode arm to a copper radiator. This construction allows the target to cool rapidly between exposures.

Lead glass shields affording a maximum of protection can be supplied for these tubes.

General Electric Company

General Office Schenectady, N.Y.

35B-7

The Storm Binder and Abdominal Supporter

Patented

General Support

Sacro-Iliac Special

Maternity

Storm Binders are being worn in Asia, Africa, Europe, Australia, South America and North America — all the continents — and in the Islands of the Sea — Porto Rico, Tasmania, Philippines, New Zealand, and the others — because physicians know the superiority of The Storm over ordinary belts. We have submitted the evidence — demonstrating what The Storm will do: The members of the Medical Profession are the judges and from far and near come their orders to us giving their verdict in favor of The Storm.

The surgeon in the metropolitan hospital and the general practitioner in the rural district alike approve and order The Storm for their patients. Our work is in co-operation with the physician and our entire resources are always at his command to secure the support desired for any condition.

The Storm Binder is for General Support in visceroptosis, obesity, general relaxation of abdominal walls, etc., etc.

The Storm Binder is for Special Support in hernia, relaxation of the sacro-iliac articulations, floating kidney, descent of stomach, colon and intestines.

The Storm Binder is for Post-Operative Support of incisions in upper, middle and lower abdomen, as after operations upon stomach, gall-bladder, liver, appendix and pelvic organs.

The Storm Binder is for Maternity Cases, relieving the nausea and discomforts of pregnancy.

The Storm Binder is for any purpose for which man, woman or child needs an abdominal supporter.

Ask for Illustrated Folder, giving details of adaptability, construction, prices, materials, testimonials of physicians and full instructions for ordering by mail.

Mail Orders Receive Immediate Attention

KATHERINE L. STORM, M.D.

1541 Diamond Street **PHILADELPHIA**

Satisfactory Standardization

Satisfactory standardization of technique is facilitated by the exclusive use of Diagnostic X-Ray Plates—equally excellent for direct and screen work.

Their superior speed in conjunction with their capacity for unsurpassed differentiation of detail and brilliant contrast help to raise the standard of the roentgenologist's work.

Diagnostic plates develop simply with any well balanced developing formula. They fix out stain-free and absolutely clear. They are manufactured from only new selected glass of the highest quality.

AMERICAN PHOTO CHEMICAL COMPANY
ROCHESTER NEW YORK

For Sale by Leading Supply Houses

DIAGNOSTIC

RADIUM RENTAL SERVICE

By The Physicians' Radium Association of Chicago

(Incorporated under the laws of Illinois, "Not for Profit")

BOARD OF DIRECTORS

William L. Baum, M. D.
N. Sproat Heaney, M. D.
Frederick Menge, M. D.
Thomas J. Watkins, M. D.
Albert Woelfel, M. D.

MANAGING DIRECTOR

Albert Woelfel, M. D.

ESTABLISHED to make Radium more available in the *Middle States* and to furnish advice based on extensive observations, about its approved therapeutic uses. Maintains the equipment, large and complete in its makeup, that is needed to meet the special requirements of any case in which radium therapy is indicated. Radium loaned to any responsible physician. Moderate rental fees charged.

For Full Particulars Address

THE PHYSICIANS' RADIUM ASSOCIATION

1104 Tower Bldg., 6 N. Michigan Ave., Chicago Telephones, Randolph 6897-6898

Cash for Back Numbers

Will pay 50 cents each for copies of the following back numbers of *Surgery, Gynecology and Obstetrics*, if in good condition for binding.

August, 1905
January, 1906
March, 1906

Surgical Publishing Company
30 No. Michigan Ave. CHICAGO

NEW LIVE RUBBER

Kinney's "WELL-NOWN" Surgeons' Gloves fit perfectly. Their construction guarantees repeated sterilizations.

SEND YOUR ORDER TODAY

Medium weight, Plain		Medium Weight, Pebbled, Non-Slip	
2 pairs	$1.20	2 pairs	$1.40
6 "	3.60	6 "	4.20
12 "	6.00	12 "	6.75

Above styles come in sizes 6 to 10

Extra Heavy Smooth Gloves (Sizes 7 to 9), per pair $1.00

Tissue cots, assorted sizes, 3 dozen lots (no less) ..... .50

All Goods Sent Prepaid on Receipt of Price
Elastic Goods Prices Sent on Request

L. T. KINNEY & CO.
57 E. Randolph St., Chicago, Ill.

B&B *Surgical Dressings*

The Standard for 25 years

BAUER & BLACK
Chicago New York Toronto

WE CAN SUPPLY YOU WITH

Gauze and Bandages

Prices upon request

The Good Manufacturing Co.
156 N. Wells Chicago

FOR THE REST THAT BUILDS UP

Your patient whose system has been weakened by long illness or overwork, will find in the bright, sunshiny winter climate of Colorado Springs true upbuilding rest. This invigorating mile-high region has been found of marked benefit to those of the East who need the stimulating change of altitude.

The visitor spends his time in outdoor life with smooth motor roads, good golf links, winding trails for "hiking" or horseback riding, far-famed mineral springs, and pine-clad mountains at his command.

A photographic record of 100 winter days and a handsomely illustrated 88-page book, written by physicians of high standing who are constantly approaching these problems from your own professional view point, is yours for the asking.

Climatic Conditions Committee
Chamber of Commerce
151 Independence Bldg. Colo. Springs, Colo.

Bound Volumes

Surgery, Gynecology and Obstetrics is especially designed for binding in book form. Our standard volumes are substantially bound in an extra good grade of blue art canvas, stamped in gold. Each volume consists of six numbers: two volumes to the year, January to June and July to December.

Surgery, Gynecology and Obstetrics with International Abstract of Surgery, per volume **$7.50**
Surgery, Gynecology and Obstetrics *without* the Abstract, per volume - - - - **4.00**
International Abstract of Surgery, per volume - - - - - - - - - - **4.00**

We Can Supply All Back Numbers in Bound Volumes Except Vol. II

Back Numbers Returned for Binding

Where copies are returned by subscribers in exchange for bound volumes, the charge per volume for binding will be as follows:

Surgery, Gynecology and Obstetrics with International Abstract of Surgery, per volume **$2.75**
Surgery, Gynecology and Obstetrics, per volume - - - - - - - - - - **1.75**
International Abstract of Surgery, per volume - - - - - - - - - - **1.75**

The prices quoted above include carriage charges on shipments to points in the United States and Canada. Express or freight charges on journals returned for binding must be prepaid.

Authorities on Corpus Luteum

For Correcting Abnormal Ovarian Functionation, Amenorrhea, Dysmenorrhea, Nervous Irritability

CURTIS F. BURNAM, M.D., Baltimore, Johns Hopkins Medical School.—"Corpus Luteum Extract, with Suggestions as to Its Use in Gynecologic Practice," *Journal of the American Medical Association*, August 31, 1912.

ADAM P. LEIGHTON, JR., M.D., L.M. (Dublin), Portland, Maine.—"The Use of Luteum Extract in the Treatment of Menstrual Disorders," *American Journal of Obstetrics and Diseases of Women and Children*, November, 1915.

OLIVER T. OSBORNE, M.A., M.D., New Haven, Connecticut, Medical Department, Yale University.—"Ovary: Corpus Luteum," *New York Medical Journal*, September 7 and 14, 1918.

Reprints of These Papers Sent Upon Request

Corpus Luteum of the Sow—Lutein Tablets, H. W. & D.

2 grain, 100 in a tube 5 grain, 50 in a tube

HYNSON, WESTCOTT & DUNNING - Baltimore

other things being equal

the more porous the hypodermic tablet, the more soluble it is. But those "other things"—they are equally essential.

For instance:—the selection of the most soluble, least irritating form of the drug; the delicate adjustment of the diluent to suit each drug or combination.

And then there's the "know how"—that imponderable thing that makes you the successful surgeon, the chosen consultant, the favorite family physician.

"S & D specifiers" all declare that we have that "know how" and that that's why we are the "hypodermic tablet people."

SINCE 1860 Sharp & Dohme
CAREFUL CONSCIENTIOUS CHEMISTS

American Made
NOVOCAIN
(*Procaine-Metz*)
In the Service

WE have furnished the U. S. Government with practically the entire output of our factory, including Novocain Powder, Novocain Tablets and Novocain-Suprarenin Tablets.

This fact has restricted our output to the profession, but our increased production now enables us to supply Novocain through the regular trade channels promptly.

Insist on N-S Tablets! No Harrison Narcotic Blank required.

Send Us the Name of Your Dealer!

H. A. METZ LABORATORIES, INC.
122 HUDSON STREET
NEW YORK



THE BATTLE CREEK SANITARIUM AND HOSPITAL—Established 1866

Medical	Surgical	Orthopedic
Neurological	Obstetrical	Reconstructive

Educational Departments

Training School for Nurses Normal School of Physical Education School of Home Economics and Dietetics
Students received on favorable terms Registered trained nurses, dietitians and physical directors supplied

Descriptive literature mailed free upon request

THE BATTLE CREEK SANITARIUM

Box 243, BATTLE CREEK, MICHIGAN

Surgical Technique: Instruction and Practice

AN ORIGINAL plan of teaching Surgical Technique, giving the instruction, and enabling the doctor to do the operations over and over, until he has mastered all details. Particular attention is given to the table toilet, and the work is performed as humanely as if the operations were being done upon an anaesthetized human. *The operations are all performed by the student.*

Each table is furnished with the same instruments that are to be found in any well-equipped operating room, and gowns and gloves are supplied to each student.

The Laboratory is open daily from 8:30 to 5 o'clock, which makes it possible for the man whose time away from his practice is limited, to get the work in the shortest possible time.

Special courses may be had in surgical anatomy on the cadaver.

Northeast Corner of Operating Room

Personal Instruction, Actual Practice, and Exceptional Equipment. Course Completed in 7 Days (50 hours), Minimizing Time Away from Practice.

As to the Plan, Time, Fee, etc., Address

The Laboratory of Surgical Technique

Phone Midway 4896 7629 Jeffery Ave., CHICAGO

The L. of S. T. of Chicago

Gentlemen: Send me information regarding the above.

Name.....

City.....

State.....

Stanolind

Reg. U. S. Pat. Off.

Surgical Wax

For use in the hot wax treatment of burns, surgical wounds and similar lesions.

It is unapproached in purity and may be applied without incorporating with it any therapeutic agent.

Many advanced workers advocate its use in that manner.

However, surgeons may use it as a base for any of the published formulas, and may be assured that it is the purest and best wax that modern science can produce.

It conforms to the requirements of the Council of Pharmacy and Chemistry of the American Medical Association.

Stanolind Petrolatum

In Five Grades

"Superla White" is pure, pearly white, all pigmentation being removed by thorough and repeated filtering.

"Ivory White," not so white as Superla, but compares favorably with grades usually sold as white petrolatum.

"Onyx," well suited as a base for white ointments, where absolute purity of color is not necessary.

"Topaz" (a clear topaz bronze) has no counterpart—lighter than amber—darker than cream.

"Amber" compares in color with the commercial grades sold as extra amber—somewhat lighter than the ordinary petrolatums put up under this grade name.

STANDARD OIL COMPANY

(Indiana)

Manufacturers of Medicinal Products from Petroleum

910 S. Michigan Avenue Chicago, U. S. A.

782

New York Post-Graduate

Medical School and Hospital

Courses arranged for the general practitioner in all branches of medicine. Separate courses on every subject and Special Practical Courses, where individual instruction is given in the following subjects:

Anaesthesia; Colon and Rectal Diseases; Complete Eye Seminar, embracing seven Special Courses; Ear Operations (Cadaver); Nose and Throat Operations on the Cadaver and in the Operating Rooms; Bronchoscopy; Nose and Throat Pathology; Abdominal Diagnosis; Physical Diagnosis; Diagnosis and Treatment of Constitutional Diseases of the Adult; Dietetic and Metabolic Problems; Infectious Diseases; Neurology; Stomach Diseases; Infant Feeding and Diagnosis; Intubation and Lumbar Puncture; Practical Pediatrics; Cystoscopy—Male and Female; Diagnosis and Office Treatment of Gynecological Cases; Gynecological Operations on the Cadaver; General Surgery on the Cadaver; Genito-Urinary Surgery on the Cadaver; Military Orthopedic and Bone and Joint Surgery; Treatment and Care of Fractures; X-Ray and Laboratory Work.

The Hospital has a bed capacity of over 400. The average number of patients admitted daily to the Dispensary is 800. The Hospital and teaching facilities are as extensive during the summer months as during the winter session. Cadaver courses omitted during June, July, August and September.

Through the courtesy of the Secretary, a two-day complimentary ticket is given, which enables the visiting physician to decide upon the courses best suited to his purpose and to meet the instructors in the various departments before registering for any work.

For Further Particulars Address

SECRETARY OF THE FACULTY

305 East Twentieth Street **NEW YORK CITY**

SURGERY, GYNECOLOGY AND OBSTETRICS

AN INTERNATIONAL MAGAZINE, PUBLISHED MONTHLY

VOLUME XXVIII FEBRUARY, 1919 NUMBER 2

THE CLINICAL SIGNIFICANCE OF CONGENITAL ANOMALIES OF THE KIDNEY AND URETER

WITH NOTES ON THE EMBRYOLOGY AND FŒTAL DEVELOPMENT OF THE KIDNEY

BY H. G. BUGBEE, M.D., F.A.C.S., NEW YORK
Urologist to St. Luke's, Woman's and Lying-In Hospitals
AND
J. R. LOSEE, M.D., NEW YORK
Pathologist to Lying-In Hospital

A COMPREHENSIVE knowledge of the embryology of a given species, human or otherwise, is necessary before one can arrive at definite conclusions concerning the cause of anomalies of development in individuals of the particular species. In this paper, therefore, we shall endeavor first to give a brief outline of the development of the organs of the upper urinary tract in the human, and then to trace the relationship between this and the various anomalies which have been noted.

A bibliography, together with a brief summary of some of the published observations, is appended.

In the development of the kidney we are concerned with the growth of three definite and distinct organs, which are formed at different stages in the growth of the embryo. These organs are known as the pronephros, the mesonephros, and the metanephros. The first two degenerate, while the third remains as the permanent kidney. It so happens that the second begins to develop while the first degenerates, and the third begins to develop as the second degenerates, so that both a constructive and a destructive process is going on at the same time.

The pronephros carries on an excretory function during its existence, but there is some discussion as to whether the mesonephros exercises a similar function. Some observers believe that it has not such a function, but that it may be active in some other way. It is known, however, that it does form the beginning of the metanephros and of the reproductive apparatus. The metanephros goes on to complete development, and is the active excretory organ at birth.

PRONEPHROS

The first anlage of the pronephros consists in the pronephric tubules. Each primitive segment stalk throughout the body cavity produces a pronephric tubule, which is composed of a principal tubule, a pronephric chamber, nephrostome canal, and an internal and external glomerulus. By the union of these pronephric tubules a collecting duct or an excretory duct is formed, running the entire length of the body cavity. The development of the pronephric tubules is divided into two portions: first, the development of the pronephric tubules and the collecting duct; second, the development of the terminal portion of the primary excretory canal.

The first anlage of the glandular portion occurs in an embryo 1.73 millimeters in greatest length. The development goes on so quickly that when the caudal portion is developed in an embro of 2.5 millimeters the cranial sac is beginning to dissolve, so that as the lower portion develops the upper portion degenerates. In an embryo of 4.25 millimeters vertex-breech length, the degeneration of the pronephros is well advanced, but the time of its complete disappearance cannot be definitely stated, since it extends into the territory of the mesonephros. This takes place approximately when the embryo is 4.9 millimeters in its vertex-breech length.

The blood supply of the pronephros is derived from a ventral arch system which is divided into two groups, a cranial group of aortic arches, and a caudal group of originally pronephric arteries.

MESONEPHROS

The mesonephric tubules develop from the same parent tissue as the pronephros, that is, the stalks of the primitive segment, and they make use of the same efferent canal, the primary excretory duct. The principal tubules of the mesonephros, however, usually arise more mesially than those of the pronephros.

The mesonephric anlage begins to develop from the nephrogenic cord which arises from the primitive segment stalks, cut out, as a whole, from the mesoderm in an embryo of 2.5 millimeters greatest length. Eight mesonephric vesicles form anteriorly and posteriorly. As the embryo increases in length, the oldest tubules gradually take on various changes in shape, until at 9.5 millimeters greatest length they are complete. In an embryo of this length there are 32 to 34 tubules, consisting of malpighian corpuscle and a secreting and a collecting tubule. In an embryo 19.4 millimeters vertex-breech length, they separate from one another and, as a result of the curvature of the excretory duct, become stronger in order to reach the mesially placed bladder. The malpighian corpuscles are pressed together, and the collecting duct of one tubule may serve as the efferent for several. As a further result of the bending of the excretory duct, the orifices of several collecting ducts unite to form a single one.

The degeneration of the mesonephros occurs in two periods. The first begins as soon as the growth cranially is complete, that is, in an embryo 5.3 millimeters in length, and is finished in an embryo of 21 millimeters greatest length. During the process, the greatest part of the mesonephros at the cranial end is degenerated. The second period comes on so gradually that definite time limits are not possible for it. Within this period there occurs a new suppression of tubules and a selection of those that will enter the service of the reproductive system, and of those that will persist, even in the adult human organism, as the *paragenitalis*. In animals without a metanephros this latter or lower portion becomes the actual functionating kidney. Estimated by tubules, 57 are degenerated out of a maximum of 83 that develop. The corresponding portion of the excretory duct disappears along with the tubules. From the stage of 21 millimeters greatest length onward, all embryos show a rather constant number of mesonephric tubules in the lumbar segment, but these are almost all broken in one or several places. The first mesonephric arteries are formed in an embryo of about 5.3 millimeters in length. They arise from the lateral surface of the aorta, pass to the malpighian corpuscles and terminate in these with an enlargement, assuming a spherical shape. The arteries are not paired. In the cranial segment one artery may lie in each segment or in two or three segments, but in the caudal segment the arteries become more numerous. From the sixteenth thoracic to the third lumbar all the mesonephric arteries persist, and from these are formed the phrenic, suprarenal, accessory renal, internal spermatic, accessory spermatic, and also the branches to the lymph nodes and sympathetic ganglia in the region between the superior and inferior mesenteric arteries.

METANEPHROS

The metanephros may be divided, embryologically, into two portions, the secretory or glandular portion, and the efferent appara-

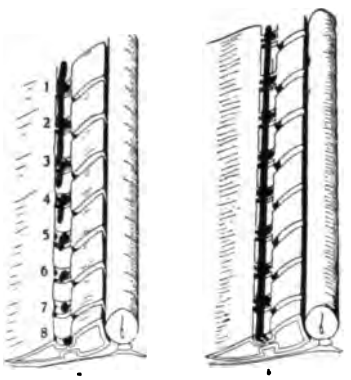

Fig. 1.

Fig. 1. Diagram of the development of the pronephros. *a*. The principal tubules, *5*, *6*, *7*, and *8*, develop by evagination from the parietal mesoblast of the primitive segment stalk. They grow caudally (*3* and *4*) and reach and overlap the succeeding tubules, passing laterally to them (*2*). The principal tubules, which are thus brought into apposition, fuse, and a collecting duct (*1*) is formed. *b*. The collecting duct remains in connection with the various segment stalks by means of the principal tubules. (From Keibel and Mall, *Human Embryology*.)

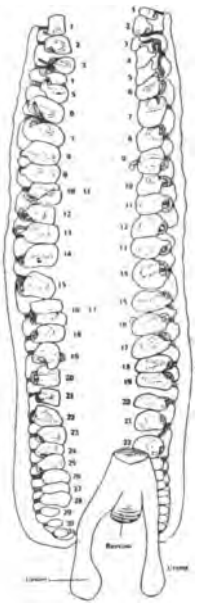

Fig. 2.

Fig. 2. Model of the mesonephroi, the metanephroi and the bladder of a human embryo of 7 millimeters greatest length. The mesonephroi have a perpendicular position and the individual tubules are at sufficient distances, so that the malpighian corpuscles lie in a single row. The lowest tubules are still developing, but have already united with the excretory duct. The fully developed canals are S-shaped. Most ventrally are the malpighian corpuscles, in the middle is the secreting tubule, and most dorsally is the collecting tubule. The loop formed by the secreting and collecting tubules usually has not yet reached the medial border of Bowman's capsule. The whole coil of a mesonephric segment (Malpighian corpuscle and the two tubules) lies still in one horizontal plane. (From Keibel and Mall, *Human Embryology*.)

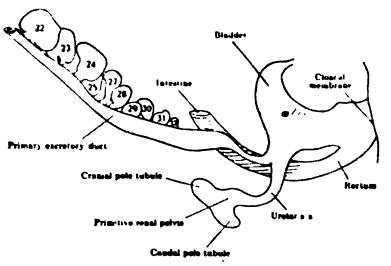

Fig. 3.

Fig. 3. Model of the bladder, primary excretory duct, and ureter of an embryo of 9.5 millimeters greatest length.

The common portion by which the primary excretory duct and the ureter open into the bladder is enlarged and is more sharply differentiated from the wall of the bladder. The ureter has differentiated into the primitive renal pelvis and the ureter segment stalk. The two pole tubules are beginning to grow out from the primitive pelvis. (From Keibel and Mall, *Human Embryology*.)

tus. We will first consider the latter, namely, the ureter, the renal pelvis, and the collecting tubule system, all of which develop from the primary excretory duct.

The anlage of the ureter arises as a hemispherical outgrowth of the primary excretory duct, in an embryo sometimes between the stages of 4.5 millimeters and 5.3 millimeters total length. The short ureter grows at first dorsally, toward the vertebral column, but later, in an embryo of 8.5 millimeters and 9.5 millimeters greatest length, it forms a curve which becomes gradually flatter, and the ureter grows cranially. When it gains the dorsal surface of the mesonephros, it lies in the retroperitoneum, surrounded by loose mesochyme. Here radial outgrowths of the collecting tubules take place, and the definite position of the renal pelvis is reached, in an embryo 9.5 millimeter to 13 millimeters greatest length, at the level of the second lumbar vertebra. While the ureter is still in the period of outgrowth the primitive pelvis elongates in the craniocaudal direction and thus acquires its poles, both of which grow out in opposite directions, and so begin the formation of the collecting tubules of the first order. Later horizontal tubules develop, corresponding to the middle of the renal pelvis, one directed ventrally and the other dorsally. These four primitive tubules become enlarged at the blind ends to the so-called ampullæ. From the various angles of the ampullæ secondary collecting tubules grow out parallel to the future surface of the kidney. When they attain a certain length they develop ampullæ, from the various sides of which tertiary tubules are formed, and so the process goes on up to the formation of the terminal collecting tubules. The formation of new collecting tubules ceases at the fifth month. The entire ureteric tree spreads

Fig. 4. Horseshoe kidney. This specimen was obtained from a full-term male infant which was stillborn. It is typical of this type of fused kidney, being united by a bridge of normal renal tissue at the lower poles. On the left side there is one ureter which divided into three portions as it enters the pelvis. On the right there are two ureters, the upper one collects the urine from the lower pole and bridge. These ureters enter the wall of the bladder separately, but have a common orifice in the trigone.

in a fan-like manner, giving as much room for growth as possible, resulting in abundant branches at the periphery and scanty at the center. Some of the tubules are compressed in growth, and are later taken up in the pelvis. An embryo of 10 millimeters greatest length has two pole tubules in process of formation, and one of 11.5 millimeters greatest length shows anlagen of the central tubules.

The secretory or glandular portion of the metanephros is derived from a group of cells known as the metanephrogenic tissue, which accompanies the ureter in its ascent, and which always covers the primitive renal pelvis. The metanephrogenic tissue has its origin in the metanephrogenic cord, which arises from the mesoderm. The tissue breaks up into as many parts as there are collecting tubules, and covers the surface and sides of these. It is at first a thin structure, but rapid cell multiplication goes on and it becomes denser. Each ureteric tree and its nephrogenic cap is known as a malpighian pyramid. These pyramids are pressed together and unite to form a single investment over the entire kidney. The lines along which the metanephrogenic tissue passes down from the surface beneath the various pyramids are marked by grooves which limit the area occupied by each pyramid, and thus a somewhat lobulated structure is formed. There are at first four pyramids, two pole pyramids and two central ones corresponding to the central tubules. These primary pyramids divide into secondary pyramids, and these, in turn, give off subordinate pyramids, and thus a finer lobulation takes place.

The uriniferous tubules are formed from a compressed mass of metanephrogenic tissue which is formed between the old and young tubule that has just been given off. In this mass a lumen, situated eccentrically, appears and converts the sphere of cells into a metanephric vesicle. The peripheral wall of this vesicle is the thinnest, and from this the entire uriniferous tubule, with the exception of Bowman's capsule, is formed. The wall towards the pelvis, or the central wall. forms Bowman's capsule. This anlage of the uriniferous tubule unites with the young collecting tubule, their lumina being continuous. As soon as this union takes place the former assumes an S shape. The lower limb of the S extends from Bowman's capsule, while the upper limb connects with the collecting tubule. The failure of the uriniferous tubule and the terminal collecting tubules to unite is said to be the cause of congenital cystic kidney.

The malpighian corpuscle begins as a shell-like form, becoming gradually spherical in an embryo 19.4 millimeter, and is complete in an embryo 28 millimeter greatest length. An evagination forms at a point where a portion of the tubule becomes continuous with Bowman's capsule. This evagination increases in size, and the lateral wall of the sphere grows toward it, so that the wide entrance into the shell-like cavity becomes converted into a natural opening through

Fig. 5. Horseshoe kidney. This specimen was obtained from a stillborn female infant at eight months. The lower poles are united by a bridge of tissue which extends well down over the brim of the pelvis, and lies opposite the bifurcation of the aorta. The pelves are not continuous. There are two ureters from the right kidney. one from the upper portion and the other from the lower portion and part of the bridge. They pass over the anterior surface of the kidney and run a parallel course to unite in the wall of the bladder, for there is a common orifice in the trigone. From the left kidney there is a single ureter which passes over the anterior surface of the kidney, and takes its normal course to the bladder.

Fig. 6. Sigmoid kidney. This specimen was obtained from a stillborn female infant near term. The mass of kidney tissue made up of both the left and right kidneys, lies on the left side. The upper pole is opposite the first lumbar vertebra, and the lower pole is in the true pelvis. The pelves are not continuous. The pelvis of the upper kidney is normally placed and the ureter takes a normal course downward and enters the left side of the bladder. The pelvis of the lower kidney is anterior, as this kidney did not rotate. The ureter lies on its anterior surface, crosses over to the right side, and enters the right side of the bladder. The trigone is normal. It will be noticed that both suprarenals are in their normal position.

which the vasa afferens and efferens find ingress and egress. The vascular and urinary poles of the malpighian corpuscles lie opposite to each other.

The development of the cortex begins with the formation of the first generation of the uriniferous tubules, and its increase in thickness depends in the first place upon the new formation of additional tubules, and in the second place on the growth of those already present.

The medulla begins to form after the formation of the definitive renal pelvis. Its increase in length and thickness is due to an increase in the diameter of the individual collecting tubules. During fœtal life it is the medulla that grows principally. After birth a cessation of the growth of the medulla occurs, and continues until the seventh year, during which period the diameter of the cortex increases rapidly. After the seventh year both the cortex and the medulla develop equally.

CAPSULE

Embryonic connective tissue surrounds the growing ureter, the outgrowing tubules and the metanephrogenic tissue from the beginning. But this is not considered a capsule until it can be separated from its adjacent structures, which is at first distinctly seen in an embryo of 70 millimeters greatest length.

Fig. 7. Congenital hydronephrosis. This specimen was obtained from a stillborn infant at term, and showed a very much distended abdomen at autopsy. Before examination a diagnosis of fœtal ascites was made. Section showed that there was a distended cystic tumor lying behind the peritoneum, which contained 400 cubic centimeters of fluid. The upper portion of the wall of this cyst is made up of the thinned out cortex with its fœtal lobulations. The pelvis is divided into two portions, the smaller one is continuous with the ureter; which presents an occlusion at the point of union. This ureter varies in size, and enters the bladder in its normal relation. The right kidney is a typical congenital cystic kidney.

CHANGE IN THE POSITION OF THE KIDNEY

At 7 millimeters in length the renal bud lies opposite the second sacral vertebra, and its pelvis looks anteriorly. At 10 millimeters the upper border of the kidney is at the brim of the pelvis, and at 14 millimeters the upper pole is at the third lumbar vertebra. At 16 millimeters the kidney has passed the second lumbar line and has rotated 90° on its long axis, so that the pelvis is lateral to the ureter and points toward the vertebral column. At 20 millimeters the ureter and kidney are in their relatively normal position. Felix says that during the first half of fœtal life the craniocaudal diameter of the kidney corresponds approximately to the first three lumbar vertebræ. In the second half the cranial pole lies at the level of the eleventh rib, and the caudal one descends to the upper border of the fifth lumbar vertebra.

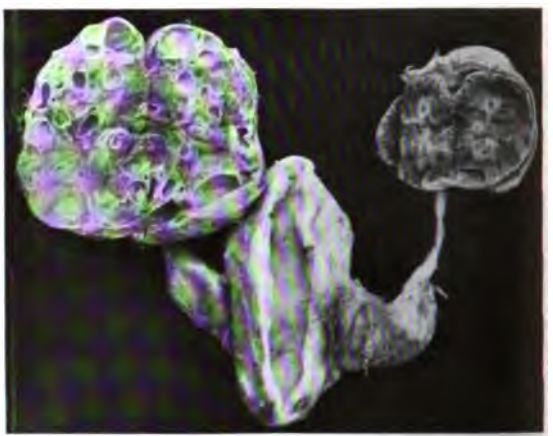

Fig. 8. This specimen was obtained from a stillborn infant at birth. It shows a stricture at the vesical neck, hypertrophied bladder, dilated ureters, torsion of the ureters at the lower third on the left side and upper third on the right side with partial cystic degeneration of the kidneys.

RENAL ARTERIES

The renal arteries are not new formations, each being formed from a mesonephric artery. The kidney climbs upward to the mesonephric arteries, and as soon as sufficient blood supply is assured, the caudal branches separate from it. When the kidney has acquired its definite position it possesses several renal arteries, one of which becomes greatly enlarged to form a definite artery, while the others degenerate or persist as accessory renals. The definite renal artery is either the last vessel of the second group or the first of the third group of mesonephric arteries. In an embryo of 26 millimeters greatest length the arrangement of the arterial apparatus is acquired.

ABNORMALITIES OF THE KIDNEY CONSIDERED AS TO THEIR NUMBER, FORM AND POSITION

There may be complete absence of one or both kidneys. In such a case the anlage of one or both failed to bud off from the excre-

Fig. 9. Torsion of the ureters. This specimen was obtained from an infant which lived eight days. It was suddenly seized with convulsions and died four hours later. At autopsy both kidneys showed a moderate degree of hydronephrosis. The right ureter; 1½ centimeters from the kidney, became dilated to four times its normal size for a distance of 4 centimeters, at which point it appeared to be twisted on itself. After turning one-half of a revolution a probe was easily passed through to the bladder. The left ureter was also dilated, and presented evidences of torsion 2 centimeters from the bladder. A silkworm-gut suture shows the point of torsion.

Fig. 10. Incomplete double ureter.

tory duct, or, if the anlage were formed, it was either arrested or absorbed in the early course of its development. Absence of the ureter and maldevelopment of the reproductive organs result.

Supernumerary kidneys have occurred on one or both sides. If the renal bud sprouts early, or if the division takes place at different points, each division may simulate a mass of mesochyme, in which case there would be a double secondary anlage for the kidney. These anlagen are usually placed one above the other. They either remain distinctly separate throughout the period of their growth, forming two kidneys, on one or both sides, or they fuse at some time during the course of development, forming one kidney on each side. Both sides may fuse, forming a large mass of kidney tissue.

Changes in form involving both kidneys result in what is generally known as the horseshoe kidney. It has already been mentioned that in an embryo of 7 millimeters both kidneys lie opposite the second sacral vertebra. Both may be placed at the same level, having the same relative position, or one may be ventral to the other. They may be placed one above the other, and the upper pole of one may fuse with the lower pole of the other. If they lie at the same height and at the same relative position, they may fuse at the lower poles or upper poles, or centrally. Fusion at the upper poles is much less common than fusion at the lower poles. It probably occurs before the organ has grown out of the true pelvis. The earlier the date of fusion the more definite is the line of demarcation. In cases of very late fusion, when the kidney has obtained its normal position, the union may be limited to the capsule.

In fusion at the lower pole, which is more common because they are nearer to each other than any other part of the kidney, there is always a well marked bridge of kidney parenchyma joining them. The pelvis and ureters lie ventral to the bridge. If the ureters lie behind the bridge the fusion is a later one. The pelves do not fuse because they are already well developed and independent structures before the parenchyma fuses. When central fusion takes place the organ

Fig. 11. Single kidney. (Case 1).

Fig. 12. Fused kidney. (Case 4).

lies in the middle line and the ureters emerge ventrally. This type is known as the disc kidney. These kidneys may have two ureters, each having a normal course and presenting a normal trigone, or there may be multiple incomplete ureters.

End-to-end fusion of the two kidneys is quite uncommon. When it occurs, both kidneys are placed on one side, generally the lower kidney is not rotated, and the ureter emerges from its anterior surface. These are late stages of fusion, as the outline of the organs can be distinguished easily one from the other. This type is known as the sigmoid kidney.

Fœtal lobulations are sometimes observed in the adult kidney. This form is due to the fact that the growth of the cortex during postfœtal life did not take place vigorously enough to obliterate the depression in the surface, and also that the cortical columns were of such depth that the usual postfœtal growth was insufficient to fill the grooves.

One of the most common forms of abnormal position of the kidney is that known as ectopic or pelvic kidney. These kidneys may be found in the pelvis or at the brim of the pelvis. The fact is that they have failed to migrate during the early embryological period of the first eight weeks, or their migration has been terminated at some time during the ascent. Many of these kidneys likewise do not rotate and their pelves remain anterior. Fused kidneys remain arrested either just above the sacral promontory, or in front of the lower lumbar vertebræ. A congenitally pelvic kidney can be differentiated from the acquired one by the length of the ureter and the relation of the vessels. Stephan (5) suggested that the causative factor of ectopic kidney was probably mechanical deviation from the normal development, such as fœtal scoliosis.

THE PELVIS OF THE KIDNEY: ITS FORM AND POSITION

Insufficient rotation or a failure to rotate leaves the renal pelvis in a mesial or anterior position. As a rule, however, the pelvis enters the hilum in the middle third of the kidney or just below it. In the case of a very long kidney the pelvis may run along the entire length of the organ. The pelvis may enter the kidney very near the lower pole. There is usually a single pelvis at the upper end of the urinary tract at the posterior site of the hilum, and it may be intrarenal or

Fig. 13. Double ureter and complete duplication of renal pelvis on right side. Sharp angulation of left ureter and incomplete duplication of renal pelvis. (Case 6).

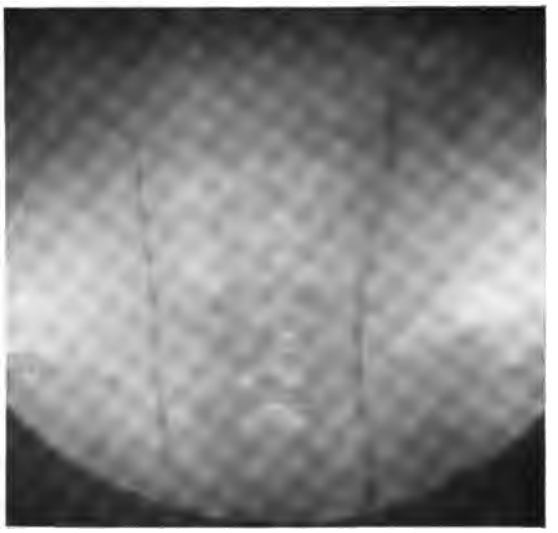

Fig. 14. Incomplete duplication of left renal pelvis (Case 7).

extrarenal. The ureter may divide into two or more branches before entering the hilum. The branching may be due to the same causes as a double ureter, that is, a double evagination of the excretory duct, or a deep ingrowth of one of the several transverse cortical columns during fœtal development, by means of which process the pelvic division becomes dislodged downward and appears at the hilum. This wedge of kidney tissue divides the ureteral branches into two main bundles, and the pelvis into two main branches. If there are two or more of these wedges the ureteral branches may be divided into three or more portions. According to Kelly and Burnam a divided pelvis occurs in about 28 per cent of cases examined.

CHANGE IN THE URETER

Change in the form of the ureter may be coexistent with change in the form of the kidney, or it may be found with normal kidneys. Abnormalities of the ureters are dependent on the renal bud, while anomalies of the kidneys result from abnormal development of the mesochyme. According to Pohlman (63), the abnormalities of the ureters may be divided into two classes: the incomplete double ureter, and the complete double ureter. In the former, the ureter has a common opening in the bladder, and in the latter, each ureter has its own separate opening. Incomplete double ureter may be due to evagination of the excretory duct. If the renal bud divides too early, or if the division extends into the ureter segment, the splitting formed in the ureter itself would remain a permanent one, and any variation might exist from exaggeration of the upper and lower pelvis to an incomplete reduplication. In this type of ureter the pelves are always distinct. The ventral ureter arises from the upper pelvis and there is one orifice normally placed.

If the splitting of the renal bud is so complete that it is affected by the shortening of the segment of the wolffian duct, lying between it and the cloaca, it is possible for each division to acquire a distinct orifice in the duct, resulting in a double ureter. In complete double ureter the ureter from the upper pelvis has the lower orifice in the bladder, lying somewhere between the higher opening of the dorsal ureter and the opening in the genital duct.

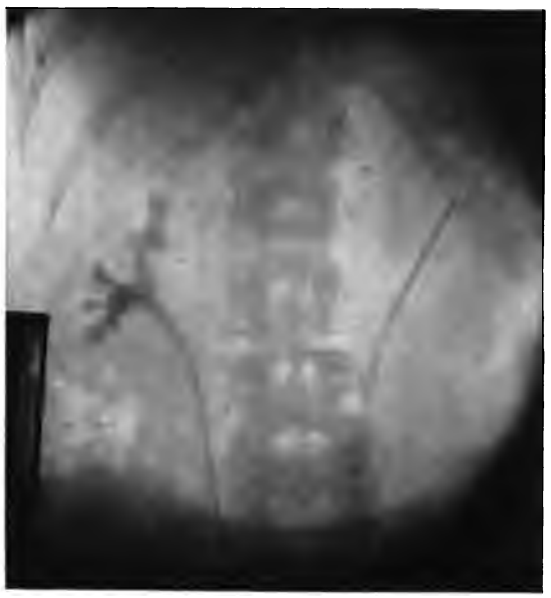

Fig. 15. Incomplete duplication of right renal pelvis (Case 8).

Fig. 16. Incomplete duplication of right renal pelves. (Case 9).

CONGENITAL HYDRONEPHROSIS

When congenital hydronephrosis is bilateral an imperforate urethra is the most common cause. In unilateral hydronephrosis, stricture of the ureter at its juncture with the pelvis is the most common cause. Complete absence of the ureter and valves of the mucous membrane near the pelvis has also been observed in these cases. The high insertion of the ureter into the pelvis of the kidney, or its oblique insertion, have been thought by some to be sufficient reason for obstruction. Anything producing intra-uterine pressure on the ureter or bladder, thus preventing the discharge of urine into the sac of the amnion, may be considered a cause of obstruction. Supernumerary vessels in close relation to the ureter at its origin have been observed in this condition.

From the foregoing it can be seen how easily an arrest in the development of the complicated urinary apparatus may result in anomalies of number, size, form and position of kidneys or ureters, or both. Such a brief review of the embryology, with the exhibition of the specimens taken from the newborn, should lead one continually to bear in mind these possibilities, and to investigate thoroughly all cases showing the slightest variation from the normal.

We are not yet in a position to say how often anomalies are found. The following twenty-three cases from a series of some ten thousand urological examinations made by one of the writers (Bugbee), during the last ten years, probably represent but a small proportion of the anomalies present in this series. An inspection of the bladder will demonstrate only the number of ureteral orifices present, unless one or more be hidden by pathological lesions. Shadow catheters in the ureters may demonstrate anomalies in number and position of the ureters, but a pyelo-ureterogram will be necessary to demonstrate a renal or pelvic anomaly, and often a ureteral anomaly. Such examinations have been a common practice for only a few years.

Just how far we are justified in going in making kidney and ureteral injections has always been a question. Only by making a routine pyelogram on all urological cases could we begin to ascertain the frequency of anomalies of the upper urinary tract. And

Fig. 17. Incomplete duplication of both renal pelvis. (Case 10).

then, again, how often are anomalies present without giving rise to symptoms?

Of practical importance is the fact that such anomalies do exist, and that organs the seat of such anomalies are apparently prone to pathological lesions. In studying lesions of the kidney and ureter, the complete knowledge of the presence and extent of an anomaly is of great importance, not only in outlining and carrying out treatment for its relief, but also as a guide to any surgical interference and operative procedure upon the kidney.

The following rule seems justifiable: If, after a careful cystoscopic examination, ureteral catheterization, study of the separate urines and functional value of each kidney together with a roentgenogram with shadow catheters in position, there exists in the mind of the experienced urologist a question as to the exact lesion present, a pyelogram, single or bilateral, should be made. Many anomalies will never be diagnosed, but when the anomaly is associated with a pathological lesion it will probably be detected.

The following cases are briefly tabulated.

Fig. 18. Incomplete duplication of right renal pelvis. (Case 11).

ANOMALIES OF NUMBER OF KIDNEY

CASE 1. *Single kidney.* A woman, Italian, aged 20, married, was seen in consultation December 15, 1915. The patient complained of pain of a gnawing character, in the right lower quadrant of the abdomen. The pain had begun in September, 1915, and was relieved by a supporting corset. She had been free from pain until December, when it returned, became worse, and was accompanied by chills and fever, diminution of urinary output, and obstinate constipation. A tender mass was palpable in the right upper abdomen. Cystoscopic examination revealed a well-marked cystitis. The right ureteral orifice was slightly dilated, and the area about it was somewhat more congested than the remainder of the bladder wall. A catheter passed 30 centimeters. The flow of urine was rapid, cloudy, contained pus, blood cells, and colon bacilli. The function was but slightly diminished. No left ureteral orifice was found, although the trigone was easily distinguished. The right ureter was completely plugged with a large Garceau catheter, and yet no urine entered the bladder during a period of three quarters of an hour. A pyelogram showed a large right kidney pelvis with dilated calyces. There was no kidney shadow on the left side. The catheter was retained in the right kidney pelvis for three days, with daily lavage. The urine cleared, the kidney decreased in size, and the symptoms disappeared. The cystocsopic examination was twice repeated, and the findings as regards the absence of a left kidney were the same. Indigocarmine was discharged from the right ureteral orifice in normal time, but none was discharged from any other point in the bladder wall. No mass could be palpated in the kidney region on the left side.

CASE 2. *Single kidney; calculus; obstruction of ureter.* A woman, Jewish, aged 33, married, was seen August 22, 1917. She gave the history that one sister, born with one arm, died shortly after

Fig. 19. Both kidneys on the same side. (Case 12).

birth. The patient had passed a calculus eight years and another four years before this examination. Ten days previously she had hæmaturia, which was followed, seven days later, by right renal colic, and for forty-eight hours she had passed no urine. A cystoscopic examination by my associate, F. E. Du Bois, showed no urine in the bladder. A catheter passed 25 centimeters along the right ureter. There was no flow from the catheter. No left ureteral crifice could be found. A roentgenogram with the catheter in the right ureter showed the catheter obstructed at 25 cemtimeters from the bladder. Although there was no shadow in the roentgenogram, a diagnosis was made of calculus obstruction of a single ureter at the ureteropelvic junction. The diagnosis was verified at operation.

At subsequent examinations, with the right ureter completely plugged with a Garceau catheter for three-quarters of an hour, during which time several ounces of urine were collected from the right kidney, no urine entered the bladder.

CASE 3. *Horseshoe kidney; tuberculosis.* The patient, a male. Italian, aged 26, was seen in 1914. He gave the following history: Although he had never been robust, he had suffered from no serious illness until two years previous to this time, when he began to have severe urinary symptoms. Frequent, burning, painful urination, at first intermittent, had been continuous, for the preceding six months, until he was voiding cloudy, bloody urine every half hour day and night. Pain low down in the left lumbar region and to the left of the umbilicus, had developed and he was tender over the left side of the abdomen. No mass was felt. A cystoscopic examination, accomplished with some difficulty owing to the extremely sensitive bladder, revealed a normal right ureteral orifice, a dilated, rigid left orifice, surrounded by an area of œdema, congestion, and ulceration. A catheter passed 28 centimeters on the right side, and with much manipulation, 26 centimeters on the left side. The urine from the right catheter was negative, that from the left was cloudy with blood and pus, contained tubercle bacilli, and showed deficient function. A roentgenogram showed each catheter passing up close to the vertebral column and not over 4 centimeters from the median line of the abdomen at the upper extremities. A diagnosis of tuberculosis of the left kidney was made. At operation through a lumbar incision a mass was found which was supposed to be a left kidney. It was found to be part of a single horseshoe kidney, the left half of which, drained by the left ureter, was tuberculous. This portion of the kidney was removed. The patient left the hospital, but has been lost sight of.

CASE 4. *Fused kidney.* A woman, Italian, aged 26, married, was seen in consultation February 7, 1914. She complained of dragging pain low down on the right side of the abdomen. A mass could be felt lying on the pelvic brim both *per vaginam* and abdominally. Cystoscopic examination showed a normal bladder. The right catheter passed 24 centimeters, the left 26 centimeters. Clear urine was obtained from each. The roentgenogram showed both catheters passing to the right side of the abdomen and arrested above the pelvic brim in the relative position of the palpable mass. At operation a fused kidney was reported, lying above the pelvic brim. This kidney was supplied with two ureters, two sets of vessels, and there was a well-marked groove between the two halves, which were separated, and an attempt was made to replace the left kidney in its relatively normal position.

CASE 5. *Fused kidney.* A woman, aged 32, Italian, married, was seen in consultation in 1913. She had had four children by normal delivery. Her chief complaint was the protrusion of a mass in the vagina for the past two years. She had a bearing-down pain on both sides of the lower abdomen, worse on exertion, and she had chronic constipation. Vaginal examination showed the uterus pushed to the right side of the pelvis by a smooth, elongated, slightly tender mass on the left side. Cystoscopic examination revealed two ureteral orifices, in normal positions. The right catheter passed 24, the left 22 centimeters. Roentgenogram showed that both catheters passed to the left side of the pelvis and were arrested, the right above the left, in the relative position of the pelvic mass. The urine from each catheter was negative. At operation the presence of fused kidney was

reported. This kidney, as in the last case, presented two ureters and two sets of vessels. The kidney was divided and each half placed as high in the abdomen as possible. A subsequent reontgenogram, in 1913, with catheters in position, showed each kidney well above the pelvis on each side, the bladder normal, and urine from each kidney negative.

ANOMALIES OF KIDNEY PELVIS

CASE 6. *Duplication of kidney pelvis (bilateral).* The patient, a man, American, aged 60, was seen February 10, 1916. Following an attack of grippe seven weeks before, he noticed blood in the urine, developed frequency and burning urination, which symptoms persisted. On examination, a large, irregular, tender mass was palpable in the right side of the abdomen. This mass could also be palpated in the lumbar region. Cystoscopic examination revealed a slight congestion of the entire vesical mucous membrane. A catheter entered each of the ureteral orifices, which were in normal position, and passed 25 centimeters on the right side and 28 centimeters on the left side. The urine from each side was hazy with pus and both showed colon bacilli on culture. The function on the right side was two-thirds that of the left. The phthalein output from both kidneys was 51 per cent for two hours. A double pyelo-ureterogram was made, which showed on the right side double ureter above the pelvic brim and a complete duplication of the renal pelvis, each pelvis having three calyces, the lower calyx of the upper kidney joining the upper calyx of the lower kidney. On the left side there was a sharp angulation of a single ureter at the uretreopelvic junction, and an incomplete duplicate of the pelvis of the kidney. This patient was relieved of his acute symptoms under colonic and pelvic lavage.

CASE 7. *Duplication of left renal pelvis.* The patient, a man aged 34, was seen April 20, 1918. One month before he had been seized with severe pain in the left lumbar region, radiating to the groin. This was relieved by passing a long, thin blood clot. Since then hæmaturia had persisted, with moderate vesical irritability. Cystoscopic examination showed a slightly congested trigone—that the blood was coming from the left ureter. Catheterized specimens showed a negative urine on the right side, the left contained much blood, pus cells, and colon bacilli with deficient function. A pyelogram revealed a double kidney pelvis on this side.

CASE 8. *Incomplete duplication of right renal pelvis.* The patient, a woman, aged 46, married, American, was examined by my associate, F. E. Du Bois, on March 7, 1918. Her history was that nine months ago she began to have frequency at night and voided every two hours by day. This condition has persisted. She then voided every two hours night and day, with burning. Both kidneys were palpable, but were not tender. Cystoscopic examination revealed a congestion of the trigone and vesical neck. The ureteral orifices were normal and a catheter passed 34 centimeters on each side. There was a rapid flow of urine from each kidney which, on examination, showed pus cells, colon bacilli, and an equal function. Roentgenograms with X-ray catheters in position showed a prolapse of the right kidney, with the patient in the erect posture, and a pyelogram revealed duplication of the renal pelvis.

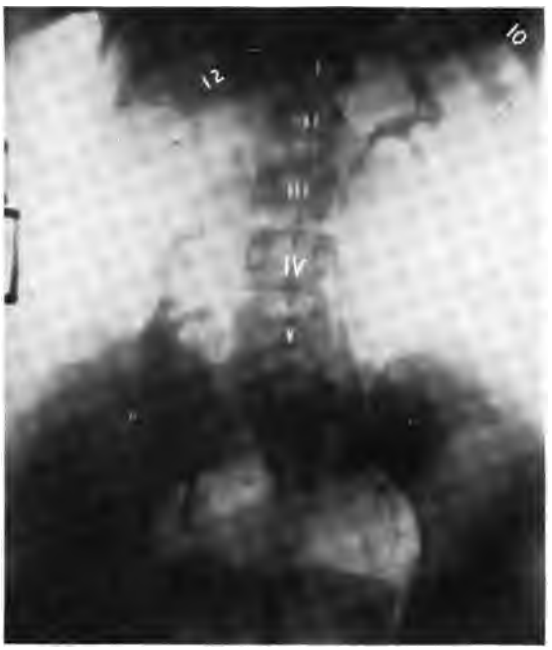

Fig. 20. Right kidney low and not rotated. (Case 13).

CASE 9. *Incomplete duplication of right renal pelvis.* A woman, aged 52, American, widowed, was seen in consultation, June 7, 1917. She complained of pain in the right upper quadrant, and frequent burning urination of six months' duration. Gastric distress, constipation, and jaundice had been noted for the previous three weeks. There was tenderness and rigidity of the right rectus. The urine was highly colored. The bladder showed hyperæmia of the trigone; the ureteral orifices were normal; catheters passed 30 centimeters on each side. The urine from the right kidney was cloudy, contained blood cells, pus and colon bacilli, while the left kidney excretion was negative. The function of the right kidney was diminished one-third. A pyelogram revealed an incomplete duplication of the right kidney pelvis. An exploration of the right upper quadrant of the abdomen was made. The report gave acute cholecystitis with obstruction of the cystic duct as the primary lesion giving rise to the abdominal symptoms.

CASE 10. *Incomplete duplication of both kidney pelves.* The patient, a woman, aged 24, American, married, was first observed in 1916. She complained of pain in the left side of the abdomen and back

Fig. 21. Obstruction of left ureter. (Case 15).

Fig. 22. Ureteral bougie passed through obstruction in contact with calculus in pelvis of pelvic kidney. (Case 15).

She had had nine attacks, each coming on with severe pain in the lumbar region, nausea, vomiting, chills, and fever, accompanied by frequency, urgency, and hæmaturia, and followed by soreness in the flank. The last attack was five weeks before coming under observation. A large tender mass could be felt in the left kidney region and a small, smooth, non-tender mass in the right side of the abdomen, low down. The latter mass was not movable. Cystoscopic examination showed slight congestion of the vesical mucosa, more apparent about the left ureteral orifice. A catheter passed 26 centimeters along the right ureter. There was no obstruction of the ureter, and there was a normal flow of amber-clear urine from this side. The catheter on the left side passed 32 centimeters. The flow was rapid and the urine colorless and cloudy with pus. Analysis showed a colon bacillus infection on the left side, with diminution of function, a normal kidney output on the right side. A double pyelogram showed a moderately low-placed kidney on the right side, with no ptosis or ureteral kink, a high-placed kidney on the left side. Both kidney pelves showed an incomplete duplication. This patient was relieved by pelvic lavage.

CASE 11. The patient, a woman, aged 46, complained of pain in the right upper quadrant. The pain was dull in character had persisted for seven weeks and was accompanied by frequent burning urination. The right kidney could be palpated, was slightly enlarged and tender. Cystoscopic examination revealed a moderate congestion of the urethra and trigone. Catheters passed to either kidney 31 centimeters. The left urine was negative. The right showed pus and colon bacilli. A pyelogram revealed an incomplete duplication of the right renal pelvis.

ANOMALY OF POSITION OF KIDNEY

CASE 12. *Both kidneys on same side.* The patient, a woman, Italian, aged 16, single, had an appendectomy four months before coming under observation, June 26, 1910, for pain in the right lower quadrant. This pain was not relieved by the operation, and was aggravated when the patient was on her feet. A small, regular mass could be palpated in the right lower quadrant, and the lower pole of the right kidney could be palpated above it. Cystoscopic examination revealed a normal bladder and normal ureteral orifices. The catheter in the right ureter passed 30 centimeters, that in the left, 26 centimeters. The flow from the right catheter was twice the amount of that from the left, and the functional capacity was in the same porportion. Culture showed staphylococcus aureus from the left side, negative culture from the right. A double pyelogram showed both kidneys placed on the right side of the abdomen, the right above the left, the latter being an organ of infantile type. This patient was greatly relieved by pelvic lavage.

CASE 13. *Right kidney low and not rotated.* The patient, a woman, American, aged 19, married, came under observation in January, 1914, complain-

Fig. 23. Tuberculosis of single functionating kidney. (Case 18).

ing of epigastric pain, nausea, vomiting, frequent burning urination, extending over a period of three months. A globular mass which was of the size and shape of a kidney, could be felt on the right side of the abdomen at the level of the umbilicus. Cystoscopic examination revealed a congested bladder, normal ureteral orifices. A catheter passed 25 centimeters along the right ureter, 31 centimeters on the left side. The urine from each side contained pus cells and colon bacilli on culture. The renal function was normal. A double pyelogram showed that the right kidney had not rotated, the renal calyces pointing toward the vertebral column, nor had it ascended to its normal position in the lumbar region. There was no kinking of the ureter, and the left ureter and kidney were in normal position. A laparotomy revealed an undescended cæcum and a diseased appendix. The appendix was removed.

CASE 14. *Migration of kidneys to opposite sides in their ascent; crossed ureters.* This patient, a woman, aged 33, married, came under observation October 13, 1914. She complained of frequent, painful urination, which had persisted and become progressively worse over a period of ten years. This was accompanied by loss of flesh and strength. Physical examination was negative. Cystoscopic examination was exceedingly painful, owing to a contracted and highly sensitive bladder, which retained but two ounces of fluid. The examination revealed well-marked œdema, congestion, and ulceration of the right side of the trigone and bladder wall, particularly in the immediate neighborhood of the dilated, rigid right ureteral orifice. The left ureteral orifice appeared normal and there was but

Fig. 24. Bilateral duplication of ureters. (Case 19).

slight congestion immediately about it. A catheter entered either orifice, but was obstructed 1.5 centimeters from the bladder on the right side, and at 2 centimeters from the bladder on the left side. No specimen could be obtained. Indigocarmine returned in good amount from the left ureteral orifice in five minutes. None was emitted from the right ureteral orifice in 25 minutes. The bladder urine showed large quantities of pus and numerous tubercle bacilli. A diagnosis of tuberculosis of the right kidney was made, and as at subsequent cystoscopic examinations it was found impossible to pass the ureteral catheter beyond the points above noted, the right kidney was removed without splitting it. This kidney, after removal, showed a pyelonephritis only, but no tuberculous lesions. The patient died of uræmia seven days after operation, and at autopsy it was found that the ureter leaving the left lateral angle of the trigone passed back of the bladder, crossed the right ureter, and ascended in the right side of the abdomen to the right kidney, while the ureter from the right side of the bladder passed in a like manner to the left kidney. Thus the urine from the right kidney was emitted from the left ureteral orifice in the bladder, and that from the left kidney from the right ureteral orifice. The left kidney was almost entirely destroyed with tuberculosis, the ureter the seat of strictures, the lowest being one-half centimeter from its point of entering the bladder wall. The right kidney, which had been removed, was com-

parativley normal, and the ureter was normal with the exception of a complete torsion, just before entering the left side of the bladder wall.

CASE 15. *Pelvic kidney with calculus.* The patient, a male, aged 27, Jewish, single, was first seen October 10, 1917. He complained of pain in the left lower abdomen, hæmaturia, and frequency of urination. Seven years before he had noticed that his urine was dark, but that it cleared after a few days' rest in bed. One year before coming under observation he had a sharp attack of pain in the left lower abdomen, accompanied by nausea and followed by hæmaturia. During the year he had many such attacks. His physical examination revealed a bad condition of the teeth and a tender mass slightly to the left of the abdomen and below the umbilicus, extending down into the pelvis. Cystoscopic examination showed a bladder mucosa somewhat congested but otherwise normal. A catheter passed 30 centimeters to the right kidney, and there was a normal flow of hazy urine which contained pus cells and colon bacilli. The catheter on the left side passed 17 centimeters and was obstructed, although a specimen of urine was collected which showed a sediment of pus, many colon bacilli, and a markedly deficient renal function. An injection was made through the catheter and a roentgenogram taken showed the solution had not passed the point of obstruction. The catheter was removed and a soft ureteral bougie inserted. This passed the obstruction after some manipulation, and the roentgenogram showed it to have entered the pelvis of a pelvic kidney and to be in contact with a calculus lying in the pelvis of this kidney. The kidney rested on the promontory of the sacrum.

CASE 16. *Pelvic kidney; pregnancy.* A woman, Russian, aged 24, was seen in consultation in 1916. The patient was pregnant for the first time, then in her sixth month. She had complained of pain in the lower back and pelvic region since the third month of pregnancy. This pain had become progressively worse. For four days she had suffered from frequent, painful urination, from vomiting and steady bearing down pain in the pelvic region.

On vaginal examination a smooth, slightly tender mass could be palpated posterior to the uterus, in the median line, resting on the promontory of the sacrum. The mass had the general contour of a kidney. Cystoscopic examination showed marked pressure in the bladder from the enlarged uterus, and an acute cystitis. The mucous membrane about the left ureteral orifice was slightly œdematous. A catheter passed to the right kidney 30 centimeters with little difficulty. On the left side the catheter passed 21 centimeters. The urine from the right kidney was negative; that from the left side was cloudy from pus, contained colon bacilli, and showed deficient kidney function. A roentgenogram showed left catheter passing slightly upward from the bladder, then directly backward, and coiled up in the pelvis of a pelvic kidney, which was the mass palpated through the vaginal vault.

CASE 17. *Pelvic kidney.* A woman, aged 22 was seen three weeks after her first confinement. The labor had been a prolonged and difficult one, requiring forceps. During the latter months of pregnancy the patient had complained of frequent, painful urination and severe pelvic pain. The pain was relieved somewhat following the delivery, but the urinary symptoms persisted. The general physical examination was negative other than the presence of a mass easily palpated in the left side of the pelvis, *per vaginam.* A cystoscopic examinnation revealed a well-marked cystitis, with somewhat more congestion about the left than the right ureteral orifice. A catheter passed to the right kidney 31 centimeters and a normal flow of clear, negative urine was obtained. A catheter passed 23 centimeters on the left side. The urine obtained contained pus, blood cells, and colon bacilli. The function of this kidney was deficient, being one-half that of the other side. A roentgenogram with catheters in position showed a right kidney in normal position, the left situated in the pelvis.

ANOMALIES OF URETERS

CASE 18. *Obliteration of lower ureter; infantile kidney.* A woman, aged 34, American, single, was first seen November 1, 1915, complaining of frequent, painful urination of six months' standing. She voided every three hours by day and twice at night. There was a urethral stricture at the internal meatus which was dilated and five ounces of residual urine found in the bladder. Cystoscopic examination revealed a very much congested bladder mucosa with a dilated, rigid left ureteral orifice surrounded by an area of œdema, and posterior to the trigone on this side was a small ulcerated area which bled easily. No right ureteral orifice could be seen, although the trigone was well outlined. The urine from the left kidney contained pus and tubercle bacilli. Repeated examinations over a period of two years always revealed the same bladder picture. The left ureter was plugged with a Garceau catheter and four ounces of urine collected from the left kidney, while no urine entered the bladder. A pyelogram showed a tuberculous lesion in the left kidney. Exploratory laparotomy in 1917 revealed a small right kidney, with a smooth surface and no visible lesions. The pelvis and ureter were slightly dilated, the ureter was dilated, but not thickened, and ended below the pelvic brim in a fibrous cord.

CASE 19. *Bilateral duplication of ureters.* The patient, a woman, aged 32, Irish, married, was seen December 1, 1916. She complained of backache, headache, pain in the lower abdomen and pelvis, and frequent burning urination. She had had three children and had received extensive perineal lacerations. The backache had been severe for four years. For six weeks she had had pain in the right lower quadrant. The uterus was retroverted and prolapsed. Cystoscopic examination showed slight congestion of the vesical trigone and two

normal ureteral orifices in each lateral angle of the trigone. Catheters entered each orifice and passed 31 centimeters. The urine from each was negative other than the presence of a few pus cells and colon bacilli. A roentgenogram taken with catheters in each ureter revealed four ureters distinct thoroughout, the anterior ureter having the higher insertion into each renal pelvis. No pyelogram was made, so we were unable to ascertain whether there was a duplication of the pelves.

CASE 20. *Duplication of ureter, one side.* A woman, aged 29, was sent for treatment in 1909. She complained of chronic constipation, frequent, painful urniation, and discomfort in the right lumbar region. The right kidney could be palpated, was slightly enlarged and tender.

A cystoscopic examination revealed a congestion of the entire bladder mucous membrane, mote marked on the right side in the region of the lateral angle of the trigone. On this side there were two ureteral orifices. A catheter entered each and passed 30 centimeters. Cloudy urine, containing pus, blood, and colon bacilli, was discharged through each catheter. There was a single ureteral orifice on the left side. A catheter passed 31 centimeters to this kidney with ease, and the urine obtained was normal.

The right kidney was exposed through a lumbar incision, and proved to be slightly enlarged, prolapsed, and very much congested, but otherwise normal. There were two ureters leading from a single pelvis. The ureters were slightly dilated but not thickened.

The kidney was denuded of its capsule and sutured as high up as possible.

CASE 21. *Bilateral duplication of ureter.* A woman, single, aged 36, was seen in 1910. The chief complaint was frequent painful urination over a period of fifteen years. Physical examination was negative. Cystoscopic examination showed a urethral stricture of small calibre. This was dilated and a cystoscope introduced. The area of the trigone showed hyperæmia and in each lateral angle were two apparently normal ureteral orifices. They were about 1 centimeter apart. A catheter entered each and passed 30 centimeters. Urine from each kidney was normal. No roentgenogram was made.

CASE 22. *Bilateral duplication of ureters.* A male, aged 24, came in 1912, for an operation for hypospadias, the floor of the terminal 3½ centimeters of the penile urethra being absent. There was no venereal history, and the physical examination was negative. A cystoscopic examination revealed, in an otherwise normal bladder, two ureteral orifices on each side in relatively the same position. i. e., in the lateral angle of the trigone, about 1 centimeter apart, the second being posterior to and to the outer side of the first. The appearance of each opening was normal. The catheter was passed into each orifice and advanced 31 centimeters. The urine from each side was normal. A roentgenogram with shadow catheters in position, on one side verified the diagnosis.

CASE 23. *Bifurcation of lower ureter.* The patient, a woman, aged 36, American, single, came for observation April 2, 1918, complaining of frequent, painful urination over a period of six months, becoming more severe until she then voided every half hour day and night. She had lost weight and strength. There was slight tenderness in the left lumbar region. Cystoscopic examination revealed a contracted, inflammed bladder, the mucosa being congested throughout, more pronounced about the left side of the trigone. A ureteral orifice was observed on this side, dilated, rigid, and overhung with an area of granulations. A catheter entered the orifice, passed 2½ centimeters, when it was seen to emerge from another orifice 1½ centimeters above and to the outer side of the first orifice. There was a single normal ureteral orifice on the right side of the trigone. A catheter passed 30 centimeters to the right kidney, and normal urine was obtained. The bladder urine contained pus and tubercle bacilli. A roentgenogram showed that there was a bifurcation of the left ureter 1½ centimeters from the vesical opening.

These 23 clinical cases represent 2 single kidneys, both the seat of infection, one presenting a calculus obstruction of the single ureter; three fused kidneys; one horseshoe kidney, the seat of tuberculosis, and two fused kidneys apparently free from infection but causing pressure in their anomalous position. All six cases showing duplication of the renal pelvis had a pyelonephritis. The six cases presenting one or both kidneys in an anomalous position showed renal infection, one being tuberculous, and another having a renal calculus. The six cases showing anomalies of one or both ureters all were the seat of renal infection.

From the above it will be seen that all but two of the cases presented renal infection which indicates that a single kidney called upon to do double work, a malformed or malplaced kidney having poor drainage, poor blood supply and subject to pressure is particularly prone to infection. Anomalies of the ureter also interfere with kidney drainage, thus predisposing to infection.

The necessity for assisting such kidneys to perform their function is apparent. The indications are to throw less work upon the kidneys. With four exceptions the infections were all of the colon type. The necessity of attention to the intestinal tract is apparent. Lavage of the kidney pelvis has been bene-

ficial, and permanent drainage often for several days with the ureteral catheter has proved efficacious. The surgical indications are to improve drainage and relieve pressure, if necessary, by placing the kidneys in more nearly their normal position; to remove any obstruction to renal drainage (as a calculus) to remove a diseased kidney when destroyed beyond repair, if the opposite kidney is able to carry on the necessary function, or in rare cases to remove the kidney which cannot be replaced and is causing pressure symptoms due to its malposition. Whenever an abdominal mass is found, a renal anomaly must be excluded. If it is not possible to make a positive diagnosis of the extent of the lesion before operation, the operation should include an exploration of both kidneys.

BIBLIOGRAPHY

The following is a fairly complete bibliography for the years from 1912 to 1917, inclusive. The references are arranged in sequence according to years.

ANOMALIES OF KIDNEY OR OF KIDNEY AND URETER

1. GOULD and PYLE. Anomalies and Curiosities of Medicine. Philadelphia: 1897. (Under anomalies of the genito-urinary tract the authors record the following figures, complied from the literature: Absence of one kidney, 292 cases; other anomalies, 293 cases; anomalies of ureter, 294 cases).
2. WITKOWSKI, ABRAHAM. Operationen an Hufeisennieren. Berlin: 1912.
3. CARLIER, V. and GÉRARD, M. Anatomie et chirurgie du rein en fer à cheval. Echo méd. de nord, Lille, 1912, xvi, 429; 442; also: Rev. de chir., Par,. 1912, xlvi, 9; 197.
4. ROSKA, J. Horseshoe kidney and its surgical treatment. Orvasi hetil., Budapest, 1912, lvi, 1007.
5. STEPHAN, SIEGFRIED. Die kongenitale Nierendystopie beim Weibe in klinischer und embyryologischer Beziehung. Greifswald: 1912.
6. ROLLETSON, J. D. Congenital renal and ureteral anomaly. Proc. Roy. Soc. Med., Lond., 1912-13, vi, Sect. Stud. Dis. Child., 114.

The author cites the case of a boy, 12 years of age, whose death was due to other causes. The following conditions were found to exist: (1) single or asymmetrical left kidney, (2) duplication of ureter, (3) union of the two branches of the left ureter 3 inches from bladder, (4) right and left ureteral orifices in bladder, (5) right ureter, patent from from bladder to its blind upper extremity; right kidney, renal artery and vein, and right suprarenal were absent.

"As far as I have been able to ascertain from a study of the literature, no other cases have been recorded of asymmetrical kidney, with partial duplication of its ureter co-existing with a patent ureter on the side on which the kidney is absent.

"The condition of single or asymmetrical kidney is by no means common, being found, according to Morris (Morris, H. Surgical Diseases of Kidney and Ureter, 1901), in only one out of 2,400 autopsies; 213 were collected from literature by Ballowitz (Virchow's Arch. of path. Anat., Berl., cxli, 390) in 1895, 286 by Anders (Anders, J. M. J. M. Sc., 1910, cxci, 313) in 1910, and 300 by Dorland (Dorland, W. A. N. Surg., Gynec. & Obst., 1911, xiii, 303) in 1911. Probably these figures are too large, some of the cases, especially those recorded by the earlier writers, being examples of fused and not of single kidney. The congenital absence of the kidney is due to failure of the wolffian duct to throw off the corresponding renal bud after the duct has reached the cloaca.

"Duplication of the ureter, which is usually incomplete, as in my case, is not so very uncommon, being found in 1 to 2 per cent of all corpses (Lessing. Charité Ann., Berl., 1906, xxx, 452). The association of solitary kidney with complete or partial duplication of the ureter, though uncommon, is not unique.

"The presence of a ureter on the side on which the kidney is absent is very exceptional. Out of 286 cases of single kidney collected by Anders (loc. cit.) there were only twenty-four in which a more or less rudimentary ureter was present on the side on which the kidney was absent. In the majority of these cases the ureter was impervious, and I have been able to find only seven cases in which, as in my own case, the ureter was patent throughout its entire length."

7. STEIN, A. Unilateral fused kidney. Am. J. Obst., N. Y., 1913, lxviii, 48.
8. VAN BISSELICK, J. W. Two congenital abnormalities of the kidneys. Nederl. Tijdschr. v. Geneesk., Amst., 1913, i, 474.
9. PERRUCHOT and COURBIN. Rein unique en fer à cheval avec deux hilus. J. de méd. de Bordeaux 1913, xliii, 420.
10. BUDDE, W. Ein sehr fruh es Stadium von Hufeisenniere. Anat. Hefte, Wiesbaden, 1913, xlviii, 297.
11. DUTOIT, A. Chirurgie der Hufeisenniere nebst anatomischen Bemerkungen. Aerztl. Rundschau, Muenchen., 1913, xxiii, 410.
12. YEFRENIOFF, P. D. Origin, formation and clinical significance of a horseshoe kidney. Kharkov. M. J., 1913, xvi, 335.
13. BEYER, C. Le rein en fer a cheval; étude anatomique, clinique et chirurgicale. Arch. internat. de chir., 1912-13, vi, 1.
14. LEEDHAM-GREEN, C. A. Horseshoe kidney. Brit. M. J., 1913, ii, 1583.
15. HERMAN, J. L., and FETTEROLF, G. Dumb-bell kidney. Tr. Phil. Academy, Surg., 1914, xvi, 38: also Ann. Surg., Phila., 1913, lvii, 868. (Illustrated).

"An unusual difficulty which might be met in renal surgery on the living patient is illustrated by a recent experience in attempting nephrectomy on a cadaver in the Laboratory of Anatomy of the University of Pennsylvania." The body was that of a male, 71 years.

"Explanation. The primitive kidney is a pelvic organ derived from a portion of the paravertebral mesoblastic tissue of the pelvic wall, the renal blastema and from the branching subdivisions of the expanded ends of the primitive ureter, which contribute that portion of the uriniferous tubular

system represented by the straight collecting tubules. Each organ is formed independently, and possibly as a result of changes in the line of curvature of the caudal extremity of the spinal column, ascends until by the end of the third month of fœtal life has reached its adult position. Fusion of the renal masses, as in this case, would cause retardation in the ascent, probably as a result of the development of the sacral promontory, which would offer obstruction to the isthmus in the midline and prevent the normal passage upward of the lateral masses along the iliolumbar grooves. Nature vascularizes the renal tissue from adjacent vessels and this would contribute to the difficulty of ascent, as illustrated by the markedly angular course of those renal arteries in our specimen which are derived from the anterior surface of the aorta near its bifurcation. It is our conception that the dum-bell type illustrates fusion of the lower poles of the primitive kidneys which in ascending were rotated as it were on their backs and transversely, as a direct result of retardation in ascent of the midportion or isthmus."

"Congenital fusion of the kidneys finds its most frequent expression in the horseshoe kidney. There are various intermediate forms of fusion between this, which Rokitansky calls the lowest degree of fusion, and the highest degree of fusion, namely when the kidney is fused into a discoidal mass lying usually in the median line, misplaced downward, and often provided with a double pelvis and two ureters.

"Clinical importance. The malformed kidney as a rule gives rise to no clinical symptoms unless complicated or through pressure as the result of misplacement. Any disease to which the normal kidney is subject may affect the malformed organ, but hydronephrosis and its frequent sequel, pyonephrosis, are the most frequent complications." Pressure of the anomalous vessels on the ureter is the cause in the majority of cases, as shown by William J. Mayo (Proc. Surg. Ass., 1911).

"Important steps in the recent progress of the surgery of the horseshoe kidney are the division of anomalous blood-vessels causing ureteric obstruction, division of the isthmus to relieve pressure symptoms, ureteropelvic anastomosis, plastic operations on the renal pelvis for hydronephrosis and heminephrectomy by the transperitoneal route."

15a. BRAASCH, W. F. The clinical diagnosis of congenital anomaly in the kidney and ureter. Tr. Am. Ass. Genito-Urin. Surg., 1913, viii, 281.

"A review of the records of abdominal operations at St. Mary's Hospital (Mayo Clinic) for the past five years shows that gross renal and ureteral anomalies were found in thirty-six patients. Of this number eighteen were operated on for various pathologic conditions complicating the anomaly, and seven were operated on for abdominal conditions other than those of the kidney, the discovery of which was largely incidental to the general abdominal exploration. In the last three years the records of those cases in St. Mary's Hospital showed that congenital anomaly was diagnosed clinically in fourteen patients; of this number, four were not operated upon for various reasons. Postmortem records of the last one hundred and seventy-one autopsies made at the clinic showed that congenital anomaly of the kidney and ureter was noted in seven cases, or over 4 per cent of the total. This number includes only those gross anomalies occurring in the adult that might be regarded of surgical importance and does not include minor anomalies so frequently found in the urinary tract such as supernumerary and aberrant renal blood vessels, fœtal lobulation, moderate degree of malposition, nor those rather frequent instances of partially deformed atrophic kidneys which may be due either to congential or acquired etiologic factors.

"The pathologic condition existing in the anomalous kidney or ureter usually calls our attention, clinically, to its existence, That such kidneys are peculiarly liable to disease has been noted by various observers. The frequency with which such anomalies are found in a surgical clinic as compared with postmortem records of a general hospital would, therefore, be at least partially explained by the fact that the complicating conditions usually require surgical treatment."

16. BUDDE, WERNER. Zur Genese der hufeisenniere und verwandter Nierenmissbildungen. Wiesbaden: 1913.
17. ADRIAN, C. Die praktische Bedeutung der Missbildungen der Niere, des Nierenbeckens und des Harnleiters. Samml. zwangl. Abhandl. a. d. Geb. d. Dermat. etc., Halle a S., 1913-14, iii, 1.
18. BROUSSE. Rein en fer à cheval. Bull. et mém. Soc. anat. de Par., 1914, lxxxix, 59.
19. MEYER, A W. A transition form between a horseshoe and "Kuchenniere." J. Anat. & Physiol., Lond., 1913-14, xlviii, 143.
20. THEVENOT. Un cas de rein en fer à cheval tuberculeux. Lyon chir., 1914, xi, 287.
21. APERT and MICHEL. Rein en fer à cheval. Bull. et mém. Soc. anat, de Par., 1914, lxxix, 122.
22. CHEVELLE, A. Reins dédoublés bilatéraux, hémipyonéphrose droite, · néphrectomie droite. Rev. méd. de l'est, Nancy, 1914. xlvi, 179.
23. BORSZEKY, K. Subdermale Ruptur einer Hufeisenniere. Pest. med. chir. Presse, Budapest, 1914, i, 128.
24. BRONGERSMA, H. Ein Fall von Trenung einer Hufeisenniere. Ztschr. f. Urol., Berl. u. Leipz., 1914, viii, 470.
25. RUMPEL, O. Ueber Nierennesektionen bei Versehmelzung und Verdoppelung der Nieren. Ztschr. f. urol. Chir., Berl., 1914, iii, 33.
26. OEHLECKER, F. Eine angeborene Anomalie der Niere und des Ureters unter dem klinischen Bilde eines perityphlitischen Abscesses. Ztschr. f. urol. Chir., Berl., 1914, iii, 147.
27. CARRARO, N. Sinfisi renale unilaterale. Morgagni, Milano, 1914, lvi, pt. 1, 300.
28. FORTUNATOVA, T. A. Horseshoe kidney in a woman. Vrach. Gaz., St. Petersb., 1914., xxi, 768.
29. NECKARSUHMER, K. Ueber Beineiren. Berl. klin. Wchnschr., 1914, li, 1641.
30. GINZBERG, M. M. Division of a horseshoe shaped kidney. Syezd. Rossiysk. Khirug., Mosk., 1914, xiii, 226.
31. STINCER, R. Sinfisis renal-unilateral. Arch. de la Soc. estud. clin. de la Habana, 1914, xxi, 56.
32. BASSINI, E. Sopra l'assenza congenita dei reni., Ginecologia, Firenze, 1914, xi, 261.
33. ZONDEK, M. Zur Diagnose der Hufeisenniere. Verhandl. f. Chir., Berl., 1914, xliii, No. 2, 409. Discussion, No. 1, 156, also: Arch. f. klin. Chir., 1914, cv, 676.
34. FRANKEL, A. Roentgenuntersuchung bei Hufeisenniere. Ibid No. 1, 157.

35. KEY, E. Ueber Nierenmissbildungen von chirurgishcen Gesichtspunkt aus. Nord. med. Ark., Stockholm, 1914, xiv., No. 7, 1.
36. OEHLER, F. Ein Beitrag zur Kasuistik des kongenitalen Nierendifekts und der kongenitalen Nierendystopie. Festchr. H. Bricher, Tuebingen: 1914, 376. also: Beitr. z. klin. Chir., Tuebingen, 1914, lxxxix, 223.
37. LOSEE, J. R. Horseshoe kidney, with anomaly of ureter. Med. Rec., 1915, lxxxvii, 165; also: Am. J. Obst., N. Y., 1915, lxxi, 672.
38. CECIL, A. B. A case of complete duplication of the renal pelvis. Calif. St. J. M., 1915, xiii, 34.
Demonstrated by the injection of colloidal silver and the functional value of the right kidney and the two portions of the left by phenolsulphonephthalein.
32. MOLL, J. M. A case of horseshoe kidney, with divided pyelum. M. J. S. Africa, Johannesb., 1915, xi, 10; also; Nederl. Tijsdchr. v. Geneesk., Amst., 1916, i, 158.
40. KRETSCHMER, H. L. Supernumerary kidney. J. Am. M. Ass., 1915, lxiv, 1447.
41. BRENIZER, A. G. Congenital ectopic kidney and hydronephrosis on the left side, with a normal kidney on the right. Surg., Gynec. & Obst., 1915, xxi, 237.
42. LEWIS, F. T., and PAPEZ, J. W. Variations in the early development of the kidneys in pig embryos. Anat. Rec., Phil., 1915, ix, 105.
43. MARYSUKI, G. Zur Diagnostik der Hufeisenniere. Deutsche Ztschr. f. Chir., Leipz., 1915, cxxxiii, 281.
44. SCHOENFELD and FRIEDL. Zur Pyelographie der kompletten Doppleniere, in einem Falle mit Hydronephrose kombiniert. Fortschr. a .d. Geb. d. Roentgenstrahlen. Hamb., 1915, xxiii, 168.
45. STEIN, A. The clinical importance of unilateral fused kidney. (Including the dystopic kidney of one side). Am. J. Obst., N. Y., 1916, lxxiii, 449.
46. ROLLETSON, J. D. Single pelvic kidney. Proc. Roy. Soc. Med., Lond., Child. Sect., 1915-16, ix, 19.
47. GIBBON, J. W., Anomalies of the kidney and ureter and their embryological significance. Jeffersonian, Phil., 1916, xvii, i.
48. VOORHOEVE, N. Radiograph of horseshoe kidney. Nederl. Tijdschr. v. Geneesk., Amst., 1916, ii, 171.
49. LYON, M. W. Two cases of congenital absence of one kidney. J. Am. M. Ass., 1916, lxvii, 1524.
50. KROTOSZYNER, MARTIN. Observations on anomalies of the urinary tract. Ann. Surg., Phila., 1917, lxv, 560.
51. PILCHER, L. S. Kidney with double pelvis and double ureter; nephrolithiasis; pyonephrosis; nephrectomy. Ann. Surg., Phila., 1917, lxv, 534.
52. LYON, N. W. Hereditary case of congenital absence of one kidney. Anat. Rec., Phil., 1917, xiii, 303.
53. EISENDRATH, D. N. Two cases illustrating the clinical importance of anomalies of the kidney. Surg. Clin., Chicago, 1917, i, 1053.
54. DELUCA, F. A. Malformations of the kidneys. Semana med., Buenos Aires, 1917, xxiv, 637.

ANOMALIES OF THE URETER

55. PAWLOFF, A. Ueber akzessorische Harnleiter. Deutsche Ztschr. f. Chir., Leipz., 1912-13, cxx, 425.
56. KALUSHKIN, N. M. Supernumerary ureter in a woman; certain peculiarities of its clinical course, diagnosis and treatment in the given case. Russk. Vrach., St. Petersb., 1912, xi, 1471.
57. HARTMANN, J. P. Ueber die extravesikale Ausmuendung der Harnleiter bei Frauen. Ztschr. f. gynaek. Urol., Leipz., 1913, iv. 69.
58. UTEAU, R., and SAINT-MARTIN, E. Sur un cas d'anomalie de situation des orifices urétéraux. Toulouse méd., 1913, 2 s., xv, 155.
59. HARTMANN, J. Zur Kasuistik und operativen Behandlung ueberzaehliger aberranter Ureteren. Ztschr. f. Urol., 1913, vii, 429.
60. PIERI, G. Malformazioni congenite dell' uretere (uretere sdoppiato con sbocco vaginale). Rev. ospedal., Roma, 1913, iii, 493.
61. DUHOT and CORDIER. Un cas de duplicité de l'uretère. Écho méd. du nord, Lille, 1914, xviii, 4.
62. WAKELEY, C. P. G. A case of duplication of the ureters. J. Anat. & Physiol., Lond., 1914-15, xlix. 148.
63. POHLMAN, A. C. Abnormalities in the form of the kidney and ureter dependent on the development of the renal bud. Johns Hopkins Hosp. Bull., 1914, xvi, 167.
64. BRAASCH, W. F. Cystoscopy and urethroscopy for general practitioners, (Lewis and Marks), 1915, chapter v, Uretero pyelography, p. 86.
65. LOCKYEAR, C. Double ureter simulating a parovarian cyst in the right broad ligament. J. Obst. & Gynæc. Brit. Emp., 1914, xxvi, 220; also Proc. Roy. Soc. Med., Lond., 1914-15, viii, Obst. and Gynæc. Sect., 47.
66. WORRALL, R. Case of bilateral duplication of ureters complicating operation for cancer of cervix uteri; one on each side severed and successfully implanted into the bladder. J. Obst. & Gnyæc., Brit. Emp., Lond., 1914, xxvi, 169.
67. FROMME. Ueberzaehliger Ureter. Ztschr. f. Geburtsh. u. Gynaek., 1914, lxxv, 758.
68. STAMMLET, A. Zur Kenntnis der aberrierenden, ueberzaehligen Ureter. Ztschr. f. urol. Chir., Berl., 1914, ii, 241.
69. OTTOW, B. Zur Embryologie der Ureterenverdoppelung und die Bedeutung der letzeren die Pathologie der Niere. Ztschr. f. gynaek. Urol., 1914, v, 5.
70. WORRALL, R. Bilateral duplication of ureters: implantation of the ureter into the bladder. M. J. Australia, Sydney, 1914, i, 7.
71. FURNISS, H. Report of several cases of ureteral anomalies. Am. J. Obst., N. Y., 1915, lxxi, 669
72. BECCHERLE, G. Su di un caso di duplicita incompleta dell' uretere. Policlin. Roma, 1915, xxii, sez. chir., 168.
73. REID, D. G. Bilateral duplication of the ureter. J. Anat., Lond., 1916-17, li, 30.
74. SIMON, A. R., and MERTZ, H. O. The supernumerary ureter, report of case of complete unilateral duplication. J. Am. M. Ass., 1916. lxvi, 1686.
75. PEACOCK, A. H. Multiple ureters with hydronephrosis. J. Am. M. Ass., 1916, lxvi, 1088.
76. EISENDRATH, D. N. Congenital strictures and spiral twists of the ureters. Ann. Surg., Phila., 1917. lxv, 552.

TUBAL AND OVARIAN HÆMORRHAGE

Its Etiological Relation to Pelvic Hæmatocele and Extra-Uterine Pregnancy[1]

By J. WESLEY BOVÉE, M.D., F.A.C.S., Washington

IN considering ovarian and tubal hæmorrhages, I am excluding those forms arising from tubal pregnancy and from overwhelming trauma or hæmophilia. Many case reports were of virgins and one in a women past the menopause.

FREQUENCY

Without careful study of ovarian and non-pregnant tubal hæmorrhage, one might think its occurrence was so rare as to be a novel or grotesque condition. But careful analysis of abdominal surgical work, including microscopical study will demonstrate that it is not a rare condition. As an instance, I may here recite briefly the history of a patient seen one night last month with Dr. A. L. Stavely.

A spinster of 32 years usually tardy in menstruation, that habitually lasted seven days, and had ceased menstruation the day before, fell in the street at midday from sudden and severe pain in the hypogastrium while on a shopping trip. She was removed to the office of an osteopathist who had been treating her for constipation and vague abdominal pains. She required the patient to drink large quantities of salt water which failed to cause vomiting. In the evening there was general abdominal rigidity though I was told two doses of morphia had been taken during the preceding two hours. The temperature was slightly above 100° F., and pain was not a special feature. She chatted with me while I made a vagino-abdominal examination that revealed retroversion of the uterus with some enlargement and fixation of the appendages. Dr. Stavely and I could not differentiate between ovarian hæmorrhage, appendicitis, and intestinal perforation, but the condition being evidently some grave lesion in the abdomen, she was at once opened by Dr. Stavely and a large amount of free blood that had escaped from a small ruptured ovarian cyst, the diameter of which he estimated as three inches, was found. No other reason for the attack was found.

Other cases might be cited to show the frequency of the condition and particularly that it is often a grave one. Novak reported a collection of 40 cases and Jayle 7, three of which were his.

CAUSES

Trauma plays a part in producing these hæmorrhages as instanced in the cases reported by Freeman, Primrose, and many others. The ingestion of poisons of various kinds are reported as exciting causes. The ingestion of oxytoxics and emmenagogues to interrupt a supposed pregnancy, especially when it did not exist, has been the cause in many cases. No doubt toxic conditions predispose to these hæmorrhages. Inflammatory changes and other pathologic conditions, including neoplasms, are causative agents. Possibly, instability of ovarian tissue and maladjustment of the internal secretions at puberty are provocative.

Hæmorrhage from the fallopian tube may occur from general conditions that similarly effect other tissues and need not be considered here. Venous stasis from circulatory disturbances or pressure from tumors may be reasonably included in a list of its causes. Vicarious menstruation may occur in the tube as well as from mucous membranes in different parts of the body. While I have not found case reports in the literature, I believe it can occur in infancy as well as can hæmorrhage from the ovary, as described by Tate, B. Schultze, and others, or from the uterus, a condition often reported by careful observers. Tubal neoplasms, especially carcinoma, may give rise to severe hæmorrhage. Local infections probably constitute a frequent cause of tubal hæmorrhage. Exposure to cold, particularly during or immediately before menstruation has been regarded by several reporters as the cause of ovarian hæmorrhage. Doran reports the case of a woman critically ill from a supposed ruptured tubal pregnancy in which he found a large hæmatocele formed from blood escaping from the fimbriated end of a tube that was neither ruptured, pregnant, enlarged or inflamed. No cause for the hæmorrhage was given. Beyond doubt tubal pregnancy is the cause in a preponderating pro-

[1] Read before the American Gynecological Society, Philadelphia, May 15, 1918.

portion of tubal hæmorrhages. Inflammatory infiltrations which compress and obstruct venous return from the tubes is thought to be the next most frequent cause.

Ovarian hæmorrhage may be confined within the ovary, constituting one or more hæmatomata or it may take place into the peritoneal cavity, producing, if abundant, an hæmatocele. In the former variety it may occur in the stroma, into new-growths or into follicles in any state of development. Several such hæmatomata may coalesce. Both may occur coincidentally and in fact, it is thought follicular may lead to stromal and *vice versa*. Between 1850 and 1859 Nélaton, Rokitansky and Puech had published their monographs on severe follicular hæmorrhage. If before or during follicular hæmorrhage rupture of the follicle or of the wall about a stromal active hæmorrhage occurs, the peritoneum may be deluged. Slight hæmorrhage from the follicle is regarded as a normal incident of ovulation. But the loss of more than a slight amount of blood in this manner must be regarded as pathologic. Ovarian hæmorrhage nearly always occurs during menstrual life. Probably its occurrence in the postclimacteric period of life is very rare. R. H. Harte reports the case of a woman long past the menopause who, while riding in a carriage, was seized with a severe attack of abdominal pain in the region of the appendix vermiformis. She had a history of chronic appendicitis and the inference was that that disease was the cause of the pain. Not improving in bed the abdomen was opened to find the abdomen filled with blood and an ovary ruptured across with free hæmorrhage from it going on. The ovary was found to contain an angiosarcoma. Several cases at birth have been reported and many striking ones chronologically near, or during, the first menstrual period though these two epochs in life cannot be regarded as having notable predilection for ovarian hæmorrhage. Probably conditions of the ovary at the time of menstruation afford the most potent factor in predisposition. Certainly a very large proportion of the reported cases have occurred during or within three days of menstruation. Bloodgood's 2 cases occurred the day before menstruation was expected. This synchronization between menstruation and ovarian hæmorrhage has been well fixed in our minds since Scanzoni reported his celebrated case in which at autopsy on the body of a young girl who had died during menstruation, he found three liters of blood in the peritoneal cavity, clearly from a ruptured ovarian follicle. Many like reports are recorded in the literature of the Surgeon General's Library. Ovarian pregnancy was the cause in one of the 35 cases of death from ruptured ectopic pregnancy reported by Formad. But as less than 25 authentic cases of this form of pregnancy have been reported, its share in etiology must be regarded as small—quite in contrast with tubal gestation in this relation.

The form of ovarian hæmorrhage, by far the most frequent and most interesting, will be discussed more fully in taking up the pathology of these hæmorrhages.

PATHOLOGY

No other organ of the body is so frequently the seat of hæmorrhage as is the ovary and a large amount of literature has been written on the pathology of the ovary in ovarian hæmorrhage. Much of it is repetition. I shall not discuss the pathology of hæmorrhage into the wall or the interior of ovarian cysts, at or subsequent to twisting of the pedicle, which is far from infrequent, nor will I take up ovarian pregnancy.

Stromal hæmorrhage is commonly preceded by infection of the ovary. Chronic ovaritis results in the development of additional connective tissue which frequently prevents rupture of the graffian follicle and retains it as a cyst. A sclerocystic condition is produced and fatty degeneration of the blood-vessel walls of the stroma follows. In the prolonged ovarian congestion incident to ovulation, or attempted ovulation, those vessel walls rupture, allowing the escape of blood either into the stroma or into the cysts retained; in one or several areas. This may also occur without ovaritis as is well shown in the case reported by Whitehouse, which occurred in a single woman of 40 years and whose menstrual periods since puberty at

16 years had each time been distressingly painful in spite of dilatation of the cervix uteri and curettage. The removed ovaries each contained on section multiple petechial or punctiform hæmatomata, most numerous in the subcortical layer, with no extensive extravasation at any place. Corpora lutea of different stages of retrogression were present. The blood cells were found free in spaces and confined within vessels. Frequently a recent hæmorrhage was found abutting against one of longer duration, the contrast being very evident. There was no evidence of excess in fibrous tissue or of inflammation. Several writers speak slightingly of the pathological and clinical significance of stromal hæmorrhage. But the pathologist and surgeon of gynecology lacks such disregard for the gravity of this form of ovarian hæmorrhage. Generally speaking it must be regarded as a product of sclerocystic degeneration—chronic ovaritis, a condition decidedly prejudicial to the integrity of the organ. Yet one cannot discredit the follicular form as a cause of the stromal variety. Moreover, infection is most apt to be a complication of stromal hæmorrhage. Several authors have written quite lengthily of the pathology of ovarian hæmatoma, including corpus luteum cysts and I shall pass over that subject, making only a few suggestive statements. The theca interna of the maturing follicle contains a richly supplied plexus of small blood-vessels which penetrate to the tunica granulosa. Following the rupture of the follicle, in the earliest stages of the corpus luteum, a much richer blood supply is developed and is termed by writers as the stage, or period, of hyperæmia. These blood-vessels are specially well developed next to the tunica granulosa and become smaller there when the lutein layer is completed. But the thecal vessels remain prominent until retrogression of the corpus luteum is nearly completed. In a large proportion of follicles, death of the ovum occurs in an early stage of development and a gradual degeneration of the tunica granulosa takes place. As a result of this death at various stages of development of the follicle a great variety of follicular cysts is found, with walls varying from a single layer of cuboidal epithelium to several layers. The cavities are found in various stages of atresia resulting from absorption of surrounding cell layers, fibrous tissue taking their place and producing the corpus fibrosum, to be distinguished from the corpus albicans—the terminal structure of the corpus luteum. These transitions were well shown in the case of Whitehouse. Some writers state the follicular form of hæmorrhage is much rarer than supposed and that the atretic follicle is by far the most frequent site of ovarian hæmorrhage. I believe this statement is true, but practically we should attach but little importance to it as, clinically, the time of predilection of such hæmorrhage into atretic follicles when of severe type, is during or very near menstruation—the usual time of severe hæmorrhage from follicles. Moreover, the atretic follicular form is usually not attended by such grave symptoms as appear with hæmorrhage into the follicle, or corpus luteum. Exceptions are those rare cases in which rupture of the ovary with hæmorrhage occurs, somewhat as in the case of the ruptured tube. The large follicle, nearly or completely developed, is far more easily ruptured, with alarming symptoms, than is the atretic follicle, though the much greater number of the latter might make the incidence of the site of hæmorrhage in favor of it. Hæmorrhage from the corpus luteum with resulting intraperitoneal hæmatocele seems so simple and easy that one wonders at its infrequent recognition. Like early tubal gestation, it may occur in a small degree without notable clinical evidence and probably often is unrecognized before operation or autopsy in but a marvelously small percentage of cases. Under such conditions to doubt that slight ovarian hæmorrhages may occur without even suspicion is illogical.

The large number of cysts often seen in the ovary is not wholly indicative of a sclerocystic condition, i. e., the ovary that is undergoing chronic inflammatory changes, and commonly has constricted zones outlined on the surface by girdling grooves underlaid by fibrous tissue, though earlier, before contractions have taken place, the surface resemblance to the cystic ovary is strikingly great. The so-called "cystic degeneration" is produced

by overstimulation in the process of maturation of follicles which have aborted and become atretic follicular cysts. It may be well to mention in passing, that "cystic ovaries" are indicative of ovarian hyperstimulation and overactivity rather than of hypofunction and disease and *cæteris paribus*, to be preserved rather than ablated. The sclerocystic ovary does not or should not enjoy such favorable consideration. No doubt hæmorrhage into these cysts is very common and equally probable is it that it results in unimportant phenomena. However, this result is not always so innocent. As these atretic cysts are so remarkably thinly lined before they become corpora fibrosa and are surrounded by such a great development of young blood-vessels, hæmorrhage into them might be expected to occur commonly. Probably the high degree of intracystic pressure, really greatest at this juncture, from general ovarian hyperæmia, and which to a greater or lesser degree neutralizes intravascular pressure accounts for it. It often occurs that such hæmorrhages into multiple cysts cause multiple hæmatomata which coalesce to form large hæmatomata. Either the small or the large ones may rupture into the peritoneum with more or less severe resulting hæmorrhage, when once the intracystic tension is removed. The naked eye appearance of such conditions does not enable one to distinguish the cystic from the sclerocystic ovary, unless the presence of pre-existing ovarian adhesions, or girdling, constricting bands of fibrous tissue are present. The microscopical evidence, however, should be ample for differentiation. Ofttimes the intracystic pressure is sufficient to prevent invasion by blood that escapes from the perifollicular zone of new blood-vessels, small infarcts, more or less zonal in shape, forming outside the cyst lining and easily becoming stromal hæmatomata.

In the corpus luteum the granulosal, zonal plexus of blood-vessels is probably more extensively developed than in the atretic form of follicle and in addition vascularization inside the follicle takes place; the two processes overlapping chronologically, in fact. The vascular area forms a lutein layer that is in turn abundantly supplied by capillaries from the perigranulosal area. At this time a moderate amount of blood escapes into the cavity of the corpus luteum and becomes adherent just within the layer of the lutein tissue. Early in the development of the corpus luteum, in fact until the corpus luteum is well matured, hæmorrhage may occur from the vascularized area into the luteal cavity and perhaps the blood be poured into the peritoneal cavity. Hæmorrhage into the luteal cavity may be so great as to interfere markedly with the process of maturation. Later, however, this type of hæmorrhage is less liable to occur as the blood-vessel walls become more resistant as do the walls of the corpus luteum.

SYMPTOMS

Non-gestational tubal hæmorrhage probably has no diagnostic symptom or symptom-complex. The symptoms of ovarian hæmorrhage are by no means distinctive. They vary from none known in cases in infancy found at autopsy to those at puberty resembling very closely dysmenorrhœa of ovarian or cervical origin and even to those severe attacks that have caused death or led to emergency abdominal sections.. Usually a history of sudden exertion that indirectly influenced the pelvic region has been followed by a very severe degree of pelvic pain, paroxysmal or quite continuous. Sometimes the pain is referred to the umbilicus or epigastrium, gradually limiting itself to the affected iliac fossa or lower abdominal zone, vomiting and collapse soon following. In some cases the pain has been well distributed throughout the abdomen and pelvis. General tenderness and muscular rigidity of the whole abdomen is usually present. Vagino-abdominal examination reveals great tenderness about the appendages. Wilson says the shock where there is no actual peritoneal hæmorrhage is out of all proportion to the extent of the lesion found. He states the two cardinal symptoms are abdominal pain and uterine hæmorrhage. Other observers scarcely subscribe to this statement but place stress upon interference with abdominal movements of respiration. As many of the cases occurred at or very near the menstrual period

the value of uterine hæmorrhage may be questioned.

Slight cases may clear up in a few days but the severer types offer no such happy result. Wilson thinks interruptions of the menstrual periods from "cold" with severe pains, so common in young girls, are often cases of ovarian hæmorrhage.

Probably careful analysis of a case would permit differentiation of the varieties, as in early infancy and early menstrual activity the follicular variety would be most likely and the corpus luteal and stromal to be least common. As infections become more common in later years the incidence of the stromal variety would seem to be increased. Moreover, stromal and corpus luteal hæmorrhages would not be so common at or very near the menstrual period.

Clinical observation bears out this statement. In the stromal variety a history of irregular or delayed menstruation is present and to this is often added evidence of long standing pelvic disease. In several instances the history was strikingly significant of tubal pregnancy. I have a very strong conviction that the diagnosis of ovarian hæmorrhage will be as clear as of ectopic gestation and its subdivisions easier to differentiate than are tubal abortion and tubal rupture.

DIAGNOSIS

In but few cases have correct diagnoses been made before operation or autopsy. One can most easily realize this fact by reading Primrose's paper and the discussion of it in the thirtieth volume of the transactions of the American Surgical Association (1912). Research of the literature presents an alarming picture with its reports of cases of ovarian and tubal hæmorrhage that had symptoms calling for immediate surgical treatment or having a rapidly fatal termination without previous recognition. Many have first been suspected at autopsy. Probably many in the future will not be decided by either of these procedures alone. In these the microscope will be of paramount importance in making the positive diagnosis. This statement has been indelibly impressed upon me by its use in my doubtful cases of ectopic gestation. In 1897, I brought this matter to the attention of the Southern Surgical and Gynecological Association and in 1914 to that of the Gynecological Section of the American Medical Association. Last year I again presented it to the first named organization. This, then is my fourth paper on the subject, written as an appeal to my confrères for more attention to be given to the subject of ovarian and tubal hæmorrhage not due to pregnancy. It must be distinguished from tubal pregnancy, ulcer of the intestine, appendicitis, and ingestion of poisons. I need not dwell upon this phase of the subject. My paper of 1904, referred to was based upon 10 cases of supposed ectopic gestation in which the microscope refuted the diagnosis. In December, 1917, I reported upon 19 later cases, 15 tubal and 4 ovarian, with the same postoperative provisional diagnosis. Microscopical reports on these reject 13 tubal and all of the ovarian cases. I am confident several of these cases had as much local evidence of pregnancy as many I have seen in the hands of others in which the microscopical diagnosis was accepted without question. One can easily appreciate the rank injustice of such an incomplete diagnosis in virgins and widows.

PROGNOSIS

I have already referred to the tragic character of many cases of these forms of intraperitoneal hæmorrhage. Their gravity may be appreciated when it is recalled that many of the foremost abdominal surgeons of the last 40 years have done emergency operations for their relief under the diagnosis of ruptured tubal pregnancy, appendicitis, etc. Among these may be mentioned Alban, Doran, Edgar, Galabin, Hind, J. A. Lee, and Tate. Depage reports a case of intraperitoneal rupture of an ovarian hæmatoma in which he promptly operated with a diagnosis of acute appendicitis with perforation. Primrose reports 2 cases which I have abstracted as follows:

CASE 1. A woman of 35 years, mother of twins of 3½ years, her only pregnancy; lifted a heavy chest two days before a menstrual period was expected and experienced sudden, severe pain

in the hypogastrium, nausea and vomiting. He found her twelve hours later anæmic, having a pinched and anxious expression, temperature 99.6° F, and pulse 130, marked abdominal distention and uniform rigidity. Palpation at once induced vomiting; general abdominal tenderness but most marked in left lower quadrant. Abdominal section revealed a very large quantity of blood in the abdominal cavity and a ruptured hæmorrhagic cyst in the left ovary from which arterial blood was spurting in a pulsatile fashion.

CASE 2. Exceptionally active woman of 40 years two days before a menstrual period was due was awakened at 2 a. m. with pain in abdomen. Seen 16 hours later the temperature was normal but severe local pain and vomiting were present. Operation four hours later for appendicitis, through right lateral incision. Fluid blood welled up into the wound and a midline incision was made. A large amount of blood, fluid and coagulated blood was found. The right ovary, considerably enlarged, contained a ruptured follicle from which the hæmorrhage occurred. No microscopic evidence of pregnancy or malignancy was found.

Bloodgood reports two cases of pelvic hæmatomata in which operation with a provisional diagnosis of appendicitis was done one day before the menses were due; one was tubal and the other ovarian in origin. Ellsworth reports a case of a girl of 18 years operated on in first 24 hours for appendicitis. The appendix was found to be normal and there was notable intraperitoneal hæmorrhage. A small laceration was found in the fallopian tube one inch from fimbriæ and from it bleeding was continuing. The microscope revealed no evidence of pregnancy. Leonard Freeman reports the case of an athletic young woman, who, in vaulting over a fence, experienced violent pain in the lower part of the abdomen and went into collapse. The abdomen was opened and the fallopian tube found torn near its middle. The uterus and appendages appeared otherwise normal with no evidence of pregnancy.

RELATION TO PELVIC HÆMATOCELE

Pelvic intraperitoneal hæmorrhages of various structures go to make up the immediate causes of pelvic hæmatocele. But nongestational tubal and ovarian hæmorrhage next to tubal pregnancy, are the chief causes and should always be considered in connection with such hæmatocele. Particularly is this true when such elements as ingestion of poisons, oxytoxics or emmenagogues; early menstrual life or postclimacteric; trauma or general conditions earlier mentioned occur.

TREATMENT

In the milder forms of the condition rest and anodynes may meet all indications. In the severer forms the same rules apply as are employed in treating ectopic pregnancy.

CLINICAL DATA ON CHORIO-EPITHELIOMA WITH END-RESULTS OF OPERATIVE TREATMENT[1]

By HIRAM N. VINEBERG, M.D., F.A.C.S., New York

THERE probably is no more interesting topic in the whole domain of gynecology than that of chorio-epithelioma. An entirely physiological process, by slightly overstepping its bounds, becomes, at once, a highly malignant condition with rapid and extensive metastases. Although it is generally associated with gestation, it may, nevertheless, occur in individuals in whom pregnancy can positively be excluded, as, for example, in a very young female, or in a male. Its development, under these conditions, forms a most interesting chapter in pathology. Another curious feature is its occasional development, originally in areas more or less remote from the site of the ovular implantation, while this remains free from the process. These and several other points in the pathology of the condition form a very tempting topic, but as they have already been so fully discussed in the literature by distinguished and capable pathologists, the writer felt it would be more within his powers to take up the clinical side, which, until now, has been very much neglected. His contribution upon this aspect of the subject is based upon nine personal cases and upon a close and rather extensive study of the literature. It is generally agreed that there are two varieties of chorio-epithelioma, the one highly malignant, the other semi-benign. The chief interest to us as clinicians is: Are there any means of distinguishing the one from the other? Marchand, who undoubtedly is the greatest authority upon the subject, and who, as we all know, has done so much to establish its pathology, frankly confesses he has failed to recognize any histological differences between the two varieties. A few pathologists, however, notably V. Velits, Robert Meyer, and Ewing, have attempted to point out features of differentiation, but their observations have not been confirmed by others. Several eminent pathologists, whom the writer has personally interviewed, emphatically stated they were unable to recognize any histological differences. The consensus of opinion, therefore, at present is that there are no definite histological features characterizing the one variety from the other.

Frequency. The number of cases recorded in the literature has been variously stated. For instance, Péry, in 1910, stated there were 700 cases on record. He has been frequently quoted. The figures are entirely too high. Pollosson and Violet, in 1913, made a very careful collection of the recorded cases and they accept Briquel's collection, in 1903, of 217 cases. From that date until 1913, they collected 238 more cases, making in all 455 cases. From 1913 up to the end of 1917, the writer has found recorded in the literature 69 cases which with his series of 9 cases make a total of 78 cases. Of course, it must be borne in mind that during this period the literature coming to us from Germany and Austria has been very scant.

Etiology. With very few exceptions, pregnancy has preceded the development of the growth; it is, therefore, essentially a disease of fertile women. But, as Teacher states, whether race, climate, or social conditions exert any influence upon its occurrence, we do not, at present, know. The ages at which it has occurred have varied from 17 to 55 years. In the series of 189 cases tabulated by Teacher in 1903, the average age was 33 years, 57 per cent of the total number occurred between the ages of 20 and 40 years, but there were 6 cases below 20 and 9 cases over 50 years.

In the writer's series of 78 cases, 4 were under 20 years; 13 were between 20 and 25; 21 were over 40 years, of these 8 were 50 and over.

The number of cases below 20 years and over 50 years is of great interest, and undoubtedly has some bearing upon the fact that hydatid mole which is the most frequent cause of the growth, is more often met with

Read before the American Gynecological Society, Philadelphia, May 17, 1918.

at the extremes of fertile life. Another factor of interest is that the frequency of the disease runs parallel with the degree of fertility.

In 156 cases of Teacher's series, in which the necessary data were available, 5 per cent occurred in connection with the first pregnancy, 15 per cent with the second pregnancy, 28 per cent with the second or third pregnancies. On the other hand, Briquel's 158 cases in his series of 181, give a much higher percentage with the second and third pregnancies: 33, or 21 per cent, with the second pregnancies; 31, or 20 per cent, with the third pregnancies; and 74, or 47 per cent, with the fourth or more pregnancies.

It is interesting to note the period elapsing between the last pregnancy and the development of the disease; in other words, the period of latency. This very often is not easily defined, as it usually has to be based upon the occurrence of the first symptom, which is generally hæmorrhage, or upon the appearance of a characteristic tumor in the vagina or vulva.

The period of latency, in the cases recorded has varied from a few weeks to several years; the longest period stated is 21 years.

Many writers doubt the accuracy of the long period of latency stated in several cases. They assume that a miscarriage of an early gestation had been overlooked. Be that as it may, there are some cases with incontrovertible evidence that several years elapsed between the last possible gestation and the development of the growth. Such a case is reported by Kroesing.[1] The patient was 52 years of age; 5½ years before, the uterus had been emptied of a hydatid mole; 2¼ years later, both ovaries were removed. At this time the uterus looked perfectly normal. Following the operation there was a complete cessation of the menses, 3¼ years later, and 5½ years after the hydatid molar pregnancy, the uterus was removed for metrorrhagia and was found to be the seat of chorio-epithelioma.

Bearing upon this point, Emil Ries, of Chicago[2] has made a most interesting and unique observation. In a uterus containing several fibroids that he removed from a woman who had not been pregnant for 18 years, he noticed a long thread-like formation hanging from the left uterine horn. This, on microscopic examination, proved to be a vein containing degenerated chorionic villi. No chorionic epithelia were found on these villi, which, according to Dr. Ries, would account for the non-development of chorio-epithelioma in that instance. The finding demonstrated beyond a question, the long period (in this instance 18 years), during which chorionic villi may remain latent in the system.

There cannot be much doubt that in many of the cases reported with a latent period of a few weeks, the growth had already existed before the termination of the pregnancy. In our Case 8, the growth was detected with the exploring finger, after manually emptying the uterus of a hydatid mole. Similar cases are reported by Eden,[3] Kelly and Workman.[4] In Pick's[5] famous case, the growth in the vagina developed during the presence of a hydatid mole in the uterus (fourth month of gestation). Wallart reported a metastatic growth in the eighth month of pregnancy. Von Rosthorn, Poten and Wasmer, each observed a metastatic growth in the vagina before the expulsion of a hydatid mole. The case reported by Jellinghaus[6] evidently belonged to this class. The patient was curetted for a hydatid mole. She continued to bleed, was again curetted and then subjected to a hysterectomy, five weeks after the first curettage. A growth was found in the uterus. Jellinghaus, in the writer's opinion, evidently failed to recognize the significance of the course of events in his case, otherwise he would not make the recommendation that every case of hydatid mole should be subjected to a second curettage, three weeks after the first, to ascertain whether any cystic villi are present, and if found, hysterectomy should be done.

But the treatment of hydatid mole, in reference to chorio-epithelioma, will receive attention later on. Bovée[7] reports an interest-

[1] Arch. f. Gynaek., 1909, lxxxviii, 469.
[2] Am. J. Obst., N. Y., 1913, lxvii, 433.
[3] Proc. Royal Soc. Med., Lond., 1913–14, vii, 146.
[4] Glasgow M. J., 1906, Sept.
[5] Berl. klin. Wchnschr., 1897, Nos. 49 and 50.
[6] Am. J. Obst., N. Y., 1917, lxxvi, 141.
[7] Surg., Gynec. & Obst., 1915, xx, 405.

ing case in this connection. In a fibroid tumor of the uterus, complicated with pregnancy, which he removed, a chorio-epitheliomatous growth was accidentally found in the wall of the uterus.

A most important consideration is the nature of the pregnancy preceding the disease. In Teacher's series of 188 cases, 73 cases, or 35 per cent, followed hydatid mole; 59 cases, or 31 per cent, followed abortion; 49 cases, or 28 per cent, followed labor at or about term; 7 cases, or 4 per cent, followed extra-uterine gestation.

In Pollosson and Violet's series of 455 cases, including Briquel's series of 217 cases, 203 cases, or 45 per cent, followed hydatid mole; 135 cases, or 30 per cent, followed abortion; 99 cases, or 21 per cent, followed labor at term; 12 cases, or 2.5 per cent, followed extra-uterine gestation; 6 were doubtful.

In Hitschmann and Cristofoletti's series of 240 cases, 116 cases, or 48 per cent, followed hydatid mole; 73 cases, or 30 per cent, followed abortion; 51 cases, or 21 per cent, followed normal labor.

They also give statistics of 200 cases of hydatidform mole, of which 15 or 7.5 per cent were followed by chorio-epithelioma. Teacher is of the opinion that this figure is too high; as five of the cases were recorded by Kromer, and as they all recovered after operation, he is inclined to question the validity of the diagnosis of malignancy. Omitting these cases of Kromer, the percentage is 5, which Teacher thinks is still too high.

Symptomatology. The most characteristic and prominent symptom is uterine hæmorrhage. This, as a rule, is very profuse and may even be alarming, as occurred in one of my cases (Case 1). The second hæmorrhage was so great that the patient became markedly exsanguinated in a few minutes, and it appeared to me, she would have bled to death, if I had not at once packed the uterus and vagina tightly with gauze.

However, in many instances, the bleeding may be only of moderate amount, but protracted, simulating that which accompanies ordinary placental or decidual residue. As a rule, the patient is subjected to a curettage, but it is found that the bleeding soon recurs. This of itself should excite suspicion. But it is not uncommon to read in the literature of cases that had been subjected to as many as four or five or six curettages, before the condition was suspected. The persistence and, at times, very abundant bleeding soon lead to marked anæmia, with its train of symptoms, cachexia becomes manifest, the patient feels and looks ill, and a septic condition may intervene. The latter is particularly prone to occur when several curettages have been done. This occurred in one of the writer's cases (Case 7), the only fatal one in the series.

In growing the tumor occasionally perforates the uterus; then there may be a most profuse intraperitoneal hæmorrhage, simulating ruptured tubal pregnancy of the cataclysmic type. T. Wilson[1] reports a case of this kind and a few others are found in the literature. In very rare instances, even when the growth is situated at the placental site, bleeding may be entirely absent, as in a case reported by Lichtenstein.[2] Even amenorrhœa of three or four months' duration, has been observed in a few cases (Eden, Cataruni, and others). This singular phenomenon has been observed only in cases following hydatid mole. Pollosson and Violet[3] draw attention to the presence of colic-like pains, caused by the expulsion of blood clots or of débris of the growth. A dull pain is an accompaniment of the later stages of the disease, when the broad ligament becomes involved. Hæmoptysis is an important symptom and may manifest itself comparatively early in rapidly advancing cases. It usually indicates the presence of pulmonary metastases (Teacher). In some instances, when the symptoms, referable to the genital tract, were not distinct or absent, a diagnosis of pulmonary phthisis was made.

In many cases, an early evidence of the disease is the appearance of characteristic tumors in the vaginal walls, most frequently in the anterior wall, near the urethral meatus. These may vary in size from that of an almond to that of a hen's egg. When they attain the

[1] Proc. Royal Soc., Lond., vi, 224.
[2] Zentral. f. Geburtsh., 1908, No. 8, 261.
[3] Ann. d. gynéc., 1913, 2d series, x, 2571.

latter size they are usually single. They possess a deep bluish color and appear very vascular. In other instances, several small papules will appear in the vaginal walls, preferably on the posterior wall, corresponding in size to that of a split pea. They have the characteristic bluish appearance and seem as if they were situated beneath the vaginal mucosa. The uterus is usually found enlarged, the degree of enlargement varying from that corresponding to the gravid organ at six weeks, to that at twelve weeks. The cervical canal may be patulous, readily admitting the index finger, thus permitting an exploration of the cavity. The growth then will be felt as a hard nodule of variable size, with a distinct excavation in the center. When it can positively be concluded that the excavation had not been artificially produced by a previous curettage, one is safe in making the diagnosis of chorio-epithelioma. In one of the writer's cases (Case 8) he was able to reach the correct diagnosis on the strength of this finding, even in the face of a negative report by the pathologist, from an examination of the curetted material. But not infrequently the uterus may not be appreciably enlarged, the growth being of very small dimensions, as has been recorded in several cases in the literature. The writer, in his series, met with one instance, in which the growth was no larger than a cherry, and was situated beneath the peritoneal covering, near the left cornu, the uterus, in that instance naturally, not being perceptibly enlarged.

In some of the cases recorded in the literature, there was an entire absence of symptoms referable to the genital tract, the first manifestation of the disease being symptoms due to a cerebral or spinal tumor, or to pulmonary metastasis. A. Straume[1] reports a case diagnosed as pulmonary tuberculosis, on account of hæmoptysis, dyspnœa, and pain in the chest. There was no bleeding from the genitals, neither was there a history of a hydatid mole, abortion, or labor at term.

A. Kedrierski[2] reports a case in which paraplegia developed eight months after last delivery at term. At the autopsy a chorio-epitheliomatous growth was found in the spinal cord, at the level of the fourth lumbar vertebra. Similar growths were found in the lungs, liver, and both ovaries. The uterus and vagina were entirely free of growths.

Chorio-epithelioma in connection with ectopic pregnancy. There are 13 cases recorded in the literature of chorio-epithelioma in the tube. The resulting mass has varied in size from that of a hen's egg to that of an adult head. The tumor is very friable and exceedingly hæmorrhagic. The histological features are the same as those of chorio-epithelioma of the uterus. Metastases are very frequent. Chorio-epithelioma of the tube has always been a discovery at operation, or on autopsy. It seems to have a more rapid course and a more rapid extension than chorio-epithelioma of the uterus.

Ectopic growths. While the usual site of chorio-epithelioma is in the body of the uterus, the growth has developed primarily in other situations. Sternberg[3] reported a case in which the growth involved the vaginal portion of the cervix, the remainder of the uterus being free of any growth. The endometrium showed a decidual reaction. The last pregnancy ending in an abortion, occurred 7 years before.

METASTASES

Metastases in chorio-epithelioma are of very frequent occurrence. They appear at a varying period and sometimes occur at a very early stage. In the case of Poten and Vassmer, two vaginal tumors were excised five days before the presence of a chorio-epithelioma was detected in the uterus. Metastases have been observed in nearly all the organs. In these cases the metastases take place through the blood-current. Most commonly a fragment of the neoplasm enters the blood current, passing through the heart and arrives in the lungs where it is disseminated to all the organs. But in the case of the organs in the genital sphere the metastases reach them through the venous anastomosis of the pelvic organs.

Robert Proust and Xavier Bender in their very excellent paper on chorio-epithelioma

[1] Petersburg med. Wchnschr., 1910, No. 28.
[2] Gaz. lek., Warsaw, 1912, No. 39.
[3] Zentralbl. f. Gynaek., 1907, No. 48, 1511.

have presented a very full description of metastases, to which I am indebted for many of the following data.

Metastases in the lungs are most frequent and their number and size vary very much. Occasionally only one tumor is found which may acquire very large dimensions, or more frequently numerous small nodules are found scattered over the entire lung. The most favorable sites are the apices and the bases. The middle lobes are less frequently involved. These metastases may develop insidiously and give no evidence of their presence until found at autopsy. This absence of clinical evidence is dependent upon the site, number, and volume of the secondary growths.

In the case of Lindfors[1] and Morison[2] the secondary growths developed to a relatively enormous size.

Next to the lungs, the vagina and vulva are the most frequent sites of metastatic growths. On account of their situation they are the most easily discerned. Occasionally a single isolated tumor only is present, but more frequently there are numerous small nodules running together forming almost a ring. Their form and their dimensions are most variable as also their location. They may involve the entire vaginal canal or they may occur only at the vulvar orifice or in the folds of the labia majora. They usually occur in the form of small nodular masses underneath the mucosa characterized by their brown or violet discoloration. They have been justly compared to thrombosed varices which they resemble so closely as to be frequently mistaken for them. The consistency is tense and elastic, almost fluctuating at times. These tumors grow very rapidly causing necrosis and irregular ulcerations. Occasionally these ulcerations are clean cut and well defined. The vaginal growths when they undergo ulcerations may be attended with profuse and obstinate hæmorrhages. They very soon become infected and give rise to a sanious and fetid discharge. The period of the appearance of the vaginal metastases varies considerably. Occasionally they appear in the later stages of advanced cachexia, but in some cases they occur remarkably early and furnish a valuable diagnostic sign.

Uterine ligaments, tubes, ovaries. The broad ligament is frequently found infiltrated by nodular masses of smaller or larger size. The invasion of the tubes and ovaries is occasionally characterized by small discrete growths discovered only on histological examination. At other times the growths may reach a considerable size readily distinguished by their reddish brown or dark color and their hæmorrhagic aspect on section.

Liver. Secondary growths in the liver are frequently found at autopsy. Generally the nodules are found disseminated, of a size varying from that of a pea to a small nut. In a case reported by Hitschmann, the entire liver was literally riddled with metastatic nodules. Paviot observed a case in which there was a tumor 4 centimeters in diameter on the convex surface and a large number of other growths in the depth of the liver. These metastatic growths generally do not give rise to many symptoms. Krawer and Macaggi have noted an increase in the volume of the liver, but the existence of a secondary tumor the size of a fœtal head was not even suspected in a case of Schmorl's.

Kidneys, urinary passages. Nitzel, Tibaldi Gottschalk, and many others have observed secondary growths in the kidneys, but the growths usually remained latent. In a case of Davis and Harris, a tumor in the left kidney 6 centimeters in diameter did not give rise to a single symptom. The exception occurred in a case of Gottschalk in which the urine contained characteristic plasmodial masses. In this instance, it is true, the tumor attained the size of a fœtal head. Secondary growths have very rarely been observed in the ureter (J. Schmidt), in the bladder (Jacubasch, Krawer, Perski, Marchand), and in the ureteral wall (Holzappel).

Metastases in the central nervous system are also frequently seen to occur most often at the level of the left hemisphere, and the most common site is the occipital lobe. They are sometimes found as a single nodule varying in size from a lentil seed to a hen's egg. In other instances they occur in multiple nodules. These secondary growths do not

[1] Zentralbl. f. Gynæk., 1901, No. 21, 567.
[2] Tr. Obst. Soc., Lond., 1890, xxxviii, 130.

usually have the hæmorrhagic aspect of visceral metastases.

In addition to these sites metastases have been occasionally observed in the most diverse organs, as for instance in the stomach, large and small intestines, heart, pericardium, pancreas, spleen, thyroid, suprarenal capsules, diaphragm, bone and subcutaneous cellular tissues.

DIAGNOSIS

The diagnosis of chorio-epithelioma is often beset with great difficulties. One should always suspect it when profuse hæmorrhage follows a hydatid mole that has been thoroughly removed. To be certain of this, one must employ the procedure advocated by the writer, some years ago; that is, in every case of hydatid molar pregnancy, to perform a hysterotomy, so that the hand may be employed to remove all the vesicles. Another inestimable value of this procedure consists in enabling the operator thoroughly to palpate every portion of the inner wall of the uterus for any suspicious nodule, or extra thinning of the wall, at any one area. In this manner the growth may often be detected in its very earliest stages, as was done by the writer in 2 cases, in his series, and by Eden in one case. For there can be no question, judging from a close scrutiny of the reported cases, that chorio-epithelioma was not infrequently present while the hydatid mole was still in the uterus. It is safe to place in this category most of the cases of hydatid molar pregnancy, in which the bleeding persisted, or recurred shortly after the uterus was emptied. The case reported by Jellinghaus, already referred to, in the writer's opinion, belongs to this class. If this assumption be correct, then the advice given by Jellinghaus and others, to subject every woman who has had a hydatid mole, to a curettage, every two or three weeks, to determine whether she is developing a chorio-epithelioma, would obviously be unnecessary, to say nothing of the dangers such a procedure would involve. H. Williamson[1] makes the suggestion that the Abderhalden test be made, every few weeks, in every woman who has a hydatid mole, so as to determine the earliest development of chorio-epithelioma. But it must also be borne in mind that in a few cases, a period of amenorrhœa intervenes between the removal or expulsion of a hydatid mole, and the first symptoms of the presence of a growth. In Eden's case a period of two months and in Cataruni's case 3 months elapsed. No explanation has been offered for this paradoxical phenomenon. In Eden's case, the growth was evidently present at the time of the hydatid mole, as when he emptied the uterus he detected a small nodule on palpation and thought it was a fibroid nodule.

When the growth follows shortly after labor at full term, the cervical canal is usually patulous. Then it may be feasible to palpate the interior of the uterus with the finger or fingers. The detection of an elevated, fairly hard, nodule with an excavation in the center is almost pathognomonic. The appearance of the characteristic bluish red papules on the vagina or in the vulva, confirms the diagnosis. When the cervix is not patulous, other means have to be employed, which will receive attention later.

The greatest difficulties are encountered when the growth follows an early miscarriage, for in these instances one can never be certain that the persistant bleeding may not be due to placental or decidual residue, even though the curettage may have been done by an expert. In such a contingency, one must have recourse to a microscopic examination which, unfortunately, even by the expert, may not be conclusive, or may even be misleading. Several cases are recorded in the literature in which the microscopic examination by a pathologist of repute and ability, proved to be inconclusive or erroneous. The writer has already referred to an instance of his own in which a most capable pathologist made an error in diagnosis. When we stop to consider the nature of the condition, we can readily understand how a microscopic examination may be attended with failure. Unless the curette scrapes away some of the deeper tissues, the pathologist has no means of determining whether he is dealing with a new-growth or with normal placental tissue. He can only determine this, if the microscope

[1] Proc. Royal Soc. Med., Lond., 1913–14, vii, 146.

shows invasion of the deeper structures, for that is the only distinguishing feature between normal chorionic tissue and chorio-epithelioma. To add to the difficulties, a curettage done so as to bring away some of the deeper tissues is not free from danger. It is prone to set free particles of the growth, which may gain entrance into the venous circulation and then bring about rapid and extensive metastases. A close scrutiny of the cases in the literature reveals the fact that the most rapidly fatal cases were those that were subjected to several curettages before a diagnosis was reached and a hysterectomy performed.

Hitschmann and Cristofoletti lay great stress upon the dangers attendant upon a curettage in chorio-epithelioma. They studied 300 cases in the German literature, and made a comparison between the cases subjected to a curettage and those that were not. In the former, they found that metastases were very much more extensive and rapid than in the latter. They found, also, that the fatal, non-operative cases, had fewer metastases than those subjected to hysterectomy, which terminated in death at an early date. Thus demonstrating that any manipulations of the affected tissues are likely to cause extensive metastases. In studying the reports of the cases in the literature, one cannot fail to observe how much better the results were, when the radical operation had not been preceded by two or three or more curettages, as obtained in many of the cases. The unusually excellent results obtained by the writer, in his series, 8 recoveries in 9 cases, cannot well be explained by the mere assumption that the cases were all of the semi-benign variety. That would be a fortuitous occurrence, not to be paralleled by a series of a similar number of cases, in the literature. It is more within reason to attribute them to the circumstance that the diagnosis was made at an early stage of the disease, than that in every instance the growth was of the non-malignant type.

The only fatality in the series occurred in the case that was subjected to two curettages, the pathological report of the first being misleading, although a tentative diagnosis, on the clinical evidences, had already been made by the writer. In spite of all these considerations, instances will arise where recourse will have to be taken to a diagnostic curettage. The clinical evidence may not be conclusive, it may justify only a suspicion, and one would under these conditions naturally hesitate to remove the uterus in a young woman, without having incontrovertible evidence of the presence of the disease. But if any aid in diagnosis is to be sought from the material obtained by a curettage, one must make sure that the curette has brought away some of the deeper structures, as already has been stated. Occasionally, in a doubtful case, especially in a young woman, one might adopt the method employed by the writer in a case recently.

The patient, aged 26 years, had had a miscarriage of twins, at about the third month, 6 weeks before. She was curetted in a metropolitan hospital on the same day. She continued bleeding, at times quite profusely. The uterus was but slightly enlarged, she was now again curetted, the pathologist reported that the tissues were suspicious of chorio-epithelioma, but he could not be certain of the diagnosis as there was no myometrium in the material. The bleeding recurred in a few days. Not wishing to subject the patient to another curettage, the writer did a vaginal hysterotomy and also anteverted the uterus through an anterior vaginal incision. In this way he was able to palpate and inspect with the naked eye both the inner and outer walls of the uterus. No growth or suspicious area was detected. The wound, in the uterus, was sutured, the organ was replaced in the pelvic cavity and a suture applied to the vaginal wound. The patient has been under observation for over 3 months; she has been perfectly well and menstruation has been normal.

The growth may be situated entirely in the uterine wall or projecting toward the peritoneal surface, and has no connection whatever with the endometrium, as in a case reported by H. Meyer[1] and another by Nagy[2]. Hence the necessity of exploring both surfaces of the uterus.

PROGNOSIS

There is no form of malignant new-growth, in which the prognosis varies so widely as in chorio-epithelioma. If the diagnosis has been made early, and the uterus has not been subjected to much manipulation, as is occasioned by several curettages, the prognosis is fairly

[1] Zentralbl. f. Gynaek., 1914, iv, 382.
[2] Arch. f. Gynaek., c, No. 2.

good. Different from other malignant growths the outcome may be good, even in the face of extensive metastases. Several cases are on record, in which there were evidences of metastases in the vagina and lungs, and the patients recovered with and without operation. A remarkable instance of this kind is a case reported by J. C. Rockafellow[1] in which, after removal of the uterus, large growths recurred in the labia, at intervals of a few weeks. As soon as the growths, sometimes the size of a kidney, were excised, they would spring up again like mushrooms, in a week or so. On the fourth recurrence, the patient's general condition was so poor that it did not seem worth while to make any further attempts at removal. To the surprise of every one, in a few weeks, the growths spontaneously began to shrink and in a few weeks more, had practically disappeared, leaving a mere hard ridge at their site. The patient began to improve and in a short time regained good health and remained so as long as she was under observation, which was a period of over two years.

Von Fleischman,[2] Hormann[3], Hitschmann and Cristofoletti (loc. cit.), each report similar cases. In Hitschmann and Cristofoletti's case, the operation was given up on account of the extent of the tumor, which involved the vagina and bladder, and extended far and wide, in the pelvis. The patient improved rapidly after the operation, and a month later there were no signs of the tumor of the uterus, and the pelvic structures seemed to be free. The patient was in perfect health, seven years later. In one of the writer's cases (Case 4), several small bluish papules appeared on the posterior vaginal wall, after the hysterectomy. These gradually disappeared spontaneously. Neumann,[4] Kelly and Teacher,[5] Marchand, have each observed spontaneous disappearance of vaginal metastases after removal of the uterus. Risel,[6] Eden and Lockyer,[7] reported the observation of healed nodules in the lungs, among those still growing, in a case which terminated fatally. Teacher, himself, publishes a similar observation.

Regarding operative results, the statistics published by Teacher (loc. cit. p. 590) exhibit the most careful study. In the 189 cases collected, radical operation was performed 100 times. Of the group not operated upon all ended fatally except the case of von Fleischman. Of the 100 cases operated upon, 63 were followed by immediate recoveries, and 37 by death; of the 37 deaths, 12 occurred within a few days, evidently from shock and loss of blood. In the remaining 25 there was no marked improvement, or interval of good health after the operation. "Out of the 63 recoveries, 32 were reported well six months or more, after the operation, and out of this number 24 remained well for more than a year, and of these again, 13 were reported well more than two years after the operation. Among the fatal cases, it was remarkable that in 5 only, did the disease recur after a longer interval than six months, and the longest interval between operation and death was one year. Death after a longer interval has since been reported." Teacher goes on to say: "Still, one is justified in the conclusion that, if the patient survives more than six months without signs of recurrence, the probability of recovery being permanent is considerable; after one year, it is very great. while cases in which two years have elapsed may be regarded as absolute recoveries."

Teacher draws attention to the striking fact that 42 of the cases, with a percentage of recovery of 78, followed hydatid mole. He adds, "Possibly a considerable number of these should not have been described as chorio-epithelioma malignum."

Briquel reported 114 cases with 72 operative recoveries and 42 deaths. Of the 181 cases collected by Pollosson and Violet, there were 126 operative recoveries and 17 deaths from operation. The difference in the operative recoveries, in the two series, could well be explained by the difference in the periods in which they were performed, the one period extending from 1885 to 1903, the other from 1903 to 1912.

[1] Tr. Ia. St. M. Soc. 1915, v, 428.
[2] Monatschr. f. Geburtsh. u. Gynaek., 1903, April.
[3] Beitr. z Geburtsh. u. Gynaek., 1904, viii, 3.
[4] Monatschr. f. Geburtsh u. Gynaek., 1897, vi, 17.
[5] J. Path. & Bacteriol., 1898, p. 358.
[6] Quoted by Teacher. New System of Gynecology.
[7] 1917, vol. ii, p. 587.

Briquel analyzed this series, in reference to the operative results, following the different kinds of pregnancy. In 21 cases following labor at term, there were 12 (57 per cent) recoveries, in 34 cases following miscarriage, there were 20 (58.5 per cent) recoveries, in 54 cases following hydatid mole, there were 37 (68.5 per cent) recoveries, in 3 cases following tubal gestation there was 1 (33.3 per cent) recovery.

The writer is inclined to agree with Pollosson and Violet, that the better results obtained in cases following hydatid mole are probably due to the circumstance that the cases are watched more closely, and the diagnosis, in consequence, is made at an earlier stage.

Before taking up the treatment of chorio-epithelioma, it may be well to devote a short time to the consideration of the treatment of hydatid mole in view of the close connection between the two conditions. This close relationship between hydatid mole and chorio-epithelioma was first established by Marchand in 1895. The frequency with which hydatid mole is followed by chorio-epithelioma has been variously stated by different writers. Bumm in his textbook placed it at 15 per cent. Palmer Findley[1] in a collection of 210 cases found it to be 16 per cent. On the other hand, in 20 cases observed at the Kiel Klinik, only two were followed by chorio-epithelioma. Kehrer[2] followed up the history of 50 cases of hydatid mole and did not meet with a single instance of this complication. The writer, during a period of four years prior to 1911, had observed 8 cases of hydatid mole, 3 of these were attended or followed by chorio-epithelioma. Senarclens (quoted by Pollosson and Violet) was enabled in the Canton of Vaud to observe for a long period of time, 42 out of 49 cases; 35 or 72 per cent were definitely cured by the expulsion or removal of the hydatid mole, 7 or 14 per cent underwent immediate cure, but the remote results were unknown. Three only, or 6 per cent, died from chorio-epithelioma. It is obvious that statistics, such as these, furnish a more reliable basis as to the relationship between the two conditions than do those coming from hospitals or operators. But granting even that the higher percentage expresses more closely the actual relationship, it would scarcely warrant the attitude of some authorities, that all cases of hydatid mole should, at once, be subjected to a panhysterectomy. When a hydatid mole occurs in a woman over 40 years of age, as not infrequently is the case, it may be the safer course to resort, at once, to hysterectomy, rather than wait for the development of chorio-epithelioma. But it occurs almost as often in young women, ranging from 18 to 25 years, in whom an unnecessary sacrifice of the generative organs would be most reprehensible. Hence, in women, let us say, under 40 years of age, the course advocated by the writer, in a paper[3] read before the New York Obstetric Society, May, 1911, ought to be followed. This, as has already been described above, consists in performing a vaginal anterior hysterotomy, for the double purpose of making certain of removing all vesicles, and of making a thorough exploration, with the hand, of the entire inner walls of the uterus. The woman should then be carefully observed for a long period, and on the occurrence of profuse bleeding, a diagnosis of chorio-epithelioma would be justified.

The treatment of chorio-epithelioma, once the diagnosis has been made, resolves itself into an immediate panhysterectomy, for, as we have already shown, we have no means of determining whether the individual case be a highly malignant one, or one that might undergo spontaneous cure. The latter contingency is so unusual that for all practical purposes it must be left out of consideration.

When the growth is discovered while emptying the uterus of a hydatid molar pregnancy, the natural thing to do would be to complete the operation through the vaginal route. The same would apply when, in a doubtful case, an exploration of the inner and outer walls of the uterus would be made through a vaginal incision. In most all other instances, the abdominal route probably is to be preferred, for it embraces less traumatism and consequently less danger of causing metastases.

[1] Am. J. M. Sc., 1903, p. 486.
[2] Arch. f. Gynaek., 1894, xcv, 487.
[3] Am. J. Obst., N. Y., 1911, lxiv, No. 3.

Hitschmann and Cristofoletti lay strong emphasis upon the selection of the abdominal route for this very reason, and also because they deem it advisable to excise the deep pelvic veins, as is done in puerperal thrombophlebitis. They assert that the pelvic veins are frequently filled with extensions from the growth. Hence, the necessity of this excision. Should this even be the case, it is doubtful whether the procedure is called for, inasmuch as these venous extensions have a tendency to disappear spontaneously by clotting of the blood, depriving the tumor masses of their source of nourishment. Vaginal nodules, if present, should be excised and, if they occur subsequently, the same procedure might be necessary, although they also have a tendency to disappear spontaneously. Different from carcinoma, the lymphatic vessels and glands are seldom involved, and there is no indication for doing anything so radical as the Wertheim operation. One should not defer doing the operation, in the face of the most unpromising local conditions, for extensive infiltrations are usually due to venous involvement which, as we have seen, has a tendency to disappear spontaneously after removal of the uterus. Even when there are signs of metastases in the lungs, hysterectomy should not be denied, if the patient be in a condition to withstand the shock of the operation, for there are several cases on record, in which the lung symptoms have disappeared, after the original growth had been removed.

Radium has been employed in a few instances,[1] but with only temporary benefit.

CASE I.[2] Mrs. E. R., a patient of Dr. Altman, was seen by me January 4, 1907. She was 47 years old, married 26 years, had had eight children, the last seven years ago; one miscarriage 16 years ago. She enjoyed good health, and menstruation had been normal until the present illness. Her last regular menstruation occurred September 27, 1906. On November 10, when she was 17 days overdue, a bloody flow occurred, resembling in amount and duration her usual menses. But the blood did not cease entirely. She continued staining and 12 days before I saw her she had a profuse flow lasting one day, and passed several large clots. She had no abdominal pain until the day of my visit, when she referred it to the lower part of the abdomen and stated that it was moderately severe. Three weeks before, while mounting a flight of stairs she felt a severe fluttering in the cardiac region, and suffered from shortness of breath. She has suffered, more or less, from similar symptoms since then and complained of great weakness. Swelling of the feet and legs was noted about this time and the swelling has kept on increasing until now. She had taken to bed the day before on account of general debility and the unwieldy size of the feet and legs. She was extremely anæmic, her breathing rapid and shallow, pulse rapid and rather bounding. There was a soft blowing murmur accompanying the first sound and the cardiac impulse was diffuse; cardiac dullness considerably increased. The abdomen was occupied by a spherical smooth tumor, reaching to the upper border of the umbilicus. On bimanual examination, the cervix was found soft and moderately patulous and passed into the abdominal tumor. The breast nipples were surrounded by a dark areola but no colostrum was found. The urine contained a large quantity of albumin and numerous granular and hyaline casts. The diagnosis was made of a probable pregnancy of an abnormal type, or a fibroid growth undergoing sarcomatous degeneration. The advice was given to have the patient enter Mt. Sinai Hospital, and under anæsthesia to explore the uterine cavity. This was done on January 9, and although only a few days elapsed since I had examined the patient, the uterine tumor had markedly increased in size, so that now it reached midway between the umbilicus and the ensiform cartilage. As soon as I could introduce the index finger into the uterine cavity, after dilating the cervix, and it encountered a soft, mushy material, I recognized I had to deal with a hydatidform degeneration of the chorion. I rapidly emptied the uterus of its contents, making certain that all the hydatid material was removed. The patient made a surprisingly good recovery. Her cardiac and pulmonary symptoms disappeared within a few days. The albumin in the urine rapidly disappeared and the casts gradually grew less.

There was a slight bloody flow for four or five days, then a mucopurulent flow for four or five days longer, and after that there was no discharge of any kind. The patient returned home and was gradually gaining in weight and improving in color, when on February 1 she was suddenly seized with a profuse uterine hæmorrhage. I advised the attending physician to pack the vagina and to make immediate arrangements for the patient to be readmitted to the hospital. I saw her two days later. She was considerably exsanguinated. In replacing the vaginal gauze there was a very severe hæmorrhage. I rapidly stuffed some gauze into the uterine cavity and repacked the vagina tightly. From the clinical history and on finding an enlarged, hard uterus with closed cervix, I diagnosed chorio-epithelioma malignum. On the day following, February 4. I performed an abdominal panhysterectomy, not deeming it

[1] Erck and Outerbridge. Internat. Clinics, 1915, vol. 1.

[2] Am. J. Obst., N. Y., lv, No. 6.

safe to wait to curette and submit the scrapings to a microscopic examination. She made an uneventful recovery from the operation. Patient well up to the present.

Pathological report by Herbert L. Celler, Assistant Pathologist, Mt. Sinai Hospital. (Specimen consists of uterus and adnexa.) The uterus is very pale. Length of body 2.5 centimeters, width just below fundus 11 centimeters, length of cervix 4 centimeters. The organ is very firm, the serosa smooth. There is a slight lateral laceration on the right side of the posterior lip of the cervix. The walls of the fundus measure 3 centimeters in thickness at the widest part. The muscular tissue is intersected by numerous bands of connective tissue that coalesce near the mucus to form a more continuous broad band. The mucus lining both the body and cervix is smooth, except at the internal os where there is a slight swelling and congestion, and at the point of entrance of the fallopian tube. At the latter site there is a bean-shaped mass 1.5 centimeters in length, projecting into the lumen of the organ. This tumor is mottled in color, red and white, soft and friable. The underlying muscular tissue is softer than that of the remainder of the uterus, and is also friable. The hæmorrhagic areas are, however, confined to the tumor itself, and are not found in the underlying muscular tissue. The right ovary is normal in size. The left ovary contains two large cysts, one about 1.5, the other about 2 centimeters in diameter. Both fallopian tubes are negative.

Microscopically, the tumor consists of both syncitial masses and Langhans cells. The former are arranged in plaques and in bands, in some places forming a fine meshed reticulum. The spaces thus formed are frequently filled with red blood corpuscles, or contain one or more cells of the syncitial or Langhans type. The former are irregularly shaped, deeply staining, the outlines of the cell not always clearly defined. The nuclei are also irregular, and stain with great intensity. Frequently these cells contain two, three, or four nuclei. The Langhans cells stain faintly, and have a sharply defined outline. The nuclei are round or oval, and vesicular. The greater part of the tumor is composed of the above syncitial masses, but at one point there is a large mass of Langhans cells. Large hæmorrhages are scattered throughout the tumor. At some points the syncitial cells lie close to the walls of blood-vessels or lymph spaces, an occasional cell being present within the lumen itself. The tumor infiltrates the musculature of the uterus for about one-third of its thickness. Scattered between the syncitial masses are numerous leucocytes, while surrounding the entire area of tumor tissue there is a marked round-celled infiltration. Between the tumor and the lumen of the uterus there is a thin band of necrotic tissue enclosing leucocytes and the remains of a few uterine glands. The walls of the blood-vessels of the uterus have undergone hyaline degeneration.

Both ovaries show a number of corpora lutea in which the lutein cells are proliferated. These bodies are small with the exception of one that lies in the midst of the dense tissue of the atrophic ovary. Here there is very marked proliferation of the lutein cells, many of which contain large granules of yellowish pigment. At the periphery of the corpus there are rather numerous distended blood-vessels with thin walls. There are no evidences of organization present.

Diagnosis kindly verified by Dr. F. S. Mandelbaum, Pathologist.

CASE 2.[1] G. H. admitted from the dispensary service into Mt. Sinai Hospital. She was 47 years of age, married 28 years, had nine children, last child eight years ago, two miscarriages, last one nine years ago. Menses had always been regular, moderate in amount, lasting from three to five days, and not attended with pain. Seven days before her admission into the hospital she began to bleed. She was then two weeks overdue. The bleeding persisted and at times was quite profuse. She looked rather old for the age given and was moderately anæmic. Her general condition, otherwise, was good. On bimanual examination, the uterus was found reaching to within two fingerbreadths of the umbilicus and was rather hard to the touch. There was a bluish discoloration of the vagina, and milk could be expressed from the nipples. Dr. F. Krug confirmed the diagnosis of hydatid mole, which was made in my service in the dispensary. He curetted the patient himself, removing a large quantity of hydatid material. The patient made a good recovery and was discharged March 3, with the instruction to return if uterine bleeding recurred. At the time of her discharge the uterus was nearly normal in size. On March 28, she returned to the hospital with the statement that soon after she left the hospital the bleeding recurred, and it has gradually been growing more profuse. The uterus was now found to be considerably enlarged, corresponding in size to the gravid organ at about the sixth week. A diagnosis of chorio-epithelioma was made and on March 30 the uterus removed by me, *per vaginam*.

April 8. The patient made an uneventful recovery and is sitting up out of bed. She was well two years later, when last heard from.

Report on specimen by Dr. F. S. Mandlebaum, Pathologist to Mt. Sinai Hospital. The specimen consists of uterus and adnexa. The uterus is enlarged, 11 x 9: 5 x 5 centimeters. The wall measures 17–30 millimeters in thickness. Occupying the posterior wall and extending downward from the fundus for a distance of 48 millimeters, there is a growth which fills up and slightly distends the uterine cavity. On either side the growth extends to the openings of the fallopian tubes, elevating the mucous membrane and causing it to slope downward to the opening. The tumor is sessile. Its edges are overhanging, except at the upper half. The surface of the tumor is irregular and ulcerated,

[1] Am. J. Obst., N. Y., lv, No. 6.

and microscopic section shows it to be chorio-epithelioma malignum.

CASE 3. Mrs. C. G. admitted to Mt. Sinai Hospital, May 1, 1912. She was 36 years old; married 17 years; VI-para, last child 4½ years ago; no miscarriages except this present one; menses established at 14 years, four-weekly type, duration 2 days. Her last menses occurred 14 weeks ago. Two weeks ago uterine bleeding set in which has persisted up to the present; uterus the size of the gravid organ at 12 weeks.

May 2. Uterus emptied by Dr. F. Krug. The cervix was patulcus, admitting the insertion of the index finger with which the membranes were ruptured. A small fœtus and placenta were secured with placental forceps, and the uterine mucosa thoroughly curetted with the sharp curette.

May 14. Discharged from the hospital. The following note was made at this time: Uterus moderately enlarged and lying in retroversion.

June 5. The patient was readmitted, stating that for 2 weeks she felt well and then began to bleed very profusely, which was 10 days ago. The bleeding has persisted until now. The patient is quite anæmic. Local findings about the same as when discharged 3 weeks ago The uterine bleeding is very profuse, necessitating packing of the vagina.

In view of the history and the certainty that none of the ovular products were left behind by Dr. Krug, a diagnosis of chorio-epithelioma was made.

June 6. Abdominal panhysterectomy was performed by the writer. The patient made an uneventful recovery. A year later was in good health.

Macroscopic report, June 6, 1912. The specimen consists of the uterus, the left adnexa complete; and the right tube. The right tube in its distal half is thickened and tortuous; its abdominal ostium is closed by adhesions. The left tube in its distal half is also thickened and tortuous, not quite so much so as that of the other side. The abdominal ostium is patent. The left ovary is somewhat enlarged, studded with small cysts up to size of a pea. The uterus is slightly enlarged. In the left cornu is a small lobulated, firm tumor fixed to the uterine wall and invading it for a short distance. The mass measures 2 x 4 centimeters and is grayish in color. The rest of the uterus and cervix is apparently normal. *Microscopic diagnosis*. Chorio-epithelioma.

CASE 4. Hydatid mole. Chorio-epithelioma. Double ovarian cysts. Hysterectomy. Postpartum eclampsia. Recovery.

Mrs. S. C. was referred to me by her physician, Dr. J. S. Diamond. She was eighteen years old, married fifteen months. Menses at fourteen years, four-weekly type. Duration three to four days. Amount moderate, not with any great pain.

Six months after marriage went two weeks overdue and then began to bleed. Was supposed to have a miscarriage and was curetted Her menses were regular after this for four months and then ceased for two months, when she began to bleed irregularly; at first scantily and later rather profusely. When she consulted me the bleeding had been going on for about two months.

She was very pale, sallow, and looked very ill. The uterus reached up to the umbilicus and was rather tense. The cervix was closed. Behind the uterus lay two irregularly shaped cystic masses each about the size of a closed fist. The urine contained a large amount of albumin and numerous hyaline and granular casts. There was no œdema. The diagnosis was made of an abnormal pregnancy with double ovarian cysts.

Operation, November 22. Finding, on attempting to empty the uterus, that it contained a hydatid mole and as both ovaries were cystic, I decided to perform a panhysterectomy, which I did, removing the cervix also. The operation offered no unusual difficulties and consumed about an hour. The patient withstood it very well. At 5 o'clock the next morning, twelve hours after the operation, the patient was seized with a severe convulsion, lasting about ten minutes. This was followed by coma of twenty minutes. From this hour until 11 a.m. she had, in all, seven convulsions, each followed by coma of longer or shorter duration. The urine was very scanty, loaded with albumin and showed very numerous granular and hyaline casts. Temperature had risen to 104° and pulse 180, very small and soft.

The patient was subjected to the usual treatment for eclampsia; in addition, phlebotomy was done, about sixteen ounces of blood withdrawn, and colon irrigations with saline solution were given. She showed signs of improvement toward the evening of the same day when the temperature fell to normal although the pulse still remained very high (140 to 160). From this on improvement was steady and on November 30, eight days after the operation, the urine showed merely a trace of albumin.

The removed uterus on microscopic examination showed quite an area of chorio-epithelioma on the posterior wall near the fundus. The ovaries were cystic throughout and showed little or no stroma. There was no excess of lutein cells. December 12. Patient discharged from the hospital as cured.

January 15, 1911. She was again referred to me by her physician on account of bleeding from the vagina. I found a small vascular growth in the center of the vaginal scar and dotted over the posterior wall of the vagina were small flat papules about the size of a split pea and of a bluish-red color. I suspected a recurrence and had her readmitted to the hospital. On January 19, I excised the growth with the Pacquelin cautery and also cauterized the papules on the vaginal wall. The removed growth showed no evidence of chorio-epithelioma, consisting only of connective tissue with blood cells. Patient left the hospital January 25.

May 8. Patient called at my request. She was in good health, her color had become good, she gained in weight. There had been no recurrence of the bleeding. The vaginal wound was healed and the entire vault was smooth and normal in appearance. Two years later when last heard from was well.

Macroscopical report, November 22, 1910. The specimen consists of uterus measuring 13 centimeters from internal os to fundus. The wall measures 2.5 centimeters in thickness. The uterine mucosa is covered throughout by necrotic, velvety tissue which is thrown up in places into markedly rugous and almost papillomatous masses. On section, sinuses of uterus are markedly enlarged, the cross section of the muscularis having a fenestrated appearance. Both ovaries are enlarged into irregular ovoid, orange-sized, completely cystic masses with straw-colored, mucin-like contents, some of them containing blood.

Microscopical diagnosis. (a) Chorio-epithelioma. (b) Polycystic degeneration of both ovaries. No marked proliferation of lutein cells. (c) Hydatidiform mole.

CASE 5. Chorio-epithelioma. Abdominal panhysterectomy. Recovery.

Mrs. C. B. was admitted to Mount Sinai Hospital on March 17, 1911. She was 36 years old, married at 18 years, 7 children, the youngest child being 23 months old. Menses at 14 years of age, irregular, three to four-week period up to two years ago; since then, menorrhagia of 2 to 10 weeks at a time. The last regular period was 12 weeks ago; bleeding since. For past 2 years she has had slight pain in the lower abdomen, associated with backache and slight leucorrhœa.

Vaginal examination showed the uterus to be uniformly enlarged to size of 10 weeks' pregnancy; fairly soft; the adnexa normal; and the presence of a good-sized rectocele and cystocele.

March 21. The patient had a rather profuse hæmorrhage from the uterus. She became pulseless and required very active stimulation. Hæmoglobin 64 per cent. Panhysterectomy by Dr. Krug.

The specimen consists of a fibroid uterus about the size of a 3 months' pregnancy. In the cavity there was a shaggy mass attached by a pedicle to the fundus, resembling very much a piece of placenta, which might be a necrotic submucous fibroid.

April 17. Patient was discharged in good condition.

Macroscopical report, March 21, 1911. The specimen consists of the uterus which is enlarged. The uterus shows marked hypertrophy of the wall which measures 3 centimeters. Near the fundus on the anterior wall is an area, covered by soft granular and fungoid tissue which causes a thickening of from 1 to 4 millimeters in the endometrium. Besides this is tissue which appears to be amnion and chorion.

Microscopical diagnosis. Chorio-epithelioma.

CASE 6. A. H. was admitted to the Mount Sinai Hospital on June 12, 1911. She was 33 years old, married 12 years, five children, last child 21 months ago, doubtful miscarriage 3 months ago. Menses at 14 years, four-weekly type, duration 7 days. Three months before, when menses were due, she merely stained. A month later stained again. At the recurrence of the next menses, she flowed very profusely and suffered with pain in the right iliac region. She was then admitted to the Lying-In Hospital, where she was curetted for a miscarriage. The flow persisted after the curettage and so did the pain. On admission the patient was found to be moderately anæmic. The uterus was about of normal size and the adnexa were apparently normal.

In view of the history of the case, chorio-epithelioma was suspected. Not desiring to subject the patient to another curettage, it was decided to explore the uterus visually by an anterior colpotomy, and if necessary by an anterior hysterotomy.

Operation, June 15. A transverse incision was made in the anterior vaginal fornix; and the uterus delivered through it. In the right cornu was seen a small vascular tumor the size of a filbert, and presenting the characteristic bluish discoloration of a chorio-epitheliomatous growth. The operation was completed by extirpating the uterus and adnexa through the vagina. The patient made a rapid recovery and was discharged on July 1. She was under observation for two years and remained perfectly well.

Macroscopical report, June 15, 1911. The specimen consists of the uterus with both tubes and ovaries. The uterus measures 7.5 x 5 x 3 centimeters. It is the normal multiparous shape. The cervix shows a shallow old laceration to the right. The wall of the uterus is 1.5 to 2.2 centimeters in thickness. A papilliferous mass is situated at the fundus in the neighborhood of the right horn. Its base is 1.7 centimeters wide and 2.2 centimeters long (from above downward), and the mass projects about 5 centimeters beyond the surface of the mucosa. The tumor is fairly firm and is pinkish brown in color. Both ovaries are of about normal size and cystic (old corpus luteum cysts.) No recent corpus luteum of any prominence is visible.

Microscopical diagnosis. Chorio-epithelioma.

CASE 7. Chorio-epithelioma. Septicæmia-streptococcæmia. Hysterectomy. Death. Mrs. L. L., 31 years of age, married 5 years, had 2 children, one three and a half years ago and the second four months ago. She was seen in consultation by me March 18, 1910, for persistent uterine bleeding. Her medical attendant, an intelligent practitioner, informed me that he had delivered the patient at term with instruments four months before. The patient went through a normal puerperium, but the flow of blood in small quantities persisted for three weeks. It then ceased for three weeks when it recurred and continued off and on in slight amounts, until two weeks before, when rather a sharp hæmorrhage took place. He then curetted her, removing apparently several fragments of placental tissue. This put a stop to the bleeding for some days when it recurred again slightly with rather a free flow now and then. On the night previous she had a profuse flow of blood. I found a strong, healthy looking woman inclined to obesity, with moderate pallor of the lips. She was nursing, and the infant seemed to be thriving satisfactorily. On bimanual examination I found the uterus enlarged to the size of the gravid organ at about six weeks. The cervix

was patulous, admitting the index finger readily, which on exploring the uterine cavity detected a sessile growth on the anterior surface of the uterus, near the left horn, corresponding in size to about a fifty-cent silver coin, raised above the surface about one-fourth of an inch, and presenting on its surface a shallow depression. There was no marked hardness of the growth. I made the diagnosis of a probable chorio-epithelioma, and stated that I would be more certain of the diagnosis had not a curettage been done a short time before. I argued that a placental residue, the other alternative in diagnosis, would not present a crater-like excavation on its surface. But here entered the element of doubt. Could not the excavation have been produced artificially by the curette? I advised, therefore, her entrance into Mount Sinai Hospital where the growth could be removed with the curette and subjected to microscopic examination. I curetted her that afternoon in the hospital without anæsthesia in the presence of Dr. F. S. Mandlebaum, the pathologist of the hospital. The curette removed so much tissue that looked like ordinary placental tissue that both he and I thought that it was an ordinary case of bleeding from placental remains. The temperature, rectal, before curettage was 100.8°, pulse 108. March 19, temperature, 99 to 100.4°, pulse, 100 to 108. March 20, temperature, 99.6 to 100°, pulse, 96 to 100, no bleeding.

Report from the pathologist stated that removed tissue showed nothing more than normal decidual structures. Being anxious to have the patient return to her nursing infant as soon as possible I had given orders to have her transported home in the ambulance. On the following morning, March 21, just as the patient was being gotten ready to be sent home, she had a moderate flow of blood. She was taken into the examining room and the interior of the uterus gone over lightly with a curette on the supposition that a small fragment of tissue might have been left behind. The curette did not bring away enough tissue to account for the bleeding. She had scarcely been returned to her bed when she had a severe hæmorrhage and she was at once brought back to the examining room and the uterus packed tightly with iodoform gauze. I now felt that we had, in all probability to do with a malignant growth, notwithstanding the report from the laboratory, and requested that a further examination be made of the tissue removed that morning. Four p.m., temperature, 102°, pulse, 136. Assuming that the fever was due to the uterine packing, the house surgeon removed two pieces of gauze from the vagina, under the belief that on so doing he had removed all the gauze that had been employed in packing. March 22, 4 and 8 a.m., temperature, 99.4°, pulse 116. Four p.m., temperature suddenly rose to 104°, pulse, 120; 8 p.m., temperature, 105.6°, pulse, 134. I had seen the patient in the morning when her temperature was normal and concluded that the temperature of the evening before was due to retention due to the uterine packing which was relieved by removal of the gauze. In the evening her condition was reported to me and I immediately visited the patient. On specular examination, I found that the house surgeon had removed only the vaginal packing and that the uterine gauze was still *in situ*. I removed it and irrigated the uterus with alcohol 50 per cent. March 23, 8 a.m., temperature, 105.6°, pulse, 140; vomited once. Blood culture taken. Decided to remove the uterus as soon as consent could be obtained. Eight p.m., temperature 103.8°, pulse, 148. Hysterectomy. Owing to the patient taking the anæsthesia poorly and to the great abundance of fat in the abdominal wall and in the subperitoneal tissue of the pelvis, it was not feasible to carry out ligation of the pelvic veins. Patient withstood the operation very well. March 24, 8 a.m., twelve hours after operation, temperature, 103.2°, pulse, 140.

March 24, 4 p.m., chill, temperature, 106.4°, pulse, 140 to 180. March 25, 4 a.m., patient died.

Notes from the pathological laboratory. March 18, 1910. Specimen of retained placenta received. Decidua with markedly atypical cells, some very large with giant nuclei. Diagnosis is in doubt, but it is suspicious of malignant change.

March 23, 1910. Uterus received for examination. Organ is moderately enlarged, and musculature is soft and flabby. Uterus measures 9 centimeters; wall considerably thickened, 18 x 25 millimeters. Mucosa shows evidence of curettement. In the body anteriorly is a lenticular avid tumor occupying the site of the mucosa, and the tissues immediately underneath infiltrate the muscularis for about 1 to 2 centimeters. On section this area measures 3½ x 2 centimeters and is composed of soft, hæmorrhagic, necrotic tissue. The microscopic sections of the uterine tumor show the so-called atypical variety (Marchand) of chorion epithelioma. In the superficial zone there is extensive necrosis, hæmorrhage, and conglomerate masses composed of atypical, acidophile syncytium and cells of the Langhans type; in the deeper layers, syncytial masses and chorionic wandering cells of bizarre shape penetrate the muscle for a considerable distance and are also found free in the blood sinuses. Diagnosis: chorion epithelioma.

Autopsy performed on March 25, 1910, at 2 p.m., by Dr. A. E. Cohn. Case of chorio-epithelioma with pulmonary metastases. Body of an adult adipose female. Panniculus adiposus well developed. Operative incision in the median line above the symphysis pubis, about 15 centimeters long.

The lungs are both voluminous, pinkish gray in color. Adhesions between lobes and between lung and pleurae. Scattered through right lung, but more especially projecting along borders, are small tumor masses varying in diameter from 3 to 10 millimeters. On cut section they project sharply above the surface of the lung and are sharply circumscribed, and have a "port wine" and a somewhat reticulated appearance. The reticulum is grayish. The dependent portions of the lung are

congested. There is no consolidation; no tubercles; no metastases. The bronchi are congested; the pulmonary arteries are normal. The left lung shows adhesions similar to the right, except that there is no fibrinous exudate on surface. There are about twelve metastases of the shape and size described.

The heart is normal in size with marked fatty overgrowth. The pericardium is normal. The right auricle is somewhat dilated, but not the right ventricle. There are marked chiari over the coronary sinus, the muscle is flabby and pale. The tricuspid valve admits two fingers, the edges of the valve are retracted, thickened, but show no recent lesion. The aorta shows fairly marked atheroma, the posterior much less than the anterior. Foramen ovale closed.

The liver shows slight parenchymatous and fatty degeneration, otherwise normal.

A slight perisplenitis is present but diffluent. The lymphatic structures of the spleen are not easily made out.

The kidneys show marked parenchymatous degeneration.

Floor of the pelvis is clean. There is some bluish discoloration along the line of suture. The vesical veins show no abnormality. The inferior vena cava in its lower half shows no thrombosis.

Microscopical examination. There are metastases in the lung. The tumor mass itself is composed of large blood sinuses together with necrotic areas into which there has been hæmorrhage. Scattered through the tumor, but especially at the periphery there are groups of cells characterized by irregularity in size and shape. Nuclei for the most part are large and vary in their amount of chromatin; some of them are almost vesicular and others show a dense network. The cell bodies, where they can be observed, are irregular in shape and finely granular. A number of cells show karyorrhexis. These cells are for the most part isolated, having only a slight tendency to form groups. A number are vacuolated. The diagnosis of chorio-epithelioma is made.

CASE 8. R. W., aged 50. Married 26 years; ten children; last child eight years ago. Three miscarriages, last seven years ago. Patient consulted me May, 1911. She stated that her menses for the past year had been irregular, occurring from four to eight weeks. A month ago, after a period of amenorrhœa of eight weeks she began to bleed. The bleeding persisted with varying intensity up to the time of her seeing me. I found the uterus enlarged, had the sign of a gravid organ of about 12 weeks. It had a soft doughy feel. A diagnosis of hydatid mole was made, and the patient given a card of admission to Har Moriah Hospital.

May 15, 1911, operation. Vaginal hysterectomy. Uterus emptied with the hand of about a quart of characteristic vesicles. Interior of uterus palpated. A suspicious nodule was felt in the posterior wall. Operation completed by doing a vaginal panhysterectomy. Microscopic examination by the pathologist of the hospital confirmed diagnosis of chorio-epithelioma, which was also confirmed by Dr. L. S. Mandlebaum, pathologist to Mt. Sinai Hospital. Patient in good condition up to the present, seven years after the operation.

CASE 9. Mrs. J. S. admitted to the Mount Sinai Hospital on November 3, 1915. She was 44 years old, married for 26 years, had seven children, one dead, youngest child six years old; all pregnancies full-term, and normal delivery; one miscarriage. Menses began at 14 years, regular every month, duration from four to five days. Up to six weeks ago patient had amenorrhœa for past five months. During this time she commenced to bleed, and this has continued steadily and progressively up to the present time, much blood being lost.

Physical examination revealed the following: The abdomen, was soft, relaxed, tympanitic. There was a mass present, reaching almost to the umbilicus, hard and smooth in consistency, conforming to shape of a gravid uterus of four months' advancement. The mucous membrane of the vaginal canal was of a violet hue. The uterus was large, anteflexed conforming to size of pregnant uterus of almost four months. Adnexa were not felt. Cervix not patulous, direction down and forward.

November 5, 1915. Hysterotomy and emptying of uterus for hydatidiform mole performed by Dr. S. Wiener. November 15, 1915. Uterus well involuted. Hysterotomy wound, slight gaping at one point. November 16, 1915. Patient discharged in good condition.

Pathological report, November 10, 1915. Tissue from uterus- hydatid mole.

November 17, 1917. Patient readmitted. Diagnosis chorio-epithelioma. Vaginal flow daily for four months. (Through courtesy of Dr. Joseph Brettauer).

Vaginal examination disclosed a moderate cystorectocele; cervix hard and nodular. Uterus anterior, slightly enlarged. Fundus globular and hard. Both fornices clear. Uterine bleeding. Sound determines small smooth sound nodules on left lateral and anterior walls. Slight tear in perineum. Uterus slightly enlarged.

November 19, 1917. Exploratory curettage by Dr. Lindeman. November 21, 1917. Cervix gauze removed. Patient's condition good. Extra systoles more frequent, otherwise no signs of cardiac lesions.

November 22, 1917. Vaginal hysterectomy for chorio-epithelioma by Dr. Lindeman.

Specimen. Uterus slightly enlarged. Normal tubes and ovary. On opening the uterus there was present in the fundus a small (2 centimeters) friable, pedunculated tumor, dark brown in cross-section and on surface, extending only a short distance into uterine tissue. November 19, 1917. Curettings show evidences of malignant tumor suspicious of chorio-epithelioma. November 22, 1917, uterus and adnexa show chorio-epithelioma.

December 3, 1917. Patient discharged from hospital in good general condition.

A VAGINAL HYSTERECTOMY TECHNIQUE FOR THE CURE OF PROLAPSE OF THE UTERUS WHEN THE REMOVAL OF THE UTERUS IS NECESSITATED

With Special Reference to Lapping of the Vaginal Fascia in All Forms of Vaginal Prolapse[1]

By DOUGAL BISSELL, M.D., F.A.C.S., New York
Attending Surgeon, Woman's Hospital in the State of New York.

IN an article read by me before this society at its last meeting describing a subtotal vaginal hysterectomy technique for the cure of procidentia uteri, I reached the conclusions that (1) there was encountered in it an element of danger to life, as the result, probably of necrosis of the reconstructed uterine body, which did not justify its further use; (2) that the interposition of the reconstructed body added nothing to the result when success was obtained; (3) that the essential features in the successes were the approximation of the cut surfaces of the cardinal ligaments and the correct readjustment of the fascial structure of the anterior vaginal wall.

My object in this communication is to make a preliminary report of a vaginal hysterectomy technique for the cure of prolapse of the uterus where the removal of the uterus is necessitated and to advocate the principle of fascial lapping in all forms of vaginal prolapse. The initial steps of the hysterectomy technique will be recognized as identical to those described in my previous study. The method of lapping the fascia described in the following sentence will be recognized as a plan of procedure suggested by me in the article referred to. "Sometimes the anterior vaginal wall, like the uterus, is considerably hypertrophied. When this is the case the mucosa can be removed in part from one lateral strip and the strips lapped so as to give additional strength."

It was not until December 11, 1917, and January 17, 1918, that there came under my care cases which conformed to the above description; namely, great hypertrophy of the uterus and vaginal wall and complete procidentia. A report of these cases and of the operation performed for their relief was made before the New York Obstetrical Society February 12, 1918, and a description of the procedure which was followed will be published in the June issue of the *New York Journal of Obstetrics*.

VAGINAL HYSTERECTOMY AND FASCIAL LAPPING FOR PROCIDENTIA UTERI

Two curved incisions, meeting in front and behind, are made about the cervix at its juncture with the vaginal mucosa. The vaginal tissue is separated from its cervical attachments and each cardinal ligament area of tissue severed from the cervix and penetrated and tied with a chromic gut suture No. 2. As the free ends of these sutures are to be used at the completion of the operation forceps are now attached to each group.

The vesicofascial area may be entered by either a longitudinal incision or by the curved incisions as they pass above and to the sides of the cervix. The preferable approach to this area of cellular tissue is through the curved incisions. When this area or line of cleavage between the bladder and fascia is found it is followed by blunt dissection on each side of the lateral limits of the anterior vaginal wall. The so-called vesico-uterine ligament, which is but a part of the vesicovaginal fascia, is next severed and the bladder separated entirely from its fascial attachment starting below and working upward. As the freeing of the bladder from the fascia is continued toward the urethra the anterior vaginal wall is incised in the median line until the blending of the fascia with the urethral tissue is reached.

The posterior surface of the bladder is now completely separated from the anterior wall of the cervix and the peritoneal reflection incised. The tissues between the cervix and

[1]Read before the American Gynecological Society, Philadelphia, May, 1918.

Fig. 1. Showing the uterus out of the vagina with all its attachments severed except the posterior vaginal barrier, which barrier with the gauze strip passed through the anterior opening, prevents the vaginal contents entering the peritoneal cavity.

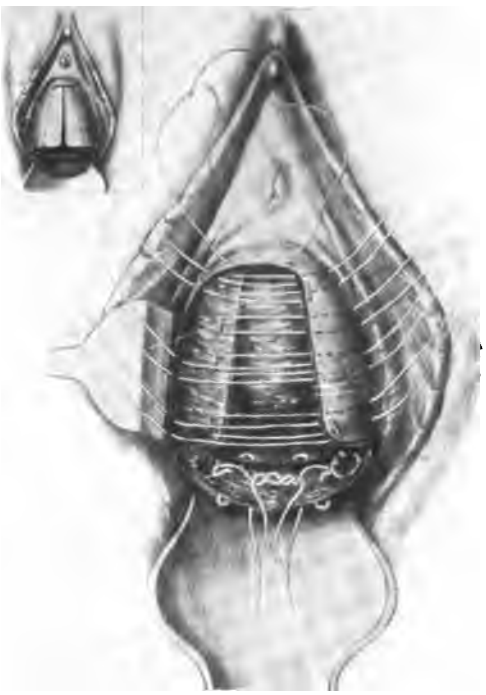

Fig. 2. The marginal insertion in the upper left hand corner shows the initial incision of the anterior vaginal wall and the opening in the vault of the vagina on the removal of the uterus. The dotted lines indicate approximately the amount of tissue removed longitudinally from each flap.

The larger illustration shows the underlapping flap denuded of its mucous membrane and the sutures placed for anchoring both flaps. A bundle of tissue is seen on each side of the vault of the vagina, encircled by a chromic gut suture. One strand of each suture is passed in and out along posterior vaginal cut surface to control hæmorrhage and the other tied with its opposite free strand to approximate the lateral bundles or cardinal ligaments.

the rectum are likewise separated, but the posterior peritoneal reflection is not incised.

The corpus uteri is now delivered through the anterior peritoneal opening and a narrow strip of gauze, to which is attached a piece of catgut, is passed into the peritoneal cavity to protect it and prevent the intestines and omentum from protruding.

The vaginal flaps are next prepared for lapping by first trimming them longitudinally to not less than half their original size. From the right flap, or that to the left of the operator, the mucosa is completely removed. This flap is severed crosswise near its urethral attachment to the extent of about 0.5 centimeter so as to facilitate its adjustment when anchoring it under the opposite flap.

Four or more mattress sutures of chromic gut No. 2 are now inserted in such a manner as will anchor this denuded flap under the undenuded flap and to the opposite stable line where the fascia meets the lateral limit of the vagina. Four or more interrupted chromic gut sutures No. 2 and a continuous suture are used to anchor the undenuded flap to the opposite stable line, or lateral limit of the vagina, and also to approximate the cut edges of the mucosa.

One strand of each chromic gut suture surrounding each so-called cardinal ligament is utilized as a running suture along the posterior cut surface of the vaginal vault to prevent hæmorrhage, which not infrequently occurs from this surface. The remaining strands are now tied to approximate the cut "cardinal ligament" tissues. These latter sutures are used again and made to penetrate the lower margin of the newly constructed anterior vaginal wall from within out and tied to the sutures passed through the poste-

Fig. 3. A sagittal section showing a larger rectocele with cervix in normal position.

rior vaginal wall. Before tying these sets of sutures a narrow strip of iodoform gauze is passed into the posterior vaginal space. Iodoform packing in the vagina completes the operation.[1]

The features which I would particularly emphasize in this technique are (1), the separation of the cellular tissue at the beginning of the operation from the posterior surface of the cervix up to the peritoneal reflection without opening into Douglas' cul-de-sac. The great advantage of not entering the peritoneal cavity at the beginning of the operation is that the continuity of tissue here acts as a barrier to prevent the contents of the vagina from soiling the peritoneal cavity and the intestines from protruding into the vagina; it also prevents the cervix uteri from coming in contact with the peritoneum when the fundus is anteverted and the cervix is forced back into the vagina.

The second feature pertains to the removal of the corpus, which is delivered through the anterior peritoneal opening and operated on at the vulva. Each step in its removal is executed with greater ease and exactness by attacking the upper portion of the broad ligaments first and working downward than by attacking the tissues around the cervix first (corpus remaining in peritoneal cavity) and working upward.

The third feature is the reinforcement of the anterior vaginal wall by lapping the fascia and anchoring the cut margins to the stable areas of the vaginal canal and approximating the cut surfaces of the cardinal ligaments.

That prolapse of the uterus, as well as of the anterior vaginal wall, has been cured by varied surgical procedures is not to be questioned, but failures continue to occur and no method has yet established itself in the confidence of the majority of surgeons.

When success is attained by any of the methods *per vaginam* now in vogue, emphasis is placed upon some particular feature considered essential for success. When hysterectomy is done for the relief of procidentia we find emphasis laid upon the approximation of the cut edges of the round and broad ligaments in one method, the shortening of the uterosacral ligaments or the anchoring of the round ligaments in the vault of the vagina in another, the interposition of the approximated round and broad ligaments or of the resected corpus uteri in still others. In my opinion all these special features are given undue consideration, and success, when attained, is the result not of them but of a common element entering into all of them—namely, surgical adjustment of the pelvic fascia.

It is not my object to discuss the individual operations for the cure of procidentia uteri and cystocele, but it would seem fitting, because of its historic interest and the principle involved in the Emmet operation to do more than make passing mention of it.

Emmet utilized the principle of fascial support of the anterior and lateral vaginal walls with the intuition and skill of the consummate surgeon he was. He recognized that success depended "upon the unyielding line along the vaginal sulcus on each side where the walls are connected with the pelvic fascia"—and that this tissue, owing to its elasticity, can be stretched to a certain degree

[1] Previous to operation a 10 per cent nitrate of silver solution is applied to the vaginal mucosa and the external os closed with a continuous catgut suture.

but for all practical purposes the areas are fixed.[1] By Emmet's method two lateral fascial surfaces are united to a central fascial surface; in this way the fascial support of the uterus and bladder is reconstructed and we have here the first instance, on a limited scale, of fascial lapping of the anterior vaginal wall. In Emmet's hands success by this method was the rule. In the hands of others success seems to have been the exception. I would not refer to this operation, long since considered obsolete by many, were I not convinced that it possesses an essential feature of success. Grant Baldwin recognized this fact several years ago, and also the cause of failure in the original technique and modified it with such results as should demand our respectful consideration.

It would seem a justifiable conclusion, with the evidence at hand, that the underlying principle of success in operations for the cure of uterine and vaginal prolapse is the proper surgical adjustment of the pelvic fascia; but the fact remains that we have not yet developed a standard technique or one which can be applied, with such modifications as the necessity of the individual case demands, to meet all requirements.

When a prolapsed uterus has undergone such structural change as necessitates its removal, or when, after menopause, its removal is considered for one reason or another desirable, the vaginal hysterectomy technique as herein described, will prove, I believe, the method most adaptable and satisfactory. I recognize that it has not yet been put to the test of time, but as it is in principle identical to that upon which nature, under normal conditions, depends for support, confidence in its ultimate success would seem justified.

CERVIX AMPUTATED, CORPUS RETAINED, AND FASCIA LAPPED

When it is found advisable, in cases of procidentia uteri, to retain the uterine body but amputate the cervix, the following technique presents certain advantages:

The first stages of the technique are in part identical to the first stages of the vaginal hysterectomy technique previously described, that is the vesicofascial area near the cervix may be entered by either the longitudinal or curved incisions. The line of cleavage is then followed laterally to the side walls of the vagina, longitudinally to the urethral region and along the cervix to the peritoneal area. As the separation of the bladder from the fascia progresses the anterior vaginal wall is incised in the median line up to the urethral region. The vaginal wall flaps are now trimmed longitudinally to the extent required and the flap to the left of the operator denuded of its mucous membrane. The sutures anchoring the flaps are placed in the manner described in the vaginal hysterectomy technique for

[1] Emmet. Principles and Practice of Gynecology. p. 257.

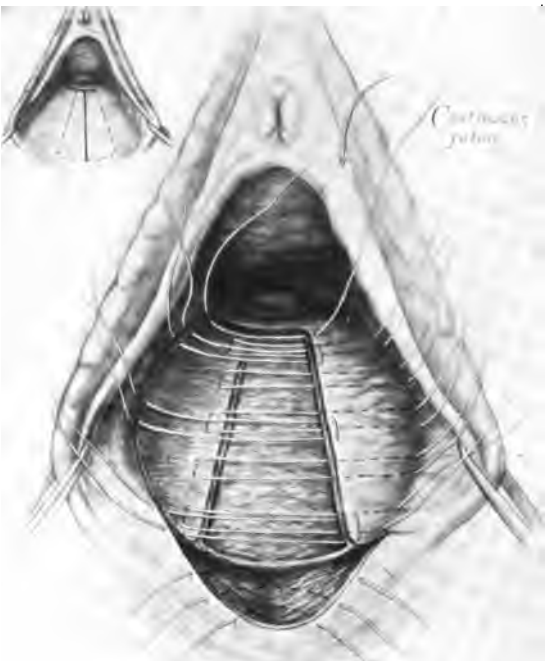

Fig. 4. The dotted lines on the marginal insert indicate the approximate amount of tissue removed longitudinally from each posterior vaginal wall flap. The drawing is somewhat misleading as the amount of tissue removed is really more than would seem from the drawing. The tendency is to undercorrect by not removing enough tissue. The appearance after operation should be that of overcorrection.

The larger illustration shows the underlapping flap denuded of its mucous membrane; the line of fascia merging with the perineal body; the denuded perineal body and all sutures placed for anchoring flaps and closing perineum.

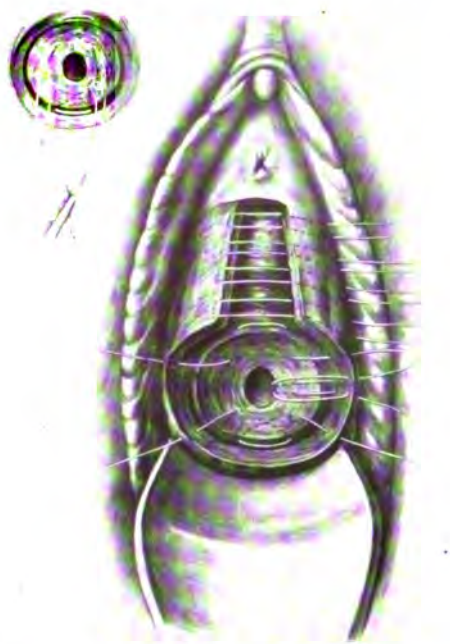

Fig. 5. This illustration shows the several stages of the operation for prolapse of the uterus where the corpus uteri is not removed, but where the cervix is amputated. The steps in the operation with respect to the anterior vaginal wall are practically identical to those where the corpus is removed. Immediately after amputating the cervix, two chromic gut sutures No. 2 are inserted in the cervical stump according to the manner shown in the insert. These sutures serve as tractors and control hæmorrhage during the progress of the operation. After anchoring the vaginal flaps the free ends of these sutures are passed through the vaginal tissues on each side and when tied anchor this vaginal tissue over the cervical stump. The middle suture in the main illustration is devised first to shift the position of the lateral tissue or cardinal ligament, and second to anchor the vaginal mucosa to the cervical stump. The method is reversed to that of Emmet and tends to lengthen rather than shorten the anterior vaginal wall.

procidentia uteri, namely, four or more mattress sutures being used to anchor the denuded or underlapping flap to the opposite stable line of the lateral wall of the vagina and four or more interrupted chromic gut sutures and a continuous suture to anchor the undenuded or overlapping flap to the opposite stable line of the lateral wall of the vagina.

Previous to tying the sutures of the anterior vaginal wall the mucosa about the cervix is stripped back laterally and posteriorly sufficiently to permit of a high amputation of the cervix. The sutures of the cervix are placed according to a plan which is here particularly adaptable and serviceable. One figure-of-8 suture is inserted through the upper area of the cut surface of the cervical stump and one through the lower area. These two sutures may be placed immediately after the amputation of the cervix and used as tractors controlling hæmorrhage at the same time. At the completion of the operation their free ends are passed through the edges of the freed vaginal mucosa and when tied they approximate the mucosa over the stump. The sutures which direct and secure the vaginal mucosa to the cervical canal are inserted in an opposite direction to the classical method of Emmet. The needle is first inserted into the more or less free lateral tissue or cardinal ligaments on each side. The free ends of each of these sutures are passed through the cervical stump near the canal and back through the margin of the freed vaginal mucosa of the same side. By this form of stitching two objects are attained, namely: the cardinal ligaments are anchored to the cut surface of the cervical stump and the vaginal mucosa is anchored to the cervical canal. Extra sutures may be inserted, if necessary, and finally a narrow strip of iodoform gauze is passed through the cervical canal into the cavity of the uterus to prevent a possible union of the cut edges of the mucosa in the region of the cervical canal. Perineorrhaphy is done, if required, and the vaginal canal is packed moderately tight with iodoform gauze. By the Emmet technique the tissues of the vesical area are used to cover the anterior surface of the cervical stump, and to that extent the anterior wall is shortened. If his method is reversed according to the plan just described the length of the anterior wall is not shortened.

When in the childbearing period prolapse of the uterus and bladder is corrected by fascial lapping and the uterus retained it is as yet an open question whether or not the reconstructed fascial wall would prevent or in any way interfere with the process of labor. I have not as yet operated for procidentia uteri or cystocele by the fascial lapping method and preserved the entire uterus.

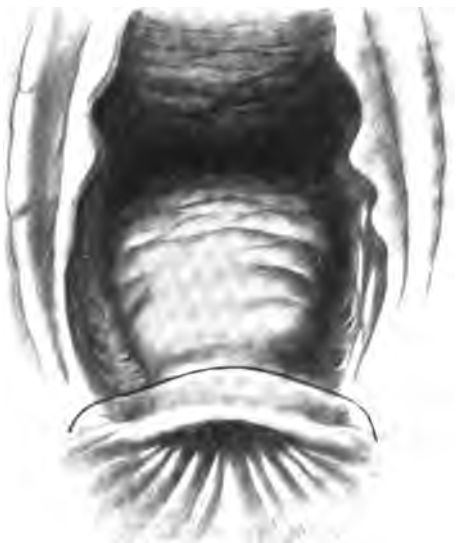

Fig. 6. This illustration shows a partial rectocele with deep vaginal sulci and a complete laceration of the sphincter. The black line indicates the first incision made in performing the Ristine operation. The repair of the sphincter and correction of the rectocele were done at the same time.

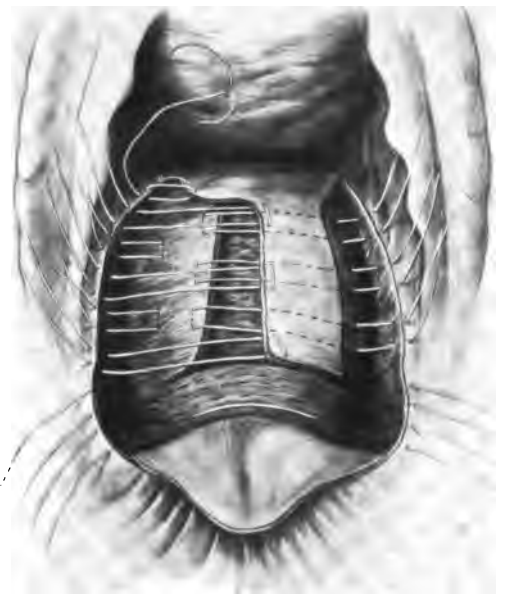

Fig. 7. In this instance we had two deep sulci to care for. The posterior vaginal flaps were prepared in the way previously described, except that the flap to the right of the operator was not trimmed longitudinally, and that portion of it which extended down in the sulci was denuded of its mucosa as was its corresponding lateral vaginal wall. The sutures were then placed in the manner shown in the drawings. When these sutures were tied, the flaps were anchored in such a way as to obliterate the sulci and elevate the posterior vaginal wall.

The Emmet-Baldwin operation does not permit of the completion of labor without the destruction of the operative results.

With complete procidentia uteri both the anterior and posterior vaginal walls prolapse in greater part; while this is the rule, cases do occur where one wall protrudes from the vulva more than the other, so that in one case we may have a marked cystocele, with the posterior wall but little affected, and in the other case a marked rectocele with but little protrusion of the anterior wall. Protrusion of one or another vaginal wall accompanying procidentia uteri does not, however, necessarily constitute rectocele or cystocele, but such a situation indicates a more or less damaged structural condition of the walls and demands surgical repair.

True cystocele is a more common accompaniment of procidentia uteri than rectocele. Either may exist independent of procidentia, but if associated with procidentia they precede and do not follow. A cystocele therefore may exist with the cervix in normal position, likewise a rectocele may exist with the cervix in normal position. The case of Mrs. D., which I reported in my last communication on this subject, was a striking example of the first type, and the first case of rectocele to be here reported, a description of which constitutes the basis of my work on fascial lapping for the cure of rectocele, is an example of the second type.

FASCIAL LAPPING FOR RECTOCELE

The mucous membrane of the perineum is first removed and the rectovaginal fascia exposed. This fascia is incised at about where it merges with the perineum or its remaining structures. On incising the fascia a cellular area is entered, which area constitutes the line of demarcation between the rectum and the vagina. The cellular tissue encountered is now separated from the under

surface of the fascia, laterally to the borders of the levator ani and longitudinally to the region of the cervix. As the freeing of the tissue from the fascia is continued in the direction of the cervix a median longitudinal incision is made and extended as far as necessary.

The vaginal flaps are now prepared for lapping by first trimming them longitudinally to an apparently excessive degree. The extent of this trimming depends on the amount of redundant tissue or size of rectocele. Roughly speaking only about half of each flap remains and the effect produced after completing the operation is that of overcorrection.

The flap to the left of the operator is now carefully denuded of its mucous membrane. Scissors are used to make the denudation, as by careful use of them a thin submucous layer of tissue is left upon the fascia, which serves to maintain the fascial continuity of the flap. The flap thus remaining is relatively thick and resists the strain of the sutures better than the fascia alone would do.

The denuded flap is now severed crosswise at its highest point to the extent of about 1 centimeter in order to make a better fascial approximation when the flaps are lapped.

Four or more mattress sutures of chromic gut No. 2 are now used to anchor the denuded or underlapping flap to the opposite unyielding line where the fascia meets the lateral limits of the vagina. Four or more interrupted chromic gut sutures and a continuous suture are used to anchor the undenuded or overlapping flap to the opposite unyielding line along the side wall of the vagina.

When the rectovaginal flaps are anchored the perineal sutures are tied.

With rectocele, as with cystocele, we have a damaged condition in part or in whole of the fascial support. When this damage is not extensive and is limited to the perineal area, surgical approximation of the perineal portions of the levator ani muscles constitutes a sufficient barrier, but when an extensive rectocele exists, such as involves the entire posterior wall, or when the fascia has been torn away from each lateral wall, as in the second case to be cited, fascial lapping to the extent of the rectocele can alone be depended upon.

A rectocele may have associated with it taxing complications and the operative technique used must be modified accordingly as illustrated in the following case: Laceration of the perineal body through the sphincter ani, extensive lateral tears of the posterior vaginal wall, forming a sulcus on each side 4 centimeters or more in length and 2 centimeters in depth. The rectovaginal fascia was here torn away from the lateral walls and the posterior or rectovaginal wall bulged out like a tumor protruding from the vulva.

A crescentic incision was first made over the torn perineal area according to Ristine and the flap of tissue dissected down to the rectum and the skin border. The protruding pouch was next incised immediately above the crescentic incision and the rectovaginal cellular area entered. The line of cleavage from this point was followed laterally to the side walls and longitudinally beyond the limits of the pouch. A longitudinal incision was now made in the middle of the posterior wall, extending half its length. The flaps were trimmed longitudinally and the mucosa was completely removed from the sulcus and the flap to the left of the operator. The mucosa of the sulcus to the right of the operator was also removed, but the mucosa of the vaginal flap from this side was not removed. Several mattress sutures were inserted which when tied approximated the denuded surfaces of the sulcus to the right and anchored the denuded flap to the stable line, where the fascia normally meets the lateral limits of the vagina. The free margin of the undenuded flap was anchored to the opposite stable line along the side wall of the vagina. The mucous membrane edges were united with a continuous catgut suture. Two plain catgut sutures No. O penetrated each free end of the sphincter ani muscle to approximate and accurately adjust these separated ends. Silver wire sutures were placed in the perineum in the usual manner, one penetrating the free ends of the muscle. The results of this operation were not only a complete restoration of the sphincter and the perineal body, but a correction of the

rectocele and an elevation of the entire posterior vaginal wall to practically its normal position. Hysterectomy had previously been performed for procidentia according to the method herein described, a report of which operation will be found in the *New York Journal of Obstetrics*, June, 1917.

It was found necessary in the first case of rectocele here reported to keep a depressor in the space created by the separation of the rectum from the vagina in order to prevent the fat deposited in the cellular tissue from interfering with the proper adjustment and anchorage of the denuded flap when the sutures were tied.

Fascial lapping meets its ideal application in extensive rectocele and cystocele. When applying this principle to these conditions the several fascial areas which have been given special names have as such no particular value. When cystocele is present a greater portion of the bladder is enveloped by the overstretched anterior vaginal fascia than normally exists. The same is true of the rectum when rectocele exists and the surgical problem here presented is to restore the normal relationship of the viscera and fascia, and reinforce the supporting structure so as to form an effective barrier and support.

The most satisfactory approach to the line of cleavage between the bladder and the fascia is at the angle formed by the cervix and the anterior vaginal wall. As the incisions sweep around the cervix from above, they should be made to cut through both the mucosa and the fascia. The line of cleavage entered here is followed laterally to the limit of the vagina and then longitudinally to the region of the urethra. The longitudinal incision of the anterior wall is started in the median line below and continued upward as the bladder is separated from the under surface of the fascia.

When the vesicofascial line of cleavage is sought entirely through a longitudinal incision of the anterior vaginal wall it not infrequently happens that the line of cleavage between the mucosa and the fascia is mistaken for the line of cleavage between the fascia and the bladder, and as a result, the fascia is considerably injured in the effort to define and free the bladder. One of the great advantages of the fascial lapping technique here described, whether dealing with a cystocele or rectocele, is that the finding and following of only one line of fascial cleavage is necessary. When this line of cleavage only is followed a minimum amount of bleeding results, but when both lines of fascial cleavage are followed a maximum amount of bleeding occurs, which under certain conditions may terminate seriously. Another important advantage in thus utilizing the fascia, without disturbing its continuity, is that a minimum amount of disturbance in its circulation is occasioned, and when the flaps are anchored the circulation in them remains practically unimpaired.

Too much emphasis cannot be laid on the desirability of trimming the vaginal flaps to apparently an excessive degree. Failure will occur if the effect produced after the completion of the operation is not that of overcorrection.

THE EFFECT OF HYSTERECTOMY UPON OVARIAN FUNCTION[1]

By EDWARD H. RICHARDSON, M.D., F.A.C.S., Baltimore, Maryland
From the Gynecological Department of the Johns Hopkins University and Hospital

THE purpose of this communication is to present an analysis and impartial estimate of the existing evidence for and against retention of ovarian tissue after hysterectomy. Such a study seems both timely and desirable for two reasons: (1) because our knowledge of ovarian function has been substantially increased during recent years, chiefly through the intensive study of endocrinology, and (2) because there has arisen a sharp division of opinion among those most competent to decide this matter. One group is persistently advocating the routine conservation of healthy ovaries after hysterectomy, while a minority is vigorously condemning the practice as scientifically without justification. From a review of this interesting controversy it very soon becomes apparent that at least some of the conflicting opinions and a good deal of confusion has come about from failure fully to appreciate the scope and complexity of the problem involved. To avoid this it is absolutely essential to begin our study with a comprehensive and clear conception of whatever knowledge we have of the normal physiology of the ovaries. With this as a criterion we may then safely proceed to inquire, from anatomical and histological data, from experimental research, from observations based upon pathological physiology and from the evidence furnished by clinical statistics in what respects and to what degree total ablation on the one hand or conservation of ovarian tissue on the other alters our physiological composite.

THE FUNCTIONS OF THE OVARY

In the light of recent investigations and from a biological point of view, the only conception of the ovary which is tenable today is that it is a complex glandular organ possessing fundamentally a dual function. One of these relates to the phenomena of reproduction of the species, while the other is concerned primarily with the elaboration of one or more specific internal secretions. Let us examine the evidence upon which this conception is based.

Constituents of the normal human ovary. For the present we will omit a discussion of the stroma, the intrinsic nerves, the lymphatics and the blood-vessels, confining our attention to a consideration of the epithelial elements. These consist primarily of varying numbers of graafian follicles, with their contained ova. Secondarily, and originating from these, are the corpora lutea, degenerated or atresic follicles and possibly also, at least during pregnancy, the so-called interstitial glands.

The ovum appears to possess at least a twofold function. Meyer has shown that from the earliest development on to atresia the life of the follicle epithelium depends upon the vitality of the ovum; that the formation and development of the corpus luteum depends upon the maturation and expulsion of the ovum; and that if fertilization occurs, the ovum operates to prolong the life of the corpus luteum. In addition to this fundamental influence upon ovarian elements, the ovum possesses the all-important function of reproduction of the species, which process begins only after fertilization with the male element. In conflict with this generalization, however, are to be mentioned the observations of Loeb that the unfertilized ovum of the guinea pig may undergo limited development, even to the formation of the anlage of the central nervous system, while still in the follicle. But this is not of uniform occurrence and furthermore, such ova subsequently degenerate.

The corpus luteum is the most conspicuous element of the ovary. Its morphology and development from the collapsed follicle following rupture and expulsion of the

[1]Read before The American Gynecological Society, Philadelphia, May 16, 1918.

ovum have been exhaustively studied and repeatedly described by a number of investigators and need not be repeated here. The various phases of its life cycle are now universally agreed upon with one important exception, which has been made the subject of much study and of prolonged discussion — namely, the origin of the lutein cells, whether they arise from the theca interna, and are, therefore, of connective-tissue origin, or whether they develop from the cells of the membrana granulosa and, hence, are epithelial in nature. Both views have been ably championed. But particular mention should be made of the work of Sobotta and of Sandes on the lower animals and of the recent studies of Robert Meyer and of Novak on the very early stages of the human corpus luteum, because collectively these investigations appear to establish conclusively the correctness of the epithelial theory. Additional evidence, too, in support of this view is to be found in the pointed observation of Frank, that "from a physiological standpoint the corpus luteum behaves like an epithelial structure, and that the entire organism furnishes no example of a gland with either internal or external secretory function which develops solely from mesodermal structures." In connection with the morphology of the corpus luteum, it is important to emphasize two other facts which have been established through these intimate histological studies. One is that the corpus luteum undergoes constant change from day to day in its structure and appearance, first progressive and later regressive in character, indicating, of course, functional activity; the other is the remarkable prolongation of the life of the corpus luteum during pregnancy.

A third epithelial structure in the ovary which demands consideration is the atresic follicle. Relatively few follicles go on to full maturity, rupture, expel the ovum and terminate in corpora lutea. The vast majority of them undergo varying degrees of development usually approaching maturity, followed by gradual disintegration of the ovum and granulosa cells. Coincidently the cells of the theca interna enlarge, become epitheloid in appearance and persist for a considerable time in many species of animals (about 50 per cent of eighty species carefully investigated by Fraenkel), but in woman this occurs only during pregnancy. These are the so-called "interstitial glands."

Since numerically, at least, atresic follicles constitute the most important epithelial element in the ovary, and, further, since they appear to play no part either in menstruation or in reproduction, our ignorance regarding their function furnishes a strong argument for ovarian retention after hysterectomy.

Concerning the function of the other epithelial constituents of the ovary we are now in possession of considerable knowledge, thanks to the studies and experimental researches notably of Loeb, Fraenkel, Ancel and Bouin, Frank, Marshall, Heape, Hitschmann and Adler, Robert Meyer, Ruge, Schroeder, and others. Thus it has been shown that cyclical changes recur with methodical regularity both in the ovaries and in the uterus, and, further, that a definite correlation undoubtedly exists between these respective phenomena. In the ovaries there occurs in orderly sequence (1) follicle ripening, (2) ovulation and (3) corpus luteum formation. Co-ordinated with and dependent upon these ovarian changes there occurs in the mucous membrane lining of the uterus an equally interesting and orderly cycle consisting of (1) premenstrual hypertrophy and hyperplasia, (2) menstruation and (3) regressive changes, followed by a period of inactivity or rest. The evidence appears to be conclusive that these changes in the endometrium are brought about through the specific action of a chemical substance furnished by the corpus luteum. This remarkable structure, furthermore, has been definitely shown to inhibit ovulation, and by so doing it prolongs the sex cycle in lower animals. During pregnancy the life of the corpus luteum is greatly prolonged, and it has been shown to be essential to the early part of pregnancy, since it has a sensitizing action on the uterine mucosa, without which the ovum is unable to implant itself thereon. In all mammals there is a

striking coincidence between follicle ripening and the period of heat, which strongly suggests a stimulation of the sexual mechanism by a specific secretory product.

In addition to these important cyclical phenomena, which are concerned primarily with reproduction, the ovary is known to possess other functions of prime importance. Thus the normal growth and development of the generative tract, together with that of the whole group of secondary sexual characteristics occurring at puberty, are known to depend largely upon trophic influences of the ovary. Likewise, we know that it not only controls the development of the mammary glands but is responsible also for the cyclic changes which they manifest. Furthermore, abundant evidence, both experimental and clinical, is available to establish incontrovertibly the intimate and vital connection of the ovaries with other units of the endocrine system. Particularly is this true of the pituitary gland, the thyroid gland and the adrenal glands. Recent reviews of the studies supporting this assertion have been published respectively by Goetsch, by Marine and by Vincent. Less convincing but highly suggestive are the observations pointing to a possible functional interrelationship between the ovaries and both the parathyroid and pineal glands. The same is true of the possible part played by the ovaries in the general metabolism of the body. Certainly no one can at present deny the possibility, at least, of the participation of ovarian influence in these several directions also. Finally, the equilibrium of the nervous system in the human female, both in the psychic domain and particularly in that of the autonomic constituent, appears to depend exquisitely upon the integrity of the ovaries.

Many interesting and valuable data have been purposely omitted from this brief summary, but we may safely accept what has been said as supplying the physiological composite of ovarian function necessary for the purposes of this study. It strikingly emphasizes at least two facts — namely, that the ovary is a vitally important biological unit, which is constantly playing an important rôle in the body economy, and that its influences are unmistakably discernible far afield from the domain of the reproductive system of which it constitutes so important a part. No more conclusive clinical demonstration of the far-reaching influence of ovarian activity could be reasonably desired than that furnished by the phenomena occurring with menstruation, and with the physiological as well as the artificial or surgical menopause.

A careful comparison of the symptomatology associated with these three conditions reveals the surprising fact that they differ from each other chiefly in degree and rate of development. This fact does not appear to be generally recognized. On the contrary, the numerous references to these varied symptoms encountered in the literature leaves one impressed with the chaotic and confused state of mind which now exists regarding them. There is manifest need of a scientific classification of these vexing phenomena, and, in hopes that an effort in this direction may stimulate discussion and eventually lead to a satisfactory co-ordination of them, I have undertaken, from authoritative sources, first to tabulate and then to classify them. It seems rational to divide them into two great groups: (1) those which arise within the domain of the autonomic nervous system, and (2) those originating in part from activation or sensitization of the spinal reflex arc, and in part from the higher cortical cells of the brain, which collectively constitute the psychic domain.

I. Symptoms from the domain of the autonomous nervous system.
   1. Vasomotor.—Hot flushes; headaches; dizziness; vertigo; fainting; dermatographia; urticaria; erythemata; cold hands and feet.
   2. Cardiac.—Palpitation; tachycardia (mild with normal heart).
   3. Gastro-intestinal (motor and secretory).—Digestive disturbances with flatulence, eructation, nausea and occasional vomiting; stasis; meteorism; constipation; diarrhœa.
   4. Urinary.—Irritable bladder; polyuria.

5. Endocrine.—Thyroid; hyper- and hypo-function; pituitary — e.g. obesity; adrenals — e.g. hypotension; gonads — e.g. changes in libido sexualis, voluptas and secondary sexual characteristics — e.g. voice, body conformation, countenance, facial hair, breasts, and external genitalia.
6. Sweat glands — e.g. sudden sweating.

II. Psycho-Neurotic Symptoms.

1. Psychic.—Fatigability, mental and physical; emotivity; hypersensitiveness; irritability; changed temperament; anxiety and apprehension; insomnia; excitability; hysteria; psychoses; depression; apathy and indifference; lack of energy; impaired memory; aphasia; indecision; self-condemnation; suicidal ideas;
2. Neurotic. — Exaggerated reflexes; tremors and epigastric quivering; visual and auditory disturbances; lowered muscle tonus; paræsthesia.

This classification is merely tentative. It seems to me, however, to be rational, simple and reasonably comprehensive, since it certainly embraces most of the disturbances associated with menstruation and the menopause, whether normal or artificial. It is incorporated in this study to help emphasize the close relationship which exists between the clinical syndromes of these epochs in a woman's life and to accentuate further the scope and complexity of ovarian influence.

We are now in a position to inquire in what respects and to what degree ovarian function, as detailed above, is impaired or disturbed by surgical removal of the uterus.

Anatomical and histological data. From this source we will first inquire whether an adequate arterial and venous circulation of the ovary is assured by the technique commonly employed in the surgical removal of the uterus, particularly when the operation includes removal of the fallopian tubes. The studies on this point of Keitler, Werth, Olshausen, Polak, and particularly of Sampson, show that the blood supply to the ovary from the uterine artery and the drainage from the ovary through the uterine veins is cut off in doing hysterectomy; that the danger to the ovarian circulation is greatly increased through salpingectomy; and finally that failure to recognize these anatomical points is responsible for a large percentage of degenerated ovaries following these operations. I feel that this last point should be stressed, because I am convinced that many of us have jeopardized the function of a conserved ovary through unnecessary surgical damage to its circulation.

We next wish to know from the data under consideration what has been learned from subsequent gross and microscopic examination of human ovaries regarding their ultimate fate after hysterectomy. Unfortunately, the available information on this point is meager, and one must be extremely cautious about drawing conclusions from it. Vineberg, in 1915, was able to glean from the literature and through personal communications reports of only 28 cases of second operations for disease of retained ovaries. In the majority of these the primary operation had been of such a capital nature as to make it highly probable that the ovarian circulation was subjected to unusual traumatism, and at least four of them were associated with malignant disease of the uterus. Graves reported two cases of cystic degeneration and one of papillary cystadenoma found at second operation upon retained ovaries. He adds that he has frequently removed ovaries which had been retained at a previous hysterectomy and in every instance found them densely adherent, degenerated and cystic. On the other hand, Vineberg removed one of two normal-looking ovaries sixteen months after abdominal hysterectomy and found it normal microscopically. Grammatikati examined the ovaries of a woman who died three years after a panhysterectomy for cancer and not only found no evidence of degeneration, but observed follicles in all stages of development. Glaevecke observed two cases six months after hysterectomy and found the ovaries normal in both of them. Weber studies fifteen ovaries obtained long after the menopause and found in four of them follicles in various stages of development, and in one instance a corpus luteum.

The inference from this evidence is that the uterus is not essential to a continuation of ovarian function, and that when ovarian degeneration follows hysterectomy it is to be attributed either to associated ovarian disease or to damaged ovarian circulation or to both of these factors.

Experimental data. Grammatikati was the first to study experimentally the effect of hysterectomy upon the ovaries. He used rabbits for this purpose, and found after an interval of three or four months that microscopic examination of the ovaries showed them to be normal in every detail. Mandl and Buerger incorporated in the most comprehensive monograph that has been published on this subject the results of a much more elaborate experimental study made upon rabbits and apes in which an interval of eight months to three years was allowed to elapse between the removal of the uterus and the subsequent examination of the ovaries. They were able to detect only slight evidences of congestion which they thought possibly interfered slightly with the function of the organ.

Similar results were obtained in experiments by Burckhardt and by Keitler. Martin concluded, from his excellent reviews of the voluminous literature on ovarian transplantation, that autotransplantation of ovarian tissue retards and modifies the symptoms of the artificial menopause precipitated by castration in a definite number of cases, depending undoubtedly upon the graft retaining its vitality. So that the available experimental evidence completely demolishes the theory of an essential physiological interrelationship between the uterus and the ovaries, and demonstrates conclusively that ovarian function, in part, at least, proceeds uninterruptedly after hysterectomy.

The data from clinical studies. Since 1899 when the question of ovarian retention after hysterectomy first received serious consideration, a voluminous literature has accumulated embodying the results of numerous clinical investigations of this problem. Mandl and Buerger's exhaustive monograph contains an excellent review of the earlier contributions, while helpful later bibliographies will be found appended to the more recent articles of Schickele, Walthard, Vineberg, Graves and Culbertson. In reviewing this literature one experiences disappointment over the conflicting opinions met with regarding a number of the points which must be determined from clinical data. I will summarize the results of a few of the most important statistical studies that have been made.

Mandl and Buerger, in 309 cases of total ablation, observed menopause symptoms in 80 per cent. Of these, 49 per cent developed symptoms very promptly after operation. Of 96 cases with retention of one or both ovaries 68 per cent subsequently developed what these authors style as "symptoms of a general nature." In 23 per cent of these the symptoms were only periodic, which they interpret as an indication of functionating ovaries. The sexual function was impaired in 42 per cent of the total ablation cases and in only 18 per cent of the retention cases. The incidence of postoperative obesity, trophic and psychic disturbances, were not strikingly different in the two groups, but the variations observed were uniformly in favor of the retention cases.

Mainzer concluded from his studies that the removal of normal or slightly diseased ovaries causes especially stormy ablation symptoms, and that while retention may not always prevent the later development of symptoms, these are mild and of the menstrual type. He saw no case with retention exhibit the severe syndrome following total ablation.

Burckhardt noted the appearance of menstrual molimina in 22 per cent of his retention cases. Ablation symptoms developed in about one-half of the cases both with retention and total ablation. The sexual function was favorably influenced by retention. He saw no injury to the health of patients from retention and advocated it in order to ameliorate the later menopause syndrome.

Werth, from his exhaustive study of 118 cases, of which 35 were instances of ovarian retention, advocated retention not only before but after the menopause age. He vigorously attacks the idea of frequent oc-

currence of ovarian tumors from retained ovaries, and concludes that the ovary has an important function in the body economy which warrants its retention in spite of certain clinical objections.

Glaevecke attributes the disturbances observed in retention cases to operative injury of the ovary or to coexisting disease. He considers it established that ovulation continues to the normal menopause in retention cases.

Leopold and Ehrenfreund studied 151 cases of hysterectomy on account of myomata, 43 of which were examples of ovarian retention. Of these 50 per cent had disturbances, in one-half of which the symptoms appeared before the climacteric age. They observed no alteration of the sexual function and no trophic disturbances.

Dickinson from a careful study of 131 cases of ovarian retention after an interval of six months and over subsequent to hysterectomy concluded that 80 per cent were free from menopause symptoms; that the results were better in cases with retention of both ovaries than with only one or than after resections; that the disturbances met with were more gradual and less severe than after total ablation; and that retention in operations for pelvic infections is relatively less satisfactory. He condemns the removal of healthy ovaries at or near the time of the menopause, since the exact period of ovarian activity is unknown. He has not had to reopen an abdomen when a conservative operation was done.

Graves last year reported his findings in a postoperative statistical study of 233 cases of total ablation and 26 cases of ovarian retention after hysterectomy. His clinical data appear to have been obtained through letters of inquiry sent to patients with reference particularly to one symptom — namely, hot flushes. This symptom he chose as a standard, and found it in 80 per cent of the total ablation cases and 81 per cent of the retention cases. He states that it was reported by many patients who had passed the natural menopause at the time of the operation, and he considers this fact evidence that the ovary retains its influence as a secretory organ long after ovulation ceases. But in spite of this admission of continuation of ovarian function long after cessation of uterine function, he contends that normal ovarian function is dependent upon a vital physiological connection between the ovary and the uterus. Hot flushes he seems to regard as tantamount to cessation of all ovarian function and, employing this arbitrary standard throughout his study, he reaches the remarkable conclusion that retention of ovarian tissue after hysterectomy is of little or no physiological value.

Such radical teaching should not be permitted to stand unchallenged, especially when it rests upon so insecure a foundation as clinical data compiled from letters of inquiry and classified according to the incidence of hot flushes, upon the unique assumption that this symptom alone may be safely accepted as a reliable and scientific indication of the varied and complex activity of the ovary.

Graves supports his advocacy of total ablation by citations respectively from Walthard and his associates, from Schickele and from Konstantinidis, to the effect that menopause symptoms occur with equal frequency in cases of retention and of ablation. But a careful examination of these several reports shows that in them it was not the purpose of any of these authors to advocate total ablation. Thus, Schickele says a "vasomotor symptom-complex" occurs in retention cases as often as in ablation ones. He insists, however, that these phenomena shall be designated as "retention symptoms" in the cases with retained ovaries, in contradistinction to the "ablation symptoms" of cases with complete removal of ovarian tissue. He states, further, that the retention symptoms need to be further studied. The inference, of course, is that he recognizes differences between the two clinical syndromes, an observation which certainly does not support the theory of total ablation.

Walthard, while at Berne, Switzerland, through the influence of Professor Paul Dubois, became enthusiastically interested in the psychoneurotic side of gynecological patients. His report includes three extremely interesting tables. The first one shows that

of 64 cases studied prior to removal of their pelvic organs, seven commonly recognized ablation symptoms were found in percentages varying from 14 to 46. The second table shows that after a period of at least one year subsequent to total ablation of the pelvic organs, in 51 of these same cases examined the seven ablation symptoms were found to have completely disappeared in from 7 to 23 instances. The third table shows that of 65 cases with normal genital organs, and free from any other organic disease, nine of the common ablation symptoms were demonstrable in percentages varying from 44 to 64. The age of the patient was found not to be a factor in any of the groups studied. Walthard concludes from this investigation that the so-called ablation symptoms are neither the direct necessary result of any genital disease nor of the loss of internal secretion of the ovary, nor of the loss of the genital function. He considers them due to a hypersensitive nervous system and psychoneurotic in origin. Whether we agree with him or not, his report certainly cannot be considered as supporting total ablation. It does, however, strikingly emphasize the caution which must be observed in the present state of our knowledge in drawing conclusions regarding ovarian function from the incidence of one or more so-called ablation symptoms.

Finally, Konstaninidis reported a postoperative study of 100 cases of hysterectomy with retention of both ovaries and 34 cases with retention of one ovary. One sentence from his summary states that of these 134 cases, one-half showed more or less vasomotor, nearly one-third trophic and about one-seventh psychic disturbances. This sentence has been used by the advocates of total ablation to support their contention. But a careful reading of the full report shows that it cannot be justly so construed.

Of the one-half with vasomotor disturbances, in only 37 per cent of them were these symptoms severe, and nearly one-half of these were furnished by the group from whom one ovary had been removed. Of the one-third exhibiting trophic disturbances, by which the author means a slight tendency to adiposity, only 23 per cent were found in the group in whom both ovaries had been retained. Furthermore, a majority of all the patients showing this tendency to adiposity were at the normal menopause age. This study, therefore, argues eloquently for ovarian retention.

These citations represent fairly the available clinical data and suffice to illustrate the conflict of opinion and confusion which such studies have brought about. The truth of the matter is that no clinical investigations have been made with proper regard for all of the various factors which in reality determine the fate of retained ovaries, and without knowledge of which one cannot possibly estimate with any degree of accuracy to what extent hysterectomy has disturbed their function. These factors are (1) a knowledge of the individual patient's condition prior to hysterectomy, both in the psychic domain and in that of the autonomic nervous system as already outlined; (2) the cases must be grouped according to age both at the time of operation and at the time of subsequent observation; (3) they must be grouped according to the pathology for which the operation was performed; and (4) with reference to the operative technique, whether or not proper measures were used to safeguard subsequent ovarian circulation.

CONCLUSIONS

1. The ovary is a glandular organ of complex function, our knowledge of which is at present far from complete.

2. The uterus is not essential to a continuation of ovarian function, except as regards menstruation and reproduction.

3. The advocates of total ablation have not furnished convincing evidence of the correctness of their contention.

4. The disturbances of ovarian function attributed to hysterectomy are partly those associated with normal menstruation and partly those arising from damage to the ovary through operative trauma or disease.

5. The weight of evidence furnished by anatomical, experimental, and clinical investigations is overwhelmingly in favor of retention of sound ovaries both before and after the menopause age.

BIBLIOGRAPHY

ANCEL, P., and BOUIN, P. Compt. rend. Soc. de biol., 1908, lxv, 365; 1909, lxvi, 454, 505, 605, 689; J. de physiol. et de path. gen., 1910, xii, 1; 1911, xiii, 31.
BELL, W. BLAIR. The Sex Complex. London: 1916.
BURCKHARDT. Zentralbl. f. Geburtsh. u. Gynaek., vol. xliii.
CULBERTSON, C. Surg., Gynec. & Obst., 1916, xxiii, 667.
DICKINSON, R. L. Surg., Gynec. & Obst., 1912, xiv, 134.
FRAENKEL, L. Arch. f. Gynaek. 1903, lxviii, 438; 1905, lxxv, 443; 1910, xxci, 705; 1913, xcix, 225.
FRANK, R. T. Arch. Int. Med., 1910, vi, 314; Tr. Am. Gynec. Soc., 1911, xxxvi, 269.
GLAEVECKE. Arch. f. Gynaek., 1889, xxxv, 1.
GOETSCH, E. Surg., Gynec. & Obst., 1917, xxv, 229.
GRAMMATIKATI, J. Zentralbl. f. Gynaek., 1889, xiii, 105.
GRAVES, W. P. Surg., Gynec. & Obst., 1917, xxv, 315.
HEAPE, W. Tr. Obst. Soc., Lond., 1899, xl, 161; Proc. Royal Soc., 1905, lxxvi, 260.
HITSCHMANN, F., and ADLER, L. Monatschr. f. Geburtsh. u. Gynaek. 1908, xxvii, 1; Arch. f. Gynaek., 1913, c, 233.
KEITLER. Monatschr. f. Geburtsh. u. Gynaek., 1904, xx, 686.
KONSTANTINIDIS, G. Inaugural Dissertation, Jena, 1909.
LEOPOLD and EHRENFREUND, F. Beitr. z. Geburtsh. u. Gynaek., Festschr. f. Chrobak, 1903.
LOEB, L. J. Am. M. Ass., 1911, lvi, 1327.
LOEB, L. Surg., Gynec. & Obst., 1917, xxv, 300.
MAINZER, F. Arch. f. Gynaek., 1897, liv, 421.
MANDL, L., and BUERGER, O. Die biologische Bedeutung der Eierstoecke nach Entfernung der Gebaermutter. Leipsig and Vienna: F. Deuticke, 1904.
MARINE, D. Surg., Gynec. & Obst. 1917, xxv, 272.
MARSHALL, F. H. A. The Physiology of Reproduction.
MARTIN, F. G. Tr. Am. Gynec. Soc., 1915, xl, 32; Surg. Gynec. & Obst. 1917, xxv, 336.
MEYER, R. Arch. f. Gynaek., 1911, xciii, 354; 1913, c, 1.
NOVAK, E. J. Am. M. Ass., 1916, lxvii, 1285.
OLSHAUSEN, R. Ztschr. f. Geburtsh. u. Gynaek., vol. xliii; Zentralbl. f. Gynaek., 1902, xxvi, 1.
POLAK, J. O. J. Am. M. Ass., 1917, lxix, 1938.
RUGE, C. Arch. f. Gynaek., 1913, c, 20.
SAMPSON, J. A. Tr. Am. Gynec. Soc., 1916, xli, 429.
SANDES. Cited from R. T. Frank.
SCHICKELE, G. Monatschr. f. Geburtsh. u. Gynaek., 1912, xxxvi, 80; Lewandowsky's Handbuch der Neurologie vol. iv, Spezielle Neurologie, iii, 434.
SCHROEDER, R. Arch. f. Gynaek. 1915, c, iv, 27.
SOBOTTA, J. Arch. f. mikr. Anat., 1897, xlvii, 261.
VINCENT, S. Surg., Gynec. & Obst., 1917, xxv, 294.
VINEBERG, H. N. Tr. Am. Gynec. Soc., 1915, xl, 59.
WALTHARD, M. Zentralbl. f. Gynaek., 1908, xxxii, 564; 1912, xxxvi, 489.
WEBER, A. Monatschr. f. Geburtsh. u. Gynaek., 1904, xx, 973.
WERTH, R. Klin. Jahrb., 1902, ix, 529.

PATHOLOGY OF GOITER

BASED UPON SPECIMENS RECEIVED AT THE STATE INSTITUTE FOR THE STUDY OF MALIGNANT DISEASE, BUFFALO, NEW YORK

BY BURTON T. SIMPSON, BUFFALO, NEW YORK
Pathologist

IN writing upon the pathology of goiter, it seemed to me to be a good plan to classify all the thyroid specimens which came into the laboratory for diagnosis. This ought to give a fair pathological classification especially for the immediate region of Buffalo, from which we naturally receive the majority of our specimens. As is well known, the term "goiter" is a purely clinical one and is usually given to any permanent enlargement of the thyroid gland.

The classification which I have indicated below seems to embody all the pathological conditions in which we find enlargement of the gland.

CLASSIFICATION

Simple goiter.
- A. Physiological
- B. Toxic

Multiple adenomata.
- A. Cystic
- B. Solid

Colloid goiter.

Exophthalmic goiter.

Neoplasms.

Acute or chronic inflammations are not included in this classification. The specimens received at the laboratory may be almost entirely put into the last four divisions. Simple goiter usually does not come to operation, especially in the early stages, and moreover, many of these cases either recover spontaneously or are amenable to medical treatment.

There are, especially in Europe, in the mountainous regions, areas or districts which are known as "goitrous districts" in which the so-called endemic goiter is very common.

In these places a large proportion of the population are affected by markedly enlarged thyroids. Buffalo, in common with other cities on the southern borders of the Great Lakes, is considered a goitrous region although we have only the incipient endemic goiter and rarely as marked as that common in the European goitrous regions.

Under the clinical term "goiter" we have grouped five distinct and separate diseases. The only thing which they really have in common is the enlargement of the thyroid gland, this being the usual sign for which the medical man is consulted.

I wish to take up each group, speaking briefly concerning the etiology, gross and microscopic pathology. It might be well to review briefly the histology of the thyroid gland. The thyroid gland takes its origin from the upper, anterior portion of the gut tract, being, therefore, derived from the endoderm. The gland consists of two lateral lobes connected by an isthmus. It has a thick connective-tissue capsule which sends down trabeculæ which divide the gland into lobes and lobules. The unit of the thyroid gland is the follicle, a little sac which is lined with a single layer of low columnar epithelium, the basal ends of which come into intimate contact with capillary blood-vessels, the lumen of these little sacs or vesicles being usually filled with colloid material, the active secretion of the thyroid cells. The follicles are surrounded by a rich network of lymphatics into which many authorities believe the secretion may be thrown, although by others it is believed the secretion is absorbed directly into the blood stream. These follicles do not communicate with each other but are grouped into lobules by connective tissue and surrounded by trabeculæ sent in from the capsule.

SIMPLE GOITER

The first group, simple goiter, may be divided into a physiological simple goiter and toxic simple gotier, using the word toxic in an etiological sense.

Physiological simple goiter is the term applied to the temporary enlargement of this gland which occurs at puberty, during menstrual periods and especially in pregnancy. The exact cause of this enlargement is not known but the mechanism of the enlargement is usually due to vascular dilatation. It probably has some relation to the sympathetic system. The gland is slightly enlarged, smooth and usually symmetrical. This enlargement is generally only temporary but repeated physiological enlargement may lead to simple goiter which is accompanied by true hyperplasia, probably due to repeated irritation and increased blood supply.

Toxic simple goiter is that variety of true goiter which occurs with such frequency in certain mountainous regions and is usually designated as "endemic goiter." It is also the type which we see in younger people along the cities of the Great Lakes. Marine has made a study of the girls of the schools of Akron, Ohio, examining the thyroids of 3,872 from the fifth to the twelfth grades, ages averaging from twelve to seventeen, and found that 56 per cent showed enlargement of the thyroid gland. This is the type of simple goiter which occurs in Buffalo and its environments. Among the chief theories for its causation may be mentioned especially those of Bircher and of McCarrison, each of which we will briefly allude to. There are two factors in the etiology of goiter that nearly all authorities are agreed upon, that is, first, the relation of drinking water to goiter and, second, an especial susceptibility of some thyroids to certain influences. One of the older theories and one that was accepted for some time was that of Bircher, who believed that the changes in the thyroid gland were due to toxic material which he took to be a chemical of a colloid nature and was associated with water of the so-called goitrous wells or streams which nearly always spring from certain of the older geological strata. This water originated or passed through certain organic sediments deposited in these layers. H. Bircher, when examining recruits in military service, noted that certain groups of individuals from certain districts showed enlargement of the thyroid gland. After the war he investigated these districts and noted the relation to the drinking water. He also observed in a neighboring town the great difference in the prevalence of goiter on either

side of the stream which ran through this town, people on the right bank having 80 per cent of goiter while on the left bank only about 2 per cent. The water supply was obtained from different sources. By changing the supply of the high goitrous district and obtaining water from the other side of the stream, the goiter incidence was reduced to 2 or 3 per cent. He found that these so-called goiter wells or streams had their origin in certain geological strata as mentioned above. His son, Eugene Bircher, carried on animal experiments, especially with rats and found that by feeding these rats upon drinking water from the so-called goitrous wells, he was able to produce enlargement of the thyroid gland in these animals.

The second theory is that of McCarrison, who worked in the region of the Himalaya Mountains in India. McCarrison made extensive investigations in a goitrous district and came to the conclusion that the thyroid changes were due to toxic substances of infectious origin and that the chief seat of the infection was to be found in the intestinal tract. His experiments are very convincing. He was able to produce enlargement of the thyroid gland by feeding fæcal matter from goitrous people to animals. He also fed the precipitate on Berkefeld filters which was obtained by filtering water from goitrous wells, to humans, producing thyroid enlargement and was successful also in curing certain cases by the use of intestinal antiseptics, as thymol, salol, etc. McCarrison speaks of several cases of enlarged thyroid which were caused to disappear by operative procedure on intestinal conditions, especially in Lane's kinks, etc. One remarkable case which he reports cured by this means was in a girl with a severe case of exophthalmic goiter. While McCarrison isolated anaerobic organisms from the intestinal canal in goitrous patients, and had some success using this organism as a vaccine, he does not claim to have found a specific organism but thinks that organisms of the colon group may be largely responsible.

Marine, who has done extensive work on the thyroid gland, especially on the lower animals, believes that the enlargement of this organ in simple goiter is often associated with the lack of ability of the body to get iodine or to assimilate the same; and that, therefore, the thyroid gland hypertrophies to compensate for this condition.

Simple goiter occurs at any age but is more frequent between the ages of twelve and twenty, and while this condition occurs in males, it is much more frequent in females. The gland is usually small, symmetrical and smooth; although either lobe may be enlarged over the other or the enlargement may be located in the isthmus. Microscopic examination shows a hyperplasia, that is, an increase in all the constituents and also a new formation of vesicles. This increase is symmetrical. While the epithelium becomes high cuboidal or columnar, still there is no tendency to papillar formation or an increase in the layers lining the alveoli. The colloid material is usually increased and stains more deeply than in the normal thyroid gland. It is to this type of thyroid enlargement that the name of goiter properly belongs.

MULTIPLE ADENOMATA

By far the greatest number of the enlarged thyroids received at the laboratory with the diagnosis of "goiter" is really true tumor formation. Whether or not true statistics of all cases of enlargement of this organ would show that the majority comprises the group of multiple adenomata, or if this form is the most frequently operated upon, nevertheless, the fact remains that 65 per cent of all enlarged glands received at the laboratory are of this type. It is a true tumor formation and is usually multiple. The accepted etiological factor is that these tumors spring from remnants of ducts which it is supposed were to be found in the organ, when, in former times, it was a duct gland. It is easy to find these remnants of ducts, with their high columnar epithelium, in thyroids of the newborn. While these nodules or adenomata may appear at any time after birth, they usually are to be found at puberty and make their appearance at this time, and gradually enlarge, until at the age of thirty or thirty-five years, they become marked goiters.

It is interesting, with the knowledge which

we have of the frequency of this type of enlargement, to read in various treatises on the thyroid, how the author dismisses this type of pathological condition, apparently with a wave of the hand, with the remark that sometimes Wolfler's fœtal adenomata are to be found in the thyroid gland and this is especially striking when as a matter of fact Aschoff in his lectures, claims that he can find these adenomata in the thyroid gland of every individual who comes to autopsy from the region of Freiburg in Breisgau. The writer found them in 80 per cent of two hundred consecutive autopsies in this region.

This type may be divided into two histological classes: the cystic and the solid.

It is to this variety of enlargement of the thyroid gland that we have the many different names, as cystic goiter, fibrous goiter, hæmorrhagic goiter, etc., and is only in this variety that the conditions exist which give rise to these various names. The tumor mass is usually irregular and nodular and for this reason has been given the name of "struma nodusa." Early this form may be confused with simple goiter, and later, the cystic variety may be confused with colloid goiter. Section of these enlarged thyroids show all the so-called "degenerative changes" and various colors which are due to hæmorrhagic changes and calcareous infiltration. One can follow the growth of these tumors from the small nodules to the large diffuse adenomata or cystic areas. They are differentiated from all other forms of enlargement of the thyroid gland by the distinct nodular tumor masses even though they be cystic and colloid. All other forms of goiter still retain the characteristic lobular form of the gland, the pathological areas being separated by trabeculæ, while the true tumor formation shows no trabeculæ dividing them into lobules. In some cases the surrounding thyroid tissue becomes compressed, forming capsules to these nodules.

The cystic variety is composed of large vesicles filled with colloid material, the secretion of the tumor cells, and as lymph vessels are not contained in these tumors, there is no absorption of this colloid secretion, which thereby accumulates and forms cystic structures and in this way may resemble the colloid goiter. Also in this variety, probably due to the effect of secretory materials on the smaller vessel walls, there is great tendency to hæmorrhage.

The solid variety is very cellular with high columnar epithelium containing very little colloid material. As these adenomata increase in size, they always show degenerative changes at the center, the tumor cells undergo necrosis and their places are taken by newformed connective tissue which soon undergoes especially hyaline degeneration. In some cases the epithelium proliferates irregularly and no doubt these cells secrete material which gives toxic symptoms, for our statistics show that 3 per cent of the enlarged thyroids diagnosed as "exophthalmic goiter" showed, upon microscopic examination, to be very cellular adenomata.

COLLOID GOITER

Nineteen per cent of the specimens received were colloid goiter. Colloid goiter might be designated as a passive enlargement of the thyroid gland, it being simply a collection of colloid material, filling the alveoli until their walls become very thin and sometimes rupture into each other. It is considered that colloid goiter is really a healed goiter, that is, at one time the thyroid gland was the seat of either thyroiditis, simple goiter, exophthalmic goiter or some other pathological condition; and the cause of these being eliminated, the active process ceased and the cells continued to secrete colloid material but the absorption of this apparently is interfered with and it accumulates in the alveoli.

These goiters are large and symmetrical with a smooth surface. Cut surface shows large alveoli filled with colloid material. Microscopically the alveoli are large, filled with thick colloid material. The epithelium is compressed and flattened. In this type of enlarged thyroid we do not find the so-called degeneration or evidence of hæmorrhage, and the lobular arrangement, while greatly enlarged, is still preserved by the trabeculæ.

EXOPHTHALMIC GOITER

Eight per cent of the specimens were exophthalmic goiter. There is considerable controversy concerning the etiology of this

disease, the main question being whether the disease is primary in the thyroid gland or primary in the nervous system, especially the sympathetic. Crotti, after a careful and elaborate discussion of the observations and experiments in this disease, concludes that the disease is primary in the thyroid gland, being a toxic irritation from infectious toxins from various sources, as the intestinal tract, pyorrhœa, tonsillitis, or other chronic infections. He does not, however hold that there is a specific organism. He speaks especially of a vicious circle, that is, the infectious toxin stimulates the thyroid to throw out its secretion which stimulates the sympathetic nervous system which in turn stimulates the thyroid again, in this way forming the so-called vicious circle. An interesting observation is that exophthalmic goiter is uncommon in regions where simple goiter is endemic.

The thyroid gland is not greatly increased in this disease. It is usually symmetrical but may be more marked in one lobe. In some cases the gland may not be clinically enlarged but in every case there is a specific pathological picture of hyperplasia of the gland. Cut surface reveals compact areas, grayish in color, and shows no exudate. Histologically, the alveoli are increased in size and number and become very irregular in shape. The epithelium is high columnar and may be several layers thick and with marked tendency to papillar formation, which is almost pathognomonic for this disease. Colloid material is decreased and may be entirely absent from the follicles, but when present stains rather faintly.

NEOPLASMS

I have added the neoplasms because 4 per cent of all the thyroids received show malignant disease. While the thyroid may be the seat of benign tumors, as fibromata, chondromata, etc., these tumors are the same as occur in other parts of the body, springing from the mesoblastic tissue. Sarcoma is not rare and is usually of the spindle-cell variety, and springs from the connective-tissue element. It is no more specific for the thyroid than for other tissues of the body and usually originates in a normal gland, in younger persons.

Ninety per cent of the carcinomata spring from pre-existing goiter and occur in individuals past forty. One should be suspicious of malignant change when a goiter in a person past forty suddenly begins to enlarge in size. Malignant epithelial tumors of the thyroid gland have a great tendency to metastasize in bone. It is also possible to have metastatic thyroid tumors from enlarged thyroids which do not give a histological picture of malignancy.

DISCUSSION

In reading various articles upon goiter one is struck by the apparent lack of uniformity in the classification of these conditions. As I have said, goiter is a clinical term and is sometimes employed indiscriminately to any enlargement of this organ. It is the opinion of the writer that much confusion exists by the classification of various distinct processes under one head, especially in goitrous regions, and by statistics upon the collection of these various conditions. It is well to keep in mind that simple goiter is probably a toxic hyperplasia of the thyroid gland in younger people, especially females, and occurs between the ages of twelve and twenty. This process in the majority of cases spontaneously recovers but may continue and may reach the colloid healed state. At about the age of twenty the adenomata proliferate in the thyroid gland and begin to evidence themselves by the appearance of marked enlargement of the gland, and from twenty to forty we have the adenomata type of enlargement. This may occur in glands which have been the seat of simple goiter or may occur in glands which have been apparently normal. So we may, therefore, have, before twenty, the simple goiter and after twenty, colloid goiter or adenomatous goiter. Exophthalmic change may occur in the normal gland, in the gland, the seat of simple goiter, in colloid goiter or in adenomatous goiter.

RECAPITULATION

To recapitulate briefly, the specimens of enlarged thyroids which come to the laboratory for diagnosis can be classified into five groups, namely: simple goiter, multiple

adenomata, colloid goiter, exophthalmic goiter, malignant neoplasms.

These are all characterized by the common factor of enlargement of the thyroid but otherwise differ markedly from one another. They may be differentiated clinically in nearly all cases by careful examination which seems to be desirable for the selection of proper treatment. The physiological simple goiter is simply a vascular dilatation and is goiter only in the sense of the enlarged gland which, however, is often only of temporary duration.

Simple toxic goiter is an enlargement of the thyroid gland due to a symmetrical hyperplasia of all the structures of the thyroid and without the clinical evidence of toxic symptoms, most probably caused by toxic factors. This form which is usually called endemic goiter is almost always associated with drinking water which probably has to do with carrying the infection or toxin.

Multiple adenomata is the most common cause of thyroid enlargement in our vicinity, at least so far as our statistics show, which are, of course, based upon operative material sent in to the laboratory. It is a true tumor formation, beginning probably in remnants of embryonic ducts occurring about the age of puberty. These tumors start as minute adenomata in different parts of the gland and gradually increase in size causing the nodular form seen in later life and having a great tendency to the so-called degenerative changes which give this form of enlargement its numerous names. It is well to remember that these adenomata when very cellular may give toxic symptoms and thereby become confused clinically with exophthalmic goiter.

Colloid goiter is simply a passive accumulation of colloid material in the dilated alveoli and it is usually considered as a healed state of some previous pathological condition of the thyroid gland.

Exophthalmic goiter, even if it be not of primary thyroid origin, has its specific pathognomonic histological picture, and there can be no doubt of the toxic effect of the excessive secretion of this gland.

The neoplasms really ought not to be included in a goiter problem and are only included here because they make up a part of the enlarged thyroids received at the laboratory.

In closing, I would draw your attention to the fact that 5 per cent of the thyroid specimens received at the laboratory showed a combination of some of these lesions, that is, colloid goiter may show adenomata and a large adenomatous goiter may show areas of true Grave's disease. Considering this fact it may explain that certain unfavorable results in operative procedure may be due to leaving part of an area of exophthalmic goiter in the removal of an adenoma or of a colloid lobe.

REFERENCES

1. Aschoff. Bemerkungen zur Strumafrage. Deutsch. med. Wchnschr., 1910, No. 12.
2. Bircher, H. Der endemische Kropf, etc. Basel, 1883.
3. Bircher. E. Zur Frage der Kropfatiologie. Deutsch. med. Wchnschr., 1910, xxxvi, 1705.
4. Idem. Zur experimentellen Erzeugung der Struma zugleich ein Beitrag zu deren Histogenese. Deutsche Ztschr. f. Chir., 1910, ciii, 267.
5. Idem. Weitere Beitraege zur experimentellen Erzeugung des Kropfes, etc. Ztschr. f. exp. Path. u. Ther., 1911, ix.
6. Crotti. Thyroid and Thymus. Philadelphia: Lea & Febiger, 1918.
7. Marine. Colloid glands — their etiology and physiological significance. Bull. Johns Hopkins Hosp., 1909, xx.
8. Idem. The prevention of simple goiter in man. J. Lab. & Clin. Med., 1917, iii.
9. McCarrison. The Etiology of Endemic Goitre. London: Bale Sons-Danielssohn, 1913 (Lit. to 1913).
10. Idem. The Thyroid Gland. London: Bailliere, Tindall & Cox, 1917.
11. Michaud. Die Histogenese der Struma Nodosa. Arch. f. path. Anat., 1906, clxxxvi; Arch. f. klin. Chir., Berl., xxix.
12. Simpson. Growth centers of benign blastomata, etc. J. M. Research, 1913, xxvii, 3.
13. Wolfler. Ueber die Entwicklung und den Bau des Kropfes, 1883.

HYPERTROPHIC STENOSIS OF THE PYLORUS IN INFANTS

By THOMAS M. GREEN, M.D., F.A.C.S., Wilmington, North Carolina
Attending Surgeon to the James Walker Memorial Hospital, Wilmington
AND
J. BUREN SIDBURY, A.M., M.D., Wilmington, North Carolina
Attending Pediatrist to the Marion Sprunt Memorial Hospital

THIS condition was first described by Hirschsprung (1) in 1888, but not until 1897, has much appeared in the literature. Since then, however, the condition has attracted more and more attention until within the last decade much has been written upon this subject.

We regard this condition as a distinct pathological entity and we feel that it should not be confused with those gastric disturbances which sometimes present some of its symptomatology. One can not help but realize that many children have heretofore been sacrificed because this condition was not recognized. This is unquestionably due to the fact that many authorities believed the condition to be due to a pyloric spasm. Every one seems to be agreed that pylorospasm does occur in neurotic infants and produces vomiting, but there are few clinicians now who do not recognize the difference between this condition and hypertrophic pyloric stenosis.

PATHOLOGY

We regard this condition as a congenital hypertrophy of the pylorus muscle, which is seldom sufficient to produce obstruction, but when obstruction does occur it is due to a spasm of the hypertrophic pyloric muscle. These cases which appear to be cured by medical treatment are not cured of the hypertrophy, but are relieved of the spasm. Indeed, Holt (2) cites instances in which he could still palpate the tumor in medically cured cases where no surgery was done. On the other hand Lewis and Grulee (3) have shown that the hypertrophic muscle remains for years after a posterior gastro-enterostomy. So also has Scudder (4) shown this. Rosenheim (5) had a case of a boy 6½ years old in whom the symptoms had existed off and on since infancy. Other reasons for considering it a congenital condition are that it is often found with other anomalies such as club foot, hair lip, etc. Hill (6) cites two cases occurring in one family with a history of its occurring before. There is sufficient time for the hypertrophy to take place before birth since we know that the pyloric muscle begins to appear at the end of the third month of fœtal life. Cautley (7) cites a case of Dent's, in which he found it in a seven months' fœtus. In one of our cases it was demonstrated on the third day of life, the child apparently having been born at term. There are a few who hold the belief that constant spasm produces an overdevelopment of the pyloric muscle. However, the evidence of the congenital origin of the hypertrophy seems to be in preponderance to us. Holt (8) says that spasm has never been known to produce hypertrophy.

SYMPTOMS

This condition is attended by a very definite symptomatology, which in itself should serve to make a diagnosis. If every infant be carefully observed the diagnosis between it and other gastric conditions associated with nausea and vomiting should be made. .

According to Hill (6) it occurs in one in every 200 babies. The onset is always abrupt. It is seen most often in breast fed, male infants. Holt (8) found 52 out of 56 cases were in breast fed children.

Vomiting. It usually begins at the end of the third week, but may occur earlier or later. The vomiting is projectile in character. It does not often attract the attention of the mother at first, but is so characteristic later that a diagnosis can almost be made by it alone.

The material vomited depends not upon the quality of the food taken, but upon the quantity. It occurs during or at the end of the feeding, sometimes ejected several feet

from the child's mouth. There is practically never eructating or spitting of food in small quantities. The child may not vomit each time that it is fed, but if it retains one meal and vomits at the end of the second, it will vomit both meals at one time. Changing the character of the food may improve the condition for a few days, but it returns, *always*. The vomited material consists of the food taken plus hydrochloric acid, mucus and some epithelium. If we insert the tube after vomiting, the stomach will be found to contain generally, a small quantity of this material in addition to what has been vomited, showing the constant presence of dilatation of the stomach. The vomited material never contains bile or any of the intestinal secretions. On inspection the upper abdomen seems to be full and tense while the lower abdomen is flat and flaccid.

Peristaltic waves. If the child is stripped and observed repeatedly, while feeding, in almost every case we can see, in the upper abdomen, peristaltic waves passing from left to right *across the median line*, becoming more and more violent as the stomach fills, showing its effort to overcome the obstruction at the pylorus, being ball-like in appearance and more or less rhythmical. Just before vomiting occurs one can often see a reverse peristalsis, and after one or two of these waves pass backward from right to left the vomiting occurs.

Pyloric tumor can be elicited in 80 per cent of the cases. Holt (8) claims that it is easier to find when the stomach is empty than when full. Our experience bears him out on this point. Its presence is not essential to diagnosis and it is not so important a symptom as the projectile vomiting and true gastric peristaltic waves. The tumor is described as a small mass the size of a lymphatic gland in the right upper abdomen, always freely movable, varying in size depending on how long the symptoms have existed. In other words it is much easier to palpate when the case has existed for some time and the symptoms of obstruction have been pronounced, though one of our cases had a tumor which was palpated easily causing complete obstruction while the patient was only three days old at operation, and where obstructive symptoms existed from birth.

Amount of retention. In milder cases where the obstruction is not so complete the amount of retention of food is often a great help. Food in diluted form is given. At the end of three hours, if the food is not vomited, it is removed with a tube and the contents measured and recorded. In some cases where the child is almost moribund it is too weak to vomit, and the vomiting occurs only once or twice in 24 hours. The amount of food recovered gives you a very good insight into the amount which has passed the pylorus and the severity of the obstruction at the pylorus.

Constipation is another symptom depending upon the obstruction. In the most severe cases the stool is afæcal and consists of bile, pancreatic juice, mucus and epithelium, but no food particle. It resembles meconium. In other less severe cases, we find small, sometimes very hard constipated stools containing fæcal matter, requiring enemata and suppositories.

The use of the X-ray is of very little value. Holt (8) regards it as of no value, while Richter (9) says its use should be limited not to determine the patency of the pylorus, but to observe the rate of emptying of the stomach. A little of the bismuth meal may pass the pylorus, but that does not tell the story of the afæcal stool and the steady loss of weight.

CASE REPORTS

CASE 1. L. L., age 4 weeks, male, breast fed, weight 7 pounds 4 ounces. Vomiting occurred after each nursing for one week and constipation had been present for 10 days. The child was born of the mother's first pregnancy which terminated in normal labor at term. Birth weight 8 pounds. The child nursed twenty minutes every 3 hours and did well up to one week ago when he began to vomit, small amounts at first and not after each nursing. The vomiting increased in frequency and quantity for three days when the baby vomited after each nursing and the mother thought all that he took. The vomiting was not projectile. The patient seemed hungry all the time. Physical examination showed a fairly well nourished child, skin of good color but a little lax. No gastric wave was seen, no tumor felt. The mother was advised to nurse the baby ten minutes every three

hours, and a lavage given four times a day. One week later the mother returned to the office and reported that the baby had been spitting up much less in quantity, only about one tablespoonful after nursing and not after each nursing, but three or four times a day; for the past three days one to three tablespoonsful three times a day, not projectile. The child weighed 6 pounds 12 ounces. The child was still hungry and still constipated. There was no gastric wave and no tumor felt at this visit. Four days later the mother returned with a very different story. The baby looked much worse and the mother said that the baby had vomited everything taken for the past 48 hours and stated that it spurted from the baby's mouth. At this examination the baby showed typical gastric peristalsis crossing the median line and a large easily felt tumor. At this time we wondered how we could have missed feeling it at the previous examinations. Weight at this time was 6 pounds 4 ounces, a loss of a whole pound in two weeks. Six hours later he was operated upon by Dr. Green and a very hard cartilaginous-like tumor of the pylorus was demonstrated. The Rammstedt operation was done requiring twenty minutes. The patient made an uneventful recovery and was discharged from the hospital in ten days having gained 8 ounces. His retention taken one time only three hours after feeding was 60 cubic centimeters.

CASE 2. N. D., age 21 days, one of twin boys, weight 7 pounds 6 ounces, breast fed. The child had been vomiting for two weeks, and had marked constipation for ten days. The vomiting was not marked for the first week, only about three times a day and about three tablespoonsful at a time but always came immediately after nursing. For the past week the vomiting had been projectile and after taking anything by mouth, even water. He had lost much in weight. He was very much smaller than his twin brother who was smaller than he at birth. The family history was negative. Examination showed a poorly nourished baby with eyes sunken and skin wrinkled and non-elastic. Projectile vomiting was very marked, there was typical gastric peristalsis and a hard easily felt tumor. Stools were afæcal. Gastric retention 30 cubic centimeters three hours after nursing. The child was seen at night in consultation and an immediate operation was advised but it was the following day before consent to operation was given, and at operation a very typical cartilaginous-like tumor was found, the Rammstedt operation done in 18 minutes. The recovery was uneventful and the patient was discharged on the seventh day having gained 4 ounces. At 12 months of age he weighed 24 pounds which is three pounds more than his twin brother.

CASE 3. M. W., age 3 months, 1 week; girl; weight 8 pounds 10 ounces; breast and bottle fed. Vomiting occurred after each nursing for nine weeks; constipation had been present for six weeks. She was born of the mother's first pregnancy which terminated in normal labor at term. The child had

Fig. 1. Case 1 at 12 months. Weight 24 pounds. Operated on at 6 weeks.

been breast fed exclusively for four weeks at which time the baby began to vomit and a bottle was advised. For the past two months she had had a number of different formulas all of which proved unsuccessful. The baby seemed very hungry but would vomit about an ounce just after or a few minutes after finishing the bottle and would repeat this once or twice before the next feeding. Examination showed a poorly nourished, pale child with gastric peristaltic waves but no tumor could be felt. The patient was given medical treatment for three weeks and a modified formula and breast milk, varying strengths during this time but there was no definite improvement. A gastric lavage was given four times a day for ten days and then four times a day with no definite improvement, but rather to the contrary the child was losing ground steadily but not so rapidly as the mother said it had the month previous. Gastric retention three hours after feeding repeatedly showed 60 to 80 cubic centimeters; on two different occasions 4 hours after a feeding 30 to 40 cubic centimeters. During medical treatment for three weeks there was a loss of 10 ounces and she was not improving as we felt she should. At no time was a tumor felt by either of us or by two other colleagues. In the face of the loss of weight, the typical gastric peristaltic waves and the failure to respond to medical treatment, we advised operation as we feared to wait too long. A Rammstedt operation was done and a medium sized, soft pyloric tumor was found. During the

Fig. 2. Case 5, five months of age. Operated on at 3 days of age.

operation the mucous membrane was punctured and additional time was consumed in closing the puncture but the operation was finished in 25 minutes. The patient was somewhat shocked from the operation and had a stormy postoperative course for three days, running a temperature 101 to 103°, and vomiting considerably the second and third days when at one time definite fæcal vomiting occurred. But the vomiting ceased rather suddenly on the third day and the convalescence was uneventful from then on. At 10 months the baby weighed 18 pounds and has had no more gastric disturbances.

Case 4. D. H., age 6 weeks, male, breast fed, weight 4 pounds 8 ounces. The child had vomited, was constipated and had lost weight for three weeks. For ten days the vomiting had been after each nursing and was projectile in character. The mother had one other baby who had lived six weeks, the cause of death not being known. There had been no miscarriages. The child was seen at midnight in consultation with another doctor and was found to be in extremely bad condition, the cry was very feeble, the pulse barely palpable, and the eyes sunken. A most typical peristaltic wave was present and an easily demonstrated pyloric tumor, quite large and very hard. The baby was taken to Wilmington the same day which was some 90 or 100 miles away and a Rammstedt operation was done after hypodermoclysis had been administered twice and some cardiac stimulants given. At the operation a very large, quite hard, pyloric tumor was demonstrated. The operation was completed in 10 minutes for we appreciated that speed was most important to save the baby's life. The child had an uneventful recovery and the only reason he was kept in the hospital longer than any of the other cases was because the parents lived out of town and we thought it most important to give the baby a good start before turning him over to his mother to be taken care of, especially since her milk supply was scant and so scant that we had to get a wet nurse to assist her to nurse the baby. When the baby was operated on he weighed 4 pounds 8 ounces and when he was discharged three weeks later he weighed 5 pounds 15 ounces. His weight at 6 months was 12 pounds 14 ounces, and he was still nursing his mother.

Case 5. B. S., age 1 day, female, never put to the breast, weight 6 pounds. Projectile vomiting persisted since birth. The mother was taken to the hospital after delivery on account of repeated convulsions. She had been unconscious since a few hours before the baby was born and the convulsions had continued for thirty-six hours after the birth. There are five other children all living and well, no miscarriages. Six hours after the baby was born the nurse gave the child one ounce of warm boiled water which she vomited immediately, with considerable force. This she kept up after each feeding of sugar solution 5 per cent until she was operated on. Examination showed a very plump newborn baby who appeared hungry whenever fed, but who vomited immediately after feeding and at times during the feeding. Lavage was given twice a day with no relief of symptoms. The retention three hours after feeding showed 5 to 10 cubic centimeters of practically clear fluid. There were seen very typical peristaltic waves, and a tumor about the size of the pea in the usual region was felt. The urine was scanty, the stools meconium, of course, but only two in three days. On account of the age of this patient we wondered if we might not have some very unusual condition, such as an atresia of the duodenum or a band constricting some part of the duodenum. We felt that either could produce the peristaltic waves, but they could not account for the tumor. An operation was advised and a small, moderately soft, but definite pyloric tumor was found. The duodenum was in perfect condition. With the exception of a slight hæmorrhage from one of the stitches the recovery was uneventful. For this 20 cubic centimeters of fresh human serum was given and the bleeding ceased. At three months she was nursing her mother 20 minutes every three hours and weighed 9 pounds.

Case 6. M. O., age 6 weeks, male, weight 7 pounds. Vomiting had persisted after each feeding for three weeks, constipation for two weeks. The

child was breast fed and nursed whenever he cried and that was nearly all the time. The child was born of the mother's first pregnancy, which terminated in normal labor at term. Birth weight 6 pounds, 8 ounces. The child was seen only once at the clinic, and on examination very typical gastric peristaltic waves were seen, and after feeding or during the feeding he ejected at least two ounces of sour curded milk to a distance of one foot. No tumor could be felt at this examination. The mother was strongly advised to let the child stay in the hospital for observation but she refused and also refused to let either a doctor or a nurse see the child afterwards for fear that they would operate on the baby. Indirectly, through other patients in the same neighborhood, I kept some track of the baby. The baby continued to vomit, to what extent I could not say, but it did continue to a greater or less extent for six weeks after I saw the baby, and then the vomiting became less. Now the baby is gaining in weight and vomits very little according to the report. If this was a case of pyloric obstruction, which of course, we can not say definitely, it was a spontaneous improvement.

TREATMENT

When this condition was first described, it was assigned to the surgeon for treatment. His results, however, were so discouraging that other methods were attempted; in some instances with flattering results, notably a series of cases treated by Hutchinson, with 20 per cent mortality. We are inclined to think that many of these so-called medical cures were after all cases of pyloric spasm and not hypertrophy. Granting that they were hypertrophic, they were relieved of the spasm, which had supervened on the hypertrophy and produced obstruction, and allowed to go on with the hypertrophy, which is always prone to relapse. Since 1905, however, with the perfection of the technique of gastro-enterostomy the surgical treatment of this condition has once again occupied the foreground. Scudder (10) reports a series of 36 gastro-enterostomies covering his cases, Richter's and Stillman's, with a mortality 13.8 per cent, while others show an improvement in their mortality percentages as time goes on. In 1913 Rammstedt (11) describes his operation of dividing the pyloric muscle fibers down to the mucous membrane, and partially separating the muscle ring from the mucous membrane, allowing the mucosa to bulge up into this wound. This we believe is going to be a distinct advantage in the treatment of this condition and will serve materially to lower still further the mortality rate. While we cannot but admire the record that Scudder (10) and Richter (9) made with gastro-enterostomy, we are of the opinion that gastro-enterostomy is a far more serious operation than the Rammstedt procedure, and will sooner or later give way to the much simpler operation, which accomplishes the same result with less danger to the patient and which permits of the giving of food and fluids so much sooner, establishing a more speedy convalescence. The Rammstedt operation is accomplished in from 15 to 20 minutes from the beginning of the administration of the anæsthetic until the child is taken from the table. In one of our cases this was accomplished in 10 minutes.

One must, of course, use care to avoid tearing through the mucous membrane. This can readily be done if the separation of the pyloric muscle, after its division, is begun at the stomach side and we proceed gradually toward the duodenum. If, however, a small tear is made it can readily be taken care of by clamping and ligating at this point with a fine silk thread as one would ligate a vessel. A stomach tube should always be passed after the abdomen is opened to allow the air, which the child has swallowed while taking the anæsthetic, to escape from the stomach. As a matter of course we also precede each operation with a gastric lavage. After the operation on the pyloric muscle is completed, the stomach tube is inserted, the stomach inflated with air to determine whether or not any perforation of the mucous membrane has occurred. In this way perforation can be demonstrated and taken care of when it might otherwise be overlooked. Feedings are started as soon as the child awakens from the anæsthetic, which is usually about two hours.

To Downes (12) must be given the credit of demonstrating the efficiency of the Rammstedt operation. His results are most striking, but we also realize that the medical care of these cases after operation is just as important as a successful operation. Often bad judgment in feeding or in changing a

AUTHOR'S CASES

Case	Date	Age	Sex	Duration of Symptoms	Operation	Weight			Stay in Hospital	Results.
						Birth Weight	On Admission	On Discharge		
1 L. L.	12-23-16	6 wks.	Male	4 wks.	Rammstedt	8 lbs.	6 lbs. 4 oz.	6 lbs. 12 oz.	10 days	Cured. At 12 months weight 24 pounds.
2 N. D.	3-18-17	22 days	Male (one of twins)	2 wks.	Rammstedt	8 lbs. 8 oz.	7 lbs. 4 oz.	7 lbs. 8 oz.	7 days	Cured. Gained steadily after operation. At 12 months, weight 24 pounds 8 ounces.
3 M. W.	9-20-17	4 mos.	Female	3 mos.	Rammstedt Accidentally opened duodenum	8 lbs. 12 oz.	8 lbs.	8 lbs. 2 oz.	10 days	Cured. Postoperative convalescence stormy for 4 days; then uneventful; at 10 months, weight 18 pounds.
4 D. H.	10-6-17	6 wks.	Male	3 wks.	Rammstedt	5 lbs. 8 oz.	4 lbs. 8 oz.	5 lbs. 15 oz.	3 weeks	Cured. At 6 months, weight 12 pounds 14 ounces.
5 B. S.	1-19-18	3 days	Female	Since birth	Rammstedt	6 lbs.	5 lbs. 12 oz.	6 lbs. 4 oz.	12 days	Cured. At 3 months, weight 9 pounds.
6 M. O.	3-4-18	6 wks.	Male	3 wks.	No operation	6 lbs. 8 oz.	7 lbs.			Refused to come in hospital. Did not return to Clinic. After 6 weeks vomiting stopped.

feeding may cause a fatality where the operation has been thoroughly successful.

These cases must have *breast milk*, and they must have it in small quantities at the beginning and it must be increased slowly. In our cases we have followed the method adopted at the Babies' Hospital, New York. We start the feeding two hours after the anæsthetic, or when the baby is well awake from the anæsthetic, with 4 cubic centimeters of breast milk and 4 cubic centimeters of barley water every three hours, increasing 4 cubic centimeters of breast milk every other feeding until we get the breast milk up to thirty cubic centimeters and then we give thirty cubic centimeters of breast milk every three hours during the day and every four hours at night. The baby is not allowed to nurse the mother for from 5 to 7 days after operation, and then the baby is weighed before and after nursing to determine the amount he gets. Castor oil is given 24 hours after operation. Practically every case that we have treated has received an ante-operative hypodermoclysis. Some few received hypodermoclysis after the operation. The greatest care is taken not to chill the baby during operation and external heat is applied for a number of hours after operation. Should a diarrhœa follow the operation we would treat it the same as other diarrhœas, with protein milk or protein and breast milk. We must remember that these cases are feeding cases still, and some of them may remain difficult feeding cases, and when the surgeon has finished the operation the baby should be turned over to some one who has some skill in feeding infants. In these cases more than any other the co-operation of the surgeon and the pediatrician is required for success.

BIBLIOGRAPHY

1. Hirschsprung. Jahr. d. Kinderheilk., 1888.
2. Holt. J. Am. M. Ass., 1917, May 26.
3. Lewis and Grulee. J. Am. M. Ass., 1915, Jan. 30.
4. Scudder. Ann. Surg., Phila., 1914, February.
5. Rosenheim. Berl. klin. Wchnschr., 1899.
6. Hill. Surg., Gynec. & Obst., May, 1914, xviii, 570.
7. Dent. Quoted by Cautley.
8. Holt. J. Am. M. Ass., 1914, June 27.
9. Richter. J. Am. M. Ass., 1914, January 31.
10. Scudder. Ann. Surg., Phila., 1914, February.
11. Rammstedt. Med. Klin., 1912, Zentralbl. f. Chir.
12. Downes. J. Am. M. Ass., 1914, June 27. Surg. Gynec. & Obst., 1916, xxii, 251.

A THEORY ON THE ETIOLOGY OF THE TOXÆMIA OF PREGNANCY WITH OR WITHOUT CONVULSIONS

By JOHN E. TALBOT, M.D., Worcester, Massachusetts

MUCH has been written in regard to different methods of treating the complex of symptoms known as the toxæmia of pregnancy with or without convulsions, and many different theories as to the fundamental cause of this condition have been evolved. Many of the profession are still hard at work collecting further data, in an endeavor to locate the fundamental cause. That this cause is not yet satisfactorily established seems generally understood.

Certain clinical facts have recently come to my notice which by their extraordinary nature seem to me to throw some light on this subject. The interpretation of clinical facts can never be a matter of absolute logic on account of the number of factors involved, but the extraordinary nature of certain facts may give a reasonable ground for making a deduction, the truth of which is increased by the extraordinary nature of the facts from which it is made.

The deduction which I have made is that the fundamental cause of toxæmia of pregnancy with or without convulsions is not in the products of conception.

The history of the following case plus subsequent observations in other cases seems to me to raise a strong probability that this statement is true.

Mrs. M. was curetted in December, 1915, for an incomplete miscarriage at 3 months. Following the operation she had some cardiac decompensation and a diagnosis of mitral stenosis was made.

In spite of caution to avoid pregnancy, on August 1, 1916, she told me that she was two weeks overdue. Throughout the pregnant period which followed she was carefully watched and the blood pressure and urine were normal at all examinations. There were no symptoms of toxæmia. Her pulse became progressively more rapid so that by the middle of February she could not move about without dyspnœa and palpitation.

In consultation it was decided to put her to bed and then deliver by cæsarean section. Accordingly on March 14, a cæsarean section was done.

For the next few days the patient did very well. Pulse 110 and no fever.

On the 18th she complained of headache which became so severe on the 19th that it resisted morphia. On the 21st, the patient had 12 convulsions and died on the 22nd. Blood-pressure was normal on entrance to the hospital. On the 19th, it was found to be 180. The bowels had moved two or three times a day since the operation.

Here is a case of postpartum eclampsia with no symptoms of toxæmia appearing until 4 days after delivery, and then reaching its climax 7 days after delivery.

A postpartum eclampsia or toxæmia such as the case cited, implies that the supply of poisonous substance causing the disease increases even after delivery to a point which gives the manifestations of eclampsia and thereby implies that the source of such a poison must be still present in the body after delivery.

It seems absolutely illogical to say that such fulminating symptoms will rise to their height seven days after the cause has been removed.

That the pregnancy itself plays a part in the causation of those symptoms must also be true. We need no more proof of this than what may be called the therapeutic test, that is, by termination of the pregnancy we frequently bring about an almost immediate abatement of symptoms in a large majority of cases. Thus we have two apparently inconsistent facts, the unquestionable evidence that the symptoms are dependent upon the existence of a pregnancy and the evidence that the products of conception are not the primary cause. In solving the problem of the fundamental cause these two facts must be made to agree.

In August, 1916, another case of extraordinary character came under my care and, as this case forms the starting point of my subsequent observations, I will report it in full.

Mrs. E., age 33, born in Massachusetts; married 6 years; no children. The patient's father died of chronic nephritis. Uncle and aunt on father's side died of kidney trouble. Aunt on mother's side ill

with high blood-pressure. (On account of chronic nephritis in the family, the patient has had her urine examined repeatedly throughout her life. All examinations have been negative.)

The patient had had no serious illnesses. Jaundice at 11 years of age. Tonsillitis occasionally. Tonsillectomy 15 years ago.

For years she has noticed that at times her hands and face were slightly swollen, especially in the morning. She has been troubled with facial neuralgia and pains in joints with stiffness, especially in the right arm. These symptoms came on following the placing of a gold crown on a tooth. About one year after the crown was put on, an abscess formed in the gums which discharged pus.

The patient came to my office at the end of the sixth month of pregnancy at which time her blood-pressure was 140. Physical examination was negative except for a small external conjugate of 17½ centimeters. Ten days later she complained of pain in her right elbow and wrist with numbness. The blood-pressure was 140, the urine negative.

One month later the blood-pressure was 155, and both ankles were swollen. The face became slightly puffy, and there was a numbness of right hand except little finger. There was no headache or eye symptoms. The urine was still negative as to albumin and but one granular cast was seen. The patient was immediately put to bed, given magnesium sulphate to bring about watery movements, placed on a meat-, fish-, egg-free diet, and fluids forced to 3 quarts of water a day.

After five days of active treatment the blood-pressure had risen to 180S-100D, albumin appeared in increasing amounts with only occasional casts. With the appearance of casts and the continued high blood-pressure (185) it was decided to start labor.

A Voorhees bag was inserted and the patient kept under morphia during labor. The patient was delivered of a 3 pound male child which died in about 12 hours after birth. Placenta had numerous white areas, no large infarcted areas.

During labor blood-pressure rose to 210, but dropped to 165 following delivery.

Convalescence during the next two weeks was without much disturbance. The first four days were marked with a slight fever 100.5° to normal. The blood-pressure did not fall to normal, however, but rose and fell between 170 and 140.

One month from date of delivery, the urine was clear of albumin and casts, and the blood-pressure was 135. Seven weeks after delivery the blood-pressure rose to 160S-100D with no return of albumin or casts. Patient said she never felt better in her life.

While in the hospital the patient complained of dropping from the back of her nose. This symptom persisted after leaving the hospital.

With the continued elevation in blood-pressure and a perfectly clear urine, this catarrh attracted my attention, thinking that chronic sepsis might explain the elevation of blood-pressure. Consultation with a nose and throat specialist revealed nothing, however.

Six months after delivery, during which time the blood-pressure ranged between 150 and 135, and with an absolutely negative urine, the patient announced that she had at last located some pus. The gold crown tooth had become inflamed and broken a sinus through the gums. This tooth was the upper right bicuspid. An X-ray examination of all her teeth was made and a pus cavity at the base of that tooth and the next molar posterior which seemed to connect with the antrum was found. During 10 weeks of treatment by her dentist the tooth quieted down only to become active again with a return of neuritic pains, puffiness of the lids and the blood-pressure rising steadily to 170S-110D. Urine always negative.

At this point I requested the dentist to remove the tooth entirely which was done on June 20, 1917, and two days later the molar was also removed. There was a marked discharge of foul pus and upon irrigating the cavity, the water came out of the patient's nose.

This undoubtedly explained the source of the catarrh, the neuritic and rheumatic symptoms. These neuritic symptoms during the pregnant period and at the time of the rise of blood-pressure signify the activity of that process although not locally painful.

Why should this human system which had hitherto been free from any evidences of serious disease, fail to perform the functions attending the development of a pregnancy? The repeated negative examinations of her urine throughout her life give good ground to believe that her kidneys had been in good condition. Until this focus of pus was located, her clear bill of health made the occurrence of toxæmia of pregnancy absolutely unreasonable.

Since March 10, 1917, the day on which this patient announced the result of the X-ray findings in her teeth, I have made observations on all cases of toxæmia occurring on my service in obstetrics at the Worcester City Hospital and Memorial Hospital and in my private practice. In a series of 97 cases up to March 1, 1918, I have been able to find evidence of chronic sepsis in the teeth in all cases, without a single exception.

In most of the cases where a reliable history was obtainable it has been possible to find evidence of the activity of these pus pockets just previous to or accompanying the onset of symptoms.

In general the severity of the symptoms of toxæmia may be said to be proportional to the amount of sepsis present.

One of my private cases is such a marked exception to this statement as to warrant reporting. The lack of any symptoms attributable to the teeth during the progress of the case made me believe that the unbroken chain of cases previously observed was to be broken by this case which I report in full.

Mrs. Po. came under my charge at the end of the second month of her second pregnancy.

Past history was negative except for history of her first pregnancy at which time she became infected and was 7 weeks in bed with right femoral phlebitis.

Throughout her pregnancy she had a normal blood-pressure and normal urine. She had occasional symptoms of dizziness and almost fainting spells, but without other signs. These were at first attributed to nervousness as she had been severely punished at the first delivery by a two-hour attempt at forceps delivery *without ether*.

About two weeks before delivery she began to develop signs of hydramnios which increased gradually. At no time during the pregnancy had the fœtal heart been audible and motion, though felt, was very slight. With the development of hydramnios a bad prognosis as to the development of the child was made. The membranes ruptured about two weeks before her date with the escape of a tremendous quantity of liquor.

After the rupture, the fœtal heart was audible in the left lower quadrant, 140. Vertex above the brim but no small parts could be made out.

On arrival at the hospital her blood-pressure was 150. Delivery was normal in about 20 hours from time of rupture of membranes. The child was a typical case of chondrodystrophia fœtalis and after 2 or 3 gasps died. The placenta showed an infarct about 4 to 6 centimeters in diameter. Bleeding was abnormally profuse. Two hours after delivery the blood-pressure was 185 and remained up for 3 hours, dropping to 130 the next morning. The patient slept well but complained of headache in the occipital region and dizzy feeling when awake.

The following night at 3 a.m. she had 5 convulsions coming on during her sleep. Blood-pressure 170. At 8 a.m. and 11:30 a.m. the blood-pressure was 120. At 12:45 p.m. the patient complained of being dizzy and had two more convulsions. The blood-pressure rose to 170 at this time, but was down to 130 within a half hour, and there it remained for the next two weeks, rising only once to 148.

Up to the end of the first two weeks there was not a sign of pus anywhere. Inspection of the teeth was negative except for one pivot tooth in front. There were absolutely no symptoms from the teeth.

On the fourteenth day the patient developed a temperature of 104°, pulse 148 with pain and tenderness in right breast. The breasts had been bound up at the start and the milk had subsided. Two days later a breast abscess, deep against the muscle, was opened and about one ounce of pus evacuated.

As the nipples had not been used, this abscess seemed to be of hæmatogenous origin and this gave me hope. At the end of another two weeks, the breast having nearly healed, she developed pain in the left kidney region with rise of temperature to 102° and pulse 140. Examination of the urine showed pus cells sufficient to warrant the diagnosis of pyelitis. Under treatment with hexamethylenamine this subsided in less than a week.

It is important to note that at the time of the breast abscess and at the time of the pyelitis there was a definite rise in blood-pressure corresponding to temperature curve.

Believing that the breast abscess and pyelitis were evidence of a pus focus somewhere, the teeth were X-rayed completely and two pockets of pus thereby located, one in the pivot tooth and one farther back in the upper jaw.

This case is important as it points out that the absence of local symptoms cannot be depended on to rule out the presence of focal infection.

The fact that in many cases there is evidence of activity in these pus pockets just preceding or associated with the occurrence of symptoms of toxæmia, and the fact that the severity of the symptoms is in general proportional to the amount of chronic sepsis present are evidences which tend to show that there is a relationship between the chronic sepsis and the incidence of the disease.

Can this relationship be explained? I not only believe that the relationship can be satisfactorily explained but also that the explanation throws light upon other than purely obstetrical problems.

Among the many striking facts associated with the development of a normal pregnancy is the marked stimulation of the metabolic processes of the maternal system, as evidenced by the increase in appetite, the increase in weight, and the remarkable sense of well-being. The patient passes through a period which is described by the common statement that "I never felt so well in my life."

That this increase in metabolism throws a definite strain on the woman's organism is a fact of which we have clinical proof.

For example, interpose a pregnancy on a damaged heart and we see clearly that the increase in the functions of the body in order to develop the pregnancy, will so tax a heart which has hitherto been sufficient for the needs of the body, that we often get definite breaks of compensation which cannot be attributed to any other cause than the physiological process going on. Thus we see that pregnancy, itself a perfectly physiological process, can break down the reserve power of one organ to the point of decompensation. If this be true, why can not this same physiological process break down other organs whose reserve may have been weakened by some previous or concurrent process?

Which of all the organs of the body is most consistently linked with this disease known as toxæmia of pregnancy? The kidneys, the main organs of excretion of the waste products of nitrogenous metabolism, give us our most reliable signs of approaching trouble. Not only do the kidneys link themselves with the vital processes of this disease by giving us warning of approach of danger, but they are more strongly linked by the similarity of the symptoms which follow from kidney inefficiency which we know as chronic nephritis, and furthermore by the marked increase in the incidence of the disease where pregnancy is interposed upon an already existing chronic nephritis.

That the waste products of normal physiological metabolism are injurious to the organism of man if retained is surely true. Anuria if continued long enough always results in death. Anuria must primarily cause an increase in the concentration in the blood of the waste products of physiological metabolism.

If they are injurious to the body cells in abnormal concentration, can it be truly said that they are *not* injurious in normal concentration?

It is a fundamental characteristic of all things in this world to wear out. It is not too much to assume that such a process must be present in the human system. It is perfectly reasonable to believe that arteriosclerosis in old age is merely the end-result of a purely physiological process. The blood vessels, being constantly bathed in a fluid containing these harmful excretory products, gradually respond to their injurious effects, resulting in what we know as arteriosclerosis. There is plenty of clinical evidence that, by regulating the diet and activities of a patient suffering from arteriosclerosis, the life of that patient can be prolonged. One of the principal results from controlling these two factors, diet and exercise, is to bring about a reduction in the production of the waste products of the body which must in time make a reduction in the concentration of these products in the blood.

If such a slow, wearing process is tenable at all, it must follow that there is a slow subminimal injury to the kidney epithelium itself.

Normal pregnancy itself without question increases the total of the metabolic products in the body and with this increase of metabolism causes an equal increase in the total quantity of excretory products to be eliminated by the kidney. This increase in quantity must increase the percentage of concentration of those excretory products in the blood and therefore put a greater strain on the kidneys, or in other words, it must use up a part of the reserve power of the kidneys.

The great concern of the kidney as an organ of excretion must be with the percentage of concentration of those excretory products in the blood. The reserve power of the kidney must consist in its ability to continue to excrete those waste products even in abnormal concentration. It must be also true that it is from the blood which is on the edge of the stream, that is, the blood which is in contact with the renal epithelium, through which the process is carried on.

We have therefore a situation during a developing pregnancy in which the kidneys as excretory organs are called upon to excrete a gradually rising tide of metabolic waste products which waste products are injurious to the system if retained. This situation demands that the excretory apparatus of the body should be in its highest state of efficiency.

How does the presence of undrained chronic sepsis affect this situation? We know that persons suffering from acute infection frequent-

ly show a concentrated urine, which not infrequently contains albumin, blood and casts. It is generally agreed that these findings are the result of an inflammatory reaction on the part of the kidneys resulting from the toxins of the acute infection which the kidney is called upon to excrete.

If the toxins of acute infection are an irritant and injury to the kidneys, so the toxins of chronic sepsis which are drained into the blood must damage the excretory functions of the kidney.

It is probable that they are like the metallic poisons, acting as a foreign substance to the physiological processes of the body and, just as we find chronic nephritis developing from chronic metallic poisoning, so we have here in the toxins from chronic infection a perfectly good cause for chronic nephritis.

The fact that chronic nephritis is so common an ailment of the human race proves that the cause must be equally common. The insidious manner in which it develops suggests an equally insidious source.

It is not the purpose of this paper to discuss the causes of chronic nephritis but, in view of the observations which were necessarily made in working up this paper, I am convinced that could we eliminate the chronic sepsis which occurs in connection with the teeth, we could surely eliminate the most potent cause of chronic nephritis.

How do the principles above set forth affect the pregnant woman?

Pregnancy in itself must be a purely physiological process, no part of which is antagonistic to the physiological processes of a normal woman. It is generally so accepted. In a normal woman nature has provided a kidney function which is sufficient to carry on that organism. The kidney reserve power in a normal individual is known to be largely in excess of the needs of that normal individual. It is sufficient in the majority of cases to take care of the extra work which is necessitated by the increase in metabolic products resulting from pregnancy which must be excreted.

When, however, we start with a woman who has an impaired kidney function as evidenced by chronic nephritis, then we begin to get an increase in the incidence of those symptoms which go to make up the entity known as toxæmia of pregnancy. We start with a kidney with reduced reserve power and this might explain the increased incidence of the trouble.

If chronic nephritis occurred as a background, preceding or concurrent with each case of toxæmia of pregnancy or eclampsia, it would be possible to say that the increase in normal metabolic waste products resulting from the pregnancy was sufficient to overcome the reserve power of the kidneys, which reserve power had already been lowered by the chronic nephritis present. But such is not the case. Toxæmia of pregnancy and eclampsia occur in individuals who show no evidence of any previous kidney trouble. This fact tends to show that the kidney reaction is only secondary to the underlying cause.

The important facts to be noted are, however, that the cause of the trouble is not primarily in the kidney, but that the lack of proper kidney function causes an increased incidence, thereby showing the immediate relation between the excretory function of the kidney and the occurrence of the symptoms.

What other evidence have we that this matter of elimination is the crux of the situation? Surely the treatment which has given the best results is the so-called eliminative treatment. Here again is the clinical recognition of the fact that there is a retention of something in the system which, if it can be reduced in amount, brings good results. It is most reasonable to assume, therefore, that this something which may be termed a poison is in the blood stream.

The reaction of the kidneys in this disease of toxæmia of pregnancy is similar to that which occurs when there is a poison or toxin in the blood. The very fact that it is the liver, kidneys, and placenta that are most damaged, as shown by the pathological findings at autopsy, is significant. These three organs may be classed together as the principal organs of the metabolism of the blood. It is also important to note that it is in these three organs that the blood stream is the most sluggish.

It is then fairly clear that we have to do with a poison in the blood stream which is in such concentration that it causes the symptoms which we know as toxæmia of pregnancy. If this concentration can be reduced by increasing the power of the body to eliminate we secure an abatement of symptoms.

The problem which presents itself is, therefore: what is the source of the poison and why is the poison not eliminated?

I have shown that the incidence of toxæmia of pregnancy in the series of cases observed was coincident with a focus of chronic infection. I have raised the point that the toxins of acute infection cause an inflammatory reaction in the kidneys with an inhibition of their excretory functions. I advance the point that the toxins of chronic sepsis are an irritant and an injury to the kidneys and cause a reduction in the reserve power of those kidneys. We have, therefore, in these individuals who have a focus of chronic sepsis a reason why their elimination is not up to normal.

The immediate cause of the syndrome of symptoms known as toxæmia of pregnancy cannot be found in the toxins of chronic sepsis. It seems clear that this cause must have a closer relationship to the pregnant state.

I have tried to show that the case of Mrs. M. is strong evidence that the immediate cause cannot be found in the products of conception.

We know beyond doubt that the normal physiological excretory products of the system are injurious to that system if retained. We also know that there is no other condition in nature where there is such a large quantity of these normal excretory products to be excreted as during a developing pregnancy.

Is it, therefore, a reasonable hypothesis to say that the symptoms of toxæmia of pregnancy with or without convulsions are caused by the retention of the normal physiological waste products of the developing pregnancy, this retention being due to the damaged functional power of the kidneys, which damage has been brought about by the toxins of chronic sepsis in the blood? There is clinical evidence that this hypothesis is true.

It is a most striking coincidence that the symptoms resulting from chronic nephritis are so similar to those which occur in toxæmia of pregnancy and eclampsia that it can be safely said that there are no symptoms of chronic nephritis which do not occur in toxæmia of pregnancy and eclampsia. This great similarity of symptoms in itself implies a common cause.

If we assume that the symptoms of chronic nephritis are due to the retention of normal physiological waste products, that it is these products which stimulate the rise in blood-pressure, that they stimulate the symptoms of headache, blurred vision, œdema, vomiting, and lastly convulsions, and that this retention is due to a lack of eliminative functional power on the part of the kidneys, is not the likeness of the two diseases made clear?

In the case of a chronic nephritic the excretory function of the kidneys is inhibited in the same way as in the case of an eclamptic. The demand made upon the kidney function in the former is, however, very different from that in the latter. The quantity of excretory products which the kidneys are called upon to excrete in normal life during the development of a chronic nephritis is more or less constant and the reserve power of the kidneys does not break down under this constant until the damage has lowered the reserve power to a point where the kidneys can not carry off the normal amount of waste products necessary to maintain life.

The demand made upon the kidney function during a developing pregnancy is not a constant but a gradually increasing strain upon that function. It is therefore an acute process as compared to the development of a chronic nephritis.

The end-results so far as symptoms are concerned resemble each other just as we should expect and it is for this reason that I believe the cause of these symptoms is the retained waste products of physiological metabolism which we know to be injurious if retained.

A vicious circle is established. The toxins of chronic sepsis, by their inhibition of the kidney functions, cause a retention of the normal waste products of the body. These waste products are also injurious to the

excretory function of the kidneys when in abnormal concentration in the blood.

Nature's endeavor to meet this situation is reflected in the rise in blood-pressure. The rise in blood-pressure has been found to be among the earliest evidences of the presence of this disease of toxæmia of pregnancy. Irving states in his review of 5,000 cases at the Boston Lying-in Hospital that the rise in blood-pressure precedes the appearance of albumin twice as often as it follows it.

What is the immediate cause of the rise of blood-pressure? Is it the toxins from chronic sepsis or is it the retention of metabolic waste products,—or is it the combination of the two? It seems to me that the rise in blood-pressure cannot be due solely to the presence of the toxins of sepsis, because there are so many instances where we know that the blood is full of toxins of acute disease without a rise in blood-pressure.

It is therefore probable that the rise of blood-pressure is due to the retained products of metabolic waste either alone or in combination with the toxins of chronic sepsis.

It is generally conceded that the rise in blood-pressure is due to stimulation of the adrenal glands and that this rise in blood-pressure is a conservative process, an endeavor on the part of the system to increase the elimination by bringing more blood to the kidneys in a given space of time.

The rise in blood-pressure arising from stimulation of the adrenals is due to a constriction of the peripheral vessels, that is an increased resistance to the flow of the blood. This increased resistance must raise the diastolic pressure in the arteries provided that the supply of force from the heart remains the same. This increase in the diastolic pressure must put an increased load upon the heart muscle in order to keep up the normal pulse pressure. In fact, unless the heart compensates for this extra load there will be no rise in blood-pressure, as the heart must be the only source of the arterial blood-pressure.

It is at this point that we have the dividing line between two types of toxæmia of pregnancy; the first class being the typical example, where the blood-pressure continues to rise in proportion to the amount of toxæmia present, which rise is due to the compensation of the heart muscle to the demands made upon it. The second class is less common, but a more serious type, in which we find evidences of the severity of the toxæmia out of proportion to the elevation of the blood-pressure. Such cases may be characterized as those with headaches, dizzy spells, blurring of vision, œdema, and albumin and casts in the urine, with only a moderate or no rise in blood-pressure. This second class of cases is clinically well known as the more serious type. The rise in blood-pressure the main object of which is to increase the elimination is what these cases lack. This lack is primarily due to a failure of the heart muscle to respond to the demand made upon it. By failure of the heart to raise the blood-pressure and thus increase the elimination, the toxins increase in concentration in the blood and do more damage to the liver, kidneys, and placenta.

Many cases are reported in the literature of the dental profession as well as of the medical profession which demonstrate the good results obtained in cases of arterial hypertension by removing all foci of infection from the teeth. It has also been recently reported that certain cases of albuminuria have been cured by eliminating chronic sepsis from the teeth. If these reports are true, and I am convinced that they are, we have further evidence to corroborate the above theory.

Once it is admitted that a focus of chronic sepsis can cause arterial hypertension or albuminuria it is then necessary to admit that the coexistence of toxæmia of pregnancy and a focus of chronic sepsis is of the utmost importance, for is it not these two signs occurring in the presence of a pregnancy on which we base our diagnosis?

Is this theory consistent with the pathological findings in the liver and placenta, which are associated with this disease?

The infarct is regarded by many to be the source of the poison which causes the trouble. If we regard the infarct as the result of this poison are not the findings more consistent?

We know that the toxins of sepsis cause an inflammatory reaction in the kidneys. Why

should not this same poison cause an inflammatory reaction in the villous membrane? It should be remembered that this villous membrane is constantly being enlarged throughout pregnancy and that it is on the edge of the placenta that this productive process is going on most rapidly. Every tissue which is in the process of production is in its stage of lowest resistance. It is therefore a tissue which would be more liable to damage from any toxins in the blood. It has been my experience to find most infarcts of any size located on the edge of the placenta and that there is frequently an indentation in the circular circumference of the placenta at this point. This indentation is evidence of the destruction of the villous membrane which prevents its further growth at this point. Is it not reasonable to regard the infarct as an area of villous membrane damaged by toxins in the blood with nature's healing process superimposed?

The central necrosis in the liver found at autopsy is most consistent. Is this not exactly what we should expect to find in view of this theory? The death of the individual represents an acute overwhelming toxæmia which the system has been unable to combat. The liver is known to be the greatest detoxifying organ of the body. If this detoxifying power is overcome it is most natural to expect that that same organ would be most consistently injured.

To return to the infarct. The association of antepartum hæmorrhage with toxæmia of pregnancy has long been recognized. As I have stated above, the injury to the placenta from a toxin in the blood is most liable to occur on its edge. If this damage is sufficient to cause a partial detachment of the placenta at this point, it would certainly result in hæmorrhage.

Here again the theory is consistent with clinical evidence.

If the above theory as to the etiology of toxæmia of pregnancy is correct, it is a logical conclusion that we must have a postpartum toxæmia of pregnancy as well as a postpartum eclampsia.

I will report two typical cases of postpartum toxæmia of pregnancy.

Mrs Pa., a 36-year old primipara, suffered from postpartum eclampsia. On discharge from the hospital she had a blood-pressure of 150 systolic. Five months later she came to me because of shortness of breath, vomiting, headache (severe), and specks before her eyes. She said she had felt perfectly well since discharge from the hospital until about a week ago. Her blood-pressure at this visit was 195-140 and she complained of severe pain in the right epigastrium. While in the office she had a moderate nosebleed. She went directly to the hospital and remained in bed for one week.

Inspection of her mouth showed the following points. Several gold crowns. One lower left molar had inflamed gums. No toothache. On second night in hospital she had severe neuralgia on right side of face and ear with toothache.

At the end of a week her blood-pressure dropped to 150 and the patient felt much relieved. Tenderness in abdomen gone.

X-rays of her teeth were taken by a dentist who was very distinctly one of the nonco-operative kind. He did not take them all and it was only after repeated questions that he admitted that he found anything. The final outcome was the removal of the molar in the lower jaw which the patient said had "an awful foul odor," but the dentist informed me that there was not much the matter with it.

Following the removal of the teeth, the patient had two weeks of considerable discomfort, having two severe attacks of epigastric pain with shortness of breath soon after the extraction. At the end of the two weeks she reported. Her blood-pressure was 160-120. The urine was negative except for light specific gravity 1010. She said she now felt better than before the extraction. Numerous small pustules appeared on her breast and legs following extraction of the tooth.

The X-ray examination is very unsatisfactory in this case, as it is not complete. Although a tooth with abscess was found on the left side, I am convinced that there is still trouble somewhere on the right side in view of the definite neuralgia experienced on the right side of her face while she was under observation in the hospital.

The history of the second case of postpartum toxæmia is as follows:

Mrs. W., age 27; primipara; born in Maryland; married 3 years. Family history negative. The patient had rheumatism when 8 years old. She has had some stomach trouble termed "gastritis." Operated upon June, 1916; dilatation and curettage for sterility.

The patient came under my observation in December, 1916. Her last period was October 15, 1916. Five days before this visit she had a little bleeding which had continued. The patient remained in bed for nearly six weeks because of intermittent bleeding which was accompanied by considerable nausea and vomiting. There was another slight bleeding

spell in March which quieted down in a few days. The blood-pressure and urine remained normal during this period.

From March until the time of delivery nothing abnormal appeared except a rise in blood-pressure in June, 1917, to 145-90 at which time there were no other symptoms except difficulty in sleeping. Forceps delivery; convalescence normal.

Three months after delivery I was called on account of a return of epigastric pain, stiffness of joints and indefinite feeling of lassitude.

Blood-pressure was found to be 145-100. Inspection of teeth revealed nothing except one gold crown. A complete X-ray of the teeth was recommended, and although the patient denied any symptoms from them, five pus cavities were revealed, the largest at the root of the gold crown tooth. Treatment of the teeth has not yet been completed.

I am convinced now that the evidence of chronic sepsis at the roots of five teeth has been established, that the difficulties which she experienced in the early part of her pregnancy, that is, the bleeding and gastric upset, were probably due to the toxins of this chronic sepsis. Note the rise of blood-pressure which occurred in June. Here we have a sufficient rise to suspect a beginning toxæmia.

Assuming that this theory on the etiology of toxæmia of pregnancy is the correct one, what does it offer in the treatment of the disease? Up to the present time I have not endeavored to treat this disease by attacking the foci of sepsis in the teeth, and I have refrained for what I believe is a very good reason.

Suppose a woman develops the signs of approaching toxæmia of pregnancy during or after her seventh month. According to the theory this is a declaration on the part of her system that the excretory function of the kidneys is not equal to the demand. I have not felt justified in having the foci of sepsis interfered with. If the tooth is extracted or dental treatment with a view to draining the tooth is instituted, this treatment will necessarily throw more toxins into the system and may thereby inhibit the functional powe · of the kidneys further, with the result of bringing on convulsions or serious toxæmic symptoms.

This view of the situation has been supported to a certain extent in the postpartum treatment of those cases which I have had the opportunity to watch. In one case (Mrs. Pa. cited above) the patient had two weeks of great discomfort from headaches, severe epigastric pain and nosebleeds with a general feeling of malaise following the pulling of one of her teeth. Another case (Mrs. W. cited above) had her blood-pressure rise to 150-105 from normal, following the pulling of two teeth with pus at the roots.

I do believe, however, that all cases should have dental treatment immediately following the end of the puerperium. By cleaning up these foci of sepsis before another pregnancy we can at least practice the principles of prophylaxis and place the patient in a position where she can enter upon another pregnancy without fear of the return of toxæmia of pregnancy with all its dangers to herself and child which that implies.

There are two very unfortunate features in the treatment of this condition; first, the details of the treatment lie in another's hands, and second, the average dentist does not work with the assistance of X-ray examinations. There is too the great disadvantage that completely to eradicate the sepsis from the teeth, the treatment must last for months, which makes it very expensive.

However, if the truth of this theory can be supported by the observation of others to the extent that it shall be accepted, methods of treatment will undoubtedly be forthcoming.

In conclusion I do not wish to imply that the focus of chronic sepsis must necessarily be found in the teeth. I believe that any focus of chronic sepsis, such as a chronic tonsillar abscess and the like, may bring about the same result. A focus of chronic infection draining toxins into the blood stream is the essential condition.

SUMMARY.

The apparent inconsistency of the clinical evidence that the primary cause of toxæmia of pregnancy with or without convulsions is not in the products of conception and yet the termination of the pregnancy causes an abatement of the symptoms is thus explained.

The immediate cause of the symptoms of the disease is the retention of the normal physiological waste products of the developing pregnancy. The primary cause, or the cause of the retention, is the inhibitory effect of the toxins of chronic sepsis on the excretory functions of the kidneys.

The increased incidence of this disease in those individuals who have a pre-existing chronic nephritis proves the intimate relation between the occurrence of symptoms and the damaged excretory function of the kidneys.

By terminating the pregnancy the main supply of these excretory products is removed. Postpartum eclampsia and postpartum toxæmia of pregnancy are caused by an increase in the inhibition of the functions of the kidney following delivery, due to an increase in the percentage of concentration of the toxins of chronic sepsis in the blood, thereby causing an exhaustion of the remaining excretory reserve power to a point where the retention of the normal metabolic waste products in the system causes the symptoms of eclampsia and toxæmia.

DIAGNOSIS AND TREATMENT OF CHRONIC DUODENAL OBSTRUCTION[1]

By EDWARD L. KELLOGG, M.D., F.A.C.S., New York
Director Surgery, Gouverneur Hospital; Professor, Gastro-Enterology Polyclinic Medical School

THE impression seems to be general that chronic obstruction of the duodenum is rare and difficult to diagnosticate. A great deal has been written on acute postoperative dilatation, but with a few exceptions the literature of chronic obstruction consists of reports of cases secondary to ulcer.

Lewis Dwight, prior to 1897, made a series of wax casts of the duodenum and in that year reported briefly his findings from a purely anatomical point of view. The casts are still preserved at Harvard and through the courtesy of Dr. Bremner I have had an opportunity to study them.

Only in infants did I observe the G shaped duodenum of uniform caliber, which the anatomies picture. In these cases there was little evidence of the angulation so evident in the adult duodenum. In the adult cases the variation in size and shape was marked. There were, however, certain anatomical markings uniformly present. The first portion lacked the deep striæ observed over the rest of the duodenum, the mucous membrane of this portion apparently being like that of the stomach. At the junction of first and second portions there was a marked constriction in every case.

The junction of the second and third portions was not always clearly defined but in about half the cases a distinct angulation was in evidence and some of the specimens show a constriction at this point.

The transverse portion varied greatly in length and circumference. Most of them showed a distinct groove on the superior and anterior surface caused by the superior mesenteric artery and beyond this an angulation at the junction with the jejunum. In all these casts, the posterior surface of the transverse portion showed a groove due to pressure of the spine alone or spine and aorta together. Some of them showed a fourth ascending portion which was absent in others.

The most important lesson to be learned from this study is that the duodenum is placed at a disadvantage in the matter of drainage and is easily subjected to mechanical interference.

The papers of Anders, Bloodgood, Stavely, Codman and Vanderhoof are worthy of perusal. Bloodgood calls attention to the association of a large prolapsed cæcum and short mesentery with dilatation of the duodenum. Stavely reports what appears to be the first case of primary duodenojejunostomy, performed in 1910. These papers give one the impression that the condition is obscure and the diagnosis impossible unless made by the X-ray or after the abdomen is opened.

It is my belief that the condition is frequently present and the diagnosis can usually be made by the history and physical examination even in cases in which it is not demonstrated by the roentgenologist.

From my private files I have taken the

[1] Read before the Stamford Medical Society, and Ohio County Medical Society, Wheeling, West Virginia.

following partial list: twelve cases treated without operation; one case treated by gastro-enterostomy; two cases treated by gastro-enterostomy plus duodenojejunostomy; three cases treated by operation upon the cæcum and ascending colon; five cases treated by division of adhesions; eighteen cases treated by primary duodenojejunostomy; three cases of viscious circle treated by duodenojejunostomy after gastro-enterostomy.

I am convinced that this condition has been present in many earlier cases, some being relieved by operation or treatment for other conditions, while in others the results have been unsatisfactory from failure to recognize this factor in the production of symptoms.

ETIOLOGY

At the operating table we have learned that the obstruction may involve the first portion of the duodenum only, the first and second portions, or the entire duodenum.

When the first portion only is dilated the junction of the first and second portions is angulated, caused by the duodenum being drawn up close to the liver by contraction of mesenteric bands or by adhesions binding together the first and second portions, or by gastroptosis, the duodenum remaining fixed. In the second group giving dilatation of the first and second portions it has appeared to be the result of adhesions extending from the gall-bladder or hepatic flexure of the colon.

In obstruction of the entire duodenum I have frequently found the condition described by Bloodgood, i. e., a redundant cæcum displaced into the pelvis with a short mesentery at portion of ileum near the cæcum. In this group, I believe, the significant factor has been the dropping of the hepatic flexure which causes a straight pull of the distended bowel from the splenic flexure across the point of union of duodenum with jejunum. The condition may exist without prolapse of the cæcum, and the following causes are suggested.

Duodenojejunal kink from prolapsed cæcum and hepatic flexure, prolapse of transverse colon, adhesions from cholecystites, ulcer, inflammation at duodenojejunal junction; constriction of opening in mesentery through which the duodenum passes, faulty development of the lower thoracic region, gastroptosis with stretching of the attachment of the second portion of duodenum, disease of pancreas.

It is certain that frequently a considerable degree of obstruction exists without symptoms, the condition being found at operation or by X-ray examination.

A study of the clinical cases shows two sets of symptoms: *toxic and mechanical.* In some cases both are present; in others one group only.

Some of the *toxic symptoms* are usually in evidence, i.e., headache, mental depression, lack of strength, disturbed heart action, cold extremities, skin eruptions.

Headache has been most frequently present. It is usually temporal, sometimes occipital and is constant or occurs several hours after meals. Often it is associated with nausea and may be relieved by eating.

The mental depression may be very marked. Impairment of vigor is more frequently complained of.

The disturbance of heart action may take the form of tachycardia or bradycardia or simple irregularity of action. These patients are apt to complain of bilious attacks, i. e. headache, nausea and vomiting of bile.

Mechanical symptoms. In obstruction of first portion only, the symptoms are those of partial pyloric obstruction without the special symptoms described below, due to interference with bile drainage.

In obstruction of second and third portions, the mechanical symptoms will vary according to the problem presenting. If the case is one in which interference is due to a prolapsed cæcum dragging on the mesentery, we may find periods of comfort so long as the colon is empty, but with an attack of constipation the drag of the distended cæcum inaugurates an attack. This is, in my estimation, the mechanism of the so-called bilious attack.

The amount of resistance to back pressure offered by the pylorus will modify the symptoms. With a resistant pylorus pain is prominent; with a relaxed pylorus regurgitation or vomiting of bile is predominant.

I have found two distinct points of discomfort: (1) A pain or dull ache just to the left of the median line and slightly above the navel (presumably the duodenojejunal junction). This pain is frequently relieved by deep pressure. (2) Pain located to the right of the median line and above the navel extending up under the liver and through to the back. It may be colic-like (due to peristaltic unrest) or steady and dull (due to distention), often lasting until relieved by vomiting. Frequently the patients obtain relief by deep pressure in the median line of abdomen below the navel (presumably by unlocking the duodenojejunal kink).

Belching without fermentation may be a troublesome symptom. *Vomiting of bile* may follow the attack of pain, apparently the resisting pylorus giving way. In some cases the patient feels something give, the pain subsides and vomiting or regurgitation of bile follows. Often bile works back into the stomach without pain (incompetent pylorus), and is vomited or regurgitated or may be found if the stomach is washed.

PHYSICAL EXAMINATION

Hayes has taught us to recognize dilatation of the duodenum by the physical examination of the abdomen. He writes as follows:

> Dilated duodenum is shown by a marked tympanites in the area behind the right rectus muscle to the right of or posterior to the pylorus and lying between the liver above and the transverse colon below. The dilated duodenum is readily mapped out by the employment of percussion with pressure. Owing to the kinking of the duodenojejunal junction the duodenum is found to be distended with gas, often two or three fingers in diameter. This duodenal inflation is frequently associated with gastric stagnation or retention.
>
> Pressure paradox. In cases showing a dilated duodenum, pressure is made backward and upward for about thirty seconds by the hand placed just below the umbilicus, the patient being in a semirecumbent or reclining position. It might be thought that this would increase the amount of gas present in the duodenum; on the contrary, in the type of case we are considering it will usually result in the undoing of the duodenojejunal kink, permitting the duodenum to empty itself, as shown by a relatively dull percussion note or marked diminution in the size of the tympanitic area. At the same time it is often possible to hear and feel the gas escape as it rushes into the jejunum.

The accuracy of this procedure has been questioned but I wish to place myself on record as indorsing his statements. Not all cases can be recognized in this way at all times, however, since the duodenum may not be distended at time of examination or may be obscured by a distended colon or stomach.

The X-ray reports of duodenal obstruction are lacking in uniformity; involvement of the first portion is generally recognized, but of the entire duodenum less frequently. This is probably due to the fact that the duodenum is in part overlapped by the stomach and is not easily demonstrated except by special technique. The procedures suggested by Quimby which seem to help in this demonstration are to massage the stomach vigorously, forcing the bismuth into duodenum and to hold the stomach up toward the dome of the diaphragm while the picture is being taken. It should be remembered that considerable obstruction may exist without marked dilatation if the pylorus is not resistant and that in the type of kink at duodenojejunal junction due to prolapsed cæcum and hepatic flexure, a preliminary cathartic may result in a failure to demonstrate the condition.

It is my custom to inspect the duodenum in all cases of operation upon the digestive tract and it is my belief that the duodenum should be regarded with suspicion if, when the transverse colon is lifted up, it can be seen bulging through the lower layer of the mesocolon.

TREATMENT

The majority of cases do not require surgery. They are amenable to the treatment given for enteroptosis or intestinal stasis: abdominal support, sleeping with foot of bed elevated, resting after meals in recumbent position (bed elevated), abdominal massage, colon irrigations, duodenal irrigations, mineral oil, cathartics, rest cure combined with forced feeding.

The abdominal support should be applied with a view to lifting up the transverse colon and so liberating the kink. The type of support will be like that for gastroptosis, varying somewhat according to shape of abdomen.

Fig. 1. Wax cast. Duodenum of an infant.

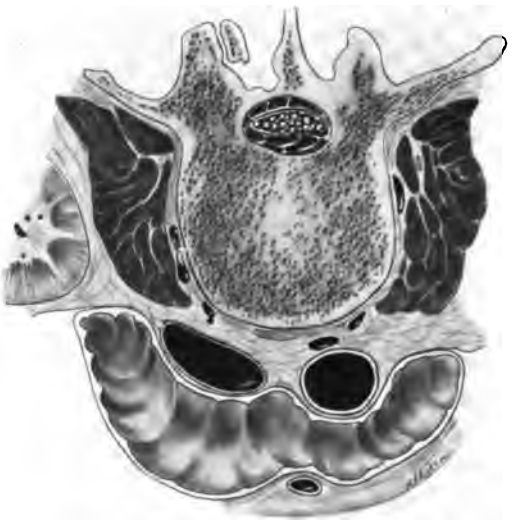

Fig. 2. Frozen section of the human body at the level of transverse portion of the duodenum showing the relation of same to the vertebræ, aorta, and vena cava posteriorly and superior mesenteric artery anteriorly. Note the narrowing of caliber of the duodenum where it passes between the aorta and the superior mesenteric artery.

For the thin retracted abdomen the Curtis-Lane supporter is the most satisfactory while the pendulous protuberent abdomen can be held up by any belt or binder that produces its maximum pressure just above the pubes and iliac crest. For temporary support the adhesive plaster belt (Achilles Rose) will be found very useful. Sleeping with the foot of the bed elevated 8 to 12 inches, is an important therapeutic measure.

By this procedure the drag of prolapsed intestine ceases and the duodenum has an opportunity to empty completely and thus to minimize the infection and irritation.

Resting after meals in the same position is helpful for the same reasons.

In applying abdominal massage the object is to empty the cæcum and ascending colon and unlock the kink. I instruct the patients to press the abdomen backward and upward below the navel with the left hand while with the right hand pressure downward is exerted over the duodenum. For the colon, pressure is exerted upward on right side, transversely at level of navel and downward on the left. A massage ball weighing six or eight pounds will be a great aid in carrying out this treatment successfully.

The rest cure and forced feeding checks the duodenal irritation and infection and diminishes pressure on the duodenum by increasing the amount of adipose tissue in the abdomen. Codman has pointed out that fat people have less pressure on the duodenum than thin people, for fat in the mesentery distributes the pressure, while in thin people the main trunk of the superior mesenteric artery presses the duodenum directly against the bodies of the vertebra.

Duodenal irrigations furnish a means of combating the duodenal infection and irritation, and at the same time help to control the general intestinal toxæmia.

SURGICAL TREATMENT

The surgical procedure will vary with the cause and degree of obstruction.

In obstruction of the first portion only, dividing the adhesions transversely and suturing longitudinally, so as to drop the duodenum, may be indicated, or if stomach is prolapsed the shortening of the gastrohepatic omentum by Beyea's operation, relieves the obstruction. In obstruction of the second portion it is usually a problem of treating adhesions.

In involvement of the entire duodenum, if not too far advanced and plainly secondary to trouble with the cæcum and ascending

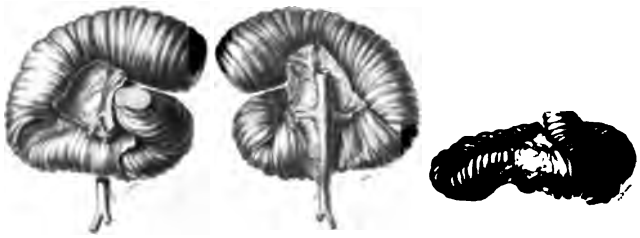

Fig. 3. Fig. 4. Fig. 5.

Fig. 3. Wax cast. Duodenum of a fourteen-year-old child. This duodenum appears to be normal in size and shape. The aorta and superior mesenteric artery are *in situ*.

Fig. 4. Same case. Posterior view, aorta *in situ*.

Fig. 5. Same case taken in horizontal position. This view is shown particularly to demonstrate the relation of the transverse portion to the aorta and superior mesenteric artery. Note the groove to the left of the aorta, presumably for the vena cava.



Fig. 6. Fig. 7. Fig. 8.

Fig. 6. Adult duodenum. Showing acute angle at junction of the first and second portions and constriction in the third portion, probably caused by the superior mesenteric artery. Note the acute angle at the junction with the jejunum.

Fig. 7. Adult duodenum. Showing the narrowing at the junction of the first and second and second and third portions. The fourth ascending portion is absent.

Fig. 8. Adult duodenum. Note the deep notch caused by superior mesenteric artery on the superior and anterior surface of the transverse portion.

colon, I have been content to relieve the cause by right sided resection of the colon or plication and anchoring of the same, by supporting the stomach and transverse colon (operations of Beyea and Coffey), or by division of adhesions.

Gastro-enterostomy has been performed, but with a better understanding of the condition, I consider the procedure obsolete in spite of the fact that the case in which I used the method was benefited. When dilatation is marked, the operation of choice, either alone or accompanied with other indicated procedure, is duodenojejunostomy.

In my series there has been no mortality and in every case there has been either improvement or complete relief of symptoms although sufficient time has not yet elapsed to speak definitely of end-results.

The procedure is only a little more difficult than gastro-enterostomy; the technique is much the same. The point of approach is through the transverse mesocolon to the right of the vertebral column. The duodenum can be easily mobilized by blunt dissection but this is seldom necessary since the dilatation causes it easily to present at point of operation. The convalescence is usually uneventful.

The following cases are reported briefly as examples of the varying problems which present:

Fig. 9.

Fig. 10.

Fig. 11.

Fig. 9. Adult duodenum. Showing a dropping of the angle at the second and third portions and an unusually long fourth or ascending portion.

Fig. 10. Under surface (Fig. 9) showing vertical groove caused by aorta. This is present in every case. It may be artificial due to injection of the aorta, but is suggestive as a possible point of pressure.

Fig. 11. Adult duodenum. Showing dilatation of the first, second, and third portions, apparently due to exaggeration of the superior mesenteric groove.

Fig. 12.

Fig. 13.

Fig. 14.

Fig. 12. Adult duodenum. The first point of constriction is the pyloric ring. The first portion of the duodenum shows marked dilatation due to constriction at the junction to the first and second portions. Second and third portions are dilated, due to constriction at the extreme left of the third portion. The cause of this is not clear, as it is beyond the notch made by the superior mesenteric artery. Probably the angulation at the junction with the jejunum is responsible.

Fig. 13. Adult duodenum. An unusual case; the second third and fourth portions are continuous, extending to the left of the aorta farther than usual.

Fig. 14. Adult duodenum. Interesting because of its peculiar shape, but particularly because of diverticula.

CASE 1. T. J. L., male, age 30. Present illness commenced five years ago. The patient had violent epigastric pain one-half hour after meals; duration short; sometimes a second attack one and one-half hours after meals. Often wakes up with pain from 11 p.m. to 1 a.m. Sometimes eating gives relief.

Examination shows tenderness to pressure over the epigastrium and at point to left and slightly above umbilicus and at hepatic flexure. The duodenum is apparently dilated but this was not demonstrated with certainty. No blood was found by any of the clinical methods.

The X-ray disclosed ulcer and adhesions of duodenum. An operation was performed for duodenal ulcer.

Pathology. A small indurated ulcer was found on the duodenal side of the pylorus; the pyloric ring being partially occluded. The duodenum was considerably dilated being visible three fingers' breadth below the transverse mesocolon when the colon was drawn out of the wound. The jejunum was fastened to the under surface of the mesocolon by a long ligament of Trietz.

Operation. Posterior gastro-enterostomy and duodenojejunostomy. The latter procedure was undertaken with the feeling that the dilated duodenum would predispose to a viscious circle unless it was drained. Convalescence was uneventful, and cure appears to be complete.

CASE 2. M. B., female, age 21. For six months the patient has complained almost daily of colic in upper abdomen to right of navel, extending up under liver and through to back. The pain has no relation to the taking of food but is worse when patient is constipated. Physical examination shows cæcum movable and distended with gas. Duodenum dilated on percussion; upward pressure below trans-

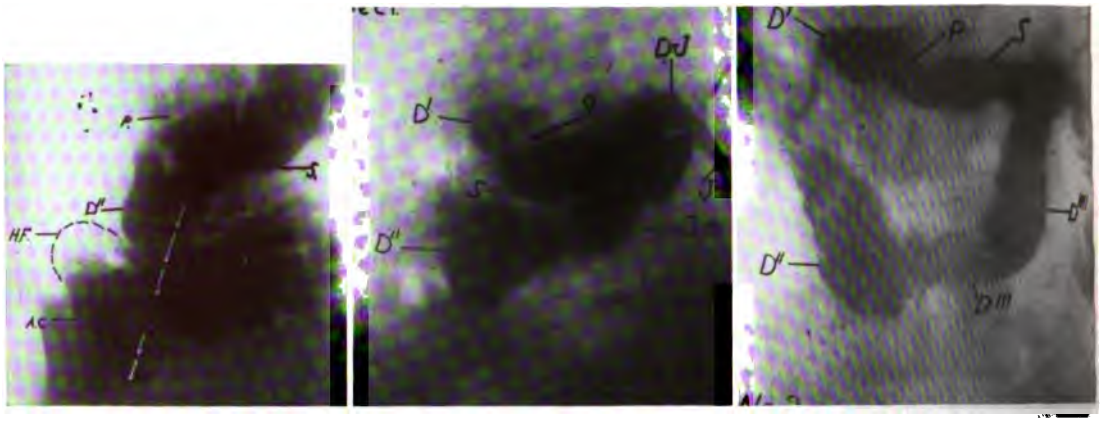

Fig. 15. Fig. 16. Fig. 17.

Fig. 15. M. B., Case 2. Taken after the injection and partial evacuation of an opaque enema, followed by the administration of an opaque meal, after a portion of the meal has been forced by manipulation into the duodenum. *S*, stomach; *P*, pylorus; *D''*, *D'''*, duodenum; *HF*, hepatic flexure; *AC*, ascending colon; *C*, cæcum. The white line of arrows indicates the direction of the line of traction when the patient is in the erect position and the cæcum is down.

Fig. 16. Case of W. A. K. Taken after the administration of an opaque meal. A portion of the stomach contents was discharged into the duodenum by manipulation with the operator's hands. *S*, stomach; *D'*, first portion of the duodenum; *D''* and *D''''*, second and fourth portions of the duodenum; *DJ*, juncture of the duodenum with the jejunum; *J*, first portion of the jejunum.

Fig. 17. Case of W. A. K. Same case as Fig. 16, with stomach pushed upward by pressure of the hand, exposing a large and dilated duodenum; this duodenum shows four distinct portions. *S*, stomach; *P*, pylorus; *D'*, first portion of the duodenum; *D''*, second portion of the duodenum; *D'''*, third portion of the duodenum; *D''''*, fourth portion of the duodenum. (This case is not reported in the text. Symptoms are stubborn constipation; recurring headaches; pain suggesting duodenal ulcer.)

verse colon liberates gas from duodenum. X-ray examination shows prolapsed cæcum and hepatic flexure and marked dilatation of the duodenum due to obstruction near its junction with the jejunum.

Treatment. A Rose belt was applied and later a combination corset and belt. The patient sleeps with the foot of the bed elevated, duodenal irrigations are given, and mineral oil, digestive ferments, and constipation diet prescribed.

Result. Immediate relief of symptoms. There is no pain while the patient wears the belt but pain returned when the belt was removed. The patient has gained in weight.

This is offered as a type of case responding to medical treatment. The absence of vomiting and bile regurgitation indicates that the pylorus functionates normally.

CASE 3. Mrs. B. B., age 47, had suffered from digestive troubles for 2½ years. Two operations had been performed, hysterectomy and gall-bladder drainage, without improvement in digestive symptoms. She complains of hyperæsthesia of the stomach, œsophagus and tongue.

Every week or two she vomits large quantities of bile and in the interim frequently regurgitates it. There is no pain but a very sore feeling in the upper abdomen. She is generally weak. Examination shows a slight resistance over the upper part of right rectus. The duodenum is moderately dilated. Lavage of fasting stomach shows bile constantly present. X-ray report suggests duodenal ulcer but makes no suggestion of duodenal dilatation.

Clinical diagnosis: duodenal obstruction with moderate dilatation, pylorus incompetent or non-resistant.

Operation, December 5. Pathology (no ulcer demonstrated). Adhesions at hepatic flexure of colon involving gall-bladder and duodenum, the latter dilated extending for three fingers' breadth below attachment of transverse colon; pylorus dilated. The adhesions were divided; duodeno-jejunostomy performed.

Result. The patient has ceased to vomit and regurgitate bile, and the soreness in the upper abdomen has disappeared. The hyperæsthesia has improved, the appetite has improved, and she is gaining weight.

This is the type of duodenal obstruction with incompetent pylorus shown by regurgitation of large quantities of bile without pain. The incompetent pylorus may account for failure of X-ray to demonstrate the condition.

CASE 4. E. F. G., male, age 25, commenced three years ago, to suffer attacks of pain with intervals of good health. Two and one-half hours after meals he has severe epigastric pain, relieved by forced vomiting. The vomitus is first sour and later

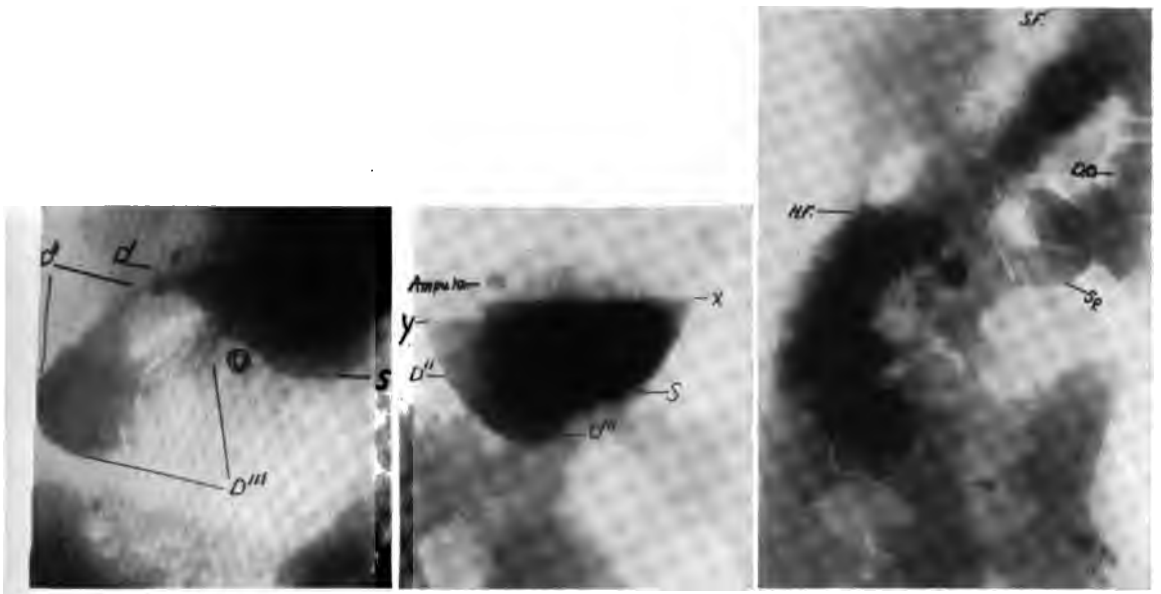

Fig. 18. Fig. 19. Fig. 20.

Fig. 18. Case of Mrs. W. Stomach, marked *S*, is pushed upward by hand of the operator; this exposes the contents of the duodenum, marked *D*. The pressure of the hand also displaces the duodenum slightly to the right.

Fig. 19. Case of Mrs. W. Stomach and duodenum in normal position with patient erect. The stomach contents are exhibited as a pool, of which the upper margin is marked *X*. The contents of the duodenum, *D*, form a pool at a slightly lower level, the upper margin of which is marked *Y*. It extends below and behind the greater curvature of the stomach.

Fig. 20. Case of Mrs. W. After administration of enema, exhibits the low position of the cæcum, marked *C*, and the drop of the hepatic flexure, marked *HF*, predisposing to duodenal obstruction. (Figs. 18, 19, and 20 refer to Case 5 reported above.)

bitter. There has been no retention vomiting. Constipation is marked. He has lost 20 pounds.

Examination. The cæcum is dilated, and there is diminished resistance in the right iliac fossa. The stomach is slightly ptosed. There is moderate *tenderness* in the region of the pylorus. The duodenum is dilated. The stomach contains hydrochloric acid in excess and empties slowly after motor meal, fasting stomach empty. There is occult blood in the fæces, and repeated thread tests show blood stain on duodenal portion of thread. X-ray examination shows penetrating ulcer in first portion of duodenum.

Clinical diagnosis: duodenal ulcer; dilated duodenum. *Operation, October 4. Pathology*. The cæcum is dilated and adherent to the abdominal wall. There is a small indurated duodenal ulcer, just beyond the pylorus. The pylorus is not obstructed. The duodenum is very much dilated, apparently due to *inflammatory* thickening and narrowing of jejunum.

Duodenojejunostomy was performed since in my judgment the duodenal obstruction was responsible for the ulceration. (Had gastro-enterostomy been performed it would have been necessary to do a pyloric exclusion and the obstruction of the duodenum would have remained).

Recovery was uneventful and complete.

So far as I can learn this is the first recorded case of duodenojejunostomy for duodenal ulcer.

CASE 5. Mrs. H. W. W., age 39. Three years ago the patient had an operation for appendicitis and floating kidney. The symptoms were relieved for two months. Following this she had a series of attacks described as follows:

First attack: Woke up at night with severe pain across the upper abdomen extending up under the sternum. The pain was so severe that she thought she would go insane. Temperature was subnormal.

Second attack: Onset after swimming preceded by three or four days of depression and constipation. Severe pain in same location but not cramp-like. She felt faint and her palor was marked. The pain was constant for a month. No vomiting; temperature was subnormal.

The third attack followed overexertion; it was cramp-like, with vomiting, and lasted two weeks, with temperature normal. Following onset she had a dull pain and soreness through the right side of the upper abdomen.

Fourth attack came on a week ago following a cold, sudden violent cramp-like pain, in the same location. There was no vomiting or faintness. The pain comes about two hours after breakfast.

This last attack continues; she can feel and hear gas moving about causing distention of upper abdomen. She wants to eructate gas but cannot. The symptoms increase as the day advances and are not affected by food. The symptoms gradually subside after retiring but keep her from sleeping in the early part of the night.

Constipation has been constant and stubborn for eighteen years but suddenly became much worse after second attack described above. Vomiting on the few occasions on which it has occurred shows only a little bile. Mental depression is marked.

Examination. The abdominal walls are relaxed. There is diminished resistance in the right iliac fossa. Gas can be heard gurgling and splashing in the cæcum. The stomach extends from the seventh rib to three fingers' breadth below navel. The dilated duodenum can be easily demonstrated by deep percussion; pressure paradox present.

The X-ray shows adhesions involving the terminal portion of the duodenum obstructing this structure when the patient is erect, and causing dilatation of duodenum; ptosis of cæcum; and bands constricting the ascending colon.

Clinical diagnosis. Prolapsed and dilated cæcum, dilated duodenum due to duodenojejunal kink.

Operation February 6. Pathology. Cæcum markedly dilated and prolapsed into pelvis. Hepatic flexure had given way completely so that traction on cæcum caused a direct pull from splenic flexure across the mesentery resulting in pressure at duodenojejunal junction. The duodenum was markedly dilated, the lower border of transverse portion protruding through the mesentery four fingers' breadth below the transverse colon when the latter was lifted out of the abdomen. There was a long ligament of Trietz.

A longitudinal plication of the cæcum and ascending colon, restoration of hepatic flexure and anchoring of cæcum to posterior abdominal wall—duodeno-jejunostomy—were performed.

Result. Convalescence was uneventful. The bowels are moving regularly, duodenal symptoms have entirely disappeared, and the patient is gaining in weight and strength.

This case seems to be identical with those described by Bloodgood which are due to prolapsed cæcum and ascending colon, causing a kink by dragging on the mesenteric vessels. The pylorus is functionating which accounts for the absence of bile in the stomach and the severity of the pain. Note that she describes both types of pain, i. e. dull steady, due to distention and colic-like due to peristaltic unrest.

CONCLUSIONS

Chronic duodenal obstruction frequently occurs, sometimes as part of a general intestinal stasis but also independently. The diagnosis can usually be made from the history and physical examination, and may be confirmed by an X-ray examination, when special technique is employed. An X-ray examination often fails to demonstrate it even when present to a marked degree.

A majority of the cases are amenable to medical treatment. Those not responding can be cured by a surgical procedure which will vary according to the etiology of the case, dividing adhesions or shortening the gastrohepatic omentum, for obstruction of first portion; dividing adhesions for obstruction of second portion. Duodenojejunostomy usually meets the indications for obstruction of the third portion or some operation on the cæcum and ascending colon when the condition is plainly secondary to a drag of the prolapsed bowel and dilatation is not excessive.

The following suggestions are offered:

Acute postoperative dilatation of the duodenum is usually preceded by a chronic condition and may be prevented by correcting the latter. Viscious circle after gastro-enterostomy is due to duodenal obstruction already present or produced by the operation.

In performing gastro-enterostomy, if the duodenum is dilated, a duodenojejunostomy should supplement the procedure. Many so-called billious attacks may be caused by obstruction of the duodenum, following constipation and the drag of a prolapsed cæcum. Chronic duodenal obstruction probably predisposes to duodenal ulcer. In operating for duodenal ulcer when the pylorus is not obstructed and the duodenum is dilated, duodenojejunostomy is the proper surgical procedure.

REFERENCES

LEWIS DWIGHT. Notes on duodenum and pylorus. J. Anat. & Physiol., 1897.
CODMAN. Obstruction of duodenum. Boston M. & S. J. 1908.
JAMES M. ANDERS. Stenosis of the duodenum. Am. J. M. Sc., 1912, Sept.
BLOODGOOD. Dilatation of the duodenum. J. Am. M. Ass., 1912, July 13.
STAVELY. Chronic gastromesenteric ileus. Surg., Gynec. & Obst., 1910, xi, 288.
HARRIS. Constriction of duodenum. J. Am. M. Ass. 1914, April 18.
HAYES. Intestinal stasis. N. Y. M. J., 1914, Jan. 24.
DOUGLAS VANDERHOOF. J. Am. M. Ass. 1917, Aug. 18.

DEPARTMENT OF TECHNIQUE

INFECTION OF A FUSED KIDNEY WITH DUPLICATION OF THE LEFT RENAL PELVIS[1]

By LEO BUERGER, M.D., F.A.C.S., New York

IN recounting the history and clinical course of a very interesting case of renal infection, occurring in a kidney with a double pelvis, it is my purpose to discuss some interesting points in the diagnosis of surgical renal disease; and also, to bring to your notice the importance of a thorough knowledge of the existence of renal anomalies, a study of which may aid both in making exact anatomical diagnoses and in the selection of subsequent operative intervention.

The frequency of the incidence of renal anomalies is well known to the urologist. Not enough, however, has been written concerning the occurrence of infections in anomalous kidneys to acquaint the surgeon with the importance of an accurate diagnostic exploration of the function of the anomalous as well as of the sister organ, for the technique of nephrectomy, if it becomes necessary, may be more safely carried out, and the indications for operative intervention more accurately planned, if such precise knowledge is at the surgeon's disposal.

In presenting below a case of duplication of the renal pelvis with duplication of the ureter complicated by calculi and infection, I feel fortunate in being able to discuss clinical manifestations, and cystoscopic and X-ray findings that should prove instructive and interesting, both from a pathological and diagnostic viewpoint.

Above all, the case to be analyzed will emphasize the value of the combined roentgenographic and cystoscopic methods as a reliable and almost necessary prelude to the operation of nephrectomy, when such is indicated for severe infection of one-half of a kidney with a double pelvis.

Large vesical calculus, cystitis, duplication of the ureter and pelvis of the left kidney, pyelitis, pyelonephritis, multiple renal abscesses, perinephritis, calculi in the pelvis of the upper portion of the left kidney with a second normal ureter and corresponding pelvis occupying the lower pole.

M. N., age 38, male, consulted me on December 28, 1917, with the complaint that he had had urinary symptoms for about 2 years, there being a distinct diminution in the size of the urinary stream during that period, with one attack of retention of urine. Two years ago he was told that he had a urethral stricture which required dilatation, this method of treatment having been regularly given for some time, apparently without relief. During a six weeks' period of such treatment, there were occasional attacks of chills and fever, frequency of urination, nocturia, and sticking pains in the left hypochondrium, radiating down into the left iliac fossa. Altogether he seemed to have suffered for about three months after his symptoms began two years ago. The symptoms then gradually subsided and the urgency, and nocturia disappeared so that he seemed to feel quite well.

About four months previously, in September, 1917, he again noticed a diminution in the size of the urinary stream, a decided increase in urinary frequency—voiding bloody urine twice a night—and with cutting pain in the bladder region and tip of the penis during the entire act of micturition.

In short, he presented a history of stricture of the urethra, with one attack of retention two years ago, complicated by chills and fever during the period of dilatation with sounds, and evidences pointing to infection of the left kidney; then again four months ago a return of symptoms, at which time he sought the advice of a physician.

X-ray examination revealed a vesical calculus which, on some of the plates had a spherical outline, (2½ inches in diameter), but in a second set of plates, taken December 29, 1917, had an elliptical shape (2⅝ x1½ inches in diameter—Fig. 1).

In the region of the left renal area, over the eleventh and twelfth ribs, there was an irregular, sausage- or kidney-shaped shadow suggesting the presence of more than one calculus, and measuring 1¾ inches in length by ¾ inches in width. The renal shadow indicated a considerably enlarged organ.

[1] A clinical lecture on "Renal Infection" at the New York Polyclinic Hospital and Medical School, March, 1918.

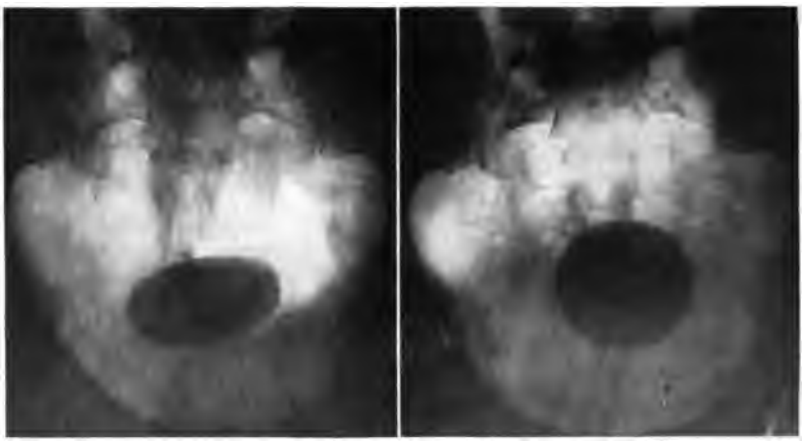

Fig. 1. Roentgenogram of large vesical calculus as it appeared on two different occasions.

In brief, the X-ray examination demonstrated a very large calculus in the bladder, and one or more calculi in the *upper* portion of an enlarged left kidney.

Cystoscopic examination on December 28, 1917, showed a large white calculus of the phosphatic type in the bladder, the ureters coming into view with considerable difficulty. It was possible, however, to push aside the calculus with the beak of the instrument, so as to bring into view the right and what was at the time supposed to be the only *left* ureter, both of which were easily catheterized. Indigocarmine was excreted by the left kidney in 25 minutes, in rather diminished concentration, the specimens being very cloudy; the function of the right kidney was much more active, indigocarmine appearing in good concentration within a period of 20 minutes.

The report of the examination of the separated urinary specimens was the following: right kidney—slightly turbid, urea 1.4, microscopic, few white and red blood; left—very turbid, numerous pus cells, and red blood cells, urea .9 per cent; bladder—turbid, acid, albumin-positive, sugar-negative, with numerous red blood cells on microscopic examination.

The prostate was not enlarged per rectum. Abdominal examination revealed no tenderness in the region of the left kidney, and this organ was not distinctly palpable.

The diagnosis, therefore, was cystitis, a large calculus in the bladder, a calculus or calculi in the left kidney with infection of the left kidney, impaired function of the left kidney, and a fairly healthy organ on the right side.

The operative indications, it seemed to me, were to remove the large calculus from the bladder first, because it was evidently causing the patient so much distress and so much spasm that it was a decided factor in influencing the development of an ascending infection of the kidneys. That it had doubtless been a factor in the infection of the left kidney could be assumed with a fair degree of probability, and it was the fear of the involvement of the right kidney which led me to advise the less serious operation, the removal of the calculus from the bladder, as a first step.

Suprapubic cystotomy. On January 10, 1918, I removed a large flat elliptical stone, measuring 2⅝ inches in length, by way of the suprapubic route, under gas-oxygen anæsthesia, the opening in the bladder being tightly closed with catgut sutures, except for the exit of a small tube through which bladder irrigations could be carried out.

Postoperative course. After suprapubic cystotomy the patient improved remarkably, the general condition at once showing evident signs of amelioration, the temperature being practically normal until the fourteenth day, when there was a sudden rise of temperature somewhat above 102°, general malaise, headache, without, however, any focalizing symptoms. The temperature remained high between 102° and 103° for two to three days, and gradually subsided. During the fourth week after the cystotomy, there was again a rise of temperature up to 103°, the temperature remaining high for three days, and then again gradually coming down to normal.

Although local tenderness in the left kidney region was absent, and spontaneous pain was absent, it appeared most likely that infection of the left kidney was the cause of the temperature and of the distinct impairment of the general condition. No other cause for the rise of temperature could be found.

Exploration of the left kidney was, therefore, advised, which the patient, however, refused, preferring to go home "in order to build up."

The suprapubic wound healed promptly after the removal of the drainage tubes, and the patient left

the hospital with practically no disturbances of micturition, but showing the distinct signs of severe attacks of pyelonephritis. He did not appear strong and healthy, and recurrences of attacks of pyelonephritis were considered extremely likely, and, in fact, were to be expected.

On February 25, 1917, he again came to the office for an opinion, having noticed that he did not "build up," but had become progressively weaker. He was referred to the Mt. Sinai Hospital, for a thorough investigation of his urologic status.

The patient was admitted to the Mt. Sinai Hospital on February 27, with a temperature of 101°, no renal tenderness, a haggard look, and urine containing a fairly large amount of pus. It was again a question as to whether the temperature was due to the infection of the left kidney without local manifestations, or whether some intercurrent or other infection, such as tuberculosis, was present.

On February 28, 1918, another cystoscopic examination was performed to determine whether we were dealing with retention of purulent urine in the kidney or not. At this time it was easy to obtain a perfectly good view of the bladder, because the stone had been removed, and the mucous membrane was found almost normal except for some congestion. It was with surprise, that *two ureters were discovered* on the left side, the upper or posterior one doubtlessly having been covered up by the large calculus at our previous cystoscopic examination. All three ureters were catheterized, specimens being obtained from the right kidney, and from the upper or posterior and lower or anterior ureteral orifices on the left side. A roentgenogram with two shadowgraph catheters, one in each left ureter was then taken, giving the picture seen in Figure 2. The urinary report was as follows:

	RIGHT	LEFT UPPER	LEFT LOWER
Reaction	Acid	Acid	Acid
Albumin	Trace	Trace	Trace
Urea	1.1 per cent	1.4 per cent	0.7 per cent
Microscopical	Few epithelial cells. Few red blood cells No pus cells Few hyaline casts	Few epithelial cells Few red blood cells No pus cells Few hyaline casts	Few epithelial cells Few red blood cells Many pus cells Few hyaline casts
Culture	Sterile	Bacillus coli communior	Bacillus coli communior.

To summarize, we have a fairly normal functionating right kidney with urine containing a trace of albumin; a left kidney containing two pelves, the lower pelvis corresponding to the upper ureter, presumably normal except for the presence of bacillus coli communior in culture and an upper pelvis evidently infected, with urine containing many pus cells, diminished urea output, and infected with bacillus coli communior.

Fig. 2. Two shadowgraph catheters, one entering each pelvis; calculi in upper pelvis.

Desirous of studying the relationship of the two left ureters to the composite left renal mass, two shadowgraph catheters were placed into the two left ureters on February 28, after the urine had been collected, and a plate taken.

On this X-ray plate the course of the two ureters was well outlined, their paths overlapping just below the pelvic brim, and again crossing or being superimposed at about the level of the fourth lumbar vertebra. The relationship of the calculi to the two ureters could also be deduced from these two plates, it being readily seen that they occupied the upper pelvis and the ureteropelvic junction. From these plates, too, the well-known fact that the upper or posterior ureter usually enters the lower pole, whereas the lower or anterior ureteral orifice leads to the upper pole, was found to be substantiated.

On February 28, at about the time that the cystoscopy was done, the temperature had already risen to 103,° and at 4 p. m. was 104.2.° The palpation of the left hypochondrium and left lumbar region gave evidence of an enlargement of the kidney without any local tenderness.

The temperature remained fluctuating between 102° and 103.8° until March 2, when it gradually came down to 102 and on March 3, did not rise above 99.2.°

On March 4, the temperature was again 100°, and by this time we were fairly certain from our investigations that no other focus was responsible for the temperature.

Thus, we were dealing with a man who had had recurrent attacks of pyelonephritis in a kidney with a double pelvis, the lower portion of which was evidently healthy, the other or upper portion harboring one or two calculi, and the seat of an extensive pyelonephritis.

Diagnostic conclusions. In a man who had had a large vesical calculus, and in whom the X-ray findings indicated the presence of a fair-sized calculus in the left kidney, the clinical course as well as the cystoscopic findings, pointed to severe infection of at least the upper half of the left kidney, the lower pelvis being uninvolved. The insiduous nature of the process as evidenced by the absence of local pain, renal colic, or local tenderness, the presence of attacks of fever with general symptoms rather than localizing phenomena, made the interpretation of the clinical course and the surgical indications somewhat difficult. However, from a consideration of the findings, it was possible to make the following deductions regarding the anatomical lesions present.

Thus, we surmised that the upper portion of the kidney was the seat of an inflammatory process with multiple abscesses, or at least extensive pyelonephritis, and suppurative areas in the parenchyma; and furthermore, because of the long history, and the absence of a true pyonephrosis (as indicated by cystoscopic findings), and the absence of pain and tenderness, we were in all probability dealing with an inflamed kidney, whose exterior was enveloped in markedly thickened perirenal adipose tissue, that is, a kidney surrounded by enormous fat production, and enveloped as it were, or encased in a mass of inflammatory tissue.

The operative findings corroborated these diagnostic inferences in revealing a kidney that corresponded almost exactly to that which we had expected to find.

Operation, March 5, 1918. Through the usual Albarran oblique incision, the left kidney was exposed, found considerably enlarged, extremely adherent, the upper two-thirds being encased in a large amount of hard, indurated, inflammatory fat, making the separation from the parietes and the peritoneum difficult. The lower pole of the kidney however, appeared to be normal. The two ureters were exposed with little difficulty, the lower one being normal, the upper one thickened, about the diameter of the small finger. The hilus of the kidney as well as the upper pole seemed to be particularly adherent and surrounded by large masses of œdematous and inflammatory fat, through which, however, a calculus in the upper pelvis could be palpated. After the upper two-thirds of the kidney had been freed, and the upper ureter cut across, it became apparent that the lower pole was held by an isthmus of renal tissue, which apparently crossed the lumbar vertebral column. When traction was made upon it, the fusion between the lower pole of this, and its sister organ could be easily demonstrated, the connection being present in the form of a band of renal tissue, about one and one-half inches in diameter.

The isthmus was then divided between clamps and sutured with catgut, the lower normal ureter cut through, and the kidney removed.

Pathological specimen. The kidney is almost twice the normal size, its upper two-thirds being enveloped in a mass of œdematous, hard fat, varying in thickness from 3 millimeters to 1 centimeter, being most markedly developed at the upper pole (Fig. 3). Occupying about the center of the hilus is the upper pelvis, also encased in a large amount of inflammatory fat, the ureteropelvic junction and the pelvis just above it protruding by reason of the presence of a calculus in the upper pelvis. The upper ureter is very much thickened and inflamed. Its walls are at least four times the normal size. That portion of the cortex of the upper part of the kidney that is shining through the capsule is evidently pale, whereas, the parenchyma at the lower pole has almost a normal appearance.

Somewhere between two-thirds and three-fourths of the renal tissue appears to be diseased from a mere surface inspection, while about one-fourth, or the lower pole, appears to be normal.

On section (Fig. 4) it is evident that the upper three-fourths of the kidney is the seat of an extensive inflammatory process that involves particularly the parenchyma of its upper half. Here there are the typical lesions of pyelonephritis with streaks of purulent matter arranged in the typical triangular or pyramidal fashion extending toward and reaching the capsule. The capsule itself is enormously thickened, œdematous and hard, separating the parenchyma from thick masses of perirenal inflammatory fat. The pelvis of the upper portion of the kidney is slightly dilated, thickened and inflamed, and harbors two calculi, which almost completely fill the ureteropelvic junction, and the distal portion of the pelvis. These measure about one and one-half inches in length by one and one-fourth inches in diameter.

The lower normal portion of the kidney occupying the lower pole is provided with a small pelvis that leads into the lower ureter, both being practically normal.

The patient made an uninterrupted recovery.

Fig. 3. Deposition of inflamed fat about the upper two-thirds of the kidney; enlarged upper ureter; normal lower ureter; normal lower pole, with cut surface through the isthmus.

Fig. 4. Kidney bisected, showing perirenal inflammatory fat, two stones in upper pelvis, with multiple abscesses, inflamed œdematous upper three-fourths of parenchyma and normal lower pole.

his general condition improving immediately, so that he was up and about on the twelfth day, and ready to leave the hospital during the third week after the operation.

CLINICAL DEDUCTIONS

A consideration of this most instructive case will disclose points of interest on the interpretation of clinical symptoms, concerning the application of cystoscopic diagnosis, regarding the importance of combined X-ray and cystoscopic methods, and finally about the technique of nephrectomy, when cases of this sort are subjected to operative intervention.

1. *The interpretation of the clinical symptoms.* Very illuminating in this case was the association of attacks of fever with evidences of infection of one kidney without, however, the presence of any localizing sign either in the form of spontaneous pain or local tenderness. At one time even the absence of a large kidney was noted, and it was not until later in the course of the disease that the left kidney became appreciably enlarged and palpable. That such attacks of fever without localizing signs can give cause for anxiety on the part of the clinician is very evident, particularly so, if a thorough investigation of the urinary tract is not carried out. Thus, in the absence of a cystoscopic and roentgenographic examination with the mere presence of pus in the urine, it can be readily understood how the kidney, as a causative factor, in the production of the clinical picture, could be overlooked. In the explanation of the absence of costovertebral tenderness or pain, we may suggest the following hypothesis: that, because of the enormous production of perirenal fat, and of the encasement of the infected portion of the kidney in a mass of inflamed fatty tissue and connective tissue, the inflammatory process was, as it were, encapsulated and prevented from producing fresh exacerbations of perirenal inflammation. It appears that only thus could we explain the absence of localizing pain. Then, too, the absence of

any considerable retention of secretion in the pelvis of the kidney could be held accountable for the dearth of symptoms. We are warranted, in concluding, therefore, that if the cystoscopic and X-ray findings definitely point to the existence of a severe or well-marked renal infection, the absence of local pain suggests, at least, the possibility of such an encasement of the inflammatory focus as was present in this case.

2. *The application of the cystoscopic method of diagnosis.* Here, par excellence, we had a case in which value of careful cystoscopy both in studying the indications for operation, as well as in making an exact anatomical diagnosis of the existing conditions, was well exemplified. Thus, it enabled us to make a diagnosis of the existence of two ureters, to determine that only one pelvis was infected, to decide as to which pelvis was infected, the upper or lower, by these means acquiring valuable suggestions as to the manipulations necessary at the time of operation.

3. *The importance of combined cystoscopic and X-ray examination.* Since the study of renal and ureteral anomalies teaches us that in the presence of a double ureter with duplication or bifurcation of the pelvis, we must be suspicious of the presence of a fused or horseshoe type kidney, it is important to know not only the course of the duplicated ureter, but also to be able to trace the path of the normal ureter with a view to deciding as to whether it leads into a normal kidney over a normal path, or whether it takes a more mesial course where it might be injured at the time of operation.

We may anticipate by saying that it is advisable in all operative cases where three ureters are present to outline these with shadowgraph catheters, and to attempt by good roentgenograms to demonstrate the existence of a renal shadow on the supposedly healthy side, in order to determine whether this is sufficiently large to permit of nephrectomy of the diseased organ, should such procedure be indicated.

Thus, the two ureters on the one side may not take a parallel course, but one of these may cross over the spinal column and lead into the other supposedly healthy kidney, a fact which is important to know. Second, there may be only one kidney present, a fused kidney, the ureters having their vesical orifices in their normal position, or third there may be a solitary kidney with all three ureters leading into one possibly elongated, but unilateral mass. Hence, the importance of visualizing a renal shadow on each side, as well as of outlining the ureters.

The demonstration of the path of the healthy or normal ureter is equally valuable for two reasons: first, because it may be impossible on account of the stoutness of the patient to obtain a satisfactory outline of the supposedly healthy kidney; and, second, because we might very easily injure the ureter of the healthy organ were it to take an abnormal course and traverse the lumbar column dangerously near the field of operation.

In short, in every case of three ureters, requiring operative intervention on one kidney, it is advisable to demonstrate the course of the three ureters by means of shadowgraph catheters. Such plates are of more value when there are three ureters than when there are four, because in the case of four ureters a symmetrical disposition is more likely than in the case of three. In a case of four ureters we may expect two on each side leading into discrete kidneys with double pelves, or two ureters on each side leading into symmetrically placed portions of a fused or horseshoe kidney. It is in the cases of three ureters that chances of asymmetry are greater; and that the course of the third or normal ureter needs visualization.

4. *The value of demonstrating the shadow of the healthy kidney.* Not only may this suggest or rule out horseshoe kidney, but it may also give us valuable information as to the size of the organ, and therefore, some indication of its functional capacity.

A normal or enlarged renal outline, attended with a normal urinary secretion (as evidenced by ureteral catheterization), means that the chances for recovery, in the event of nephrectomy of the other organ, are better; it means in all probability that adequate parenchyma for sustaining life is present, and it indicates that a severance of an isthmus—

in the event of renal fusion—would be a relatively easy matter.

SUMMARY

The following instructive points may be learned from a study of our case:

1. That when a large calculus lies in the bladder, catheterization of both ureters may be possible, particularly if the stone be pushed aside by means of the beak of the cystoscope, but that a double ureter on one or the other side may be overlooked, the posterior or upper one being covered by the calculus.

2. That infection may occur in one of the pelves of a kidney with ureteral duplication, without involving the parenchyma corresponding to the other pelvis.

3. That cystoscopic diagnosis is of great importance, even though the X-ray examination may show a calculus, for it permits of an exact anatomical diagnosis, and enables us to diagnosticate a double pelvis and ureter, if such be present, giving us thereby valuable hints as to the technique of nephrectomy.

4. That the presence of a ureteral and pelvic duplication should make us suspect the existence of a fused kidney, although such cannot always be diagnosticated with certainty.

5. That a knowledge of the possible presence of a fused kidney at time of nephrectomy is important, in that it not only suggests to us the search for the existence of a connection isthmus, but also induces us to avoid injuring the ureter of the other kidney.

6. That whenever a double pelvis is present with two ureters, it is interesting not only to outline these two by means of the shadowgraph catheter, but also to obtain by means of the shadowgraph catheter an outline of the third ureter, and if possible, to obtain a shadow of the normal kidney. The outline of the two ureters on the one side helps us in the technique of nephrectomy, and the course of the normal ureter is of importance to us in that it spells safety for us if its course is normal, whereas, it should be dealt with with great care, if the normal ureter be situated far mesial or overlying the isthmus of a horseshoe or fused organ.

7. That the occurrence of attacks of fever, sometimes with chills, means pyelonephritis and multiple abscesses, in the absence of evidences of marked retention of urine in the kidney.

8. That the absence of local, lumbar or costovertebral tenderness in a case of pyuria with attacks of fever and chills, with cystoscopic evidences of unilateral renal infection does not mean an absence of severe renal infection, but that it indicates an associated *intense perinephritis* with enough fat production to form a large massive shell about the infected kidney, the suppurating parenchyma being walled off thereby to such an extent that the usual symptoms do not manifest themselves.

THE EXTREME PENDULOUS ABDOMEN AND ITS SURGICAL TREATMENT BY A NEW THREE-FLAP OPERATION

By NEIL JOHN MacLEAN, M.D., M.R.C.S. (Eng.), F.A.C.S., Winnipeg, Canada
Surgeon to Winnipeg General Hospital

THE surgical treatment of the pendulous abdomen is still in the evolutionary stage. One looks in vain for any reference to this subject in the ordinary textbooks and but very brief mention is made in the more exhaustive systems of surgery, though many excellent articles by Alexius McGlannan, Cullen, Wayne Babcock, and others have appeared in the recent issues of the surgical journals. Especial mention should be made of the work of Blake in developing the double flap operation, and of W. J. Mayo's operation for umbilical hernia, both procedures having their places in the treatment of some of the less marked types of the condition under discussion. Pendulous abdomen is usually seen in women who have gone through repeated pregnancies, and in whom the panniculus adiposus is especially well developed. Modern methods of dress which tend to displace the abdominal viscera into the lower abdomen rather than giving support thereto tend to aggravate the condition.

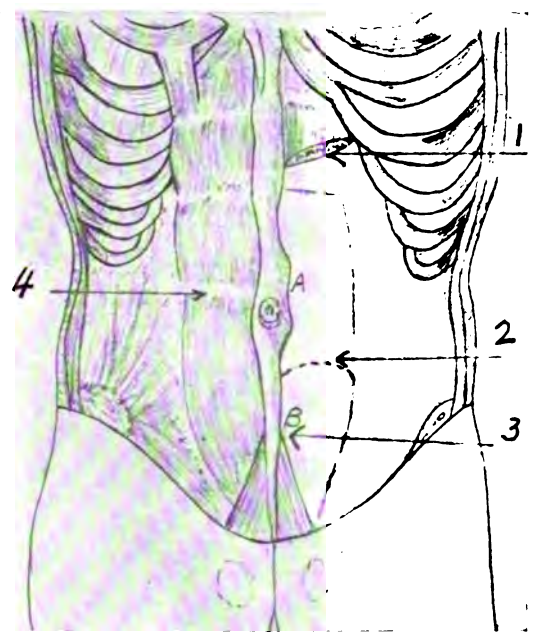

Fig. 1. Between the points *A* and *B* the linea alba yields most to increased intra-abdominal pressure. *1*, Rectus abdominis cut across; *2*, semilunar fold of Douglas; *3*, point above pubis where linea alba is reinforced by the pyramidals abdomines and triangular fascia.

ANATOMICAL CONSIDERATIONS AND PATHOLOGICAL ANATOMY

Anatomical reasons for the condition are found in the arrangement of the aponeurosis of the linea alba. From one and one-half to two inches above the symphysis pubes where the recti muscles decussate and are reinforced by the triangular fascia of the abdomen and the pyramidales muscles, the wall at this point is extremely strong. In no case was the stretching of the linea alba found to have passed below this point. Again at a point immediately above the umbilicus the linea alba appears to be very dense and unyielding. In all the cases observed, a well defined line of demarcation existed between the stretched part and the part above the umbilicus which had not given way. This point appears to be at the lowest linea transverse of the recti muscles, and is situated just above the umbilicus. The point of

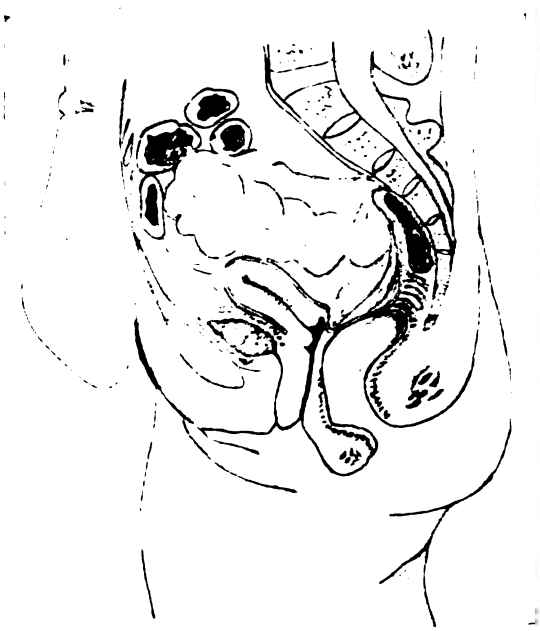

Fig. 2. Pendulous fat. Abdominal wall not relaxed.

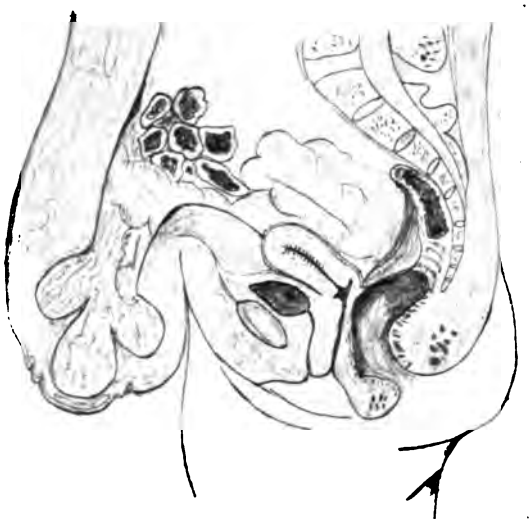

Fig. 3. Extreme pendulous abdomen with umbilical hernia. The umbilicus forming the apex of the protrusion.

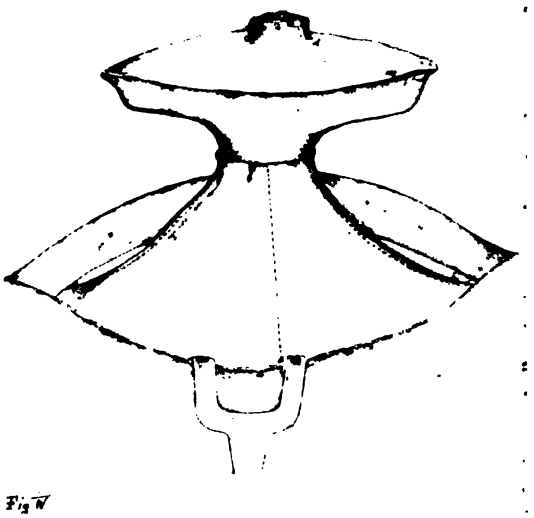

Fig. 4. Elliptical incision. Fat dissected from external oblique aponeurosis, relaxed abdominal wall lifted up in form of a cone.

maximum lateral stretching in all the cases seen by me was at the semilunar folds of Douglas. The recti muscles are displaced, and while in some cases somewhat attenuated, do not enter into the parts that have given way.

According to Cunningham[1] the umbilicus is situated normally below the mid-point between the infrasternal notch and the symphysis pubes. It is opposite the fourth lumbar vertebra. In most of the cases referred to in this article it was opposite or below the symphysis pubes.

If an opening is made at the umbilicus and the hand inserted into the abdomen of one of these huge pendulous cases, a definite internal ring can be felt which might be compared to the internal ring of an ordinary hernia. This ring is bounded laterally by the margins of the recti muscles, below by the point of decussation of the recti

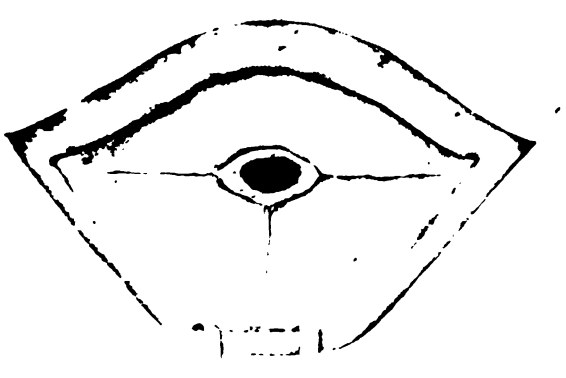

Fig. 5. Two lateral incisions and one vertical incision e made forming three flaps.

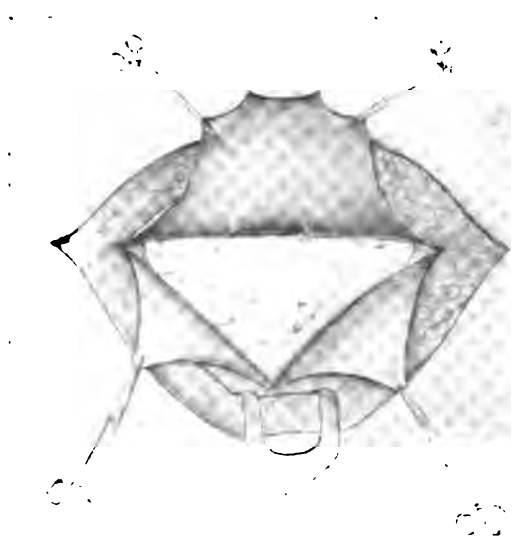

Fig. 6. The three flaps are here shown ready for stitching.

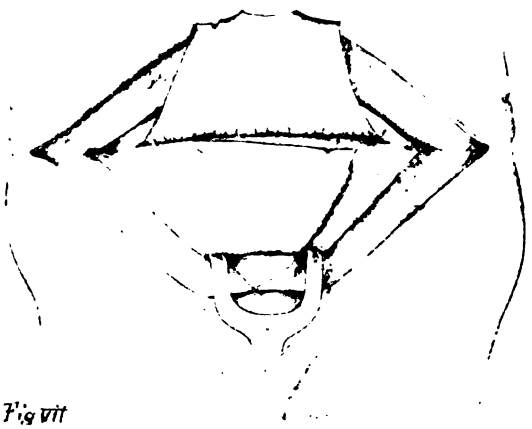

Fig. VII

Fig. 7. The two lower flaps are overlapped and stitched, their upper double margin being stitched to upper margin of internal ring.

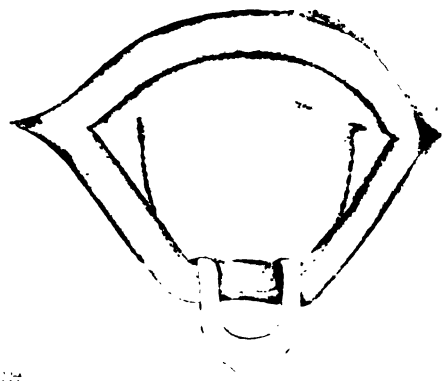

Fig. VIII

Fig. 8. Upper flap brought down over the lower, the double flap, and stitched to the external oblique apo neurosis.

muscles about one and one-half inches above the pubes, and above by the margin of the linea alba which has not yielded to the stretching corresponding to the lower linea transversa of the recti muscles.

It will therefore be seen that while at first sight the stretching of the structures appears to be universal to the whole anterior abdominal wall, it is entirely limited to a definite area. This area in the normal anatomy corresponds to a narrow line, the linea alba and that part of it lying between a point very little above the umbilicus and a point about one and a half or two inches above the symphysis pubes (Fig. 1).

SURGICAL TREATMENT

Surgical treatment should not be lightly undertaken and is called for only when the condition is causing troublesome symptoms. The operative mortality has been high in this type of patient. McGlannan (2) places it at 6 per cent for massive non-strangulated, and 50 per cent for massive strangulated hernias. These figures only convey a relative idea of the mortality, for we do not know what type of operation was done, or whether anything was done beyond a simple umbilical hernia operation without any attempt at reducing the protruding abdominal wall. The cases becoming obstructed must necessarily be those associated with an umbilical hernia, as obviously it would be difficult to have an obstruction in a pendulous abdomen not accompanied by an umbilical hernia.

The preparation of the patient for operation in these cases is most important for two reasons: first because the intra-abdominal pressure should be reduced to a minimum, and second, the skin, which is moist and foul from intertrigo, must be cleansed and purified. For a week or ten days the patient should be put on purgation, and a very restricted diet. Daily warm baths should be given and alcohol applied to the skin of the abdomen. A folded sterile towel should be placed between the overhanging abdomen and the pubes and kept in place by a narrow binder or bandage

Fig. 9. Case 1.

Fig. 10. Case 2.

Fig. 11. Case 3.

Fig. 12. Case 3.

which falls into the crease and over which the towel folds. This should be worn during the preparation to prevent the two skin surfaces coming in contact with each other.

Operation. The pendulous abdomen due entirely to an abnormal development of the panniculus adiposus where the muscular and aponeurotic structures are normal (Fig. 2) rarely calls for treatment, and if it does, a simple lipectomy is all that is necessary.

In one case referred to me by Dr. H. P. H. Galloway, suffering from sacro-iliac strain, a lipectomy was done to facilitate the fitting of an orthopedic apparatus for the support of the strained sacro-iliac joints. This type of pendulous abdomen may be associated with an umbilical hernia, in which case a Mayo operation combined with a lipectomy is indicated. These types are not to be confused with the type of extreme pendulous abdomen where there is marked diastasis of the recti muscles and where the linea alba is greatly stretched. Their recognition and differentiation should not be difficult.

The following procedure which I have named the three-flap operation, is, I believe, the method of choice when operative treatment is undertaken in the case of extreme pendulous abdomen (Fig. 3). Two long incisions forming an ellipse are made from one side of the abdomen to the other, the upper passing above the umbilicus, the lower passing about two inches above the fold where the abdomen hangs over the pubes. The skin and fat are dissected away from the external oblique aponeurosis until the ring of the umbilicus is met (Fig. 4). The abdomen is then opened at the umbilicus, and the mass dissected away from the umbilical ring. Great care must be taken at this point as the umbilicus is often dilated into a multilocular sac and the contained omentum and intestines are often adherent. It will now be found that the part of the abdominal wall which has given way can be lifted up in the form of a cone with the umbilicus forming the apex (Fig. 4). If the fingers be inserted within this cone the internal ring already described can be felt at its base.

It will serve the purpose for the convenience of description to call this the internal ring of the protrusion. The upper limits of the ring while several inches from the umbilicus in the pendulous abdomen cases, is a point very close to the normal anatomical position of the umbilicus and, as already mentioned, corresponds to the lowest linea transversæ of the recti muscles.

Two lateral incisions are now made from the umbilical ring to the inner margins of the recti muscles. A third incision is made from the umbilical ring downward to the firm lower margin of the internal ring, the point already described where the recti muscles decussate (Fig. 5). Three flaps are thus formed, two lower and one upper (Fig. 6). The two lower flaps are overlapped from side to side thus reducing by one-half the space between the recti muscles. The free margin of each flap is stitched with strong chromic catgut to the firm margin of the sheath of the opposite rectus muscle. The upper flap is now drawn upward, and the upper margin of this lower and now double flap is stitched to the upper margin of the so-called internal ring (Fig. 7). The upper flap is next drawn downward and spread over the lower double flap and its margin stitched to the aponeurosis of the external oblique (Fig. 8).

It was found in my series of cases, that in all, the lower margin of this upper flap reached the point below which no stretching had taken place. The skin is closed, and three small tube drains are inserted, one at each angle and one in the center of the wound. It will be seen that in the place of the relaxed wall we have now a three-fold aponeurosis covering the opening and secured at every point to normal anatomical structures that have not yielded to the intra-abdominal pressure.

CASE 1. Mrs. N., age 49, mother of a large family, had an umbilical hernia more than ten years. It has been gradually enlarging and the abdomen has been growing pendulous.

Operation, 1913. A large elliptical incision was made from side to side. A mass of fat weighing 7 pounds was removed with umbilicus which was multilocular. The great omentum was adherent. Three-flap operation performed. Recovery normal. Result excellent. Patient seen in 1917, and condition still excellent.

CASE 2. Mrs. H., age 53, mother of several children, has had an umbilical hernia and pendulous abdomen for a number of years. Operation, 1914. Transverse lipectomy. Fat and umbilicus removed weighing 7½ pounds. Three-flap operation. Recovery normal. Patient seen in 1917. Has a small inguinal hernia (bubonocele) right side. Abdomen in excellent condition.

CASE 3. Mrs. S., age 43, eight children, first noticed small swelling at navel fifteen years ago during pregnancy. The patient has suffered from constipation, pain and vomiting, which was diagnosed as attacks of acute obstruction.

Operation, January, 1916. Lipectomy, removal of umbilicus, which was very large and multilocular. It contained the lower part of ilium, cæcum and appendix, ascending colon, hepatic flexure and part of transverse colon and great omentum. The appendix was very large and markedly inflamed. The intestines and omentum showed recent inflammatory adhesions, undoubtedly due to peritonitis from the acutely inflamed appendix. Recovery was normal.

CASE 4. Mrs. D., age 44. (I am including this case in this series, though strictly speaking, it belongs to another class.) The patient had a large incisional hernia with a

large amount of pendulous fat. The hernia followed an operation for removal of inflamed adnexa from the pelvis which necessitated drainage. Though she had one week of preparation before operation for the hernia, she did not escape what we most dread in these cases — infection.

Operation, March, 1916. Lipectomy with reclosure of the hernia by overlapping. The center skin drain discharged a greenish serum. Culture showed streptococcus. The patient died on the fifth day from peritonitis.

CASE 5. Mrs. T., age 48, mother of eight children. After last child six years ago, noticed a swelling at the navel. This has gradually enlarged.

Operation, June, 1916. Lipectomy and three flap operation. Recovery normal. Result excellent.

CASE 6. Mrs. C., age 46, mother of several children. Some years before had an operation which was followed by an incisional hernia. The abdomen was pendulous, though the umbilicus was normal and not displaced. This did not seem to be a case for a three-flap operation. However, in trying to suit the procedure to the condition, it was found that the three-flap method filled the indications most perfectly. Recovery was normal, except that a superficial infection occurred and discharged from the center drain which delayed convalescence.

CASE 8. Mrs. S. No pregnancy. Patient had a small umbilical hernia and pendulous abdominal fat. No relaxation of abdominal wall. This is a case of the type represented in Fig. 2.

Operation. Lipectomy and Mayo operation for umbilical hernia.

REFERENCES

1. CUNNINGHAM. Textbook of Anatomy, sec. iv, p. 1264.
2. MCGLANNAN, ALEXIUS. Massive umbilical and ventral hernias. Surg., Gynec. & Obst., 1915, xx, 700.

BOOKS RECEIVED

Books received are acknowledged in this department and such acknowledgement must be regarded as a sufficient return for the courtesy of the sender. Selections will be made for review in the interests of our readers and as space permit.

SURGICAL TREATMENT. A Practical Treatise on the Therapy of Surgical Diseases; for the use of practitioners and students of surgery. By James P. Warbasse, M.D. Philadelphia and London: W. B. Saunders Company, 1918.

A COMPEND OF GENITO-URINARY DISEASES AND SYPHILIS. Including their Surgery and Treatment. By Charles S. Hirsch, M.D. 3d ed., revised. Philadelphia: P. Blakiston's Son & Co., 1918.

MASSAGE AND THE ORIGINAL SWEDISH MOVEMENTS; their Application to Various Diseases of the Body. By Kurre W. Ostrom. 8th ed., revised and enlarged. Philadelphia: P. Blakiston's Son & Co., 1918.

PAPER WORK OF THE MEDICAL DEPARTMENT OF THE UNITED STATES ARMY; a guide for administrative work. By Ralph W. Webster, M.D., Ph.D. Philadelphia: P. Blakiston's Son & Co., 1918.

EQUILIBRIUM AND VERTIGO. By Isaac H. Jones, M.A., M.D. With an analysis of pathologic cases. By Lewis Fisher, M.D. Philadelphia and London: J. B. Lippincott Company, 1918.

THE SURGICAL CLINICS OF CHICAGO. Vol. ii, No. 5 (October, 1918). Philadelphia and London: W. B. Saunders Company, 1918.

LEÇON DE CHIRURGIE DE GUERRE. Published under the direction of Cl. Regaud. By Mm. Guillain, Jeanbrau Lecène, Lemaitre, Leriche, Magitot, Mocquot, Nogier Okinczyc, Piollet, Policard, Roux-Berger, Tissier. Paris Masson et Cie, 1918.

THE OXFORD MEDICINE. Advance Pages. Edited by Henry A. Christian and Sir James Mackenzie. Vol. I part 1. New York: Oxford University Press, America Branch, 1918.

NEOPLASTIC DISEASES; a Textbook on Tumors. By James Ewing, A.M., M.D., Sc.D. Philadelphia an London: W. B. Saunders Company, 1919.

THE PRINCIPLES AND PRACTICE OF OBSTETRICS. By Joseph B. DeLee, A.M., M.D. 3d ed. thoroughl revised. Philadelphia and London: W. B. Saunder Company, 1918.

A MANUAL OF GYNECOLOGY. By John Cooke Hirs M. D. Philadelphia and London: W. B. Saunde Company, 1918.

AMERICAN COLLEGE OF SURGEONS

CASE RECORDS AND THEIR USE

IN RELATION TO HOSPITAL SUCCESS

TO create grim earnestness among hospitals in the matter of case records and to indicate the relation of case records to good hospital service are the purposes of these pages. The sheets or record-forms described in the following pages are published simultaneously by the College in Bulletin No. 2, Vol. IV. The sole object in issuing these two bulletins is to make for the better practice of medicine; and whatever value they may present toward this end springs from the good co-operation of the hospitals with the College in its program of hospital standardization.

The keeping of case records in hospitals came about in a natural fashion. Long ago, as the practice of medicine developed into a profession, the more competent and conscientious practitioners made notes for themselves as to the physical condition of their various patients and as to what they did for their patients. These notes were aids to the memories of the doctors who made them, and a guide for other doctors when similar cases presented; they were an effort in the interest of the patient. Then by very swift degrees medicine became a more complex and exact science and the need for notes or records in clinical practice became more imperative; and as this process went on and great strides forward occurred in medical science like the discovery of bacteria, anæsthesia, and asepsis, there came a quick development of hospitals with their cleanliness, their laboratories, their X-ray apparatus, their dietitians, their trained nurses, and their case records. All of these advances are to aid the doctor in the care of his patients.

The whole story of hospitals is one of natural evolution. Today the hospital is in a striking period of transition, changing from the kindly-disposed boarding house for sick people, which met a genuine need in its day, to the institution worth while on its own account, rendering service to the sick for which it assumes responsibility. In other words, the modern hospital is an institution where not only the competent study and treatment of sick people *may* occur, but where, also, the competent study and treatment of every man, woman, and child who enters its service as a patient *do* occur as a matter of clear-cut institutional policy.

The remarkable success in recent years, financially and otherwise, of the comparatively few hospitals which have instituted and carried forward this policy indicates the lines of hospital advancement during at least the next decade. The reasons for the success of these hospitals are the quick appreciation and gratitude on the part of the public for the service rendered and the resultant bonds of confidence created between these hospitals and their communities. The wholesome factor of competition means among hospitals, as among individuals or among nations, that success and prosperity will come where due on the basis of merit.

TEST OF MEDICAL PATRIOTISM

But to return now to case records: First, what are these records? Second, what element are the records in the success of a hospital?

First, case records are an orderly and written statement of the complaint of the patient, of the findings as to the physical and mental condition of the patient, of the treatment,

EXPLANATORY NOTE.—Better health through better hospitals is the object of the series of hospital conferences arranged by the American College of Surgeons the first of which is to be held at Kansas City early in February. The Fellows of the College, the medical profession, hospital superintendents and hospital trustees are invited to these conferences each one of which covers from one to five states. In order to bring effective attention to bear upon the chief needs of hospitals and practice of medicine, the College, in addition to the calling of the conferences, is publishing a series of hospital bulletins. The first two of these are just issued and the following pages are taken from one of them entitled, "Case Records and Their Use."

medical and surgical, of the complications, if any, and of the final results.

Second, as to the relation of case records to the success of the hospital: If case records are essential to good hospital service, just why are they essential?

In answer to this question let us keep vividly in mind that the hospital exists for the patient. Let us assume that the hospital seeks to give worthy service to every man, woman, and child admitted to its care; that in return it seeks the confidence and good-will, and even the financial aid of its community. If these conditions are true, it follows that the hospital creates an equation which consists of service to the sick on its own part, balanced by proportionate and practical gratitude for that service on the part of the public. The next and inevitable step is that the truth of the equation be sharply tested. Rational and convincing evidence as to the hospital's service is wanted by the public, and not general or sentimental optimism. In other words, because of its very importance, the hospital is under fire of criticism. In some practical fashion it must account for efficient performance in every department. It must account for the ability and in some measure for the moral worth of the doctors privileged to practice within its walls; for the completeness and dependability of its laboratory reports, including the X-ray; for the faithfulness and intelligence of its superintendent, its internes, and its nurses; and for the strength of all of these to work together in single purposefulness. How shall the hospital make this accounting? Well, results are what count and the results are to be found in case records.

The first practical reason, therefore, as here stated for the keeping of case records is that these records are a pledge of loyalty of service on the part of the hospital to its community. For example, a patient comes to the hospital, a diagnosis of appendicitis is made, the patient is operated upon and dies; unless an accurate record of the case has been kept showing the hopeless state of the patient and what was done for him, how can either the hospital or the surgeon justify a death from simple appendicitis?

CASE RECORDS IN ARMY HOSPITALS

The relation of the army hospitals since the beginning of the Great War to the people of this country is an excellent illustration in point. The officers of the medical department of the United States Army realized at the outset that the Surgeon General's office was accountable to the entire nation for the treatment of each soldier admitted to sick report. They realized that each soldier was, in case of sickness, entitled to the best service known to the science of medicine; they realized that the people of the nation were entitled to exact evidence that the sick soldier received such care. The report just issued by the Surgeon General to the Secretary of War for the year ending June 30, 1918, is a monument in the history of medicine for its effect on the civil practice of medicine. The Surgeon General in this report has presented in an intelligible fashion the exact facts as to the care and treatment of soldiers in the army hospitals. The entire report is based upon data taken from the individual case records of the soldiers. These records for each patient were written under strict military orders, and not only was the completeness of the records checked up constantly through the Surgeon General's office, but the character of intelligence displayed by the medical officers through these records was also constantly held up to critical review.

Space does not permit here an analysis of the Surgeon General's report. But the question may fairly be asked as to whether or not the civilian hospital is not quite as much obligated to report the character of its work to its community as are the army hospitals to report to the Secretary of War and through the Secretary to the public. There is but one basis on which such report may be made and that is from properly kept case records.

To illustrate again, let us suppose that a workman enters a hospital and learns that he needs an operation for hernia. Is it not reasonable that he should ask: "Based on your figures for other cases like mine during the past year, what chances have I to be at work again after the operation?" The question is of importance to the workman. Can the hospital answer it? Can the staff and office

claim with easy conscience that they protect the welfare of this man by every safeguard known to medical science? If so, how can they prove the claim? Or is the best of service too good for this man?

Facts, facts, — facts in the relevant personal history of each case, facts developed in the physical findings, facts brought to light by the laboratories and the X-ray, facts deduced through pliable wisdom from all of these and expressed as diagnoses, — these are the foundation of the hospital. And unless the hospital as a matter of institutional policy is in possession of these facts, filed in an orderly fashion in justification of its work, it is entitled to little credit in its community or in the medical profession. To repeat, the character of the case records is a test of the hospital's loyalty to service.

In taking the position here that the hospital is a public service corporation and that as such it is accountable, the question of ownership or of control is not raised. It is immaterial whether the hospital is municipal, state, or private. The contention here is simply that every hospital is a public service institution just as a college is a public service institution. Columbia University, for example, is a privately endowed university controlled by a self-perpetuating board of trustees. In a broad sense, however, Columbia considers herself a public service institution. It makes an annual accounting to the public for the expenditure of all of its funds; it states clearly at frequent intervals its various aims; and it analyzes its efforts to fulfill its aims. It states facts. Through the result of this policy and the wisdom of carrying it out, Columbia stands in an exalted position throughout the world. Millions of dollars go to it unsought because it has won and merited public confidence.

CHECK UPON CHARACTER OF SERVICE

Emphasis in the foregoing paragraphs has been placed upon case records as a test of medical honesty, or let us call it medical patriotism. A second and quite as significant a reason for these records lies in their use to prevent or minimize errors in all clinical practice; to serve as a direct test of efficiency.

Medicine in its application to the needs of the human body is both an art and a science. It can never be reduced to the simplicity or to the certainty that two and two are four. The variable factor of judgment and variations in individual patients is always present. Case records, if wisely kept, offer an invaluable means to the hospital staff to profit constantly by its own experience in practice. This phase of record keeping was especially emphasized by the College in the announcement of its first hospital survey; and in this connection the use of a summary card to make available for study and review the important data of the records was urged. But just how as a practical problem of administration are case records to be used as a test of efficiency? This question leads to a consideration of staff meetings.

WHY MEETINGS OF HOSPITAL STAFF?

The whole scheme of the universe is organization. If you pick up a gosling in the orchard, the flock of geese will attack you; you will learn a practical lesson about organization and about co-operation. The stone men hunted the mammoth together. Our early pioneers built block-houses wherein whole communities could gather and protect themselves from Indians. The building of towns, whether they be towns of people or towns of squirrels or of prairie dogs, is predicated on community action and on organization.

The individual doctor in the hospital can usually accomplish very little single-handed. But working together, all of the doctors or the staff can accomplish almost any right thing which they set out to do. Their business then is to get together, to agree upon what they want, and to turn wishes into action.

Doctors want good service for their patients. Now the staff meeting is the means for the doctors to get together. It is the occasion, for example, at which they will find out the extent of seemingly unnecessary infection among surgical cases in the hospital, the character of these infections, and the causes of them. Almost any problem which will present itself to the staff is related directly or indirectly to the case records. Certainly the

number of septic cases, the character of the infections, and the probable causes of the infections will be recorded in an adequate record system.

But harmony of purpose at staff meetings and clinical facts are not alone enough. The meetings must be an assembling of live people to discuss live subjects for a definite purpose. Each meeting must "get somewhere."

"Are we having unnecessary infections in the surgical service?" asks the head of the surgical department at the staff meeting. Certainly it is his business to know the answer to this question; and in a broad sense it is the business of every member of the staff to know the answer to this question. What are the facts? Where are the infections coming from, if they exist? Whose cases are they? What or who is to blame? Is it the operating room sterilization, or dressing room uncleanliness, or water infection, or is the doctor himself to blame? Open and frank discussion of such topics will lead to action and do more for a hospital than anything else.

But let us not assume that the staff meeting is to develop into a scolding bureau. Let us rather assume that every man and every woman is doing his and her level best to get good results, and that the only sure way to get these results is to talk about the failures. More can usually be accomplished by recognition of merit, kindly expressed, than by scolding.

Again, let us suppose that the medical service is up for review. Is everything going well there? Is the dietary in good hands? Is the nursing happy, conscientious, and adequate? Are patients given the individual attention they need? Is the hospital clean? Is the air kept pure? Is the humidity right in the wards and in the rooms? Has each case received due and prompt study, aided by competent laboratory reports?

Is there any reason why such subjects as these should not be discussed by the staff with freedom, warmth, and candor? Will not such discussion increase manyfold the efficiency of the hospital?

Again, the staff may consider the material equipment of the hospital. Is there the necessary apparatus, let us say, in the examining room? Let us suppose that there is not and that the superintendent says that he has not the money to buy the apparatus. If the superintendent reports lack of funds to one doctor, the chances are that the doctor will accept the report and let it go at that; but if the superintendent reports to the staff, the staff should not and will not be casually put off. It will insist upon its need and effectively lay the responsibility upon the trustees. It will win.

Is there co-ordination between the departments of the hospital, and co-operation between individuals? Is there team-work? If not, the hospital will fail, for success and team-work live together. It takes harmony in all departments and between all departments to spell hospital success. To establish the habit of frankness in talking about these things at staff meetings will do much to create harmony.

There will be times when the trustees should be present at staff meetings to listen to wholesome truths about the hospital and about themselves and about individual members of the staff. More good can be done in five minutes' talk with the trustees in this way than can be done in a whole year of talk behind the backs of trustees.

How often ought staff meetings to be held? Often enough to keep up the active interest in the work of the institution; often enough to keep the staff members talking about hospital progress from meeting to meeting; not often enough to cause the meetings to be a burden to busy doctors. One evening a week ought not to be too much to ask of every man on the staff of a hospital to spend at staff meetings.

The objection is sometimes raised that "the staff won't come." If this is true, why "won't" the staff come? The real answer is perhaps that the meetings are perfunctory, uninteresting, deadly monotonous, and uninstructive. If, in addition to the purposes of meeting above described, two or three clinical cases can be shown at each staff meeting,—cases that have been well worked up, the records of which are complete, the resources of the hospital being exhausted to obtain a diagnosis of the disease, and if all these points are brought out by the man whose case is

being shown, and if there is instruction and information, — then the staff meetings will be like meetings to which those same medical men gladly go hundreds of miles to attend.

A staff member does not have to be a star in the medical sky to present a most interesting and instructive case. All he has to do is to have an interesting case and to present the facts marshaled in logical order. Then he will get the interest of his fellows on the staff, and meetings at which this kind of work is done will be popular and productive.

The staff meeting in every hospital ought to be a red-letter day in that institution, and everything in the hospital ought to radiate toward these staff meetings, — criticisms, complaints, and commendation. The staff meetings are the clearing-house of the hospital. The value of these meetings may be briefly summarized:

1. The fostering of great-heartedness, of determination, of courage, and of desire to grow in ability and worth. With right comradeship and purpose, the difficult task becomes the interesting task and excuses for failure give way to action towards success. Too much value cannot be attached to the right spirit of service in a hospital staff; and human nature is such that we need constant sincere interchange with our fellows to keep that spirit at its brightest glow. "Repeat to me every criticism you hear," said Pasteur; "I shall prefer them to praise."

2. The elimination to a practical degree of incompetence, negligence, or laziness in the hospital, first, because the staff meetings serve to stimulate and to inspire each member to his highest effort; and, second, because elements of incompetence, negligence, etc., will become so plain that those who continue guilty will either voluntarily resign from the privileges of practice in the hospital or be requested so to do. All of this means protection to the patient.

3. The internes and the younger men in medicine today will in a brief period become the masters in the profession. The character of their leadership will depend much upon the inspiration gained by example during the early years of their life's work. Fearlessness in seeking truth and evidences of honor which will develop at staff meetings will put into the hands of internes the lights which shall burn after the present masters are gone.

4. Staff meetings in time will be productive of data relative to the treatment of disease which are comparable among hospitals. When the practice of regular staff meetings becomes general among hospitals and when the facts and results of practice are regularly summarized in intelligible form, we shall have a mass of information which will not only lead directly to the advancement of medicine, but which will also create a wholesome rivalry among hospitals and thereby stimulate further progress.

PRACTICAL POINTS ABOUT CASE RECORDS

1. The basis of a good case record is keen native ability, sound training in medicine, and the use of both in the care of a patient. Upon the condition of the patient depends the extent of the record. The record consists only of such facts as will be of worth to the patient in the study and treatment of the case; and to the profession for its information in the treatment of similar cases in the future.

2. Whatever the nature of a serious illness, that illness has a relation to the entire body and, though briefly stated, this relation should be recorded. Novel writing under the guise of case records is a waste of time, energy, and money.

3. The psychology of case records is admirably designed for the prosperity of the hospital. A patient who is convinced that his case has been wisely studied and considered of sufficient importance to be recorded is usually a satisfied patient. A bond at once results from this procedure between the patient and the hospital to their mutual advantage. Sound, complete physical examinations often make unnecessary what seems at first a necessary surgical operation.

4. Insistence upon case records in no way reduces the practice of medicine to a machine-made process. The entire process is human and the records are human documents. They are the sincerity and reality of good work; they are the muffins and not the promise of muffins. Good records have something in them that can be made at no mill. They are

not dull facts recorded as a mere routine. They are the records both of an art and of a science, the whole design of which is shot through with the purpose to prolong life, to relieve suffering, to make life glad and nutritious. They are a chief basis of progress in the medical profession, a means to extend the science of medicine and to make surer medical practice: and when the value of case records is estimated at its true worth, all wavering as to the task of keeping them will end in determination.

5. Who is to be responsible for hospital records? The old saying that everybody's business is nobody's business applies to case records. If the records are worth keeping and if they are worth keeping so that their contents are available for study and review, then somebody must have charge of them; somebody must check them up, see that they are all promptly complete, conveniently accessible, and protected from misuse. In a small institution, not oversupplied with funds, it may be wise to double up on duties in this matter. The person who keeps the records may also have other things to do, perhaps in the receiving room, or in the bookkeeping department. But in a hospital of considerable size and especially in a hospital of great earnestness, the records are the sole responsibility of one person.

Supervision of records usually falls to a woman; and if the woman is competent, it may be understood at the outset that she will not be popular for a long time at least with those for whom she works. She will be a nagger and a nuisance to those who are indisposed to keep up to the hour with their records. She will have to appeal to the doctors, and sometimes appeal over the heads of individual doctors to the staff as a whole. But by insistence upon performance of duty the recordkeeper will ultimately win the hearty good-will of the staff and render also a service mightily worth while.

6. A word about filing records and indexing: If records are useful, they ought to be continually useful, which means that they must be accessible. They cannot be useful if tied in bundles indiscriminately and packed away in the attic or basement.

How are records to be filed? Of course, they must be filed so that any record can be quickly found in good and usable shape. Many methods of filing records have been proposed and tried, but no system has been found that answers better all purposes than the envelope system or the vertical filing system, each record in its own envelope or folder. The patient's name and number appears on the corner of the envelope or folder so that one may readily find any record. The system of binding records in volumes meets with little approval in practice. The volume cannot freely be taken from the library and hence the doctor who wishes to examine the record, especially of a patient who returns to the hospital on a second or subsequent visit must practically have an abstract made of that record. When a patient comes into the hospital and it develops that he or she has been there before, the new record should be added to the former one. It is not necessary that the record on this last visit should have the same number.

This consideration raises the question of indexing. If there is a librarian at the hospital who has charge of the records, she will make her service most useful by keeping three indices, each in alphabetical order, of the cases as follows: First, an index of the names of the patients; second, an index of the final diagnoses; and, third, an index of the organs affected. Other index entries may also be kept which concern complications.

Records indexed in this way are available for the purposes of the literature. The hospital also can readily find the patient's record where the patient is concerned by name; and for the purposes of the literature the librarian can pick out required records without trouble. If a staff member, for example, is writing on pneumonia, the index shows all of the pneumonias which have occurred in the hospital, including those with pneumonia as a secondary complication. Again, if the doctor is writing about an organ or the diseases of an organ, or is studying some problem incident to a certain organ, all the cases that have ever been in the hospital in which this particular organ was involved can be procured without delay.

ANNUAL SUBSCRIPTION: UNITED STATES AND CANADA, $10.00; FOREIGN, $12.00 (£2 10s.)

Volume XXVIII MARCH, 1919 Number 3

Surgery, Gynecology and Obstetrics

WITH

International Abstract of Surgery

EDITORIAL STAFF

FOR AMERICA

William J. Mayo, M.D.

E. Wyllys Andrews, M.D. J. Clarence Webster, M.D.

L. L. McArthur, M.D. E. C. Dudley, M.D. Frederic A. Besley, M.D.

A. J. Ochsner, M.D. C. S. Bacon, M.D. Carl Beck, M.D.

Thomas J. Watkins, M.D. John L. Porter, M.D. William R. Cubbins, M.D.

FOR THE BRITISH EMPIRE

Sir Arthur Mayo-Robson, C.B., C.V.O., D.Sc., F.R.C.S.

Sir Berkeley Moynihan, C.B., M.S., F.R.C.S. Thomas W. Eden, M.D., F.R.C.S.

Sir Harold J. Stiles, M.B., F.R.C.S. (Edin.) Henry Jellett, M.D., F.R.C.P.I.

James Rutherford Morison, M.B., F.R.C.S.

Franklin H. Martin, M.D., Managing Editor

Allen B. Kanavel, M.D., Associate Editor

EDITORIAL AND BUSINESS OFFICES: 30 N. Michigan Ave., Chicago, Illinois, U. S. A.

PUBLISHERS FOR GREAT BRITAIN: Bailliere, Tindall & Cox, 8 Henrietta St., Covent Garden, London, W. C., England

"Warbasse"

The Surgical Treatment for the Surgeon, Specialist and Family Doctor

SAUNDERS, *Publishers*

SEE PAGE 13

Entered as second-class matter May 22, 1913, at the postoffice at Chicago, Ill., under the Act of Congress, March 3, 1897.

Published monthly. Copyright, 1919, by The Surgical Publishing Company of Chicago.



USE
Paragon X-Ray Plates

They are FAST, CLEAN, BRILLIANT

And if you want to see the finest results your apparatus will produce

TRY THEM

THEY MAKE GOOD, as proven by the constant increase in repeat orders received.

IF YOU are not using them, some one else may make the diagnosis you failed on by not taking every opportunity to improve the standard of your work.

Hundreds are building reputations by their use. *Why Not Join Them?* We will help you with technical advice if needed.

If your dealer has no *fresh* Paragon plates in stock, write us, for quick shipment.

We Also Supply

Lower Priced X-Ray Plates
Barium Sulphate for Stomach Work
Dental X-Ray Films and Mounts
Developing Tanks—Soapstone or porcelain enameled, 1, 4 or 6 compartments
Developer Chemicals
Intensifying Screens
Filing Envelopes
Radiator or Regular Coolidge Tubes
X-Ray Protective Materials

Complete Price List and Discount Sheet on request. YOUR NAME should be on our mailing list for monthly X-Ray Bulletin.

Geo. W. Brady & Co. 756 S. Western Avenue **Chicago**

PARAGON X-RAY PLATES

SAVE TWO-THIRDS

Sherman's Bacterial Vaccines, when administered early, will reduce the average course of acute infections like Pneumonia, Broncho-pneumonia, Sepsis, Erysipelas, Mastoiditis, Rheumatic Fever, Colds, Bronchitis, etc., **to less than one-third their usual mortality and duration.**

Sherman's Bacterial Vaccines are prepared in our specially constructed Laboratories, devoted exclusively to the manufacture of these preparations and are marketed in standardized suspensions.

Write for literature.

MANUFACTURER OF BACTERIAL VACCINES

G. H. SHERMAN M.D.
Detroit, Mich. U.S.A.

GALL BLADDER INCISION
J. MEYER'S HOCKEY STICK INCISION
BATTLE-JALAGUIER-KAMMERER-INCISION
McBURNEY INCISION
J. MEYER HOCKEY-STICK INCISION
OBLIQUE SUBCOSTAL INCISION
MEDIAN SUPRA-ABDOMINAL
MEDIAN INFRA-ABDOMINAL
M. VISCHER'S INCISION
FOWLER'S INCISION
PFANNENSTIEL'S INCISION
WOUNDS heal by nature's own device, but the linear scar of primary union is essentially the achievement of the aseptic surgical suture
DAVIS & GECK, INC.
Sterile Surgical Sutures
LABORATORIES: 217-221 Duffield Street
BROOKLYN, N.Y.
Seattle - San Francisco - London
© 1919 - DAVIS & GECK, INC.

CONTENTS—MARCH, 1919

ORIGINAL ARTICLES

1. OBSERVATIONS ON THE PATHOLOGY OF FOREIGN BODIES IN THE AIR AND FOOD PASSAGES; BASED ON THE ANALYSIS OF 628 CASES. *Chevalier Jackson, M.D., F.A.C.S., Philadelphia* 201

2. BLOOD TRANSFUSION. *J. de J. Pemberton, M.D., Rochester, Minnesota* 262

3. THE TREATMENT OF CERTAIN TYPES OF ANORECTAL FISTULA. *Arthur A. Landsman, M.D., New York* 276

4. A PRACTICAL CLASSIFICATION OF CUTANEOUS NEOPLASMS. *F. T. Van Beuren, Jr., M.D., F.A.C.S., New York* 278

5. FURTHER STUDIES IN POSTOPERATIVE PNEUMONITIS. *Captain Mather Cleveland, M.C., U.S.A.* 282

6. HYDATIFORM DEGENERATION IN TUBAL PREGNANCY; A REPORT OF FORTY-EIGHT NEW CASES. *Arthur William Meyer, M.D., Palo Alto, California* 293

7. IMMEDIATE SURGICAL MANAGEMENT OF ACUTE APPENDICITIS IN MILITARY HOSPITALS; SUGGESTING A POSSIBLE RELATIONSHIP BETWEEN THE ONSET OF THE CONDITION IN THOSE CASES WITH A HISTORY OF PREVIOUS ATTACKS AND THE PRESENT METHOD OF ADMINISTERING THE TRIPLE TYPHOID VACCINE. *Hugh McKenna, M.D., F.A.C.S., Chicago* 303

CONTENTS CONTINUED OPPOSITE NEXT PAGE

EMPYEMA TROCAR

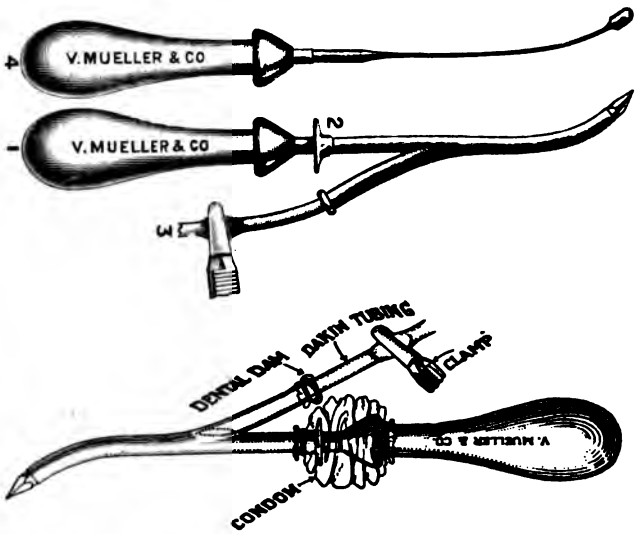

Devised by

VICTOR P. DIEDERICH
Lieut. M. C., U. S. A.

and employed in

Trocar Thoracotomy

At the Base Hospital,
Camp Pike, Ark.,
and other army hospitals.

This important instrument has been developed by us in accordance with Dr. Diederich's instructions.

Supplied complete with accessories and directions by

V. MUELLER & CO., 1771-1783 Ogden Ave., Chicago

ANNOUNCEMENT

AN EPOCH-MAKING ADVANCE IN THE ROENTGEN ART

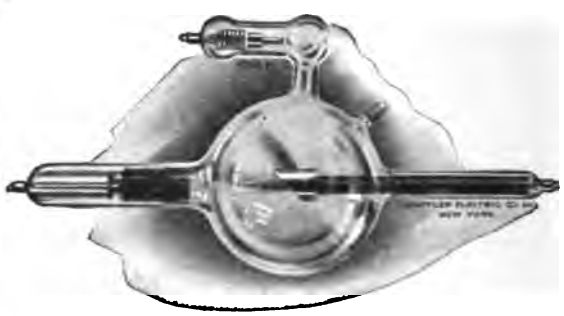

The Wappler Electric Company announces the production of a new Roentgen Ray Tube known as

NITROKEN

This new gas tube remains stable during heavy prolonged exposures and cannot be over-reduced

Full technical and commercial information will be sent upon request

WAPPLER ELECTRIC COMPANY, Inc.
173 E. 87th Street, NEW YORK. U. S. A.



Dr. Charles Geiger's

Electro-Operative Surgical Bone Instruments and Accessories

These instruments are made especially for transplanting bone, dowel making and cranial work. **Water is not required** to keep the cutters from burning the bone when using these instruments, **because of their slow speed.**

A few of the many advantages not found in any other motor bone instruments are: Slow speed, sterilization of motor, its great power, simplicity of chuck, and firmness with which it can be held. Sterilizable shell is included in the set.

Write F. A. Davis Pub. Co., Philadelphia, Pa., for Dr. Charles Geiger's book on **"MODERN OPERATIVE BONE SURGERY."**

The Charles Geiger Mfg. Co.

St. Joseph, Missouri, U. S. A.

CONTENTS—MARCH, 1919—CONTINUED

ORIGINAL ARTICLES — CONTINUED

8. THE OPERATION OF OMENTOPEXY IN CIRRHOSIS OF THE LIVER. *Ellsworth Eliot, Jr., M.D., and Ralph Colp, M.D., New York* 309

DEPARTMENT OF TECHNIQUE

9. INCOMPETENCY OF THE URETEROVESICAL VALVES NOT DUE TO OBSTRUCTION. *Thomas N. Hepburn, M.D., Hartford, Connecticut* 316

10. AN OPERATION FOR THE PRODUCTION OF STERILITY. *R. C. Cupler, M.D., Chicago* 317

11. LOWE'S COLOSTOMY RECEPTACLE. *Captain Horace A. Lowe, M.C., U.S.A.* 319

12. THE POCKET METHOD OF CLOSING SKIN DEFECTS. *Joseph E. Fuld, M.D., New York* 320

13. A SIMPLE METHOD OF EXCLUDING THE SEPTIC END OF THE BOWEL DURING INTESTINAL RESECTION. *R. E. Farr, M.D., Minneapolis, Minnesota* 322

14. SIMPLIFIED TECHNIQUE FOR THE INTRAVENOUS INJECTION OF SALVARSAN OR ANTITOXIN IN COMBINATION WITH NORMAL SALT SOLUTION. *Peter C. Clemensen, M.D., Chicago* .. 323

15. A NEW FORCEPS FOR THE CONTROL OF HÆMORRHAGE AFTER THE REMOVAL OF THE TONSILS. *William A. Gross, M.D., Chicago* 324

CONTENTS CONTINUED OPPOSITE NEXT PAGE

Campbell

EXPERIMENT AND UNCERTAIN RESULTS ARE ELIMINATED WHEN YOU INSTALL

Campbell Roentgen Apparatus

Sure-X Interrupterless Transformer
Tube Tilt Table
Stereoscopic Tube Stand
High Frequency Coils
Electro-Therapeutic
and Roentgen Accessories

Send for Literature

CAMPBELL ELECTRIC CORPORATION
LYNN, MASSACHUSETTS

Economy of Gas **Control of Flow**
Simplicity of Operation

Use S. S. White Nitrous-Oxid and Oxygen. Always reliable. For sale by dealers in surgical or dental supplies.

You should know more about these features of S.S.White Nitrous-Oxid-Oxygen equipment (with ether attachment) for surgical anesthesia.

—

Fully described in Catalog R—mailed free upon request.

The S. S. White Dental Manufacturing Company
"Since 1844 the Standard"
PHILADELPHIA

Treatment of Lobar Pneumonia With Partially Autolyzed Pneumococci— *Pneumococcus Antigen

IN the *Journal of the American Medical Association* (pages 759 to 763—March 16, 1918) Dr. E. C. Rosenow has reported results in the treatment of lobar pneumonia with partially autolyzed pneumococci.

His work has established the harmlessness of this antigen and apparently indicates that it has a definite beneficial action on the disease, especially when given early.

Supplied through the regular drug trade in five c.c. rubber-capped ampoule vials. Order as V-903.

*Dr. Rosenow's Pneumococcus Antigen must not be confused with the vaccine devised by him for prophylaxis against influenza

ELI LILLY & COMPANY, Indianapolis, U.S.A.

CONTENTS—MARCH, 1919—CONTINUED

DEPARTMENT OF TECHNIQUE — CONTINUED

16. ANTHRAX; REPORT OF A CASE. *Captain Louis J. Pritzker, M.C., U.S.A.* 325
17. PERITONEAL DRAINAGE. *C. L. Heald, M.D., Cedar Rapids, Iowa* 326
18. TRANSFUSION APPARATUS. *R. E. Farr, M.D., F.A.C.S., and Earl W. Gilroy, M.D., Minneapolis, Minnesota* 327
19. A SUGGESTED STEP IN THE TECHNIQUE OF INGUINAL HERNIOTOMY. *Lieutenant Marsh Pitzman, M.C., U.S.A.* 329

CORRESPONDENCE

ARTIFICIAL SYNOVIAL FLUID. *Robert T. Morris, M.D., New York* 331

BOOK REVIEWS

Fibroids and Allied Tumors. By Cuthbert Lockyer, M.D., B.S., F.R.C.P., F.R.C.S. 332
Gynecology. By William Graves, A.B., M.D., F.A.C.S. 333
A Text Book of Obstetrics. By Barton Cooke Hirst, A.B., M.D., LL.D., F.A.C.S. 333
Obstetrics, Normal and Operative. By George Peaslee Shears, B.S., M.D., and E. E. Shears, M.D. 333
Diseases of Women. By Harry Sturgeon Crossen, M.D., F.A.C.S. 333
Talks on Obstetrics. By Rae Thornton LaVake, M.D. 333
Books Received 331

AMERICAN COLLEGE OF SURGEONS

CASE RECORDS AGAIN 334



Graduated Low Tone Tuning Forks

Devised by DR. W. G. REEDER

Important Announcement

WE are now able to deliver the first graduated low tone tuning forks manufactured in America. These forks are graduated in four tone intervals from 16 to 64 double vibrations per second. They are free from overtones and guaranteed to be perfect. Otologists who have been unable to obtain such a set of instruments at any figure since the war, are now offered a superior product at a nominal price. These forks are indispensable in accurate functional testing of the ear, especially in cases of incipient conduction deafness and those in which the lower tone limit is disturbed.

No. 1 Reeder's Tuning Fork, 16 to 20 double vibrations, is 23½ inches long and weighs 7½ lbs. . . . . Price $35.00

No. 2 Reeder's Tuning Fork, 24 to 28 double vibrations, is 19½ inches long and weighs 7 lbs. . . . . Price $35.00

No. 3 Reeder's Tuning Fork, 32 to 44 double vibrations, is 17 inches long and weighs 7 lbs. . . . . Price $32.50

No. 4 Reeder's Tuning Fork, 48 to 64 double vibrations, is 14 inches long and weighs 6 lbs. . . . . Price $32.50

SHARP & SMITH

Manufacturers and Exporters of High Grade Surgical Instruments and Hospital Supplies

65 E. LAKE ST. Between Wabash Ave. and Mich. Blvd. CHICAGO, ILL.

Established 1844 Incorporated 1904

THE

RADIUM INSTITUTE

1604 Mallers Bldg., 59 E. Madison St.

Cor. Wabash Ave., Telephone Randolph 5794

CHICAGO

DR. FRANK E. SIMPSON

COUNCIL

DR. F. A. BESLEY — DR. E. C. DUDLEY
DR. A. R. EDWARDS — DR. O. T. FREER
DR. M. HERZOG — DR. L. E. SCHMIDT
DR. G. F. SUKER

TREATMENT of Malignant and Benign Growths with Radium; Postoperative Prophylactic Radiations following the Surgical Treatment of Cancer.

Radium is indicated in inoperable malignant conditions. By its use an inoperable case may become operable.

We desire to confer and co-operate with surgeons, assuring them adequate amounts of Radium to meet the requirements of patients referred to us.



A **Sharp Knife** is a **Satisfaction**
to the **Surgeon**
The **Bard-Parker Knife**
is a Sharp Knife

Handle No. 3 carries Blades Nos. 10 and 11.
Handle No. 4 carries Blades Nos. 20, 21 and 22.
Handles, $1.00 each. Blades, $1.50 per dozen.
Case, holding two handles and two dozen blades, 75c each.

Blades are packed in envelopes containing ½ dozen blades of one size.

Your dealer can supply

Bard-Parker Co., Inc.
37 E. 28th St. NEW YORK

INDEX TO ADVERTISING

Surgical Instruments and Apparatus

American Precision Works..... 15
Bauer & Black..... 16
Bard-Parker Co..... 7
Electro Surgical Instrument Co.... 14
Feick Brothers Co..... 14
Charles Geiger Mfg. Co..... 3
Goodwill Electric Co..... 16
Kny-Scheerer Corporation..... 10
McIntosh Battery & Optical Co... 14
V. Mueller & Co..... 2
Northwestern Steel & Iron Works.. 26
Harvey R. Pierce Co..... 12
J. D. Pollard..... 16
Prometheus Electric Co..... 14
Sharp & Smith..... 6
Taylor Instrument Companies..... 15
Truax, Inc..... 18
Victor Electric Co..... 28
Wappler Electric Co..... 2

Hospital Supplies

Bauer & Black..... 16
General Laboratories..... 15
Good Mfg. Co..... 16
Kny-Scheerer Corporation..... 10
V. Mueller & Co..... 2
Northwestern Steel & Iron Works.. 26
Harvey R. Pierce Co..... 12
Prometheus Electric Co..... 14

Rubber Goods, Gloves, Etc.

B-Z Patch Co..... 27

X-Ray Apparatus, Tubes, Plates, Etc.

American Photo Chemical Co..... 30
Geo. W. Brady & Co.....2nd cover
Campbell Electric Co..... 4
Eastman Kodak Co..... 29
General Electric Co..... 31
Wm. Meyer Co..... 26
Victor Electric Co..... 28
Wappler Electric Co..... 2

Catgut—Ligatures

Armour & Co.....4th Cover
Davis & Geck, Inc..... 1
Hollister-Wilson Laboratories..... 11
Johnson & Johnson..... 25
C. DeWitt Lukens Co..... 24

Anæsthesia Apparatus

Foregger Co..... 15
Safety Anæsthesia Apparatus Concern..... 16
Scientific Apparatus Co..... 9
S. S. White Dental Mfg Co..... 4

Corsets, Bands, Etc.

Earnshaw Knitting Co..... 18
Katherine L. Storm..... 18

Post-Graduate Instruction

Laboratory of Surgical Technique . 36
New York Post-Graduate Medical School and Hospital..... 40

Medical Books

Bailliere, Tindall & Cox..... 37
P. Blakiston's Son & Co..... 17
Lea & Febiger..... 23
Macmillan Co..... 19
Massachusetts General Hospital ... 17
C. V. Mosby Co..... 21
Oxford University Press..... 22
Rebman Company..... 20
W. B. Saunders Co.....Cover and 13

Pharmaceuticals

Abbott Laboratories..... 8
Armour & Co.....4th Cover
Cutter Laboratory.....3rd Cover
General Laboratories..... 15
Hynson, Westcott & Dunning, 4th Cover
Eli Lilly & Co..... 5
H. A. Metz Laboratories, Inc..... 35
Sharp & Dohme..... 34
Dr. G. H. Sherman.....2nd Cover
Standard Oil Co..... 39

Radium

Physicians' Radium Association... 34
Radium Chemical Co..... 9
Radium Company of Colorado.... 25
Radium Institute..... 6

Miscellaneous

Battle Creek Sanitarium..... 36
Colorado Springs..... 37
Gradwohl Biological Laboratories.. 27
Medical Protective Co..... 18
Quaker Oats Co..... 27

Why Take a Chance

with poisonous germicides like mercury bichloride or phenol and

Why Bother

With the inconveniences, instability and inaccuracies of hypochlorite solutions when in **CHLORAZENE,** Dakin's non-poisonous, non-irritating antiseptic, you have a *safe, stable* and *accurate,* definite chemical compound from which solutions are quickly made by simply dissolving the tablets or powder in water?

CHLORAZENE is one of the most powerful germicides known
CHLORAZENE does not irritate
CHLORAZENE is stable and convenient
CHLORAZENE is cheap

Prices on Chlorazene, Chlorazene Surgical Cream, Dichloramine-T (Dakin's Oil-soluble antiseptic) and its solvent, Chlorcosane, Parresine for burns, Parresined Lace Mesh Surgical Dressing, Procaine (Novocain) and Barbital (Veronal) will be quoted upon request.

THE ABBOTT LABORATORIES

Home Office and Laboratories, Dept. 82, Chicago, Illinois

New York Seattle San Francisco Los Angeles Toronto Bombay

This New Bacterin Container

Note the squat shape of this container and the "safety" crimped-on cover.

Saves money for you
Is a great convenience
Is proof against contamination

Why pay the added cost of numerous single-dose ampules and extra packing, when you can have greater convenience, positive sterility, and bulk-package economy by buying your bacterins in these new 5 and 20 mil capacity Abbott bulk bacterin containers?

This is the only bulk bacterin container which is permanently sealed so that the cork cannot become loosened in handling, thus avoiding contamination.

Ask today for complete price list of Abbott Bacterins in ampules and bulk containers.

THE ABBOTT LABORATORIES

Home Office & Laboratories, Dept. 82, Chicago

New York Seattle San Francisco Los Angeles Toronto Bombay

RADIUM

STANDARD CHEMICAL CO.

Efficacious in the treatment of many Benign and Malignant Growths, and in Post-Operative Prophylactic Raying.

We sell Radium on the Basis of U. S. Bureau of Standards measurement. Interesting and helpful literature upon request.

RADIUM CHEMICAL CO.

GENERAL OFFICES - PITTSBURGH, PA.

LITTLE BLDG., BOSTON - MARSHALL FIELD ANNEX BLDG., CHICAGO - 501 FIFTH AVE., NEW YORK - WATSON & SONS, ELECTRO-MEDICAL) LTD., LONDON.

CONNELL GAS OXYGEN APPARATUS

ANAESTHESIA
APPARATUS AND APPLIANCES

THE CONNELL GAS OXYGEN
METER MEASURE APPARATUS, Four Models

THE ANAESTHETOMETER
DELIVERS AUTOMATICALLY ANY VOLUME AND PERCENTAGE OF ETHER VAPOR WITH MATHEMATICAL ACCURACY

CONNELL SUCTION INSUFFLATION APPARATUS
A MOTOR BLOWER MAINTAINING THE STANDARD OF EFFICIENCY SET FOR OUR OTHER MACHINES

SEND FOR OUR BOOKLET *Scientific Anaesthesia*
IT DESCRIBES THE VARIOUS MACHINES WE MAKE

SCIENTIFIC APPARATUS COMPANY, Inc.
162 WEST 34th STREET - - - NEW YORK, N. Y.

Hawley New Fracture and Orthopedic Operating Table



Hundreds of these tables are in use in our Government Hospitals in this country and abroad as there is no other table which will answer the same purposes.

IT IS INDISPENSABLE IN FRACTURE WORK AS IT MAINTAINS THE RE-UNITED FRACTURE PERFECTLY UNTIL THE PLASTER IS SET OR THE GRAFT IS COMPLETED.

Head end is movable to facilitate easy and free access to the back and shoulders for jackets or spicas. Movable sections overlap to prevent soft parts of the body becoming wedged and injured.

Foot plates hold the foot at right angle to the limb and prevent toe drop. Foot plates rotate to any angle for hyper-abduction, hyper-extension, inward rotation and traction; also brings pressure against ball of foot to force the foot into dorsal flexion.

ACCEPT NO IMITATION; write for bulletin showing the genuine Hawley and Albee Surgical Apparatus and Instruments.

The Kny-Scheerer Corporation

Manufacturers of Surgical and Therapeutic Instruments and Apparatus

404-410 West 27th Street, New York, U. S. A.



Preparing Perfect Surgical Gut

No. IX—Testing and Standardizing Laboratories

IN the preceding installments of this series we have illustrated and described the various steps in the manufacture and sterilization of surgical gut as conducted in our Plant and Laboratories, every detail of which has been under the constant observation of competent technical workers from the moment of the animal's slaughter.

To facilitate this work we maintain a most complete series of laboratories — Physical, Chemical and Bacteriological, equipped to the last detail with apparatus calculated to insure accuracy, uniformity and the maximum of protection to the surgeon who discriminates in the selection of his surgical ligatures.

Sterility, tensile strength and elasticity are here determined for the finished product under the most favorable but exacting conditions, and to these laboratories are brought systematic reports for the bacteriological chemist in charge as the material in process of manufacture is carried through to completion.

In this brief chapter and the ones that have already appeared, we believe that we have conclusively demonstrated to the thinking surgeon that unless the source of supply of the raw material is under the immediate observation of the catgut manufacturer from the killing of the sheep to its manufacture into the twisted strand and final sterilization under the same personal control, surgical catgut will always be an enigma and a source of anxiety and controversy to operating surgeons.

A copy of our pamphlet "FROM ABBATTOIR TO TUBE" will be mailed to you on request, together with samples of Hollister "TUBES OF DISTINCTION."

Hollister Ligatures can be obtained wherever surgical supplies are sold

HOLLISTER-WILSON LABORATORIES

4444-46-48 So. Ashland Ave. CHICAGO, U. S. A.

"TUBES OF DISTINCTION"

Pratt-Lowman
Self-Retaining Retractor

for use in the open method of repairing fractures especially in connection with the Albee Motor Saw method.

Devised by Major John B. Lowman, M.C., and Captain R. B. Pratt, M.C., U. S. Base Hospital No. 38.

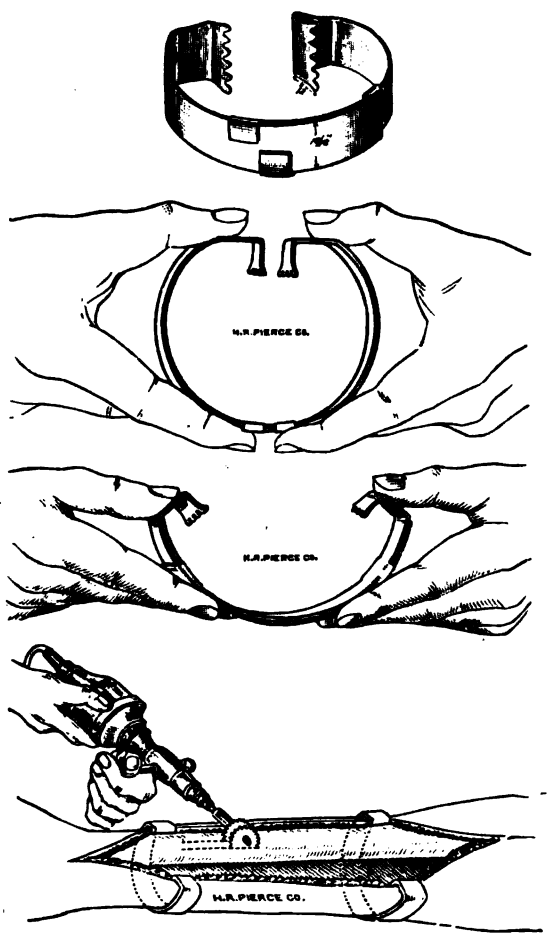

It affords the following advantages:

SIMPLICITY
No parts to be lost. Easy to clean, sterilize, manipulate.

DURABILITY
It not only gives RETRACTION of tissues, but also DEPRESSION of them with an uncomplicated automatic lock in any degree of retraction. Pressure upon its lower surface by the weight of the limb forcing it against the operating table only serves to increase retraction and locking.

It does away with retraction by assistants and with this the danger of extra hands in the operative field and leaves the operator unhindered in the use of the electric saw and drill.

It leaves the bone in a higher plane than the surrounding tissues and so obviates the danger of the saw, drill or spinning shaft engaging with the soft tissues or toweling.

In conjunction with an orthopedic table, assistants can be dispensed with during that stage of the operation in which the saw or drill is in use.

It is a useful addition in a teaching clinic in that it renders the field of operation more visible to spectators.

Made in several sizes.

Manufactured by

HARVEY R. PIERCE COMPANY

1801 Chestnut Street *The Modern Surgical Instrument Store* **PHILADELPHIA**

PITTSBURGH SALES OFFICE: 3030, 3031, 3032, 3033 JENKINS ARCADE

"Warbasse"

The Surgical Treatment for Surgeon, Specialist and Family Doctor

For the surgeon there is hardly need to emphasize the importance of this work. It gives him the ripe judgment of 25 years' extensive and *intensive* surgical practice. He gets here both major and minor surgery — the treatment of every injury or disease or condition requiring the care of the operator, and he gets it all in the clear, clean-cut instruction of a teacher, an operator, a student whose command of the King's English is as unusual as his wealth of surgical learning. He gets everything he has a right to expect to find — *and vastly more!* He finds here many, many things he would not expect to find — dozens and dozens of procedures, methods, and operations not usually found in a work on surgery.

For the specialist, too, emphasis seems unnecessary, because every specialty is covered — brain, eye, ear, nose, throat, nervous system, skin, gynecology, surgical consequences of child-birth, genito-urinary diseases, both male and female, electricity and radiotherapy. And when we say covered, we mean *fully covered.* Not just a smattering of each, but a concise treatment of the *practical side* of each.

For the family doctor, Warbasse's "Surgical Treatment" has a particular appeal, because, first of all, Dr. Warbasse gives *a detailed plan of medicinal and non-operative treatment* whenever such treatments hold out promise. He gives indications, the limitations and results to be expected, frequently adds prescriptions, and always gives dosage. Such conditions, for instance, as rhinitis, tonsillitis, gastric and duodenal ulcers, appendicitis, amebic colitis, gonorrheal urethritis, hemorrhoids, etc. Then he takes up the question of operation, pointing out when surgical interference is demanded, what is to be expected of operation, the choice of operation and the actual technic, illustrated.

After operation, when the cases are returned to the family doctor — what does he then need? He needs post-operative detail and management. He gets it here — *plenty of it.* How to watch for complications, how to combat them, treat them, and carry the patient through to complete and successful recovery.

There is no branch of surgery, major or minor, it does not cover, whether it be general, special, industrial, military, or civilian.

Three octavos, totaling 2637 pages, and *separate desk index volume*, with 2400 original illustrations. By JAMES PETER WARBASSE, M.D., Surgeon to the Wyckoff Heights Hospital, Brooklyn, New York. Per set: Cloth, $30.00 net.

W. B. SAUNDERS COMPANY, West Washington Sq., Phila.

London: 9, Henrietta St., Covent Garden Australian Agcy: Centreway, 263 Collins St., Melbourne

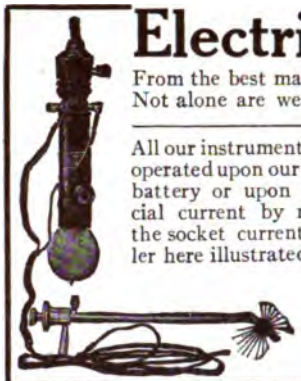

Electrically Lighted Instruments

From the best material obtainable and by skilled workmen E. S. I. Co. instruments are made. Not alone are we the originators, but, as well, we are exclusive manufacturers of the most valuable diagnostic instruments in use. Their position is firmly established among the profession and their usefulness is unquestioned.

All our instruments may be operated upon our tungsten battery or upon commercial current by means of the socket current controller here illustrated.

Koch, Swinburne, Young, Gordon and MacGowan Urethroscopes
Braasch Cystoscopes, E. S. I. Co. Vaginal Specula

These and many other instruments are described and illustrated in our Catalogue, a copy of which will be mailed on request.

For your own protection be sure every instrument is marked "E. S. I. Co."

ELECTRO SURGICAL INSTRUMENT CO.
ROCHESTER, N. Y.

The Surgeon

is generally called upon for advice as to

Artificial Limbs

Why not recommend one that is sure to be SATISFACTORY?

Our Latest Model

with Adjustable Leather Socket, Cordless Ankle, Felt or Sponge Rubber Foot, Ball-bearing Joints

assure the patient of comfort and perfect locomotion.

Our GUARANTEE Covers All Repairs
Write for Catalogue

FEICK BROS. COMPANY
809 Liberty Ave. Pittsburgh, Pa.

The PROMETHEUS
ELECTRIC STERILIZER
With Latest Conveniences

Tray Supported from Body in Raised Position—Not Attached to Cover.

Tray and Contents Freely Removable. Inside Unobstructed. Side Handle on Cover Away from Steam. Drawing-off Faucet on Side. Made in Four Sizes.

THE ONLY ELECTRIC STERILIZER EQUIPPED WITH WIRE-LESS HEATER. Has Automatic Cut-Out. Heat Regulation in Three Degrees at Steriliser.

The Prometheus Electric Co.
245 East 43rd St. New York



McIntosh No. 4 Polysine Generator

Success in Electro-Therapy

MANY a practitioner can trace the origin of his success to the purchase of some piece of good apparatus which enabled him to individualize his system of treatment and give his patients something which they were not getting elsewhere.

With the McIntosh No. 4 Polysine Generator shown you have a means of combating the long train of sequelæ to abdominal insufficiency—conditions in which the slow sinusoidal current is unexcelled.

Ask for an Interesting Booklet "Sinusoidal Therapy" and Get Our Proposition

McINTOSH BATTERY & OPTICAL COMPANY

Eastern Office and Service Station
1777 Broadway, New York

Main Office and Factory
217-223 N. Desplaines St., Chicago

Why Not Have That Satisfaction

of knowing your blood pressure readings are taken with an instrument that *proves* its readings? That instrument is the

Tycos Self-Verifying Sphygmomanometer

$25.00

The Tycos is absolutely self-verifying. It has no adjustments; requires no checking. If the pointer returns to zero, the reading is *correct.*

Have a demonstration at your dealer's. It will gain your good will, as will the daily use hold it.

Tycos Fever Thermometers
Tycos Urinary Glassware

Taylor Instrument Companies
ROCHESTER, N. Y. 700

There's a Tycos and Taylor Thermometer for every purpose.

HYCLORITE
SODIUM HYPOCHLORITE

HYCLORITE

For Infected Wounds

The results obtained from the use of Hyclorite in the treatment of infected injury cases are daily demonstrating the efficacy of this antiseptic in the oxidizing of toxins, and in the removal of necrosed tissue through solvent action. In these respects, according to the work reported by Milroy and also Austin and Taylor, hypochlorites are decidedly superior to the chloramin and dichloramine type of antiseptic.

Hyclorite is always ready for immediate use.

Just add water and apply.

Hyclorite is prepared to a definite hypoclorite strength and alkalinity.

Solutions made from Hyclorite keep much longer than ordinary Dakin's solutions.

There is no waste, testing, or waiting in making a Dakin's solution from Hyclorite.

Price, 32 oz., $1.25

Order from Your Supply House

Accepted by the Council on Pharm. and Chem. for inclusion in N.N.R.

GENERAL LABORATORIES
4711 South Dickinson St.
MADISON - - - WISCONSIN

Gwathmey Apparatus

The advantage of the "Sight Feed"

is not—to *set* the proportion,

it is—to *get* the proportion.

Nor is it—to know the amounts in liters or gallons,

but it is—to know what you are doing.



As an indicator for the quick obtainance and safe maintenance of uniform anesthetic conditions the visible gas flow of the "Sight Feed" is absolutely reliable and permanently so.

Write for Our 1919 Catalog

THE FOREGGER CO.
47 West 42nd St. New York

AMERICAN PRECISION WORKS

135 Cedar Street, New York City

—●—

WE REPAIR

KOLLMANN DILATORS OF ANY MAKE AND EQUIP SAME WITH

NEW-SAFETY PRESSURE GAUGE-NEW

WE DEVELOP

INVENTIONS AND MANUFACTURE ALL KINDS OF SPECIAL MEDICAL APPARATUS.

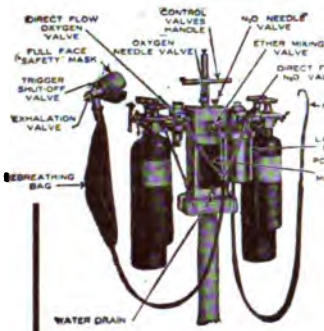

SAFETY GAS-OXYGEN APPARATUS

Simplifies the administration of
NITROUS OXIDE and OXYGEN
with or without an Ether Sequence
Major or Minor Surgery—Obstetrics—Dentistry

Positive mixtures instantly obtained, accurately maintained and clearly shown by the New Sight-Feed-Measurement, which is controlled by a simple water column. No gauges or springs to get out of order.

Complete outfits for Private and Hospital use.

Write for booklet containing full information

SAFETY ANAESTHESIA APPARATUS

CONCERN

Ogden Ave. and Randolph St., Chicago, Ill.

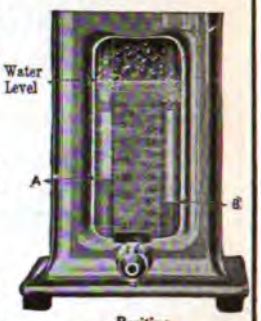

Positive Sight-Feed Measurement

Pollard High Tension Stethoscope

A 'scope with which you can hear the heart sounds through an overcoat, coat and vest, and with which you can easily hear the fetal heart sound. The regulation binaurals are used on this stethoscope.

Try it a week; if not satisfied return and your money will be cheerfully refunded.



Price, postpaid in the U. S., $6.00

John D. Pollard, M.D.

2755 Jackson Blvd. CHICAGO, ILL.

The
Pad Without a Fault

It has none of the drawbacks of other electric pads. It is so near perfection that it is

Guaranteed For One Year

The Goodwill Thermostatic control gives positive temperatures ranging from 100° to 180°. Used and endorsed by leading hospitals and physicians. *Money back if not satisfied.* Price $7.00. Order to-day.

GOODWILL ELECTRIC CO.

69 E. VAN BUREN ST. DEPT. A CHICAGO

B&B *Surgical Dressings*

The Standard for 25 years

BAUER & BLACK

Chicago New York Toronto

WE CAN SUPPLY YOU WITH

Gauze and Bandages

Prices upon request

The Good Manufacturing Co.

156 N. Wells Chicago

Some New Surgical Books

HULL—Surgery In War *(2nd Edition)*

210 Illustrations, Including Colored Plates. 8vo, xv, + 624 Pages. Cloth, $6.00 Postpaid. By ALFRED J. HULL, F.R.C.S., Lieut-Col., Royal Army Medical Corps; Surgeon, British Expeditionary Forces in France. With a Preface by Lieut-General T. H. J. C. GOODWIN, C.B., C.M.G., D.SO., Director-General Army Medical Service of Great Britain. With Contributions by Several Eminent Surgeons at the Front.

BINNIE—Regional Surgery

A Treatise by Eminent Surgeons. Three Octavo Volumes Covering Every Phase of Modern Surgical Practice. Edited by JOHN FAIRBAIRN BINNIE, A.M., C.M., Surgeon to General Hospital, Kansas City. With 1100 Illustrations. Cloth, $21.00 Postpaid.

WALLACE—War Surgery of the Abdomen

By CUTHBERT WALLACE, C.M.G., F.R.C.S., M.B., B.S. (Lond.) Surgeon, St. Thomas' Hospital; Consulting Surgeon, British Armies in France. With 26 Illustrations. 8vo. Cloth, $3.00 Postpaid.

P. BLAKISTON'S SON & CO., *Publishers*

1012 Walnut Street **PHILADELPHIA**

Increased Efficiency In Diagnosis

CASE RECORDS

Edited by LT.-COL. RICHARD C. CABOT, M. R. C., A. E. F.
Professor of Clinical Medicine, Harvard Medical School, and
LT.-COL. HUGH CABOT, C. M. G., R. A. M. C., B. E. F., France
Assistant Professor of Genito-Urinary Surgery, Harvard Medical School

A weekly series of diagnostic problems with discussions and necropsy findings, so arranged that the reader can give himself the discipline of the original clinico-pathological exercises held at the

MASSACHUSETTS GENERAL HOSPITAL

With the return of the editors from war service in France

DISCUSSION OF CASES BY LT.-COL. R. C. CABOT and LT.-COL. HUGH CABOT

will now be resumed.

THE WAR TEST. The value of the series has been proved by vigorous growth in circulation during the past year. Subscribers are constantly sending such comments as these:

"In all my thirty-five years of practice no medical journal has afforded me so much satisfaction as the 'Case Records'; in fact, in my opinion none can compare with them in practical usefulness."

"I find them indispensable." "Of inestimable value." "An aid past all description."

Published by the Massachusetts General Hospital, Boston. Subscription $5.00 per annum in advance. Checks should be made payable to the Hospital.

Sample Copies and Rates to Medical Societies Will Be Sent On Application

"Vanta" Abdominal Binder

KNITTED of soft wool—firm but elastic—it gives just the protection and abdominal support needed, yet always adjusts itself to the full or empty stomach.

A big improvement on the old-fashioned inelastic strip of flannel. Ties with three little bows of *twistless* tape—no dangerous pins—no troublesome sewing.

We would like you to know, Doctor, what an excellent binder this is. Mail us your card, or write on professional letterhead, and we will gladly send you a sample binder free.

EARNSHAW KNITTING COMPANY
1401 West Jackson Blvd - Chicago

The Abdominal Binder illustrated above is only one of the many Vanta Garments that enable baby to be dressed from top to toe without a single pin or button. Our booklet, "Baby's Outfit," describes and illustrates the entire line. May we send you a copy?

SKELETONS

We have secured a large stock of

Selected Skeletons

Prices and descriptions gladly furnished on application

TRUAX

CHARLES TRUAX, Incorporated

141 N. Wabash Ave. CHICAGO

50% BETTER

Prevention Defense Indemnity

1 All claims or suits for alleged civil malpractice, error or mistake, for which our contract holder,

2 Or his estate is sued, whether the act or omission was his own.

3 Or that of any other person (not necessarily an assistant or agent).

4 All such claims arising in suits involving the collection of professional fees.

5 All claims arising in autopsies, inquests and in the prescribing and handling of drugs and medicines.

6 Defense through the court of last resort and until all legal remedies are exhausted.

7 Without limit as to amount expended.

8 You have a voice in the selection of local counsel.

9 *If we lose, we pay to amount specified, in addition to the unlimited defense.*

10 The only contract containing all the above features and which is protection per se. *A sample upon request.*

The MEDICAL PROTECTIVE CO.
***of* Fort Wayne, Indiana**

Professional Protection Exclusively

Storm Binder and Abdominal Supporter

(Patented)

Adapted to use of men, women and children, for any purpose for which an abdominal supporter is needed. **High and Low Operations, Ptosis, Pregnancy, Obesity, Hernia, Relaxed Sacro-Iliac Articulations, Floating Kidney, etc.**

Folder on request—with prices, materials and physicians' testimonials

Mail Orders filled at Philadelphia—within 24 hours

Katherine L. Storm, M. D.
1541 Diamond Street, Philadelphia

A New Macmillan Magazine—A Pioneer in a New Field

THE JOURNAL OF
INDUSTRIAL HYGIENE

Published Monthly with International Abstract

Editor-in-Chief, DAVID L. EDSALL, A.M., M.D., S.D.

Associate Editors

W. IRVING CLARK, JR., M.D. — HARRY E. MOCK, M.D.
ALICE HAMILTON, M.D., — J. W. SCHERESCHEWSKY, M.D.
YANDELL HENDERSON, Ph.D. — C.-E. A. WINSLOW, M.S.
WILLIAM H. HOWELL, Ph.D., M.D., Sc.D., LL.D.

Managing Editors

CECIL K. DRINKER, M.D. — KATHERINE R. DRINKER, M.D.

Plan and Scope of the Journal

This Journal has grown out of the recent establishment of teaching and research in Industrial Hygiene in the Harvard Medical School and is the first periodical covering the field. Such a publication must necessarily display wide vision and therefore it is planned to deal with all the problems of industrial hygiene and sanitation and, in addition, to handle community hygiene, accident prevention, adequate medical and surgical treatment, compensation, insurance and mutual benefit associations, and reconstruction and vocational training of disabled employees. The Journal thus will cover *subjects of vital interests to medical men, industrial engineers, sanitation engineers, sociologists, welfare workers and educators*—especially the vocational training group—as well as subjects of interest to the leaders in both industry and labor. The Journal will also maintain a *large abstract department* covering both foreign and American medical, surgical, technical, trade and professional journals.

Table of Contents, May—Other Numbers to Be Announced Later

MAY ISSUE

Industrial Hygiene, Medicine and Surgery, a Résumé of Its Growth. Part I. Harry E. Mock, M.D., Lieut.-Col., M.C., U.S.A., Office of the Surgeon-General, Division of Reconstruction of Disabled Soldiers; formerly Medical Director of Sears, Roebuck Co.; Instructor, Industrial Medicine and Surgery, Rush Medical College, Chicago, Ill.

The Duties of the Industrial Surgeon in the Shipyard. Philip S. Doane, M.D., Lieut.-Col., M.C., U.S.A., United States Shipping Board, Emergency Fleet Corporation.

The Problem of Fatigue, Reynold A. Spaeth, Ph.D., Associate in Physiological Hygiene, School of Hygiene and Public Health, Johns Hopkins University.

Industrial Poisoning in the United States. Part I. Alice Hamilton, M.D., Special Investigator, Department of Labor.

Telephone Operating: A Study of Its Medical Aspects as Shown by Statistics of Sickness Disability Reports. Anna G. Richardson, M.D., Physician of the New England Telephone and Telegraph Co., Boston, Mass.

Abstracts of current literature, domestic and foreign, dealing with industrial medicine and surgery, with sanitation and community hygiene, with accident prevention and safety devices, with workmen's compensation and insurance, with mutual benefit associations, and with reconstruction and vocational training of disabled employees.

SUBSCRIPTION PRICE:
United States and Canada, $5.00 per Year. Single copies, 75 Cents.
Great Britain, 21 s. per year. Single Copies, 3 s. 6 d.
Foreign, $6.00

Business Offices:
THE MACMILLAN COMPANY
64-66 FIFTH AVENUE - - - NEW YORK

Editorial Offices:
HARVARD MEDICAL SCHOOL
240 Longwood Avenue - - - - Boston, Mass.

THE MACMILLAN COMPANY, 64-66 Fifth Ave., New York
Enclosed find $5.00, for which enter my subscription to the JOURNAL OF INDUSTRIAL HYGIENE for one year, beginning with May, the first number, and until forbid.
Name .....
Address .....
S.G.O. 3-19

REBMAN COMPANY

141 W. 36th St.
NEW YORK

NOTED BOOKS

CORNWALL—A Clinical Treatise on Diseases of the Heart. Price.....$1.50

FLUHRER—Principles of Treatment of Broken Limbs. 21 half-tone plates and 11 textual figures. Price.....$3.00

FOSTER—Diagnosis from Ocular Symptoms. Price.....$6.00

HART—The Diagnosis and Treatment of Abnormalities of the Myocardiac Function. 248 Illustrations. Price.....$4.50

KAUFFMANN—Care of the Mouth and Teeth. Price.....$0.60

MITCHELL—The Doctor in Court. 2d edition, much enlarged. Price.....$1.50

STERN—Fasting and Under-Nutrition in the Treatment of Diabetes. Price.....$2.00

STRONG—Modern Electro-Therapeutics. New edition, 95 illustrations. Price.....$2.00

BARDELEBEN and HAECKEL—Applied Anatomy. In colors. One volume, 204 woodcuts with explanatory text. Price.....$8.00

TOLDT—Atlas of Anatomy for Students and General Practitioners. Revised edition. 1505 illustrations.

VOLUME I

A.—The Regions of the Human Body (Figures 1 to 5).
B.—Osteology (Figures 6 to 377). With Index.
C.—Arthrology (Figures 378 to 498). With Index.....$6.00

VOLUME II

D.—Myology, with a Supplement on the Anatomy of Hernia (Figures 499 to 640). With Index.
E.—Splanchnology (Figures 641 to 932). With Index....$7.00

VOLUME III

F.—Angeiology (Figures 933 to 1123). With Index.
G.—Neurology.
H.—The Organs of the Senses (Figures 1124 to 1505. With Index.....$11.00

Three Volumes complete, $24.00.

KRAUSE—Surgery of the Brain. With 199 (17 of which are in colors) illustrations in the text, 122 figures on 60 Plates in colors and 2 half-tone plates, over 1200 pages. 3 vols., Art. Lea. Price.....$20.00

TANZI—Mental Diseases. 132 illustrations. Price.....$7.50

BIRK—Diseases of Infancy. Price.....$3.50

SHEFFIELD—The Backward Baby. Price..$1.50

ADAM—Ophthalmoscopic Diagnosis. 18 illustrations in the text. 86 colored figures. Price.....$7.00

TIBBLES—The Theory of Ions. Price.....$1.00

GREEFF—External Diseases of the Eye. 84 colored illustrations. (New Edition). Price...$7.00

ROEMER—A Text-Book of Ophthalmology in the Form of Clinical Lectures. 186 black and white illustrations in the text and 58 figures in colors. 896 pages. (New Edition). Price.....$6.00

GOURAUD—What Shall I Eat? Price.....$2.00

ASCH—Gonorrhea (New Edition). Price...$1.50

OPPENHEIMER—Practical Points in Gonorrhea. Price.....$1.25

RUMPEL—Cystoscopy. 107 illustrations (85 in colors). Price.....$6.00

CARLSON—Obstetrical Quiz for Nurses. Price.....$1.75

KISCH—Sexual Life of Woman. Illustrated. Price.....$6.00

KRAUSE (RUDOLPH)—Normal Histology, Including Microscopical Anatomy. 502 pages, 30 figures in the text, 208 magnificent illustrations in many colors on 98 plates. Part I.....$0.75
Part II..... 5.50

KRAUSE (RUDOLPH)—Textbook of Histology. Illustrated. Price.....$3.00

SENATOR-KAMINER—Health and Disease in Marriage and the Married State. Price...$6.00

KLOPSTOCK and KOWARSKY—Clinical Chemistry, Microscopy and Bacteriology. 70 illustrations (27 in colors). Price.....$3.50

McBRIDE—Alcoholism—Drug Narcotism. Price.....$2.50

WOODRUFF—Effects of Tropical Light on White Men (Medical Ethnology). Price.....$3.50

FOREL—The Sexual Question. Illustrated. Price.....$5.00

KRAFFT-EBING—Psychopathia Sexualis. Price.....$4.00



One of the really worth-while books of the year

903 pages + xxxii, 223 illustrations, 11 full-page plates in colors.
Price, silk cloth $7.50

—*the last word on acidosis*

Nothing terrorizes a surgeon more than the development of acidosis in a patient.

Much of the mystery surrounding this condition has been cleared up.

Much has been done in an experimental way to enable the surgeon to detect the development of this condition, and there are effective methods that can be employed to prevent it.

—these points on acidosis, and many other important ideas concerning physiology that are of value to the surgeon are brought out in the new book by Doctor Macleod on—

Physiology and Biochemistry
in Modern Medicine

Every surgeon should have a copy of this book. Its teaching is one of the chief corner stones of a well-balanced surgical foundation. The whole subject of physiology and biochemistry has been covered in an entirely different manner in this new work, and it has been pronounced by critics everywhere as a work of the highest order.

By **J. J. Macleod, M.B.,** Professor of Physiology in the University of Toronto; formerly Professor of Physiology in Western Reserve University. Assisted by ROY G. PEARCE, B.A., M.D., Director of Cardio-Respiratory Laboratory of Lakeside Hospital; and by other well-known physiologists.

☞You should not deny yourself for another day the SERVICE that you will derive from a study of this great book. No use writing—just sign the attached coupon and mail, but do it today, NOW, before you lay aside this journal.

C. V. Mosby Co.
Medical Publishers
ST. LOUIS - U. S. A.

Write for a copy of our new 88-page catalog of Medical Books.

Surg.
G. & O.

C. V. MOSBY COMPANY
St. Louis

Please send me one copy of **Macleod — Physiology and Bio-Chemistry in Modern Medicine,** for which I enclose my check for $7.50, or you may charge to my account.

Name.....

.....

.....

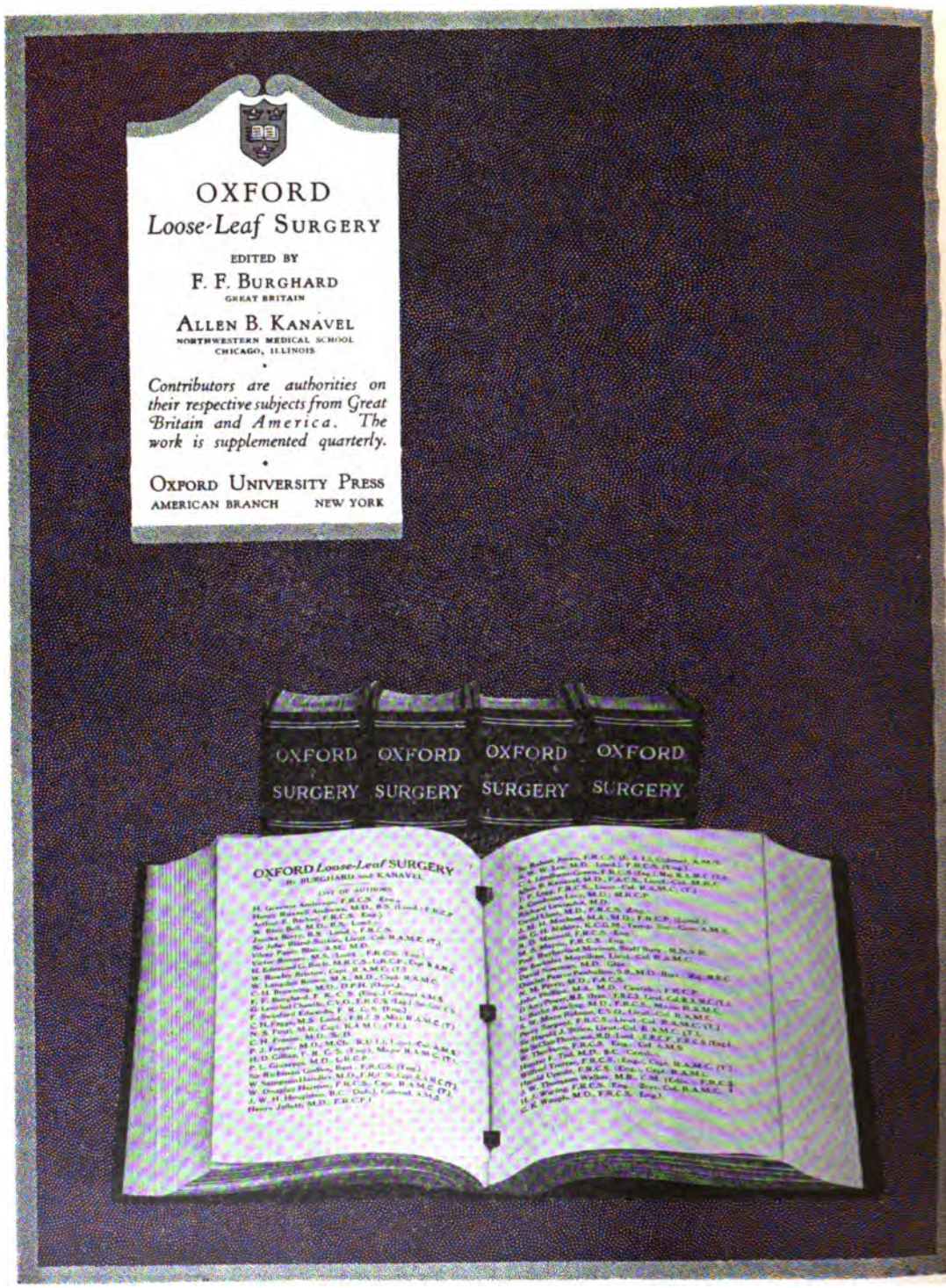
OXFORD
Loose-Leaf SURGERY
EDITED BY
F. F. BURGHARD
GREAT BRITAIN
ALLEN B. KANAVEL
NORTHWESTERN MEDICAL SCHOOL
CHICAGO, ILLINOIS
Contributors are authorities on their respective subjects from Great Britain and America. The work is supplemented quarterly.
OXFORD UNIVERSITY PRESS
AMERICAN BRANCH NEW YORK
OXFORD SURGERY
OXFORD SURGERY
OXFORD SURGERY
OXFORD SURGERY
OXFORD Loose-Leaf SURGERY

Books for Surgeons

ASHHURST—Surgery
Over 1000 informative illustrations, mostly originals.
Octavo, 1140 pages, 1039 illustrations. Cloth, $6.00.

BREWER—Surgery
A complete reference work by a master of clinical surgery.
Octavo, 1020 pages, 523 illustrations. 3d Ed. Cloth, $5.50.

BROWN—Oral Surgery
Up-to-the-minute on war surgery, conductive anesthesia, focal infection, etc.
Octavo, 734 pages, 590 illustrations. *New (3d.) Edition.* Cloth, $7.oc.

LYNCH—Rectum and Colon
Operative steps are carefully shown.
Octavo, 596 pages, 228 engravings, 9 colored plates. Cloth, $5.00 net.

DAVISON & SMITH—Autoplastic Bone Surgery
A comprehensive study of transplantation of bone, bone regeneration and repair.
Octavo, 369 pages, 174 engravings. Cloth, $3.50.

KANAVEL—Infections of the Hand
Invaluable to surgeons doing industrial work or still in Military Service.
Octavo, 498 pages, 161 illustrations. 3d Ed. Cloth, $4.00 net.

SPEED—Fractures and Dislocations
A sound and practical exposition of this subject.
Octavo, 888 pages, 656 engravings. Cloth, $6.00.

STIMSON—Fractures and Dislocations
No one treating these conditions can afford to be without this leading authority.
Octavo, 946 pages, 514 illustrations, 39 full page plates. *New (8th) Edition.* Cloth, $6.00.

WARREN—Principles and Practice of Surgery
A clear account of present-day methods by a famous English operator.
Two octavo vols. about 700 pages each, 504 original illustrations. Cloth, $7.50.

CRAGIN—Obstetrics
Based on over 35,000 deliveries, covers subject completely.
Octavo, 858 pages, 512 illustrations. Cloth, $6.00.

DUDLEY—Gynecology
Twenty-two drawings show steps in Myomectomy and Hysteromyomectomy, twenty-five on Perineorrhaphy.
Octavo, 795 pages, 463 illustrations. 6th Ed. Cloth, $5.00.

FINDLEY—Gynecology
A complete exposition, covering many points not generally found in such works.
Octavo, 954 pages, 670 illustrations. Cloth, $6.00.

JELLETT—Practice of Gynecology
By a foremost English authority, operations described with profuse illustrations.
Octavo, 618 pages, 385 illustrations. Cloth, $6.00.

HAYDEN—Venereal Diseases
Emphasizes the practical clinical aspects, and proven methods of diagnosis and treatment.
12 mo., 365 pages, 133 engravings. 4th Ed. Cloth, $2.50.

THOMPSON—Syphilis
Immediately recognized as a leading authority. Illustrations are largely photographs from the author's practice in Hot Springs.
Octavo, 415 pages, 84 illustrations. Cloth, $4.25.

CABOT—Modern Urology
The latest Urology, covering every phase of Urology, by the country's leading Urologists.
Two octavo volumes, over 700 pages each, 632 engravings, 17 plates. *New.* Per volume: Cloth, $7.00, net.

VEDDER—Syphilis and Public Health
Covers Infection, Transmission, Prophylaxis, Control, Wassermann Technique, etc.
12 mo., 315 pages. Cloth, $2.25.

JELLIFFE & WHITE—Diseases of the Nervous System
War psychoses and psychoneuroses covered—increased space on diseases of the glands and internal secretions.
Octavo, 938 pages, 435 illustrations. *New (2d) Edition.* Cloth, $7.00.

BACON—Otology
Text on suppurative inflammation of labyrinth entirely revised, also on adenoids, enlarged tonsils, submucous resection of nasal septum, etc.
12mo. 583 pages, 206 illustrations. *New (7th) Edition.* Cloth, $3.00.

BALLENGER—The Ear, Nose and Throat
The outstanding authority in its field. The His leukocyte—extract therapy in detail.
Octavo, 1080 pages, 556 illustrations, 4th Ed. Cloth, $5.50.

BALLENGER & WIPPERN—The Eye, Ear, Nose & Throat
Covers the specialty of the four organs, as developed from clinical experience.
12 mo., 524 pages, 188 illustrations. *New (2d) Edition.* Cloth, $3.50.

CARTER—Nutrition and Clinical Dietetics
Modern and giving special attention to diet in relation to Surgical operations.
Octavo, 646 pages, illustrated. *New.* Cloth, $5.50.

AARON—Diseases of the Digestive Organ
Symptoms; analysis of stomach and duodenal contents, and feces; diagnosis and treatment—given clearly.
Octavo, 818 pages, 172 illustrations. *New (2d) Edition.* Cloth, $7.00.

LUMB—Systematic Treatment of Gonorrhea
The therapeutic measures found most practical in Great Britain's campaign against venereal disease.
12 mo., 119 pages. Cloth, $1.50.

BRAUN—Local Anesthesia
The various means and aids, effects, toxic actions, methods, technique, value and indications.
Octavo, 399 pages, 215 illustrations. Cloth, $4.25 net.

TREVES—Surgical Applied Anatomy
Every chapter revised, 27 new illustrations. Considerable additions to "Orthopedic Anatomy," necessary for successful treatment of stiffened joints and disabled limbs.
12 mo., 702 pages, 153 illustrations largely colored. *New (7th) Ed.* Cloth, $3.00 net.

Tear this page out—check books wanted—Enclose remittance or have them charged, as you prefer

PHILADELPHIA **LEA & FEBIGER** NEW YORK

Lukens Sterile Catgut

TRADE (Bartlett Process) MARK

Make the Test Yourself

Compare It Point for Point
With Any Other Catgut
We Will Send the Samples

It is sterile, antiseptic, strong, supple, elastic: free from excess oil; will not untwist in using and is more than usually resistant to absorption.

Sizes 00-4 Plain *Sizes 00-4 Tanned*

C. DE WITT LUKENS CO.
4908 Laclede Avenue
ST. LOUIS MO., U. S. A

FOR SALE BY ALL DEALERS.

The thought behind the tube—
"the patient on the table"
Van Horn
Sterling
Not "good enough"-but the best from every standpoint-alone assures that degree of "Catgut Safety" demanded when the patient on the table is "ONE OF MY OWN FAMILY."
Only on this peculiarly personal basis is "Van Horn" Catgut supplied to the profession.
Johnson & Johnson
VAN HORN and SAWTELL DEPARTMENT,
NEW BRUNSWICK, N. J.

RADIUM

Salts of Any Desired Purity

STANDARD APPLICATORS

Guaranteed by U. S. Bureau of Standards Certificate

RADIUM EMANATION STATIONS

We furnish Scientific Installations designed to efficiently separate the Emanation from Radium.

The Emanation can be readily put into applicators, leaving the entire supply of Radium Intact.

Write us for information and estimates.

THE RADIUM COMPANY
OF COLORADO

DENVER *Incorporated* COLORADO

PURVEYORS TO HIS BRITANNIC MAJESTY'S GOVERNMENT

Adopted by the Nation

as "standard" for Army and Red Cross service, and therefore demanded in great numbers in field and base hospitals, at the front and in training camps, the

National High Pressure Sterilizer

was practically off the market to private users for many months. The government demand is still large, but we are gradually accumulating stock for private use and can now fill orders promptly for any of the

Three Sizes: Doctors', $60, Medium, $85; Hospital, $145

Most good supply houses handle the National. Order from your dealer. If he hasn't what you want, write us for full information and the name of the National dealer nearest you.

NORTHWESTERN STEEL & IRON WORKS
882 Spring Street **Eau Claire, Wis.**

THE MEYER MULTOSCOPE

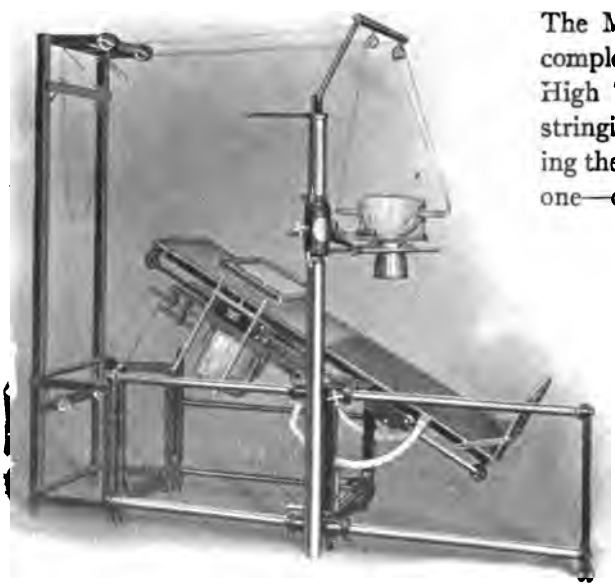

The Meyer Multoscope is furnished complete with Self Contained Aerial and High Tension Switch, eliminating the stringing of wires in a room and making the placing of the apparatus a flexible one—changeable as desired. No current wasted in excess wiring. The last word in classiness.

It covers every phase of Modern X-Ray Work.

Send for the
MULTOSCOPE BULLETIN

Price complete $1100.00

THE WM. MEYER COMPANY

817 WASHINGTON BLVD. **CHICAGO, ILL.**

Do You Want the Highest Order of Serological Diagnosis?

Send Your Specimens to us for

Wassermann and Hecht-Gradwohl Tests,
Gonorrheal Complement Fixation,
Tuberculosis Complement Fixation.

All other Laboratory Tests.

Gradwohl Biological Laboratories.

R. B. H. GRADWOHL, M.D., Director.

928 N. Grand Ave. ST. LOUIS, MO.

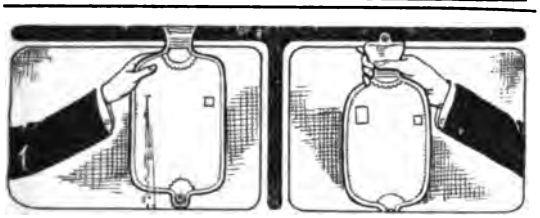

Patch — All Your Leaking, Punctured

HOT WATER BOTTLES

With the Never-Failing, Cleanly

E-Z SELF CEMENTING SELF VULCANIZING **PATCH**

WIDELY used in hospitals everywhere because so easy and clean to apply—no tedious, sticky messes of glue or cement—just a little touch of gasoline and on goes E-Z patch to STAY. During sterilization or boiling it becomes actually vulcanized to the bag; can't peel or tear off. Have some handy—they will save time and money.

PRICES
E-Z Patches for Hot Water Bottles, Four for 25c; Hospital Size Pkg., Twenty for $1.00.

THE E-Z PATCH CO.
Manufacturers of Patches for Surgical and Household Rubber Goods
AKRON - - - OHIO

Oats Cost 5c
Per 1000 Calories

This Costs 57c
Per 1000 Calories

Quaker Oats supply 1,810 calories of energy per pound. Eggs supply 635 per pound—about one-third as much.

Meats, eggs, fish and fowl cost from 8 to 18 times Quaker Oats for the same calory value.

Served in place of meat, each large package of Quaker Oats saves about $3.

And the food is better-balanced. The oat is almost the ideal food—rich in minerals 16 per cent protein.

Quaker Oats

These are extra-grade oat flakes, rolled from queen grains only—just the richest, plumpest oats. We get but ten pounds from a bushel. The result is superlative flavor without extra price.

The Quaker Oats Company
Chicago (3009)

VICTOR

A Medium Priced X-Ray Apparatus to Meet Every X-Ray Demand

was the predominating thought in the minds of the engineers who, in view of the rapidly advancing art of roentgenology and the ever increasing requirements of the x-ray generator, designed the

Victor Model "New Universal" Roentgen Apparatus

For radiography, fluoroscopy and roentgenotherapy, this apparatus covers the entire range with simplified and refined control. A modern x-ray generator for the present day art.

Details in Bulletin 217 — write for it

VICTOR ELECTRIC CORPORATION

Manufacturers of a Complete Line of Roentgen and Electro-Medical Apparatus

CHICAGO
236 S. ROBEY ST.

CAMBRIDGE, MASS.
66 BROADWAY

NEW YORK
131 E. 23d ST.

Sales and Service Stations:

NEW YORK, N. Y.
131 E. 23d St.
CAMBRIDGE, MASS.
66 Broadway
PHILADELPHIA, PA.
25 S. 17th St.
OMAHA, NEBR.
3042 Cass St.
SEATTLE, WASH.
823 White Bldg.
PORTLAND, ORE.
803 Morgan Bldg.
KANSAS CITY, MO.
414 E. 10th St.
BIRMINGHAM, ALA.
619 Brown Marx Bldg.
TORONTO, CANADA
24 Hayter St.

CHICAGO, ILL.
30 E. Randolph St.
236 S. Robey St.
CHARLOTTE, N. C.
11 Dartmouth Pl.
ALBANY, N. Y.
82 S. Grove Ave.
LOUISVILLE, KY.
433 Atherton Bldg.
ROCHESTER, N. Y.
840 Genesee St.
NEW ORLEANS, LA.
606-608 Maison Blanche
LOS ANGELES, CAL.
4002 Walton Ave.
MINNEAPOLIS MINN.
220 La Salle Bldg.
AUSTIN, TEXAS
708 Colorado St.

CLEVELAND, OHIO
505 Frederick Bldg.
PITTSBURGH, PA.
620 Fulton Bldg.
FT. WAYNE, IND.
1333 Calhoun St.
DES MOINES, IOWA
518-22 Utica Bldg.
WINNIPEG, CANADA
Keewayden Block
VANCOUVER, CANADA
536 Smythe St.
SAN FRANCISCO, CAL.
334 Sutter St.
BUFFALO, N. Y.
318 Pearl St.
DETROIT, MICH.
103 Broadway

That important case may depend on

Eastman Dupli-Tized X-Ray Films

There's satisfaction in obtaining perfectly rendered quality, when conditions of rare pathological interest are involved. Dupli-Tized X-Ray Films more nearly answer every requirement of the Roentgenologist, for speed and dependable results, than any other x-ray material on the market.

Ask your dealer for Eastman Dupli-Tized X-Ray Films.

EASTMAN KODAK CO., ROCHESTER, N. Y.

Distinct Differentiation

Distinct differentiation in fine tissue work is facilitated by the use of Diagnostic X-Ray Plates. They show a wealth of detail—a clear cut contrast—that is of exceptional value in the portrayal of kidney and gall bladder work.

Combined with density, contrast, detail, the Diagnostic X-Ray Plate possesses superior speed. It is the fastest plate made—100% faster than others.

Only new selected glass, free from flaws, is used in their manufacture. Equally good for direct and screen work.

AMERICAN PHOTO CHEMICAL COMPANY
ROCHESTER NEW YORK

For Sale by Leading Supply Houses

DIAGNOSTIC

The Essential Definition of Image Is Assured by Correct Use of the Proper Size Focal Spot

Radiator Type Coolidge X-Ray Tube

—an exceptionally fine focus tube for Radiography and Fluoroscopy.

Immediate Shipment can be Made

General Electric Company

General Office Schenectady, N.Y.

35B-9

Advance Information

Original articles which are to appear in early issues

Ununited Fracture of the Patella and of the Olecranon....FRED H. ALBEE, M.D., New York

The Experimental Production of Pancreatitis in Animals as the Result of the Resistance of the Common Duct Sphincter..... EDWARD ARCHIBALD, M.D., Montreal

Polyposis of the Stomach.....D. C. BALFOUR, M.D., Rochester, Minn.

The Empyema Problem.....EMIL G. BECK, M.D., Chicago

Acute Appendicitis Complicating Epidemic Influenza; with Report of Eight Cases.....
.....MOSES BEHREND, M.D., Philadelphia

Necessity for Special Positions in the Radiographic Study of Shoulder Cases.....
.....W. W. BOARDMAN, M.D., and M. DONOVAN, M.D., San Francisco

Radiographic Diagnosis in Renal Tuberculosis.....
.....W. F. BRAASCH, M.D., and F. A. OLSON, M.D., Rochester, Minn.

Intrinsic Trifid or Double Hour-Glass Stomach...JOSEPH P. F. BURKE, M.D., Buffalo, N. Y.

The Treatment of Hodgkin's Disease..... CURTIS F. BURNAM, M.D., Baltimore

The Use of Continued Extension by Means of a New Extension Frame in the Bloodless Reduction of Congenital Dislocation of the Hip.....
.....JOHN W. CHURCHMAN, M.D., New Haven, Conn.

Pancreatic Lymphangitis With and Without Jaundice..JOHN B. DEAVER, M.D., Philadelphia

The Rôle of the Cystic Duct in Recurring Cholecystitis..J. EARL ELSE, M.D., Portland, Ore.

Choice of Method in Operations upon the Pituitary Body.....
.....CHARLES H. FRAZIER, M.D., Philadelphia

Syphilitic Induration of the Vulva.....JOSEPH F. GALLAGHER, M.D., Nashville, Tenn.

The Primary Suture of Wounds .....PROF. GEORGES GROSS, Nancy, France

Acute Intestinal Obstruction Following Appendectomy.....
.....ANTHONY H. HARRIGAN, M.D., New York

The Radical Operation for Teratoma Testis; with Report of Five Cases.....
.....FRANK HINMAN, M.D., San Francisco

Interposition Operation for the Cure of Prolapsus Uteri and Cystocele.....
.....F. W. JOHNSON, M.D., Boston

Tuberculosis of the Cervix Uteri; with Report of a Case.....
.....G. A. MOORE, M.D., Brockton, Mass.

New-Growths of the Testis, Their Symptomatology, Pathology, Diagnosis and Treatment
.....C. RUTHERFORD O'CROWLEY, M.D., Newark, N. J.

Negative Pressure versus Free Open Drainage in Thoracic Empyema.....
.....J. CHRIS O'DAY, M.D., Honolulu, Hawaii

Banti's Disease, Reporting Four Operative Recoveries.....
.....E. M. PRINCE, M.D., Birmingham, Ala.

Observations Regarding the Indications for the Operation of Cranial Decompression.....
.....WILLIAM SHARPE, M.D., New York

Observations on Empyema.....J. GARLAND SHERRILL, M.D., Louisville, Ky.

Note on the Recurrence of Exophthalmic Goiter after Thyriodectomy.....
.....HARRY G. SLOAN, M.D., Cleveland, Ohio

Laparoplasty by a New Method.....WELLER VAN HOOK, M.D., Chicago

The Status of the Vesical Sphincter after Prostatectomy.....
.....ERNEST M. WATSON, M.D., Buffalo, N. Y.

Treatment of Purulent Arthritis by Wide Arthrotomy Followed by Immediate Active Mobilization..... PROF. CH. WILLEMS, Ghent, Belgium

War Amputations.....CAPTAIN PHILIP D. WILSON, M.C., U. S. A.

Advance Information

Original articles which are to appear in early issues

The Surgery of Tendon Transposition with Special Reference to the Importance of the Tendon Sheath.....M. A. BERNSTEIN, M.D., Chicago

Congenital Diverticulæ of the Intestines; Report of Case of a Tumor Growing from the Tip of an Apparent Congenital Diverticulum in the Lower Sigmoid Region.....WILLIAM T. BLACK, M.D., Memphis, Tenn.

Gynecological Pelvic Drainage, Its Indications, Methods, and Materials.....J. WESLEY BOVEE, M.D., Washington

Gunshot Fractures of the Femur.....J. R. BUCHBINDER, M.D., Chicago

Devices Useful in Fracture Work.....JOHN E. CANNADAY, M.D., Charleston, W. Va.

The Treatment of Undescended or Mal-Descended Testis with Particular Reference to End-Results; Report of 415 Cases.....WILLIAM B. COLEY, M.D., New York

The Acute Abdomen.....F. GREGORY CONNELL, M.D., Oshkosh, Wis.

Ectopic or Pelvic Kidney. E. S. JUDD, M.D., and S. W. HARRINGTON, M.D., Rochester, Minn.

A Gauze Sponge Spontaneously Expelled from the Urinary Bladder.....G. PAUL LAROQUE, M.D., Richmond, Va.

Prostatectomy with Its Preparatory and Postoperative Treatment.....BRANSFORD LEWIS, M.D., St. Louis

Contribution to the Study of the Surgical Treatment and Prognosis of Empyema Following LaGrippe.....MAJOR L. LEYVA and MAJOR LEGENDRE, French Army Medical Service

Scalpel Sharpening.....G. G. LITTLE, M.D., Rochester, Minn.

Clinical Efficiency and Terminology in Cancer of the Breast.....WILLIAM CARPENTER MACCARTY, M.D., and H. MILTON CONNER, M.D., Rochester, Minn.

Are We Justified in Removing Comparatively Healthy Gall-bladders?.....W. H. MAGIE, M.D., Duluth, Minn.

Treatment of the Sac in Herniorrhaphy.....A. MERRILL MILLER, M.D., Danville, Ill.

Notes on Two Signs in Chronic Appendicitis.....ROBERT T. MORRIS, M.D., New York

The Surgical Treatment of Empyema.....MAJOR ALEXIS V. MOSCHCOWITZ, M.C., U.S.A.

Infective (Secondary) Hæmorrhages from War Wounds; a Clinical and Pathological Study.....CAPTAIN HAROLD NEUHOF and CAPTAIN FORDYCE B. ST. JOHN, M.C., U.S.A.

Some Points in Surgery of the External Carotid Artery.....WILLIAM PERRIN NICHOLSON, M.D., Atlanta, Ga.

Summary of the Surgical Treatment of Goiter...MILES F. PORTER, M.D., Fort Wayne, Ind.

Malignant Leiomyomata.....MINA SHEPARD PROPER and BURTON T. SIMPSON, M.D., Buffalo, N. Y.

Notes on Vesical Diverticula; a Modified Technique of Surgical Attack.....NATHANIEL P. RATHBUN, M.D., Brooklyn

Reconstruction of the Uterus.....CHARLES R. ROBINS, M.D., Richmond, Va.

Some Technical Points in Gastro-Enterostomy and Gastroplication.....ARNOLD SCHWYZER, M.D., St. Paul, Minn.

Congenital Radio-ulnar Synostosis.....JAMES WARREN SEVER, M.D., Boston, Mass.

Practical Considerations with Regard to Permanent Colostomies.....W. E. SISTRUNK, M.D., Rochester, Minn.

The Use of Automobile Inner Tubes to Provide Lung Exercises and to Make Esmarch Bandages and Tourniquets.....CARROLL SMITH, M. D., St. Louis

A Method of Exposing the Musculospiral and the Posterior Interosseous Nerves.....CAPTAIN BYRON STOOKEY, M.C., U.S.A., and STACY GUILD, Ph.D., Ann Arbor, Mich.

A New Conception of Amputation.....J. P. WARBASSE, M.D., Brooklyn

Fractures of the Neck of the Femur in the Feeble.....W. D. WISE, M.D., Baltimore

every surgeon knows

the annoyance of using slowly or imperfectly soluble hypodermic tablets; how at times tiny fragments of such tablets block up needles.

Every surgeon who uses our hypodermics knows that they dissolve almost instantly and that the solution is so perfect that blocking of needles is an impossibility.

Leading druggists everywhere supply S&D H. T.'s if specified—often by preference even if not specified. They, too, recognize us as "the hypodermic tablet people."

SINCE 1860 *Sharp & Dohme*
CAREFUL CONSCIENTIOUS CHEMISTS

RADIUM RENTAL SERVICE

By The Physicians' Radium Association of Chicago

(Incorporated under the laws of Illinois, "Not for Profit")

BOARD OF DIRECTORS
William L. Baum, M. D.
N. Sproat Heaney, M. D.
Frederick Menge, M. D.
Thomas J. Watkins, M. D.
Albert Woelfel, M. D.

MANAGING DIRECTOR
Albert Woelfel, M. D.

ESTABLISHED to make Radium more available in the *Middle States* and to furnish advice based on extensive observations, about its approved therapeutic uses. Maintains the equipment, large and complete in its makeup, that is needed to meet the special requirements of any case in which radium therapy is indicated. Radium loaned to any responsible physician. Moderate rental fees charged.

For Full Particulars Address

THE PHYSICIANS' RADIUM ASSOCIATION

1104 Tower Bldg., 6 N. Michigan Ave., Chicago Telephones, Randolph 6897-6898

NEOSALVARSAN

(Neoarsphenamine-Metz)

Now Ready for Distribution

Manufactured by

H. A. Metz Laboratories, Inc.

122 Hudson Street

NEW YORK

THE BATTLE CREEK SANITARIUM AND HOSPITAL—Established 1866

Medical. Surgical Orthopedic
Neurological Obstetrical Reconstructive

Educational Departments

Training School for Nurses Normal School of Physical Education School of Home Economics and Dietetics
Students received on favorable terms Registered trained nurses, dietitians and physical directors supplied

Descriptive literature mailed free upon request

THE BATTLE CREEK SANITARIUM
Box 243, BATTLE CREEK, MICHIGAN

Surgical Technique: Instruction and Practice

AN ORIGINAL plan of teaching Surgical Technique, giving the instruction, and enabling the doctor to do the operations over and over, until he has mastered all details. Particular attention is given to the table toilet, and the work is performed as humanely as if the operations were being done upon an anaesthetized human. *The operations are all performed by the student.*

Each table is furnished with the same instruments that are to be found in any well-equipped operating room, and gowns and gloves are supplied to each student.

The Laboratory is open daily from 8:30 to 5 o'clock, which makes it possible for the man whose time away from his practice is limited, to get the work in the shortest possible time.

Special courses may be had in surgical anatomy on the cadaver.

Northeast Corner of Operating Room

Personal Instruction, Actual Practice, and Exceptional Equipment. Course Completed in 7 Days (50 hours), Minimizing Time Away from Practice.

As to the Plan, Time, Fee, etc., Address

The Laboratory of Surgical Technique

Phone Midway 4896 7629 Jeffery Ave., CHICAGO

The L. of S. T. of Chicago

Gentlemen: Send me information regarding the above.

Name.....
City.....
State.....

MID WINTER HERE IS MORE LIKE SPRINGTIME

Bright, warm, sunshiny days are the rule—yet there's a tang to the air in this mild, high climate that refreshes, strengthens and invigorates. The patient whose system is weakened by overwork or thru long illness will find here the rest that builds up! Motoring, riding, hiking, golf and every outdoor sport.

Ask for our handsomely illustrated 88-page book written by physicians of high standing who know just your problem. It will be sent you free.

Climatic Conditions Committee
Chamber of Commerce
151 Independence Bldg. Colo. Springs, Colo.

NOW READY ***Third Edition With New Illustrations*** ***Thoroughly Revised***

MUNRO KERR'S
OPERATIVE MIDWIFERY

A Guide to the Difficulties and Complications of Midwifery Practice

Royal Octavo. Pp. xvi. + 725. With 308 Illustrations. Price in Britain 25/- Net

By J. M. MUNRO KERR, M.D., C.M., Glasg., Fellow of the Royal Faculty of Physicians and Surgeons, Glasgow; Hon. Fellow, American Gynæcological Society; Professor of Obstetrics and Gynæcology, Glasgow University (Muirhead Chair); Obstetric Physician, Glasgow Maternity Hospital; Gynæcologist, Royal Infirmary; Past President of the Glasgow Obstetrical and Gynæcological Society.

"We regard this book as the most considerable addition to English obstetrical literature that has been made for a long time."—*British Medical Journal*.

LONDON
Bailliere, Tindall & Cox
8 Henrietta Street, W. C.

NEW YORK
Wm. Wood & Co.
Fifth Avenue

BOUND VOLUMES

Surgery, Gynecology and Obstetrics is especially designed for binding in book form. Our standard volumes are substantially bound in an extra good grade of blue art canvas, stamped in gold. Each volume consists of six numbers: two volumes to the year, January to June and July to December.

Surgery, Gynecology and Obstetrics with International Abstract of Surgery, per volume **$7.50**

Surgery, Gynecology and Obstetrics *without* the Abstract, per volume **4.00**

International Abstract of Surgery, per volume . . . **4.00**

We Can Supply All Back Numbers in Bound Volumes Except Vol. II

Back Numbers Returned for Binding

Where copies are returned by subscribers in exchange for bound volumes, the charge per volume for binding will be as follows:

Surgery, Gynecology and Obstetrics with International Abstract of Surgery, per volume **$2.75**

Surgery, Gynecology and Obstetrics, per volume . . . **1.75**

International Abstract of Surgery, per volume . . . **1.75**

The prices quoted above include carriage charges on shipments to points in the United States and Canada. Express or freight charges on journals returned for binding must be prepaid.

Stanolind
Reg. U. S. Pat. Off.
Petrolatum

For Medicinal Use

In five grades to meet every requirement.

Superla White, Ivory White, Onyx, Topaz and Amber.

Stanolind Petrolatum is of such distinctive merit as to sustain the well-established reputation of the Standard Oil Company of Indiana as manufacturers of medicinal petroleum products.

You may subject Stanolind Petrolatum to the most rigid test and investigation—you will be convinced of its superior merit.

Stanolind Surgical Wax

For Injuries to the Skin

While it is more generally used in the treatment of burns, it also is employed successfully in the treatment of all injuries to the skin, where, from whatever cause, an area has been denuded—or where skin is tender and inflamed—varicose ulcers, granulating wounds of the skin, etc.

Surgeons will find it useful to seal wounds after operations instead of collodion dressings.

It maintains the uniform temperature necessary to promote rapid cell growth.

It accommodates itself readily to surface irregularities without breaking.

STANDARD OIL COMPANY
(Indiana)

Manufacturers of Medicinal Products from Petroleum

910 S. Michigan Avenue Chicago, U. S. A.

703

New York Post-Graduate

Medical School and Hospital

Courses arranged for the general practitioner in all branches of medicine. Separate courses on every subject and Special Practical Courses, where individual instruction is given in the following subjects:

Anaesthesia; Colon and Rectal Diseases; Complete Eye Seminar, embracing seven Special Courses; Ear Operations (Cadaver); Nose and Throat Operations on the Cadaver and in the Operating Rooms; Bronchoscopy; Nose and Throat Pathology; Abdominal Diagnosis; Physical Diagnosis; Diagnosis and Treatment of Constitutional Diseases of the Adult; Dietetic and Metabolic Problems; Infectious Diseases; Neurology; Stomach Diseases; Infant Feeding and Diagnosis; Intubation and Lumbar Puncture; Practical Pediatrics; Cystoscopy—Male and Female; Diagnosis and Office Treatment of Gynecological Cases; Gynecological Operations on the Cadaver; General Surgery on the Cadaver; Genito-Urinary Surgery on the Cadaver; Military Orthopedic and Bone and Joint Surgery; Treatment and Care of Fractures; X-Ray and Laboratory Work.

The Hospital has a bed capacity of over 400. The average number of patients admitted daily to the Dispensary is 800. The Hospital and teaching facilities are as extensive during the summer months as during the winter session. Cadaver courses omitted during June, July, August and September.

Through the courtesy of the Secretary, a two-day complimentary ticket is given, which enables the visiting physician to decide upon the courses best suited to his purpose and to meet the instructors in the various departments before registering for any work.

For Further Particulars Address

SECRETARY OF THE FACULTY

305 East Twentieth Street **NEW YORK CITY**

SURGERY, GYNECOLOGY AND OBSTETRICS

AN INTERNATIONAL MAGAZINE, PUBLISHED MONTHLY

VOLUME XXVIII MARCH, 1919 NUMBER 3

OBSERVATIONS ON THE PATHOLOGY OF FOREIGN BODIES IN THE AIR AND FOOD PASSAGES

BASED ON THE ANALYSIS OF 628 CASES[1]

BY CHEVALIER JACKSON, M.D., F.A.C.S., PHILADELPHIA

THIS paper will not deal systematically with all phases of the subject, because to do so would be to repeat much matter that has previously been written by the author and collected in textbook form (1). It would seem more profitable use of time and space to deal with new phases or new observations on the previously considered phases of the subject. To report many cases *in extenso* would unduly lengthen this paper; therefore, with a few important exceptions, comments on cases will be inserted here and there, as may seem apropos, and a table of cases will be appended.

Autoptical opportunities have been limited to a single case; therefore, most of the observations herein concern the living pathology, endoscopically observed.

The author regards himself as very fortunate in having had a sufficiently large experience to afford many opportunities to contrast the endoscopic appearances of recently aspirated foreign bodies with cases of prolonged sojourn of other foreign bodies of the same or similar physical character. Thus we are able to record and contrast the immediate and late later pathological changes produced by short and by prolonged presence of a foreign body in the air passages. Unfortunately, a similar opportunity has been afforded to only slight extent in regard to foreign bodies in the œsophagus; for, while recent œsophageally-lodged foreign bodies are very numerous, cases of prolonged sojourn are much less common in the gullet than in the air passages.

Results of bronchoscopy and œsophagoscopy. Though treatment is not within the scope of the present paper, it may be germane merely to mention the fact that with the development of roentgenography for diagnosis and of bronchoscopy and œsophagoscopy for removal, the future should see very few cases of prolonged sojourn of foreign bodies that have entered through natural passages. Statistics in the author's clinic remain about the same, namely 98.1 per cent of successes; the slight diminution being due to the fact that an increasing percentage of the easier cases is eliminated by the successes elsewhere, resulting in an increasing percentage of patients arriving with pathologic complications or with complicated mechanical problems. Our mortality has been less than one-half of 1 per cent directly attributable to the endoscopic procedure. Taking together all deaths from any cause whatever within one month after endoscopy, the mortality has been 1.9 per cent.

Ultimate results after removal of the foreign body in long-standing cases. From a pathologic viewpoint it is unfortunate that we have had no autoptical opportunities in any of the

[1] Muetter Lecture, 1917. Delivered before the College of Physicians, Philadelphia, December 14, 1917.

cases from which we have removed a foreign body of prolonged sojourn. Of the 23 cases in which the foreign body had been present for periods ranging from 2 months to 26 years, all of the cases recovered perfect health except two. One of the two died about a month after removal of a nail that had been in the lung for 4 years. Postmortem was unobtainable; but the symptoms pointed clearly to embolism of the middle meningeal artery. The child was known to have an endocardial lesion secondary to the septic pulmonary focus; but whether the embolus was from this or from the primary infective focus in the lung, obviously could not be determined (4). The other fatal case died of some thoracic or abdominal condition of sudden onset, the nature of which could not be determined. He had been playing about outdoors, apparently in good general health. No autopsy was obtainable (4).

The recovery of lung tissue from such extensive and prolonged suppurative processes as those present in some of the cases is very remarkable (see Roentgenograms, 17 and 18). The case of Mrs. K., from whose lung we removed a glass collar button that had been in the lung for 26 years, is one of the most interesting. She had emaciated from septic toxæmia until she weighed only 98 pounds. Two years after removal of the collar button she had regained perfect health and today weighs 182 pounds. The physical signs over the lungs show no abnormalities (5). All of the other cases made good recoveries, except the two cases noted above (21 recoveries, 2 deaths, out of 23 cases. No operative mortality).[1] In some of the cases it was necessary to dilate a cicatricial stricture to gain access to the foreign body for removal. It seems unlikely that from a single dilatation the lumen would remain dilated; but, of course, it must be remembered that the lumen of the stricture was occupied by the foreign body which was itself, by its bulk, a large factor in the obstruction; so that probably the better drainage was due as much, if not more, to the removal of the foreign body which occluded the strictured lumen. Granulations are also an impediment to drainage. While, doubtless, they do not disappear for some time, yet it is logical to suppose they would gradually recede after the removal of the cause of their presence. Their recession would constantly improve drainage. Repetition of the bronchoscopic dilatation of a bronchial stricture for the improvement of drainage is very easily carried out without anæsthesia; but, so far, our foreign-body cases have not seemed to require it.

[1] Seven recent cases are not included; because, though now recovering rapidly, time enough has not yet elapsed to class them as cured.

VARIOUS CLASSES OF FOREIGN BODIES

The list below includes the various classes of substances I have removed from the air and food passages. Needless to say it has been impossible to distinguish a different kind or degree of inflammatory reaction peculiar to each class. On the other hand, I have been able to distinguish a marked characteristic and unmistakable difference between certain classes.

The following is a classified, not an itemized list. In the absence of complete chemical analyses of the particular specimens, the exact composition of some of the alloys is somewhat uncertain. The combinations are those in common use in the arts and trades.

Metals

Iron, wrought.
Iron, cast.
Iron, malleable.
Steel, low.
Steel, low, galvanized.
Steel, low, nickel-plated.
Steel, low, copper-plated.
Steel, tool, tempered.
Steel, tool, untempered.
Brass (an alloy of copper and zinc, sometimes tin also).
Brass, high.
Brass, low.
Brass, cast.
Brass, lacquered.
Brass, nickel-plated.
Brass, gold-plated.
"Brass" plating.
Copper, pure (practically).
Copper, alloyed with tin (bronze).
Copper, alloyed with lead (pewter).
Copper plating on steel.
Gold, solid, pure (practically).
Gold, filled.
Gold plating.

Silver, pure (practically).
Silver, alloyed.
Silver plating.
Tin plating.
Tin, alloyed with lead.
Tin, alloyed with silver and mercury.
Tin, alloyed with copper (bronze).
Lead, pure (practically).
Lead, alloyed with copper.
Lead, alloyed with tin.
Lead, alloyed with antimony (?).
Lead, alloyed with bismuth (?).
(These alloys are the usual ones in pewter of which we have had many instances as foreign bodies).
Zinc (galvanized coating on iron and steel).
Zinc, alloyed with copper (brass).
Zinc, probably present in other alloys.
Nickel, alloyed with copper.
Nickel plating on iron, steel and brass.
Aluminum, pure (practically).
Mercury, as an amalgam with tin and silver.
Antimony, alloyed with lead.
Bismuth, alloyed with lead.

Minerals (other than metals)

Glass.	Anthracite coal.
Enameled ware.	Pebbles.
Porcelain.	Diamonds.

Animal substances

Bones, mammals.	Wool fiber.
Bones, mammals, processed.	Hair (bristles).
	Horn (buttons).
Bones, birds.	Pearl shell.
Bones, fish.	Shellac.
Meat, mammals.	Seed lac.
Meat, birds.	Entozoa.
Meat, fish.	Blood clots.
Teeth, human.	Cheesy débris.
Cartilage, human.	Ivory.

Vegetable substances

Nut kernels.	Celluloid, jewelry, poker chip.
Nut shells.	
Seeds.	Paper.
Hulls.	Vegetable "ivory."
Burrs.	Wood.
Grasses.	Rubber, soft.
Fruit pits.	Rubber, hard.
Fruit pulp.	Lacquer.
Cotton fiber.	

'CORROSION" AND OTHER CHANGES IN THE FOREIGN BODY ITSELF

From a viewpoint of biologic chemistry his question is of only academic interest. But, clinically, it bears importantly on the question of reaction of the tissues to the presence of the foreign body, not only by the changes in the physical qualities of the surface, rendering smooth surfaces rough and mechanically irritating when moved about by pulsatory, respiratory, and bechic forces; but, conceivably, in the chemicals given off in the dissolving or in the corrosive processes, the penetration and incubation of the bacteria, etc.

Wrought iron and steel foreign bodies appear in our case-records as having been present in the lung for periods varying from 2 hours to 11 years. In one case time was unknown, probably since boyhood of a man, aged 23 years. From examination of the specimens it seems certain that corrosion takes place rapidly at first and more and more slowly as the crust of corroded metal accumulates. The metal in three cases (400, 410 and 569) became a mere mass of corroded material resembling coke. It lost its tensile strength and crumbled when pulled upon by forceps. The tissues had built around it in both these cases a cicatricial encasement with a narrow strictured neck from which pus escaped, but through which there seemed no possibility of the corroded material being extruded either in crumbs or *en masse*. In a number of cases, notably Case 408 the bulk of the foreign body was greatly increased by the heavy corrosive crust, thus interfering with drainage. The polish disappeared from blued steel pins in 2 days in some instances and corrosion was always manifest when the pin had been in 4 days or longer. Galvanized coating on steel staples, nails, etc., disappears totally in 1½ years, as shown in Case Fbdy. 409. The staple in this case was corroded quite deeply, a thick crust covering all parts of the staple. This crust was black when the staple was removed; but when dried had rather a reddish, rusty appearance. This reddish appearance was not noticeable on any of the other corroded steel or iron foreign bodies. The rapid disappearance of the galvanized coating from galvanized steel foreign bodies may be favored by galvanic action.

Cast-iron bodies we have not had in sufficient number justly to compare the degree of corrosion. Case Fbdy. 550 was one of cast iron in the bronchus for 3 days. In this short time good tool steel, such as is used in shawl pins and dental instruments would have

corroded sufficiently to be quite manifestly blackened. On the contrary, the cast iron in the case referred to did not give off any black stain on a clean white linen cloth. Cast-iron jacks in the œsophagus 2 weeks in one case (P. E. 234), and 2 months in another (Fbdy. 558), seemed to have undergone almost no corrosion.

Brass objects were present in the lungs of our patients for periods varying from a few hours to 10 years. Examination of these specimens shows that it corrodes much more slowly than wrought iron or steel. In Case P. E. 266 the thin brass wires, if of steel, judging by comparison with Cases 569 and 410, would have crumbled away when removed. The lacquer put upon brass to protect it from atmospheric corrosion seems to disappear very quickly from lacquered brass foreign bodies in the air passages. Nickel-plating on brass seems to disappear quickly, though doubtless the removal is the result of the attack of the secretions on the brass underneath, the start being obtained at spots where the plating is deficient. The mottled irregular shape and depth of the patches of corrosion on many foreign bodies, notably of the atomizer tip in Case Fbdy. 611, seem to support this view. The atomizer tip had been in the lung 1½ years. The precisely similar foreign body in Case P. E. 230, was not corroded at all in 10 days. It is possible that galvanic action may favor the removal or undermining of the plating on nickel-plated brass objects.[1]

Copper corrodes very quickly and deeply, the corroded surface quickly becoming rough and black. So-called copper coins are in some instances made of bronze. We have not yet made a chemical determination as to which coins were bronze.

Gold seems to be very slow to tarnish. Gold-plated brass seems to lose its plating very quickly, and then to corrode as rapidly as unplated brass. Doubtless, the attack is on the underlying metal, beginning at defective places in the plating.[2]

Nickel in the form of coins seems to be relatively slow to corrode. Nickel-plating on brass is quickly removed as mentioned under "brass." Nickel plating on steel has been noted in only 3 instances and it seemed to be yielding to attack in the same way. In the œsophagus a thin yellowish, adherent coating appears on a "nickel" coin in a central zone similar in position and area to that shown on silver coins (Figure 20, Plate II). The nature of this yellowish coating has not been determined; but as the so-called "nickel" coin is about 25 per cent copper the coating may be cupric.

Silver is very quickly corroded. The prompt formation of a heavy coating of black sulphides is more quickly developed, apparently, in the œsophagus than in the air passages; but after silver objects have remained for a considerable time in the air passages they begin to develop a heavy coating quite rapidly. Possibly this delayed activity is due to the sulphides liberated by bacterial activity. In the œsophagus a heavy black coating appears promptly in a central zone, while the lateral zones which are clasped by the tissues remain very bright. (Case Fbdy. 628. See Figure 20, Plate II.) It remains to be determined whether the sulphide of silver or a nascent agent is bactericidal.

Lead more or less alloyed was not infrequently encountered. It seems to undergo very slight corrosion. In one instance (Case P. E. 243) but slight corrosion had occurred in a 10 years' sojourn in the bronchi. The corrosion was slight also in Case Fbdy. 440, in which the lead alloy collar button had been present for 9½ years. In both these cases the pus had been exceedingly foul for years. If this foulness was due to sulphides it seems strange that the lead was so slightly acted upon. The nature of the hardening alloy has not yet been determined.

Zinc was encountered as a galvanized coating on various iron and steel substances. In these the zinc disappeared very quickly possibly as the result of galvanic action or of the undermining of the coating by attack on the underlying metallic base. Zinc as an alloy was probably present in many of the metallic foreign bodies.

Tin was encountered as a coating on wire. It seemed not to have undergone any notice-

[1] A brass screw in the lung 4 months, removed after the delivery of the Muetter Lecture, was as bright as if newly made (Case Fbdy. 636).

[2] *Vide infra*, footnote relative to hard-rubber intubation tube.

able change in 6 weeks. The exposed parts of the steel wire were considerably corroded. The possibility of galvanic action is worthy of consideration. The amalgam fillings which doubtless contained a large proportion of tin, with silver and mercury, did not seem to be corroded but none was in the air passages more than 2 weeks.

Wood in the two instances encountered seemed to have undergone no change other than swelling in 10 days' and 3 days' time, respectively.

Rubber, hard and soft, seems to undergo little or no change. In Case Fbdy. 622 the rubber had been in the bronchus (or trachea) for a period of 7 months and seemed to be unchanged. The surface looked slightly more porous than a new eraser; but not so markedly that it could be said to have undergone any great degree of change. Vulcanite seems quite resistant; but the duration in our cases was not long.[1]

Pearl-shell did not lose its luster in the œsophagus in over 1 year; but it was incrusted with a calcareous-looking deposit in patches. It is possible that this incrustation was deposited during the lifetime of the mollusk from whose shell the foreign body had been roughly fashioned by a boy. Pearl buttons seemed to be unaffected but their sojourn was short.

Bones seem to change very slightly. If any disintegration goes on it is so little as to be unnoticeable. Of course, there is no means of knowing the exact weight or size of the foreign body before aspiration; but in Case Fbdy. 608, the bone had been *in situ* 10 years, and was as large as could have been aspirated through the glottis of a child of 10 years, which was the age of the patient at the time of aspiration. The color of the bone (beef) was dark purplish brown. In Case Fbdy. 385, the chicken bone was in the lower air passages for more than 1 year. It was cracked open, evidently before aspiration, and was slightly disintegrated superficially. Whether this disintegration was because of its being avian bone, its age, or because it was naturally cancellous with but a thin cortex, could not be determined. The differences of duration of sojourn prevented a just comparison as to disintegration between the bones of mammals, birds and fish, all of which are represented in our series of cases.

Meat (muscle, connective tissue, periosteum, etc.) was attached to bones in only two recent cases of bronchially-lodged bones. In these it was foul and soft. Doubtless, it was present in other cases, but had been quickly removed by the bacteria. It was, of course, cooked.

Horn and vegetable "ivory," of which buttons were made, were unaffected but none was in for a long period.

Glass, in our experience, was unaffected in surface except in three instances in which incrustations were deposited after long sojourn. In Case 244 P. E., in addition to the incrustations, the gloss usually present on glass collar buttons had apparently been dulled; but, of course, there was no way of knowing what sort of surface was present when the collar button was aspirated 26 years previously. The glass heads of pins seemed to be unaffected as to the surface. In two instances they were slightly incrusted.

Fiber or composition. which is a manufactured material resembling paper, but impregnated with shellac or other substance to render it impervious to moisture, was found in shoe buttons. One of these (Case Fbdy. 630) was present in the bronchus 7 months without apparent change except loss of polish. In another case (P. E. 351) the button was heavily coated with incrustations after 11 months' sojourn. Composition heads to "mourning" shawl pins were unchanged after a few days' sojourn.

Nut kernels are supposed to disintegrate in time, but we have found no evidence of it clinically. The longest duration was one month and even in this time a roasted peanut kernel seemed to be in about the same condition as one purchased for comparison. Some degree of swelling probably occurred.

Maize, beans, and other dried starchy vegetable substances seem to undergo no change other than swelling. This has an important pathologic bearing because of the pressure

[1] In a recent case an O'Dwyer intubation tube, composed of hard rubber vulcanized on a gold (alloy?) lining had remained in situ one year and four months. There was a diffuse tracheobronchitis with a bronchiectatic dilatation above the foreign body. The outside of the rubber was very much roughened with concretions. The gold seemed to be covered with a reddish brown crust.

exerted on the tissues, and, especially because of the increased interference with drainage.

Seeds, hulls, watermelon seeds, peach stones, cherry pits, etc., were found unchanged by sojourns of from 1 to 15 days.

Anthracite coal, chinaware, enameled ware, human teeth, wool and cotton fiber, seemed to have undergone no change; but the duration was in all of these cases relatively short.

REACTION OF THE TISSUES — INFLUENCE OF THE CHARACTER OF THE FOREIGN BODY ITSELF ON THE REACTION OF THE TISSUES TO ITS PRESENCE

The broadest classification is as follows:

1. *Shape and size.* A foreign body that does not obstruct drainage from, or aeration of, the conical mass of lung tributary to the invaded bronchus, in our observations, has produced less reaction than a foreign body of the same physical and chemical characters, but of such size and shape as to occlude the invaded bronchus in such a way as to obstruct drainage and aeration.

2. *Surface qualities.* A rough or sharp foreign body may traumatize the mucosa, but the reaction of such trauma seems to be limited to the immediate neighborhood of the trauma. If the intruder is knocked about by coughing, the trauma may be scattered in patches in different localities. So far as we are able to determine from bronchoscopic observations, once the foreign body becomes fixed these traumatized areas heal promptly provided drainage is unobstructed. In children, swelling of the subglottic tissues is apt to interfere with bechic expulsion, and then intense diffuse reaction is usual, regardless of the nature of the foreign body.

3. *Composition and character.* (a) The least reaction of the bronchial tissues to the presence of foreign bodies is caused by iron and steel, provided the intruder is of such shape and such size, relatively to the size of the particular bronchus invaded, as not to interfere with the drainage from, and aeration of, the subjacent lung area to which the invaded bronchus is tributary. Further experience may make an exception to the foregoing statement in case of pure gold and pure silver, of which our examples are fewer and of shorter duration than the iron, brass, and lead foreign bodies. Platinum, of which we have encountered no instance, may also be an exception. Cast iron seems rather more irritating than steel; but the number of cases is too small to be certain.

b. Next to iron and steel the class of substances least irritating, other things being equal, is metallic substances other than iron and steel.

c. Next in order comes the dense non-absorbent mineral substances, such as pebbles. Probably enameled ware and anthracite coal should be included here, possibly also chinaware, but as only one case of each has come to our clinic the data are not sufficient to warrant the statement. Glass seems least irritating of all, but as we have only one case of very long sojourn, I have not put it ahead of iron and steel. We have had 3 cases of short sojourn, and 17 other cases in which the foreign body was partly of glass, such as glass-headed shawl pins, imitation diamonds, etc.

d. Most organic substances set up more extensive and severe inflammatory reaction than mineral substances. The one marked exception to this is bone, which seems to create singularly little reaction, considering its combined septic and surface characters that favor trauma.

e. Maize, dried and uncooked, seems to set up a severe reaction, greater than any metal but not quite equal to that of peanut kernels.

f. The most irritating of all substances we have encountered in the air passages is roasted peanut kernels. Other nut kernels (raw) are also very irritating; whether less or more so has not been determined because of the remarkably less frequency of occurrence of kernels other than peanut as foreign bodies. The botanical and chemical differences between true nuts and peanuts are well known, but the bearing on the reaction of the tissues to their presence has not heretofore been studied.

Having thus broadly referred to the subject of the relative degrees of reaction observed bronchoscopically in the various classes of foreign bodies encountered, we will now

consider some of the classes a little further. Additional observations have, for the convenience of the reader, been placed in the description of the colored plates.

Iron and steel. Our case records are very rich in observations of iron and steel foreign bodies present in the bronchi for periods varying from a few hours to 9½ years. In one case (Fbdy. 400) the intruder had probably been in the lung since childhood of a man, 24 years of age. From these observations it is clear that iron and steel bodies set up quite slowly a very slight and strictly localized reaction, provided they do not, by their shape, obstruct drainage and aeration. It is only when, after prolonged sojourn, the bulk of the foreign body plus swelling of the tissues, plus granulations, plus stricture, results in obstruction that abscess, bronchiectasis and extensive tissue changes take place. Even then the changes are limited to the conical mass of lung to which the invaded bronchus is tributary. The bronchi of the other side are so invariably free from inflammatory changes that it is possible always to decide, in any case of prolonged sojourn, which lung to explore, from a comparison of the endoscopic appearances on the two sides.

Interesting comparisons of iron and steel foreign bodies are shown in Figures 1, 2, 3, 4, 6, 7, 8, 9, 21, 22, 23, 24, 28, 29, 30 and 31, Plate I.

Brass is one of the most frequently encountered metals in bronchoscopy for foreign bodies. I have been able to compare the results of sojourns of various periods ranging from a few hours to 10 years. The inflammatory processes even in the cases of longest standing are strictly localized, being limited to the invaded bronchus and the area of lung tributary thereto. It seems clearly demonstrated that a brass foreign body of such size and shape as not to obstruct drainage or aeration will cause only slight and strictly localized congestion followed by localized moderate inflammation. When, however, the inflammatory products have reached the stage in which the bulk of the foreign body, plus the swelling, plus the granulations, plus the thick secretions interfere with drainage, the saprophytes break down the pus into irritating materials, and the defective drainage and aeration otherwise result in a more rapid tissue destruction; but even then the extent of destruction, considering the duration, and judging by the recovery of functionally good lung, is most remarkably slight. Interesting comparisons are shown in Figures 14, 19 and 26, Plate I. Comparison of long and short sojourns of nickel-plated brass are shown in Figures 12 and 13, Plate I.

Lead. Our experience with lead as a foreign body has been relatively large and we are able to compare the reactions set up by sojourns varying from a few days to 10 years in the bronchi. (See Figures 17, 18, 19, and 20, Plate I.) In addition to Figure 17, there have been many cases of short sojourn, mostly pewter, jewelry, and toys. From this experience we are able to state that the reaction from lead is relatively slight, slow to develop, and always localized if the intruder is not of such shape as not to interfere seriously with drainage and aeration. Doubtless there is more or less alloy in all my lead foreign bodies.

Gold seems to be quite unirritating to the tissues, but no case of very prolonged sojourn was observed in which solid gold of relative purity was concerned. Plated objects lost their gold coating very promptly. "Filled" and heavily alloyed gold objects seemed to exhibit about the same phenomena as brass. It may be that pure gold would be found to set up less reaction than steel if we could observe a case of a relatively pure gold foreign body present for a prolonged period. In Case P. E. 354 (Figure 27, Plate II) a gold locket in the œsophagus had set up no inflammation or even congestion. In Case Fbdy. 426, Figures 21 and 28, Plate II, a gold "filled" cuff-link had ulcerated through from the œsophagus into the trachea in 3 months' sojourn in an infant 6 months old.[1]

Silver in a recent case seemed to have caused practically no inflammation. In cases of longer standing the irritation seemed very slight. Whether or not the sulphide of silver, or some substance in a nascent state is bactericidal, remains to be determined. The corrosion in 5 days in the œsophagus is shown in Figure 20, Plate II.

[1] *Vide supra*, footnote relative to hard-rubber intubation tube.

Aluminum we did not encounter as a foreign body in the bronchi; but a long experience with aluminum intubation tubes in the treatment of laryngeal stenosis leads me to believe that so long as it retains a smooth surface it is relatively unirritating; but it has a strong tendency to become pitted and to become coated with incrustations. In one case that left the hospital without permission and returned after 4 months, the surface of the tube was, in patches, like sandpaper in color and roughness, owing to the incrustations. After removal, the metal was found deeply pitted. The tissues, which had been epithelialized cicatricial structures, were denuded of their epithelium and were covered with granulations where the incrustations had been embedded.

Plated, galvanized, and tinned objects of all kinds seem to lose their plating or coating in a remarkably short time. Whether this is due to galvanic action or to the undermining caused by the attack on the basic metal, a start being obtained at a defectively coated spot, has not been determined. In Case Fbdy. 409, the heavily galvanized steel staple was so deeply corroded into the steel in a 1½ year's sojourn that the protective galvanizing must have been off in a few months after its aspiration. Nickel plating had entirely disappeared and the underlying brass was deeply corroded in the atomizer tip present 1½ years in Case Fbdy. 611. Gold plating seemed to have lasted but a short time on various pieces of jewelry in numerous cases.

Pebbles and glass, if smooth and free from sharp edges as in Cases Fbdy. 624, P. E. 359 and P. E. 361, seem to produce but little reaction unless they "cork" a bronchus. In neither of the "corked" cases was the intruder allowed to remain long enough for extensive destruction to take place. In Case P. E. 244, the glass collar button was present 26 years. It is quite clear from the history that the collar button caused very little irritation for many years. Gradually, however, the secondary purulent processes developed, ending in lung abscess and pyopneumothorax, reducing the patient to a septic wreck weighing 98 pounds. What her original weight was unknown but after the glass collar button was removed the patient gained in weight to 18[illegible] pounds. It seems probable that the collar button, which when found bronchoscopically was fixed in a position with the post cross wise, allowed free escape for all secretions during many of the earlier days of its sojourn Its surface then was smooth and unirritating Its hardness and impenetrability and in solubility gave no chance for corrosion or fo the growth of bacteria. The collar button o removal was found to be crusted with salts i places and the surface of the uncrusted por tions had less luster than a new button of th same kind. It seems probable that but littl irritation of the bronchi took place unt incrustation of the foreign body took plac and made it mechanically irritating, resultin thus in introduction of the bacteria beneat the epithelial barrier. Possibly prior to th time there may have been sufficient loc reaction to result in destruction of cilia and i enough swelling to interfere with escape o secretions past the intruder. Be this as may, the fact remains that this glass colla button was present in the lung of Mrs. K. fo a longer period (26 years) than is recorded i any other case in the history of medicin The patient though seemingly moribund o admission, is alive and well today almost 3 years after the original accident. An isolate case is insufficient even for broad conclusion but the case is in such marked contrast t many others herein referred to, in which oth kinds of foreign bodies were concerned, tha we feel warranted in the conclusion stated a the beginning of this paragraph. The sligh and strictly localized reaction of glass wa noticed in many instances of glass-heade shawl pins, and notably in the case of th "teddy-bear" eye. (Case Fbdy. 583. Se Figure 6, Plate II.) The œdema of the laryn in Case P. E. 341, present after 6 days, wa probably due to the incision of the mucosa b the thin sharp edges of a Bohemian Christma tree ornament. Wounding of the mucosa, o course, introduces the bacteria beneath th epithelial barrier; and, moreover, the sub glottic tissues of an infant are exceedingly prone to develop œdema on the slightest pro vocation.

Roentgenogram 1. Case No. Fbdy. 394. Shawl pin in left bronchus of an infant aged 18 months.

Roentgenogram 3. Case No. Fbdy. 619. Safety pin very low in left lung of a girl aged 15 years.

Diamonds were encountered only in minute settings in jewelry so that no distinction could be drawn between any possible reaction caused by them and by the metal in which they were set.

Anthracite coal was embedded in a ring of annular œdema but, as it had been drawn in by negative pressure due to subjacent air absorption, the œdema was probably from the pressure on the mucosa of the bronchial wall.

Bone. It is a very remarkable thing that so septic a thing as a piece of cancellous bone can remain in the lung for a period of 11 years and not produce a fatal degree of sepsis. For instance, in Case 608 (Figure 14, Plate II), a piece of cancellous bone, inhaled while eating soup, had in 11 years set up a septic bronchitis, perichondritis, stricture and bron-

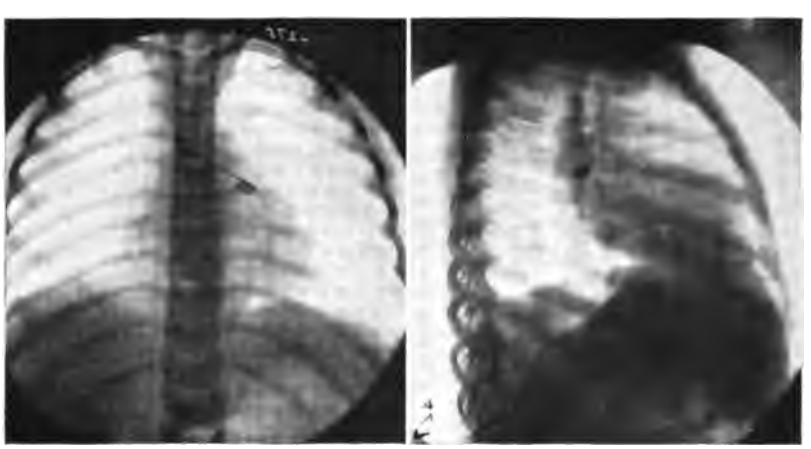

Roentgenogram 2. Case No. Fbdy. 617. Portion of safety pin in left bronchus of a girl aged 3 years.

Roentgenogram 4. Case No. Fbdy. 382. Upholstery tack in middle lobe right bronchus of boy aged 18 years. Sojourn about 7 months. Note pathologic shadows over middle lobe area.

Roentgenogram 5. Case No. Fbdy. 611. Atomizer in right bronchus 1½ years. Patient aged 58 years.

chiectasis. Yet this boy inhaling the bone at 9 years of age grew and developed, though

Roentgenogram 6. Case No. Fbdy. 410. Nail in right lung of boy aged 11 years. Probable sojourn 9½ years. Note shadows in right lower lobe posteriorly.

constantly an invalid, for 11 years. For months before I removed the bone the b had been in bed outdoors for supposed tub culosis. One of the most remarkable thir about the case is that under the antituber lous régime the boy increased 15 pounds weight. This is in marked contrast to t rapidly fatal bronchopneumonia set up nut kernels, corn (maize) and the like, in t bronchi of children.

Meat in all cases was cooked. Hence probably contained chiefly or exclusively bacteria harbored by the patient, and which the patient was probably more or immune. Meat, even when putrid, as it in most of the œsophageally-lodged ca seemed to have set up practically no reacti The most that could be noticed was onl slight congestion and this only in a few ca In no case was there local inflammation, was there general reaction to indicate p maine absorption. In one case a spicule bone in the meat had caused a wound, arou which was a small inflammatory areola. T duration of sojourn was not longer than a f days in the purely meat cases; but the bo

Roentgenogram 7. Case No. Fbdy. 444. Triangular shadow shows area of "drowned lung" due to "corking" of a bronchus by a peanut shell in a girl aged 8 years.

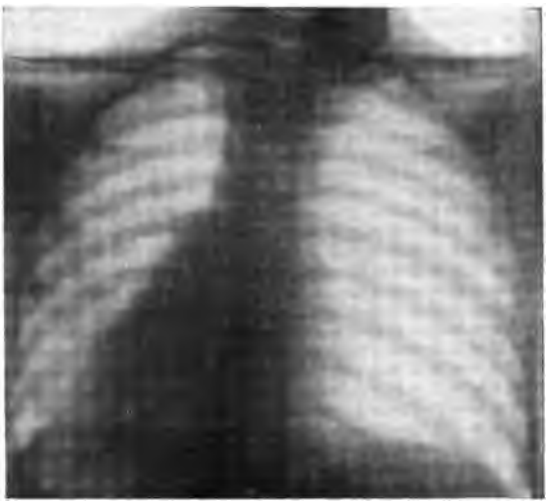

Roentgenogram 8. Taken two days after removal of peanut shell in case No. Fbdy. 444 shows complete evacuation of the "drowned lung."

with periosteum, etc., attached, were present in a few instances for a number of weeks in the œsophagus. In the air passages the maximum sojourn of bones was 11 years (Case Fbdy. 608). Whether or not, softer tissues were originally attached could not be determined in any of the long duration cases; but in cases of less duration, putrid soft tissues did not seem to have given rise to any special degree or extent of reaction, certainly no more than bone alone excited in other cases. In no case were there symptoms similar to ptomaine poisoning following gastro-intestinal ingestion. This is rather remarkable in view of the violence of such symptoms in some instances. Possibly the relatively small quantity might have been a factor.

Roentgenogram 9. Case No. Fbdy. 409. Large fence ıple in left bronchus of a man aged 43 years. Present ears.

Roentgenogram 10. Case No. Fbdy 552. Dental root-canal reamer in left upper lobe bronchus of a man aged 30. Sojourn about 3 months. Pathologic shadows absent.

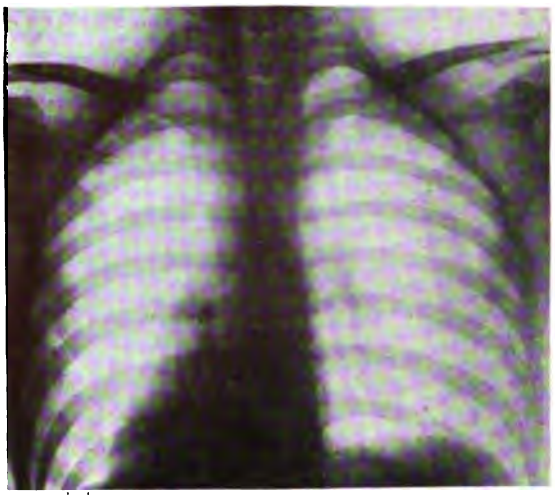

Roentgenogram 11. Case No. Fbdy. 574. Amalgam tooth-filling in left bronchus of a woman aged 26 years.

Wood in two cases seemed to have set up a high degree of inflammation. In one of the cases, however, a small fragment of soft rubber was attached and might have been a factor.

Rubber. The tissues of the air passages seem quite tolerant of vulcanite, or hard-rubber. To soft rubber, however, the reaction seems quite violent. This was shown in two recent cases and most remarkably in the following case:

CASE Fbdy. 622. Man, aged 36 years. History of convulsive seizures. One year ago began having



Roentgenogram 13. Case No. Fbdy. 553. Brass foot of an alarm clock in left main bronchus of child aged 21 months.

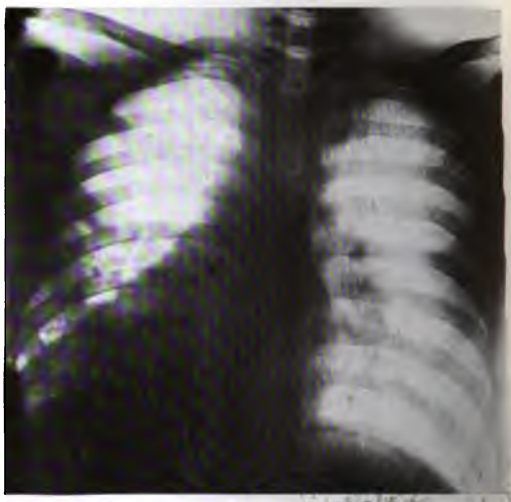

Roentgenogram 12. Case No. Fbdy. 440. Lead alloy collar button in left lung of a boy aged 14 years. Probable sojourn about 10 years. Note extensive pathologic change in left lower lobe. Compensatory emphysema of right chest.

short, generalized convulsive seizures which occurred always at 5 a.m. and during which he would bite the tongue. Attacks first occurred every 5 or 6 weeks; later they became more frequent until they occurred on successive mornings. A diagnosis of epilepsy was made. He was examined by various physicians, one of whom gave 6 intravenous injections of a "German medicine which cost ten dollars for each treatment." (Salvarsan?) He also received mercury tablets. Under this treatment the attacks diminished in severity and duration and became less frequent. The last attack occurred 5 weeks ago.

Present illness. Seven months before admission the patient had a convulsive attack during which a stenographer's eraser was inserted between his teeth to prevent injury to the tongue. The patient bit off a portion of the eraser, the piece being immediately aspirated. This was followed by much choking and coughing with failure to dislodge the foreign body. He was told by a physician that he had swallowed the piece of eraser.

The patient continued to cough and wheeze and was told by a second physician that he had asthma. A third consultant had roentgenographic plates made and stated that the portion of eraser had lodged in the right bronchus. Three weeks later an unsuccessful attempt to remove it by bronchoscopy was made by a physician in the patient's native city. Another series of plates made failed to show the foreign body. The patient was then told he had asthma.

The patient has wheezed and coughed ever since. He lost 19 pounds in the last two months. Once he spat a small amount of blood and was told he

Roentgenogram 14. Case No. Fbdy. 583. Glass eye of "Teddy bear" in right lung of child aged 2 years.

Roentgenogram 15. Case No. Fbdy. 572. Cap off brass bedstead in the right bronchus of boy aged 9 years. Probable sojourn about 2 years. Note dense pathologic shadow in right chest and compensatory emphysema in left.

tuberculous. Repeated sputum examinations were negative for tubercle bacilli. A third series of roentgenographic plates made by another roentgenographer, Dr. Farley, showed the presence of a foreign body and the patient started for Philadelphia.

On the train he became very dyspnœic and cyanotic, feverish and very feeble. He arrived in Philadelphia in very poor condition. He was brought to the hospital in an ambulance. Temperature on admission, 103.3°, pulse 140, and respirations 52, maximum. H. A. Hare and E. Quin Thornton both saw the patient and diagnosticated bilaterial pneumonia with gangrene and multiple abscess formation. The patient was apparently dying. Under stimulation as advised by H. A. Hare, the patient recovered consciousness, took some nourishment, and went through the last religious ceremony.

His pulse became very weak. He failed to respond to stimulation. Respirations became very shallow and labored, and ceased.

Autopsy. (Submitted by E. D. Funk.) The body is that of a well developed, adult, white male. Rigor mortis is present but easily broken up. Postmortem suggillation posteriorly and over upper anterior chest wall. Pupils are equal and normal in size; conjunctivæ, slight yellowish tinge.

Abdomen quite prominent, particularly in upper left quadrant. No external evidence of any injury. Peritoneum is smooth and glistening. Cavity contains only a few cubic centimeters of clear yellowish fluid. Great omentum is well supplied with fat and covers the intestines in lower abdomen. Appendix measures approximately 7 centimeters in length and is free except at the tip which is bound down by adhesions. Liver extends 3.5 centimeters beyond costal margin in midclavicular line and 6.4 centimeters beyond ensiform cartilage. Diaphragm is at upper border of fifth rib on left. Stomach greatly dilated, the pylorus sagging to level of umbilicus.

Left pleural cavity contains a normal quantity of slightly turbid fluid. Serosa over lower lobe is covered by a thin granular, grayish film of exudate.

Roentgenogram 16. Taken immediately after removal of brass cap in Case No. Fbdy. 572. More air seems to be entering all parts of left chest.

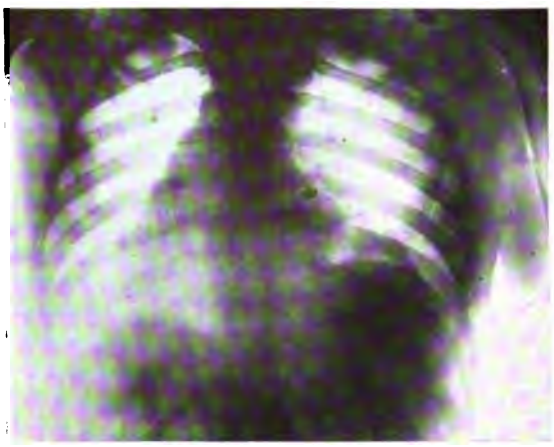

Roentgenogram 17. Case 266 P. E. Woman aged 23 years. Brass paper fastener in right lung.

Left lung weight 770 grams. Pleural surface is uniformly smooth except at base which is hyperæmic and covered by an exudate. On section the entire lung is œdematous and congested, especially at base. Margins of upper lobe are light in color and emphysematous. In lower lobe the bronchi are inflamed and many contain rather thick, dark, frothy material. Along the course of these bronchi and bronchioles the lung tissue is darker and softer than elsewhere. This tissue contains discrete grayish hard areas about the size of a pin-head; they are definitely circumscribed and surrounded by a faint reddish zone.

Right pleural cavity contains an excess of turbid flocculent fluid. The lining — both visceral and

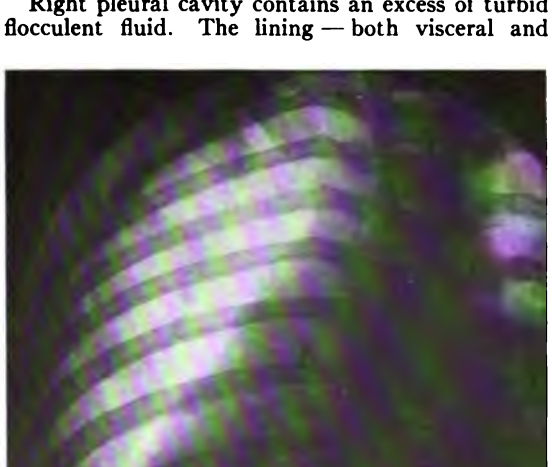

Roentgenogram 19. Case No. Fbdy. 630. Shoe button in left bronchus of girl aged 12 years. Probable sojourn 6 months.

Roentgenogram 18. Same case as in Roentgenogram 7 years after peroral bronchoscopic removal of brass pap fastener that had been in the lung 7 years. There are more pathologic shadows than are usual in the avera individual of the same age.

parietal — is covered by a thin grayish exuda below the level of the third rib.

Right lung weighs 1570 grams and is somewh voluminous. The trachea, 6 centimeters above t bifurcation, measures 3 centimeters in diamet just above the bifurcation the left bronchus me sures 2 centimeters. The right bronchus is 3 cen meters in diameter. The mucosa of the trachea swollen and almost black in color. Pressure upon t lung causes a foul smelling material to exude fr the trachea. Section of the lung reveals ma abscesses of various sizes and shapes, most num ous in the middle and lower lobes and situated groups along the course of bronchi and bronchiol Here many have coalesced and contain soft necro centers. The bronchial mucosa is swollen and t bronchi are filled with mucopurulent exudate. the lower lobe where the lung is black, very soft a friable, a distinctly gangrenous area may be se Bronchial lymph-nodes are abundant, enlarged a œdematous.

The pericardium is smooth and glistening. T cavity contains a small amount of clear, deep yell serum.

The heart weighs 327 grams and measures by 11 centimeters. The wall of the left ventri measures 2.6 centimeters in thickness. The my cardium is dark red, firm and congested. The ri side of the heart is dilated and the cavities are fil with dark red clots. The valves and orifices of t left side apparently are efficient. On the anter leaflet of the mitral valve are two yellowish rais

Roentgenogram 20. Case No. Fbdy. 608. Bone in right bronchus of boy aged 20 years. Probable sojourn 11 years. Note pathology in right lower lobe.

areas. Two aberrant chorda tendineæ span the cavity of the left ventricle. The foramen ovale is close.

The spleen weighs 175 grams and measures 14 by 9 by 3 centimeters. The organ is slightly enlarged, the capsule is smooth and free from adhesion. On section the pulp is firm and presents no gross lesion.

Adrenals, no macroscopic change.

The right kidney weighs 230 grams and measures 13.5 by 6 by 4.5 centimeters. The kidney bed is well supplied with fat. The capsule is smooth, thin, and easily stripped. An incision shows no change in the cortex except swelling and congestion. The ureter is single and patulous.

The left kidney weighs 220 grams and measures 12.5 by 6 by 4.5 centimeters. It presents same general appearance as its fellow. Ureter single and patulous.

Bladder, no gross change.

External genitalia apparently normal.

The liver weighs 1770 grams and measures 29 by 19 centimeters. The capsule is smooth and tense, the edges rounded. On section the liver is firm and dark red with yellowish mottling. The veins are full of blood. The gall-bladder extends 3 centimeters below the margin of the liver and contains a small amount of yellowish bile. The biliary passages are patulous.

The stomach is greatly dilated and partly filled with thin granular grayish material and air. The mucosa is flattened and smooth.

The pancreas weighs 100 grams and measures 18 by 4 centimeters. No lesion is discernible.

The aorta shows several raised grayish patches, most numerous at the arch.

The intestines show nothing noteworthy.

Roentgenogram 21. Case No. Fbdy. 578. Pearl shell ring in œsophagus of a boy aged 3½ years. Probable sojourn 1 year.

Gross diagnosis. Multiple abscesses of lungs, septic pneumonia with beginning gangrene, œdema and congestion of lungs, acute fibrinous pleuritis, dilatation of right heart and stomach, cloudy swelling of kidney and liver, congestion of myocardium, acute suppurative bronchitis and peribronchitis.

Bacteriologic diagnosis. Inoculations from the trachea yielded pneumococci, staphylococci, bacillus of Friedlander, streptococci, and a gram-negative motile organism which could not definitely be identified.

Microscopic diagnosis. Left lung, acute suppurative bronchitis and peribronchitis; acute suppurative pneumonia; septic pneumonia. Right lung, acute suppurative bronchitis, septic pneumonia; œdema. Heart, granular degeneration. Spleen, congestion. Liver, congestion; granular degeneration. Peribronchial lymph-nodes, acute non-suppurative lymphadentis. Kidney, slight congestion; cloudy swelling. Pancreas, normal. Adrenals, normal.

Coffee berry. We have had two instances of coffee berry, one roasted, the other not. Both were in children. The unroasted berry had set up a violent diffuse tracheobronchitis with a copious accumulation of pus. The roasted berry had caused a diffuse reaction; but of less severity.

Peanut kernels. Of all substances that we have encountered in our bronchoscopic ex-



Roentgenogram 22. Case No. Fbdy. 500. Lead weight in the œsophagus of a child aged 15 months.

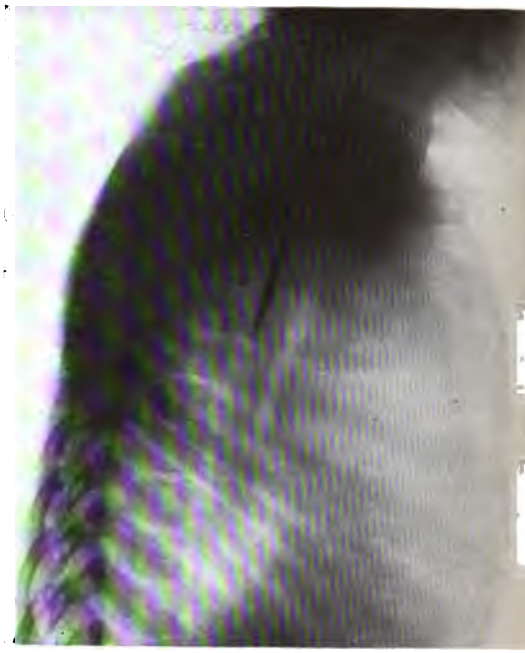

Roentgenogram 23. Case No. Fbdy. 550. Englis half-penny (copper alloy?) in œsophagus of girl aged 4 years. Probable sojourn 8 months. Lateral roentgeno gram showing coin edgewise.

perience, peanut kernels set up the most prompt and violent reaction. All of our peanut cases were in children. The younger the child, the more severe the reaction. In a number of cases, a peanut kernel in a few hours produced a diffuse general tracheobronchitis. Three cases in which we were not permitted to do a bronchoscopy died within 2 weeks. In Case 604, a child, aged 2½ years, showed violent tracheobronchitis with patches of exudate from a 6 weeks' sojourn of pieces of peanut kernel in the bronchi. Had the child been younger it is doubtful, from a clinician's point of view, if the child would have lived this long. Many similar cases are now in our case records, and while the degree of inflammatory reaction varies with the age of the child and with other and unknown factors, the evidence is sufficient to warrant the statement made at the beginning of this paragraph. In some of the cases the pus was so copious as to be coughed out, on insertion of the bronchoscope, onto the bronchoscopist's gown, dripping thence to the floor.

Observations on the reaction of peanut kernels have been solely in the trachea and bronchi, because no case of lodgment in the œsophagus has come under our observation.

The only other nut kernel encountered as foreign body was a walnut kernel. This pa tient (Case Fbdy. 425), an infant of 1 months, developed a most violent trache bronchitis in three days' sojourn of the ker nel. This similarity is the more remarkabl since the so-called peanut is not truly a nu botanically speaking, whatever it may b chemically. Moreover, the walnut kernel wa raw, whereas the peanut kernels were all, s far as known, cooked.

Hypothetical questions. Many hypothese come to mind in comparing the reaction o different kinds of foreign bodies on th mucosal surfaces of the air and food passages To attempt the solution of these problems b theoretic consideration would be to resort t the old theoretic "pathology" which kep medicine and surgery groping in the dark fo ages. Most of these hypotheses are promising subjects for laboratory investigations an plans to this end are now under way. Thes will be reported upon later. The purpose o the present paper is to record the visual ob

servations of living pathology. Recognizing the dangers of theoretic pathology, we are, however, justified in considering certain established facts in regard to the reaction of tissues to the presence of various substances. These will be alluded to briefly in connection with the various classes of substances.

When one notes the readiness with which certain substances are encysted in bacteria-free tissues, there is an unavoidable suspicion that bacteria are largely concerned in the wide variation in the degree to which different foreign bodies in the lower air passages cause reaction. This naturally brings up the questions:

What is the relative suitability of foreign bodies of various kinds to serve as carriers of bacteria? To what extent is such suitability a factor as compared to the after-service of the characters of the foreign body as a matrix, an occluder of drainage and aeration, a helper of bacterial growth, as a medium or otherwise?

Other general questions are: To what extent do certain foreign bodies facilitate penetration of bacteria through the epithelial barrier by means other than purely mechanical puncture and the atria resulting from the inflammatory outward migration of leucocytes? Can certain kinds of foreign bodies impair ciliary activity by means other than the excitation of inflammation?

Undoubtedly one of the factors in the pathologic processes is the impairment of ciliary activity. On how soon after the invasion the impairment takes place, in other words, whether the primary inflammatory processes stop or seriously lessen this activity, or whether it is in the later destructive inflammatory processes that the cilia are destroyed, bronchoscopy has as yet not thrown any light. Plans for working out this problem have been made.

The relative activity of the cilia in adults and children seems never to have been determined.

It may here be mentioned that previously reported bronchoscopic observations by the author[1] have established the fact that the flow of the stream of secretions under normal conditions is greatest up the posterior wall of the trachea and out the posterior commissure of the larynx between the right and left arytenoid eminences (Fig. 10, Plate I.)[2]

Previously referred-to bronchoscopic observations and cultural tests by the author have also established the fact that the mucosal surfaces of the bronchi are not absolutely and at all times sterile; but they are occasionally so, and the deeper (more peripheral) the location, the fewer the organisms. Doubtless, this is because under normal conditions, the organisms are swept out by the flow of sterile secretions poured out by the mucosal glands and propelled by ciliary, bechic, and forced expiratory action, voluntary and involuntary.

Hypothetical questions suggested by Dr. W. M. L. Coplin, upon which we hope later to have laboratory data, are:

1. Do metallic foreign bodies give off, in the process of corrosion, bactericidal products?

2. Are the vastly greater irritating properties of such substances as peanut kernels due to:

a. Irritating chemical substances present in the peanut, either naturally as the abrin in jequirity or ricin in the castor bean, or developed in the roasting process? Ricin is non-toxic when taken into the gastro-intestinal tract. (Jacob Rosenbloom suggested to me the testing of the possibly irritating properties of arachidic acid as an irritant. This saturated fatty acid is present in about 5 per cent strength in peanut oil.)

b. The contact of an alien protein with tissue not naturally accustomed to such substances, the alien protein not having previously gone through the mill of enteric and hepatic preparatory processes?

c. The protective matrix afforded by a porous organic vegetable protein for the growth of bacteria in a warm moist incubating chamber, such as the living bronchi, the bacterial growth giving off irritating toxins or acquiring virulence to enable the organisms to attack the living tissues?

[1] Personal Endoscopy and Laryngeal Surgery. Textbook, 1914. Also J. of diag., April, 1908.

[2] At the suggestion of Dr. W. M. L. Coplin, the author has since made further observations by which it was discovered that the tendency of the endotracheal blood streak selected the posterior wall when the patient was standing or sitting erect, just the same as in a recumbent patient. In other words posture had no influence in the predilection of the endotracheal blood streak for the posterior wall.

3. Is the reaction to the presence of the peanut simply an unusually violent effort of nature to split up and get rid of a very complex alien protein by an unnatural route?

4. Is the relative mildness of the reaction from so septic a substance as a cancellous bone, as compared to a peanut kernel, explainable upon the basis of the well-known toxic properties of alien proteins?

Cough as an aid to ciliary activity is important. Bechic inefficiency in infants and young children as compared to adults, in whom voluntary expectorative aid is a large factor, has been demonstrated by the author (3). Possibly this is one of the factors leading to the greater vulnerability of children to the reaction of foreign bodies.

LOCATION OF LODGMENT OF FOREIGN BODIES IN THE BRONCHI

A distinction must be made between the location of primary lodgment and of ultimate lodgment. The latter term must be used with reservations, since, if the patient lives, nearly all bronchially-lodged foreign bodies migrate continually downward and outward toward the periphery of the lung, at first as far as the size and shape of the intruder, relatively to the size and shape of the bronchi, will permit. Later, pathological processes fix the foreign body. Still later the intruder may ulcerate loose and migrate farther toward the periphery, but this is relatively very rare. Usually the intruder remains fixed in inflammatory tissue, while the subjacent purulent processes migrate toward the pleural cavity into which they often enter, causing a pyopneumothorax. In only one of our cases that came in with this condition had the foreign body followed the pus into the pleura. In none of them had the intruder worked its way through an area of adhesive pleuritis to the skin surface but such cases have been recorded in the prebronchoscopic days.

Foreign bodies often lodge in the larynx. These instances were chiefly in the case of large, long, or sharply pointed substances, lodgment taking place because of a point sticking into the walls or into the ventricles. In a few instances lodgment was due merely to size. In more than half the cases that came in with foreign bodies in the bronchi there was good reason to believe that the intruder had first lodged higher and had been dislodged by natural reflexes or by efforts at removal, especially ill-advised efforts in the upright posture.

Nothing new, statistically or otherwise, has developed to lead me to alter the statement previously made (1) as to the greater frequency of right-sided lodgment and reasons therefor, the rarity of middle-lobe lodgment, the influence of size, shape, specific gravity and other characters on lodgment, nor as to the rarity of spontaneous expulsion. Further observation corroborates the fact then noted that lodgment is almost always at or below the orifice of a branch bronchus; because, probably, of the fact that the bronchi do not diminish in diameter taperingly between branches. The branching is of monopodic type and the interramal parts of the bronchi are relatively cylindrical. The most frequent site of lodgment, as shown in earlier observations, is at, or immediately below, the giving off of the right upper-lobe bronchus, usually far enough below to permit air to enter the upper-lobe bronchus over the top of the foreign body. The next most frequent site is the corresponding anatomical location on the left side. Next in order of frequency are the stem bronchi, first the right then the left. The dorsal branches of either side are much more frequently invaded than the ventral branches, the most frequent of all being the large posterior branch of the left inferior-lobe bronchus that is given off immediately below the left upper-lobe bronchus. The data bearing on this subject have already been published (1).

Participation of the other lung in the bronchitis of foreign-body origin does not usually occur in recent cases except when the intruder is of the extremely irritating class, such as peanut kernels and maize. In these, diffuse bronchitis of both lungs is the rule, so much so that the bronchoscopist is deprived of one of his best guides for finding the location of the foreign body: namely, the evidences of pathology at or near the orifice of the particular bronchus invaded. The evidences of inflammation are not localized in such cases

as they are in metallic bodies for instance. In case of metallic and other mineral bodies present for a long time, there is usually a mild degree of chronic bronchitis in the other lung due, doubtless, to the secretions getting over from the invaded lung during sleep and at other times when the cough reflex and the ciliary activities are lessened. The same is true of bones and of all inorganic substances. But in all of the cases of substances other than the irritating class (nut kernels, maize, etc.), the evidences of pathology are relatively so slight that there is no trouble in going directly to the invaded bronchus by following the signs of pathology, provided the intruder has been *in situ* sufficiently long to produce marked pathologic changes.

Tissues involved in the reaction to the presence of a foreign body. It is logical to suppose that, primarily, the lodgment of a foreign body in a bronchus produces a reaction limited to the mucosa. Many foreign bodies, owing to impact on aspiration of the foreign body, or on its being knocked about, or by the friction caused by respiratory, pulsatory and bechic movements, perforate the mucosa, introducing the bacteria and attendant inflammatory processes into the perichondrium, the cartilage, the interannular tissues, the vessels and all the tissues composing the parenchyma of the lung.

CAUSES OF REACTION OF BRONCHIAL TISSUES TO THE PRESENCE OF FOREIGN BODIES

It is probably justifiable to assume that the causes of the reactions of the mucosal and adjacent tissues to the presence of a foreign body may be classified as mechanical, chemical, biomechanical and biochemical.

Mechanical causes of reaction of the tissues the presence of foreign bodies. These are easily understood and admit of little dispute. Direct trauma of a foreign body by the impact of its striking when it is aspirated with projectile-like force, assisted or not by gravity, is easily understood. So also is the puncture of the epithelium either on the impact or later as a result of the chafing due to the to-and-fro excursion of the contactual bronchial wall in the respiratory, bechic, and pulsatory movements which are continuous. As previously pointed out by the author, long objects pointed at one end only, such as pins, tacks and the like, have a ratchet-like movement by which they work downward to the lowest possible location, due to the prevention of upward return by the sticking of the point into the lateral wall. The axis of the foreign body not coinciding with the bronchial axis because of the relatively large diameter of the latter, the point, which is almost invariably upward, sags over into contact with the bronchial wall, into which it penetrates during the subsequent longitudinal shortening of the bronchus during expiration, cough, or transmitted cardiac or vascular impulse.

Under mechanical processes may also be included the occlusion or "corking" of a bronchus by which drainage and aeration of the subjacent tributary lung is interfered with. This obstruction may be contributed to by swelling of the tissues, swelling or corrosive increase in the bulk of the foreign body.

Biomechanical processes may include: (a) the irritating roughness induced in a foreign body by corrosion and by the incrustation of a foreign body secondary to tissue reaction; (b) the swelling of the foreign body due to the absorption of the ever-present secretions, normal or pathologic, resulting in great lateral pressure; (c) the increase in bulk of the intruder by corrosive processes; (d) the swelling of the bronchial wall, obliterating the airways that on first invasion existed at certain points between the foreign body and the bronchial wall, due to irregularities in the shape of the foreign body.

Chemical processes include those in which the intruder contains material which is directly irritating to the tissues.

Biochemical processes. In this classification might be included the reactions on the tissues produced by irritative agents developed by bacterial or tissue-cell activities.

Age in relation to reaction of tissues to foreign bodies. Our observations show beyond doubt that the larynx, trachea, and bronchi of infants react much more severely and generally to foreign bodies than those of adults. This is especially true of the subglottic region in children aged less than 19 months. Their

subglottic tissues will swell until in the most severe cases they meet in the middle line and will asphyxiate the little patients unless a tracheotomy be done to supply air until the subglottic œdema subsides. Peanut kernels seem peculiarly liable to set up this subglottic swelling. Subglottic œdema in infants, is however, not peculiar to foreign-body cases. We have often seen it in acute laryngo-tracheitis commonly called "the grippe" or broncho-pneumonia. In quite a proportion of the cases of laryngeal and tracheal diphtheria in infants, in our observation, it is often this subglottic œdema rather than the bulk of the membrane that necessitates tracheotomy or intubation. Logan Turner has shown the peculiar histology of the subglottic region in children; and, doubtless, structure is the chief factor in the tendency to subglottic œdema in infants. Our youngest patient was 11 days old.

Contact reaction. The mere contact (without impact) of a foreign body in the trachea or bronchi seems to cause very little reaction. In Case Fbdy. 557, the needle in contact with the mucosa, after it had been in the lower air passages for 2 hours, had caused only a slight congestion. This seemed to be the case in most instances of metallic bodies of short sojourn though none was quite so short as that of the needle. In a number of peanut cases of very short sojourn a diffuse general reaction was set up. The mechanical irritation of contact of a peanut would theoretically seem much less than that of a metallic body. The reaction from contact of the bronchoscope in a careful, gentle bronchoscopy seems very slight, and successive introduction of the instrument shows that the slight congestion caused very quickly disappears, provided no abrasion of the epithelium has occurred. The reaction from improper, rough, violent use of the bronchoscope as shown in Figure 3, Plate I, is followed by more or less severe traumatic bronchitis.

The slight reaction from mere contact observed endoscopically corresponds to clinical findings. When each one of us recalls the violent choking and strangling excited in ourselves by a mere crumb of bread that has "gone the wrong way" we really refer onl to laryngeal sensations. Strange as it ma seem, the deeper passages are quite toleran for foreign bodies. In most instances aft the coughing and choking excited by th presence of the foreign body while passin through the larynx, practically all coug ceases. It is this deceptive and little-know period of quiescence that deludes patient an practitioner into believing the foreign bod could not have entered the lung. In Cas Fbdy. 409 (Figure 8, Plate II), the famil physician when called immediately after th accident said: "Impossible. You woul have been dead in 5 minutes and would hav been coughing your head off the whole time.

CASES OF PROLONGED SOJOURN OF FOREIG BODIES IN THE AIR PASSAGES

Of the 23 cases in which the foreign bod had been in the lung for periods ranging fro 3 months to 18 years, the clinical signs of pu monary sepsis supervened and the patient developed the clinical picture of pulmonar tuberculosis; yet in not one of the 23 we tubercle bacilli found, though repeated e aminations were made. Moreover the rel tively prompt and complete recovery of th patient in 16 out of the 23 cases clinicall substantiated the bacteriological finding It seems, therefore, that the statement tha appears in many textbooks that cases foreign body in the lung are prone to die pulmonary tuberculosis is a relic of the da when the diagnosis of tuberculosis was mad upon clinical, and not upon the bacteri logical, or even pathological data.

The predominant characteristics of th pathologic processes of the 23 cases of pr longed sojourn of a foreign body in the bronc were:

1. Foul and dark-colored or greenish p indicating the presence of saprophytes a chromogenic bacteria.

2. Presence of an abundant bacteri flora, without distinctly predominant va eties of organisms.

3. Absence of bacillus tuberculosis.

4. Presence of a stricture of the bronch the foreign body occupying the lumen of t stricture in 16 out of the 23 cases.

5. The presence of a cavity varying from a slight dilatation of a bronchus to an abscess cavity, though in most instances the "cavity" was filled with granulation tissue and usually its walls were collapsed. In some instances the cavity gaped on inspiration after removal of the foreign body and bronchoscopic aspiration of the pus; in one instance the "cavity" was inflated with the caisson bronchoscope (Figure 9, Plate II).

6. The location of the foreign body at the upper part of the pathologic mass. In all save two of the 23 cases of prolonged sojourn of a foreign body in a bronchus, the foreign body was located at the upper part of the diseased tissue which has resulted from its presence. In the cases in which cavities of abscessal or bronchiectatic character had resulted, the foreign body was, in all cases but two, located in a stricture at the top (or proximal end) of the cavity.

Pus and secretions in foreign-body cases. Systematic laboratory work has, unfortunately, not been carried out in all cases. The cases that were investigated, however, revealed the same organisms and the same tendency to mixed infections that are found in other inflammatory states of the bronchial mucosa. Pure cultures of one organism were not found in any instance. The specimens, so far as studied, showed, in the cases of prolonged sojourn, the same histologic and bacteriologic elements as are found in bronchiectasis and lung abscess. It is unfortunate that this abundant opportunity for investigation of these relatively rare conditions was not taken advantage of for systematic and thorough laboratory work. Arrangements are now made to do better in the future. Clinically the secretions of relatively recent cases were mucopurulent in character, often tinged with blood. In the peanut cases (all children) the mucopus, in most instances, was pink in color. In all the cases of prolonged sojourn the pus was characterized by being very foul, stale odor. Usually the color was rather dark and somewhat greenish, rather thin than thick, not creamy. In some cases it was rather stringy. As soon as coughing was commenced in the procedure of bronchoscopy the oozing of blood from the granulations made the pus bloody to the extent that all other characteristics were lost, except the odor which persisted most obtrusively. In many of the cases of peanut kernels, maize, etc., the pus (often of "laudable" character) was coughed out as soon as the bronchoscope was inserted, in such copious quantities as to drip from the bronchoscopist's gown to the floor.

DROWNED LUNG AND LUNG ABSCESS

It is my custom always to take a roentgenograph of the chest after the removal of the foreign body for comparison with the one taken before the bronchoscopy. This has led to the discovery that much of the opacity of the subjacent lung tissue in recent cases disappears after bronchoscopy, evidently due to the usual bronchoscopic "sponge-pumping" out of purulent secretions. In cases of prolonged sojourn of the foreign body in the lung the same thing is noticeable but to a less degree, and there still remains, in the latter class of cases, much opacity as compared to the other side. Possibly part of the contrast of the two sides is due to compensatory emphysema of the uninvaded side; but allowing for this there is unmistakable opacity. In the course of years (ranging from 1 to 10 in our records), the shadows almost entirely disappear, though traces may be visible long after all symptoms have disappeared and all physical signs have become normal.

When the drainage from a bronchus, large or small, becomes obstructed the secretions accumulate below and we have the natural passages filled with secretions which are, or soon become, purulent. This condition we have fallen into the custom of referring to as "drowned lung." It may give the same note as an atelectatic area and the two conditions may co-exist. Clinically it differs from true abscess in that it may develop rapidly, within a day or two in some instances, and in that if relieved at once by removal of the foreign body, recovery from whatever local reaction may be present is almost always prompt and complete. If, however, the area of "drowned lung" is not relieved by removal of the foreign body from the bronchus, the bacteria become

active in the pent-up secretions; the saprophytes decompose the secretions; the toxins and other products of bacterial activity, together with the inflammation, result in destruction of the cilia, the epithelium, then the subepithelial tissues, and the perichondrium; the cartilage itself dies and we have a cavity. Across one such "cavity" there stretched a band of tissue, which had an appearance of branching (Figure 9, Plate I). As to the nature of this band it is impossible to say. It may have been cicatricial tissue left during the shifting from some previous stage in the course of the inflammatory changes in the reaction of the tissues to the presence of the foreign body. It seems more probable, however, that it was some of the natural tissues more resistant than the others to the pathologic processes. Its form suggested a small branch bronchus, though the author's experience with purulent processes about the larynx is that perichondrium and cartilage are very prompt to become involved and break down under purulent processes. The interior of the abscess wall in the case with the band, was lined with large mushy, flabby granulations which entirely filled the cavity. Possibly this apparent filling may have been due in part to collapse of the walls. Be this as it may, the interior could be explored only by "caisson bronchoscopy," a method devised by the author for endoscopically inflating lung abscess cavities during examination. This case and the method have been previously reported. In the absence of autopsies it has been impossible to determine, by bronchoscopy alone, in every case, whether an observed hollowness constituted an abscess cavity or a bronchiectasis. The region below the stricture that held the foreign body was, in every case of prolonged sojourn, lined with bleeding inflammatory tissue, endomacroscopically resembling granulation tissue. In some of the cases in which there had been relatively free drainage around the foreign body, in the interstices between it and the bronchial wall, the latter, more or less altered by chronic inflammation, was visible in certain portions of the visible field. As near as the author has been able to determine, the condition has been one of bronchiectasis in 10 cases, and of abscess properly so called 6 out of 23 cases of prolonged sojou of foreign bodies in the lung. In the oth 7 cases, no conclusion as to which to call t condition could be arrived at bronchosco cally. Foreign-body abscesses have be known to have a tendency to rupture in the pleural cavity or the mediastinum.

Drowning of the patient in his own secretio In the foregoing paragraphs reference is h only to the drowning of sections of lu The author (3) has previously called tention to the fact that glottic impairm can cause the bronchi and trachea to fill until the patient will actually drown in own secretions. It is a true drowning in sense that fluid by its presence mechanic prevents atmospheric air from reaching capillaries of the air cells. This condition arisen in our foreign-body cases chiefly children, whose subglottic tissues for a tomical reasons are peculiarly susceptible œdema. This œdema occurred in 3 classe case:

1. Those in which a loose foreign body been knocked about in the trachea by co
2. Those in which the foreign body wa such peculiar character or accompanim as to have excited a very violent dif reaction in the tracheobronchial tree.
3. A foreign body so jammed in the gl as to prevent glottic closure in the be cycle.
4. One adult patient who had a recur paralysis before the foreign-body acciden

The mechanism of bechic expulsion secretions (or anything else) is briefly:

1. The taking of a deep breath, filling lungs with air.
2. Tight closure of the glottis.
3. Contraction of the expiratory mu to raise the air pressure.
4. Sudden opening of the glottis, relea the compressed air and gases in the ches
5. Outward rush of the blast of compre air and gases through the bronchi, trac larynx, fauces and mouth, the blast carr with it secretions and foreign bodies wi varying degree of efficiency.

The efficiency depends, as one of its phases, upon free glottic movement, as

as upon glottic patulency. If the glottis cannot close tightly preliminary compression of the intrathoracic air is impossible, so that the outward rush lacks suddenness, hence its efficiency as a secretion remover is lessened. If the glottic chink is narrowed so that its maximum exposure does not permit thick secretions to pass, the efficiency is impaired obstructively.

BRONCHIAL STENOSIS SECONDARY TO FOREIGN BODY

Recent cases. Bronchial stenosis in cases of globular or cylindric foreign bodies of more or less regular outline, so far as we could determine, resulted promptly from the wedging of the respective foreign bodies by impact in the smallest bronchus they could enter. Thus occluded, absorption of air took place in the tributary lung below, resulting in a negative pressure which forced the intruder farther and farther down. Then the inflammatory reaction in the neighborhood of the foreign body resulted in an annular œdema on the proximal side of the foreign body. Whether or not a similar condition existed below could not always be determined because in acute cases there was not often any justification for reinsertion of the bronchoscope after the removal of the foreign body. But the swelling on the proximal side, constituting, as it does, one of the difficulties to be overcome in the bronchoscopic seizure of the foreign body, was only too obvious. It was present in every recent case in which a cork-like occlusion of a bronchus had existed for a day or more. When a foreign body of somewhat irregular shape enters a bronchus, for a time the air can pass through the interstices left by the irregularities, as in Figures 6 and 12, Plate II. These interstices may be more or less occluded, if small, by this mucopus. If large, air and secretions may pass for a varying length of time, probably depending on the rapidity and intensity of the mucosal swelling which the particular foreign body may excite, the thickness of the secretions, the size of the bronchus, or, rather, the amount of cubical capacity of the subjacent lung on which depends the force of the respiratory and bechic blasts. A slender foreign body, such as a pin, located in a relatively large bronchus, had not resulted in bronchial obstruction in any of our cases short of 5 years. In Case Fbdy. 569 the exact time elapsed before obstruction supervened could not be determined; but occlusion was practically complete when the first bronchoscopy was done, 5 years after the aspiration of the pin.

Cases of prolonged sojourn. In all the 23 cases of prolonged sojourn of a foreign body in a bronchus there was more or less obstruction. This stenosis was composed of the foreign body plus the inflammatory sequelæ, cicatricial stricture, granulation tissue and purulent secretions, these various factors being present in varying degrees in the various cases.

Encysting of foreign bodies in the lung. Anthracosis concerns only relatively minute foreign bodies, which by reason of the small size reach the bronchioles and air cells. The author's observations concern only foreign bodies of relatively large size which necessarily occupy bronchi of a size not less than probably 3 millimeters in diameter. Such bodies probably rarely become encysted. If the bronchus closes proximally the locked-up bacteria and their pabulum form an abscess in most instances. In only two cases in the author's experience was a foreign body of size truly encysted and even in these the encysting may ultimately break down and result in abscess formation. There are five factors that probably contribute to prevent encysting of a foreign body in the lung.

1. Infection.
2. Patulency.
3. Epithelialized surfaces.
4. Movement.
5. Penning up of subjacent secretions, normal or abnormal, the passage of which maintains an open channel when forced upward either by bechic or accumulative pressure.

COLOR PLATES

The illustrations are reproduced by photo engraving from the original oil color drawings painted by the author from his sketches made immediately after the removal of the foreign bodies. They all represent the living tissues (except Figure 9, Plate II) as seen through the

laryngoscope, bronchoscope or œsophagoscope. Color always varies with the degree and character of the illumination and nowhere more so than in endoscopy. The light used by the author is of moderate intensity close to the tissues, at distal end of tube. For clearness the drawings are made to show appearances after the removal of secretions.

The effort is made to compare the effect of short and of prolonged sojourn of foreign bodies of the same character rather than isolated instances of all kinds of foreign bodies.

BIBLIOGRAPHY

NOTE.— The following publications are all written by the author and their listing here is intended only to enable those interested to find case reports, repetition of which has been omitted in this paper. No attempt has been made to review the literature. It has been deemed best to limit this paper to the recording of a relatively enormous endoscopic experience, for what it may be worth.

1. Peroral Endoscopy and Laryngeal Surgery. Textbook. 1915. St. Louis: Laryngoscope Co., 1915.
2. Amalgam tooth filling aspirated into the lung during extraction. Dental Cosmos, 1917, May.
3. Drowning of the patient in his own secretions. Laryngoscope, 1911, Dec.
4. Bronchiectasis and bronchiectatic symptoms due to foreign bodies. Penn. M. J., 1916, Aug.
5. Bronchoscopic removal of a collar button after twenty-six years' sojourn in the lung. Ann. Otol., Rhin. & Laryngol., 1913, June.
6. Influenzal tracheitis. Laryngoscope, 1912, Feb., (editorial).
7. Caisson-bronchoscopy in lung abscess due to foreign body. Surg., Gynec. & Obst., 1917, XXV, 424-428.
8. The dilatation of bronchial strictures. J. Am. M. Ass., 1912, Sept. 21.
9. A new method of working out difficult mechanical problems of bronchoscopic foreign-body extraction. Laryngoscope, 1917, Oct.

BRONCHOSCOPIC AND ŒSOPHAGOSCOPIC VIEWS SHOWING THE PATHOLOGIC CHANGES FOLLOWING THE PRESENCE OF FOREIGN BODIES IN THE BRONCHI AND ŒSOPHAGUS

PLATE I

Fig. 1. Case Fbdy. 616B. Child, aged 7 years. Steel shawl-pin with head downward to left in left upper-lobe bronchus. Point lying in contact with median wall of left main bronchus. Peroral bronchoscopic removal. Cure.

Fig. 2. Case 269 P. E. Child, aged 12 years. Steel shawl-pin with head in left upper-lobe bronchus; point imbedded in median wall of left main bronchus. Endoscopic view 2 days after aspiration of pin. Peroral bronchoscopic removal. Cure.

Fig. 3. Case Fbdy. 394B. Infant, aged 18 months. Steel shawl-pin with head in left upper-lobe bronchus; point imbedded in median wall of left main bronchus. Pin probably *in situ* 35 days. Inflammatory state obliterating image of bronchial rings due to 2 previous rough bronchoscopies by an operator who was unable to see the pin. The grayish patch is exudate from improper instrumentation. Ordinarily reaction is only local around the buried point, as in Figure 2. That the baby survived the two previous rough, prolonged bronchoscopies is remarkable. Usually such work is fatal to infants. I have never seen such a reaction from either a metallic foreign body or a carefully done bronchoscopy. Peroral bronchoscopic removal. Cure.

Fig. 4. Case Fbdy. 577B. Girl, aged 7 years. Steel shawl-pin with head in left upper-lobe bronchus; point imbedded in median wall of left main bronchus, the pin being transfixed across the lumen of the bronchus. Observed 5 months after aspiration of pin, which is thickened and roughened by corrosion. Inflammatory state less than that of trauma from rough bronchoscopy in case shown in Figure 3. This illustrates the surprisingly little and the remarkably limited inflammation set up by a metallic foreign body in the bronchi. It is only in the immediate neighborhood that the rings are obliterated by the inflammation, which moreover, is essentially chronic. Peroral bronchoscopic removal. Cure.

NOTE.— Figures 1, 2, and 4 afford a noteworthy opportunity for comparison of the effect of a foreign body of precisely the same character (steel pins with glass heads) in about the same location, but of various durations of sojourn.

Fig. 5. Case Fbdy. 565. Girl, aged 8 years. Steel shawl-pin with head in left main bronchus, the point in tracheal wall above orifice of right bronchus. A tiny stream of blood is seen to be carried by the cilia toward the posterior wall of the trachea. (See also Figure 10.) Peroral bronchoscopic removal. Cure.

Fig. 6. Case Fbdy. 625. Man, aged 21 years. Dental root-canal-reamer (tool steel with brass handle) in middle-lobe bronchus, the point having entered slightly into the mucosa. Faint areola around point of entrance. (Compare Figure 11, in which a similar foreign body had been in a bronchus for 3 months.) Peroral bronchoscopic removal. Cure.

Fig. 7. Case Fbdy. 569. Woman, aged 63 years. Steel shawl-pin was aspirated 5 years previously, and probably entered a branch of the middle-lobe bronchus. The yellow patch on the mound-like swelling represents a mass of pus and exudate.

Fig. 8. Same case as in Figure 7. The pus and exudate have been wiped away, revealing the end of the much-corroded pin occupying the strictured orifice of an abscess cavity. This appearance of a foreign-body abscess cavity is not unusual but the mound-like protrusion into the lumen of the bronchus is rare.

Fig. 9. Same case as in Figures 7 and 8. Interior of abscess cavity. The orifice was dilated and the pin was removed, a caisson-bronchoscope has been inserted and the cavity ballooned for examination of its interior. The nature of the band stretching across from wall to wall was not determined. It might have been vascular, bronchial or cicatricial tissue. Pus was very foul. All expectoration ceased after a few weeks and the patient is still well at end of 2 years.

NOTE.— Comparisons of Figures 1, 2, 4, 7, 8 and 9 are interesting as they show the pathologic changes of

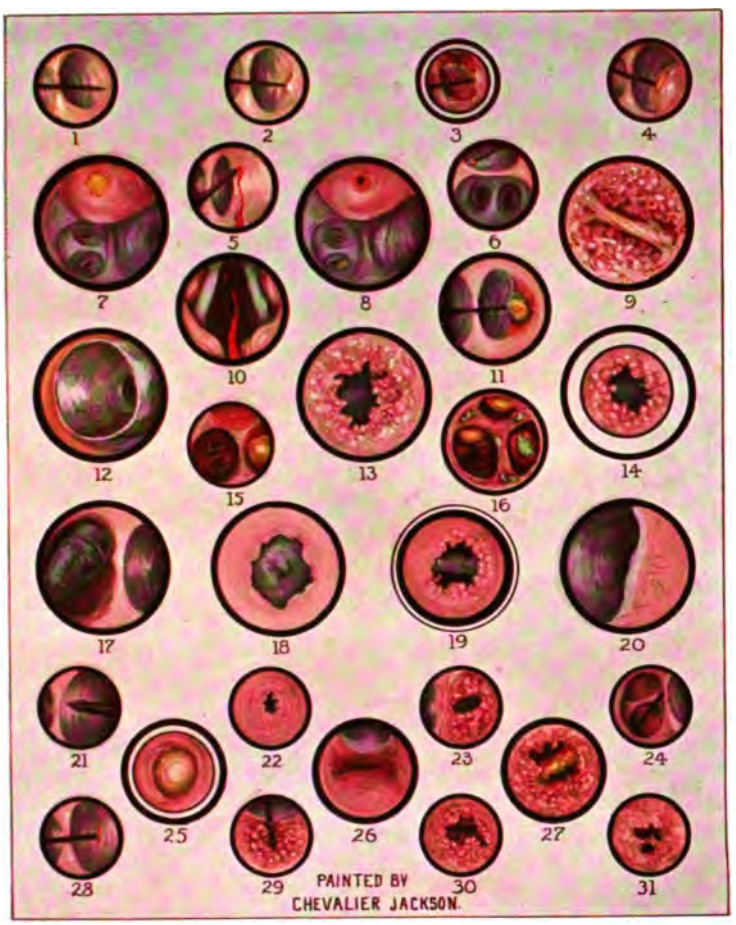
1
2
3
4
5
6
7
8
9
10
11
12
13
14
15
16
17
18
19
20
21
22
23
24
25
26
27
28
29
30
31
PAINTED BY
CHEVALIER JACKSON.

PLATE I.



similar foreign bodies (steel pins with glass heads), present for various periods from 2 days to 5 years.

Fig. 10. Same case as in Figure 5. Tiny stream of blood is seen to be carried by the cilia up the posterior wall of the trachea and out the "pitcher mouth" between the arytenoids. This original observation of the author has been observed in previous and subsequent foreign-body cases. Occasionally it is seen in tuberculous cases. At intervals the cough removed the streak of blood; but it was soon replaced in cases in which the bleeding continued in sufficient and not too great amount. It was not noticeable in copious hæmorrhages.

Fig. 11. Case Fbdy. 552. Dental root-canal-reamer (tool steel with brass handle) in left upper-lobe bronchus or 3 months. The point has entered the wall of the main ronchus, the point of entrance being surrounded by an nflammatory areola. A small patch of exudate is adherent. The local and mild character of the inflammation is imortant. Compare Figure 6, which shows the endoscopic ppearances in a case of only 2 days' sojourn of a similar nstrument.

Fig. 12. Case 230 P. E. Man, aged 76 years. Nickelated brass atomizer tip in right stem bronchus 10 days. nflammatory reaction localized, probably because the reign body is not of very irritating character and owing the hole in the distal end, it does not obstruct drainage. ickel-plating tarnished but not corroded. Peroral onchoscopic removal. Cure.

Fig. 13. Case Fbdy. 611. Man, aged 58 years. Nickelated brass atomizer tip in right stem bronchus 1½ years. he size, shape and position of this foreign body are ecisely the same as in the preceding case. (See Figure 12, ove.) The granulation tissue that obstructs the view to the interior of the atomizer tip has developed as the sult of a 1½ years' sojourn. The granulations surmount firm, fibrous stricture, which required bronchoscopic atation for the removal of the foreign body. Pus very il. Perichondritis present. Nickeling entirely gone, ss much corroded. Peroral bronchoscopic removal. re.

NOTE.— The localized character of the inflammatory cesses in the cases illustrated in Figures 12 and 13, is eworthy and is probably due to the relatively unirriing character of the foreign body and to its form, which ause of the opening at both ends did not greatly obstruct inage.

ig. 14. Case Fbdy. 572. Boy, aged 9 years. Brass cap n bedstead in right main bronchus 1 year and 9 months. e general shape and position of the foreign body are ilar to Figure 12; but there is no hole in the distal end he cap. The obstruction to drainage had caused much e extensive pathology in the right lung (shown by ntgenography and physical signs) as compared to the preceding cases. Endoscopically the bronchi of the lung were normal, and this was corroborated by the and the physical signs, both the two last indicating pensatory emphysema. The illustration shows a imal fibrous stricture covered with granulations. pus was copious and very foul. Brass much corroded.

g. 15. Case Fbdy. 439b. Boy, aged 6 years. Peanut el projecting from the orifice of the right upper-lobe chus, two days after the kernel was inhaled. Intense se bronchitis, which is particularly noteworthy in parison with the relatively mild and markedly localized mmation resulting from the presence of foreign bodies r than vegetable substances and especially in comon with metallic bodies, particularly steel. Peroral choscopic removal. Cure.

g. 16. Case Fbdy. 584. Child, aged 5 years. Peanut els in middle-lobe bronchus and an anterior branch of the inferior-lobe bronchus, 4 weeks after the accident. Diffuse bronchitis, patches of exudate. The pus which was copious has been sponged away. The trachea and the bronchi of the other lung were also inflamed. A younger child would probably have succumbed in less time. Peroral bronchoscopic removal. Cure.

Fig. 17. Case 369 P. E. Man, aged 23 years. Bullet, probably chiefly lead, in orifice of left bronchus. Accidentally inhaled a few days previously. Localized bronchitis. Lead not corroded.

Fig. 18. Case Fbdy. 574. Amalgam tooth filling, probably composed of silver, tin and mercury; in left stem bronchus 2 weeks. Proximal annular œdema, possibly due in part to tight impaction of the foreign body. Localized bronchitis. Bronchi of the upper lobe and of the other lung were normal. Peroral bronchoscopic dilatation of annular œdema; removal of foreign body. Cure.

Fig. 19. Case Fbdy. 440. Boy, aged 14 years. Lead alloy collar button in left inferior-lobe bronchus 11 years. Proximal, firm, fibrous stricture, covered with granulations. Bronchiectatic cavity, below, lined with granulations, and filled with very foul pus. The button was somewhat corroded. Stricture dilated and foreign body removed by peroral bronchoscopy. Cure.

Fig. 20. Case 243 P. E. Youth of 18 years. Lead alloy collar button in right lung for 10 years. Cicatricial web occluding half of bronchus. At bottom of dilated cavity is the lumen of a firm fibrous stricture. The foreign body was found immediately below this stricture after dilatation. The bronchiectatic cavity below was filled with foul pus. It seems probable that originally the collar button had remained for a long time at the location of the web. Peroral bronchoscopic removal of foreign body. Cure.

NOTE.— Figures 17, 19, and 20 afford opportunity for comparison of the effect of short and prolonged sojourn of lead alloys in the bronchi.

Fig. 21. Case 225 P. E. Boy, aged 5 years. Steel nail in right main bronchus 1 week. Superficial mild bronchitis. Nail coated thinly with film of corrosion. Peroral bronchoscopic removal. Cure.

Fig. 22. Case Fbdy. 410. Boy, aged 11 years. Steel nail in right stem bronchus 9½ years. Chronic purulent bronchitis over entire right lung. Firm fibrous stricture of very small lumen. Granulations and very foul pus filling cavity below stricture. Nail corroded to a cinder-like mass that pulled apart on traction. Peroral bronchoscopic dilatation of stricture and piecemeal removal of foreign body. Cure.

Fig. 23. Case Fbdy. 408. Steel nail in right main bronchus about 3 years. Much corroded nail clasped tightly in a bed of fibrous tissue and granulations. Pus very foul. Peroral bronchoscopic removal of nail. Apparent recovery, followed 2 months later by death from purulent process in lower thorax or upper abdomen. Postmortem unobtainable.

Fig. 24. Case Fbdy. 621. Girl, aged 4 years. Steel nail in left inferior-lobe bronchus 1 month. Bronchitis all over right side due to violent bronchoscopy before admission. Peroral bronchoscopic removal of nail. Cure.

NOTE.— Figures 21, 22, 23, and 24 afford opportunity to contrast the effects of steel nails present in the bronchi for periods varying from 7 days to 9½ years.

Fig. 25. Case Fbdy. 624. Girl, aged 4 years. Pebble in right main bronchus 3 days. Proximal annular œdema, probably from pressure of tightly impacted smooth, round, closely-fitting body. Localized bronchitis. In a previously reported case of a pebble the conditions were precisely the same. Peroral bronchoscopic extraction. Cure.

Fig. 26. Case 266, P. E. Woman, aged 23 years. Brass tag-fastener in right lung 7 years. Chronic bronchitis.

Firm fibrous stricture of stem bronchus, with slit-like lumen, below orifice of middle-lobe bronchus. Very foul pus was coughed through the stricture. A large cavity below the stricture was revealed after dilatation of the stricture. The foreign body was located at the top of the cavity, fixed in fibrous tissue. Foreign body (brass) corroded, but still strong after 7 years' sojourn. Extraction. Cure.

Fig. 27. Case 244 P. E. Woman, aged 48 years. Glass collar button in left lung for 26 years. On passing bronchoscope bronchus was found completely occluded by fibrous tissue. This was excised with biting forceps used through the bronchoscope, until a cavity was reached. Across the neck of the cavity, the collar button was found fixed in fibrous and granulation tissue, as here shown. The cavity contained very foul pus. The collar button was removed by peroral bronchoscopy and patient made a perfect recovery.

Fig. 28. Case 233 P. E. Child, aged 11 years. Brass-headed steel tack in left upper-lobe bronchus 4 days. Slight congestion is present where the tack rests on the spur between the upper-lobe and stem bronchi. Slight areola of inflammation around the buried point of the tack on the inner wall of the main bronchus. Tack not visibly corroded but a black film was wiped away with gauze. Peroral bronchoscopic removal. Cure.

Fig. 29. Case Fbdy. 382. Youth, aged 18 years. Brass-headed steel tack in right bronchus. The head is buried in granulation tissue in the stem bronchus below the orifice of the middle-lobe bronchus; the point is buried in the anterior wall of the main bronchus. Pus foul. Localized bronchitis. The middle-lobe bronchus is relatively normal. Small amount of pus was found in uninvaded lung, probably drawn in shortly before bronchoscopy. Peroral bronchoscopic removal of tack. Cure.

Fig. 30. Case Fbdy. 412. Boy, aged 6 years. Brass-headed steel tack in right bronchus 2½ months. The head is buried in granulation tissue; the point has ulcerated outward through the bronchial wall; but this occurred so slowly that the mediastinum was not affected. Bronchus bronchiectatic below tack; dilatation filled with foul pus. Large area of "drowned lung." Peroral bronchoscopic removal. Cure.

Fig. 31. Case 221 P. E. Woman, aged 52 years. Brass-headed steel tack in left lung 2 years. Granulations have been nipped away, revealing the point of the corroded steel shaft of the tack in an almost closed posterior branch of the inferior-lobe bronchus. The pus was very foul. Peroral bronchoscopic removal. Cure.

NOTE.— Figures 28, 29, 30, and 31 afford an opportunity to contrast the pathologic changes present in 4 different cases, all of the same kind, of a foreign body in the bronchi for periods varying from 4 days to 2 years. The head of these tacks was of umbrella-like shape, the obstruction by which would vary with changes of position.

PLATE II

Fig. 1. Case Fbdy. 411. Girl, aged 17 months. Fishbones in right stem bronchus at orifice of upper-lobe bronchus "many days." Intense localized bronchitis. Peroral bronchoscopic removal. Cure.

Fig. 2. Case 308 P. E. Infant, aged 9 months. Fishbone in right stem bronchus 29 days. Bronchitis localized. Orifice of right upper-lobe bronchus normal. Peroral bronchoscopic removal. Cure.

Fig. 3. Case Fbdy. 386. Woman, aged 25 years. Fishbones in branches of left inferior-lobe bronchus 5 weeks. Bronchitis limited to invaded branches and their orifices. Proximal portion of stem bronchus and the orifice of the upper-lobe bronchus are seen to be normal. Peroral bronchoscopic removal. Cure.

NOTE.— Figures 1, 2, and 3 afford opportunities for noting the effect of fishbones in the bronchi for considerable periods.

Fig. 4. Case Fbdy. 425. Infant, 17 months. Walnut kernel in orifice of right upper-lobe bronchus 3 days. Diffuse tracheobronchitis. Note thickened interorificial spurs. Severe diffuse bronchitis was present in left lung also. Peroral bronchoscopic removal. Cure.

Fig. 5. Case Fbdy. 550. Boy, aged 11 years. Iron casting in right main bronchus 3 days. Localized bronchitis. Left bronchial orifice is normal. Peroral bronchoscopic removal. Cure.

Fig. 6. Case Fbdy. 583. Child, aged 2 years. Half of the glass eye of a "teddy bear" in the right stem bronchus below orifice of upper-lobe bronchus 4 days. Localized bronchitis. The main bronchus above the stem bronchus was normal, as were also all the bronchi on the left side. Peroral bronchoscopic removal. Cure.

Fig. 7. Case Fbdy. 399. Man, aged 44 years. Galvanized steel staple (double-pointed) in a dorsal branch of the right inferior lobe bronchus 15 days. Localized inflammation. Only the concavity of the rounded middle portion of the U-shaped staple is visible. The points are toward us, buried in the mucosa by coughing, and hidden by the annular inflammatory swelling. The orifice of the middle-lobe bronchus (above) and of the upper-lobe bronchus (to the right) are normal. The points of the staple were slowly and carefully freed, brought upward and turned down into the two anterior-branch orifices seen above the invaded bronchus to permit "version" of the staple for safe removal, which was followed by prompt and complete recovery. (See *Journal American Medical Association*, June 5, 1915, p. 1906.)

Fig. 8. Case Fbdy. 409. Man, aged 43 years. Large fence staple, galvanized steel, in left main bronchus 2 years. Localized bronchitis. Acute œdema, due to efforts at bronchoscopic removal before admission, masks the chronic lesions somewhat. Localized bronchitis and perichondritis. The ring of reddish tissue hiding the upward projecting points is fibrous inflammatory tissue, much firmer than the acute œdematous ring in Figure 7. Vessels are visible. There were granulations deeper down below the fibrous ring, where the staple had been lying. The points are deeply embedded by prolonged coughing and ulceration. The staple was removed by version, the points being disembedded, brought upward and turned down into the right bronchus, whose orifice is shown to the right. The limitation of the inflammation after 2 years is remarkable. The carina is not thickened and the right bronchial orifice is normal. Peroral bronchoscopic removal. Cure.

Fig. 9. Case Fbdy. 622. Postmortem bronchoscopic view of a rubber eraser lying in the orifice of the right main bronchus 7 months. The carina is thickened. The thin, greenish, flocculent fluid filled both lungs and the trachea up to the larynx. The view represents conditions after the fluid had been removed sufficiently partially to expose the carina and the rubber. Both lungs were functionally destroyed in 7 months.

Fig. 10. Case Fbdy. 385. Chicken-bone lying loose at the orifice of a bronchiectatic cavity as seen after sponging. Usually foreign bodies of prolonged sojourn are fixed in inflammatory new formation. The bone had been in the lungs about a year. Peroral bronchoscopic rmoval. Cure.

1
2
3
4
5
6
7
8
9
10
11
12
13
14
15
16
17
18
19
20
21
22
23
24
25
26
27
28
PAINTED BY
29 CHEVALIER JACKSON. 30
31

PLATE II.

Fig. 11. Man, aged 37 years. Perichondritis of the orifice of the middle-lobe bronchus. Unhealed cartilage is indicated by the granulations occupying the orifice of an anterior branch of the inferior-lobe bronchus, in the track of a bullet which passed through the chest 13 months before. This shows the effect of trauma without the continued presence of the foreign body that inflicted it. (Perichondritis is often present in cases of prolonged sojourn such as 9, 14, 22, etc.) Recovery after internal adminstration of small doses of potassium iodide and the use of thromboplastin.

Fig. 12. Case Fbdy. 623. Man, aged 39 years. Beef bone impacted in right main bronchial orifice as seen 23 days after aspiration. Acute localized bronchitis due to rough bronchoscopy before admission. The greenish patch of exudate is due to a wound made in a bronchoscopic attempt to remove the bone before admission. The left bronchial orifice is normal and the carina nearly so. Peroral bronchoscopic removal. Cure.

Fig. 13. Case Fbdy. 310. Woman, aged 39 years. Chicken bone transfixed in trachea. Contrary to the rule, this bone is in the lateral plane. The bone had been in the trachea 6 days, yet the reaction is limited to an areola around the points of fixation. This is in marked contrast to the cases of prolonged sojourn, such as shown in Figures 10 and 14.

Fig. 14. Case Fbdy. 608. Man, aged 20 years. The beef bone had been in the lung 11 years. It is shown beyond a firm fibrous stricture covered with granular, inflammatory, partly epithelialized tissue. Perichondritis. The bone in its crosswise diameter is larger than the stricture but permitted continuous drainage, at both sides, and the lumen of the stricture was not small, which probably accounts for the survival of the patient for so many years in spite of the suppuration. There was a chronic bronchitis throughout right side. Peroral bronchoscopic removal. Cure.

Fig. 15. Case Fbdy. 3676. Boy, aged 14 years. Deciduous molar tooth completely obstructing the orifice of right upper-lobe bronchus, 2 months after accident. The inflammatory mass in which the tooth was embedded is thrown into prominence by strong lateral pressure with the lip of the bronchoscope. Distant bronchi and those of the other side were not inflamed. Peroral bronchoscopic extraction. Cure.

Fig. 16. Case Fbdy. 578. Boy, aged 3½ years. Ring of pearl shell (mollusk) in œsophagus for a period of over one year. Localized chronic œsophagitis, ulceration; swollen folds. Foreign body embedded in a pocket of inflammatory tissue, with granulations at the lateral edges. The shell had whitish incrustations at certain points; but whether or not they occurred during the sojourn in the œsophagus could not be determined. Œsophagoscopic extraction. Cure.

Fig. 17. Case Fbdy. 431. Boy, aged 12 years. Cockle burr in larynx one day. Moderate acute laryngitis; not nearly so severe as one would anticipate from the prickly nature of the foreign body. Extraction. Cure.

Fig. 18. Case Fbdy. 432. Girl, aged 4 years. Lead alloy image of a horse in the larynx more than one month. Larynx swollen almost shut. Granulations, ulceration. Tracheobronchitis was present from the accumulation of secretions due to glottic obstruction and loss of the aid of glottic movement in the bechic cycle. Lead alloy partly covered with a colored varnish, partly not. No apparent corrosion.

Fig. 19. Case Fbdy. 364. Boy, aged 4 years. Brass safety pin in larynx more than 2 months. Larynx swollen nearly shut. Glottic margins eroded. Tracheobronchitis was present from accumulation of secretions that could not be expelled, as in preceding case (Fig. 18). Brass pin blackened by corrosion.

Fig. 20. Case Fbdy. 628. Boy, aged 12 years. Coin (silver half-dollar) in œsophagus 5 days. Slight congestion of œsophagus; no œsophagitis. The silver surface is bright at the sides where it was clasped in the œsophageal folds. The vertical central zone on all surfaces is black with a thick dull corrosion, probably sulphides.

Fig. 21. Case Fbdy. 426. Nursing infant, girl, aged 6 months. Gold "filled" cuff-button partly in trachea and partly in œsophagus. (See Fig. 28.) Button had been swallowed 3 months before and had evidently ulcerated through the party wall into the trachea, the large part of the button being in the œsophagus, the stem between the two parts occupying a fistula through the party wall. Granulations around the fistula. Tracheobronchitis probably from mother's milk leaking through fistula while taking breast. The metal was corroded in patches. Endoscopic removal. Cure.

Fig. 22. Case Fbdy. 630. Girl, aged 12 years. Shoe button (fiber composition with steel eyelet) in left stem bronchus 7 months. Chronic bronchitis limited to left lower-lobe bronchus. Granulations form a bed for the button and obstruct drainage. Some degree of bronchi ectasis was noticeable below the button. Fiber unchanged, steel eyelet corroded. Bronchoscopically removed. Cure.

Fig. 23. Case Fbdy. 558. Boy, aged about 2 years. Cast-iron "jack" in œsophagus about 2 months. Œsophagitis, inflammatory infiltration, granulations. (Compare Fig. 30.) The cast-iron was not corroded in the slightest degree in its 2 months' sojourn.

Fig. 24. Case Fbdy. 434. Woman, aged 57 years. A U-shaped bit of tinned wire from an eggbeater in the œsophagus for 5 weeks. The only inflammatory reaction is a small areola around the location where the two sharp, hook-shaped points have buried themselves in the mucosa. The wire was not corroded except on spots where the tinning was absent. Œsophagoscopic removal. Cure.

Fig. 25. Case Fbdy. 358. Girl, aged 5 years. Copper (or bronze) halfpenny (British) in œsophagus 20 hours. No local reaction; not even congestion. (Compare Fig. 26.) Coin not corroded.

Fig. 26. Case Fbdy. 559. Girl, aged 4½ years. Copper (or bronze) halfpenny (British) in œsophagus 8 months. Granulation, fibrous narrowing, swollen folds. (Compare Fig. 25). The penny was very much corroded.

Fig. 27. Case Fbdy. 354. Boy, aged 2½ years. Gold locket in œsophagus 36 hours. No inflammation or congestion. No corrosion.

Fig. 28. Same case as shown in Figure 21. The large end of the cuff button is here shown as seen in the œsophagus, the stem disappearing in the anterior wall occupies a fistula leading into the trachea. There is a moderate œsophagitis with swollen folds and rough granular mucosa. Peroral endoscopic removal. Cure.

Fig. 29. Case Fbdy. 590. Girl, infant, aged 9 months. Wool from a blanket in œsophagus many days. No œsophagitis. Mucosa not reddened. (Patient a nursling and very anæmic.) Below the wool there was a mild œsophagitis surrounding 3 other foreign bodies; namely, a fragment of a button, a cherry pit, and a mass of cotton wool. All were extracted by œsophagoscopy. Recovery.

Fig. 30. Case 234 P. E. Infant, 11 months old. Cast-iron "jack" in œsophagus 2 weeks. No œsophagitis. Slight congestion. (Compare Fig. 23.) No corrosion of the cast-iron. Œsophagoscopic extraction. Cure.

Fig. 31. Case 93. Boy, aged 3 years. Probang bristles in œsophagus 7 days. Intense œsophagitis due to use of probang before admission. To the right are seen two linear abrasions covered with exudate.

SAFETY PINS

Case Number and Illustration	Age	Foreign Body	Location	Anæsthetic	Tube	Problem	Forceps	Point of Seizure	Result	Time	Route	Remarks
No. 364 Fig. 1	4 yrs.	Safety pin; bent, brass, open	Larynx	None	Laryngoscope	None	Alligator	Keeper end	Extraction Cure	9 sec.	Oral	Larynx swollen nearly shut; glottic margins eroded (Fig. 19, Plate II).
No. 383 Fig. 2	10 mo.	Safety pin (part)	Rt. bronchus, 2 weeks; point up	None	4 mm.	Point up; embedded in left bronchial wall	Side-curved	Near point	Extraction Cure	2 min. 1 sec.	Oral	Diffuse tracheobronchitis; had bronchial symptoms before aspiration of pin.
No. 384 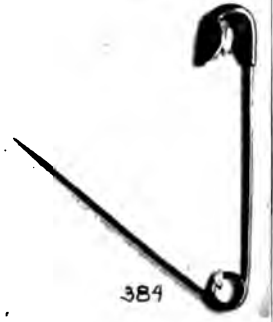 Fig. 3	4 yrs.	Safety pin, open	Larynx, 5 hours; point up	None	Laryngoscope	Open; point up; embedded	Alligator	Near point rotated	Extraction Cure	14 sec.	Oral	Areolar inflammation only.

No. 406 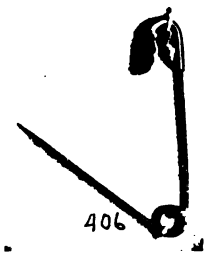 Fig. 4	11 mo.	Safety pin, open	Larynx 8 hours; point up	None	Laryngo-scope	Open; point up; embedded	Alligator	Near point rotated	Extraction Cure	26 sec.	Oral	Very slight areola.
No. 566 Fig. 5	2 yrs.	Safety pin, open	Larynx, subglottic, 2 days; point up	None	Laryngo scope	Avoidance of trauma by point	Alligator	Near point rotated	Extraction Cure	10 sec.	Oral	Slight areola; prior to admission treated for meningitis because of aphonia after fall with pin in mouth.
No. 617  Fig. 6	3 yrs.	Safety pin (part)	Left bronchus, 7 months	None	5 mm.	End hooked into orifice p. bronchi l. b.	Side-curved	End	Extraction Cure	2 min. 11 sec.	Oral	Bronchitis; granular mucosa; granulations about lower end of pin.

SAFETY PINS—*Continued*

Case Number and Illustration	Age	Foreign Body	Location	Anæsthetic	Tube	Problem	Forceps	Point of Seizure	Result	Time	Route	Remarks
No. 619 Fig. 7	15 yrs.	Safety pin, open	Left lung, lower lobe, point up; 10 months	None	7 mm.	Open pin; point up in lung; end only, in (very small) bronchus	Side-curved	End after bending	Extraction Cure	21 min. 3 sec.	Oral	Granulations fungating; localized reaction; pin had not been in same location 11 months; four bronchoscopies before admission had moved pin.
No. 397 Fig. 8	8 mo.	Safety pin, open	Œsophagus below cricopharyngeus, 2 days; point down	None	Laryngoscope	Preventing keeper from hooking under cricoid	Alligator	Spring end	Extraction Cure	30 sec.	Oral	Traumatic œsophagitis from probang used prior to admission.
No. 415 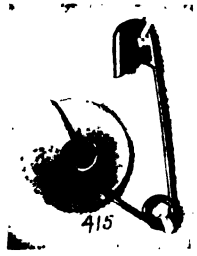 Fig. 9	10 days	Safety pin and and button (pin open)	Œsophagus below cricopharyngeus; point up; 6 hours	None	Laryngoscope	Point buried, fastening button	Alligator	Near point	Extraction	1 min. (approx.)	Oral	Small areola around buried point.

No. 423  Fig. 10	7 mo.	Safety pin, open	Œsophagus; point up; 6 hours	None	Laryngoscope	Open; point up; embedded	Alligator	Near point	Extraction Cure	18 sec.	Oral	Slight congestion.
No. 430 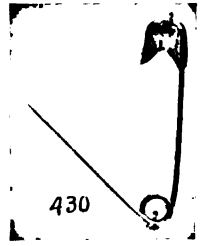 Fig. 11	21 mo.	Safety pin, open	Œsophagus; point up; 6½ hours	None	Laryngoscope	Open pin; point up	Alligator	Near point	Extraction Cure	11 sec.	Oral	Mucosa normal except around buried point.
No. 576 Fig. 12	2 yrs.	Safety pin, open	Œsophagus below cricopharyngeus, 6 hours	None	Laryngoscope ant. com.	Open pin; point up	Alligator	Spring end after version	Extraction Cure	28 sec.	Oral	Mucosa apparently normal; closed by drawing into tube mouth after version.

SAFETY PINS—*Continued*

Case Number and Illustration	Age	Foreign Body	Location	Anæsthetic	Tube	Problem	Forceps	Point of Seizure	Result	Time	Route	Remarks
No. 587  Fig. 13	1 yr.	Safety pin, open	Œsophagus below cricopharyngeus, 7 days	None	Œsophageal speculum	Open pin; point up	Alligator		Extraction Cure	?	Oral	Point buried in mucosa; inflammation around point.
No. 605  Fig. 14	4 mo.	Safety pin, open	Œsophagus at bronchial crossing	None	7 mm.	Open pin; point up	Side-curved	Near point; lip protection.	Extraction Cure	25 sec.	Oral	Œsophageal mucosa apparently normal except slight redness where point lay.
No. 615 Fig. 15	9 mo.	Safety pin, open	Œsophagus at bronchial crossing, 1 week	None	7 mm.	Avoidance of puncture by pushing downward	Straight	Spring end	Extraction Cure	50 sec.	Oral	Mucosa apparently normal.

No. 424 Fig. 16	18 yrs.	Brass imitation tooth crown	Rt. stem bronchus close to u. l. b., 10 days	Local	7 mm.	Turning necessary	Straight	Flatwise after turning	Extraction Cure	2 min. 56 sec.	Oral	Localized moderate bronchitis.
No. 430 Fig. 17	10 yrs.	Brass cap	Rt. bronchus, 4 years	None	5 mm.	Finding			Could not be found		Oral	Cap in pleural cavity; removed by thoracotomy.
No. 551 Fig. 18	4 yrs.	Brass cap	Trachea, subglottic	None	5 mm.	Turning	Side-curved	Edge after turning	Extraction Cure	11 min. 56 sec.	Oral	Traumatic tracheitis close to larynx, from motion of foreign body with saw-like edges during 7 days.
No. 572 Fig. 19	9 yrs.	Brass cap	Rt. bronchus, 2 years	None	7 mm.	Hollow; edges buried	Plain and special	Inside and outside	Extraction Cure	17 min. 53 sec.	Oral	Proximal narrowing; granulations; foul pus (Fig. 14, Plate I).
No. 611 Fig. 20.	58 yrs.	Atomizer tip; brass, nickeled	Rt. stem bronchus, 1½ years	Local	9 mm.	Hollow; sharp, ragged edges buried below fibrous stricture, plus granulations	Straight after liberating edges	Side	Extraction Cure	2 min. 55 sec.	Oral	Proximal fibrous stricture covered with exuberant granulations; perichondritis; plating entirely gone; brass corroded (Fig. 13, Plate I).

HARDWARE—*Continued*

Case Number and Illustration	Age	Foreign Body	Location	Anæsthetic	Tube	Problem	Forceps	Point of Seizure	Result	Time	Route	Remarks
No. 553 Fig. 21	21 mo.	Brass foot of alarm clock	Left main bronchus, 5 hours	None	4 mm.	Proximal ring of œdematous mucosa	Straight	End	Extraction Cure	1 min. 25 sec.	Oral	Acute diffuse tracheobronchitis; accumulation of mucopus below tightly fitting cork-like body.
No. 367 Fig. 22	11 yrs.	Brass-headed tack	Left bronchus, 4 days	None	7 mm. bronchoscope	Point embedded; mushroom anchor	Side-curved	Shaft near point; rotated	Extraction Cure	62 sec.	Oral	Localized congestion.
No. 382 Fig. 23	18 yrs	Brass-headed tack	Rt. stem bronchus at orifice m. l. b., 7 months	Local	7 mm. bronchoscope	Point embedded in ant. wall u. l. b.	Side-curved	Shaft near point; turned	Extraction Cure	11 min.	Oral	Localized bronchitis right; foul pus; granulations buried tack; bronchiectatic dilation; left side normal except a little pus probably from invaded side (Fig. 29, Plate I).
No. 412 Fig. 24	6 yrs.	Brass-headed tack	Rt. main bronchus, 2½ months	None	5 mm bronchoscope	Crosswise fixation; point ulcerated out	Side-curved	Point	Extraction Cure	12 min. 4 sec.	Oral	Pus. very foul; granulations; bronchus dilated below tack and filled with foul pus; large area of drowned lung; dull over entire lower lobe. (Fig. 30, Plate I).
No. 408 Fig. 26	24 yrs.	Tack	Rt. main l. b., many years	Local	7 mm.	Stricture; tack invisible around corner	Upper lobe fcps for bringing into view Side-curved for removal after dilatation of stricture		Extraction Cure	16 min.	Oral	Intermittent abscessal discharge after chill, fever, and sweat; localized inflammation.
No. 400 Fig. 25	6 yrs.	Nail	Rt. main and stem bronchi, 3 years(?)	None	5 mm.	End of nail friable from corrosion. masses of corrosion impacted	Side-curved	Point	Extraction; survived 2 months	4 min.	Oral	Granulations and inflammatory tissue held nail; cavity below nail filled with foul pus (Fig. 23, Plate I).

No. 410 Fig. 27	11 yrs.	Nail	Rt. main bronchus, 9½ years	None	7 mm.	Friability from corrosion; stricture	Straight	Gnawed away bit by bit	Extraction Cure	32 min.	Oral	Granulations; stricture; cavity filled with foul pus (Fig. 22, Plate I).
No. 621 Fig. 28	4 yrs.	Nail	Left inf. l. bronchus, 1 month	None	5 mm.	Transfixion; head anchored in branch orifice	Side-curved	Point after disembedded	Extraction Cure	2 min.	Oral	Bronchitis all neighboring bronchi; right bronchi normal (Fig. 24, Plate I).
No. 399 Fig. 29	44 yrs.	Staple, double-pointed	Post. branch rt. inf. l. b., 15 days	Local	7 mm. 45 cm.	Points upward; buried; proximal œdema	Side-curved Hooks	Curved end after turning	Extraction Cure	1 hr. 24 min.	Oral	Localized inflammation due to puncture of mucosa by points; proximal annular œdema (Fig. 7, Plate II).
No. 409 Fig. 30	43 yrs.	Staple, double-pointed	Left main bronchus, 2 years	Local	9 mm.	Points upward	Side-curved Hooks	Curved end after turning	Extraction Cure	1 hr. 20 min.	Oral	Granulations; fibrous narrowing of lumen proximally; foul pus; no trauma from bronchoscopy done before admission (Fig. 8, Plate II).
No. 550 Fig. 31	11 yrs.	Iron casting	Rt. main bronchus, 3 days	None	6 cm.	Conical end; smooth	Side-curved	Small end	Extraction Cure	6 min. 52 sec.	Oral	Localized bronchitis (Fig. 5, Plate II).

JEWELRY

Case Number and Illustration	Age	Foreign Body	Location	Anæsthetic	Tube	Problem	Forceps	Point of Seizure	Result	Time	Route	Remarks
No. 440 Fig. 32	14 yrs.	Collar-button, lead	Left inf. lobe bronchus, 10 years	None	7 mm.	Stricture; granulations	Side-curved	By post	Extraction Cure	11 min. 2 sec.	Oral	Firmly embedded in granulations and fibrous tissue; bronchiectatic cavity filled with very foul pus below stricture; cavity lined with granulations (Fig. 19, Plate I).
No. 443 Fig. 33	9 mo.	Collar-button, brass	Œsophagus below cricopharyngeus	None	Laryngoscope	Large end presenting	Alligator	Post after version	Extraction Cure	47½ sec.	Oral	Localized slight œsophagitis; foreign body not corroded.
No. 562 Fig. 34	11 mo.	Bar-pin, open	Left inf. lobe bronchus, 2 weeks	None	4 mm.							Removed postmortem.
No. 554 Fig. 35	2 yrs. 4 mo.	Bar-pin, brass and celluloid	Œsophagus at bronchial crossing, 4 days	None	7 mm.	Open pin; point upward; buried in wall; mass of cotton and food entangled	Side-curved	Hinge after version	Extraction Cure	15 min. 15 sec.	Oral	Local œsophagitis; cotton and food foul; point ulcerated deeply into wall.

No. 561 Fig. 36	11 mo.	Bar-pin, silver	Laryngopharynx, 24 hours	None	Laryngoscope	Avoidance of dislodgement into deeper passages	Alligator	Pin	Extraction Cure	6 sec.	Oral	Areolar congestion.
No. 441 Fig. 37	4 mo.	Bar-pin, brass	Left bronchus	None	4 mm.	Anchored; open; point up; in small bronchus	Plain after bent probe	End after closing with bent probe	Extraction Cure	4 min. 5 sec.	Oral	Pus streaming in around foreign body; œdema. (Trauma from bronchoscopy before admission.)
No. 564 Fig. 38	21 mo.	Brooch	Œsophagus below cricopharyngeus, 4 days	None	7 mm.	Preventing laceration of point and serrated edges	Rotation	Flatwise permitting rotation	Extraction Cure	35 sec.	Oral	Lacerations beginning to ulcerate; localized œsophagitis.

PINS

Case Number and Illustration	Age	Foreign Body	Location	Anæsthetic	Tube	Problem	Forceps	Point of Seizure	Result	Time	Route	Remarks
No. 370 Fig. 39	16 yrs.	Pin	Posterior surface epiglottis overhanging larynx, 2 days	None	Laryngoscope	Extraction without dropping deeper	Alligator	Near point	Extraction Cure	18 sec.	Oral	Areolar inflammation only.
No. 586 Fig. 40	2½ yrs.	Pin	Larynx, 2 months(?)	None	Laryngoscope	Fish-hook shape	Alligator	Near point	Extraction Cure	3 min.	Oral	Septic perichondritis; laryngeal œdema.
No. 618 Fig. 41	8 yrs.	Pin	Base tongue overhanging larynx.	None	Laryngoscope	Extraction without dropping deeper	Alligator	Near point	Extraction Cure	20 sec.	Oral	Slight areolar congestion.
No. 557 Fig. 42	17 yrs.	Needle in trachea	Trachea, 2 hours	None	Laryngoscope	To grasp without losing	Alligator	Near point	Extraction Cure	14 sec.	Oral	Slight congestion only.
No. 394  Fig. 43	18 mo.	Shawl-pin	Left bronchus, 35 days	None	5 mm.	Buried in swollen mucosa	Side-curved	Near point; head pushed downward into branch bronchus	Extraction Cure	13 min.	Oral	Diffuse intense traumatic bronchitis from 2 op., 1 hour each duration, under ether before admission (Fig. 3, Plate I).

No. 565 Fig. 44	8 yrs.	Shawl-pin	Head in left main bronchus, 2 days	None	7 mm.	Point buried in tracheal wall	Side-curved	Near point	Extraction Cure	1 min. 16 sec.	Oral	Hæmorrhage from pin-point puncture (Fig. 5, Plate I).
No. 569 Fig. 45	63 yrs.	Shawl-pin	Abscess cavity anterior to right stem bronchus, 5 years	Local	Caisson-broncho-scope	Finding pieces of corroded crumbling pin	Malleable ended	As presented	Extraction Cure	37 min. 24 min. 27 min.	Oral	Abscess; minute opening exuding pus; interior of abscess lined with granulations and heavy band of tissue across it (Fig. 7, Plate I).
No. 577 Fig. 46	7 yrs.	Shawl-pin	Left bronchus, 5 months	None	7 mm.	Transfixed	Side-curved	Near point	Extraction Cure	32 min. 13 sec.	Oral	Localized chronic bronchitis; mound-like swelling around buried point (Fig. 4, Plate I).
No. 616 Fig. 47	7 yrs.	Shawl-pin	Left bronchus; head in u. l. b.	None	7 mm.	None	Side-curved	Near point	Extraction Cure	25 sec.	Oral	Slight congestion; point free; no congestion (Fig. 1, Plate I).
No. 392 Fig. 48	44 yrs.	Shawl-pin	Laryngopharynx, 24 hours	None	Laryngo-scope	None	Alligator	Near point	Extraction Cure	2½ min.	Oral	Sloughing traumatic œsophagitis from attempts prior to admission.
No. 568 Fig. 49	14 yrs.	Shawl-pin	Hypopharynx, 2 days	None	Laryngo-scope	Transfixion; buried point	Alligator	Near point	Extraction Cure	32½ sec.	Oral	Red areola about 1 cm. diameter around buried point.

Case Number and Illustration	Age	Foreign Body	Location	Anæsthetic	Tube	Problem	Forceps	Point of Seizure	Result	Time	Route	Remarks
No. 395 Fig. 50	46 yrs.	Chicken bone	Œsophagus below cricopharyngeus, 2 days	None	10 mm.	None	Rotation	Flatwise near left point	Extraction Cure	45 sec.	Oral	Slight areolar inflammation localized at 2 points of contact.
No. 407 Fig. 51	46 yrs.	Chicken bone	Œsophagus below cricopharyngeus, 2 days	None	10 mm.	None	Rotation	Flatwise near left point	Extraction Cure	1 min. 10 sec.	Oral	Intense œsophagitis, probably from 2 prolonged esophagoscopies before admission.
No. 555 Fig. 52	43 yrs.	Chicken bone	Œsophagus below cricopharyngeus, 24 hours	None	Laryngoscope	None	Alligator rotation	Flatwise near left point	Extraction Cure	25 sec.	Oral	Slight redness around engaged point.

No. 582 Fig. 53	20 yrs.	Chicken bone	Œsophagus at bronchial crossing, 6 days	None	10 mm.	None	Straight and side-curved	Flatwise after turning	Extraction Cure	1 min. (approx.)	Oral	Localized œsophagitis; erosion with red edges at contactual points.
No. 377 Fig. 54	2 yrs.	Chicken bone	Larynx, 10 days	None	Laryngoscope	None	Alligator	Flatwise	Extraction Cure	11 sec.	Oral	Relatively slight local reaction.
No. 385 Fig. 55	12 yrs.	Chicken bone	Right bronchiectatic cavity, 1 year	None	5 mm.	None	Straight	Small end	Extraction Cure	5 min. 3 sec.	Oral	Bone loose in bronchiectatic cavity (Fig. 10, Plate II).
No. 300 Fig. 56	32 yrs.	Chicken bone and meat	Œsophagus below cricopharyngeus, 2 days	None	10 mm.	None	Straight, also mechanical spoon	Fractured part of bone	Extraction Cure	2 min. 3 sec.	Oral	Œsophagitis around puncture of spicule of bone; meat putrid; normal 2 days after removal.

BONES—*Continued*

Case Number and Illustration	Age	Foreign Body	Location	Anæsthetic	Tube	Problem	Forceps	Point of Seizure	Result	Time	Route	Remarks
No. 403 Fig. 57	60 yrs.	Chicken bone	Œsophagus at bronchial crossing, 18 hours	None	10 mm.	Transfixion	Rotation	Near end	Extraction Cure	1 min. 10 sec.	Oral	Mild œsophagitis.
No. 428 Fig. 58	23 yrs.	Chicken bone	Œsophagus below bronchial crossing, 2 days	None	10 mm.	Sharp spicule	Straight	End	Extraction Cure	1 min. (Approx)	Oral	Red areola about 1 cm. diameter.
No. 608 Fig. 59	20 yrs.	Beef bone	Rt. inf. l. b., 11 years	None	7 mm.	Transfixion below firm stricture	Side-curved	Flatwise	Extraction Cure	5 min. 45 sec.	Oral	Firm fibrous stricture; red granular edges; granulations, perichondritis bronchitis (Fig. 14, Plate II).
No. 623 Fig. 60	39 yrs.	Beef bone	Right main bronchus, 23 days	Local	9 mm.	Tight impaction	Straight	Least diameter	Extraction Cure	58 sec.	Oral	Local reaction at points of contact; localized mild inflammation (Fig. 12, Plate II).

No. 580 Fig. 61	24 yrs.	Beef bone	Œsophagus below cricopharyngeus, 4 days	None	10 mm.	Shape and size; avoidance of laceration	Rotation alligator	Flatwise	Extraction Cure	15 min. 18 sec.	Oral	Bone putrid; shreds of periosteum and contents of cells foul; local mild œsophagitis; no general symptoms.
No. 614 Fig. 62	68 yrs.	Beef bone	Œsophagus at hiatus, 3 weeks	None	9 mm.	Large, sharp, rough foreign body; tightly impacted	Rotation	Flatwise	Extraction Cure	3 min. 25 sec.	Oral	Linear varicosities; ulceration; plaques of exudate at traumatized points; localized inflammatory area; bone cancellous very foul; no systemic disturbance.
No. 386 Fig. 63	25 yrs.	Fish bone	Left inferior lobe bronchus, 5 weeks	None	7 mm.	None	Side-curved	Flatwise	Extraction Cure	3 min. 30 sec.	Oral	Localized bronchitis; mucopus (Fig. 3, Plate II).

BONES—*Continued*

Case Number and Illustration	Age	Foreign Body	Location	Anæsthetic	Tube	Problem	Forceps	Point of Seizure	Result	Time	Route	Remarks
No. 411 Fig. 64	17 mo.	Fish bone	Right main bronchus	None	5 mm.	None	Straight	As presented	Extraction Cure	4 min.	Oral	Localized bronchitis, severe in degree (Fig. 1, Plate 2).
No. 612 Fig. 65	Adult	Fish bone	Left ventricle overhanging glottis	None	Laryngoscope	None	Alligator	As presented (crosswise)	Extraction Cure	1 min.	Oral	Slight localized congestion
No. 609 Fig. 66	25 yrs.	Fish bone	Œsophagus above hiatus, 8 days	None	10 mm.	Point upward and embedded	Side-curved	Near point	Extraction Cure	1 min. 12 sec.	Oral	Inflammatory swelling around puncture in which point of bone was embedded; stream of blood issuing around embedded point.

SEEDS, NUTS, SHELLS, ETC.

No. 374 Fig. 67	2 yrs.	Peanut kernel	Trachea, 13 days	None	4 mm.	Crosswise position; extreme dyspnœa	Straight	Flatwise after turning	Extraction Cure	18 sec.	Oral	Intense tracheobronchitis simulating diphtheria; antitoxin given.

No. 380 Fig. 68	18 mo.	Peanut kernel	Right bronchus, 11 days	None	4 mm.	Fragile	Straight	As presented	Extraction	32 sec.	Oral	Intense tracheobronchitis; pertussis along with other children of family two weeks after leaving hospital; died of "broncho-pneumonia."
No. 402 Fig. 69	3½ yrs.	Peanut kernel	Left stem bronchus, 23 days	None	5 mm.	Fragile	Straight	As presented	Extraction Cure	6 min. 12 sec.		Diffuse severe tracheobronchitis; "drowned lung" over lower lobe showed in radiograph.
No. 439B Fig. 70	6 yrs.	Peanut kernel	Right main bronchus at upper lobe bronchus	None	5 mm.	Fragile	Straight	End; flatwise	Extraction Cure	3 min.	Oral	Intense diffuse bronchitis (Fig. 15, Plate I).
No. 445 Fig. 71	2 yrs.	Peanut kernel	Left main bronchus, 24 days	None	5 mm.	Fragile	Straight	As presented	Extraction Cure	2 min.	Oral	Diffuse bronchitis both sides; pink pus.
No. 573 Fig. 72	5 yrs.	Peanut kernel	Right inferior lobe branches, 3 pieces, 11 days	None	5 mm.	3 fragments in different localities	Straight	As presented	Extraction Cure	9 min. 20 sec.	Oral	Diffuse tracheobronchitis; not severe; muco pus.

SEEDS, NUTS, SHELLS, ETC.—*Continued*

Case Number and Illustration	Age	Foreign Body	Location	Anæsthetic	Tube	Problem	Forceps	Point of Seizure	Result	Time	Route	Remarks
No. 584 Fig. 73	5 yrs.	Peanut kernel	Middle lobe bronchus and branch inferior lobe bronchus, 4 weeks	None	5 mm.	Fragments different location	Straight	As presented	Extraction Cure	17 min.	Oral	Diffuse bronchitis; much pus mixed with some mucus; exudate in patches (Fig. 16, Plate I).
No. 604 Fig. 74	2½ yrs.	Peanut kernel	Right main bronchus at orifice of upper lobe bronchus	None	5 mm.	Proximal annular œdema	Straight	As presented	Extraction Cure	2 min. 19 sec.	Oral	Diffuse tracheobronchitis; rings of trachea obliterated by swellings; pus coming from all branches on right.
No. 444 Fig. 75	8 yrs.	Peanut shell (Greek pistachio)	Left inferior lobe bronchus orifice post branch, 25 days	None	7 mm.	Turning to present edge; fragile	Straight	Flatwise after turning	Extraction Cure	12 min. 32 sec.	Oral	Bronchitis limited to left side; no granulations; pus welled up from drowned lung when foreign body disimpacted.
No. 425  Fig. 76	15 mo.	Walnut kernel	Right upper lobe bronchus, 3 days	None	4 mm.	Around the corner	Side-curved	As presented	Extraction Cure	2 min.	Oral	Severe diffuse bronchitis both lungs; thick mucopus (Fig. 4, Plate II).

No. 570 Fig. 77	70 yrs.	Peachstone	Œsophagus below cricopharyngeus, 6 hours	None	Laryngo-scope	Seizure; tight impaction	Alligator rotation	Presenting end	Extraction Cure	1 min. 5 sec.	Oral	Slight congestion; fruit pulp attached.
No. 595 Fig. 78	28 yrs.	Bayleaf	Larynx, few minutes	None	Kirstein's autoscope	None	Alligator	Flatwise	Extraction Cure		Oral	
No. 429 Fig. 79	2 yrs.	Coffee berry, unroasted	Right stem bronchus, 1 day	None	5 mm.	Tightly jammed from previous bronchoscopy	Straight	Flatwise on end	Extraction Cure	6 min.	Oral	Intense tracheobronchitis probably from prolonged bronchoscopy under general anæsthesia before admission.
No. 431 Fig. 80	2 yrs.	Cockle burr	Larynx, 3 days	None	Laryngo scope	None	Alligator	Across middle	Extraction Cure	14 sec.	Oral	Moderate laryngitis (Fig. 17, Plate II).
No. 368 Fig. 81	3 yrs.	Maize	Right stem bronchus, 2 days	None	5 mm.	Tight impaction	Straight	Flatwise	Extraction Cure	1 min. 7 sec.	Oral	Traumatic bronchitis from two bronchoscopic attempts before admission; no reaction in left bronchi.

SEEDS, NUTS, SHELLS, ETC.—*Continued*

Case Number and Illustration	Age	Foreign Body	Location	Anæsthetic	Tube	Problem	Forceps	Point of Seizure	Result	Time	Route	Remarks
No. 584 Fig. 73	5 yrs.	Peanut kernel	Middle lobe bronchus and branch inferior lobe bronchus, 4 weeks	None	5 mm.	Fragments different location	Straight	As presented	Extraction Cure	17 min.	Oral	Diffuse bronchitis; much pus mixed with some mucus; exudate in patches (Fig. 16, Plate I).
No. 604	2½ yrs.	Peanut kernel	Right main bronchus at orifice of upper lobe bronchus	None	5 mm.	Proximal annular œdema	Straight	As presented	Extraction Cure	2 min. 19 sec.	Oral	Diffuse tracheobronchitis; rings of trachea obliterated by swellings; pus coming from all branches on right.
		[illegible] shell	Left inferior lobe bronchus orifice post branch, 25 days	None	7 mm.	Turning to present edge; fragile	Straight	Flatwise after turning	Extraction Cure	12 min. 32 sec.	Oral	Bronchitis limited to left side; no granulations; pus welled up from drowned lung when foreign body disimpacted.
					4 mm.	Around the corner	Side-curved	As presented	Extraction Cure	2 min.	Oral	Severe diffuse bronchitis both lungs; thick mucopus (Fig. 4, Plate II).

			Œsophagus below pricopharyngeus, 6 hours	None	Laryngo scope	Seizure; tight impaction	Alligator rotation	Presenting end	Extraction Cure	1 min 4 sec	Oral	Slight congestion; fruit pulp attached	
Fig. 90													
No. 420	8 mo.	W... seed											
Fig. 91													
No. 563	14 mo.	Watermelon seed	Right stem bronchus, 5 days	None									
Fig. 92													
No. 371	8 mo.	Eggshell	Larynx, 3 days	None	Laryngo-scope	Fragility	Alligator	Flatwise	Cure				
Fig. 93													

SEEDS, NUTS, SHELLS, ETC.—*Continued*

Case Number and Illustration	Age	Foreign Body	Location	Anæsthetic	Tube	Problem	Forceps	Point of Seizure	Result	Time	Route	Remarks
No. 381 Fig. 82	6 yrs.	Maize	Right main bronchus at orifice upper lobe bronchus; 7 days	None	7 mm.	Tight impaction; abundant secretion	Straight	Flatwise	Extraction Cure	2 min.	Oral	Right-sided bronchitis; pus largely admixed with mucus.
No. 404 Fig. 83	3 yrs.	Maize	Trachea, 4 days	None	5 mm.	None	Straight	Flatwise	Extraction Cure	63 sec.	Oral	Diffuse tracheitis, not severe.
No. 414 Fig. 84	3 yrs.	Maize	Trachea, 4 days	None	5 mm.	Crosswise; macerated; dyspnœa	Straight	Flatwise	Extraction Cure	1 min. 4 sec.	Oral	Diffuse tracheitis, not severe.
No. 446 Fig. 85	5 yrs.	Maize (popped corn) hull	Left main bronchus, 5 days	None	5 mm.	Finding			Coughed out through bronchoscope		Oral	Diffuse bronchitis, worse left.
No. 579 Fig. 86	5 yrs.	Maize	Right bronchus, 2 days	None	5 mm.	None	Straight	Flatwise	Extraction Cure	2 min. 54 sec.	Oral	Moderate diffuse tracheobronchitis.
No. 375 Fig. 87	4 yrs.	Watermelon seed	Trachea, 15 days	None	5 mm.	Dyspnœa from sidewise position	Straight	Flatwise after turning	Extraction Cure	19 sec.	Oral	Reaction only a slight localized tracheitis.

No. 376 Fig. 88	1 yr.	Watermelon seed	Left stem bronchus, 6 days; pushed down	None	5 mm.	Jammed tightly from pursuit by previous bronchoscopist; œdema	Straight	Flatwise	Extraction Died	28 sec.	Oral	Septic traumatic bronchitis from 3 bronchoscopic efforts with claw forceps before admission.
No. 379 Fig. 89	2 yrs.	Watermelon seed	Bifurcation, 13 days	None	4 mm.	Somewhat crosswise	Straight	Flatwise after turning	Extraction Cure	34 sec.	Oral	Only slight local inflammation.
No. 417 Fig. 90	21 mo.	Watermelon seed	Right upper lobe bronchus, 11 hours	None	4 mm.	None	Straight	Flatwise	Extraction Cure	1 min. 5 sec.	Oral	Localized bronchitis.
No. 420 Fig. 91	8 mo.	Watermelon seed	Trachea, 16 hours	None	4 mm.	None	Straight	Flatwise	Extraction Cure	1 min. 15 sec.	Oral	Localized tracheitis.
No. 563 Fig. 92	14 mo.	Watermelon seed	Right stem bronchus, 5 days	None	5 mm.	None	Side-curved	Flatwise	Extraction Cure	2 min. 16 sec.	Oral	Localized bronchitis.
No. 371 Fig. 93	8 mo.	Eggshell	Larynx, 3 days	None	Laryngoscope	Fragility	Alligator	Flatwise	Extraction Cure	9 sec.	Oral	Œdema due to parent's finger-nail efforts at removal.
No. 419 Fig. 94	1 yr.	Eggshell	Larynx, 9 days	None	Larygnoscope	Fragility	Alligator	Flatwise	Extraction Cure	12 sec.	Oral	Pus in trachea; probably escape prevented by interference with glottic aid.

COINS AND OTHER DISKS

Case Number and Illustration	Age	Foreign Body	Location	Anæsthetic	Tube	Problem	Forceps	Point of Seizure	Result	Time	Route	Remarks
No. 418 Fig. 95	2½ yrs.	Brass disk (Beer check)	Œsophagus below cricopharyngeus	None	7 mm. œsophagoscope	None	Side-curved	Flatwise	Extraction Cure	14 sec.	Oral	Slight congestion at point of lodgement.
No. 373  Fig. 95a	3 yrs.	Coin (quarter)	Œsophagus below cricopharyngeus, 4 days	None	7 mm.	None	Side-curved	Flatwise	Extraction Cure	18 sec.	Oral	Food accumulated; mild œsophagitis.
No. 378 Fig. 96	17 mo.	Coin (penny)	Œsophagus below cricopharyngeus, 7 days	None	Laryngoscope	None	Alligator	Flatwise	Extraction Cure	11 sec.	Oral	Food accumulated; œsophagitis probably from stagnation. T. 101.
No. 388 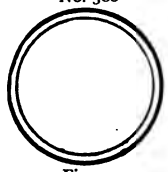 Fig. 97	3½ yrs.	Coin (nickel)	Œsophagus below cricopharyngeus, 8 days	None	Œsophageal speculum	None	Alligator	Flatwise	Extraction Cure	2 sec.	Oral	Sloughing œsophagitis from œsophagoscopies before admission. Central vertical zone of coin stained yellowish, as in Fig. 103.
No. 393 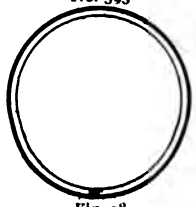 Fig. 98	2½ yrs.	Coin (quarter)	Œsophagus below cricopharyngeus, 2 days	None	7 mm.	None	Straight	Flatwise	Extraction Cure	1¼ sec.	Oral	Mucosa normal.

No. 413  Fig. 99	2½ yrs.	Coin (penny)	Œsophagus, 3 months	None	7 mm.	None	Straight	Flatwise	Extraction Cure	57 sec.		Coin embedded in granulations below constriction; localized œsophagitis.
No. 426  Fig. 100	5 yrs.	Coin (nickel)	Œsophagus below cricopharyngeus, 24 hours	None	7 mm.	None	Straight	Flatwise	Extraction	11½ sec.	Oral	No inflammation; no congestion.
No. 435 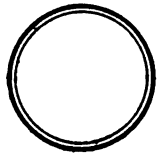 Fig. 101	15 mo.	Coin (penny)	Œsophagus below cricopharyngeus, 7 days	None	Laryngoscope	None	Alligator	Flatwise	Extraction Cure	19 sec.	Oral	No inflammation; slight congestion.
No. 438 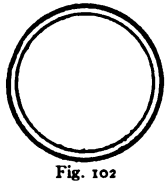 Fig. 102	3½ yrs.	Coin (nickel)	Œsophagus below cricopharyngeus	None	7 mm.	None	Straight	Flatwise	Extraction Cure	30 sec.	Oral	No inflammation; slight congestion.
No. 439 Fig. 103	3 yrs. 2 mo.	Coin (nickel)	Œsophagus, 5½ hours	None	7 mm.		Straight	Flatwise	Extraction Cure	13 min. 53 sec.	Oral	Central vertical zone of coin stained yellowish.

COINS AND OTHER DISKS—*Continued*

Case Number and Illustration	Age	Foreign Body	Location	Anæsthetic	Tube	Problem	Forceps	Point of Seizure	Result	Time	Route	Remarks
No. 441  Fig. 104	15 mo.	Coin (penny)	Œsophagus below cricopharyngeus, 12 days.	None	7 mm.	None	Straight	Flatwise	Extraction Cure	28 sec.	Oral	Slight localized œsophagitis.
No. 442  Fig. 105	3 yrs.	Coin (nickel)	Œsophagus below cricopharyngeus, 4 days.	None	7 mm.	None	Side-curved	Flatwise	Extraction Cure	½ min. (approx.)	Oral	No inflammation; slight congestion.
No. 556  Fig. 106	13 yrs.	Coin (half-dollar)	Œsophagus below cricopharyngeus, 3 hours	None	7 mm.	None	Straight	Flatwise	Extraction Cure	1 min. 19 sec.	Oral	Mucosa apparently normal.
No. 559  Fig. 107	4½ yrs.	Coin (British halfpenny)	Œsophagus above bronchial crossing	None	7 mm.	None	Side-curved	Flatwise	Extraction Cure	50 sec. (second œsophagoscopy)	Oral	Granulations, fibrous narrowing; swollen folds; coin much corroded (Fig. 26, Plate II).

No. 575  Fig. 108	3 yrs.	Coin (nickel)	Œsophagus below cricopharyngeus, 9 days	None	7 mm.	None	Straight	Flatwise	Extraction Cure	2 min. 30 sec.	Oral	Embedded below fold of swollen mucosa; local œsophagitis and erosion, possibly from stagnation of food.
No. 585 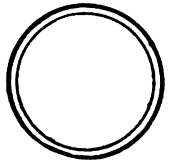 Fig. 109	18 mo.	Coin (nickel)	Œsophagus below cricopharyngeus, 15 days	None	7 mm.	Obscured by food, granulations and exudate	Side-curved	Flatwise	Extraction Cure	2 min. 17½ sec.	Oral	Foul food; localized œsophagitis, exudate, beginning granulations.
No. 602 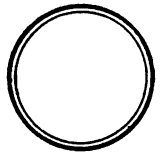 Fig. 110	22 mo.	Coin (penny)	Œsophagus below cricopharyngeus, 5 weeks	None	7 mm.	None	Straight	Flatwise	Extraction Cure	19 sec.	Oral	Foul, sloughing œsophagitis due to œsophagoscopy before admission, masking all appearance of pre-existing lesion if any.
No. 603 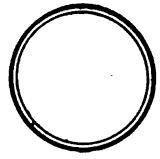 Fig. 111	2 yrs.	Coin (penny)	Œsophagus below cricopharyngeus, 4 days	None	7 mm.	None	Side-curved	Flatwise	Extraction Cure	44 sec.	Oral	Slight congestion.
No. 606 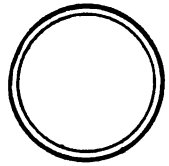 Fig. 112	2 yrs. 9 mo.	Coin (nickel)	Œsophagus below cricopharyngeus, 6 days	None	7 mm.	None	Straight	Flatwise	Extraction Cure	23 sec.	Oral	Œsophageal mucosa apparently normal.

COINS AND OTHER DISKS—*Continued*

Case Number and Illustration	Age	Foreign Body	Location	Anæsthetic	Tube	Problem	Forceps	Point of Seizure	Result	Time	Route	Remarks
No. 607  Fig. 113	16 mo.	Coin (penny)	Œsophagus below cricopharyngeus, ? days	None	7 mm.	None	Straight	Flatwise	Extraction Cure	19 sec.	Oral	Mucosa apparently normal.
No. 620  Fig. 114	7 mo.	Coin (penny)	Œsophagus below cricopharyngeus, 5 days	None	7 mm.	None	Side-curved	Flatwise	Extraction Cure	44 sec.	Oral	Mucosa apparently normal; thymic compression of trachea and œsophagus
No. 627 Fig. 115	6 yrs.	Coin (quarter)	Œsophagus below cricopharyngeus, 8 days	None	7 mm.	None	Straight	Flatwise	Extraction Cure	23 sec.	Oral	Œsophagus lacerated and covered with shred-like sloughs from "coin-catcher" used before admission.
No. 628 Fig. 116	12 yrs.	Coin (half-dollar)	Œsophagus below cricopharyngeus	None	7 mm.	None	Straight	Flatwise	Extraction Cure	5 min. 44 sec.	Oral	Mucosa normal; coin corroded and blackened in vertical central zone (Fig. 20, Plate II).

No. 416 Fig. 117	15 mo.	Lead skirt-weight	Œsophagus below cricopharyngeus, 19 hours	None	Esoph. speculum	None	Alligator	Flatwise	Extraction Cure	15½ sec.	Oral	No œsophagitis; no congestion.
No. 427 Fig. 118	6 yrs.	Poker chip	Œsophagus below cricopharyngeus, 24 hours	None	7 mm.	None	Straight	Flatwise	Extraction Cure	11 sec.	Oral	Mucosa normal.

MEAT

No. 571 Fig. 119	57 yrs.	Meat (veal)	Above cricopharyngeus, 24 hours	None	Laryngoscope	Pultaceous consistency	Mechanical spoon, alligator form	Scooped out, not seized	Extraction Cure	3 min. 37 sec.	Oral	Goitrous compression stenosis; meat putrid; mucosa locally congested.

BUTTONS

Case Number and Illustration	Age	Foreign Body	Location	Anæsthetic	Tube	Problem	Forceps	Point of Seizure	Result	Time	Route	Remarks
No. 567 Fig. 120	4 yrs.	Button, pearlshell	Œsophagus below cricopharyngeus, 5 days	None	7 mm.	None	Side-curved	Flatwise	Extraction Cure	30 sec.	Oral	Œsophageal mucosa apparently normal at site of button; lower œsophagus lacerated by œsophagoscopy before admission.
No. 630 Fig. 121	12 yrs.	Shoe button	Left inferior lobe bronchus	None	7 mm.	Rounded top presenting below stricture	Side-curved	Edgewise after version	Extraction Cure	8 min. 19 sec.	Oral	Proximal annular swelling; granulations; pus (Fig. 22, Plate II).

MINERALS

No. 624 Fig. 122	4 yrs.	Pebble	Right main bronchus	None	5 mm.	Large, smooth hard, rounded body; annular proximal œdema	Straight	As presented	Extraction Cure	3 min. 15 sec.	Oral	Œdema; slight inflammation, localized (Fig. 25, Plate I).

DENTAL AND SURGICAL OBJECTS

No. 387b Fig. 123	39 yrs.	Dental instrument	Right inferior lobe bronchus, 7 days	Local	7 mm.	Finding in small peripheral bronchus	Straight	Point	Extraction Cure	32 sec.	Oral	Slight local congestion.

No. 552 Fig. 124	30 yrs.	Dental instrument	Left upper lobe bronchus, 3 months	Local	9 mm.	Disengaging buried point	Side-curved	Near point	Extraction Cure	1 min. 50 sec.	Oral	Areolar inflammation; patch of purulent exudate (Fig. 11, Plate I).
No. 625 Fig. 125	21 yrs.	Dental instrument	Right middle lobe bronchus, 2 days	Local	9 mm.	Point embedded	Side-curved	Near point	Extraction Cure	2 min. 10 sec.	Oral	Small faint areola at point of puncture (Fig. 6, Plate I).
No. 574 Fig. 126	26 yrs.	Tooth filling amalgam	Left bronchus, 2 weeks	Local	7 mm.	Tight impaction; proximal annular œdema	Side-curved	As presented	Extraction Cure	7 min. 54 sec.	Oral	Proximal annular œdema and tight impaction probably due to shape, specific gravity and air absorption below; localized bronchitis; pus below foreign body (Fig. 18, Plate I).

UTENSILS

Case Number and Illustration	Age	Foreign Body	Location	Anæsthetic	Tube	Problem	Forceps	Point of Seizure	Result	Time	Route	Remarks
No. 434 Fig. 127	57 yrs.	Tinned wire from egg beater	Œsophagus	None	9 mm.	None	Side-curved	Both points after pressing together	Extraction Cure	4 min. 2 sec.	Oral	Inflammatory areola around each embedded point (Fig. 24, Plate II).

TOYS

No. 583 Fig. 128	2 yrs.	Eye of "Teddy Bear" (part)	Right stem bronchus. 4 days	None	5 mm.	Slippery; conoidal	Plain	End	Extraction Cure	5 min. 15 sec.	Oral	Pus coming up around foreign body; localized bronchitis; left bronchi normal (Fig. 6, Plate II).
No. 432 Fig. 129	4 yrs.	Lead alloy "horse"	Larynx, 1 month	None	Laryngo-scope	None	Alligator	Flatwise	Extraction Cure	56 sec.	Oral	Larynx swollen almost shut; granulations; ulceration.

No. 560 Fig. 130	8 yrs.	Wooden whistle; bit rubber	Left main bronchus, 3 days	None	7 mm.	Only central hole visible	Expanding	Periphery of hole	Extraction Cure	8 min.	Oral	Severe inflammation in neighborhood of bit of rubber (Fig. 18, Plate II).
No. 558 Fig. 131	2 yrs. (about)	Jack (castiron)	Œsophagus below cricopharyngeus, 1½ months	None	7 mm.	Buried in granulation tissue	Straight for granulations	Escaped downward	Passed by bowel	15 min.	Passed by rectum	Two weeks in municipal hospital for supposed diphtheria; severe œsophagitis; granulations; foul ulceration; cervical cellulitis; double pneumonia; septic arthritis; condition unimproved after œsophagoscopy; died (Fig. 23, Plate II).
No. 578 Fig. 132	3½ yrs.	Pearl shell ring	Œsophagus at bronchial crossing, 1 year	None	7 mm.	Buried in granulation tissue and swollen folds	Straight	Flatwise	Extraction Cure	52 sec. (2nd esoph)	Oral	Localized chronic œsophagitis; ulceration; granulations; swollen folds; foreign body fixed in pocket of inflammatory tissue (Fig. 16, Plate II).

WOOL AND COTTON

Case Number and Illustration	Age	Foreign Body	Location	Anæsthetic	Tube	Problem	Forceps	Point of Seizure	Result	Time	Route	Remarks
No. 590 590 Fig. 133	9 mo.	Cotton, fragment of button, (vegetable ivory) cherry pit, wool	Œsophagus (middle third)	None	7 mm.	None	Straight	As presented	Extraction Cure		Oral	Mild localized œsophagitis; no erosion; wool had stale, cheesy odor, not foul; length of sojourn unknown; food had been milk only (Fig. 29, Plate II).

RUBBER

No. 622 Fig. 134	36 yrs.	Rubber eraser	Right bronchus, 7 months									Rubber removed post-mortem; patient moribund when admitted; autopsy; both lungs gangrenous, consolidated and filled with multiple abscesses (Fig. 9, Plate II).
No. 629 Fig. 135	16 mo.	Rubber gasket catsup bottle	Œsophagus (middle third)	None	7 mm.	None	Straight	Flatwise	Extraction Cure	13 sec.	Oral	Œsophagitis.

BLOOD TRANSFUSION[1]

By J. de J. PEMBERTON, M.D., Rochester, Minnesota
From the Mayo Clinic

THE history of the development of the operation for the transfusion of blood is an interesting record of alternate triumph and failure. History is replete with evidence that from early time man's imagination has been stirred by the possibility of restoring health, vigor, and even youth to the aged and infirm by replacing blood of the young and healthy. Stimulated by the wonderful possibilities offered, there has been no dearth of investigators, but insurmountable difficulties prevented the operation from being placed upon a practical basis until recent years. As expressed by an early English writer, "Transfusion is a sort of Will-o'-the-wisp of science, holding out the most brilliant prospects, which never seem to be realized."

In the medical literature on the subject are many references to the report that in an attempt to save the life of Pope Innocent VIII in 1492, he was transfused by a Jewish physician. No description of the method employed is given, but it is recorded that blood from the Pope was first allowed to run into the vein of a youth, whose blood was transferred into the vein of the old man. The lives of three youths were sacrificed in this manner without benefit to the Pope. This is flatly denied in A. H. Matthews' *Life and Times of Rodrigo Borgia*. In speaking of the Pope's death he says: "It is related that, during his last illness, the operation for transfusion of blood was unsuccessfully performed. This, however, is an error, arising from two important facts: first that the idea of this operation could not occur to any one to whom the circulation of the blood was unknown, and second, that the phenomenon of the circulation of the blood was not discovered until the seventeenth century. Raynaldus and Infessura say that a certain Jewish physician undertook to restore the Pope's health. For this purpose he drew all the blood out of three young boys, who immediately died. With their blood he prepared a draught which failed to improve the sick pontiff's condition. The saving virtue of drinking human blood was no new idea."

In 1616, in lectures at the College of Physicians, William Harvey first presented a detailed exposition of his views concerning the circulation of the blood, but it was not until 1628 that he gave his views to the world at large in his celebrated treatise on *Motion of the Heart and Blood*.

Mentions are made of transfusions performed by an Italian physician, Franscesco Folli, in 1654, and by Daniel, of Leipzig, in 1664, but in the writings of most recorders, the names of Richard Lower, of England, and Jean Denys, of France, stand out conspicuously as pioneers, the former as the first to practice blood transfusion experimentally, and the latter the first to perform transfusion in man.

Lower began his experimental work in 1665, transfusing successfully by anastomosing by means of a cannula or pipe the artery of one animal into the vein of another. In 1667, Denys successfully transfused a man, using the blood of a lamb. About the same time, King in England, Immerets in France, and Riva and Manfredi in Italy, practiced transfusion from animal to animal and from animal to man.

It is evident that the new procedure was warmly received by the profession and eagerly put into practice. Deaths resulted and the operation was condemned in France by the Supreme Court interdicting its practice until the Faculté of Paris should give its approval. This was not obtained and for more than a century the practice of blood transfusion was forsaken.

In England, in 1818, the experiments of Blundell revived the interest of the profession. He devised an apparatus consisting of a syringe connected by a two-way stop-cock to a receptacle, and to a tube in turn connected with a cannula for insertion into the vein of the recipient (Fig. 1). He credits Goodridge as

[1]Thesis submitted to the Graduate Faculty of the University of Minnesota in partial fulfillment of the requirements for the degree of Master of Science in Surgery, June, 1918.

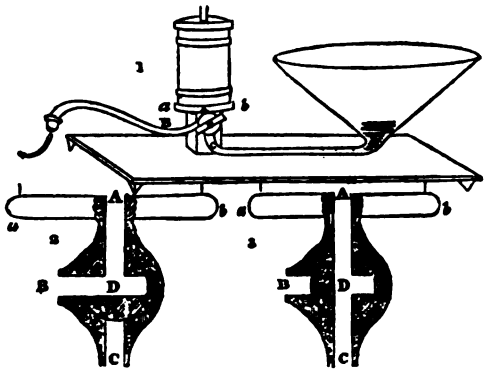

Fig. 1. Transfusion apparatus (taken from Blundell).

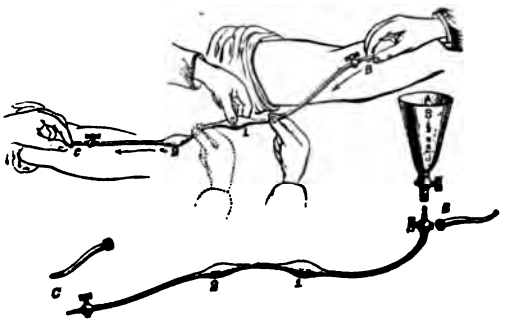

Fig. 2. Transfusion apparatus (taken from Fryer).

having employed the syringe method previous to this. Blundell exposed the femoral artery and vein of a dog and introduced a pipe into each. The blood was allowed to flow from the artery into the cup and was then reinjected into the vein by means of a syringe. This was continued for a period or twenty-four hours, about twelve pints of blood, in all, being reinjected. The dog lived. Later he transfused women suffering from loss of blood due to childbirth, employing human blood, and it is recorded that three out of seven attempts were successful.

In 1835, Bischoff introduced the idea of injecting defibrinated blood, and this method became popular with a large group of workers, among whom were included Prevost, Panum, Dieffenbach and Brown-Sequard. While it was pointed out by Koehler, in 1877, that this form of transfusion was fraught with danger owing to the excess of fibrin ferment injected, and its use was discouraged by Landois, Gesellius, Ponfick, and others, it was used throughout the nineteenth century although with somewhat abated enthusiasm, and in fact was quite extensively employed during the first decade of this century, until it was replaced by the simple methods of today. During this period other methods were devised. Higginson and Aveling used two cannulas attached by tubing to a bulb syringe. Gesellius and Leisrink, in 1872, employed a glass cannula and Landois, in 1875 transfused directly from vein to vein, employing cannulas and tubing. Phosphate of soda (Braxton Hicks) and minute quantities of ammonia (Richardson) were advocated as anticoagulants.

Transfusion became an established procedure the latter part of the nineteenth century and was practiced with a considerable degree of frequency. The success attending the operation was at times brilliant, but reactions described as oppressed breathing, choking, and a train of other more or less serious symptoms met during transfusion, were likely to be attributed to the accidental entrance of air into the vein, although, as early as 1818, Blundell showed experimentally



Fig. 3. The complete Soresi instrument; the figure on the right shows how the instrument opens on a hinge (taken from Soresi).

Fig. 4. Showing how the blood-vessel is cuffed over the hooks while blood is still flowing in it; the dotted line shows where the vessel must be cut (taken from Soresi).

Fig. 5. A simple arteriovenous anastomosis (according to Hull).

that the admission into the veins of a small amount of air did not produce any serious effect on the animal. Oré showed that a large quantity of air allowed to enter the veins resulted in death, but minute quantities, as might accidentally get into them, produced no ill effects. This was also observed by Loewenthal in 1871. In the light of our present knowledge, it is certain that many of these reactions were the result of incompatible bloods.

Professor Martin, of Berlin, in 1859, published reports of 57 cases in which transfusion was done in obstetrical practice. There were successful results in 43. Blasius, in 1863, collected all the cases for forty years previous and recorded 116, 56 of which were successful. It is interesting to note that 14 of these in which undefibrinated blood was used, all proved unsuccessful. In the main, clinical indications for transfusion were then recognized similar to those which are observed today. Leisrink in 1872 says: "Transfusion is indicated in all those pathological conditions where the blood, in quantity and quality, is so altered that it is unfit to fulfill its physiological duties." Fryer, who apparently was among the first in this country to employ transfusion, and who used a modified Aveling apparatus, consisting of tube, bulb, and cannulas, recommended its use in asthenic patients before and after necessary surgical measures in order to avert pyæmia, and its allied evils, especially in operations in which the peritoneum is involved (Fig. 2). Dumas and Prevost and Landois pointed out the injurious effects of transfusing the bloods of dissimilar species. Brunton, Hueter and Gesellius, in 1870 to 1873, advocated its use in case of monoxid poisoning, and reported successfully treated cases. Judging from the frequent warning against its use in bleeding cases, except after the bleeding point had been checked, it is evident that its hæmostatic effect was not recognized.

Buchser in 1869 reports a case of a young woman, almost exsanguinated from bleeding from the vagina and bladder following convalescence from typhus, who was transfused with three ounces of blood from her husband by letting the blood run into a warmed receptacle and then injecting it with a syringe into the recipient, which resulted in cessation of the bleeding. Smith, in 1873, reported the case of a child, aged 8 years, with purpura, who had bled from the nose until practically exsanguinated and was then transfused by means of syringe and cannula, defibrinated blood being employed. The result was excellent. No mention was made of the idea of hæmostasis, and it is apparent that the transfusion was employed solely with the view of replacing lost blood. Its value following hæmorrhage was early appreciated. Hicks attributes its want of success in these cases to the postponement of the operation until too late. He recognized that patients who had suddenly lost a large amount of blood were less likely to respond than those whose exsanguination had been protracted.

Autotransfusion by the application of Esmarch bandages to the extremities was advocated by Lesser in 1875.

In 1875, with the introduction of normal saline solution for intravenous therapy, there again followed a period of about thirty years in which there was a very noticeable decline in the enthusiasm for, and employment of, blood transfusion. Because of the technical difficulties met in the successful employment

of the technique in use at that time, and because, also, of the varied results achieved owing, doubtless, to the want of the proper understanding of iso-agglutination and iso-hæmolysis, saline infusion was quickly adopted as a substitute. Prior to this, in 1850, Hodder, in Canada, reported cases of cholera treated successfully by the intravenous injection of fresh cow's milk, and Brinton, lecturer at the Jefferson Medical College in 1878, basing his opinion on the reports of Hodder, Thomas and others, advocated the injection of milk in place of blood transfusion. He concluded that it was feasible and safe, that it was easier than blood transfusion, that it was commonly followed by chills, that the dosage should not be over 8 ounces, and that its practice should not be limited to cases prostrated from the loss of blood, but should be employed in disorders which greatly depreciate the blood, as in cholera, pernicious anæmia, typhoid fever, and others.

While the operation made rapid advances during the nineteenth century, there were two important factors which greatly impeded its progress, that is, the tendency for the rapid clotting of blood during its transference from the donor to the recipient, and the occurrence of hæmolysis resulting from the employment of incompatible bloods. To overcome the first of these, ingenious apparatus for the rapid transference of the blood were devised, defibrinated blood was employed, and attempts were made to delay the coagulation by the addition of chemicals. These were only partially successful. During this time, knowledge of iso-agglutination and iso-hæmolysis was lacking, although its clinical occurrence was seen often and repeatedly described in reports, but the symptoms resulting were attributed to the introduction of air into the veins.

Early after the advent of the present century, rapid progress was made in meeting and overcoming the two chief dangers associated with blood transfusion. Landsteiner and Shattuck independently reported the presence of iso-agglutinins and Landsteiner, in 1901, divided human beings into three groups according to the agglutinating reactions of their bloods. In 1907, Jansky proved that

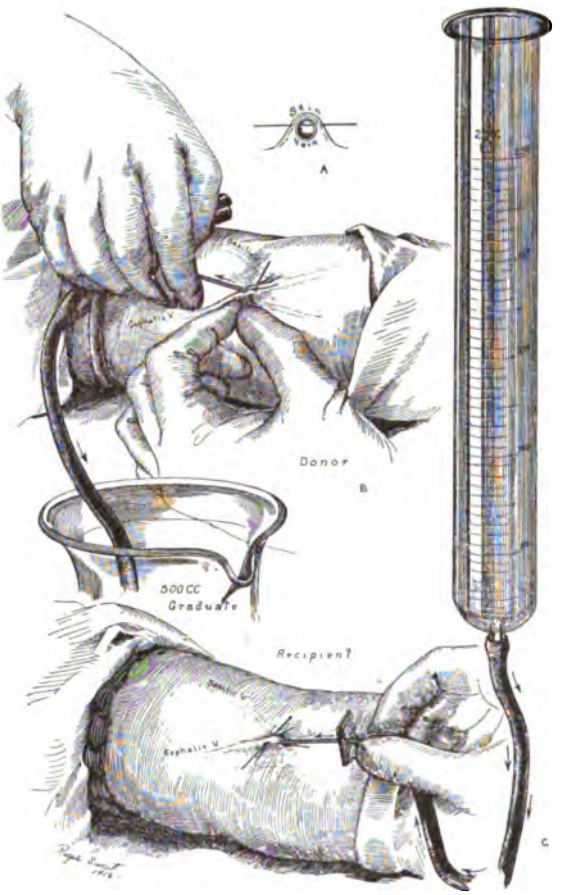

Fig. 6. *A*. Cross-section of vein transfixed in its upper segment to skin by a straight intestinal needle. *B*. Introducing Kaliski cannula into the cephalic vein of the donor. The vein is steadied and prevented from rolling from under the cannula by means of slight traction exerted upon the transfixing needle. *C*. Cannula introduced in vein of recipient.

human beings fall into four groups and this was later confirmed by Moss who made the important observation that hæmolysis of the red blood cells never occurs without their previous agglutination. The tests for the group determination were simplified by Brem, Sanford, and others.

Great strides in blood-vessel surgery were being made at this time, notably by the work of Murphy, in 1897, Doerfler in 1899, Carrel and Guthrie, Crile and others, and this lent impetus to the development of more certain methods of transferring blood.

The first permanent suture of blood-vessels

was made by Eck, a Russian, in 1879, when he established a lateral anastomosis between the portal vein and the inferior vena cava. Murphy, in 1897, successfully anastomosed in men the divided femoral artery by invaginating the proximal into the distal end. Carrel and Guthrie, by the most painstaking details, perfected blood-vessel suture. While Nitze, in 1897, and Payr, in 1900, made successful vessel anastomoses by means of ivory clamps and magnesium rings, respectively, it remained for Crile, the real pioneer in modern blood transfusion, to perfect a method of anastomosing vessels, intima to intima, by the employment of a cleverly devised cannula. He put the method in practice experimentally and in clinical research, reporting 225 experimental and 32 clinical transfusions, at first anastomosing artery to vein, later showing that transfusion could be successfully and readily accomplished by vein to vein anastomosis.

Stimulated by this work, the profession began to realize more clearly than ever the really enormous therapeutic value offered by blood transfusion, and there followed in rapid succession the publication of numerous articles describing "new and simple" methods for transferring blood, and advocating wider fields of application. In 1909, Brewer and Leggett, after successfully experimenting on 31 animals, advocated transfusion by the interpolation between the artery and vein of a paraffin-coated glass tube. In the same year, Frank and Baehr, transfused by means of a vascular bridge or link made of a dog's carotid and preserved in 2 per cent formalin, to connect the artery to the vein. The Lespinasse and other modifications followed.

Ingenious modifications of the Crile cannula were devised by Buerger, Soresi, Janeway, McGrath, and others (Figs. 3 and 4).

Hull has described a method of arteriovenous anastomosis which, for its simplicity and sureness of accomplishment, should commend itself to those who may have occasion to perform an emergency transfusion, when anticoagulants and the ordinary apparatus are not to be obtained. The donor's radial artery is exposed and divided, and compression is made on its proximal end to prevent flowing. The recipient's vein is exposed for a distance of one inch and a small slit is made in it, large enough to admit the artery, which is carried into it by means of a needle and suture (Fig. 5). Mann has reported its successful application in experimenting with the method in the laboratory.

The use of any of these methods necessitated the sacrifice by the donor of either an artery or a vein, and with every donation he subjected himself to considerable risk. In addition it was impossible accurately to determine the amount of blood transfused, estimates being based upon blood pressure and hæmoglobin readings. Curtis and David overcame the last objection by employing a receptacle for the blood and then re-injecting. Their apparatus consisted of a glass bulb, paraffin coated, with two cannula tips at one end and, attached to the other end by means of rubber tubing, a syringe. This idea was modified by Kimpton and Brown, Percy, and Satterlee and Hooker, and it resulted in the perfection of a method of transfusion which under favorable circumstances, is ideal. The one essential objection lies in the difficulty in the coating of the tube and connections with a uniform layer of paraffin. Any error in this means failure.

In 1892, von Ziemssen devised and employed successfully a method of transfusion by means of syringes and cannulas: "By rapid work he was able to draw 20 cubic centimeters of blood from a subcutaneous venous puncture, disconnect the syringe, and empty it through a needle similarly placed in the recipient's vein before coagulation took place. By filling the syringes one after another he transfused 280 cubic centimeters at one time." The method did not receive the attention it deserved and was soon forgotten. In 1913, Lindeman improved the technique by adding a larger number of syringes which were kept constantly washed by an assistant, and by devising a special nest of three cannulas, the outer one rounded on its end to prevent injury to the intima. Its application was certain and, with a specially trained operator and assistants, the method was nearly perfect. By the utilization of the principle of a two-way stop-cock, modifications were devised by Freund, Unger, and Kush.

In 1914, Hartwell wrote: "The attainment of the ideal seems to lie in the development of a method by which coagulation and other alterations of the blood are prevented during the time required to draw sufficient blood (1000 cubic centimeters) into a receptacle connected by subcutaneous venous puncture with the donor and to empty it again through a similar puncture in the recipient—these two principles, if desirable, being in separate rooms." Except in the hands of those skilled in the application of a special technique, and under the most favorable circumstances, none of the methods up to this time fulfilled all of these requirements. Excluding those methods in which the technique required the employment of a paraffin-coated receptacle, the successful application of all others was dependent upon the rapid transference of blood from donor to recipient in less than the normal coagulation time. In devising a technique to fulfil the requirements of the ideal, it was natural then, that means should be sought to retard the coagulation time without altering the normal properties of the blood. Various means were employed, that is, by the dilution of the blood with normal saline, by isotonic glucose and by the addition of chemicals, namely, herudin and sodium citrate.

In 1914 and 1915 Hustin, Agote, Weil, Lewisohn, Rueck, and others, working independently of one another, published articles recording experiments and clinical application of transfusions performed with citrated blood. Hustin's article appeared August 6, 1914. He mixed the blood with equal parts of isotonic (5 per cent) glucose solution to which was added 20 cubic centimeters of sodium citrate for every 200 cubic centimeters of blood-glucose mixture. He claimed that citrate of soda impaired the oxygenating property of the blood and the addition of glucose was necessary to overcome this. He reported experiments and one clinical application in man. The first transfusion performed in man by blood rendered incoagulable by the addition of sodium citrate alone was performed by Prof. L. Agote of Buenos Aires on November 14, 1914. He employed 1 grain of neutral sodium citrate in 25 per cent solution for every 100 cubic centimeters of blood. Weil observed that citrated blood augmented the coagulative properties of the recipient's blood. From the work of Lewisohn in determining the proper dosage of sodium citrate which can be used with safety, there has developed a method which "unites four advantages in surgery of extreme importance—facility, rapidity, efficacy and security," and which fulfills in every detail the requirements of the ideal.

CLINICAL APPLICATION

This report of a series of 1036 blood transfusions, summarizing the results and recording the general indications and dangers, is submitted because of the belief that the most accurate test of the value of any therapeutic procedure developed from experimental study, lies in its repeated clinical application.

The 1036 transfusions were performed on 429 patients between January 1, 1915, and January 1, 1918, in the Mayo clinic. Five were done by means of the paraffin-lined cylinder, 30 by a modified cannula-syringe technique, and the others, 1001, by the citrate method.

INDICATIONS FOR TRANSFUSION

With the development of simpler methods of technique, and with the introduction of accurate blood tests, blood transfusion has lost the dangers which once attended its use, until today it is a safe and proved therapeutic measure, rather than merely a means of last resort. If blood transfusion is looked upon as a homologous transplantation of living tissue, as suggested by Hartwell, the indications may be epitomized as being those which indicate the necessity of restoring the lost or impaired body tissue (blood) by a homologous transplant. Definite effects of transfused blood are: (1) restoration of the bulk of the circulating fluid, (2) provision of oxygen and assimilable pabulum for tissues, (3) increase of the coagulability, (4) stimulation of the hematopoietic organs, and (5) increase of resistance to infection by its antitoxic and bactericidal properties.

In this series, the cases may be grouped according to indications for transfusion as follows:

1. Primary (pernicious) anæmia, 657 transfusions in 185 cases.

2. Secondary anæmia, 243 transfusions in 149 cases.

Chronic infection	24 cases
Malignancy	44 cases
Chronic hæmorrhages	43 cases
Acute hæmorrhages	7 cases
Hæmolytic jaundice	4 cases
Splenic anæmia	10 cases
Actinomycosis	2 cases
Causes unknown	15 cases

3. Bleeding, 81 transfusions in 59 cases.

4. Acute toxic and septic conditions, 34 transfusions in 25 cases.

5. Leukæmias, 20 transfusions in 10 cases.

6. Shock, 1 transfusion in 1 case.

A detailed analysis will not be made of the cases included in this report, but for completeness a general summary and discussion of the results obtained will be given under each group of cases.

Group 1. Pernicious anæmia. Basing his opinion, presumably, upon the fact that destruction of the patient's own blood is more or less continuous in this group of cases, Soresi classified pernicious anæmia with malignancy, as being the two diseases in which the operation for blood transfusion was absolutely contra-indicated. While the percentage of occurrence of the milder reactions following transfusion is decidedly greater in this class of cases, due probably to the slight hæmolytic action of the blood of the patient upon the blood transfused, definite beneficial effects are seen in a very large percentage of cases. The result varies in different patients, and also in the same patient, following separate transfusions. Whether this variation is the result of the difference in the stimulating properties of the bloods of the different donors, or to a difference of degree in the active hæmolysis of the patient, depending upon the stage of the disease, is a matter of conjecture. The observation based upon the results in this series would tend to support the latter theory. One patient who had been transfused previously, with definite improvement, returned after several months, in a very grave condition—lethargy, temperature 102-3°, hæmoglobin below 20 and red blood cells below one million. He was given 500 cubic centimeters of blood from a suitable donor. A definite reaction of chill, fever, increased drowsiness and hæmoglobinuria followed, and later, herpes on the lip. The patient received no improvement from the transfusion.

A series of transfusions ranging from 1 to 30, was practiced in the cases in this group; some were performed preceding and following splenectomy, but the vast proportion were in non-operated cases. The results were equally good in the different groups. One case of unusual interest is herein reported:

A male, aged 36 years, was admitted for examination February 10, 1915, with a history of good health until about one year previous to admission, when weakness, shortness of breath and increasing pallor gradually developed. From the history, examination and blood findings, a diagnosis of pernicious anæmia was made. At this time his hæmoglobin was 20 per cent, red blood cells 1,730,000, with the presence of normoblasts and megaloblasts. Splenectomy was performed March 10, 1915, and April 7, 1915, before his dismissal, the hæmoglobin was 70 and the red cells 3,640,000. Following acute tonsillitis in the fall he began to run down, and on December 1, 1915, he returned with hæmoglobin 20, and red blood cells 1,190,000. From then until May, 1918, he had thirty-five transfusions of 500 to 750 cubic centimeters each. His response to the transfusions has been remarkable. Ordinarily two to four transfusions at weekly intervals are required to effect a definite remission in the course of the disease. His condition now is apparently as good as it was two years previously. It is of special interest to note that the blood of the patient belongs to Group 1 and while there have been transfused into him blood of all four groups, without any evidence of hæmolysis, he has retained his original grouping.

The conclusions of Archibald, who made an extensive study of a part of the cases in this series, hold good for the series in its entirety. In effect his conclusions were that the greater number of the patients, except those who have reached the very last stages of the disease, will receive immediate benefit from the transfusion of blood. Many also who are in extremis, and who are not benefited by medical treatment alone, will show great improvement by a series of blood transfusions.

Group 2. Secondary anæmias. Except in the seven instances in which the anæmia was due to acute hæmorrhage, the majority of the patients in this group were transfused preliminary to operation, with the idea of improving their general condition and thereby

increasing their resistance to infection. In cases of acute, frank and concealed hæmorrhages, the enormous value of replacing the lost bulk of fluid by blood in connection with efficient surgical means of checking further loss, is well recognized. As pointed out by Hicks in 1869, "the want of success in transfusion lies in the postponement of the operation until too late a period." The normal quantity of blood is estimated to be one-twelfth to one-fourteenth of the body weight, and clinically, the rapid loss of one-half of this amount proves fatal. Various "rules o' thumb" have been offered, based upon the blood pressure readings and hæmatologic estimates, indicating when to transfuse and when it is safe to wait. Dorrance considers it imperative to transfuse when the count falls to 1,000,000 red blood cells and 20 per cent hæmoglobin, or below, and optional when the red cells are 1,500,000 and hæmoglobin 25 per cent. DePage studied wounded soldiers and found that when the red cells fall below 4,500,000 in three hours, 4,000,000 in eight hours, or 3,500,000 in the first twelve hours, the patient will probably die unless transfused. Others have considered the blood pressure readings as the most reliable indicator, pointing out that systolic pressure below 80 mm.Hg. meant danger. Hicks relied solely upon clinical symptoms, especially "the obstinate jactitations and resistance to comply with our wishes in regard to treatment, coupled with the persistent indistinctness of pulse." Robertson warns us against using ordinary resuscitative measures before resorting to transfusion. Our clinical observations bear out his belief that permanent degenerative changes occur in the organism when the exsanguinated condition persists for more than a few hours. We advise transfusion when in doubt. From experiments, Rous and Wilson demonstrated that the amount of hæmoglobin retained in the severest hæmorrhage is above the point necessary to sustain life. Unless the blood withdrawal is too rapid, the organism replaces this bulk by substituting plasma which the body retains in reserve, and thus maintains blood pressure. In animals bled, the investigators were able to raise and maintain the blood pressure reading by the injection of either horse serum or gum acacia (7 per cent). The effect of normal saline solution was only transient, as this quickly leaves the vessels for tissues and urine. David and Curtis showed that dogs bled under similar conditions, until there was cessation of flow at the carotid, could be resuscitated either by injection of physiologic serum or by transfusion. However, in the eighteen hours following this experiment, 77 per cent of the dogs treated with serum died, and only 6 per cent of the animals transfused, succumbed. In all but two cases in this series of acute hæmorrhage, the transfusion was life-saving or greatly beneficial. In the two unsuccessful cases, the patients were temporarily restored, but later, died due to the continuation of the bleeding.

The results of transfusion on the weak, starved, and anæmic patient, as a supportive measure preliminary to operation, are eminently gratifying, as is evidenced both by the increased ability to withstand the operation and by the rapid postoperative convalescence. In the anæmic cases in which the patients are to be submitted to abdominal operation, transfusion is especially indicated. It may be safely asserted that in practically all operations in which the gastro-intestinal tract is opened, there is more or less soiling of the peritoneum which potentially spells peritonitis. It is the normal resistive elements of the organism which prevent this eventuality or limit it to a small area. In those cases in which the resistance of the body has been impaired by chronic bleeding, malignancy, and chronic infection, this complication is most frequently seen. The value, then, of transfusion as a preliminary measure is illimitable.

Group 3. Bleeding. The general oozing which follows certain operations, especially in intensely jaundiced patients, has always been a source of grave concern to the operator, who, in most instances, has been without efficient means of checking it. The results of blood transfusion in these cases have been strikingly good; usually the hæmorrhage ceases almost immediately, and the patient's improvement is quickly obvious. In certain cases, usually of the malignant type in which

the biliary obstruction has not been relieved by the operation, the hæmostatic value of the transfusion rapidly decreases, after 48 to 72 hours, and the patient may start bleeding again. Also, in the oozing occurring after operations on the stomach and intestines, transfusion alone will often be followed by complete and permanent cessation of bleeding, and the rapid convalescence of the patient. The bleeding in ulcers of the stomach and duodenum is usually due to an erosion of one of the larger vessels and transfusion should always be considered preliminary to, or in association with, a laparotomy for the excision of the ulcer. For the postoperative bleeding in patients suffering from blood dyscrasia, transfusion is an effective hæmostasis, but probably has no effect upon the ultimate course of the disease. It is of interest that, clinically, the use of an anti-coagulant in the transfused blood not only does not retard the coagulability of the recipient, but possesses an equal power of hæmostasis with the undiluted blood administered by the syringe-cannula method. Experimentally, this observation was borne out in a series of 41 transfusions by the citrate method in which the coagulation time of the recipient was tested by means of a Boggs' coagulometer and by Lee's test-tube method, just prior to, and immediately following, the transfusion. In 25 instances (58 per cent), the coagulation times was lowered from 1 to 6 minutes; in 6 (14 per cent) it was not affected, and in 12 (28 per cent) it was increased from 1 to 3 minutes. The coagulation time of a hæmophiliac, not included in this series of tests, was taken before transfusion, and recorded as 23 minutes. Five minutes after the transfusion of 500 cubic centimeters of citrated blood, the coagulation time was 3 minutes, 12 hours later it was 8 minutes, and on the fourth day after the transfusion, the coagulation had returned to 20.

Group 4. Acute toxic and septic conditions. The cases included in this group were for the most part infections following abdominal operation, and while the results are not encouraging, largely because of the fact that the patients were hopelessly ill before transfusion was employed, we believe that if given shortly after or, in some instances, before, the operation, blood transfusion offers a reasonable means of combating infection.

Group 5. Leukæmias. As a temporary supportive measure for the correction of the anæmia, the results in the ten cases in this series justify the employment of transfusion.

Group 6. Shock. In this series the diagnosis of surgical shock has been made in the cases of postoperative patients in whom there is no tenable etiologic factor for the production of the chain of symptoms usually attributed to this condition. The clinical diagnosis is often disproved upon re-opening the abdomen or at necropsy, by the presence of "concealed" hæmorrhage, or fat embolism. In the one case in this series, transfusion was without beneficial effect.

METHOD OF TRANSFUSION

Since December, 1915, we have employed the citrate method exclusively, and it has been used in this series of cases in 1001 instances. According to Howell, the rôle of calcium in the phenomenon of coagulation is to activate prothrombin into the formation of thrombin (fibrin ferment) which in turn activates fibrinogen into fibrin. By the addition of citrate of soda, coagulation is prevented by the chemical immoblization or stabilization of the calcium without forming precipitate. Excessive intravenous injection of citrate of soda deprives the blood and tissues of calcium, and the symptoms of convulsions, tonic and clonic, tetany, paralysis and dyspnœa, are the results of the decalcification of the nervous system. To combat this, Hedon would administer calcium in the proportion of one atom to three molecules of the trisodic citrate. Lewisohn, experimenting with a 10 per cent solution, found the toxic dose equivalent to 0.3 grams per kilo, and later Carter showed that the more concentrated the dosage, the smaller the lethal dose. He found the lethal dose with a 2 per cent solution to be 0.835 to 1.24 grams per kilo. Early in this series it was observed that there was a tendency for the milder reactions to occur in cycles, which corresponded in a striking manner with the preparation of fresh citrate solution. It was observed that citrate in

solution rapidly deteriorates, and the importance of employing freshly prepared solution was thus emphasized. From the recognition of the fact that the coagulative properties of different bloods vary in different persons, as evidenced by the occasional coagulation of blood withdrawn from the donor in a 2 per cent citrate solution, we have substituted a 0.24 per cent citrate solution.

TECHNIQUE

The arm of the donor is prepared in the usual manner. A tourniquet is lightly applied above the elbow and the median basilic or the median cephalic vein is either punctured with a large-sized needle or exposed by a small incision, and a cannula introduced. By a simple, yet very ingenious little trick, advised by Watson, we have been aided greatly in introducing a large-sized Kaliski (gauge 11) needle into the lumen of the vein. By means of a small, straight intestinal needle, inserted transversely, the vein is transfixed to the skin, the needle passing through its upper segment. With the end of this transfixing neelde as a handle, the vein is steadied and the cannula needle, directed parallel with the line of the vein, can be readily pushed beneath the level of the transfixing needle into the lumen of the vein (Fig. 6). The blood is received in a sterile graduated glass jar containing 30 cubic centimeters of a 2 per cent sterile solution of sodium citrate at the bottom. While the blood is running, it is well mixed with the citrate solution by means of a glass rod. The flow of the blood should be in a steady continuous stream, and when there occurs slowing of the stream, as is often observed with a sudden drop in venous pressure, due either to syncope or the too snugly applied tourniquet, the needle should be immediately withdrawn and a clean one inserted. If the blood is allowed to flow in an impeded stream, there will be clotting of the whole or part of the blood collected because of the incipient coagulative changes which have taken place in transit from the vessel to the citrate solution. After the blood has reached the 250 cubic centimeter mark another 30 cubic centimeters of the citrate solution is added and the blood is permitted to flow until there are 500 cubic centimeters of the mixture. If more blood is desired, a sufficient amount of citrate solution is added to maintain this ratio of 0.24 per cent. The blood may be carried to the recipient's room or the recipient may be brought into the operating room. The needle is then introduced into the recipient's vein, after the manner above described, and attached by rubber tubing to a glass irrigating flask, the tubing and the bottom of the flask having been previously filled with saline solution. The citrated blood is then transferred into the flask and permitted to flow into the vein of the recipient. It is advisable to have the blood run in slowly in order to guard against suddenly overloading the right side of the heart, and in order to watch for any untoward effects upon the patient. A marked slowing of the pulse, syncopal attacks, dyspnœa, cyanosis, a sensation of cardiac oppression or excruciating pain throughout the body, especially localized in the small of the back, should be interpreted as danger signals, and if these persist after temporary stopping of the flow, it is advisable to conclude the operation at once, and another donor should be secured.

The amount of blood to be transfused should be dependent upon several factors, namely, the age of the patient, the presence of associated physical impairments, such as cardiac lesions, arteriosclerosis, etc., and the pathologic condition for which the transfusion is indicated. Unless for the purpose of replacing a large bulk of blood lost from an acute hæmorrhage, the impression received from the study of this series of cases would indicate that better results are to be expected from the use of a relatively small quantity, 500 to 750 cubic centimeters, repeated in from five to seven days, rather than from a single transfusion of a larger amount. While the evidence is most conclusive that the transfused blood lives for a time at least as a transplant, yet a greater value in many of the anæmic conditions lies in its stimulating effect on the blood-forming organs of the recipient, as is evidenced by the secondary rise in the hæmoglobin and blood picture, which occurs four or five days after the transfusion.

DONORS

In the selection of a suitable donor, a young healthy, robust individual is desired. Our results tend to corroborate the observations of Peterson that the value of the transfusion is largely dependent upon the individual donor. One donor's blood may exhibit remarkable powers of hæmostasis, that of another may induce unusual hæmatopoietic stimulation, and that of another, owing to the presence of some antibody, may exert real antitoxic effect. The blood of every donor should be tested for syphilis and as to its compatibility in reference to agglutination and hæmolysis. The seriousness of transmitting syphilis or other diseases, especially to those patients in whom there is no urgency for the transfusion, cannot be overestimated. As our ability for detecting syphilis, by examination and Wassermann test, is within limits, and as there is a possibility of the infection of the donor subsequent to his examination, the chances of transferring syphilis, while admittedly small, should always be considered, and unless the transfusion is performed in emergency, this possibility should always be explained to the patient. Two instances of syphilis transmission are reported in the literature. In our series, syphilis was transmitted by transfusion in one instance. This patient had been receiving a series of transfusions; the blood of the donor, in each instance, was Wassermann negative. One man who had served as a donor about twelve days prior to the development of the skin eruption was suspected as the infecting donor, but these suspicions could not be definitely confirmed.

Since July, 1916, the blood of the prospective donors has been tested according to the Moss agglutination test, as modified by Brem. In instances of the newborn, when it is necessary to transfuse in order to check hæmorrhage, Cherry and Langrock have showed, in a series of 34 tests, that the mother is always a suitable donor. However, it should be emphasized that after the first few weeks of life the child develops an independent group of its own which is not necessarily the same as that of the mother, and accordingly tests should always be made preliminary to transfusion. In an emergency, such as that following an acute hæmorrhage, when the life of the patient is dependent upon an immediate transfusion, it is justifiable to use a donor without a preliminary test. In such instances the operator should allow the first 200 cubic centimeters of blood to run in slowly. If the patient shows symptoms of hæmolysis, the operation should be concluded or another donor secured. In this series we used donors without preliminary test in eight emergency transfusions and in none of the patients was there any evidence of hæmolysis. These results, we believe, were due to good fortune.

In 1913, Ottenberg and Kaliski explained that in the instance in which the serum of the donor is agglutinative to the cells of the patient, the plasma of the donor, on transfusion, will be diluted by the excess of the patient's plasma and will meet with a large excess of agglutinable cells. In practice they had four such transfusions with no unfavorable results. When it has been feasible we have always made it a point to use a donor in the same group as that of the recipient, but in a great number of instances, as in emergencies, and in cases in which a relative or volunteer donor is obtainable whose blood is not in the same group with that of the recipient, we have used donors whose cells are not agglutinable by the serum of the patient. In Croup 4 there is a large percentage (43 per cent) of persons whose blood is suitable for transfusion with the blood of all the groups, and this point has been utilized in our emergency transfusions. Formerly, in cases of utmost urgency we were forced to take a large chance by using an untested donor, but now there is always on call a list of prospective donors in Group 4 whose blood, we have absolute confidence, will be suitable with that of any patient. In the entire series there have been no untoward effects upon the donor from the loss of 500 to 750 cubic centimeters. On the other hand, the loss of blood in the majority of donors has been followed by a temporary gain in weight. Many of these donors continue their normal duties immediately upon the conclusion of the transfusion. We have used especially robust persons as donors as often as 8 times within 12 months.

There are three well recognized accidents associated with and complicating blood transfusions, namely, acute dilatation of the heart, embolism from the introduction of air or clotted blood, and hæmolysis. The first two accidents are absolutely preventable by the exercise of due caution as to the technique, the rapidity with which the blood is permitted to flow, and the limiting of the quantity of blood in cases of suspected cardiac and circulatory impairment. The third danger, due to the incompatibility of the blood of the donor and the blood of the recipient, is controllable by accurate blood tests. By the term "hæmolysis" we mean the destruction of the red blood cells with the liberation of the hæmoglobin and clinically we detect this by the finding of hæmoglobinuria, increased urobilin in the urine and phagocytosis of red cells. The gravity of the danger depends upon the degree of destruction.

REACTIONS

In 219 transfusions (21 per cent) of the series, there occurred from 15 minutes to one hour later, a slight reaction of chill and fever, a temperature of 100 to 105°, with or without malaise, headache, nausea and vomiting and diarrhœa, and followed, in a small percentage of cases, on the third day after the transfusion, by an eruption of herpes. In another 15 per cent of transfusions there occurred a rise of temperature to 100° or above, not associated with chill and nausea. These were, in every instance, of a transitory nature, the temperature returning to normal in from 12 to 36 hours, and in only two instances was it at all probable that the good of the transfusion was vitiated by this complication.

The nature of such reactions is unknown. Various theories have been suggested, for example: (1) the introduction of a foreign protein, (2) the introduction of a citrate solution, (3) incipient coagulative changes in the transfused blood, (4) slight degree of hæmolytic changes occurring after transfusion not sufficient to be evidenced by clinical test, and (5) incompatibility of the white corpuscles of the donor and recipient. All may be factors, but in this series there was a striking relationship between the pathologic condition for which the transfusion was indicated, and the occurrence of these milder reactions. A decidedly higher disproportion in the percentage was seen in those cases, such as pernicious anæmia and advanced malignancy, in which there were active hæmolytic changes. In some of these, the intravenous introduction of normal saline alone was followed by similar reactions.

In 1915, Bernheim collected data of 800 transfusions performed by 12 different operators, and reported the occurrence of hæmolysis in 15 cases, with four deaths. In 12 instances in this series there were group reactions. The blood of three of these patients had been tested by the old macroscopic test, and the others had been grouped by the method of Brem. In every case in which the blood had been grouped by the microscopic test, we were able later to locate an error in the testing. Most of these were due to a clerical error in recording the group of the donor or the recipient. In one patient, supposedly in Group 2, attempts were made on two different occasions to inject blood from a donor in Group 2, and both times we were forced to stop because of the occurrence on the table of a severe reaction. Later, this patient's record was reviewed, and he was found to be in Group 3 instead of Group 2. Retesting proved this, and subsequent transfusions with Group 3 donors were unattended by any reaction. These reactions are most typical. They occur early after the introduction of 50 or 100 cubic centimeters of blood; the patient first complaining of tingling pains shooting over the body, a fullness in the head and an oppressive feeling about the precordium, and, later, an excruciating pain localized in the lumbar region. Slowly but perceptibly the face becomes suffused, a dark red to a cyanotic hue; respirations become somewhat labored, and the pulse rate, at first slow, sometimes suddenly drops as many as 20 to 30 beats a minute. The patient may lose consciousness for a few minutes. In one-half of our cases an urticarial eruption, generalized over the body, or limited to the face, appeared along with these symptoms. Later the pulse may become very rapid and thready; the skin becomes cold and clammy, and the patient's

condition is indeed grave. In from fifteen minutes to an hour, a chill occurs, followed by high fever, a temperature of 103 to 105°, in which the patient may become delirious. *Jaundice* may appear later. The macroscopic appearance of hæmoglobinuria is almost constant. In three such instances the symptoms were not recognized at the time of the transfusion and 500 cubic centimeters of blood were injected. All the patients died, two in one and three hours, respectively, following the transfusion, and one became comatose shortly afterward and died 30 hours later. In the other 9 instances the symptoms were early recognized and interpreted, and the transfusion was concluded after the injection of 50 to 100 cubic centimeters of blood. Adrenalin and atropin were administered with good effect. There was no mortality in this group.

Writers, notably Ottenberg and Kaliski, Bernheim, Brem, and others, for a number of years have been emphasizing the importance of preliminary blood tests, and yet today there are a few who advocate such a measure only when it is "convenient." The cases in our series point out most strikingly the fact that the injection of incompatible blood, namely, in which the donor's cells are agglutinable by the serum of the patient, is attended by the development of symptoms of the gravest nature, and that if these are not early recognized and the transfusion concluded before the injection of a large quantity of blood, fatal results are to be expected.

REFERENCES

1. AGOTE, L. Nuevo procedimiento para la transfusión de sangre. An. d. Inst. mod. de clin. méd., Buenos Aires, 1915, i, Nos. 1 and 3.
2. ARCHIBALD, A. The transfusion of blood in the treatment of pernicious anæmia. St. Paul M. J., 1917, xix, 43–47.
3. AVELING, J. H. An improved apparatus for immediate transfusion. Med. Rec., 1874, ix, 190-191.
4. BERNHEIM, B. M. Hæmolysis following transfusion of blood. Lancet-Clinic, 1915, cxiii, 259–262.
5. BISCHOFF, T. L. W. Beitraege zur Lehre von dem Blute und der Transfusion desselben. Arch. f. Anat., Physiol. u. wissensch. Med., 1835, 347–372.
6. BLASIUS. Statistik der Transfusion des Blutes. Monatsbl. f. med. Statist. u. œff. Gsndhtspflg., Berl., 1863, 77–84.
7. BLUNDELL, J. Experiments on transfusion of blood by syringe. Med. Chir. Tr., 1818, ix, 56–92.
8. BREM, W. V. Blood transfusion with special reference to group tests. J. Am. M. Ass., 1916, lxvii, 191–193.
9. BREWER, G. E., and LEGGETT, N. B. Direct blood transfusion by means of paraffin coated glass tubes. Surg., Gynec. & Obst., 1909, ix, 293–295.
10. BRINTON, J. H. The transfusion of blood and the intravenous injection of milk. Med. Rec., 1878, xiv, 344–346.
11. BROWN-SEQUARD. Quoted by Ottenberg, R. Ann. Surg., Phila., 1908, xlvii, 486–505.
12. BUCHSER, J. A successful case of transfusion. Med. Rec., 1869-70, iv, 337–339.
13. BUERGER, L. A modified Crile transfusion cannula. J. Am. M. Ass., 1908, li, 1233.
14. BRUNTON, T. L. Quoted by Dorrance and Ginsburg. Loc. cit.
15. CARREL, A. Quoted by Guthrie. Loc. cit.
16. CARTER, W. S. An experimental study of the use of sodium citrate in the transfusion of blood by direct and indirect methods. South. M. J., 1916, ix, 427–439.
17. CRILE, G. The technique of direct transfusion of blood. Ann. Surg., Phila., 1907, xlvi, 320-332.
18. CHERRY, T. H., and LANGROCK, E. G. The relation of hæmolysis in the transfusion of babies with the mothers as donors. J. Am. M. Ass., 1916, lxvi, 626–627.
19. CURTIS, A. H., and DAVID, V. C. Transfusion of blood by a new method, allowing accurate measurement. J. Am. M. Ass., 1911, lvi, 35–36.
20. DANIEL. Quoted by Dorrance and Ginsburg. Loc. cit.
21. DAVID, V. C., and CURTIS, A. H. Experiments in the treatment of acute anæmia by blood transfusion and by intravenous saline infusion. Surg., Gynec., & Obst., 1912, xv, 476–480.
22. DENYS, J. Quoted by Dorrance and Ginsburg. Loc. cit.
23. DEPAGE and GOVAERTS. Quoted by Rous and Wilson. Loc. cit.
24. DIEFFENBACH, J. F. Die Transfusion des Blutes und die Infusion der Arzneien in Blutgefaesse. 1. Theil. Berl., 1828.
25. IDEM. (Second work on transfusion.) Rust, Handbuch der Chirurgie, iv. Quoted by Ottenberg, Ann. Surg., Phila., 1908, xlvii, 486–505.
26. DOERFLER, J. Ueber Arteriennaht. Beitr. z. klin. Chir., 1899, xxv, 781–825.
27. DORRANCE, G. M., and GINSBURG, N. Transfusion: history, development, present status, and technique of operation. N. Y. M. J., 1908, lxxxvii, 941–944.
28. IDEM. Indications for blood transfusion. Am. J. M. Sc., 1917, cliv, 216–220.
29. DUMAS and PREVOST. Quoted by Ottenberg, Ann. Surg., Phila., 1908, xlvii, 486–505.
30. ECK. Quoted by Guthrie. Loc. cit., p. 2.
31. FOLLI, F. Quoted by COX, R. Blood transfusion in the Seventeenth Century. J. Am. M. Ass., 1914. lxii, 222.
32. FRANK, R. T., and BAEHR, G. A new method for the transfusion of blood. An experimental study. J. Am. M. Ass. 1909, lii, 1746–1749.
33. FREUND, H. A. Transfusion of fresh normal blood. J. Mich. M. Soc., 1913, xii, 459–461.
34. FRYER, B. E. A few remarks on the transfusion of blood, with a modification of the apparatus of Aveling. Med. Rec., 1874, ix, 201–203.
35. GESELLIUS, F. Die Transfusion des Blutes. St. Petersburg, 1873.

36. IDEM. Zur Thierblut-Transfusion beim Menschen. St. Petersburg, 1874.
37. GUTHRIE, C. C. Blood-vessel Surgery and Its Applications. London: Arnold; New York: Longmans, Green, 1912. p. 360.
38. HARTWELL, J. A. A consideration of the various methods of blood transfusion and its value. N. Y. S. J. Med., 1914, xiv, 535–541.
39. HARVEY, WILLIAM. Works. Transl. by Robert Willis. London: Sydenham Soc., 1847. 624. pp.
40. HÉDON, E. Note complémentaire sur la transfusion du sang citraté. Presse méd., 1918, xxvi, 57–58.
41. HICKS, J. BRAXTON. Cases of transfusion with some remarks on a new method of performing the operation. Guy's Hosp. Rep., 1869, 3. s., xiv, 1-14.
42. HIGGINSON, A. Report of seven cases of transfusion of blood, with a description of the instrument invented by the author. Liverpool Med.-Chir. J., 1857, i, 102–110, 1 pl.
43. HODDER, E. M. Quoted by Brinton. Loc. cit.
44. HOWELL, W. H. Textbook of Physiology. 6th ed. Philadelphia: Saunders, 1915, 1043 pp.
45. HULL, A. J. Direct transfusion of blood. Brit. M. J., 1917, ii, 683–684.
46. HUSTIN. Principe d'une nouvelle méthode de transfusion muqueuse. J. méd. de Brux., 1914, xii, 436–439.
47. HUETER, C. Ein Fall von Kohlenoxydvergiftung; Heilung durch Transfusion. Berl. klin. Wchnschr., 1870, vii, 341.
48. JANEWAY, H. H. An improved device for transfusion. Ann. Surg., Phila., 1911, liii, 720, 1 pl.
49. JANSKY. Quoted by Sydenstricker, et al. Loc. cit.
50. KIMPTON, A. R., and BROWN, J. H. A new and simple method of transfusion. J. Am. M. Ass., 1913, lxi, 117.
51. KING, E. Quoted by McClure and Dunn. Loc. cit.
52. KOEHLER, A. Ueber Thrombose und Transfusionen, Eiter—und septische Infection und deren Beziehung zum Fibrinferment. 1877. 134 pp.
53. KUSH, M. An automatic transfusion apparatus. J. Am. M. Ass., 1915, lxv, 1180–1181.
54. LANDOIS, L. Die Transfusion des Blutes. Leipzig, 1875.
55. LANDSTEINER, K. Zur Kenntnis der antifermentativen, lytischen und agglutinierenden Wirkungen des Blutserums und der Lymphe. Centralbl. f. Bakteriol., 1900, xxviii, 357–362.
56. LANDSTEINER, K. Ueber Agglutinationserscheinungen normalen menschlichen Blutes. Wien. klin. Wchnschr., 1901, xiv, 1132–1134.
57. LEISRINK, H. Ueber die Transfusion des Blutes. Samml. klin. Vortr., No. 41, Leip., 1872, Chir., No. 13, 235–246.
58. LESPINASSE, V. D. Technique of direct transfusion of blood, using iridio platinum tubes. Chicago Med. Recorder, 1915, xxxvii, 589–593.
59. LESSER, L. Transfusion und Autotransfusion. Samml. klin. Vortr., No. 86, Leip., 1875, Inn. Med., No. 29, 665–684.
60. LEWISOHN, R. Blood transfusion by the citrate method. Surg., Gynec. & Obst., 1915, xxi, 37–47; Med. Rec., 1915, lxxxvii, 141–142.
61. LICHTENSTEIN. Eigenbluttransfusion bei Extrauteringraviditaet und Uterusruptur. Muenchen. med. Wchnschr., 1915, lxii, 1597–1601.
62. LINDEMAN, E. Simple syringe transfusion with special cannulas; a new method applicable to infants and adults. Am. J. Dis. Child., 1916, vi, 28–32.
63. LOEWENTHAL, W. Ein Beitrag zur Lehre von der Transfusion des Blutes. Berl. klin. Wchnschr., 1871, viii, 487–491.
64. LOWER, RICHARD. Quoted by Dorrance and Ginsburg. Loc. cit.
65. MCCLURE, R. D., and DUNN, G. R. Transfusion of blood. Bull. Johns Hopkins Hosp., 1917, xxviii, 99–105.
66. MCGRATH, B. F. A simple apparatus for transfusion by the aspiration-injection method. Surg., Gynec. & Obst., 1914, xviii, 376–377.
67. MADGE, H. M. On transfusion of blood. Brit. M. J., 1874, i, 42–44.
68. MANN, F. C. Personal communication.
69. MARTIN. Ueber eine mit guenstigem Erfolge bei einer lebensgefaehrlichen Intrauterinblutung vollzogene Transfusion. Verhandl. d. Gesellsch. f. Geburtsh. in Berl., 1862, xiv, 59–63; Monatschr. f. Geburtsh. u. Frauenkr., 1861, xvii, 269–273.
70. MOSS, W. L. A simple method for the indirect transfusion of blood. Am. J. M. Sc., 1914, cxlvii, 698–703.
71. MOSS, W. L. Iso-agglutinins and isohæmolysins. Bull. Johns Hopkins Hosp., 1910, xxi, 63–70.
72. MURPHY, J. B. Resection of arteries and veins injured in continuity—end-to-end suture. Med. Rec., 1897, li, 73–88.
73. NITZE. Quoted by Guthrie. Loc. cit.
74. ORÉ. Études historiques et physiologiques sur la transfusion du sang. Paris, 1868.
75. OTTENBERG, R. Transfusion and arterial anastomosis. Ann. Surg., Phila., 1908, xlvii, 486–505.
76. OTTENBERG, R., and LIBMAN, E. Blood transfusion. Am. J. M. Sc., 1915, cl, 36–69.
77. OTTENBERG, R., and KALISKI, D. J. Accidents in transfusion. J. Am. M. Ass., 1913, lxi, 2138–2140.
78. PANUM, P. L. Experimentelle Untersuchungen ueber die Transfusion, Transplantation oder Substitution des Blutes in theoretischer und practischer Beziehung. Virchow's Arch. f. path. Anat., 1863, xxvii, 240–295; 433–459.
79. PAYR, E. Beitraege zur Technik der Blutgefaess— und Nervennaht nebst Mittheilungen ueber die Verwendung eines resorbirbaren Metalles in der Chirurgie. Arch. f. klin. Chir., 1900, lxii, 67–93.
80. PAYR, E. Zur Frage der circulaeren Vereinigung von Blutgefaessen mit resorbirbaren Prothesen. Arch. f. klin. Chir., 1904, lxxii, 32–54.
81. PERCY, N. M. A simplified method of blood transfusion; six cases of pernicious anæmia treated by massive blood transfusions [and splenectomy. Surg., Gynec. & Obst., 1915, xxi, 360–365.
82. PETERSON, E. W. Result from blood transfusion in the treatment of severe posthæmorrhagic anæmia and the hæmorrhagic diseases. J. Am. M. Ass., 1916, lxvi, 1291–1295.
83. PONFICK. Experimentelle Beitraege zur Lehre von der Transfusion. Virchow's Arch. f. path. Anat., 1875, lxii, 273–335.
84. RICHARDSON, B. W. The cause of the coagulation of the blood: The Astley Cooper prize essay for 1856.
85. ROBERTSON, L. B., and WATSON, C. G. Further observations on the results of blood transfusion in war surgery. Ann. Surg., Phila., 1918, lxvii, 1–13.
86. ROUS, P., and WILSON, G. V. Fluid substitutes for transfusion after hæmorrhage. J. Am. M. Ass., 1918, lxx, 219–222.
87. RUECK, G. A. Med. Rec., 1915, lxxxvii, 354.
88. SANFORD, A. H. Iso-agglutination groups. J. Am. M. Ass., 1916, lxvii, 808–809.

89. IDEM. Selection of the donor for transfusion. Journal-Lancet, 1917, xxxvii, 698–701.
90. IDEM. A modification of the Moss method of determining isohæmagglutination groups. J. Am M. Ass., 1918, lxx, 1221.
91. SATTERLEE, H. S., and HOOKER, R. S. Experiments to develop a more widely useful method of blood transfusion. Arch. Int. Med., 1914, xiii, 51–75.
92. SORESI, A. L. Clinical indications for direct transfusion of blood. Med. Rec., 1912, lxxxi, 835–839.
93. SMITH, T. Transfusion of blood in case of purpura. Lancet, Lond., 1873, i, 837.
94. SHATTUCK, S. G. Chromocyte clumping in acute pneumonia and certain other diseases, and the significance of the buffy coat in the shed blood. J. Path. & Bacteriol., 1900, vi, 303–314.
95. SYDENSTRICKER, V. P. W., MASON, V. R., and RIVERS, T. M. Transfusion of blood by the citrate method. J. Am. M. Ass., 1917, lxviii, 1677–1680.
96. THOMAS, T. G. The intravenous injection of milk as a substitute for the transfusion of blood. N. Y. M. J., 1878, xxvii, 449–465.
97. UNGER, L. J. Transfusion of unmodified blood. J. Am. M. Ass., 1917, lxix, 2159–2165.
98. IDEM. A new method of syringe transfusion. J. Am. M. Ass., 1915, lxiv, 582–584.
99. WATSON, J. J. A method of fixation of vein to facilitate the introduction of a needle for intravenous injections. J. Am. M. Ass., 1911, lvii, 383–384.
100. WEIL, R. Sodium citrate in the transfusion of blood. J. Am. M. Ass., 1915, lxiv, 425–426.
101. v. ZIEMSSEN. Quoted by Hartwell. Loc. cit.

THE TREATMENT OF CERTAIN TYPES OF ANORECTAL FISTULA

BY ARTHUR A. LANDSMAN, M.D., NEW YORK
Attending Rectal Surgeon, Philantropin Hospital; Associate Surgeon, Rectal Department, Post Graduate Medical School and Hospital; Deputy Surgeon, Diseases of the Rectum, Out Patient Department, New York Hospital

THE successful operative treatment of anorectal fistula has offered difficulties which are nothing short of surprising, when we consider the brilliant achievements of the surgery of other regions during the past quarter of a century. The end-results have been far from satisfactory, even at the hands of the most expert, judging by the frequency of recurrences, postoperative complications, and sequelæ. Every surgeon must recollect instances from his own practice, in which radical operation, apparently thorough and complete, has been followed by humiliating failure, despite careful precaution during and after the operation. This is especially true of certain types of non-specific, complex, anorectal fistula, in which there is still some confusion as to what constitutes ideal treatment; we refer to those, which have one or more external openings on the skin, connected with one or more internal openings in the rectal wall, occurring simultaneously in both ischiorectal fossæ, from either two independent abscesses running their course at the same time, or originating from a single infective focus, by extension of the inflammation through the anococcygeal ligament. The proper operative management of such a condition requires skill and experience, for it is in this type of a case one is likely to meet not only a considerable percentage of recurrences, but distressing complications as well. Given such a problem, the surgeon is confronted with one of two alternatives: to follow up the tracts, and cut through the sphincters on both sides at one sitting, or permit one side to heal up first, before doing a secondary operation on the other, at some later date. Division of the sphincters in more than one place exposes the patient to the danger of incontinence, especially if both external and internal sphincter muscles have to be divided, while operation in two sittings subjects him to a double risk, and a prolonged convalescence, not to be lightly dismissed in a person already weakened from an exhausting suppurative process.

The writer has tried a plan which seeks to overcome these difficulties; it is based on the observation that, under certain conditions, a complete anorectal fistula will heal, and remain permanently closed, even if its internal opening is left undisturbed. Time and again do we see patients in our dispensary work, who have small sinuses which open into the rectal wall, and yet if at the time of operation the surgeon fails to locate such openings, it happens that some of these patients nevertheless are found to be cured permanently when examined months after-

wards, provided other conditions are favorable. This we believe may be accomplished in a majority of cases by careful attention to certain details, which may be set down as being fundamentally concerned in the successful treatment of anorectal fistula. It goes without saying, that the principles which apply to the treatment of a fistula (which is nothing more than a chronic abscess cavity contracted down to a thin, tubular tract) differ in no wise from those which medical science has found to be true in all other infections; they are constant physical values, modified only by local anatomical and physiological conditions. Failure to recognize this basic fact, has given us a false conception of the situation, wrongly influenced our methods and led to annoying complications. The keynote of the surgical treatment of abscess is prompt, radical, and thorough drainage, to permit the organism to rid itself of as many of its invading enemies as possible, prevent the absorption of their poisons into the blood, and stimulate and encourage repair. These conditions find their most favorable expression when the parts are kept at rest, because sick organs and diseased tissues will not repair readily, when their natural processes are disturbed by constant changes in the medium which surrounds them. There is no proof that re-infection from wound products and fæcal discharges play more than a secondary rôle in the treatment of fistula, provided only that good drainage is available; for the evolutionary tendency in an otherwise sound organism is toward repair and recovery, and not toward destruction and death, when favorable conditions are permitted to assert themselves.

Our plan then, is to cut into one of the external openings, and connect all of the tracts of one side with each other by suitable incisions, break up all pockets, trim away scar tissue, exuberant granulations, and as much of the edges of the wound as appear dead, or badly infected, attend to hæmostasis, and convert the wound into one single cavity with walls smooth and clean; then repeat the process on the other side, *without, however, dividing the sphincter on either side.* This procedure provides for the necessary drainage. The next step is intended to immobilize the parts, by cutting through both sphincter muscles in the posterior median line, regardless of the location of the internal openings. This enables the parts to secure the rest they require to complete their healing, and does away with the necessity of the division of the sphincter on each side, in two different places. Moreover the posterior incision is in a neutral position in respect to both fistulas, and will confer equal benefit to both, instead of much benefit to one, and but little to the other. It possesses the further advantage of enabling us to drain both ischiorectal fossæ through a single opening, and is less liable to be followed by damage to the fibers of the external sphincter. Because of their anatomical arrangement, these can be practically split in this situation, instead of being divided transversely. The posterior incision does not injure any vital parts, and being in a more dependent position when the patient is in bed, enables us to carry out drainage more easily; while anteriorly there are important organs in both male and female, besides dense fibromuscular structures which meet at the central tendon of the perineum, and are necessary to the integrity of the pelvic floor. Their division impairs the strength of the outlet, and causes sagging of the supporting muscles, an obvious objection in female patients.

The rest of the treatment is carried out with the same painstaking care which should be the rule in all cases of fistula. We have tried our plan in a limited number of bilateral anorectal, and so-called horseshoe fistula, and would recommend its use in suitable cases.

SUMMARY

The indications of successful treatment of of non-specific, complex, anorectal fistula occurring simultaneously on both sides, may be met by—

1. Adequate drainage, obtained by proper operative means.

2. Complete rest, by division of the muscles, not necessarily in line with the internal openings.

Given these, the internal openings may be trusted to take care of themselves.

A PRACTICAL CLASSIFICATION OF CUTANEOUS NEOPLASMS

By F. T. VAN BEUREN, Jr., M.D., F.A.C.S., New York
From the Laboratory of Surgical Pathology, Columbia University

A CAREFUL examination of the ponderous forms of classification invented by the dermatologist and the simpler but more subtle arrangements that pure pathologists have evolved, leaves one with the feeling that, for the useful purpose of clinical diagnosis, the broadest and most obivious differentiation of skin tumors would be the most practical. Looking at the subject from this point of view, let us consider cutaneous neoplasms in three groups: i. e., (1) those upon the skin, (2) those in the skin, and (3) those beneath the skin.

Of course these broad divisions necessarily include intermediate or borderline zones; yet although the integrity of the classes is by no means inviolable, the form is so simple and so obivous that I shall attempt to justify its use by the clinician.

1. New-growths *upon the skin* we may define for our purpose as those projecting markedly beyond the surrounding surface plane, in which there is, visually or palpably evident, proliferation of the more superficial layers of the integument.

2. New-growths *in the skin* usually project little, if at all, beyond the surrounding surface plane but are more apparently connected with (or even a part of) the deeper dermal layers, as if the proliferation involved the entire thickness of the skin.

3. New-growths *beneath the skin* we must consider as including those cystic or solid tumors which, while connected with the skin and often elevating it beyond the surrounding surface plane, fail to exhibit any evident proliferation of the epidermis but rather a thinning of the overlying integument.

Papillomata and epitheliomata (especially those of the papillary type) fall readily into the first of the above classes.

Fibromata, keloids, granulomata, pigmented moles, angiomata of capillary type, the rare composite or fibro-epithelial tumors, melanocarcinomata, and sarcomata (except such metastases as may at first be entirely beneath the skin) belong in class 2.

Implantation, sebaceous and dermoid cysts, lipomata of pure or fibrous type and cavernous angiomata are classified with the third division.

During the past eight or nine years, morphological diagnoses have been recorded in the Department of Surgical Pathology on a few more than 350 new-growths of the skin, which may be grouped, according to our proposed classification, as follows:

1. Tumors upon the skin.

1. Papillomata			44
2. Epitheliomata	Basal cell	58	122
	Squamous cell	61	
	Papillary type	3	
			166

2. Tumors in the skin.

1. Fibromata	38
2. Sarcomata	24
3. Pigmented moles	28
4. Melanocarcinomata	12
5. Keloids	9
6. Granulomata	7
7. Fibro-epithelial or composite tumors.	3
8. Capillary angiomata	2
	123

3. Tumors beneath the skin.

1. Angiomata (cavernous type)	20
2. Lipomata	5
3. Sebaceous cysts	18
4. Implantation cysts	15
5. Dermoid cysts	5
6. Carcinoma metastasis	1
	64

About 45 per cent of these tumors then are epitheliomata, sarcomata, and melanocarcinomata, and, if we omit the basal cell epitheliomata from this percentage, we find at least 28 per cent of the tumors presenting morphological characteristics of malignancy.

Fortunately, this does not at all accurately represent the relative frequency of incidence of malignant neoplasms of the skin; for it is well understood that many of the tumors re-

moved, whose benign character is clinically evident, (tumors such as lipomata and sebaceous cysts) are not sent to the laboratory for diagnosis.

On the other hand it must be remembered that a few tumors which, in their early stage, appear both clinically and morphologically to be non-malignant, give unmistakable evidence later (by metastasis) of their autonomous character. And these growths cannot but excite our peculiar interest.

Leaving their detailed consideration for a later moment, let us now examine the group of epitheliomata, sarcomata, and melanocarcinomata among the laboratory specimens with reference to the clinical diagnosis made by the sender of the specimen.

Among the 64 squamous epitheliomata there were 20 correct diagnoses and 27 cases in which the sender was either too indifferent or lacked the confidence to record his diagnosis. It is perhaps fair to argue that the sending of the specimen was inferential evidence that the operator at least suspected possible malignancy. Among the 58 basal-cell epitheliomata, there were 9 correct diagnoses, 13 incorrect diagnoses, and 36 cases with none. Of the 12 melanocarcinomata, 4 were incorrectly diagnosed and 4 had no diagnosis recorded. Five of the 24 sarcomata were correctly and 8 incorrectly named and 11 were not recorded.

Analyzing these figures, we find 25 per cent of straightforward, recorded mistakes, failures clinically to detect epithelioma; 26 per cent of failures to recognize basal-cell epithelioma; 33 per cent mistakes in melanocarcinoma and 33 per cent in sarcoma.

These facts are sufficiently striking to raise again the old question (most pertinent of cutaneous new-growths) "How do you know a malignant tumor when you see one?"

An attempt to answer leads us to a brief review of the clinical characteristics of cutaneous tumors in general without drawing any hair lines between hypertrophy and new-growth.

Situation, size and surface appearance, consistency, pigmentation or the lack of it, but above all the presence or absence of ulceration and the rate of growth are the important details to be observed in the examination of any skin tumor.

Following the outline of our tentative classification we may say that for purposes of clinical surgery, all new-growths *upon the skin* not epitheliomata may be called papillomata. Now, in any respectable treatise upon diseases of the skin, at least ten varieties of verruca or warts may be discovered; but most of these agree in their description with what surgeons are apt to designate papilloma; and this term connotes, lexicographically, "Any excresence upon the cutaneous or mucous surfaces," although morphologically speaking, papillomata are outgrowths from the surface having a covering layer of epithelium and a connective-tissue framework.

Such tumors, indeed, may be many in number, various in form, size, shape and appearance; but, no matter how different the histologic features, an accurate, positive clinical differentiation cannot be made between the varieties except it be based upon their situation or the history of their origin and course.

Exceptions, perhaps, to the very general rule are the cutaneous horns, rarely seen (but never afterward to be forgotten) and of little surgical significance except for the possibility of epitheliomatous change which, Lebert says, occurs in 12 per cent of the cases. Also the common corns and callosities (which are "what every woman knows") and which, though (like horns) of enormous etiological, histological and phylogenetic interest, are too familiar to require any mention further than to record that occasional confusion may arise between an early melanotic growth and a corn upon the sole of the foot, because of the minute hæmorrhagic extravasations that are frequently found simulating pigment in the deeper layer of the latter.

Now epitheliomata are found, in our experience, most frequently upon the forehead (15 per cent) the lips (15 per cent), and the cheek (14 per cent); but while the basal-cell favor the cheek, nose and forehead, they may occur on any part of the surface. Nor in the early stage is there anything absolutely characteristic in their size, shape, or consistency. True they are generally hard. But so

of many papillomata and it is not until the former are, so to speak, full blown and well developed (especially in the basal-cell type) that evident acceleration of the rate of growths and the development of ulceration afford fairly definite evidence of their wicked identity.

Among the tumors *in the skin* fibromata and sarcomata so closely resemble each other at the period when local removal has curative possibilities that even under the microscope a diagnosis may be doubtful and the elements are so mixed that the term fibrosarcoma has arisen to conceal our ignorance. The same may be said with regard to angiomata, although of course the perfectly typical instances may be easy to differentiate.

Keloids are usually so straightforward as to be positively uninteresting (from a diagnostic point of view), but we have at least one specimen of clinical keloid that turned out to be, on microscopic examination, a basal-cell epithelioma.

But any fungating tumor may be mistaken for a granuloma; and between a melanotic carcinoma and a pigmented mole no pathognomonic symptom can be stated that will definitely point to removal for malignancy while yet local removal is of any value.

Tumors *beneath the skin* present some diagnostic dfficulties as between certain angiomata and lipomata, but these are unimportant from the standpoint of mortality; while sebaceous, implantation and dermoid cysts, although exciting to the diletante to argue over, for the most part, share the same inglorious degree of safety.

If a wearying repetition of too well known symptoms has been avoided, enough has yet perhaps been said to indicate that, although in what might be called, the "developed" stages, acceleration of growth rate and occurrence of ulceration are most pointedly suggestive of danger: in the developing stages, on the other hand, a positive, correct diagnosis between the benign and a malignant tumor of the skin can rarely be expected. If this be true, and our records speak loudly in its affirmation, it follows as the night the day, that the only question a clinical surgeon has the right to haggle over is whether the offensive excresence is a real new-growth or not, i. e., whether it has grown since first noticed.

If it be, then it must come out, for, to paraphrase the old story of the good Indian, the only permanently benign tumor is one that has been bottled early.

And now, lest this presentation may have robbed the subject of its proper gravity, your attention is most seriously invited to two propositions.

1. That every new-growth of the skin should be excised as soon as one can decide that it is a new-growth.

2. That if any suspicion of present malignancy is entertained and local excision is thought adequate, a much wider incision of the tumor should be planned than has commonly been practiced in the past. And in support of these propositions I have selected, from a number of others, filed in the laboratory, three malignant cutaneous neoplasms with histories of their courses.

1. No. 1830 illustrates the danger of waiting for rapid growth and ulceration.

2. No. 2775 illustrates the same.

3. No. 2546 illustrates the futility of close excision.

Fannie Bernicker, No. 2775. Admitted Febuary 5, 1914, Roosevelt Hospital. History No. A4692. Chief complaint, sore on left heel and swelling in left groin. Six months ago, patient first noticed a small reddened swelling on left heel. There was some tenderness and the skin was rubbed off, and there was occasional bleeding but no pus. The swelling did not grow perceptibly larger but the surface became ulcerated and did not heal and there developed little black nodules about the ulceration. Three weeks ago, she went to Vanderbilt Clinic. She was seen by Dr. Brewer, who made a diagnosis of papilloma. The entire area was excised and the specimen sent to Dr. Clarke (January, 1914) who made a diagnosis of melanocarcinoma.

The outer margins healed, but the central part remained an ulcerating area. Since the excision of the mass in the foot, the patient has noticed presence of small nodules in the left groin, associated with sensations of drawing and pressing in the inguinal region and indefinite pain in the leg. She had no difficulty in walking, but believes she has lost a little in weight.

Examination of left heel, inner aspect, shows an ulcerating area about the size of a five cent piece. The edges are slightly raised and show small dark areas with brown pigment. On the skin, in the

immediate neighborhood, are three raised pigmented nodules.

In left groin are palpable two distinct, firm masses about the size of an English walnut; not red or tender, no fluctuation; seem firmly attached to deep structures. Few small palpable kernels in right groin.

First operation Febuary 6, six months after discovery of growth. Two glands excised and sent to laboratory for frozen section. Report chronic inflammation. Further examination of glands showed melanocarcinoma.

Second operation, Febuary 16. Amputation at hip done under the impression that there was yet no metastasis in glands.

A letter from Dr. S. Pollitzer to Dr. Russell of the Roosevelt Hospital, received July 25, 1914, twelve months after tumor was first noticed, six months after first excision reads:

> I learn from Dr. Brewer that a case which I saw recently had been under your care at the Roosevelt Hospital last January. An elderly woman, Mrs. Bernicker, had a malignant growth near the ankle. You amputated at the hip-joint. Within a month of her discharge from the hospital, as nearly as I can get the facts, she began to develop little tumors under the epidermis. When I saw her, a few weeks ago, she had about fifty such nodules, varying in size from a small shot to a walnut, freely movable, scattered over the integument of the trunk and neck; color of skin normal. I excised one of these tumors and enclose a section.
>
> The woman complains of various internal pains. No visceral lesions can be made out.

Skin nodules July, 1914, show a small focal area forming a definite tumor of epitheloid cells with supporting fibrous stroma. No pigment. Dr. Pollitzer reports that she died, date unknown.

Henry Kelly, 73 years old. No. 2546. Epithelioma of elbow region; metastasis in axillary lymph nodes. Death from visceral metastasis and spinal metastasis twenty-three months after excision of primary growth and, about twenty-five months after it began to grow rapidly.

Primary History. May 22, 1913, from Vanderbilt Clinic. Fungating mass 1⅛ inches in diameter on outer side of left forearm just below elbow. Commenced three years ago as a small mole. Grown to present size in two months, i. e., rapid growth for two months.

Sent to the Roosevelt Hospital from Vanderbilt Clinic, January, 1914, (eight months after excision of primary growth on arm). Then had mass of stony hard enlarged nodes in left axilla attached to deeper part. On operation nodes found not adherent to sheath of axillary vein. Nodes excised as thoroughly as possible. Wound healed ***per primam.***

March, 1914 (two months later) no plapable recurrence in axilla but he spit up a little blood and complains of occasional sharp pain in left shoulder region. (Query—Lung metastasis, or exacerbation of chronic bronchitis?)

April, 1914, (three months later). Recurrence (local) noted in axilla. On operation, gristly hard mass found adherent to sheath of axillary vein. Mass excised as completely as possible. (Vessels should have been removed also.) Wound healed ***per primam.***

July, 1914, (six months later). Second local recurrence was observed in *scar* and deep axilla. Dr. Hotchkiss operated. A mass was found involving the axillary vessels which were almost completely surrounded by it and so compressed as to be nearly obliterated. Neoplasm and about four inches of axillary vessels removed ***en masse.*** Wound never entirely healed.

September, 1914, (8 months later). The patient complained of pain in both shoulders and sides of chest.—(Query—Spinal metastasis?) Some induration of margin of unhealed wound. Loss of flesh and strength noted. Codeine ¼ grain p. r. n. begun.

October, 1914, (9 months later). The patient was suffering much pain. General condition decidedly cachectic. Evident local recurrence in unhealed suppurating skin wound and one nodule elevated and size of hazel nut in anterior axillary fold and similar one in posterior fold. Now taking morphine sulphate 1½ grain every day.

December, 1914, (11 months later). Death rather sudden but with no definite ascertainable symptoms of hæmorrhage or embolus. He had been taking less and less nourishment lately. Not able to leave bed past three days.

Bertha Vanderen, age 55 years, German, No. 1830. Sixteen years ago (after childbirth) the patient noticed warts on right side of forehead which were dark colored. The skin around them gradually became dark. A few months ago, lower wart began to grow high and its top to ulcerate. Fourteen days ago the patient noticed a lump on the right cheek, this has increased in size and become tender. Two or three other small lumps also appeared in neck below the angle of jaw. One slightly tender. On right side of forehead, just below the hairline, is a dark brown area about two inches in diameter, which looks like a birthmark. Near the center is an ulcerated, papillomatous growth nearly one-fourth of an inch in diameter with considerable purulent discharge. It is friable and bleeds easily. Another papilloma appears in upper anterior part of the dark area, but this is smaller and not ulcerated. In front of the auricle is an oval, smooth, tender mass (apparently parotid lymph node) about one-half by three-quarters inch, and below the angle of the jaw are several others.

On the second day after admission, signs of suppuration appeared on the neck and an incision was made. The parotid node was smaller and softer.

On the twelfth day after admission the area on the forehead was excised.

On the forty-second day the lump in the parotid was excised.

About three months after excision of the primary growth, a recurrence was noted about the excised

area. Seven months later, recurrence in neck. An attempt was made to remove this, but it was too deep and involved great vessels and nerves. From this time on, growth became very rapid, finally causing constant, severe pain, dyspnœa and dysphagia. Many small local recurrences dotted her forehead and right side of face.

Nine months after the original operation (about eleven months after tumor began to grow fast) a block dissection of neck done for relief of dyspnœa. Patient died on operating table.

With these three fatal examples before us of the many mistakes that have been honestly recorded, and bearing in mind the ease and safety of early removal of skin tumors, is it not fair to ask the general practitioner to forget the minute differences between the ten varieties of warts and remember only that, of cutaneous neoplasms in or upon the skin, a large percentage are or will become malignant?

A source of chronic irritation removed, a precancerous lesion excised is more valuable by far than many a treatment of developed cancer if there be any truth in the old adage that "an ounce of prevention is worth a pound of cure."

FURTHER STUDIES IN POSTOPERATIVE PNEUMONITIS[1]

By Captain MATHER CLEVELAND, M.C., U.S.A.
Evacuation Hospital No. 10

DURING the years 1915 and 1916, the subject of postoperative pneumonitis at the Presbyterian Hospital was carefully studied by Whipple (1) and reported by him in SURGERY, GYNECOLOGY and OBSTETRICS, January, 1918. The work has been continued for another year for comparison with the statistics of the preceding two years and also to observe the effect of certain prophylactic measures which had been instituted. A special analysis sheet has been used in each case of postoperative pneumonitis to insure a uniformity in ascertaining data. A copy of this sheet is again published with this paper since it shows the line along which our investigations have run and it may be of interest in the development of comparative work by others (Fig. 1).

There has recently appeared in SURGERY, GYNECOLOGY and OBSTETRICS, a very comprehensive study of postoperative pulmonary complications by Cutler and Morton (2). A considerable part of this work deals with pneumothorax, mediastinitis, and pulmonary embolism of mechanical origin, and which of necessity does not come within the scope of this present article, dealing only with inflammatory conditions of the lungs following surgical operations. It will be interesting to contrast certain of the statistics of Cutler and Morton relating to postoperative pneumonia with those of the 1915-1916, and 1917 series of the Presbyterian Hospital.

Previous to Whipple's work there had been reported no series of postoperative pulmonary inflammations in which the bacteriology had been carefully studied. Roentgenography as a routine procedure in all cases had likewise been neglected and the bedside history analysis of the complication had been very meager. With these facts lacking, any work on postoperative pneumonitis must be very incomplete.

It seems advisable to divide quite arbitrarily, postoperative pneumonitis into at least three types.

1. The true postoperative pneumonia, often called ether pneumonia: a disease coming on within the first few days after operation, accompanied by cough, rise in temperature, usually due to some exposure.

2. Embolic pneumonia, occurring at any time after operation and as far as is known, one of the accidents of the postoperative course.

3. Terminal pneumonia, occurring usually as an incident in patients *in extremis* after a short or protracted postoperative course.

[1]Under grant from the Harriman Research Fund.

The Presbyterian Hospital
IN THE CITY OF NEW YORK

Ward..... *History No.*.....

Name.....*Age*.....*Division*.....

Operation
Operator, Dr. **Anæsthetist** **Time of Anæsthesia**
Untoward Symptoms Occurring During Anæsthesia:
Cyanosis (1), Vomiting (2), Excessive mucus (3), Aspiration of vomitus (4).
History of Recent Concurrent Respiratory Trouble Before Entering Hospital:
Recent cold (1), Cough (2), Bronchitis (3), Tonsillitis (4).
Exposure during examination (1), following admission bath (2), from operating room to ward with length of time (3), after operation till patient is in bed (4), in ward after operation (5).
Mode of Life and Habits of Patient:
Works in-doors (1), out-doors (2), wears cotton underwear (3), woolen underwear, one suit (4), more than one suit (5), takes cold baths (6), hot baths (7).
Number of blankets patient sleeps under, 1, 2, 3, 4, etc.
Patient Has on Admission, Physical Signs of Inflamed Condition of Respiratory Tract:
Rhinitis (1), Tonsillitis (2), Pharyngitis (3), Laryngitis (4), Bronchitis (5), Pulmonary Tuberculosis (6).
Cardio Vascular and Renal Systems on Admission:
Normal (1), Valvular Disease (2), Arrhythmia (3), Tachycardia (4), Insufficiency (5), Thickened Peripheral Arteries (6), Hypertension with Blood Pressure (7), Nephritis (8).
Disease:
Symptoms of Onset in Order of Appearance, With Date (underline important one):
Cough (1), Pain in chest (2), Dyspnœa (3), Chill (4), Rapid respiration (5), Cyanosis (6), Temperature (7), Rusty sputum (8).
Marked Symptoms during Attack (underline important one):
Cough (1), Pain in chest (2), Rapid respiration (3), Cyanosis (4), Rusty sputum (5), Herpes (6).
Temperature Remained Over 102° F. (note number of days, 1, 2, 3, 4, 5, etc.):
Blood Count, Date **W. B. C.** **Differential**
Signs of Congestion or Consolidation Made Out in,
R. U. L. (1), R. M. L. (2), R. L. L. (3), L. U. L. (4), L. L. L. (5), Entire Right (6), Entire Left (7).
Congestion. Date
Consolidation, lobular, (1).
Consolidation, lobar, (2).
X-ray shadow with no signs of consolidation. Date
Signs of consolidation with no X-ray shadow. Date
X-ray shadow and signs of consolidation agree. Date
X-ray showed shadow before signs of consolidation appeared.
X-ray showed wedge shaped shadow. Date
No X-ray taken.
Cardio Vascular and Renal Systems During the Disease.
Blood Pressure:
Pulse: Strong (1), Weak (2), Regular (3), Irregular (4), Rate
Heart: Arrhythmia (1), Fibrillation, etc. (2), Tachycardia (3), Insufficiency (4)
Kidneys:
Albuminuria (1), Nephritis (2).
Complications:
Empyæma (1), Lung abscess (2), Sero-fibrinous pleurisy (3), Otitis (4), Peritoneal abscess (5), Pneumococcus peritonitis, local (6), Diffuse (7).
Postoperative Respiratory Disease Other Than Pneumonia:
Bronchitis (1), Pleurisy (2), Embolus (3).
Bacteriology:
Pneumococcus I (1), II (2), III (3), IV (4), Non-hæmolytic Streptococcus (5), Hæmolytic Streptococcus (6), Bacillus Influenza (7), Friedlander Bacillus (8), No organism recovered (9).
Ante-operative sputum. Date
Postoperative sputum. Date
Blood culture. Date
Agglutinations.
Blood with sputum Ante-operative (1), Postoperative (2).
Prophylactic Measures:
Pneumonia bed jacket (1), Digitalis M XV 4 i. d. (2), Bath Rules (3), Counter irritation with liniments (4)
Treatment:
Open air (1), Serum (2), Croup tent (3), Digitalis (4), Other stimulation.
Final Result: **Autopsy:**

Fig. 1.

This is more often discovered by the pathologist than by the clinician. There are often no physical signs, usually no abrupt rise in temperature and no cough. This type of pneumonia is merely mentioned in this article as a matter of interest and will be summarily dismissed. It is outside the scope of any work attempting to consider the prevention of postoperative pneumonitis. During the year, five of these terminal pneumonias, usually bronchopneumonia, were found by the pathologist in autopsies on

surgical patients. None of them presented clinical signs.

There were noted several cases of postoperative bronchitis during the year. These were uniformly mild, clearing up within two or three days.

Postoperative pleurisy with effusion occurred once. The patient had severe pain in the chest with a temperature of 103.° Signs of fluid appeared at the right base and 200 cubic centimeters were aspirated.

In this present work only pneumonitis *per se*, exclusive of those terminal pneumonias not recognized clinically, will be dealt with, in order to compare results with those obtained by Whipple. The embolic pneumonias will be considered separately, frequently contrasting them with the postoperative pneumonias:

INCIDENCE

The postoperative pneumonitis encountered at the Presbyterian Hospital during 1917 is divided as follows:

Postoperative pneumonia	58
Postoperative embolic pneumonia	7
Total cases	65

Out of 1940 operations during the year, this gives a morbidity percentage of 3.3, which is high, but at the same time there has been a disappearance of the unexplained so-called "postoperative reaction." Every case with a temperature of 101° or over after operation, without the presence of known infection, has been carefully examined for signs of pulmonary involvement and has been radiographed. The latter procedure not infrequently gives the clue to the rise in temperature some time before physical signs appear. In a number of cases these signs never do appear. The increasing morbidity percentage of postoperative pneumonia in our series is, we are convinced, a tribute to greater diagnostic accuracy and keener observation rather than any actual increase. The physical signs in this series have in no instance been discovered without turning the patient and listening at the base of the lungs.

Referring to Table I, the relation of appearance to (1) sex, (2) season and (3) age, may be appreciated.

TABLE I

	Postoperative Pneumonias Number of Cases	Embolic Pneumonias Number of Cases
Sex		
Males	45	4
Females	13	3
	58	7
Months of the year		
January	5	1
February	7	
March	7	1
April	7	
May	6	1
June	2	
July	2	1
August	6	1
September	4	1
October	1	
November	5	1
December	6	
	58	7
In decades		
1– 9		
10–19	8	
20–29	17	
30–39	13	5
40–49	8	
50–59	8	2
60–69	4	
70–79		
	58	7

1. *Sex.* While the embolic pneumonias were nearly evenly divided between men and women, the postoperative pneumonias were present in men four times as frequently as in the women. It may possibly be due to the fact that the women are less exposed to coughs and colds than men and that the oropharynx is not so chronically inflamed in women.

2. *Season.* The influence of the season on the occurrence of the postoperative pneumonias is seen when 65 per cent, practically two-thirds of the cases, occurred during the six winter and spring months. No explanation for the relatively large number of postoperative pneumonias in August can be advanced unless it was due to a general relaxation of phrophylactic vigilance toward the end of the summer. The embolic pneumonias were widely distributed, no two within the same month. This is what might be expected.

3. *Age.* Fifty-two per cent of the cases of postoperative and embolic pneumonia occurred in the third and fourth decades, agreeing almost exactly with Whipple's findings. Only four of the patients were over 60 years of age. These figures differ quite materially from those of Cutler and Morton. In their series of 40 postoperative pneumonias, 67 per cent were over 40 years of age.

PREDISPOSING FACTORS

Among the predisposing factors of postoperative pneumonia are the following: (A) coughs, colds, etc., previous to or on admission to the hospital; exposure to cold while in the hospital; (B) condition of the patient; (C) type of operation; (D) anæsthesia.

A. *Coughs, colds and exposure.* The great importance of this subject warrants a detailed discussion (see Table II). Of the sixteen patients who gave a history of having had a cold before admission, three had previously been sent home to recover and returned apparently cured. None of these patients showed any physical signs of inflammation of the respiratory tract. The risk of catching cold from exposure, following the admission bath, has been largely eliminated during the year. Two women patients caught cold from failure of their hair to dry properly after their bath. The electric dryer was installed directly after this. Exposure after operation from insufficient covering, draughts from windows, etc., claims its fair share of victims. Some patients, owing to restlessness when coming out of anæsthesia, are of course very difficult to keep properly protected against exposure. The five patients entering the hospital with acute inflammation of the respiratory tract were exceedingly poor risks from the standpoint of pneumonia, but they were all emergency operations and the surgeon was left no choice in the matter. The low grade inflammations of the respiratory tract noted, range from hypertrophied tonsils to chronic bronchitis and are doubtless important predisposing factors. These chronic respiratory ailments are extremely prevalent and the only way to be sure of their importance would be to note them carefully in the physical examinations of all patients about to undergo operation and see what percentage developed postoperative respiratory disease.

TABLE II

Patients giving history of recent cold or cough, 2 days to a month before admission	16
Patients giving history of exposure following admission bath or change from heavy underwear to their ward clothing	4
Patients giving a history of exposure from open windows, insufficient covers, etc., after operation.	11
Patients having on admission physical signs of an acute inflammation of the respiratory tract, acute bronchitis, acute tonsillitis, acute rhinitis, etc.	5
Patients having on admission physical signs of low grade or chronic inflammation of the respiratory tract, such as hypertrophied tonsils, chronic bronchitis, red throat, etc	18
Total cases	54

B. *Condition of patient.* This series offers a relatively small number of cases of the aged and infirm, but there are several instances of those worn down by the cachexia of malignancy or constitutional disease, falling an easy prey to postoperative pneumonia. Under the heading of condition of the patient, it will be well to consider the average type which comes to operation at the Presbyterian Hospital. Of the 65 cases in this series, the occupation of 62 was ascertained. Of these, 53 worked indoors while only 9 worked in the open air. The great majority stated that they changed from heavy to light underwear according to the season and took hot or cold baths by the same token. In regard to general physical condition, 59 of the patients were examined and 78 per cent of these were recorded as having normal cardiovascular and renal functions in so far as routine physical examinations and urinalysis showed. Six patients had albuminuria, three with casts; one patient had slight cardiac insufficiency and another hypertension of 195-105. It will thus be seen that roughly speaking, these patients were in good physical condition, though as a class they are quite susceptible to changes in temperature.

C. *Type of operation* (Table III). Eighty-six per cent of the operations performed in this series were cœliotomies and a majority of these were of a relatively simple nature,

TABLE III.—SUMMARY OF OPERATIONS

	Cases
Hernia, inguinal and ventral	19
Appendicectomy	16
Pelvic-gynecological	10
Gall-bladder	7
Exploratory cœliotomy	2
Gastrostomy	1
Enterocolostomy	1
Incision and drainage of abscesses (extraperitoneal)	3
Mastectomy for carcinoma	1
Skingraft following mastectomy	1
Thyroid, excision of cyst	1
Decompression, fracture of skull	1
Phlebectomy	1
Laminectomy	1
Total acess	65
Total cœliotomies	56

such as hernia repair and removal of simple appendix. These findings lend added weight to the argument that those operations which tend to limit respirations by splinting the abdominal or thoracic muscles, predispose to postoperative pneumonia. In Whipple's series 90 per cent of the operations were cœliotomies. Cutler and Morton likewise ascribe to restricted respiration the high percentage of postoperative pneumonia following cœliotomy, particularly after epigastric incisions. In this series there were eight epigastric incisions, which is certainly a relatively high percentage of the total of such incisions.

D. *Anæsthesia.* Time was when the entire blame for postoperative pneumonia was laid at the door of anæsthesia. "Ether pneumonia" was a term well known and widely circulated. The surgeon was only too willing to shift the blame to the anæsthetist or consider the pneumonia as one of those unavoidable accidents of the postoperative course. That the anæsthetic *per se* does not cause the pneumonia is no longer doubted. The irritation of the anæsthetic does, however, prepare the way for organisms already present in the upper respiratory tract by lowering the resistance of the lung tissue. The commonest organism present in the mouth is the pneumococcus group IV, which is, indeed, the one most commonly responsible for postoperative pneumonia. Patients markedly obstructed with mucus during the anæsthetic may very easily aspirate a considerable quantity loaded with organisms from the mouth. In six cases it was noted that there was considerable mucus, causing obstruction to breathing. Cyanosis due to obstructed respirations was present in 14 cases. This condition is simply an indication of insufficient aeration or oxygenation of the blood and a congestion of the pulmonary vessels and favors a descending infection according to Whipple. The anæsthetic of choice has been gas and ether, by the closed method with the Bennett apparatus, though recently there has been a trend toward ether by the drop method. This latter certainly tends less toward cyanosis. Ether has rarely been used during the year where there was any inflammatory condition of the respiratory tract that was considered a risk from the standpoint of postoperative pneumonia. Gas and oxygen, local anæsthesia and chloroform are used in such cases. Table IV, shows the number of cases developing pneumonia after the various anæsthetics. The number following chloroform is large in proportion to the total number of chloroform anæsthesias, but these cases were almost invariably bad risks.

TABLE IV

	Cases
Gas-ether sequence, closed method	44
Gas-oxygen-ether	7
Ether, drop method	7
Ether-intrapharyngeal	3
Gas-oxygen	2
Chloroform	2
Total cases	65

The cases were divided among the various anæsthetists, professional and members of the house staff about in proportion to the number of anæsthetics given by each. The length of anæsthesis had very little, if any, influence. The shortest in the series was three minutes and the longest two hours and twenty minutes, with an average of sixty-two minutes.

Before further detailed consideration of the postoperative pneumonias encountered in this series, the routine followed in their study should be understood. A pre-operative sputum examination was made on all patients. As soon as a patient came under suspicion of postoperative pneumonia, whether for a sudden rise in temperature, cough or

pain in the chest, with or without the presence of physical signs, the following measures were taken: (1) postoperative sputum examination; (2) blood count, leucocytes and differential; (3) blood culture; (4) urine for pneumococcus precipitation test (this latter has been in use only since September 1917); (5) roentgenograph of lungs.

The type of postoperative pneumonia which it is our object to emphasize, has most frequently occurred in otherwise healthy young adults. In our 58 cases an attempt was made to subdivide them into lobar and lobular with the aid of the roentgenograph to check up physical findings. This is a rather crude method of stating the extent of the consolidation. Twenty-six of the cases were lobular and twenty-eight lobar; four were undetermined.

SYMPTOMATOLOGY

(SEE TABLE V)

A typical case of postoperative pneumonia has very definite characteristics of its own. The average time of onset is 48 hours after operation, though that of 55 per cent of the cases occurred within 24 hours after operation. A sudden rise in temperature to about 103° or cough, or less frequently pain in the chest, may mark the onset. There is rarely an initial chill. During the course of the disease the temperature falls by lysis within a day or two. In this series it remained over 102° for an average of only 2.5 days. The most important symptom during this period is cough, as shown in 66 per cent of the cases, followed by rapid respiration and pain in the chest, respectively. In the meantime signs of consolidation usually appear at either base and the roentgenogram shows the shadow. This disease *per se*, unaccompanied by cachexia, debility, or by any other constitutional disturbance, has not proven itself a dangerous complication in this present series.

In strong contrast to the foregoing, embolic pneumonia has likewise very definite earmarks. The average day of onset was the twelfth day after operation. The most important symptom of onset was pain in the chest in six out of the seven cases. The temperature falls by lysis after persisting for seven or eight days. The pain in the chest continues as the most important symptom throughout. Cough is usually present and in about one-third of the cases blood-tinged sputum was noted. The signs in the chest are those of consolidation often preceded by pleuritic friction rubs. The roentgenograms checked up the physical findings in every case in which it was employed.

TABLE V.—SYMPTOMS

Symptoms of Onset	Postoperative Pneumonias 58 Cases	Embolic 7 Cases
Cough	41	1
Temperature	39	6
Pain in chest	19	7
Rapid respiration	32	1
Cyanosis	10	1
Dyspnœa	9	1
Chill	3	1
Rusty sputum		1
Average day of onset after operation	2.4	7
Symptoms during attack		
Cough	44	5
Pain in chest	16	5
Rapid respiration	40	5
Cyanosis	6	2
Dyspnœa		
Rusty sputum		2
Herpes	1	1
Temperature remained over 102°.		
Never reached 102°	11	
1 day	11	2
2 days	17	0
3 days	4	1
4 days	7	
5 days	3	1
6 days	2	1
8 days	1	0
9 days	1	0
10 days	1	
15 days	0	1
19 days	0	1

PHYSICAL SIGNS

The physical signs of consolidation of postoperative pneumonia, in our experience, have invariably been found in one or the other lower lobe, usually at the extreme base. These signs may be easily missed unless the patient is turned over on his side and the bases are carefully searched with percussion and auscultation. Any patient can be turned after operation without danger if proper care and gentleness are exercised. In the postoperative pneumonias the signs usually appear with the onset or shortly after, in about 70 per cent of the cases within the first 24

hours. In the embolic pneumonias of this series the signs of consolidation were a little slower to appear, 43 per cent occurring from the third day to the fifth day after the onset of the disease. The right lower lobe was most frequently involved, being solely affected in 27 out of the 54 cases of postoperative pneumonia and in conjunction with the left lower lobe in 10 or more cases, while the left lower lobe was involved alone in but 15 cases. Among the embolic pneumonias the bases were also the chosen sites, though in one case the right upper and right middle lobe were involved. These signs frequently appeared first as a slight congestion with a few râles, followed by dullness and later, by frank bronchial signs of consolidation. They are often fleeting, clearing up within a day or so in distinction to the regular medical lobar pneumonia, due to pneumococcus groups I, II, or III.

In the meantime, as a rule, the heart shows but very slight signs of embarrassment in a typical postoperative pneumonia. The pulse is always slightly increased in rate, though of good quality and regular. There was marked irregularity of the pulse in but five cases in this series, three of which proved fatal. Tachycardia was noted twice and an auricular fibrillation once. The blood pressure, recorded in 31 cases was quite within normal limits of systolic and diastolic pressure, in all except one case of hypertension and three of slightly diminished tension.

TABLE VI.—PHYSICAL SIGNS AND ROENTGENOGRAPHIC FINDINGS

	Postoperative Pneumonias	Embolic
Signs of consolidation elicited	54	7
Signs consolidation not elicited	4	0
Lobar	28	3
Lobular	26	4
Right lower lobe	27	3
Left lower lobe	15	2
Right and left lower lobe	10	1
Entire left side	1	
Left lower lobe and left upper lobe	1	
Right upper lobe and right middle lobe		1
Number of cases roentgenographed	51	5
Number of cases not roentgenographed	7	2
X-ray shadow with no signs of consolidation	4	
Signs of consolidation with no X-ray shadow	6	
X-ray shadow and signs of consolidation agreed	41	5
X-ray shadow present before signs appeared	6	
Roentgenographic shadow wedgeshaped	7	

THE ROENTGENOGRAM IN RELATION TO SIGNS OF CONSOLIDATION

Roentgenography was employed as an aid to diagnosis in 56 out of the 65 cases. It has been our purpose to subject every patient suspected of postoperative pneumonia of either variety to this procedure. Of the nine who escaped, four were private patients on whom permission was withheld. The remaining five failures represent three patients considered too sick to move and two overlooked through careless failure to carry out orders.

The importance of roentgenography cannot be overestimated as a diagnostic procedure in the study of postoperative pneumonia. In four cases there could have been no diagnosis made without roentgenography, for the signs of consolidation never appeared though the shadow was perfectly frank, and the customary symptoms were present. The shadow in the lung not infrequently precedes the advent of physical signs of consolidation. With the knowledge that a shadow is present a careful search for the signs is continued until they may be found.

In a certain number of cases there are signs of consolidation present with no shadow displayed by roentgenography. In this series there were six of these cases. In three the signs were at the left base where a small shadow of consolidation might easily be obscured by the heart shadow. The remaining three were at the right base, but one of these was not roentgenographed until four days after the signs appeared, which was evidently too late to show a shadow. Just as the physical signs of consolidation are transitory, so is the shadow, and there should be no delay in roentgenographing the patient under suspicion. The shadow appearing at the right base offers better opportunity to study its contour. In seven cases it was noted to be wedgeshaped with the base of the wedge

pointing downward and outward. This peculiarity has been mentioned by Whipple and others.

In the great majority of cases the roentgenogram agrees with the physical signs, proving it a valuable and conclusive aid in the diagnosis. The details of the roentgenographic shadow in relation to physical signs may be seen in Table VI.

COMPLICATIONS

Complications directly due to the pneumonitis arose in six cases of the postoperative and two of the embolic pneumonias. The most frequent of these complications was serofibrinous pleurisy occurring in three postoperative pneumonias. In none of these was an organism recovered on culturing the fluid. Another postoperative pneumonia developed a serofibrinous pleurisy from the fluid of which a gram-positive diplococcus was recovered. This same patient also had a marked localized pneumococcus peritonitis and was jaundiced. Jaundice occurred in one other patient. These pleural effusions mentioned were uniformly small and relatively unimportant.

The most serious complication noted among the postoperative pneumonias was a lung abscess following a delayed resolution for five weeks. This patient eventually recovered without operative treatment.

The embolic pneumonias had far more spectacular complications. One patient with a hæmolytic streptococcus in the blood culture and sputum developed an empyema which was drained by rib resection and thoracotomy. The pus likewise yielded a pure culture of hæmolytic streptococcus. A second embolic pneumonia with a staphylococcus aureus present in his blood culture developed a small pleural effusion. The fluid removed was tinged with blood which very probably accounts for the presence of the staphylococcus aureus in the culture. The effusion soon cleared up.

BACTERIOLOGY

In the study of postoperative pneumonitis, the greatest importance has been placed upon this aspect of the work. We have been fortunate in having the services of a thoroughly scientific bacteriologist, Miss Marion Olmstead, who has followed the subject of postoperative pneumonia during the entire three years covered by the present work and that of Whipple. We have been particularly anxious to learn what organism or organisms are responsible as direct causative factors in the disease. This has meant a large increase in the routine work of the bacteriologists, but has been carried out with a splendid spirit of co-operation. The pre-operative and postoperative sputum examinations and blood cultures and blood agglutination should have been done in every case as was intended. The failures represent a certain carelessness on the part of the nursing and house staff, and include a few private patients on whom permission to obtain specimens was withheld. The urine precipitation test was not adopted until September, 1917, but since then has been tried consistently.

1. *Sputum* (see Table VII). A little less than half of the pre-operative sputum examinations showed no pneumococcus present, but after operation this was reduced to one-sixth. Of the organisms present the pneumococcus group IV holds the pre-eminent place, being present in 32 per cent before operation and in 57 per cent after operation in cases developing postoperative pneumonitis. The other groups of pneumococcus were all represented except group I. Hæmolytic streptococcus and bacillus mucosus capsulatus also were occasionally found. In 17 cases the pre-operative and postoperative sputum examinations showed the same organism, 10 of these showing pneumococcus IV.

2. *Blood culture.* This test was made in fifty-one cases of postoperative pneumonia and found positive in but three. Pneumococcus group IV was present in the blood of one patient, non-hæmolytic streptococcus in that of another, both of whom recovered, and finally pneumococcus group III was found in the blood of a third who died.

In the embolic pneumonias with two positive blood cultures out of seven, the incidence was much greater in proportion, as might be expected. In one case hæmolytic streptococcus was present in the blood both before

TABLE VII.—SPUTUM EXAMINATIONS

Postoperative Pneumonias	Total Cases Examined	No. Organisms Recovered	Pneumococcus IV	Pneumococcus III	Pneumococcus II Atypical	Pneumococcus II	Pneumococcus IV, III	Hæmolytic Streptococcus	Bac. Mucos. Caps.	Bacillus Muc. Caps. Pneumoc. IV.
Pre-operative sputum	46	20	15	4	4	1		1	1	
Postoperative sputum	54	7	31	4	4	1	1	2	3	1
Pre- and postoperative coincided with same organisms	17		10	2	2	1		1	1	
Embolic Pneumonias										
Pre-operative sputum	5	3	1	1						
Postoperative sputum	7	2	3	1				1		
Pre- and postoperative coincided with same organisms	2		1	1						

TABLE VIII.—PNEUMOCOCCUS AGGLUTINATION

Case No.	Pre-operative Sputum	Postoperative Sputum	Agglutination	Test
1	No organism	Pneumococcus IV	+	3rd
2	Not examined	Pneumococcus IV	+	3rd
3	No organism	Pneumococcus IV	+	2nd
4	Pneumococcus IV	Pneumococcus IV (different strain)	With postoperative strain	4th
5	Not examined	Pneumococcus IV	+	3rd
6	Pneumococcus II (stypical)	Pneumococcus II (atypical)	+	4th
7	Pneumococcus II (atypical)	Pneumococcus II (atypical)	+	3rd
8	Pneumococcus IV	Pneumococcus IV	+	1st
9	Not examined	Pneumococcus IV	+	3rd
10	Pneumococcus IV	Pneumococcus IV (different strain)	With pre-operative strain	4th

and after the operation which merely consisted of incision and drainage of abscesses. In the second case staphylococcus aureus was found in the blood of a paraplegia with a huge sacral decubitus. The operation had been an exploratory laminectomy. The blood culture remained positive for weeks after the pneumonia subsided.

3. *Pneumococcus agglutination.* This test depends upon the development in the serum of the individual suffering from postoperative pneumonia of specific agglutinins, which will act upon the organism recovered from the pre-operative or postoperative sputum, or both, causing agglutination. The reaction is quite specific and its presence shows that the patient has developed a reaction against the organism. The only organisms agglutinated by this test were pneumococcus group IV and pneumococcus group II (atypical). This atypical group II is said to be closely allied to the group IV. The test is seldom positive at the beginning of the disease, but if it be repeated at three day intervals, three or four times, it will become positive, usually with the third or fourth tests, i.e., the ninth or twelfth day, if the patient develops the reaction at all. This probably indicates the length of time during which the individual is acquiring his agglutinins. When pneumococcus group IV, recovered in the postoperative sputum, is of a different strain from that in the pre-operative sputum, if the serum develops the power of agglutination, it will be specific for either one strain or the other, but not for both. The agglutination test was performed in forty-two cases of postoperative pneumonia with positive results in about 24 per cent. None of the embolic pneumonias showed a positive agglutination. Table VIII shows relation of sputum to agglutination and time required for reaction to develop.

4. *Urine precipitin test.* This is probably an equally specific test depending upon the precipitation by a protein in the urine of the organism recovered in the pre-operative or

TABLE IX

Hospital	No. of Cases	Pneumonia Morbidity	Morbidity Percentage	Mortality	Mortality Percentage	Mortality Per Cent of Morbidity
Mayo (Beckman) 1910 (3)	3657	10	0.27	5	0.14	50.0
Mayo (Beckman) 1912 (4)	5835	19	0.32	6	.10	31.5
Mayo (Beckman) 1913 (5)	6825	27	0.39	0	0.0	0.0
Roosevelt Hospital, N. Y., (L. S. B.) (6)	2612	23	0.9	7	0.26	30.4
New York Hospital, F. W. B. (7)	1413	15	1.06	7	0.50	46.6
Mass. General, E. C. C. L. J. J. M	3490	40	1.14	22	0.63	55.
Montreal General, Armstrong (9)	2500	30	1.20	22	0.88	73.3
Leipzig Laeven (8)	9755	180	1.8	113	1.15	63.
Presbyterian, A. O. W. 1915–16	3719	97	2.1	25	0.66	25.7
Presbyterian, M. C	1940	65	3.3	7	0.36	10.7

postoperative sputum. This test has only been tried during the last four of the twelve months during which this series runs. It was positive in five out of sixteen cases which is a somewhat higher percentage than the agglutination test. In one case in which the bacillus mucosus capsulatus was recovered in both pre-operative and postoperative sputum, the test was positive for pneumococcus group I, showing that although the sputum failed to demonstrate it, there must have been a group I infection. When the pre-operative and postoperative pneumococci were of different strains of the same group, the precipitation held for one strain only.

The result of the bacteriological investigation has been to establish the specificity of the causative organism in 18 out of 58 cases of postoperative pneumonias. In eleven of these the pneumococcus group IV was the causative organism. During the disease this organism was isolated from the sputum twice as frequently as all the other organisms combined. There can be but little doubt but that the pneumococcus group IV is in most instances the cause of that definite and distinct type of pneumonia already described and called in this instance, postoperative pneumonitis. The bacteriology of the embolic pneumonias presents a different aspect. In one instance the positive blood culture may be the cause of the pneumonia by a bacterial embolus. The pneumonia may possibly in another instance be the result of a secondary infection of an embolus already present in the lungs. The pneumococcus group IV was however, found most frequently in the sputum of pneumonias of this type as well as in that of the postoperative pneumonitis.

MORTALITY

In considering the mortality in postoperative pneumonia, attention should be paid to whether or not the patient died as a result of his pneumonia. There were seven deaths in the sixty-five patients, making the mortality 10.7 per cent. No one of these occurred where the pneumonia was the only complication, in other words no otherwise healthy patient undergoing operation died as a result of his pneumonia. Malignancy claimed three patients, one with carcinoma of the colon, another with carcinoma of the œsophagus and a third with carcinoma of the cystic duct. All of these were in very poor condition. A pulmonary embolus caused one death. Another patient died in a diabetic coma following incision and drainage of an alveolar abscess. A mastectomy in a patient sixty-five years of age, not in very good condition, resulted in a fatal pneumonia. The seventh patient died of inanition following a duodenal fistula rather than from the pneumonia. It is only fair to say that two other patients in the present series died in the hospital; one, a paraplegia with a positive blood culture, died of sepsis six weeks after the embolic pneumonia had subsided, the other died over a month after his pneumonia and from no associated condition. One of the most distressing tragedies of hospital experience is to see a young, healthy individual undergo a simple surgical operation and die of postoperative pneumonia. During the past year, we have fortunately been spared this, perhaps due to greater care in prophylaxis.

For the greater part of Table IX, the writed is indebted to Cutler and Morton.

The Presbyterian Hospital statistics have simply been added. As the above mentioned investigators have pointed out the statistics from the Mayo clinic can in no way be compared to those of a general city hospital, because their patients must be fit to stand railway journeys of varying distances. The low morbidity of this clinic is quite remarkable. Although the morbidity of postoperative pneumonia at the Presbyterian Hospital has been increasing during the past three years, the mortality percentage has been falling even more markedly. The present series shows the highest morbidity percentage in Table IX, but it shows also by far the lowest mortality percentage of morbidity. This leads to the question whether at the other clinics there might not have been other postoperative pneumonias not altogether frank clinically, which roentgenography and bacteriological investigations might have revealed.

TREATMENT AND PROPHYLAXIS

The following prophylactic measures have been instituted and followed out with considerable faithfulness during the past year.

1. Great care is taken to elicit a history of recent cold, cough, sore throat, etc., and in the physical examination the respiratory tract is given special attention. Patients with history of recent cough or signs of rhinitis, tonsillitis, pharyngitis, etc., are sent home to wait a week or two if their operation be one of choice.

2. In case of operations of necessity in patients with signs of inflammation of the respiratory tract, ether is seldom used, if it can be avoided. Chloroform, gas and oxygen, and local anæsthesia have been used with such patients whenever possible.

With the experience gained from Whipple's work on the problem, the following measures for prophylaxis were put in the form of rules for the nurses to observe:

1. The temperature of the bathroom for the routine admission bath must be 70° F.

2. No patient who has had his admission bath and is to be operated on the following day shall be allowed out of bed.

3. The hair of all female patients is to be thoroughly dried with an electric blower.

4. Before leaving operating room each patient shall be given a dry, warm night shirt and be carefully covered with sufficient blankets.

5. On arriving in the ward, a cotton pneumonia jacket shall be put on each patient.

6. Sufficient blankets must be provided and all draughts avoided.

7. As soon as the patient is conscious, a heavy woolen bed jacket is to be worn.

(The rules relating to blankets, bed jackets, etc., did not apply during hot weather.)

Two additional experiments in prophylaxis were tried:

1. All the patients of one male ward were given tincture of digitalis, 15 minims on admission and every four hours until they had 40 minims in an attempt to obtain a digitalis effect on the heart to combat pulmonary congestion during the operation.

2. All patients of another male ward had their chests rubbed with a turpentine camphor liniment immediately after operation.

Of these two measures the counter irritation seemed to be of some benefit and came into pretty general use throughout the hospital in cases where any respiratory trouble was anticipated after operation.

The treatment of postoperative pneumonia is almost entirely symptomatic. If it should be due to pneumococcus group I, serum is to be used. Fresh air by an open window and forced fluids were almost invariably used. Digitalis was used in 38 cases out of the 65, usually in the form of the tincture, though occasionally digipuratum or digalin was given intravenously. On rare occasions camphor or caffeine was given, but when such stimulation was indicated it was of doubtful benefit.

CONCLUSIONS

1. Coughs, colds, and other inflammatory conditions of the respiratory tract are the most important factors predisposing to postoperative pneumonia. Restriction of abdominal respiratory movements as a result of incision, postoperative distention, tight dressings, is also a definite factor.

2. Exposure of the patients to cold while in the hospital before, as well as after, operation, is responsible for a certain number of postoperative pneumonias.

3. The pneumococcus group IV is most frequently the inciting organism of postoperative pneumonia.

4. The urine of patients suffering from postoperative pneumonia frequently develops precipitins against the organism recovered in the pre- or postoperative sputum, while the blood develops agglutinins.

5. The pneumonia due to pneumococcus group IV is a definite clinical entity, differing from the pneumonia due to pneumococcus groups I, II or III.

6. The use of the roentgenogram in all cases of suspected postoperative pneumonia and the careful and constant search for physical signs will reveal more postoperative pneumonias than have hitherto been reported.

BIBLIOGRAPHY

1. Whipple, A. O. Surg., Gynec. & Obst., 1918, xxvi, 29.
2. Cutler, E. C., and Morton, J. J. Surg., Gynec. & Obst., 1917, xxv, 621.
3. Beckman. Collected Papers, Mayo Clinic, 1910, p. 594.
4. Ibid. 1912, p. 738.
5. Ibid. 1913, p. 776.
6. Booth, L. S. Med. Record, 1916, lxxxix, 582.
7. Bancroft, F. W. Ibid., 583.
8. Laewen. Zentralbl. f. Chir., 1907, iv, 96.
9. Armstrong, G. E. Brit. M. J., 1906, i, 1141.

HYDATIFORM DEGENERATION IN TUBAL PREGNANCY

A Report of Forty-Eight New Cases

By ARTHUR WILLIAM MEYER, M.D., Palo Alto, California
Department of Embryology, Carnegie Institution of Washington; and Department of Anatomy, Stanford Medical School

STRANGELY enough, the occurrence of chorio-epithelioma arising from tubal pregnancy seems to be better known and also better established than the occurrence of hydatiform mole within the tube. This is especially surprising in view of the stress laid especially by Marchand (1895) upon epithelial proliferation in cases of hydatiform mole, and in view of the fact that trophoblast formation and epithelial proliferation in general have been regarded as being greater in tubal than in cases of uterine implantation. This is illustrated well by such cases as that of Fellner (1903) in which it was found impossible to distinguish by histologic examination between the epithelial proliferation present in a case of tubal pregnancy and that from a chorio-epithelioma. It seems to me that from these circumstances alone one might expect hydatiform degeneration to be relatively more common in the tubes. Moreover, when it is recalled that experts still regard it as impossible to decide the question of malignancy or benignity in cases of suspected uterine chorio-epithelioma on the basis of histologic preparations alone, this surmise gains more in probability. The presence of hyperactivity in the trophoblast in many cases of tubal pregnancy as compared with the uterine, was confirmed also by personal observation, and if, as stated by Teacher (1903), chorio-epitheliomata arose from hydatiform moles in approximately 40 per cent of 287 cases, and according to Seitz (1904) and Frankel (1910) in 50 per cent even, the occurrence of hydatiform degeneration in tubal pregnancies can hardly be doubted because of this fact alone. Nevertheless, of the 7 cases of tubal hydatiform moles cited by him, Werth (1904) regards only the case reported separately by von Recklinghausen (1889) and by Freund (1889) as well authenticated. Werth reserves judgment, however, on the case of Matwejew and Sykow (1902), a report upon which was accessible to him, and to me, in a short review only. Seitz, however, accepted the short review of this case as convincing, nor questioned the case of Otto (1871), or that of Wenzel (1893) but incorrectly credits Wenzel with 2 cases. Werth, on the contrary, regarded these last 2 cases, and also that of

Croom (1889), which is accepted also by Veit (1910) as genuine, as undoubted instances of "simple hydropic degeneration of the connective tissue of the villi so common in aborted chorionic vesicles, both from the tubes and from the uterus." But Werth unfortunately does not state just what he means by simple hydropic degeneration. Since he speaks of it as common in aborted ova, one may conclude that he refers to changes in the chorionic vesicle while still within the uterus, after its complete detachment from its implantation site. For want of a better term such changes may, I presume, be spoken of as maceration changes, although they may not occur under sterile conditions. However, I do not thereby imply that these changes are similar under sterile and under putrefactive conditions. They undoubtedly differ.

Since Werth speaks of simple hydropic degeneration in aborated ova, he does not, I take it, refer to a dropsical condition of the villi possibly due to an obstruction of the venous return, for such a condition necessarily would be rare and not common. Moreover, this condition of necessity would have to arise before and not after the death of the embryo and of detachment of the chorionic vesicle. As in one of the cases of Hiess (1914), such a specimen also should contain blood-vessels, for as emphasized also by Ballantyne (1913) the hydatiform villus not merely is an œdematous villus.

That any one at all familiar with hydatiform degeneration in its earlier, as well as its later forms, could upon gross and microscopic examination, confuse such a condition with maceration changes in a fairly well-preserved specimen in any but its very earliest or very latest stages does not seem possible to me. Normal villi contain capillaries, not to mention other things characteristic of them. Hydatiform villi, on the contrary, do not contain them or only very rarely so and in early stages. When a villus becomes hydatiform, that is, when liquefaction of the stroma occurs, this liquefaction appears in more or less restricted portions of the villus, thus giving rise to the long fusiform, and later spherical vesicles so characteristic of the hydatiform mole. But when a villus becomes macerated the change is general, and usually also is noticeable in the embryo and in the chorionic membrane itself, or at least within its epithelium. The latter usually is lifted from the stroma here and there, the caliber of the entire villus is increased and the capillaries and the stroma also show maceration changes as the villus becomes more translucent. This increase in caliber of the entire villus is not due merely to local liquefaction of the stroma, but to the pseudo-œdema occurring under such conditions, in a villus of normal structure and form. In hydatiform moles, on the contrary, the epithelium not only is firmly attached but usually is hyperactive. The changes characteristic of hydatiform degeneration may and often do appear in the villi while they still are implanted, and do not arise only after the chorionic vesicles are detached. This does not imply, however, that the villi of a detached hydatiform mole cannot also undergo maceration changes. They, of course, frequently do so, and it is in such cases as these that differentiation may be difficult or impossible, especially if differentiation is to be made from an examination of ill-preserved fragments only. The same thing is true also of the villi in the early stages of hydatiform degeneration and maceration, when the latter masks the former. The difficulty in diagnosis would be still greater in case of whole chorionic vesicles which are almost completely dissolved, leaving only a shadow picture formed by coagulum without nuclei, which nevertheless may retain the form of the chorionic vesicle and of the individual villi almost perfectly. Such cases as these it long may be impossible to differentiate, but they form only a relatively small proportion of the whole. The many cases both of uterine and of tubal chorionic vesicles which still were implanted and showed exceedingly fine instances of hydatiform degeneration, as well as the many splendid examples of groups of villi detached from the chorionic vesicle, which still were implanted in the tube or in the decidua, and which were equally good examples of hydatiform degeneration, leave no room for doubt as to the frequency of occurrence of this condi-

tion, even after due allowance for the occurrence of doubtful cases is made.

Werth further concluded that not one of the seven cases of chorio-epithelioma regarded as having arisen from tubal pregnancies recorded before 1904, was sufficiently authenticated. Nevertheless, by 1908 Veit felt justified in saying that a considerable number of cases of chorio-epithelioma arising from tubal pregnancies had been described. Veit added that Risel (1905) gathered 11 cases from the literature, and that a second case had been reported since Risel's paper.

Since my interest in this subject is largely incidental, I have not taken the trouble to gather from the literature cases of chorio-epithelioma alleged to have arisen from tubal pregnancies which may have been reported since Veit wrote. Moreover, I could not presume to judge these cases critically. Hence I will accept the fact that chorio-epithelioma arising from tubal pregnancy is regarded as established by a number of investigators and if the present conception regarding the relation of chorio-epithelioma to hydatiform mole is justified, then the occurrence of hydatiform degeneration in tubal pregnancy must follow on *a priori* grounds alone. Moreover, whatever the causes of hydatiform degeneration may be, one probably is safe in assuming that the condition is not restricted to the uterus, and when I noticed that hydatiform degeneration was so very common in young uterine abortuses, the surmise that it might be still more common in cases of tubal pregnancy seemed justified. Since over 100 specimens of tubal pregnancies from the Mall collection were included in the survey originally planned by Mall, a study of these specimens formed an excellent opportunity for observations on this subject.

That the case of tubal pregnancy of Otto, with its pathetic history, really was one of hydatiform mole, one cannot doubt in view of the careful description of the whole case, its clinical history, necropsy and the histologic examination. This case is interesting also because the degeneration was in its early stages, the hydatids being only as large as a pinhead, and the embryo still being present. Moreover, from Otto's description it is very likely that the specimen contained Hofbauer cells which are discussed elsewhere (Meyer, 1919).

The history of the case observed by Wenzel in 1855 and reported in 1893 is equally complete, and equally pathetic, as can be surmised by all familiar with the history of tubal pregnancy. In this case the mole was as large as a "hen's egg," the hydatids varied in size from a dot to a "bird cherry" wild (?) cherry, and the degeneration was universal, although the menstrual age of this specimen was given as only 51 days. It is significant that Wenzel expresses surprise that even excellent handbooks of the day had nothing to say about hydatiform mole in cases of tubal pregnancy, except perhaps to refer to the case of Otto. Nor does the case of Wenzel seem to be the first one observed, or that of Otto the first one reported, for Storch (1878) in truly epochal, though largely ignored observations on hydatiform mole, states that Hennig (1876) stated that 2 cases of moles in the tube were reported by Blasius (very likely E. Blasius, 1802–75). Since Storch wrote on hydatiform mole it is implied that Blasius saw such and not another type of mole, and since hydatiform mole is such a striking condition and has evoked much more interest than the other forms, an observation regarding it in the tubes, well might travel down the decades, especially since until recently, the occurrence of hydatiform degeneration in the tubes was regarded as extremely rare. This is indicated also by the fact that Menu (1899) still referred to the case of Otto as a curiosity.

Pazzi (1908) states that 2 cases of extra-uterine moles have been described each by Hennig (1872), Favell (1893), Donald (1902), and one case each by Otto, Freund, Theilaber, Maret, Matwjew (Matwejew?) and Sycow, Bland Sutton, and one case of ovarian mole by Wenzel (1893). Wilkinson is said to have described a case of rupture of the tube with reduction of the mole to the size of a cherry, and Lob (1902) a case of molar tubal pregnancy without cessation of menstruation. Since I am quoting Pazzi essentially verbatim, it is evident that he did not read the

literature critically or discriminate between ordinary and hydatiform moles, but was misled by the old inclusive usage of the terms mole and molar still current at the present day.

Krueger (1909) also reported a case of hydatiform mole with a cyst as large as a "walnut." The pedicle of the cyst was 4 centimeters long and attached to the amnion near the cord. Krueger spoke of this as a placental cyst, but regarded it as a hydatiform-mole-like structure which microscopically was limited to a single villus. If this were the only evidence presented by Kreuger one well might question the nature of this cyst, but he added that microscopically the beginnings of hydatiform formations could be recognized on other villi also. Hence it would seem that Kreuger's cases must be added to the authenticated cases of hydatiform degeneration in the tubes.

So far as I am able to learn we have, then, in the literature, reports of 8 cases of hydatiform mole occurring in the tube. Of these, 2 or 3 cases are not well authenticated, however. These 8 cases consist of the 2 cases of Blasius or Hennig, that of Otto, of von Recklinghausen and Freund, of Wenzel, of Croom, that of Matwejew and Sykow, and that of Krueger. A critical reading of Hennig's (1876) book on diseases of the tubes and tubal pregnancy makes it quite clear, however, that Hennig merely said that Blasius discovered "tubal moles" and that he observed 2, and Behm 1 case of abortion of tubal moles. From the context it also is very clear that Hennig was not discussing hydatiform moles, although it is not possible to say whether he meant that he himself or Blasius observed 2 cases. I should judge that the latter is the idea it was meant to convey. To the 6 remaining cases I make bold to add that of Maxwell (1910). In reading Maxwell's description one cannot help but feel that he himself regarded the case as one of hydatiform mole, but that he deferred to the opinion of the "committee." This is also suggested by the title of his article. The illustration which accompanies Maxwell's article is so very suggestive, and his description so characteristic of hydatiform mole that it seems very probable indeed that the specimen really was such. Maxwell states, for example, that "sections of the villi embedded in the wall of the tube have the typical structureless, bloated appearance of such pathological villi; and though there is no central cavitation in the villi, their structure, associated with the active proliferation of the Langhans' layer, suggests that one is looking at a stage just short of vesicle formation." Moreover, as I am about to show, hydatiform mole is so very common both in tubal pregnancies and in uterine abortions that the likelihood that Maxwell's case actually was one of hydatiform mole is increased still further. This, to be sure, merely is a presumption, and a more complete description, or an examination of the specimen itself only could decide the matter.

In connection with what has been said, it is interesting that Maxwell also emphasized that epiblastic activity is increased in all abnormal sites of implantation, and any one interested in the problems of tubal pregnancy and acquainted with Mall's (1915) findings will be struck by Maxwell's statement "that microscopic examination of many cases of tubal gestation lends no weight to the view that chronic inflammation of the tubes is at all a common causal factor." Nor can I refrain in this connection from quoting the strangely uncontradicted opinion of Doran, expressed in the disscusion of Maxwell's case, that tubal gestation "probably represents some general deterioration in the generative power among civilized women."

To these 7 cases contained in the literature, I wish to add 48 found among the first 1187 accessions from the Mall collection. Nor is it necessary to stop with these, for the rest of this collection contains others not here included. It is merely a matter of recognizing the specimens by a routine examination, and since this paper has been written, a number of specimens have been recognized among the daily accessions of tubes which we receive through the unselfish efforts and the scientific interest of practitioners, from all parts of the nation.

In addition to over 100 specimens of hydatiform degeneration reported elsewhere,

Fig. 1. Cross section of a hydatiform, twin, tubal pregnancy. No. 825, case of Cecil E. Vest. No embryo.

I also have seen more than a dozen fine specimens in large sections of uterine implantation sites, and also a number of entire specimens still embedded in the pregnant uteri and tubes. Indeed, how many cases of hydatiform degeneration one can find in abortuses in tubal or hysterectomy specimens even, will depend very much upon the care with which the examination is made, for the condition undoubtedly is extremely *common*, and not rare, as heretofore supposed.

Although the alleged menstrual age of these 48 conceptuses ranged approximately from 6 to 218 days, most of them were young *empty* chorionic vesicles or mere remnants of such. Portions of quite a number still were implanted within the tube, however, and among these were two unusually fine specimens from a twin pregnancy in the tube donated by my friend, Cecil E. Vest of Baltimore. Since the question of superfœtation has been raised also in connection with twin tubal pregnancies, I hasten to add that such a phenomenon, even if it ever occurs, which seems exceedingly doubtful, can be excluded absolutely in this case. Both chorionic vesicles were approximately of the same size and lay in practically the same cross section of the tube, the surfaces of contact being flattened.

Before proceeding with the statistical findings I may say that the abortuses in the Mall collection, which are regarded as pathologic, are grouped (1) as villi only; (2) as empty or partial chorionic vesicles; (3) as chorionic vesicles containing some or all of the amnion; and (4) specimens containing a nodular; or (5), cylindrical embryo, or (6) a stunted, and (7) macerated and mummified fœtus. Any one interested in this classification will find it discussed and exemplified in an article by Mall (1917), and also in a forthcoming publication by Mall and Meyer, to be issued by the Carnegie Institution of Washington.

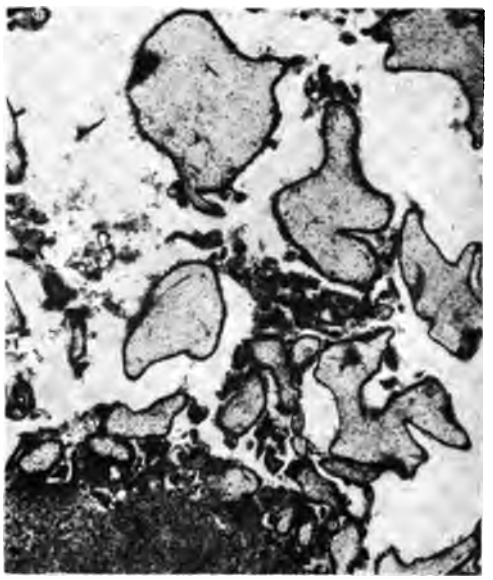

Fig. 2. Hydatiform villi from same case as in Fig. 1.

There were 34 tubes containing villi only, and in 13 of these hydatiform degeneration probably was present. In 8 specimens its presence was undoubted, but in 5 it was probable only. I realize that this margin of probability is exceedingly large, but if it is recalled that often only a few degenerate villi embedded in clot were contained in the cross sections of many of the tubes, and that only a few sections, and not, of course, a complete series of each tube, were examined, this is easily understood. Had the entire tubes been examined, or if more villi had been present, and if those present had been better preserved, the difficulty would have been obviated almost wholly. However, it is idle to set forth these things, because such conditions never will obtain, and if it be remembered that a large series of specimens necessarily supplement each other, the margin of

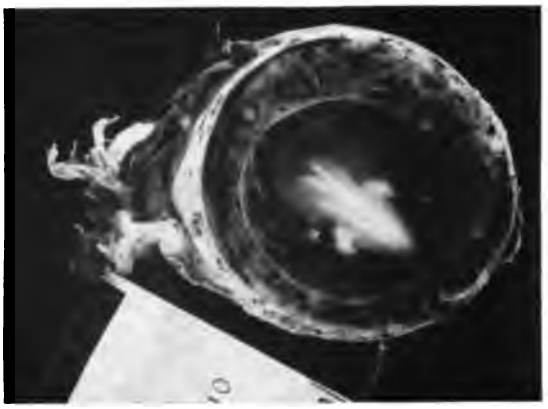

Fig. 3. Cross section of a hydatiform, tubal pregnancy with embryo. No. 1771, case of H. M. N. Wynne.

Fig. 4. Embryo from same case showing magma.

probability becomes greatly reduced. Moreover, the changes in the villi often are so typical that they are unmistakable, even if only a few villi are present. Besides examination in complete series undoubtedly would increase, not decrease, the number found. In some of the doubtful cases the existence of hydatiform degeneration became probable only upon comparison with the many uterine specimens previously examined.

The evidence offered by the 34 specimens in the second group which is composed of empty chorionic vesicles or parts thereof, was very conclusive, for the cut portions of most of these tubes contained considerable portions, or even sections of whole chorionic vesicles, sometimes quite free from clot. Some of these were implanted almost perfectly in the wall of the tube, and although many of them were folded extremely and were collapsed more or less, small areas of several, nevertheless, were implanted undisturbed within the tube. The villi in some of these implanted specimens were so characteristic, and the whole picture was so exquisite, that these specimens rightly belong among the very finest instances of hydatiform degeneration found so far. Many of the tubal specimens were remarkable indeed, and this is true in particular of the case of twin pregnancy received from Dr. Vest. In this specimen the two chorionic vesicles, the intervillous spaces of which were devoid of blood, lay in almost the same transverse diameter of the tube, and hence had distended the latter considerably. Both were implanted quite well over the entire area of contact, which included the whole perimeter of the tube. The chorionic vesicles were flattened at the region of mutual contact which divided the tube somewhat unequally, as shown in Figure 1. Although the embryo and the amnion long had disintegrated completely, and although the chorionic membrane itself is thin, covered by degenerate epithelium and also disintegrating, the epithelium of the villi not only is well-preserved but is accompanied by large masses of trophoblast and considerable syncytium as shown in Figure 2. Syncytial buds are found on the chorionic membrane also. The tubal mucosa is largely, and the tubal wall partly, destroyed by the invading trophoblast. Only a few small vestiges of the walls of the villous vessels remain, and the stroma of all of the villi has undergone changes characteristic of hydatiform degeneration. One villus also contains an epithelial cyst resulting from epithelial invagination with subsequent isolation of the distal extremity, a process to be referred to elsewhere (Meyer, 1919) in connection with uterine specimens. Since most of the villi of this and similar specimens still are implanted in the tube, there no longer can be any question as to the time in which hydatiform changes in the stroma of the villi are inaugurated. As illustrated in previous instances in which isolated and small groups of villi still were implanted, the advent of degeneration of the stroma occurs, in part at least, before the villus is detached. It not merely is a maceration change.

Another very interesting specimen of tubal implantation is No. 1771 received from H. M. N. Wynne of the Johns Hopkins Hospital and shown in Figure 3. The menstrual age of this specimen is 49 days, but its anatomic age, as based on length, according to Dr. Streeter's curve (unpublished), is 37 days, thus showing a discrepancy between the menstrual and anatomic ages of 12 days. The embryonic length is only 12.5, although with a menstrual age of 49 days it should be at least 18 millimeters. Upon examination, Dr. Streeter found the chorionic vesicle to contain a good deal of magma, some of which still was adherent to the embryo, as Figure 4 shows. As has been repeatedly emphasized in the literature, the presence of this coagulum in itself probably indicates that the embryo died some time prepartum.

The wall of the tube was quite thin, as Figure 5 shows, but the implantation is fairly well preserved around the whole perimeter of the specimen. The mucosa is destroyed throughout the greater extent of the section, but the trophoblast is abundant except in one rather degenerate and hæmorrhagic area. The chorionic membrane is thin but contains some vessels distended with blood. The stroma of many of the villi also contains vessels filled with blood, but the vessels in many villi are very evidently in degeneration. The syncytium is scanty, and many of the villi are very plainly hydatiform, as Figure 6 shows.

A second exceptionally fine specimen of tubal hydatiform mole is No. 2052, donated by N. M. Davis of Washington. Figure 7 shows a portion of the tube containing the hydatiform mole, some hydatiform villi of which protrude through an incision in the wall of the tube. The whole opening is filled with typical hydatiform villi which are perfectly evident to the unaided eye, and very evident under an enlargement of 4 diameters. They present an extremely fine picture when seen with the binocular under a magnification of 10 to 20 diameters. Examination under a higher magnification shows that the preservation of the specimen is unusually good, and that all the villi are markedly hydatiform. Trophoblastic proliferation is so marked that

Fig. 5. Cross section of tube.

in some places it gives the appearance of decidual formation. Relatively little syncytium is present, but the trophoblast invades the muscularis in many places, and a good deal of coagulum is present, most of it apparently having arisen from degeneration changes in the stroma of the mucosa, and from similar changes in the trophoblast and the muscularis. The latter is moderately invaded by round cells. No remnant of the wall of the chorionic vesicle or of the amnion or embryo could be detected in the sections examined, both evidently having been absorbed completely and only some of the villi remain behind. Or, the chorionic vesicle may have been aborted and these villi left implanted within the tube.

Some exceedingly fine hydatiform villous trees were found among the specimens in this group. Scaffoldings or frameworks formed by proliferating syncytium arising from the epithelium of the chorionic membrane also were seen. Since the syncytial buds also were found far out on proliferations of trophoblast which capped the villi, and also in the center of trophoblastic nodules, the origin of the syncytium from the Langhans' layer would seem to be again and exceptionally well confirmed here. In some cases a detached

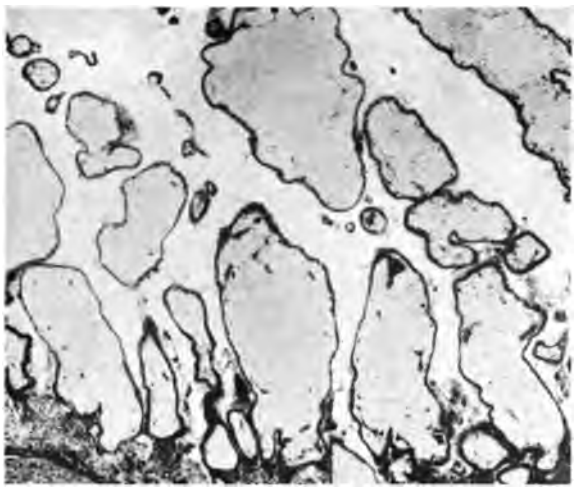

Fig. 6. Hydatiform villi from the same case.

Fig. 7. Excised portions of a pregnant tube showing hydatiform villi protruding from the incision. No. 2052, case of N. M. Davis.

hydatiform villus was fastened by opposite extremities to two portions of the tube wall. It is well to remember, however, that these attachments may have been gained, and indeed they probably were gained before the separation of the particular villus from the chorionic vesicle.

Of the 34 cases remaining in this group of chorionic vesicles without amnion 17, or 50 per cent, showed the presence of undoubted hydatiform degeneration, and in one additional case its existence was doubtful.

Since only a few specimens are contained in each of the last five groups, I shall treat them as one. Among the 30 specimens in these groups, 16, or 52.3 per cent, showed the presence of hydatiform degeneration. From this percentage it is evident that the incidence of hydatiform degeneration among tubal specimens seems to increase slightly with advancing age of the conceptus rather than decrease, as was emphasized in connection with the uterine specimens considered elsewhere. (Meyer, 1918.) This probably can be attributed to the fact that the specimens in the first group are composed of villi only, and that many of the empty chorionic vesicles in group 2 were detached from the wall of the tube by hæmorrhage, before hydatiform degeneration had developed sufficiently to enable me to recognize it. Moreover, it must be remembered that all tubal specimens, no matter in what group they are classified, are in fact young specimens and since those falling in the later groups succeeded in maintaining a foothold in spite of repeated hæmorrhages, a larger number of them might rightly be expected to show the presence of a hydatiform change.

The incidence of hydatiform degeneration among 104 tubal pregnancies classed as pathologic is 48, or 46.1 per cent of the whole. This is a somewhat higher incidence than was obtained in the 348 uterine abortuses classed as pathologic. This may be due partly, or wholly even, to the greater incidence of young specimens in the tubal series. That the tubal specimens undoubtedly were younger follows from common knowledge regarding tubal pregnancies, but it also is shown by the average menstrual ages, which were 43.4 days in 25 tubal, as compared with 66.6 days in 51 uterine specimens. Moreover, 32 of the 48 tubal specimens of hydatiform degeneration, or 66⅔ per cent, fall into the first two groups of the pathologic, thus again showing that the majority are small, young specimens.

Although the incidence of hydatiform degeneration among the pathologic tubal specimens is but slightly higher than that among the pathologic uterine specimens, the incidence of hydatiform degeneration in all tubal specimens, both the normal and pathologic, is twice as high as that among the same classes of uterine specimens. This difference can be explained only partly by the fact that a larger proportion of the tubal specimens are young and pathologic. The pathologic tubal

specimens were found to form 62.9 per cent of 153 normal and pathologic tubal specimens found among the first 1187 accessions, but the pathologic uterine specimens form only 33.6 per cent of the normal and pathologic uterine groups among the first 1187 accessions. Hence the real question remains, for the incidence of hydatiform degeneration among the specimens classed as pathologic was essentially the same in tube and uterus. The increased incidence of hydatiform degeneration, of 100 per cent in all tubal as compared with all uterine specimens may be due to the less favorable nidus found in the tube. If so, it throws a very significant light upon the probable cause of hydatiform degeneration, which would seem to lie in the conditions surrounding implantation and early development rather than in the ova or spermatozoa themselves.

Whether hydatiform degeneration in the tube also is relatively more common near the menopause as was found to be the case in uterine pregnancies I do not know, for I have not been able to obtain data on the relative frequency of tubal pregnancy in the different decades of the reproductive life of women. However, since by far the greater number of uterine pregnancies occur early in this period, it probably would be safe to assume that most tubal pregnancies also occur during this time. Consequently it might well follow that the ratio of tubal hydatiform degeneration to the number of tubal pregnancies occurring in the *later*, actually might be greater than in the *earlier* decades.

The conclusion reached in a study of uterine specimens that hydatiform degeneration is *absolutely* less, not more frequent near the menopause, is confirmed also by the study of the tubal specimens. The average age of 20 women in the tubal series was 33.9 years, as opposed to an average of 31 years obtained from 36 women in the uterine group. This age difference offers a tempting opportunity for generalization, and did the statistics include thousands of cases one might be willing to say that it points to a progressive change as cause, which begins in the uterus and finally reaches the tubes. But strangely enough, the average number of years of married life of 15 women in the tubal series is exactly the same as that of 29 women in the uterine series, or 7.1 years. This fact at once guards against a venturesome hypothesis, for it allows a no longer period for the supposed ascending change to reach the tubes than the uterus.

Eight of the 20 women in the tubal series had borne one child, four had borne two, and three more than two; thus again more than confirming the statistical findings in the uterine series, which show that 9 of 33 women had borne once and 18 twice. The parallelism between these statistics is striking indeed, especially if the numbers involved be considered. Fourteen of the 23 women, or 60.8 per cent, in the tubal series had aborted but once, as compared to 19 out of 44, or 46.3 per cent in the uterine series, facts which again point to the middle, rather than to the end of the reproductive life of these women.

Since the structural changes in hydatiform degeneration will be considered more fully in the Mall Memorial Volume, I shall not repeat the description here. Suffice it to say that since I directed my attention especially to hydatiform degeneration I have been able to recognize its presence repeatedly at sight in relatively young chorionic vesicles —one centimeter large—not only from uterine but also from tubal pregnancies. This is true, of course, especially in the former, for the chorionic vesicles of these often are quite characteristic, and when inspection with the unaided eye or with a reading glass under a magnification of two diameters, fails to reveal the true nature of the specimen, examination with a binocular under a magnification of ten or twenty diameters often does so at sight.

The observations reported here should not in themselves be permitted to change the present opinion regarding the malignancy of uterine hydatiform mole. That opinion is based on specimens which survive until the later months of pregnancy, and the tendency to malignancy in such may be and undoubtedly is, a totally different one from that present in the overwhelming majority of specimens which are aborted in the early

months of pregnancy. The great frequency of hydatiform degeneration in uterine abortions first emphatically asserted by Gierse (1847) and confirmed with some qualification elsewhere should, however, counsel every practitioner to be on the alert, especially in cases of uterine abortion.

REFERENCES

BALLANTYNE, J. W., and YOUNG, JAMES. Fatal case of hydatiform mole. Obst. Tr., Edin., 1913, xxxviii.

CROOM, J. HALLIDAY. Two cases of extra-uterine gestation operated upon at the fourth month. Edin. M. J., 1895, xl, Pt. 2.

FELLNER, O. O. Ueber periphere Langhanszellen, zugleich eine Erwiederung auf den Aufsatz von R. Meyer: Zur Kenntniss der benignen Chorioepithelialen Zellinvasion. Ztschr. f. Geburtsh. u. Gynaek., 1903, xxi.

FRANKEL, L. Rueckbildung von Ovarialtumoren nach Blasenmole. Monatschr. f. Geburtsh. u. Gynaek., 1910, xxxii.

FREUND, W. A. (No title.) See Berichte ueber die Verhandlungen der gynaekologischen Sektion der 62 Versammlung deutscher Naturforscher und Arzte zu Heidelberg, 1889. (A reference to the case only.) Zentralbl. f. Gynaek., 1899, xiii, 690.

GIERSE, AUGUST. Ueber die Krankheiten des Eies und der Placenta. Verhandl. der Gesellsch. f. Geburtsh. Berl., 1847, vol. ii.

HIESS, VIKTOR. Gynaek. Rundschau, 1914.

HENNIG, CARL. Die Krankheiten der Eileiter und die Tubenschwangerschaft. Stuttgart: 1876.

KRUEGER, M. Eine seltene Form der Placentarcyste. Ztschr. f. Geburtsh. u. Gynaek., 1909, lxiv, No. 2.

MALL, F. P. On the fate of the human embryo in tubal pregnancy. Contributions to Embryology, i, No. 1, Carnegie Institution of Washington, 1915.

Idem, 1917. On the frequency of localized anomalies in human embryos and infants at birth. Am. J. Anat., 1917, xxii.

MARCHAND, FRANZ. Ueber den Bau der Blasenmole. Monatschr. f. Geburtsh. u. Gynaek., 1895, cxxxii.

MAXWELL, R. D. Tubal mole with œdema of the connective tissue of the villi. Proc. Royal Soc. Med., Lond., iii, Sect. Obst. and Gynec., 1910.

MATWEJEW, G. F., and SYKOW, W. M. Blasenmole in der Tuba Fallopii und cystische Degeneration des Ovariums. Sitzngsb. der Mosk. Gynaek. Gesellsch. Vratsch., No. 24. (Rev. in Zentralbl. f. Gynaek., 1902, xxvi.)

MENU, ADOLPHE. Mole vesiculaire tumeur maligne, Thesé de doct., Paris, 1899.

MEYER, A. W. On the nature, occurrence and identity of the plasma cell of Hofbauer villi. J. Morph., 1919. (In publication.)

Idem. Deductions from over one hundred new cases of hydatiform degeneration. Am. J. Obst., N. Y., 1918, lxxviii.

OTTO, HEINRICH. Ueber Tubenschwangerschaft mit Beruecksichtigung eines Falles von Graviditas tubaria molaris hydatidosa. Inaugural Dissertation, Greifswald, 1871.

PAZZI, M. La nostre cognizioni intorno alla mola vesciculare ed alla nidificazione del-l'uovo. Rassegna d'ostet. e ginec., 1908, xvii.

v. RECKLINGHAUSEN. Perforierende Blasenmole bei fuenfwoechentlicher Tubenschwangerschaft. Deutsche med. Wchnschr., 1889. (Merely a society minute reporting the demonstration.)

RISEL, W. Demonstration von frischen Praeparaten nebst Bemerkungen. Gesellsch. f. Geburtsh. zu Leipzig, 1895, June 17. (As reported in Zentralbl. f. Gynaek, 1896.)

SEITZ, L. Erkrankungen der Placenta. Handb. der Geburtsh., 1904, vol. ii. Wiesbaden: F. von Winckel.

STORCH, E. D. Beitrag zur pathologie des Eis, Faelle von sogenannter partiellem Myxom der Placenta. Arch f. path. Anat., etc., Berl., 1878, lxii.

TEACHER, J. H. On chorionepithelioma (the so-called deciduoma malignum) and the occurrence of chorionepithelioma and hydatiform-mole-like structures in tumors of the testes. London Obst. Tr., 1903, xlv.

VEIT, J. Das maligne Chorio-epitheliom. Handb. der Gynaek., 1908, iii, Wiesbaden.

WENZEL, CARL. Alte Erfahrungen im Lichte der neuen Zeit und ihre Anschauungen ueber die Entstehung von Krankheiten. I. Blasenmole im Eileiter. Wiesbaden: 1893.

WERTH, R. Die Extrauterinschwangerschaft. Kap. I. Handb. der Geburtsh. Wiesbaden: F. von Winckel, 1904, ii.

IMMEDIATE SURGICAL MANAGEMENT OF ACUTE APPENDICITIS IN MILITARY HOSPITALS

Suggesting a Possible Relationship Between the Onset of This Condition in Those Cases with a History of Previous Attacks and the Present Method of Administering the Triple Typhoid Vaccine

By HUGH McKENNA, M.D., F.A.C.S., Chicago
President of Staff, St. Joseph's Hospital; formerly Lieutenant Colonel Medical Corps, U. S. A., and Chief of the Surgical Service, Camp Pike Base Hospital

ANYONE who has listened to, and practised, the lessons taught by the late John B. Murphy in the surgical management of acute appendicitis cannot help but be profoundly impressed with the accuracy of his teaching, especially where opportunity affords an extensive observation over acute abdominal lesions.

This opportunity has come to us in the surgical management of 248 cases of appendicitis operated on at the Camp Pike Base Hospital. The following pathological conditions of the appendix were found:

Acute cases		143
a. Not ruptured	122	
b. Ruptured	15	
c. Necrotic	6	
Subacute cases		36
Chronic cases		65
Appendicitis obliterans		4
		248

The feature of paramount importance in the early recognition of acute appendicitis is brought out by a carefully and intelligently interrogated history. Conviction in the necessity of instituting surgical treatment within the first few hours after the onset of acute appendicitis prompts me to urge the taking of a more methodical history, and the institution routinely of a searching examination in every abdominal condition in a patient seeking advice from a physician.

I am of the opinion that medical men do not frequently get out of the patient's history the points of real diagnostic value. Under a controlled system of examination and history taking, such as is required in this hospital, it is interesting to note how quickly and accurately young medical officers have been trained to recognize acute lesions of the abdomen.

I wish to digress at this stage of the discussion of the history of this disease to give an account of what has been done at this hospital to bring these cases under early surgical observation.

In the latter part of November, after an experience in handling a number of patients suffering with ruptured appendicitis and peritonitis because of delay in being sent to the Base Hospital, I asked permission of the Commanding Officer of the Hospital and the Division Surgeon, to take this subject up at the weekly lyceum meeting with the regimental surgeons. In this conference the mortality statistics were brought out where operation followed; (a) in the first 12 hours; (b) 36 hours (c) 72 hours, etc. etc. Vital importance was directed to the fact that where operation was performed for this disease in the first twelve hours after the onset, the mortality should be practically nil in the hands of a competent surgeon and in a hospital where modern surgical technique has been instituted.

The method of diagnosis was gone over in the detailed manner about to be given here-

Fig. 1. Photograph of Lieut. D's. appendix.

Fig. 2. Photograph of a number of appendices showing the pathological changes in this group of cases.

after in this paper. Much importance was attached to the fact that all cases suffering with pain in the abdomen should be sent to the hospital immediately even though the regimental surgeon did not make the diagnosis of appendicitis.

Since it is imperative that these medical officers not only keep the cardinal symptoms of acute appendicitis clearly before them, but also keep in mind their sequential order of occurrence, I am taking the liberty of reiterating them here.

1. Pain, cramp-like in character, the patient stating that the pain is in his stomach and not in the region of his appendix. The initial pain, complained of by the patient as in the pit of his stomach, finally becomes general and later is confined to the McBurney region. (It is very strange to me that so many medical men miss the significance of noting that the pain comes *first*, as many will state that the patient was sick at his stomach, when upon a close interrogation, the patient clearly states that the nausea came on later.) Muscular rigidity and local tenderness shows a marked contrast when compared with the opposite side.

2. Nausea or vomiting practically always follows and never precedes the abdominal pain. Since the nausea or vomiting may not come on for several hours to eighteen hours after the initial attack, the patient may have been operated upon before this symptom manifests itself. The nausea and vomiting, as a rule, is not repeated.

3. The increase in temperature is not of great significance, because it may or may not be present, though a slight increase at least is usually always present in these cases.

4. Leucocytosis, when it is positive, is a valuable symptom, and a differential count in order to show an increase of the polymorphonuclear leucocytes, should always be made.

I might take up much more time reviewing other symptoms or points of differential diagnosis, but will content myself with the review of these important cardinal symptoms that every medical man should keep constantly before him when he examines an acute abdominal condition.

Much interest has been manifested at this camp over the occurrence of acute appendicitis, characterized by some unusual symptoms, following inoculations of the triple typhoid vaccine. The clinical symptoms would seem to be milder than those observed in civil practice, among patients who have not been immunized against typhoid and paratyphoid fever. The blood findings have

been of special interest since even in many of the well-established inflammatory conditions of the appendix a leucocytosis apparently was not present. The blood findings were found so uniformly to contain a low white cell count in the presence of suppurative conditions of the appendix that it was decided to examine the blood of a few hundred soldiers in good health who had previously received the triple typhoid vaccine.

I have asked the Director of our Laboratory to make these examinations, and through the courtesy of Lieutenant Soloman F. Hoge, I am able to submit the following report:

This preliminary report which follows, includes the white blood count of two hundred persons of the Base Hospital. The first hundred was taken of the men on duty in the hospital and were considered perfectly healthy. The second hundred was taken from men who had been in the hospital for one or more ailments of a trivial character and just before a discharge from the hospital.

From the general condition of these patients, it seems that their leucocytic curves should stand about at its normal. These persons were chosen in an attempt to establish a measure of influence that the triple typhoid vaccine could show on the leucocyte curve of the individual and at the same time, if possible, to give some clue as to the question of why so many cases of appendicitis, acute and subacute do not show a higher leucocyte count.

The patients coming into the hospital to the Surgical Service for observation and for operation as the case may be, have all had at some time or other their triple typhoid vaccine. This course of immunization seems to be the one common factor which could possibly cause a transient or semi-permanent alteration in the leucocyte count. Not being able to find definite statistics in the literature at hand covering this point, it seems well to hold this uppermost in the course of our study. The technique employed was similar in every respect, and done by the same persons, as those who made the count for the operative cases. Each man was asked the time of his vaccination, whether one or more courses of vaccination, and the reaction that followed. Each person was questioned and examined for the possible condition that would cause an increase of leucocytes at the time of the count. The relationship to meals, the factor of excitement, depression, the presence and absence of malarial history were all considered, and where indicating a possible influence upon the leucocyte count, the patient was excused.

An inspection of the findings shows that the total leucocyte count of the first hundred men is 819,000, making an average of 8,198. The total months of the first hundred patients were 609, from the time of vaccination until the blood count. The average number of months was 6.09. The second hundred show a total count of 729,000, with an average count of 7,290. The total months from the time of vaccination were 533, with an average of 5.33. The chief differences in the comparison of those with a count between the various thousands, as shown by the table, shows in the first hundred "4" between the counts of four and five thousand, while in the second hundred the number is doubled. The first hundred of the series showed "7" between five and six thousand, while the second hundred of the series shows "18" between five and six thousand, otherwise the hundreds are similar, with the exception that the second hundred of a series shows "20," with a count of over 9000, while the first hundred of the series shows "35," with a count of over 9000.

Summing up the two hundreds, we find that the greatest number (43) is found between six and seven thousand. The next nearest number (41) is between seven and eight thousand. Adding these two, we find 84, or a percentage of 42, between six and eight thousand. The sum of those less than 7000, is 80, which gives us a percentage of 40, with a leucocyte count less than 7000.

A review of the blood findings submitted shows that 40 per cent of the bloods examined gave a white cell count of 7000 or under. In the event of these cases represented in this 40 per cent, i. e., those with a white cell count of 7000 or under, contracting an inflammatory condition, such as an acute appendicitis, it can be readily seen that a white blood count of 9 to 10 thousand would show a relative leucocytosis.

My observation over these cases leads me to believe that the foregoing is an explanation of a large number of the low blood findings in the cases of acute appendicitis developed at this camp.

Respecting a possible relationship between the inoculation of the triple typhoid vaccine and the onset of attacks of acute appendicitis, I have the following facts to submit. An examination and history (which is still going on) have been made of over fifty soldiers suffering with various inflammatory conditions of pyogenic origin. The following interrogations were made:

a. What was the date of the triple typhoid vaccination?

b. Did you have fever and malaise after the inoculation, and if so, was it sufficient to keep you in quarters or in bed?

c. Have you had bad teeth, bad tonsils, and does examination at this time show infections in the mouth or throat?

d. Have you had malaria?

Sufficient data have been collected to show that in a majority of cases a marked reaction follows the inoculations with the triple typhoid vaccine. Our examinations have covered a sufficient number of cases to say that it would appear that the reaction following the injection of the triple vaccine is a predisposing factor in the causation of an attack of appendicitis, particularly in those cases with a previous history of appendicitis. Whether this gives expression by the formation of an embolism from the vaccine itself or by causing the passage of an embolism from a point of focal infection into the end arteries of the appendix, or is responsible for a lymphadenitis that stirs up a latent infection in the lymph follicles of the appendix, cannot be stated definitely. However, the following evidence is suggestive of some pathological change in the lymphoid tissue of the body. An examination of many of the soldiers, giving severe reaction following the triple typhoid inoculations in addition to clinical manifestations involving the heart and kidneys, shows an acute adenopathy in various parts of their anatomy and a fair percentage manifests marked tenderness in the McBurney region.

It is thought that the lymph follicles of the appendix, may become a *locus minoris resistenciæ* and therefore, undergo an early inflammatory change in those soldiers suffering with infections about the teeth and mouth when the infection is stirred up and thrown into the blood stream by the vaccine reaction.

These references to triple typhoid vaccine are in no way to be construed as being opposed to immunizing against typhoid or paratyphoid fever as an experience of seven months' observation at this camp without a single case of either of these diseases is significant proof of how invaluable this prophylactic measure really is in military life. I am strongly of the opinion, though, that the triple typhoid vaccine should be given in five or six inoculations instead of three, as I am quite sure that the reaction would be much less, the patient spared from much unnecessary suffering and possibly from some complications.

We have operated upon a number of cases that were walking about in the wards and showing no signs of discomfort. In one case a soldier had been discharged with instructions to return to his barracks, when a slight distention of the abdomen called for re-examination, and one hour later an operation revealed a much distended. suppurative appendix.

In the early organization of this hospital these patients, as a rule, had had their initial symptoms of appendicitis in the regimental infirmaries or barracks, before entering the Base Hospital so that we had to depend upon the history given by the patient for a diagnosis, rather than upon the findings at the time of entrance into the hospital. The symptoms have been so mild in many cases that it has been difficult to impress the patient with the necessity of an immediate operation; so that in a number of instances, cases have gone on to a rupture before the patient consented to an operation.

I am of the belief that however slight the symptoms manifest themselves at the time of the patient's entrance to the hospital, the initial symptoms, though they may be mild, come in sequential order, and should permit the ward surgeon to make an early diagnosis when these symptoms are properly interpreted at the onset of the disease. It is singular that with the great amount that has been done and written regarding the subject of acute appendicitis, still so many medical men fail to grasp in their proper order the symptoms of this disease. The majority of cases reported in this paper, at the time they were examined by me, gave a history of the symptoms previously outlined in this paper, and though these symptoms were mild in degree, I believe, came according to the well-established law in appendicitis.

Among the early patients operated on, I wish to direct especial attention to the history of a young medical officer, because I believe it is fairly typical of many of our deceptive cases. Since this patient is a doctor, I am incorporating the history as given by

him. Let me say that even after a very careful and painstaking examination, it required considerable argument to persuade this officer that he was suffering with an acute appendicitis.

Patient, W. J. D., First Lieutenant, M.C., 312 Supply Train; born in Wilkesbarre, Pennsylvania; age 31; has always been healthy, never having suffered with any disease of consequence, except a mild attack of malaria, ten years ago. He has never had typhoid, and has always been free from constipation previous to this time. He received his inoculations of triple typhoid vaccine some time previous to this attack. On the morning of December 20, 1917, owing to constipation, the patient went to the dispensary where he was given two ounces of castor oil. He noticed a little distress in his abdomen, but nothing that he would describe as pain. He took care of his regular duties on that day and on the two following days, but remained constipated during this time, for which condition he took a dose of epsom salts, which gave him immediate relief. On Sunday, the 23rd, the patient developed an abscess in the root of a tooth and came to the hospital where the dentist drained his tooth cavity. He returned to his command, and on the 24th he held sick call and inspected all barracks, giving a full day's work. He retired at the usual time that evening, and on Christmas morning, at two o'clock, he noticed some discomfort and soreness in his abdomen, which he attributed to a large steak he had eaten the evening before. He threw the covers off and examined his side, and thought he felt a mass in the region of his appendix. He disabused his mind of the possibility of his having appendicitis, since he had not had any appreciable pain, nausea, or vomiting and contented himself with the thought that what he actually felt was impacted fæces. However, at this time, he felt a least bit nauseated. He immediately went to sleep and did not awaken until 7 o'clock, when he arose, dressed and took up his regular duties; held sick call, made out and sent in his sick report and went out for a walk and was preparing to go to the city, but because of his experience during the night, and not because of any distress or discomfort at this time, he asked one of his medical officers, who happened to be at his quarters, to examine him. This examination was made at 12 o'clock mid-day. The examiner was of the opinion that he could feel some induration and a mass in the abdomen, and urged the patient to go to the hospital. The patient decided to shave and change his clothing before doing so, and after straightening up his work about his quarters, packed his own suit case and came to the hospital, arriving at 4:00 p.m. carrying his suitcase and apparently feeling well.

Examination at the hospital: pulse 76; temperature; 98.6; respiration, normal; blood examination, 10,200 white cells.

Physical examination: abdomen was perfectly soft; on pressure over the McBurney's point, some tenderness was elicited; on deep pressure over this region, an induration was perceptible to the palpating fingers.

The patient was immediately sent to the operating room, where, upon opening the abdomen, the cæcum was found bound down by a recent exudate, the appendix was located adherent to the omentum, lying entirely within the true pelvis. The intestines were carefully packed off with gauze and upon separating down to the appendix, free white and creamy pus escaped. By a very careful and painstaking blunt dissection with the gloved fingers, the appendicular mass was brought up and tied off, without in any way contaminating the surrounding viscera. This pocket was carefully swabbed out with sponges moistened in 1 per cent lysol, drainage was carried into the bottom of the cavity, the abdomen closed and the patient placed in the Fowler position and given normal salt solution according to the Murphy plan. The patient contracted pneumonia during convalescence and continued the abdominal drainage for several months, but finally went on to complete recovery. The pathological report of this case is given by Captain M. L. Morris: "Appendix is 6 centimeters in length. Diameter at widest part is barely 1 centimeter. It is covered throughout its whole extent with a thick gray exudative membrane which is firmly adherent to surrounding parietal as well as visceral peritoneum. The entire distal half of the organ is necrotic. Rupture had taken place most likely at about the middle third of the distal half of the organ. The mesentery is congested, thickened, and covered by a like grayish membrane."

The right rectus border incision has been used entirely. A point is made of the introduction of the laparotomy sponge immediately upon making a tiny nick through the peritoneum. By pushing the sponge into the peritoneal cavity by means of a Mayo scissors one is enabled to keep the intestines and omentum out of the field — allowing a quick and safe manner to open the peritoneum and protect the viscera from trauma at the same time. The appendix, in the large percentage of cases, should be picked up exposing only the cæcum which procedure may be readily carried out by passing the exploring fingers into the abdomen along the inner side of the right abdominal wall, allowing them to sweep inward over the external iliac vessels until the meso-appendix and cæcum are grasped. The appendix may be easily delivered unless held by adhesions or a recent exudate.

Our experience in the management of suppurative appendicitis with rupture has taught us that, except in a very small percentage of cases with advanced abscess formation where the wall is so formed that further manipulation would allow free pus to run into the free cavity, the appendix can be taken out successfully and should be removed.

I have made this statement with some reluctance, fearing that physicians may misunderstand my position respecting acute appendicitis with rupture; however, it is made on the basis of past experience in not removing the appendix if rupture had occurred, depending upon drainage alone; then, after recovery, giving instructions to the patient to return for an operation in the event of subsequent trouble. We have found that the second operation is difficult owing to adhesions and far more serious than the ordinary operation of appendectomy. As a rule the patient is invalided for a much longer period, owing to the length of time the remnant of the appendix, acting as a foreign substance, causes drainage to continue.

The unremoved appendix is much more apt to cause further inflammatory disturbance in the abdomen, particularly abscess formation in dependent positions.

The ability of a surgeon to perform, successfully, an operation for the removal of a ruptured appendix depends upon the intelligent and painstaking methods used in the operation. With the field well packed off with gauze pads, and a line of cleavage to the appendix discovered there is no reason why the surgeon may not gently remove such a necrotic appendix, without, in my estimation, any additional risk to the life of the patient.

CONCLUSIONS

1. The chiefs of surgical services in all Base Hospitals should place before the regimental surgeons of the Division the importance of early recognition of acute appendicitis, in order that surgical intervention may be immediately instituted.

2. The administration of the triple typhoid vaccine in three doses produces a marked reaction, one phase of which we believe comes in the form of a lymphadenitis, which condition when produced in an individual suffering with a latent infection in the lymphoid tissue of the appendix would seem to predispose to an acute attack of appendicitis.

3. The administration of the triple typhoid vaccine in more, but smaller doses would probably produce the same degree of immunity without causing so severe a reaction.

4. Reliance should not be placed upon a leucocyte count as a diagnostic symptom in acute appendicitis unless it is positive. This is particularly true in a large percentage of the soldiers operated on at this camp for this condition, whose blood seems to have been affected by some agent causing a low white blood count to an extent that the normal white count of 9,500 may represent in these cases a relative leucocytosis.

5. Whether the triple vaccine is responsible for the low white count, or is a factor in predisposing to acute appendicitis, cannot be stated definitely, but the uniform clinical findings, associated with these cases, are very suggestive and a report now in progress upon the blood findings made within the first two months following the triple typhoid vaccination of the soldiers of the present draft now being inducted into service, may show even a lower leucocyte curve than those that have been examined and who may have lost some of the effect of their vaccination since they represent a period of four to nine months after inoculation.

I wish to take this opportunity to express my sincere thanks to my Commanding Officer, Colonel Joseph Taylor Clarke, to the Division Surgeon, Lieutenant Colonel Robert M. Thornburgh; to my former Commanding Officer, Lieutenant Colonel A. P. Upshur, for their hearty co-operation in this work; also to Captain Arthur H. Curtis who has been associated with me in the surgical management of this service.

THE OPERATION OF OMENTOPEXY IN CIRRHOSIS OF THE LIVER

By ELLSWORTH ELIOT, Jr., M.D., and RALPH COLP, M.D., New York

WHILE the literature contains many individual case reports of the so-called Talma operation, or omentopexy, for cirrhosis of the liver, and several excellent collections and reviews have been compiled by Greenough, White, Montprofit, Bunge and Ladenburger, a few observations made from the study of twenty-three cases operated upon at the Presbyterian Hospital during the last seventeen years may be of interest, especially from the viewpoint of factors influencing the prognosis, and from the end-results.

It will be remembered that Talma, of Utrecht, conceived the idea of his operation from the supposition that cirrhosis of the liver was caused by a mechanical factor; that is, he believed the smaller radicals of the portal vein system were partially obliterated by the deposition of newly formed tissue in the diseased liver with a resultant higher pressure in the portal vein and a corresponding effusion of fluid into the peritoneal cavity. Hence, by establishing an aiding anastomosis, the blood of the portal system might be partially diverted and shunted into the systemic circulation. The veins of the great omentum, which drain indirectly into the vena portalis, and those of the diaphragmatic surfaces of the liver and spleen, which are brought to the opposed surface of the diaphragm in the Talma operation, were, therefore, utilized as the means for bringing the portal into contact with the systemic through the internal mammary and deep epigastric veins.

This theory has met with much opposition. Hale, White, and Thomson asserted that the ascites in cirrhosis of the liver was due to a chronic peritonitis and perihepatitis; for in the postmortem findings of ten cases which survived more than one tapping, four had no cirrhosis whatsoever and six had a peritonitis, the latter due possibly either to the tapping or to the obliteration of the diaphragmatic lymphatics.

Rolleston stated that when the pressure is highest in the portal vein, the time when hæmatemesis occurs, ascites does not as a rule make its appearance; also, that in a cirrhosis of the liver existing for many years without the effusion of fluid, ascites may develop suddenly. Moreover, ligation of the portal vein in animals (perhaps also in humans, Brewer having reported one such supposed case) does not result in ascites.

Hahn, Nasse, Neckst and Pawlow believed that the fluid in the abdominal cavity might be explained by the fact that less blood passing through the liver, the percentage of toxins becomes, therefore, higher and consequently a lymphagogue action might be exerted. That the blood which had not passed through the liver did have a higher percentage of toxins was demonstrated by a series of experiments on dogs establishing an Eck's fistula (communication between the portal vein and the inferior vena cava), with depression, asthenia, clonic and tonic spasms, and coma following the anastomosis.

Whether Talma's reason for his procedure is sound, or whether other factors are instrumental is an open question. Thomson, Dickinson and Webber respectively, from postmortem examinations made upon operative cases, found the peritoneal cavity to be the seat of universal adhesions. Possibly, as suggested by Rolleston and Turner, the vascular channels of these adhesions carry off enough blood, thereby lessening the volume which passes through the liver, and this organ is thus enabled to detoxify more satisfactorily. Their suggestion perhaps resulted in the practice of rubbing the liver with gauze at operation in order to produce vascular adhesions to the under surface of the diaphragm.

In 1889, at the suggestion of Talma, Van der Menke made the first attempt at an omentopexy with a resulting death. In 1891 a patient of Schley died of peritonitis; and although a case of Lens, of Holland, lived for six months, he showed no improvement. To Morison, in 1895, is really due the credit for performing the first successful operation; the patient lived

for many years with marked improvement, dying from an attempt to repair a ventral hernia which had developed at the site of the previous incision. Since then, there have been many successes, many failures; and many changes have resulted in the operative technique and postoperative treatment.

Much has been written concerning the proper selection of cases. Drummond and Morison suggested only those cases whose ascites was due to cirrhosis of the liver. Greenough has collected from the literature cases of an omentopexy performed for ascites with rather discouraging results in cases of renal disease, tubercular peritonitis, chronic peritonitis, adherent pericardium, malaria, and syphilis.

Of 127 cases of cirrhosis of the liver admitted to the Presbyterian Hospital in the last seventeen years only 23 were chosen for operation. F. Meleney found that out of 50 cases of portal cirrhosis treated in the medical wards, 10 were transferred for operation. As a rule only those patients were selected who appeared to have enough resistance, and who had little or no evidence of nephritis or cardiovascular disease.

ETIOLOGICAL FACTORS OF THE CIRRHOSIS

Eighteen cases were undoubtedly due to excessive use of alcohol; in 2 cases syphilis was the cause; in 1 the cause was unknown, and in 2 the ascites was associated with an enlarged liver secondary to cardiovascular disease. One of these last mentioned cases died of acute cardiac dilatation directly after operation. The other, three years after operation, is still alive and greatly improved, almost equaling in the duration of the "cure," the case reported by Primrose, of Canada, of a cardiac who, tapped at least once a week during a long period of time, was relieved from further paracentesis for four years by an omentopexy. The following is a brief outline of the authors' case.

M. B., age 34, nationality, Irish; white; female; married. (Referred by Dr. Jeffrey.) The patient was admitted January 4, 1915, and discharged February 16, 1915. A diagnosis was made of cirrhosis of the liver with ascites and chronic cardiac valvular disease with auricular fibrillation. The chief complaint was swelling of the abdomen. The family history was irrelevant. The patient had scarlet fever as a child, rheumatic fever at 23, with cardiac injury and joint swelling, and mild recurrent attacks of rheumatic symptoms since. The menses have been regular. The patient has been married 12 years and has three children living and well. There had been a stillbirth three years ago. There was no history of alcoholism, and syphilis was denied by name and symptom.

The onset of the abdominal swelling had been gradual, appearing first about one and a half years ago, and accompanied by swelling of the feet. The symptoms were worse at night. For the past year the patient has suffered from gaseous eructations, nausea and vomiting. Orthopnœa has been a constant symptom from the beginning of her illness. For three weeks before admission, the patient was forced to take to her bed because of severe dyspnœa..

Physical examination shows a poorly developed, thin, and slightly dyspnœic woman. The abdomen is very large, and there are definite signs of fluid and marked œdema of the lower extremeties. The heart is hypertrophied, the apex in the sixth space; 16 centimeters to the left of the midline sounds are irregular in force and frequency. The systolic murmur at apex is transmitted to axilla, and there are rough systolic and diastolic murmurs over the base. After paracentesis, the liver edge felt as a hard, irregular, nodular mass, about one inch below the costal arch. The spleen is not palpable..

The urine is clear, amber colored, without albumin, and with a specific gravity of 1025. There are a few pus cells. Phthalein test: color in ten minutes, 43 per cent in two hours. .

Blood count: white blood corpuscles 5,400; polymorphonuclears 72 per cent; hæmoglobin, 80 per cent. The Wassermann is negative in both antigens. Blood pressure 132-72. Von Pirquet's test was slightly positive; Moro test negative.

The ascitic fluid showed a specific gravity of 1020; it was cloudy, yellow, and showed a small amount of sediment. NaCl. 717. Polymorphonuclears 10 per cent; lymphocytes 90 per cent.

Electrocardiogram tracings show auricular fibrillation and ventricular extra systoles.

On January 1, 1915, the patient was tapped and 6,000 cubic centimeters of fluid obtained; on January 7, 5,600 cubic centimeters; on January 23, 7,000 cubic centimeters; and on February 10, 1915, 10,000 cubic centimeters. On February 11, 1915, an omentopexy was done under novocaine. The liver was found to be large and rough with evidence of chronic passive congestion.

The patient was discharged as improved, February 16, 1915, following an uneventful recovery.

Our follow-up notes states that on May 2, 1915, the patient feels well, has no orthopnœa, but there are signs of fluid. On May 25, 1915, the patient was tapped and 6,000 cubic centimeters of fluid obtained. Notation of August, 1916, states that no tapping has been done for the past year. The patient works around the house and her appetite is good. November, 1916: the patient feels very well but is slightly dyspnœic; there is little fluid in the abdomen. Feb-

ruary, 1917: the patient feels very well. December, 1917: fluid has collected in the abdomen very slowly; 11,000 cubic centimeters removed.

AGE INCIDENCE

It may be doubted whether age is a factor of importance, but it does appear that before the age of twenty and after the age of forty the death rate is higher. There were 2 cases under twenty years of age and both died. From the second to the fourth decade the mortality was 16 per cent, from the fourth to the sixth, 60 per cent; and all cases that were more than sixty years succumbed to the operation.

SYMPTOMS AND PHYSICAL FINDINGS

Ascites was the cardinal symptom for which the operation was performed. This was present to a variable extent in the 23 cases. Eleven had œdema of the lower extremities; morning nausea was troublesome in 9; jaundice was present in 4 and hæmatemesis occurred in but 2 patients. Of 14 cases noted in the physical examination as being poorly nourished and emaciated with the thin drawn face, and the reddened nose with dilated venules, 43 per cent succumbed to the operation. Of 8 cases having definite cardiac disease, 3 with auricular fibrillation, 2 with myocarditis, 3 with relative mitral insufficiency, 70 per cent died. In those cases where dilatation of the deep epigastric and internal mammary veins indicated the establishment of compensatory circulation, 50 per cent died shortly after operation. This may show that where the portal channels were so obstructed as to force hypertrophy of collaterals, operative interference was of little value, the functional liver tissue being inadequate for the demands.

RAPIDITY OF THE ONSET OF SYMPTOMS

There is, indeed, an interesting relationship between the suddenness with which symptoms develop and the prognosis. In 2 cases ascites developed within three months and both died. of 4 cases where the ascites was of six months' duration, 3 died; of 7 cases where the ascites developed over an extended period of one year or longer, there was no mortality. It is quite evident then, that the slower the effusion into the peritoneal cavity, which perhaps may be considered a gauge of the rapidity of the pathological process, the better the operative prognosis. Whether the number of ante-operative tappings, which were always greater where the disease was rapid in onset, are of any prognostic value may be gathered from the following tables: 4 cases tapped 15 to 25 times, mortality 75 per cent; 5 cases tapped 6 to 10 times, mortality 50 per cent; 14 cases tapped 1 to 5 times, mortality 30 per cent.

ANÆSTHESIA AND THE TYPE OF OPERATION

As far as the anæsthesia is concerned, some cases were operated upon under cocaine and novocaine, and some under a general anæsthetic of gas and ether, the former with a mortality of 29 per cent, the latter with a death rate of 37 per cent. While many authorities claim that the anæsthesia, whether local or general, has little or no effect, it must not be forgotten that most cases of cirrhosis of the liver are due to alcohol and that in this group, the risk of an anæsthesia is relatively great. The same risk may be increased still further by an associated nephritis. The operation with local anæsthesia is easily borne if the parietal peritoneum is carefully infiltrated, and if no undue traction is made in drawing the greater omentum into the wound. Furthermore, a local anæsthesia diminishes the risk of postoperative pneumonia and largely eliminates postoperative nausea and vomiting, and consequently, the frequency of a subsequent ventral hernia, although a rare complication.

The operation itself, as originally planned by Talma and carried out by Morison has undergone many subsequent modifications. Morison and Drummond advocated an incision from the ensiform cartilage to the umbilicus through which the peritoneum was opened, and a portion of the anterior surface of the great omentum sutured to the posterior surface of the parietal peritoneum. The liver and spleen had been previously vigorously rubbed with gauze, so as to promote and encourage vascular adhesions to the diaphragm. This practice obviously was attended with much shock.

Nareth modified this by bringing the omental tab in between the recti muscles and their fascia, to a position directly beneath the surface of the skin.

Schiassi, of Bologna, sutured the omentum to the posterior surface of the peritoneum and to the preperitoneal space, sewing tightly the anterior sheaths of the recti in the midline so as to insure a firm closure.

Greenough, in his collection, states that the method of Talma and Morison used in 68 cases showed improvement in 41 per cent and a mortality of 32 per cent; while the method of Schiassi used in 23 cases gave 43 per cent improvement and a mortality of 17 per cent.

The Mayos make an incision over the right side of the liver in line with the deep epigastric and internal mammary vessels so that a thorough exploration can be made. About 4 inches below, a second incision is made, through the rectus down to the posterior sheath. A tab of omentum is then drawn from the upper incision down into the pocket formed by the posterior sheath of the rectus and the muscle itself. This may be done on both sides and the intervening segment of the omentum sutured to the parietal peritoneum.

In the present series, the type of operation prior to 1908 was that advocated by Morison; subsequent to 1908, the method of Schiassi was adopted, with slight modifications. Ordinarily, a three-inch incision is made in the midline about two inches below the ensiform cartilage, the fascia of the linea alba divided, the recti retracted to either side, and the posterior sheath and the peritoneum incised. The fluid, remaining after a paracentesis twenty-four hours before operation, is further aspirated by suction through a metal catheter. In withdrawing the omentum, care is taken not to distort the position of the transverse colon. A vascular portion of the omentum is then sutured to the posterior surface of the parietal peritoneum with interrupted chromic catgut; further, the tongue of the omentum is sutured lightly to the posterior sheath of the rectus in the preperitoneal space and to the edge of the rectus muscle. Then, the sutured sheath of the rectus is closed with interrupted chromic catgut, and continuous silk is used to close the skin. After the sterile dressing, a tight binder is applied, and directions given that in case of vomiting the patient should receive manual support. The operation as a rule requires about thirty minutes.

In the early cases of omentopexy, drainage of the peritoneum was employed. It was later omitted for several reasons. First, the drainage tract might act as an entrance for infection; and furthermore, some patients drain enormous quantities of fluid, which resulted fatally in one case in spite of saline given by hyperdermoclysis, proctoclysis, and intravenously. Where drainage is omitted, some claim there is danger from the mechanical effects due to the reaccumulation of fluid after operation. But should this occur, should the fluid become sufficient in amount to embarrass either the heart or respiration, paracentesis may be employed at any time forty-eight hours after operation. One advantage claimed for drainage is that through the formation of adhesions the peritoneal cavity is partially obliterated, and hence the space is restricted for the subsequent accumulation of fluid. Ito and Omi have shown that in dogs the peritoneal cavity might be obliterated by tamponade of the abdominal cavity for twenty-four hours; yet it is very doubtful whether even partial obliteration occurs in man. In his collection of 54 cases, Greenough states that drainage was instituted in twenty, with a resultant mortality of 50 per cent; while in the 34 cases where the drainage was omitted, there was a death rate of 14 per cent. In the present series, drainage was employed in 5 cases, a mortality of 80 per cent resulting; while in the 18 cases where it was not used, there were seven deaths, or 38 per cent. Practically all surgeons have agreed that drainage is unnecessary, of no distinct advantage, and certainly multiplies materially the operative risk.

APPEARANCE OF THE LIVER

The appearance of the liver at operation is usually either hypertrophic or atrophic. In the present series, there were 3 cases of enlarged liver, one of which died; while of 13 cases of a small and shrunken liver, 7 died after operation. In Greenough's summary, there are 15 cases of an enlarged liver, 3 of which died after operation, and 9, or 60 per cent, showed improvement; and in 37 cases of an atrophic liver, 11, or 29 per cent, died after operation, while 36 per cent were improved. White, in his collection of 106 cases, mentions

the pathology of the liver and derives the following statistics:

Hypertrophic, 24; cured, 10; improved, 6; unimproved, 3; died, 5.

Atrophic, 82; cured, 38; improved, 7; unimproved, 10; died, 27.

POSTOPERATIVE COURSE

There were eight postoperative deaths in this series, seven occurring within the first eight days and one on the seventeenth day after operation. Of these eight deaths, six were due to a combination of cholæmia and uræmia; one was due to a cardiac failure, and one the result of a mesenteric thrombosis. A brief résumé of the last mentioned case is herewith appended:

J. M., age 50, male; married; German; fish dealer. The patient was admitted January 24, 1916, died February 28, 1916. Diagnosis: cirrhosis of the liver. The family history is irrevelant. The patient is markedly alcoholic having taken large amounts of whiskey daily for the past ten years. Three weeks before admission he noticed a gradual swelling of the abdomen, with a progressive feeling of great weakness, and morning nausea with vomiting. There were no hæmorrhages from the nose, mouth, or rectum. Physical examination shows a markedly emaciated man, slightly jaundiced, accentuated aortic second sound. There is marked ascites and general condition of arteriosclerosis. The urine is clear amber, specific gravity 1030; albumin faint trace, hyaline and granular casts. The blood count showed white blood corpuscles 6,000; polymorphonuclears 70 per cent. The Wassermann was negative in both antigens.

January 26, 1916. Patient tapped and 2,000 cubic centimeters withdrawn. February 9, 1916, 6,000 cubic centimeters withdrawn, February 18, omentopexy was done under gas and ether—time 20 minutes. The liver was found to be small and nodular. February 23, temperature 103° and patient feels comfortable. The abdomen is soft, slightly distended. February 26, temperature daily reaches 103°. The wound is clean. Distention is but little relieved by colon irrigation. Paracentesis removed 2,5000 cubic centimeters of dark brown fluid. Analysis of the fluid showed protein, 1 per cent; much pus; polymorphonuclears 68 per cent. February 27, the abdomen was soft except in the right lower quadrant and around to the flank where there is moderate rigidity. The patient breathes rapidly but the lungs are clear. There is slight nausea with vomiting of greenish fluid, not fæcal. February 28, the patient is very restless, irrational, and cyanotic. The abdomen is soft. Death in coma.

Autopsy by R. A. Lambert. The liver weighs 1950 grams and is typically hobnail. There is thrombosis of the superior mesenteric vein just below the mouth of the splenic vein. Acute diffuse purulent peritonitis.

Of the 75 cases of postoperative death collected by White, 14 died of peritonitis; 12 of uræmia; 10 of shock and cachexia; 3 of hæmatemesis; and 2 of intestinal obstruction. It is interesting to note that two of our cases died from what was presumably acute hepatic insufficiency — the latter characterized by a complete group of nervous symptoms, so marked, that in one case a diagnosis of meningitis was made. It will be remembered that Morison reported a similar occurrence in a case where undue excitement and depression prevailed after operation. At that time, this was thought due to the injurious effects of turning the stream of portal blood into the systemic circulation. It may, indeed, be doubted whether the anastomosis is effective in so brief a postoperative period; specimens taken at the autopsies of these two cases and of one which died six weeks after operation showed no macroscopic signs of newly formed blood vessels. Unfortunately, microscopic sections were not made.

Herewith is given a summary of two cases which showed marked symptoms of nervous character after operation.

E. K., age 19, American; schoolgirl; single. Admitted January 18, 1915; died February 15, 1915. Diagnosis: cirrhosis of the liver. The family history is irrevelant. At the age of five, the patient had had measles and scarlet fever, with no sequelæ. The patient's menses were regular, syphilis was denied, and she made no use of alcohol. For the past six months the patient has noticed a gradual swelling of the abdomen with no other symptoms. She was tapped three times in the last two months before admission, the last tapping being five days before admission. Physical examination showed a very emaciated, poorly nourished girl, with no other abnormalities except marked ascites. The urine was clear amber color, specific gravity 1030, and was negative as to albumin and microscopic examination. The blood count showed 12,000 white blood corpuscles, polymorphonuclears 75 per cent. The Wassermann was negative in both antigens; von Pirquet negative; stools negative for parasites; phthalein test showed color in ten minutes, 41 per cent in two hours.

February 1, 1915, omentopexy was done, under gas and ether. The liver was found to be small, hard and of hobnail appearance. Nine thousand cubic centimeters of clear amber fluid were aspirated.

February 13, 1915. For past few days the patient

has been getting very apathetic and there are signs of a reaccumulation of abdominal fluid. February 14, the patient is very stuporous and has suffered three periods of excitement during which she screamed and bit, and gave no response to questions. Paracentesis of the abdomen relieved the patient of 10,000 cubic centimeters of clear amber fluid. February 15, the patient is very stuporous and has voided very little urine today. Up to the present a normal quantity of urine was voided which was negative to examination. No abnormality was observed in regard to the abdomen except the reaccumulation of fluid. The patient died in convulsions. Autopsy showed a liver weighing 750 grams, of typical hobnail cirrhosis appearance. The kidneys were normal.

J. C., age 12; single; schoolgirl; Bohemian. Admitted January 15, 1917; died February 8, 1917. Diagnosis: cirrhosis of the liver. One sister died at the age of 19, from cirrhosis of the liver, thought to be syphilitic. The patient had measles at the age of three with no sequelæ. The patient had always been well until the onset of present illness. She had never used alcohol. For two weeks previous to admission, the patient noticed that the abdomen was increasing progressively in size. She had no pain, no nausea and no vomiting. She had noticed no swelling of the legs. She urinated five and six times a day and twice at night. Physical examination revealed a very thin little girl, with no stigmata of congenital syphilis. The abdomen was filled with fluid but no masses could be made out. Œdema spread over sacrum, legs and ankles.

On January 16, 1917, 6,000 cubic centimeters of pale amber fluid were removed by paracentesis. The laboratory examination reported the fluid to be ascitic, with specific gravity of 1013, protein 5 per cent, NaCl 6.4 grams per liter. Cellular examination showed polymorphonuclears 1, lymphocytes 48, endothelial cells 41, degenerated cells 10 per cent. The urine was clear amber, specific gravity 1030; albumin negative; microscopical examination negative. The Wassermann was negative in both antigens. A guinea pig inoculated with ascitic fluid at autopsy showed no tuberculosis.

February 2, 1917. Omentopexy under gas and ether. The liver was very small, hard and nodular. February 3, the patient is very comfortable. February 4, the patient screams with pain and points to upper abdomen. She seems stuporous. The abdomen is soft without rigidity, but distended; no vomiting, no nausea. No relief from colon irrigations. She voids normally. February 5, the patient appears slightly better. February 6, she has signs very suggestive of meningitis. The arms and legs are flexed, neck slightly rigid; suggestive Kernig sign. Lumbar puncture showed no increased pressure. Ten cubic centimeters of clear fluid were withdrawn; 4 cells. The Noguchi was negative; Wassermann negative; no tubercle bacilli were found. February 8, 1918, the patient died in coma.

Autopsy. The liver weighs 760 grams and measures 18 x 13 x 7 centimeters. It is small, firm, with projecting masses from 1 to 6 millimeters. The tissues between liver nodules are opaque and yellow.

Miscroscopic examination. The cells of the liver seem swollen and hyaline; innumerable groups of cells are evidently regenerating from radicals of bile-ducts. The lobular structure of the cells is entirely lost. The spleen is slightly enlarged. The kidneys are normal. The great omentum is adherent to line of incision and infiltrated with a large extensive hæmorrhage. Hæmorrhage is also present in the right lung, but very small beneath pleura. The cause of death is thought by Dr. G. MacKenzie, pathologist, to be hepatic insufficiency with amino-acid poisoning. The pain was caused by hæmorrhage into the omentum and hæmorrhages were thought to be due to the insufficient formation of fibrinogen by the liver.

END—RESULTS

When it comes to the ultimate question of the actual benefit derived from the operation, the criterion necessarily must be the relief of the symptom for which the operation was designed, namely, the diminution in the number of tappings and the final disappearance of the peritoneal fluid. The seven cases of which we have postoperative records show the following:

Ante-operative Tappings	Postoperative Tappings
Case 1.	
7 in 2 months	
1 in 1 month	3 in 5 months
25 in 13 months	0 in last 16 months
33 in 16 months	
Case 2.	
6 in 4 months	0 in last 11 months
Case 3.	
11 in 4 months	0 in last 4 months
(Average about 12 days.)	
Case 4.	
1	0 in 1 year, 3 months
Case 5.	
4 in 28 days	6 in 54 days.
(Average about 8 days.)	At present intervals over 14 days
Case 6.	
2 in 6 months	2; 1 after 5 months, 1 after 9 months
Case 7.	
Never tapped.	No tapping for past 3 years.

Therefore, in 7 cases under observation from three months to three years after operation, definite benefit has been derived. Of the 8 fatal cases after the omentopexy, 1 died at four, 1 at three, and 1 at nine months respectively, with no benefit. Five cases left the hospital as improved, but all trace of them was lost. Of the 7 previously cited recoveries, ventral hernia at the site of incision was the sole complication observed.

In reviewing his 16 cases, Grey Turner reported 5 postoperative deaths within a few days; 3 from pneumonia; 1 from uræmia, and 1 from cholæmia. Of the 11 who survived, 5

died subsequently, leaving 6 alive and well seven months to seven years after operation. This author believes that the operation proved successful where ascites was due, not to toxæmia, but to portal obstruction; furthermore, that this may be indicated when several tappings had caused no material disturbance; and patients with rapid emaciation, slight jaundice, and œdema of the extremities should not be considered as suitable risks. Ladenburger advises operation as soon as the case is diagnosed as ascites due to portal obstruction, and when, after the first tapping, there is a reaccumulation of fluid. Welp and Montprofit are even more radical, advising immediate operation. We have always believed it best to tap at least once and even more, before the operation; for occasionally a patient will go into absolute collapse following paracentesis; and rarely after a tapping or two will the patient have a return of ascites.

At the French Surgical Congress in 1904, Professor Montprofit, in an analysis of 224 cases collected from the literature, deduced some interesting statistics as far as end-results are concerned. Eighty-four cases, or 38 per cent, died within the first month — some from postoperative shock; 9 from peritonitis; 7 from complications of the heart, lungs and kidneys; 30 from late causes of cirrhosis; 8 from stomach complications; 4 from renal disease. Eleven cases were not followed up, and 25 cases were not improved. Twenty-six cases were tapped at long intervals and complained less of bleeding. Seventy cases were therapeutic cures; that is, either the ascites had disappeared or the hæmorrhages were arrested.

Bunge in his collection of 273 cases states:

	Per Cent
57 died in one month	20.8
90 not improved	32.9
35 improved	12.4
91 cured of ascites	33.0

White, excluding from Bunge's statistics and Montprofit's table the doubtful and valueless case reports and cases other than those of cirrhosis, collected 227 cases:

	Per Cent
Deaths, 75	33
Failures, 34	15
Improved, 29	13
Cured, 84	37.3

	Number of Cases
Cured for 6 mos. to 1 year	7
Cured from 1 to 2 years	7
Cured from 2 to 3 years	17
Cured for 3 years	5

SUMMARY

In regard to the prognosis, probably the most favorable cases are those between the second and fourth decade, fairly well nourished, without severe nephritis, without cardiac lesions, without signs of compensatory circulation, which have stood a few tappings (not more than five), in which the disease has come on gradually and slowly, — the symptoms extending over a year,— where the liver was of the hypertrophic variety, and for which an operation of omentopexy was performed of the Schiassi type, without drainage, preferably under local anæsthesia. That the operation is of benefit in carefully selected cases, there can be no doubt.

REFERENCES

Dickinson, C. H. Allbutt's System, vol. iii, p. 691.
Drummond and Morison. Brit. M. J., 1896, Sept.
Frazier, C. H. Am. J. M. Sc., 1900.
Greenough, A. Am. J. M. Sc., 1902.
Hahn, Nasse, Neckst, and Pawlow. Arch. f. exper. Path. u. Pharmakol., 1893, xxxii, 166.
Ladenburger, H. Die Talmische Operation. Wuerzburg, lxviii, No. 7.
Mayo, C. Keene's Surgery, vol. iii, p. 981.
Montprofit. French Surgical Congress, 1904.
Rolleston. Diseases of the Liver, p. 261.
Thomson, H. C. Med. Chir. Tr., xxxiv, 321.
Turner, G. Brit. M. J., 1906, Nov.
Talma. Berl. klin. Wchnschr., 1898, Sept. 19.
Weber, F. P. St. Bartholomew Hosp. Rep., xxxiv, 321.
White, S. Brit. M. J., 1906, Nov.

DEPARTMENT OF TECHNIQUE

INCOMPETENCY OF THE URETEROVESICAL VALVES NOT DUE TO OBSTRUCTION

By THOMAS N. HEPBURN, M.D., F.A.C.S., Hartford, Connecticut

INCOMPETENCY of ureterovesical valves not the result of intravesical pressure is quite uncommon so far as we know by reported cases. Hagner,[1] in 1908 and again in 1912, reported 4 cases of regurgitation of bladder fluid around a catheter in the ureter. He believes this phenomenon occurs only in "chronic inflammatory diseases of the ureteral orifices and is produced by infiltration and cicatricial tissue formation in this region which causes a destruction of the valve-like arrangement in the normal ureteral orifice." Two of Hagner's cases were secondary to tuberculosis of the kidney; one case was secondary to bilateral renal calculus, and one case was secondary to a previous prostatic obstruction for which a successful prostatectomy had been done. This last case, in my opinion, belongs to the more common group as being the result of intravesical pressure, and therefore does not come completely within the scope of his inflammatory etiology theory.

[1] Surg., Gynec. & Obst., 1912, xv, 510.

Fig. 1. Shows the bladder distended with 15 per cent thorium which has found its way into both ureters and both renal pelves. Note the small bladder and the normal renal pelvis outlines.

Kretschmer and Greer in 1915[2] review the cases reported before this time and add one of their own with a very good X-ray picture taken with collargol showing a dilated bladder, incompetent ureterovesical valves, dilated and kinked ureters and dilated renal pelves and calyces. They do not explain the etiology in their case, but with the cystoscopic report of trabeculation of the bladder and the roentgenogram showing dilatation of the bladder, the etiology in my opinion was very probably intravesical pressure perhaps secondary to a central lesion impossible of demonstration.

In analyzing the sixteen cases reported in Kretschmer's article, it is interesting to note that Cases 2, 3, 6, 8, and 16 give a definite history of obstruction to urination, so that intravesical pressure may have been the predominating etiological factor in causing the incompetency of the ureterovesical valves. Cases 1, 5, and 7 give a definite history of the trouble beginning with pain in the kidney region so that they can be looked upon as probable cases of ureterovesical incompetency, the result of a descending infection, and can therefore be classified with three of Hagner's cases. Cases 9, 10, 11, 12, 13, 14, and 15 are reported with no history of onset, only the cystoscopic findings being given, so that it is quite impossible to speculate as to their etiology. This leaves Case 4, which was reported by Israel as following childbirth and being ushered in by bladder cramps. He made no X-ray with shadow-

[2] Surg., Gynec. & Obst., 1915, xxi, 228.

producing fluid, but one kidney was enough diseased to require nephrectomy. This fact suggests that very possibly renal infection was the cause of the cystitis, so that this case probably belongs with Hagner's group of descending infection.

To the above cases I wish to add one which bears out Hagner's theory of inflammatory infiltration as a cause of ureterovesical valvular incompetency, but which differs from his cases in that the inflammation apparently started in the bladder instead of in the kidneys.

History. October 23, 1916. Female, age 21. Following a difficult labor 18 months ago she had dysuria and incontinence. This was so marked that her urine dripped constantly and her bladder felt "on fire." Her condition so embarrassed her that she had not left the house for over a year, being almost constantly confined to bed. She had no pain other than in her bladder. Her general health was excellent.

General physical examination showed a fairly well nourished girl, with no tenderness anywhere except over the bladder, no fever, and no leucocytosis. Cystoscopic examination showed a bladder so small that it could hardly be dilated enough to get any vision. The wall was covered with a thick whitish membrane which, when pealed off, left a raw bleeding surface. Neither ureteral opening could be located easily, and the examination was so painful that a prolonged search was not attempted.

Diagnosis, interstitial cystitis.

Treatment. At first the various antiseptics were used, but they increased her pain so that they had to be given up after a week's effort, with no benefit. It was then I made use of a suggestion, which I first saw in an article by Caulk, of using bulgaris bacillus, mixing an ounce of an emulsion of bulgaris bacillus with an ounce of saturated sugar solution, and injecting it into the urethra with a blunt-nosed syringe. Within 48 hours she was relieved of pain, and within 4 days she began to have a little control of her bladder sphincter. These daily injections were continued and she improved so that at the end of a month I could cystoscope her with ease.

At second cystoscopic examination the bladder could be dilated to 75 cubic centimeters. The wall showed chronic cystitis. The right ureteral opening was dilated to 6 millimeters in diameter. It admitted a No. 7 F. catheter easily and cloudy urine flowed freely. A specimen sent to the laboratory was reported filled with pus cells. The left ureteral opening was dilated to 5 millimeters in diameter. It admitted a No. 7 F. catheter easily and cloudy urine flowed freely. A specimen sent to the laboratory was reported filled with pus cells.

A differential renal function test was made by injecting 6 milligrams of phenolsulphonephthalein intravenously. The right kidney excreted it in 4 minutes and in 15 minutes, 7 per cent; the left kidney excreted it in 4 minutes and in 15 minutes, 7 per cent. There was bladder leakage around the catheters, 15 per cent.

A roentgenogram was taken after introducing by gravity through a bladder catheter as much 15 per cent thorium as she could comfortably stand. This picture is shown in Figure 1. It demonstrates a small bladder, with incompetent ureterovesical valves and approximately normal renal pelves.

Within two months after beginning the bulgaris bacillus injections the patient could hold her urine for an hour at a time, and she left the hospital to go to work. A month later she returned at my request for another cystoscopy.

A third cystoscopic examination showed the bladder capacity only 150 cubic centimeters. The mucosa was normal. The right ureteral opening was 5 millimeters in diameter. The left ureteral opening closed almost to normal size.

A second roentgenogram was taken as before and very little of the thorium ascends into the left ureter but the right valve is still quite incompetent.

The patient is now away doing war work and is apparently in the best of health.

CONCLUSION

1. Acute interstitial cystitis may cause incompetency of the ureterovesical valves with an ascending pyelitis, even when there is no history of retention, or sign of bladder distention.

2. That treatment of interstitial cystitis by injection with bulgaris bacillus may be a valuable aid.

3. That recovery of the normal function of the ureterovesical valves after prolonged incompetency is a problem of which we know little, and it is to be hoped that urologists will make a point of noting the degree of recovery in reporting such cases.

AN OPERATION FOR THE PRODUCTION OF STERILITY

By RALPH C. CUPLER, M.D., F.A.C.S., Chicago
Professor of Clinical Surgery, Loyola University; Surgeon, St. Anthony's Hospital

IT is occasionally important to sterilize a woman without removal of any of the organs. Simple tying, section or exsection of the tube as recommended by Blundell in 1812, is quite inadequate as the lumen of the tube becomes readily re-established. Abolition of the tubes, a wedge-shaped section being removed from each uterine cornu including the tubal mucosa, is safe. Also division of the tube and the cut ends covered with broad ligament is considered safe.

During the past ten years I have used successfully the operation to be described. I have had

opportunity to observe the result of the procedure many years after it was performed and on each occasion there was no attempt by the tube to re-establish itself. In favor of this method is the fact that the tube can be made patent again by salpingostomy or end-to-end anastomosis.

This operation can be done rapidly and I believe secures sterility in 100 per cent of the cases. There is only a small portion of the ovaduct removed. It is based on a sound surgical principle. Crushing out of the mucosa thereby doing away

with the endothelial cells, bringing in contact the ribbon of connective tissue, gives to us a condition most favorable to healing and minimizes the possibility of the endothelial cell regeneration and the consequent re-formation of the duct. It is quite true and is keenly recognized that the operation of election in any surgical condition is the one that gives the most to the patient. I simply present my experience in the management of this class of cases, and the method I have used.

Operation. Infiltration or general anæsthesia. The abdomen is opened by a suprapubic, median incision. The tube is delivered and held in a position to be easily handled. A No. 1 catgut is placed around a small area in the broad ligament including the blood-vessels supplying a limited part of the tube. The tube is then divided and a peritoneal cuff on the proximal end is turned back, the denuded muscle and mucosa is crushed in the bite of an angiotribe. No. 0 catgut ligature is applied in the crease, the cuff is brought over and a ligature applied. The distal end of the tube is ligated, and both ends approximated and the rent in the broad ligament closed. The relation of the structures now appear quite normal. The opposite tube is treated in the same manner and the abdomen is closed in the usual way. The operation can be done by the vaginal route. I have used it in the vaginal interposition operation for procodentia uteri.

LOWE'S COLOSTOMY RECEPTACLE

By Captain HORACE A. LOWE, M.C., U. S. A.
Base Hospital, Camp Shelby, Miss.

I AM prompted to report this apparatus because it has proven a success in my hands and is, I think, a distinct improvement over ones commonly used.

The unfortunates who have to spend the balance of their days, or even part of them, with colostomy openings are entitled to everything possible that will make their condition more bearable and if this will help, if only in a small way, I shall feel grateful. The apparatus is simple, efficient and can be self-adjusted.

It is constructed like the ordinary colostomy receptacle with the pneumatic ring and rubber pouch. Instead of being held in place by a belt, it is held by an ordinary truss spring, which distributes an equal pressure around the opening, the pressure remains constant with changes of the body position and, therefore, prevents leakage. The advantages claimed are:

1. The spring attachment keeps a constant pressure on the pneumatic ring which is equally distributed and prevents leakage.

2. Does away with the perineal straps and belt.

3. The constant pressure of the spring preserves the contour of the abdomen and prevents the tendency to hernia.

In this connection, I should like to point out a few of the salient points in dealing with colostomies. The incision should be made well toward the median line opposite the anterior superior spine, if a receptacle is to be worn; otherwise the rim of the receptacle will encroach upon the crest of the ilium and make it hard to adjust to prevent leakage. Constant pressure against the bone also produces irritation and makes the apparatus uncomfortable.

The skin and fascia incision should always be small with close approximation of the skin and fascia to bowel, allowing it to remain thus for twenty-four to forty-eight hours, depending on amount of obstruction, before opening the bowel. If it is necessary to explore the abdomen, a median incision or rectus incision should be employed. The colostomy incision should never be made large enough for an exploratory operation.

THE POCKET METHOD OF CLOSING SKIN DEFECTS

By JOSEPH E. FULD, M.D., New York
Instructor in Operative Surgery, College of Physicians and Surgeons, Columbia University; Assistant Visiting Surgeon, City and Governeur Hospitals

THE successful outcome in plastic operations depends far more on careful attention to details than anything else. Every possible effort should be made to observe the apparently minor points. If the operation is a failure, the final result may be even worse than the original deformity and in many cases the operation cannot be repeated.

The pocket method of skin grafting consists in raising a bridge of skin and subcutaneous tissue from the underlying aponeurosis, inserting under it the part to be grafted, and fixing it there until union between the raw surfaces has taken place, when the two pedicles are cut. It is very important to take a Wassermann and never to operate while there is an active syphilitic process.

This method is indicated when it is necessary to cover large skin defects of extremities as after injuries of hand, wrist, finger or foot especially about their joints; to remove cicatrices which bind down tendons and interfere with action of muscles or their tendons; and to restore flexion or extension.

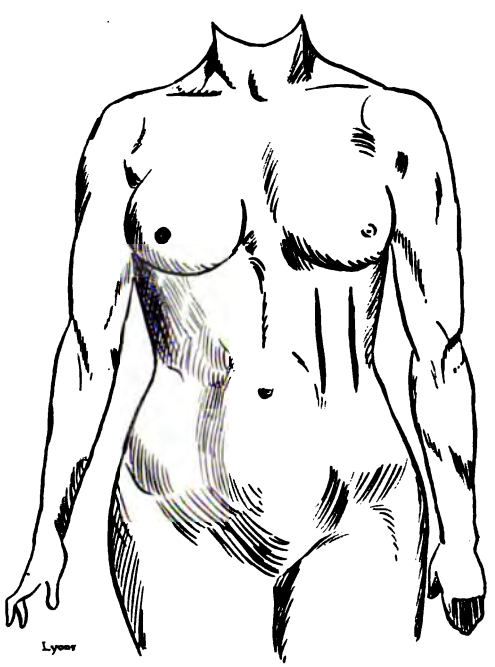

Fig. 1. Incisions for the two pedicled skin graft.

The patient, a female, age 20, came under my care about October 1, 1917, and was admitted to the Park Hospital, October 6, 1917. Family and past history negative. While working in a laundry, about 2½ months before her admission to the hospital, her right hand was caught in a mangle. The skin and subcutaneous tissue were torn off the dorsum of the hand, exposing all the extensor tendons. The wound refused to heal. The extent of her injuries is clearly shown in the accompanying photograph. In addition to the skin defect due to cicatricial contraction of the dorsum of her hand, the extensor tendons were fixed, so that she was unable to close her hand. This made the indications for the operation twofold: (1) to cover skin defect, and (2) to prevent contraction.

Preparation of the patient. My first effort was to improve her health and strength by general hygienic, dietetic, and tonic measures.

The operation which I planned for her relief was to transplant from the abdomen to the dorsum of the hand a strip of normal skin, broad enough to fill the gap left after excision of the scar tissue binding down the extensor tendons and allow the flexor tendons to act in the closing of the hand.

Preparation of the wound. The skin of hand and abdomen was surgically prepared. At the first step of the operation all the cicatricial tissue was removed, then the edges of the wound were freshened and elevated allowing them to retract away from the field, so as to free the field far above and below, thus preparing the bed for the transplant.

Two parallel vertical incisions were made extending from a little below the left nipple to a line on a level with the umbilicus, cutting right down to the aponeurosis of the abdominal muscles, including in the flap the entire thickness of the skin and subcutaneous tissue of the abdominal wall. The formation of adhesions is prevented by the fat which is present in the flap. The far edges of

Fig. 2 (at left). Condition of the hand before operation.

Fig. 3. Condition of the hand six weeks after the operation. Sutured edges were united by primary union leaving only a faint scar.

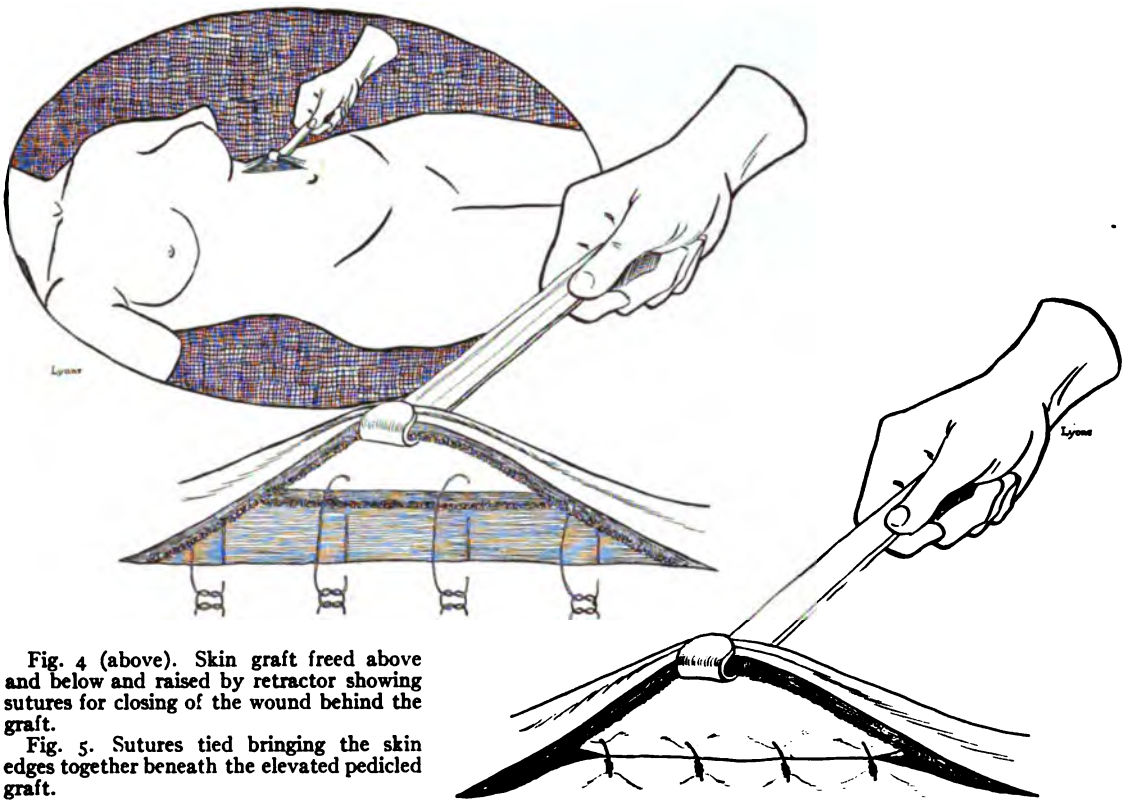

Fig. 4 (above). Skin graft freed above and below and raised by retractor showing sutures for closing of the wound behind the graft.

Fig. 5. Sutures tied bringing the skin edges together beneath the elevated pedicled graft.

the wound were sutured together under this flap so as to restore the continuity of the abdomen.

The patient's hand was now passed beneath the flap with the palm facing the abdomen and the dorsum in contact with the under surface of the flap. The skin edges of the hand wound were sutured to the flap, which must be gently handled, carefully adjusted, and precisely sutured, as accuracy of apposition is essential. From the natural contractility of the skin it contracts and shrinks considerably, so it must therefore be one-third wider than the defect to be filled, and longer than apparently necessary to avoid undue contractility on the pedicles. Perfect hæmostasis, strict asepsis and antisepsis are necessary to assure success. The flap lived in its entirety. The sutured edges were united by primary union. The cut edges of the flap bled freely, which spoke well for a successful outcome. The freshly cut edges were now sutured to the hand and a dry gauze dressing held in position by a bandage applied. The position in which the hand is held is a very comfortable one. The hand and arm must be kept perfectly still for 15 days, and the best way to procure this immobilization is to retain arm against abdomen with adhesive plaster.

The graft is released from its pedicle 15 days after the operation.

Under local anæsthesia on the 15th, both pedicles of the bridge flap were entirely severed and the hand released from the abdomen. The cut edges of the flap bled freely, which spoke well for a successful outcome. The freshly cut edges were now sutured to the hand and a dry dressing applied.

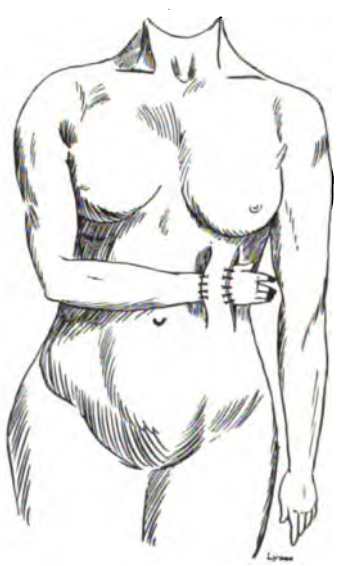

Fig. 6. Hand passed beneath the flap with the palmar surface facing the abdomen and the dorsum in contact with the under surface of the flap. The skin edges of the hand are sutured to the skin graft.

Final result. The skin defect is perfectly covered. The patient is able to flex and extend the fingers. The hand grip is strong; the esthetic effect marked; the only scars shown are the suture lines at the union of the flaps, replacing the unsightly and awkward scar of a granulating surface.

CONCLUSIONS

The advantages of this method far outweigh the disadvantages of a two stage operation.

1. The blood supply from two pedicles insures the necessary viability.
2. There is no stimulation of connective-tissue formation and resultant cicatricial contraction.
3. The presence of fat in the flap prevents adhesions to the tendons below.
4. The raw surfaces are approximated and held in position with ease.
5. The two pedicles act as splints to hold the grafted portion in position.
6. At least six weeks is saved in healing time.
7. The excellent pressure surface is of great advantage in this part of the body exposed as it is to rough usage, traumatism, constant flexion, and extension.
8. Finally it is the method of choice when the sliding method is impractical.

A SIMPLE METHOD OF EXCLUDING THE SEPTIC END OF THE BOWEL DURING INTESTINAL RESECTION

By R. E. FARR, M.D., F.A.C.S., Minneapolis, Minnesota

IN doing an intestinal resection, numerous methods have been devised for protecting the peritoneal cavity from contamination. The remaining ends of the bowel may be sterilized by cauterization or inverted, and the same treatment may be accorded the portion of the bowel which is to be excised, but this takes time. For the method recommended the materials are always at hand, and the septic bowel may be excluded in an instant after its division without the slightest possibility of contamination.

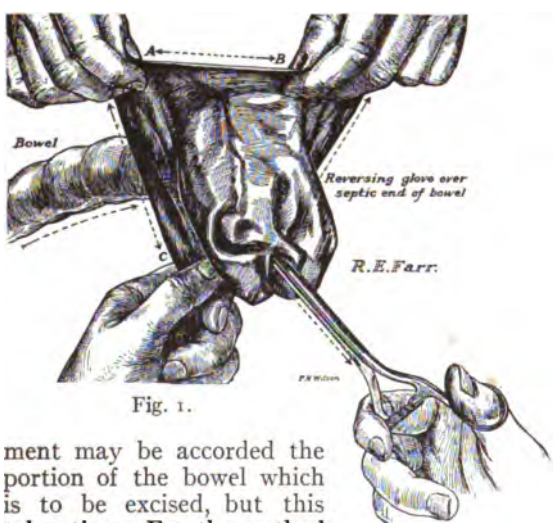

Fig. 1.

At the first point of division of the bowel a heavy clamp is placed upon the portion which is to remain, while the portion to be excised is grasped by a long-handled forceps, the blades of which have been inserted into two fingers of a sterilized glove (Fig. 1). After the division of the bowel by knife, scissors, or cautery, the end that is to remain may be treated in the usual manner. The end which is to be removed is held in the forceps, as illustrated (Fig. 1); the operator then grasps the glove at point *C* with his left hand, and his assistant grasps the glove at points *A* and *B*. By making traction, the sleeve of the glove assumes a triangular form (Fig. 2); the septic end is then made to disappear by making traction upon the forceps, the glove being turned inside out over the bowel and there securely clamped by means of a forceps.

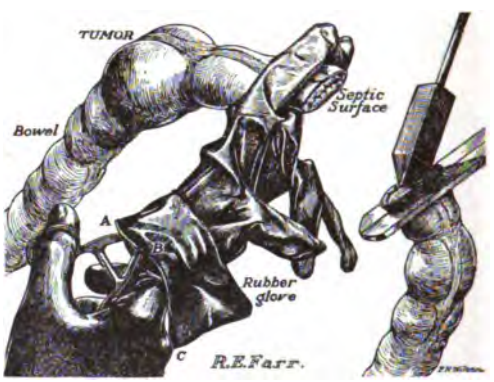

Fig. 2.

This principle may be applied in many other operations where a septic mass with a pedicle is to be isolated.

SIMPLIFIED TECHNIQUE FOR THE INTRAVENOUS INJECTION OF SALVARSAN OR ANTITOXIN IN COMBINATION WITH NORMAL SALT SOLUTION

By PETER C. CLEMENSEN, M.D., Chicago

ABOUT two years ago, I began using normal salt solution more or less regularly in all intravenous injections of salvarsan and the newer preparations, diarsenol, arsenobenzol and nov-arsenobenzol. I had noticed that the watery solution prepared according to the directions of the manufacturer would in many patients cause a painful sensation in the vein. I think most physicians will bear me out as having observed similar symptoms.

Also I preferred to use the salt solution because with it it is possible to inject any fluid into the vein very slowly at blood temperature, 100° F. This cannot otherwise be done with a small volume of fluid, as it cools too rapidly. Since I started to give antitoxins intravenously, I have observed that it is very important that the serum be heated to blood temperature before starting to inject it and to maintain it at that temperature until it is all injected.

The apparatus which I have devised for this purpose consists of a quart flask; a rubber cork[1] with two quarter inch holes; two pieces of one-fourth inch glass tubing; a large thermometer, one-fourth inches in diameter; two lengths of pure para rubber hose; two glass hose connections, one of them ground in one end to fit a Fordyce needle; one 20 cubic centimeter Luer syringe; one Fordyce needle; a piece of rubber hose and a pair of artery forceps for a constrictor for the arm.

The technique I use is as follows:

Several flasks of normal salt solution are sterilized and corked with cotton stoppers, covered with gutta percha tissue and are ready for use. I remove the gutta percha and cotton stopper and in its place insert the rubber cork in the flask with the short glass tube and the thermometer (all previously sterilized). Then the flask is placed on an asbestos pad over a Bunsen burner (or gas stove) and heated until the salt solution shows a temperature of 110° F.

The thermometer is removed and the long glass tube inserted through the hole in the cork which it formerly occupied. This tube should be brought close to the bottom of the flask as it is to act as an air tube. The sterilized rubber hoses and their connections are now fastened to the short glass tube in the flask and the same inverted and held by an assistant, or suspended in a ring holder, *A*, as illustrated.

The arm to be used for the injection, having previously been prepared, is placed at right angles to the body and the constrictor rubber band, *D*, stretched and clamped about the arm to bring out the veins. The Fordyce needle is next inserted into the vein. The blood will ooze freely from the needle if it is in the vein until the rubber constrictor is removed, which by the way is done at this time. I now allow the salt solution to run through the hose (be sure to have the glass connection *B* connected to the hose) for in that way all the air is quickly removed from the hose.

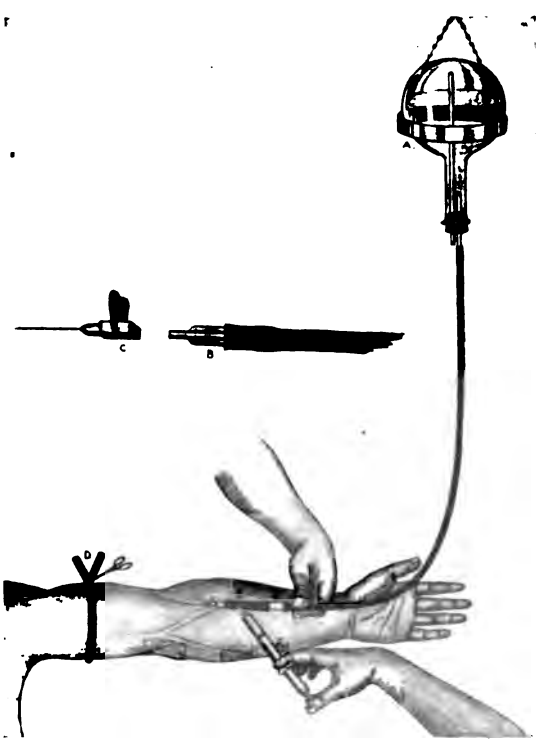

Author's apparatus showing method of administering salvarsan or antitoxin in combination with normal salt solution.

[1] The rubber cork and hoses should be of the acid cured variety.

When all the air is out of the hose, let a little of the salt solution run into a medicine glass and test it (by an ordinary fever thermometer), to see if it tests 100° F. If it does, connect the ground end of tube, *B*, to the Fordyce needle, *C*, and allow the salt solution to run into the vein.

I use the short hose marked *E*, as a sort of outside vein into which I jab the needle of my antitoxin (or salvarsan) syringe marked *F*. By gentle pressure the contents of the syringe is now allowed to flow into the hose to mix with the warm salt solution. If too much pressure is used the solution from the syringe, *F*, immediately backs up and shows in the glass tube, *G*, which acts as an indicator and assures a perfect mixture and flow.

It might be of some interest to mention that I started to use this apparatus in injecting physiological sea-salt solutions with salvarsan in some cases of syphillis of the liver which resisted all forms of antisyphilitic treatment. But, I now like this apparatus so well that I use it in all cases of intravenous injection of salt solution and combinations of the solution.

A NEW FORCEPS FOR THE CONTROL OF HÆMORRHAGE AFTER THE REMOVAL OF TONSILS

By WILLIAM A. GROSS, M.D., Chicago

THE common method of controlling hæmorrhage in surgery is that of applying an artery forceps and ligature wherever possible or practical. This procedure of hæmostasis may also apply to throat surgery. However, more or less difficulty has been experienced in the past in applying forceps and ligature in such cases owing to the inaccessibility of the field of operation.

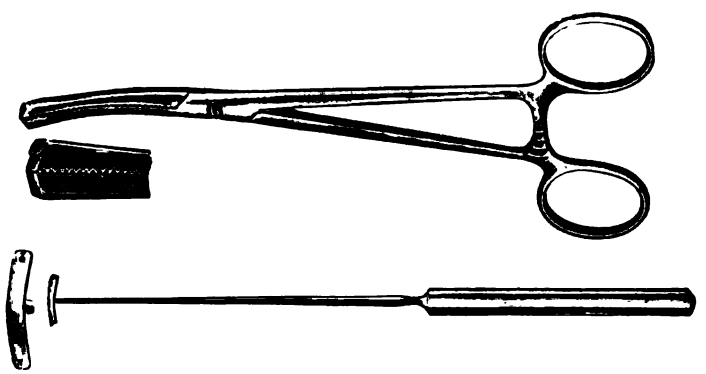

The object of the forceps illustrated is to simplify this procedure in surgery of the throat and other operative fields, where difficulty is experienced in applying the ordinary hæmostat. The special hæmostat has a groove at the end of one of the jaws in which a piece of No. 1 catgut is inserted. After sponging the cavity, the hæmostat with the ligature in position is applied to the bleeding point. One end of the ligature is swung around the forceps and a double knot is tied which is then pushed down as far as possible, whereupon the "tying instrument" is placed in position. After placing both ends of the ligature into the slots of the "tyer," the free ligature-ends are held in one hand while pushing, with a seesaw motion, firmly down with the other hand until the knot is firm. Then the "tyer" is released and, with the forceps remaining in position, the second knot, which has been made with a single twist, is pushed down into position with considerable pressure. After completing the knot the "tyer" is removed and the free ends of the ligature are cut off with a pair of scissors, and the forceps may be removed.

The hæmostat is so designed that the knot will slip easily over the ends of the instrument, which obviates the difficulty heretofore found in applying the ordinary artery forceps in a cavity, such as is left after removing a tonsil.

ANTHRAX

Report of a Case

By LOUIS J. PRITZKER, M.D., Chicago
Captain, M.C., U. S. A.; Chief of the Surgical Service, U. S. General Hospital No. 29, Fort Snelling, Minnesota

BECAUSE of certain unusual features, the following case is reported at the suggestion of the Commanding Officer, Major A. Schuyler Clark, M.C.

Private W. I. T., Infantry, was admitted to the Surgical Service, on August 19, 1918, having been transferred thereto from the Medical Service with the diagnosis of anthrax.

On admission the following history was obtained: Onset of illness June 23, 1918, when patient noticed a small pimple at about one inch below the angle of his right jaw. The morning following the right side of his neck became considerably swollen and stiff, felt as if it were paralyzed and produced a choking sensation, though it was not very painful. At that time too the pimple was "discharging a little" and the patient felt generally uncomfortable, very feverish and chilly, but not weak.

About a month ago the patient visited a shed, containing straw that had been lying around for some time and was damp. He gathered some of this straw, stuffed a tick with it and used it as a bed up to within about two weeks of the onset of symptoms. This was absolutely all the information that could be obtained, on very careful and painstaking questioning of the patient, as regards his coming directly or indirectly in contact with horses, cattle or sheep.

On June 27, 1918, he became very sick, was taken off of a transport train, on which he was a passenger, brought to this hospital and admitted to the Medical Service. On that day his condition, as described in the records, was as follows: "Man came in very ill, with marked swelling of right side of neck and jaw, with a large pustule beneath the angle of the jaw. Appearance raised, elevated border with depressed center, looking dark and gangrenous. Swelling extended downward over upper part of sternum. Very painful, red, and resembling erysipelas. Marked adenitis, patient unable to move head." Temperature 103.2°, pulse 102, respirations 24. In the afternoon of the same day his temperature rose to 104°, pulse 102, respirations 36. The same afternoon a blood examination by Lieut. W. J. Carson, M.C., showed white corpuscles 20,000, hæmoglobin 90 per cent, small mononuclears 8, large mononuclears 2, transitionals 1, polymorphonuclears 88, and eosinophiles 1. *Blood smear showed positive for anthrax.* Throat swabbing showed the prevailing organism to be the bacillus anthracis. Swabbing from the nose was negative for anthrax but showed staphylococci. Urinalysis negative.

The treatment consisted principally of the injection of ten (10) drops of a 10 per cent solution of carbolic acid in glycerine for five successive doses at four-hour intervals. The first dose was given intravenously, the subsequent ones intramuscularly. In the morning of June 28, the temperature dropped to 102°, pulse 102 and in the afternoon of the same day there was a further drop of temperature to 99.2°, pulse 95. Thereafter the temperature, pulse, and respirations varied between 96 and 98.6, 54 and 88, and 14 and 24 respectively until the termination of the illness.

On August 19, 1918 (the day of transfer of the patient to the Surgical Service) his condition was found to be as follows: temperature 97°; pulse 68; right sternocleidomastoid and pectoralis major muscles indurated causing limited motion of the head; œdema and swelling, about the size of a hen's egg, over right sternoclavicular articulation; no open wounds but a scar, about one inch below and slightly external to the right angle of the jaw.

A specimen of blood, obtained from the patient, was sent to the laboratory for examination and a large hot boric acid dressing applied over the swelling. On August 22, 1918, the laboratory report by Sgt. 1st Class, D. Cross, M.C. read as follows: red corpuscles 5,000,000, white corpuscles 8,400, blood culture positive for anthrax. On August 27, a saline solution of this culture was injected intravenously into a rabbit. Results and post mortem findings appended herewith. On September 6, 1918, another specimen of blood from the patient was studied by Lieutenant D. B. Roach, M.C.; in this instance too the report of positive cultural findings for anthrax was returned. A specimen of this latter culture was injected intraperitoneally into a guinea pig and the results of this is also appended herewith.

The treatment of the patient at this time was principally supportive plus the local daily application of large hot boric acid dressings which applications were later changed to the following:

Rx	Grams
Extracti belladonnae	4
Plumbi iodidi	4
Lanolini q. s. ad	30

The patient kept steadily improving and by the middle of September there was no longer a vestige left of the swelling or any of the symptoms. Repeated examinations of blood, throat, and nose cultures and fæcal analysis and urinalyses all showed negative results.

The unusual features in this case are (1) the extraordinary long period of incubation (if the history is to be relied on); (2) the persistance of the bacillus anthracis in the blood from practically the first day of the illness up to almost the time of complete recovery, and (3) the demonstrability of the bacillus in the blood.

With reference to the latter we find the following in literature: Osler (1): "It is to be remembered that the blood may not show the bacilli in numbers until shortly before death." Simon (2): "Adequate data from which a blood picture of anthrax could be constructed are wanting. In infections of some of the lower animals the corresponding organism may be demonstrated in the blood in large numbers. In man this is apparently possible only in exceptional instances, late in the disease, when general

septicæmia has developed, and even then not in all cases." Hiss and Zinsser (3): "Although the bacilli are not demonstrable in the blood until just before death, they nevertheless invade the blood and lymph streams immediately after inoculation and are conveyed by these to all the organs."

LABORATORY INVESTIGATIONS

By Lieutenant W. S. Carson. A blood count made June 27, showed white corpuscles 20,000; red corpuscles not recorded; eosinophiles 1; polymorphonuclears 88; large mononuclears 2; small mononuclears 8; transitionals 1; hæmoglobin 90 per cent. Blood smear and throat culture were positive for anthrax. Nose culture negative for anthrax, positive for staphylococcus. Urinalysis on June 27, June 28, July 3 and July 6 negative.

By Sergeant Cross. A blood count taken August 22 showed red corpuscles 5,000,000; white 8,400. Five cubic centimeters of this blood was cultured in 150 cubic centimeters of dextrose beef broth, and incubated for 24 hours at 37° C; this resulted in the formation of a white pellicle. Examination of the broth showed pure culture of gram positive bacilli. Transplanted to agar and incubated for 24 hours at 37° C. showed anthrax in filaments of from 2 to 20 elements; many of the organisms containing endospores. Incubated again for 48 hours and most of the vegetative forms changed to spore forms. The agar plates showed the characteristic anthrax-like colonies. On August 27, one and one-half cubic centimeters of saline agar slant suspension was injected intravenously into a rabbit. The animal died in 15 days after an illness of 3 days.

By Lieutenant Roach and Sergeant Cross. Autopsy examination of rabbit on September 11 showed the peritoneum to be congested and peritoneal cavity containing large quantity of clear fluid. The liver was enlarged and very much congested, as was the spleen. Cultures from various organs and heart's blood showed pure culture of anthrax. September 6, another specimen of blood from patient was studied in broth, agar slants, and plates showing a pure culture of bacillus anthracis. This culture was injected intraperitoneally into a guinea pig. The pig developed symptoms in two hours and died in 8 hours. Autopsy showed the tract along path of inoculation inflamed, the peritoneum congested and containing large quantities of exudate. The spleen was enlarged and congested. Cultures from organs and exudate studied in broth and agar smears showed pure culture of bacillus anthracis.

REFERENCES

1. Osler, Sir William. The Principles and Practice of Medicine. 1912, 8th ed., p. 149.
2. Simon, Charles E. Manual of Clinical Diagnosis. 1918, 9th ed., pp. 584 and 585.
3. Hiss and Zinsser. A Textbook of Bacteriology. 1918, 4th ed., p. 571.

PERITONEAL DRAINAGE

By C. L. HEALD, M.D., F.A.C.S., Cedar Rapids, Iowa

THE impossibility of continuous drainage of the peritoneal cavity has been proved conclusively by animal experimentation. Within a few hours, probably less than 24, adhesions completely isolate the drain tract. Any drainage after that is from the drain tract alone. Yet clinical experience has proved the necessity of some form of drainage in the presence of pyogenic peritoneal infection. Since all drainage from the peritoneal cavity ceases after 24 hours, whatever benefit it brings must be secured during that brief period.

Tube drainage of the abdominal cavity is against gravity and depends upon the overflow. Dependent drainage can only occasionally be employed. "Mikulitz long ago was convinced of the physical and pathological impossibility of ideal tube drainage." (Yates.)

Gauze as a drain depends upon capillarity, and, as soon as it becomes saturated, ceases to drain, becoming an obstruction to drainage.

Free pus in the peritoneal cavity may be removed by exposure and sponging, or by irrigation; but both these procedures may be attended with grave danger, and, in many cases, it is safer not to attempt to remove the pus at the operation, but to rely upon rapid, efficient drainage. To such cases Murphy referred in his dictum: "Get in quick; get out quicker."

Ideal peritoneal drainage should remove the pus from the bottom of the cavity with the minimum of injury to the patient.

The double caliber glass tube with movable gauze wick, as shown in the accompanying illustration, comes nearer meeting these requirements than any method I have used. The double tube is one-half inch in (outside) diameter. The lower end is closed except for an oval opening one-eighth inch in its long diameter, one-fourth inch from the lower end on each side, and a small opening in the bottom. The longitudinal septum extends to one-fourth inch from the lower end.

One end of a gauze wick, one inch wide and several yards long, is inserted in the upper end of one "barrel," and is pushed down its lumen to the lower end with a small probe, pulled out of

the opening in the bottom, the end reinserted through this opening and pushed up through the other "barrel," passing around the smooth lower end of the septum.

The tube, threaded with the wick, is inserted to the bottom of the cavity and the wound is closed completely around it. The tube should be long enough to project above the dressings, which are covered and protected by a sheet of rubber dam, through a small stretched opening in which the tube has been previously passed. The roll of sterile gauze wick in a cloth bag is pinned outside the dressings and covered with a sterile towel.

During the first 24 hours, at more or less frequent intervals, depending upon the quantity of purulent secretion, the nurse, with sterile-gloved hands, steadies the tube with one hand, pulls the wick through with the other until it comes through dry, cuts off and removes the soiled portion, and replaces the sterile towel, without having disturbed the patient. After 24 hours, the tube, having served its purpose, is removed, and replaced by a small "cigaret," or by any form of drain the surgeon may prefer.

The method may be used in the drainage of any cavity where dependent drainage is impracticable, but in peritoneal infections from perforations, it will probably be found most useful.

With this method of drainage it is not necessary to leave a large portion of the wound open, as is often advisable with the usual methods, resulting so frequently in postoperative hernia.

It has the advantage of gauze drainage without its disadvantages.

It is similar in its effects, yet superior, to dependent drainage, in that the tube will not, with proper attention, become obstructed.

It drains the bottom of the cavity, while, with the usual methods, overflow drainage only is obtained.

Finally, by this method, the maximum drainage is secured during the few hours when drainage of the peritoneal cavity is possible.

TRANSFUSION APPARATUS

By R. E. FARR, M.D., F.A.C.S., and EARL W. GILROY, M.D., Minneapolis, Minnesota
From the Clinic of R. E. Farr, Farr Pavilion, St. Barnabas Hospital

THE efficacy of the citrate method of transfusion seems to have been established. This method has made the operation comparatively simple. In order further to simplify the technique we have made use of some of the well-known laboratory methods, adapting them to this new field. This method of withdrawal of the donor's blood has been used by many men for various purposes, but the application of the second part of the procedure we think has not been described.

The apparatus consists of a liter Erlemeyer flask arranged in the same fashion as an ordinary laboratory wash bottle (Fig. 1) with a long glass tube extending from the bottom of the flask through a rubber cork and outward, having a bend of 45 degrees on the outside, *A*. One other

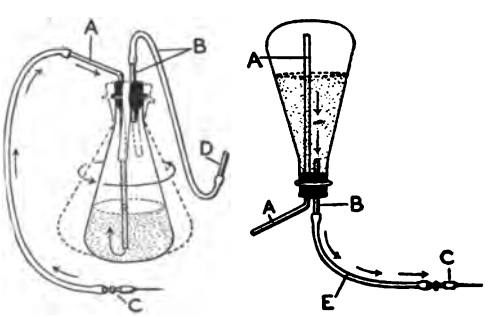

Fig. 1.

Fig. 2.

Fig. 3.

short tube, *B*, extends into the bottle about one-half inch and about one and one-half inches on the outside. Tube *A* is connected with a rubber tube and at the distal end of the rubber tube there is an adapter, *C*, to fit either a Luer or record needle. Tube *B* is plugged loosely with sterile cotton and is connected with a long rubber tube, at the distal end of which there is a glass tube, *D*. The glass tube is likewise plugged with cotton and is used as a mouthpiece for the operator from which point by means of suction he is able to create a negative pressure in the bottle.

In the preparation of the patient the usual technique is followed as to the application of the constrictor, sterilization, etc. Citrate solution in sufficient quantity to make a 0.2 per cent solution of the citrated blood may be introduced into the bottle before the cork is inserted or this may be done fractionally by suction after removing the adapter and placing it in citrate solution.

We usually hold the cork in place by means of adhesive tape so that the second stage of the procedure (Fig. 2) may be performed without danger of the cork coming out at the time the bottle is inverted. With the mouthpiece in the operator's mouth, the needle, directed peripherally, is inserted into the vein of the donor and by suction negative pressure is produced in the bottle. The blood then runs through tube *A* to the bottom of the flask which is continually agitated, and the blood is at once intimately mixed with the citrate solution. If at any time the vacuum created is too great, it may induce a valvelike action at the tip of the needle, the wall of the vein closing over the orifice. In such an event the adapter is simply loosened from the needle and normal tension is restored. By this same means tube *A* may be evacuated of blood at any time and thus the possibility of the blood stagnating and clotting in the tube is eliminated.

Having completed the operation of withdrawal of the blood, which operation is almost as simple as taking blood for a Wassermann, the bottle is inverted (Fig. 3), the long tube *A* becomes the air intake, the short tube *B* becomes the tube of exit which tube is connected with another long rubber tube *E* in the same fashion as in the administration of saline by the gravity method.

The whole apparatus, including a bottle of sodium citrate (grams 2) with needles No. 16 may be autoclaved and wrapped so that the operation can be accomplished with but little preparation and with no delay. The application of these simple laboratory methods minimizes the possibility of contamination and makes for efficiency and simplicity of operation.

SUGGESTED STEP IN THE TECHNIQUE OF INGUINAL HERNIOTOMY

By MARSH PITZMAN, M.D., St. Louis
Lieutenant, Medical Corps, U. S. A.

THE very multitude of the modifications in the technique of inguinal herniotomy today in widespread use opens the question as to whether, after all, we have really gotten to the root of the matter. The essence of the Bassini suggestion, that is opening the inguinal canal freely to facilitate removal of the sac and to yield a better opportunity for the repair of the musculo-aponeurotico-fascial layers, was unquestionably a revolutionary step in the right direction. Bassini deserves lasting credit for directing the attention of surgeons to the importance of the repair of the abdominal (internal) ring in contradistinction to the previous emphasis on the subcutaneous (external) ring. My personal suggestion is simply a new technique for the surer and better closing of the abdominal ring, together with the reasons for my step.

All modern herniotomy techniques split the aponeurosis of the external oblique muscle in the direction of its main bundles throughout the length of the inguinal canal. And further, all techniques remove, or otherwise destroy, at least the inguinal portion of the hernial sac. But, beyond this point, all is babel. Thus, for example, we have the Bassini operation, with and without transplantation of the cord (incidentally differences of opinion as to what constitutes transplantation), and the radically variant Ferguson-Andrews technique, together with the innumerable minor variations as regards steps and suture material of individual operators. Enough has been said to show that inguinal herniotomy is still far from a standardized operation and that surgeons, as a class, are as yet not satisfied with their technique and results.

In order to simplify our problem, and to keep in touch with the spirit of the day, let us confine our discussion to the typical hernia of vigorous adult life, that is, the indirect inguinal hernia. For among potential soldiers the direct type, that is actually descending medially (internally) to the deep epigastric artery, is comparatively a negligible factor. Here we have ideal conditions, that is vigorous, otherwise sound men, and hernias of small or average size. And yet, without going into statistics, most of us, I am sure, will admit that the eventual failures of the average surgeon, even in this selected class of cases, are considerable, while the most competent surgeons report many disconcerting and somewhat unexplained recurrences. Many recurrences due to obvious causes, such for example as infections, chronic cough and too early return to heavy physical strain, should, in fairness, be eliminated from the failures. But, after eliminating this group, a variable percentage of failures remain, many of which I, personally, attribute to a faulty technique in the closure of the abdominal inguinal ring.

As true hernias never exist without peritoneal sacs, and, as such open sacs always allow the escape of intestines on the slightest increase in intra-abdominal pressure, nobody doubts the interdependent relationships of hernias and their sacs. But peculiarly in regard to inguinal hernia, at least, the argument has been generally accepted that the open sac caused the hernia to the practical exclusion of the other equally possible alternative that the hernia caused the sac. The pendulum, however, has begun to swing the other way, as even a superficial comparison of the run of modern texts and literature with the older will demonstrate. If this is really another case of the confusion of cause and effect, as many of us now feel, the wideness of the acceptance of the older argument will prove an interesting subject for the psychologist and the medical historian. The gist of the newer argument is that hernia is caused by greater intra-abdominal pressure than the particular wall can withstand; that under such circumstances a hernia forces its way out through the musculo-aponeurotico-fascial layers of the abdominal wall; and that the hernia causes the sac in absolute contradistinction to the older opinion that the sac caused the hernia. As I have recently briefed this argument in some detail elsewhere,[1] I will simply state here that the past year has not caused me to wish to add or substract one iota from that discussion.

The discussion of whether the sac causes the hernia, or, as many of us now believe, the hernia causes the sac, might, at first glance, seem far afield from our subject of operative technique. And yet this question of theory is the foundation on which my step in technique rests. So far as I can find out the universal custom of resecting the sac and closing off the peritoneal cavity before proceeding to the repair of the musculo-

[1] The cause and prevention of hernia. J. Am. M. Ass., lxix, 776-777.

aponeurotico-fascial layers of the abdominal wall rests on the older conception of the sac causing the hernia. My suggestion in technique is simply to insert the mattress sutures for the repair of the abdominal wall, while the peritoneal cavity is still open. With the finger introduced through the abdominal ring, the strength and character of the tissues forming this ring can be accurately determined and the sutures carried through all the layers of the abdominal wall at appropriate points. Careful surgeons are justly afraid of sinking their needles deeply into these layers from the outside inwardly, but with a finger inside the abdominal cavity, no excuse seems to me pardonable for failure to get a good firm grip on all the tissues forming this ring, that is the internal oblique muscle and aponeurosis, the transversus (transversalis) muscle and aponeurosis, and the transversus fascia. On account of fear in regard to this comparatively blind step, many otherwise competent surgeons skimp the stitch until, as a matter of practice, they have grasped little more than the superficial muscular fibers of the internal oblique muscle. And, in view of the danger of intestinal adhesions, or bladder attachment in the neighborhood of the abdominal ring, only a very brave, or perhaps foolhardy man would attempt as deep a grasp on the tissue as he could safely accomplish from within outwardly. As far as the sac is concerned, I always resect at least the inguinal portion of a thickened sac, while the thin ones can be either resected or inverted as per routine techniques. But I lay so much stress on the repair of the abdominal wall, and so little on the sac, that I seriously doubt whether it is necessary to pay any further attention to it, once the abdominal cavity has been opened.

This really completes my suggestion, but here, just for good measure, are a few personal opinions in regard to minor points in technique. A full curved round needle is much to be preferred to any cutting-edge needle or instrument, as it minimizes the danger of injury to the deep epigastric artery and vein. Incidentally, the term "epigastric" is a misnomer,[1] as, according to the rules of anatomical nomenclature, it should be known as the hypogastric artery (of the abdominal wall).

As regards suture materials, I feel that No. 2 twenty-day catgut will hold the tissues in apposition for a sufficient length of time to insure proper union, provided the knot is tied firmly three times and the free ends are left at least one-quarter of an inch long. If the operation is not properly performed, no non-absorbable suture material will improve the result, while the disadvantages of non-absorbable sutures are too well known to call for comment. From a theoretical point of view, I feel that a superficial scarification of the opposed white fibrous tissues would increase the certainty of early and proper union, but have absolutely no basis except theory for this opinion. In order to obtain a clean and bloodless exposure of the required anatomical parts, I make free use of the well known gauze dissection. As aseptic wound healing should be fairly firm at the end of two weeks, I have allowed some of my patients to get up at the end of two weeks and some even at ten days, with, so far as I could determine, no deleterious effect on the six month result. For the usual indirect inguinal hernia I have long felt that the technique, which most nearly reproduced the normal anatomical relations of the spermatic cord, is much to be preferred to the other proposed techniques. On theoretical grounds, at any rate, I object to any technique which brings the spermatic cord straight out through the abdominal wall, and prefer the technique which brings the cord out on its normal valve slant. In other words, I make use of that Bassini technique which brings the musculo-aponeurotico-fascial layers down to the inguinal ligament of Poupart, deep to the spermatic cord. Finally the cut edges of the external oblique are simply sewn together superficially to the cord. And further, I insist that this is the normal relation of the parts, and is a herniotomy without transplantation of the cord.

In regard to practical results, as any individual operator's personal experience in so big a field could be only as a drop of water compared to an ocean, I will simply state that my early results have been excellent throughout. As I, myself, have only used this step during the past year, and, as hernia results should, in fairness, be checked up after the lapse of three to five years, I lay absolutely no stress on this report of personal results. My excuse for publishing the report is based on my opinion that, in the army, this question is an emergency problem of some importance.

CONCLUSIONS

1. All types of hernia are caused by greater intra-abdominal pressure than the particular wall can withstand.

2. The newer point of view, that the hernia causes the sac, in contradistinction to the sac causing the hernia, deserves serious consideration.

[1] Some suggested changes in anatomical nomenclature. Anat. Record, xiii, No. 3, 165-168.

3. Greater operative emphasis should be placed on the repair of the musculo-aponeurotico-fascial layers of the abdominal wall.

4. My suggestion in technique is that the sutures for the repair of the wall should be placed before the peritoneal cavity is closed.

CORRESPONDENCE

ARTIFICIAL SYNOVIAL FLUID

To the Editor: In June, 1911, I published in SURGERY, GYNECOLOGY AND OBSTETRICS, an account of artificial synovial fluid, a subject which always interested my classes at the school. It would seem to require more or less attention now at the hospitals which are caring for soldiers with joint injuries. The fluid consists in an eight ounce mixture of:

	Ounces
Boroglyceride	1
Glycerine	3
Normal saline solution	4

After the breaking up of adhesions and in cases of chronic inflammation of fibrous structures this fluid injected into a joint acts mechanically in two ways.

1. As a hygroscopic fluid of physical consistency somewhat resembling synovial fluid, it furnishes a benign lubricant which remains in place for days or weeks, furnishing an obstacle to re-adhesion of joint surfaces.

2. As a hygroscopic fluid it has a tendency to unload interstitial infiltrates from the fibrous tissues about a joint, when these are congested as a result of chronic inflammation.

ROBERT T. MORRIS, F.A.C.S.

New York.

BOOKS RECEIVED

Books received are acknowledged in this department and such acknowledgment must be regarded as a sufficient return for the courtesy of the sender. Selections will be made for review in the interests of our readers and as space permits.

SURGERY AT A CASUALTY CLEARING STATION. By Cuthbert Wallace, C.M.G., F.R.C.S., and John Fraser, M.C., F.R.C.S. (E.). New York: The Macmillan Company, 1918.

PROTHÈSE ET CHIRURGIE CRANIO-MAXILLO-FACIALE. By J. Lebedinsky and M. Virenque. Preface by M. le Dr. H. Delagenière. Paris: J. B. Baillière and Sons, 1918.

TRANSACTIONS OF THE AMERICAN GYNECOLOGICAL SOCIETY. Vol. xliii, 1918.

WAR SURGERY FROM FIRING LINE TO BASE. By Basil Hughes, D.S.O., M.A., M.B., B.C. (Cantab.), B.Sc. (Lond.), F.R.C.S., Temporary Major R.A.M.C., T.F.; and H. Stanley Banks, M.A., M.B., Ch. B. (Glasg.) Captain, R.A.M.C., T.C. New York: William Wood & Company, 1919.

SURGERY IN WAR. By Alfred J. Hull, F.R.C.S. With preface by Lieut. Gen. T. H. J. C. Goodwin, C.B., C.M.G., D.S.O., Director General Army Medical Service. 2d ed. Philadelphia: P. Blakiston's Son & Co., 1919.

THE DISABLED SOLDIER. By Douglas C. McMurtrie. Introduction by Jeremiah Milbauk. New York: The Macmillan Company, 1919.

BOOK REVIEWS

A CRITIQUE OF NEW BOOKS ON OBSTETRICS AND GYNECOLOGY

By GEORGE GELLHORN, M.D., F.A.C.S., St. Louis

THE war may have reduced the quantity, but happily, it has not affected the quality of gynecologic literature. Witness in proof thereof, the row of books on the reviewer's desk.

Lockyer, of London, heads the list. This author, long known to us by his contributions on gynecologic pathology, has more recently become prominent as a writer of books. Within less than two years he has published, jointly with Eden, a *Textbook of Gynecology for Students;* he has edited, again with Eden, a *System of Gynecology* in three volumes; and now he has written a book of his own. In times of peace and under the most favorable circumstances, this would be testimony to an exceptional assiduity — under the stress of war it is an exceptional achievement. In this latest work,[1] Lockyer presents to us a monograph of imposing size on uterine fibroids. The book is divided into three parts which deal with myoma, adenomyoma, and operations for myoma respectively, and contains a full account of the pathology, clinical features, and treatment of these tumors. Extensive practical experience and museum collections of unusual size and variety enable the author to contribute to any phase of the subject from his own knowledge and to introduce the results of his personal investigations and scientific researches. Yet, the literature of the world is fully considered and we meet, for instance, with repeated references to the work of Kelly and Cullen. Of Continental writers, German and French authorities are frequently quoted. Beautiful color plates and a multitude of half-tones illustrate both the histologic and the gross aspect of the various forms of fibroids and visualize the steps of the operation described.

A work of such magnitude cannot possibly be reviewed adequately within a limited space, but the few selections appended will serve to whet the appetite of the prospective reader. While the causation of fibroids is obscure and the question of their histogenesis must still be held in abeyance, Lockyer believes that ovarian activity is a determining factor in the development of myomata. The term myxoma should be discarded and the mucinoid change had best be regarded as the liquefactive stage of hyaline degeneration. In the controversy as to the etiology of necrotic fibroids, the author leans to the view that hæmolysis and not thrombosis is the predominant change. He denies any interrelation between fibroids and polypoid endometritis and assumes for the latter an infective origin. The coincidence of cancer and myoma in the uterus is of great clinical importance, but pathologically it cannot be said that one growth predisposes to the development of the other. Sarcomatous transformation, on the other hand, is a well established fact though existing statistics do not indicate the frequency of this occurrence. Submucous polypi in particular should be regarded with suspicion and never be removed without a thorough histologic examination. As to the question of the heart in cases of myoma, Lockyer rejects the possibility of specific myoma toxins inimical to the heart and refers the cardiac lesion back to anæmia. The effect of pregnancy on a myomatous tumor is very marked, but induction of labor or abortion should never be performed. Expectancy gives the best chances to mother and child.

This leads us to the subject of the treatment of fibroids, and here we find the same completeness of detail that may be assumed from the foregoing excerpts from the chapters on pathology. Both the operative and the non-surgical therapy are dealt with on a broad basis and with a fairness altogether refreshing. The diagnostic chapters are equally rounded out and contain not a few diagnostic signs which seem to have been permitted to lapse into oblivion. If the reviewer does not continue to quote from his notes, it is due to fear of the editor's blue pencil. Moreover, there is no need of going into further detail, for it must be evident by now that the treatise before us is one which is indispensable to any up-to-date gynecologist.

There is, to the reviewer's mind, yet another aspect from which this book appears momentous. We have fondly believed in the past that Medical Science was in truth international, that it knew no geographic bounds, that it stood serene and sublime above empires and republics, knowing no sovereignty but that of Humanity.

The war has shattered many such illusions and shown that men of science are first of all human beings. Now that the nightmare is ended and reconstruction is upon us, many bridges must be laid across the gaping chasm to unite once more mankind torn asunder; and this book of Lockyer's is just such a bridge for it encompasses all the

[1] Fibroids and Allied Tumors. By Cuthbert Lockyer, M.D., B.S., F.R.C.P., F.R.C.S. London and New York: The Macmillan Company, 1918.

wisdom of the world on a certain subject, and medical men of all tongues and all nations will have to turn to it for reference, again to study together, to work together, to serve together for the sake of Humanity.

A TEXTBOOK is a thing that is associated in one's mind with hard work on the part of the student. A chapter, or two perhaps, to obtain some desired information and then it is laid aside until another need arises. But here we have a book[1] that one does not put down after a chapter or two, but keeps on reading and finds in the end that it has not only been immensely instructive, but entertaining as well. We encounter the Freudian theory on the sex impulse and wonder why other authors have not thought to embody this important chapter in their textbooks. In the section on the relationship of gynecology to the internal secretions, we find the few definitely established facts hulled out of a maze of contradictory and confusing observations, the plausible theories clearly pointed out as a working basis, and the lines of further investigations plainly indicated; and everywhere we see the author's active collaboration on a subject that may yet revolutionize our entire conception of gynecology. There is further an interestingly written discourse on the relations of gynecology to all the other organs and systems of the body which correlates our special field of work to the other branches of medical science and emphasizes the point that gynecology can no longer be regarded as an offshoot of either surgery or of obstetrics. And so this first part of the book is, in reality, a treatise on general gynecology and would be a distinct gain to literature even were the work to end here.

But there are two more parts. In the second part, gynecologic diseases are treated at length. The undergraduate student will find this part particularly attractive. Both the microscopic and macroscopic illustrations, the latter from the author's hand, show a high degree of perfection and serve, in conjunction with the precision of the text, as a true guide into the theory and practice of gynecology.

In the third part which deals exclusively with operative gynecology, text and illustrations vie with one another in a clear and helpful presentation of our surgical procedures.

We have welcomed the first appearance of the work with warm recommendation, and this second edition deserves even higher praise.

A BOOK which appears in its eighth edition, *per se* relieves a reviewer of his responsibility. The eight editions speak too loud and eloquent a language to require more than a simple announcement. But in this case[2] the reviewer cannot refrain from pointing out that the author personifies in himself that happy union of the sister sciences of obstetrics and gynecology, from which alone progress and a perfect understanding of all reciprocal problems can come. Hirst is one of the few authorities who have written textbooks both of obstetrics and gynecology.

In the present volume his long experience as a teacher has helped him to recognize and omit material unessential to the medical student and general practitioner. Thus, while all real advances in obstetrics are embodied in the work, the size of the book is smaller than that of former editions. In the galaxy of American textbooks of obstetrics, this one occupies an honored place.

THE second edition of Shears' *Obstetrics*[3] has preserved the excellent qualities of the first edition. Originality of conception, vividness of description, and proper valuation of practical needs are the dominating features of the work and warrant the prospect of a long and successful career. Unfortunately, certain technical imperfections were likewise preserved which, in the first edition, could be overlooked as due to hasty proofreading. In this second "revised" edition, they should have been eliminated. Such shortcomings, however, should not be permitted to mar the intrinsic value of the book.

CROSSEN'S textbook[4] proves its popularity by a fourth edition. In the absence of the author in France, Dr. Hugo Ehrenfest has attended to the revision. He has succeeded in bringing the book up to date by deft touches, adding valuable facts which have come to light since the last edition, and eliminating doubtful or unessential matter. He has also written a chapter on the relationship of the endocrine glands to the female genitals in which this complicated subject is set forth in systematic and succinct manner. The book will be a staunch friend to students and general practitioners.

THE last book[5] to be reviewed is inferior to its precursors only in size. In its subject matter it takes front rank in the reviewer's opinion and should receive the careful and appreciative attention of teachers on obstetrics. "These talks," says the author "are merely printed chats similar to those often held with students during the hours of waiting while on out-patient cases." The more common complications met with in obstetric practice are set forth in thirteen short chapters, and the conversational style preserved throughout makes the reader forget that he is absorbing a great deal of practical experience and sound judgment. The book is small enough to be slipped into one's pocket and is, in truth, a genuine *vade mecum*, a constant companion in the work of the obstetrician.

[1] GYNECOLOGY. By William Graves, A.B., M.D., F.A.C.S. 2d ed. Philadelphia and London: W. B. Saunders Company, 1918.

[2] A TEXT BOOK OF OBSTETRICS. By Barton Cooke Hirst, A.B., M.D., LL.D., F.A.C.S. 8th ed. Philadelphia and London: W. B. Saunders Company, 1918.

[3] OBSTETRICS, NORMAL AND OPERATIVE. By George Peaslee Shears, B.S., M.D., and E. E. Shears, M.D. 2d ed. revised. Philadelphia and London: J. B. Lippincott Company, 1917.

[4] DISEASES OF WOMEN. By Harry Sturgeon Crossen, M.D., F.A.C.S. 4th ed. St. Louis: C. V. Mosby Company, 1917.

[5] TALKS ON OBSTETRICS. By Rae Thornton La Vake, M.D. St. Louis: C. V. Mosby Company, 1917.

AMERICAN COLLEGE OF SURGEONS

CASE RECORDS AGAIN

HOSPITAL standardization, according to the American College of Surgeons, is a poor phrase to describe a good purpose. The purpose is to improve the service which sick people receive in hospitals. In its program the College has centered its aim. In effect the College says, "There are many, many things to be done by the medical profession and by hospitals in the way of better care for sick people. But let us not try to do all of them at once. Let us, first, turn our attention to the most imperative needs of a good hospital; to the needs about which there is no debate and without which no hospital may claim the approval of its community. These needs are, first, case records; second, clinical laboratories; and third, staff organization.

The College has recently published two bulletins on the subject of case records, some account of which was given in the last issue of the JOURNAL. The bulletins met with heartiest response from the medical profession, from the hospital administrators, and from the public. An occasional misconception, however, arises with regard to the records. How "complete" must a record be in order to be adequate? is a usual question. Again, how much laboratory work must be done in each case?

The answers to these questions obviously lie in sound medical training. A case record is not an ornament and quite as definitely a case record does not normally include laboratory work unless such work was actually needed or deemed advisable in the diagnosis or treatment of the particular case. For instance, it would not be expected that a Widal should be taken in a fracture case, nor would a Wassermann be expected in an obvious appendicitis, but it would be regarded as highly neglectful and an evidence of slipshod work if an obscure bone disease were permitted to proceed to operation without a Wassermann having been made.

In other words, the clinical record ought to show everything that was done in each case; and what was done in the case ought to include every reasonable effort to ascertain exactly what was the matter with the patient. The doing and recording of unnecessary laboratory work in a case are not only a cause of unnecessary expense, but are also evidence of faulty medical or surgical practice.

But the chief difficulty in the way of adequate records today is not the laboratory phase just stated. It lies rather in the thorough study of the case, first, through a personal history and, second, through a physical examination. The confusion of these two parts of a case record is so usual that some emphasis is here given the subject.

PERSONAL HISTORY

The personal history is, in effect, the patient's story of himself in relation to his complaint. It is not a diagnosis; it need not be verbose or elaborate. But the personal history should include every point likely to be of interest in leading up to the illness for which the patient came to the hospital. It included his family history; any family traits that might have a bearing on his own condition as, for instance, nervous manifestations. Incidents or previous illnesses of the patient may have a marked bearing on the case under discussion. An early inflammatory rheumatism, for instance, contracted during childhood might have a marked effect in accounting for a heart condition. A ptomaine of years ago might easily have something to do with a disturbed stomach function at the present time.

The patient should be catechised carefully as to the beginnings of his present illness; the symptoms, their extent and durations.

The parts of the body should then be discussed with the patient from his standpoint; he should be required to think about himself with the mind focused on one question at a time. It is not sufficient that the patient be asked whether or not he has had any previous illnesses. Has the patient ever had headache? If so, what was its character? Have his ears ever troubled him? Or his, eyes or nose, or mouth, or throat? Oftentimes a patient will entirely forget something that may be most important on which his memory is checked by reference to that particular thing.

It is not sufficient that the patient be asked whether he has ever had heart disease, or anything the matter with his heart; he must be quizzed about shortness of breath, palpitation, vertigo, swelling of the feet, puffiness of the eyelids. Then the physician can determine whether these incidents point to previous heart trouble.

The same detailed examination must go through every part of the body; the chest, the abdomen, the extremities, and the genito-urinary system.

Too often the personal history sheets are merely marked "negative," and give evidence, not that the examiner has made inquiry in these different directions, but that he has assumed that they had no bearing on the case.

THE PHYSICAL EXAMINATION

The physical examination is what the doctor finds on examination. It is not the patient's story. It is a statement of actual objective facts and this examination taken in conjunction with the personal history make up the basis of the diagnosis.

The clinician is now assumed to know what the patient has had to say about himself and the time is at hand when the patient's story is checked up by an actual examination. The obscurity or simplicity of a case will determine in the main, the extent of the physical examination. The point at issue is the diagnosis and if this can be made by going direct to some indicated part of the body or to some group of symptoms and can be so plainly determined as to leave practically no ground open for debate, then it would seem that this direct course is permissible. If the diagnosis is obscure every point should be thoroughly covered and studied. It is important to remember that whatever the illness of the patient, that illness bears a relation to the entire body and all significant fact in this connection should be recorded.

In the two bulletins (Vol. IV, Nos. 1 and 2) full detail is given as to the distinction between a personal history and a physical examination.

Some indication of the need that the medical profession give keen attention to physical examinations is clear in the following figures. In a group of 603 hospitals in the United States and Canada last year, 27.4 per cent of the patients received careful physical examinations. In this group some 1,546,000 were admitted to the care of the hospitals and later discharged without physical examinations.

CASE RECORDS FOR PRIVATE PATIENTS

It is considered settled that careful, accurate, and comprehensive case records should be kept on all ward patients in the hospital. There seems to be no argument about this. Hundreds of hospitals keep these records well. But many physicians and surgeons hesitate about keeping detailed records on their private patients, and this feeling has been responsible for much carelessness in record keeping. Under such circumstances the administration of the hospital naturally concludes that if the bars are down in one place they might just as well be down in other places.

Much serious thought is due on this subject of records for private patients. The problem is difficult. Many doctors feel that their relations with their private patients are confidential and that these cases are not to be talked about by outsiders. The result is that some of these doctors keep rather accurate records in their own offices and not in the hospitals, although the patients are cared for in hospitals. Other doctors keep no records at all of private patients. A woman, for example, has a miscarriage, or has several mishaps of the sort. Obviously the case is not one for outsiders to know about. A Wassermann has been made and the result is positive, which may account for the abortion. There may be a gonorrhœal history connected with the patient, or something in the story

that goes back to a syphilitic history. Very rightly these are things which are not to be talked about.

And, yet, should not a full record be kept? Does not the patient, himself or herself, frequently suffer because of the want of an adequate record? Suppose the doctor treats a private case and makes no record of it; and suppose that later he dies, or that the family moves away, or that for some other reason a new doctor is called into the case. Is not the patient entitled to have the experience gained by the first doctor available for use under the new conditions? The answer is undoubtedly yes. The data should be available to the patient, private or clinical.

What is to be done? Nearly all objections to the keeping of records for all patients disappear if the hospital records themselves are private and inviolable and not subject to review by any one who has not a definite right to know what the records contain. The answer is, of course, that hospital records are confidential data and should not be seen or known by any one excepting in the interest of the patient and on the patient's order or on the order of the doctor authorized by the patient. The protection of the records is a responsibility which the hospital owes to each doctor who practices in it.

ANNUAL SUBSCRIPTION: UNITED STATES AND CANADA, $10.00; FOREIGN, $12.00 (£2 10s.)

Volume XXVIII APRIL, 1919 Number 4

Surgery, Gynecology and Obstetrics

WITH

International Abstract of Surgery

EDITORIAL STAFF

FOR AMERICA

William J. Mayo, M.D.

E. Wyllys Andrews, M.D. J. Clarence Webster, M.D.

L. L. McArthur, M.D. E. C. Dudley, M.D. Frederic A. Besley, M.D.

A. J. Ochsner, M.D. C. S. Bacon, M.D. Carl Beck, M.D.

Thomas J. Watkins, M.D. John L. Porter, M.D. William R. Cubbins, M.D.

FOR THE BRITISH EMPIRE

Sir Arthur Mayo-Robson, C.B., C.V.O., D.Sc., F.R.C.S.

Sir Berkeley Moynihan, C.B., M.S., F.R.C.S. Thomas W. Eden, M.D., F.R.C.S.

Sir Harold J. Stiles, M.B., F.R.C.S. (Edin.) Henry Jellett, M.D., F.R.C.P.I.

James Rutherford Morison, M.B., F.R.C.S.

Franklin H. Martin, M.D., Managing Editor

Allen B. Kanavel, M.D., Associate Editor

EDITORIAL AND BUSINESS OFFICES: 30 N. Michigan Ave., Chicago, Illinois, U. S. A.

PUBLISHERS FOR GREAT BRITAIN: Bailliere, Tindall & Cox, 8 Henrietta St., Covent Garden, London, W. C., England

War Clinics

During 1919 we plan to introduce into the *Surgical Clinics of Chicago* many instructive Clinics from those surgeons who have been in actual contact with surgery in the field and at the Base Hospitals. They have much to tell that will be of untold value in reconstruction and rehabilitation work. In the first number, now ready, you get *six such clinics* (See page 13)—five war wound cases from Major Kellogg Speed, with the treatment used at the A. E. F. Evacuation Hospital; and another by Lieut.-Col. Frederic A. Besley on Secondary Hemorrhages.

SAUNDERS, *Publishers*



SEE PAGE 13

Entered as second-class matter May 22, 1913, at the postoffice at Chicago, Ill., under the Act of Congress, March 3, 1897.
Published monthly. Copyright, 1919, by The Surgical Publishing Company of Chicago.

USE
Paragon X-Ray Plates

They are FAST, CLEAN, BRILLIANT

And if you want to see the finest results your apparatus will produce

TRY THEM

THEY MAKE GOOD, as proven by the constant increase in repeat orders received.

IF YOU are not using them, some one else may make the diagnosis you failed on by not taking every opportunity to improve the standard of your work.

Hundreds are building reputations by their use. *Why Not Join Them?* We will help you with technical advice if needed.

If your dealer has no *fresh* Paragon plates in stock, write us, for quick shipment.

We Also Supply

Lower Priced X-Ray Plates
Barium Sulphate for Stomach Work
Dental X-Ray Films and Mounts
Developing Tanks—Soapstone or porcelain enameled, 1, 4 or 6 compartments
Developer Chemicals
Intensifying Screens
Filing Envelopes
Radiator or Regular Coolidge Tubes
X-Ray Protective Materials

Complete Price List and Discount Sheet on request. YOUR NAME should be on our mailing list for monthly X-Ray Bulletin.

PARAGON X-RAY PLATES

Geo. W. Brady & Co. 756 S. Western Avenue **Chicago**

SAVE TWO-THIRDS

Sherman's Bacterial Vaccines, when administered early, will reduce the average course of acute infections like Pneumonia, Broncho-pneumonia, Sepsis, Erysipelas, Mastoiditis, Rheumatic Fever, Colds, Bronchitis, etc., **to less than one-third their usual mortality and duration.**

Sherman's Bacterial Vaccines are prepared in our specially constructed Laboratories, devoted exclusively to the manufacture of these preparations and are marketed in standardized suspensions.

Write for literature.

MANUFACTURER OF BACTERIAL VACCINES

G. H. SHERMAN, M.D.
Detroit, Mich. U.S.A.

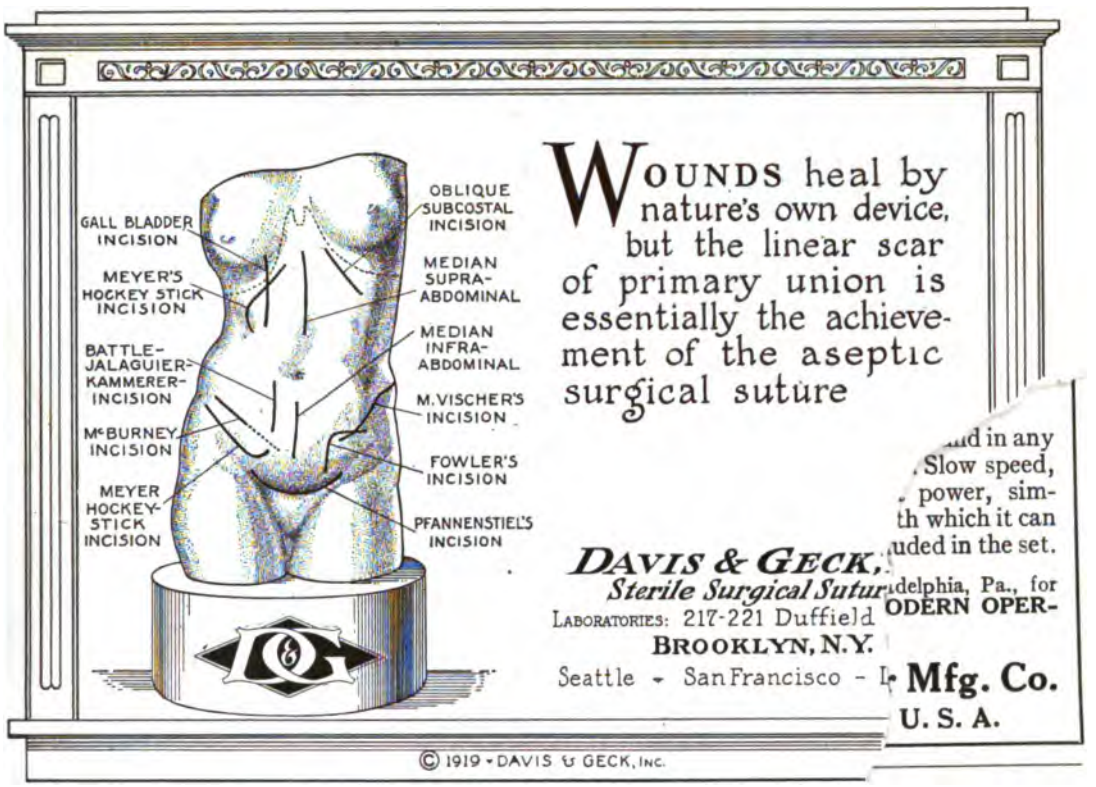

CONTENTS—APRIL, 1919

ORIGINAL ARTICLES

1. THE SURGICAL TREATMENT OF EMPYEMA. *Alexis V. Moschcowitz, M.D., Peoria, Illinois.* 404
2. EMPYEMA; ANALYSIS OF 70 CASES AT BASE HOSPITAL, CAMP JACKSON AND OF CRANIAL DECOMPRESSION. *Carl Eggers, M.D., New York* 407
3. A REVIEW OF THE TREATMENT OF PURULENT PLEURITIS (EMPYEMA) AT BASE HOSPITAL. *Lieutenant Victor P. Diederich, M.C., U. S. A., Camp* 418
4. OBSERVATIONS ON EMPYEMA. *J. Garland Sherrill, A.M., M.D., Louisville, Kentucky* 422
5. NEGATIVE PRESSURE VERSUS FREE OPEN DRAINAGE IN THORACIC EMPYEMA. *Fred H. Albee, M.D., O'Day, M.D., F.A.C.S., Honolulu, Hawaii* 428
6. THE EMPYEMA PROBLEM. *Emil G. Beck, M.D., F.A.C.S., Chicago* 431
7. PERFORATED GASTRIC AND DUODENAL ULCERS. *H. M. Richter, M.D., F.A.C.S., F. Porter, M.D., F.A.C.S.,* 432
8. ARE WE JUSTIFIED IN REMOVING A COMPARATIVELY HEALTHY APPENDIX IN THE PRESENCE OF CHRONIC CONSTIPATION? *Magie, M.D., F.A.C.S., Duluth, Minnesota*

CONTENTS CONTINUED OPPOSITE NEXT PAGE

EMPYEMA TROCAR

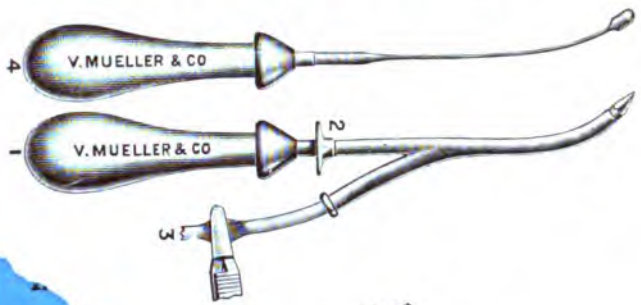

Devised by

VICTOR P. DIEDERICH
Lieut. M. C., U. S. A.

and employed in

Trocar Thoracotomy

At the Base Hospital,
Camp Pike, Ark.,
and other army hospitals.

This important instrument has been developed by us in accordance with Dr. Diederich's instructions.

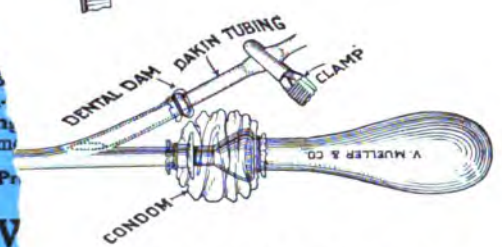

Lower P
Barium S
Dental X-
Developin
celain enam
Complete Pr

Geo. V

Supplied complete with accessories and directions by

LLER & CO., 1771-1783 Ogden Ave., Chicago

T

Sherman's B
will reduce the a
Broncho-pneumo
Fever, Colds, Br
mortality and

The Eclipse Door in

DEANE'S
PATENTED
STERILIZERS

The construction of the Eclipse Door is ingenious. It rolls inside the sterilizer and cannot open while any pressure remains in the chamber. It has no mechanical fasteners or gaskets, cannot leak and is safe and efficient. DEANE'S PATENTED STERILIZERS are recognized as the standard leading surgeons everywhere. They are made of the ery finest materials, and in various sizes and combinations suit every requirement of the modern hospital.

ur Advisory Department is at your service at any me and our catalog is yours for the asking. Send r it.

BRAMHALL, DEANE CO.
263 N West 36th Street, New York, N. Y.



Dr. Charles Geiger's

Electro-Operative Surgical Bone Instruments and Accessories

These instruments are made especially for transplanting bone, dowel making and cranial work. **Water is not required** to keep the cutters from burning the bone when using these instruments, **because of their slow speed.**

A few of the many advantages not found in any other motor bone instruments are: Slow speed, sterilization of motor, its great power, simplicity of chuck, and firmness with which it can be held. Sterilizable shell is included in the set.

Write F. A. Davis Pub. Co., Philadelphia, Pa., for Dr. Charles Geiger's book on **"MODERN OPERATIVE BONE SURGERY."**

The Charles Geiger Mfg. Co.
St. Joseph, Missouri, U. S. A.

CONTENTS—APRIL, 1919—CONTINUED

ORIGINAL ARTICLES — CONTINUED

9. PAROTITIS AS A POSTOPERATIVE COMPLICATION. *Clifford U. Collins, M.D., Peoria, Illinois.* 404

10. OBSERVATIONS REGARDING THE INDICATIONS FOR THE OPERATION OF CRANIAL DECOMPRESSION. *William Sharpe, M.D., New York* 407

DEPARTMENT OF TECHNIQUE

11. INTERPOSITION OPERATION FOR THE CURE OF PROLAPSUS UTERI AND CYSTOCELE. *Frederick W. Johnson, M.D., F.A.C.S., and Louis E. Phaneuf, M.D., Boston* 418

12. UNUNITED FRACTURE OF THE PATELLA AND OF THE OLECRANON. *Fred H. Albee, M.D., Sc.D., F.A.C.S., New York* 422

13. SOME TECHNICAL POINTS IN GASTRO-ENTEROSTOMY AND GASTROPLICATION. *A. Schwyzer, M.D., F.A.C.S., St. Paul, Minnesota* 428

14. A SUMMARY OF THE SURGICAL TREATMENT OF GOITER. *Miles F. Porter, M.D., F.A.C.S., Ft. Wayne, Indiana* 431

Books Received 432



A Sharp Knife

is a
Satisfaction
to the
Surgeon

The Bard-Parker Knife
is
Sharp

Handle No. 3 fits blades No. 10 and 11.
" No. 4 " " " 20 21 and 22.
Handles $1.00 each. Blades $1.50 per dozen.
Case for two handles and two dozen blades, 75 cents.
Blades are packed in envelopes containing ½ dozen blades of one size.

Your Dealer Can Supply

Bard-Parker Co., Inc. 37 East 28th St. New York

THE

RADIUM INSTITUTE

1604 Mallers Bldg., 59 E. Madison St.
Cor. Wabash Ave., Telephone Randolph 5794
C H I C A G O

DR. FRANK E. SIMPSON

COUNCIL

DR. F. A. BESLEY — DR. E. C. DUDLEY
DR. A. R. EDWARDS — DR. O. T. FREER
DR. M. HERZOG — DR. L. E. SCHMIDT
DR. G. F. SUKER

TREATMENT of Malignant and Benign Growths with Radium; Postoperative Prophylactic Radiations following the Surgical Treatment of Cancer.

Radium is indicated in inoperable malignant conditions. By its use an inoperable case may become operable.

We desire to confer and co-operate with surgeons, assuring them adequate amounts of Radium to meet the requirements of patients referred to us.

Your Pharmacist Knows

Send for beautifully illustrated catalog, in four colors, showing the complete line of Lilly Aseptic Metal Pocket Cases

YOUR pharmacist knows the care required to make a snow-white hypodermatic tablet of even texture, accurate grainage and dependable solubility.

Hand moulding hypodermatic tablets is more than a matter of routine; it is a definite responsibility. A hypodermatic injection is often an emergency measure; the physician relies upon it to produce results—quickly.

Ask your pharmacist for something more than a tube of hypodermatic tablets—specify Lilly's.

Drop One In Water; Watch It Disappear

ELI LILLY & COMPANY, Indianapolis, U. S. A.

NEW YORK CHICAGO ST. LOUIS KANSAS CITY NEW ORLEANS

INDEX TO ADVERTISING

Surgical Instruments and Apparatus

American Precision Works..... 14
Bauer & Black..... 16
Bard-Parker Co..... 4
Electro Surgical Instrument Co.... 14
Feick Brothers Co..... 27
Charles Geiger Mfg. Co..... 3
Goodwill Electric Co..... 14
Kny-Scheerer Corporation..... 10
McIntosh Battery & Optical Co... 14
V. Mueller & Co..... 2
Northwestern Steel & Iron Works.. 11
Harvey R. Pierce Co..... 12
Sharp & Smith..... 7
Taylor Instrument Companies..... 11
Truax, Inc..... 32
Victor Electric Co..... 28
Wappler Electric Co..... 26
Wm. V. Willis & Co..... 27

Hospital Supplies

Bauer & Black..... 16
Bramhall, Deane Co..... 2
General Laboratories..... 11
Good Mfg. Co..... 16
Kny-Scheerer Corporation..... 10
V. Mueller & Co..... 2
Northwestern Steel & Iron Works.. 11
Harvey R. Pierce Co..... 12

Anæsthesia Apparatus

Foregger Co..... 11
Safety Anæsthesia Apparatus Concern..... 6
Scientific Apparatus Co..... 33

X-Ray Apparatus, Tubes, Plates, Etc.

American Photo Chemical Co..... 30
Geo. W. Brady & Co.....2nd cover
Campbell Electric Co..... 32
Eastman Kodak Co..... 29
General Electric Co..... 31
Wm. Meyer Co..... 26
Victor Electric Co..... 28
Wappler Electric Co..... 26

Catgut—Ligatures

Armour & Co.....4th Cover
Davis & Geck, Inc..... 1
Hollister-Wilson Laboratories..... 9
Johnson & Johnson..... 25
C. DeWitt Lukens Co..... 24

Corsets, Bands, Etc.

S. H. Camp & Co..... 35
Earnshaw Knitting Co..... 33
Katherine L. Storm..... 32

Rubber Goods, Gloves, Etc.

E-Z Patch Co..... 16

Foods

Horlick's Malted Milk Co....4th Cover
Quaker Oats Co..... 27

Post-Graduate Instruction

Laboratory of Surgical Technique . 38
New York Post-Graduate Medical School and Hospital..... 40

Medical Books

P. Blakiston's Son & Co..... 15
Lea & Febiger..... 23
J. B. Lippincott Co..... 17
Macmillan Co..... 21
Massachusetts General Hospital ... 15
C. V. Mosby Co..... 20
Oxford University Press..... 22
Rebman Company..... 19
W. B. Saunders Co.....Cover and 13
Wm. Wood & Co..... 18
John Wright & Sons, Ltd..... 16

Pharmaceuticals

Abbott Laboratories..... 8
Armour & Co.....4th Cover
Cutter Laboratory.....3rd Cover
General Laboratories..... 11
Hynson, Westcott & Dunning..... 36
Eli Lilly & Co..... 5
H. A. Metz Laboratories, Inc..... 37
Sharp & Dohme..... 36
Dr. G. H. Sherman.....2nd Cover
Standard Oil Co..... 39

Radium

Physicians' Radium Association... 34
Radium Chemical Co..... 7
Radium Company of Colorado.... 25
Radium Institute..... 4

Miscellaneous

Battle Creek Sanitarium..... 38
Colorado Springs..... 34
Gradwohl Biological Laboratories.. 16
Medical Protective Co..... 33

SAFETY GAS-OXYGEN APPARATUS

SIMPLIFIES

the administration of

NITROUS OXID and OXYGEN

with or without an ETHER sequence in

MAJOR or MINOR SURGERY—OBSTETRICS—DENTISTRY

The old TROUBLE points ELIMINATED.

No high pressure bags. No spring gauges. No delicate mechanisms to get out of order.

The "Safety" employs HYDROSTATIC regulation which is *always* dependable and accurate.

Simple to operate. Minimum gas consumption. Ideal Anæsthesia and Analgesia.

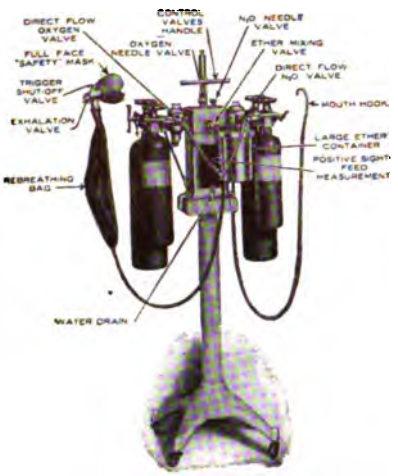

Model "F," with large ETHER Container and Mouth Hook. Style "B" and "C" Cylinders Attached.

The IDEAL HOSPITAL APPARATUS. This is the Outfit supplied all American Government mobile operating rooms in France, and many Military Hospitals and Cantonments in the United States. Uses from 40 to 60 gals. of N_2O per hour of profound anæsthesia.

Perfectly controlled smooth mixtures assured by

THE NEW

Positive Sight-Feed-Measurement

YOU SEE 1 The flowing of the separate gases.
2 That you obtain the desired mixtures.
3 That your mixtures are accurately maintained as long as required.

Gases delivered *Washed, Moistened* and *Heated* to body temperature.

Manufactured in three models, "D," "E" and "F;" truly portable and complete outfits for Private and Hospital use.

Write for illustrated booklet containing full information

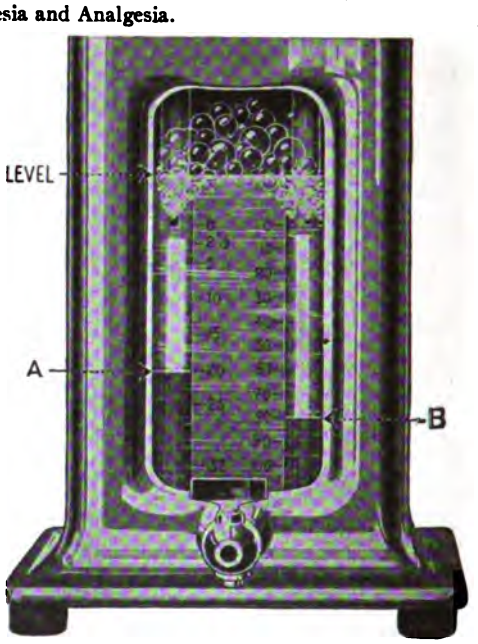

Cut showing Sight-Feed-Measurement, 3/7 actual size. The water-level "A" in the Oxygen Feed Tube, and the water-level "B" in the Nitrous Oxid feed tube fall or rise as a greater or less volume of the respective gases is admitted to the mixing chamber, by the needle valves. Accuracy of mixture and VISIBLE PROOF OF ACCURACY are thus assured.

SAFETY ANAESTHESIA APPARATUS

Ogden Ave. & Randolph St. CONCERN CHICAGO, ILLINOIS

RADIUM

STANDARD CHEMICAL CO.

Clinical data clearly proves the effectiveness of Radium in certain inoperable benign and malignant growths.

Many surgeons now employ a prophylactic dose before and after operation in all cases.

Sold on basis of United States Bureau of Standards' measurement. Information as to dosage, technic and equipment upon request.

RADIUM CHEMICAL CO.

GENERAL OFFICES - PITTSBURGH, PA.

LITTLE BLDG., BOSTON - MARSHALL FIELD ANNEX BLDG., CHICAGO - 501 FIFTH AVE., NEW YORK - WATSON & SONS, (ELECTRO-MEDICAL) LTD., LONDON.

Graduated Low Tone Tuning Forks

Devised by DR. W. G. REEDER

Important Announcement

WE are now able to deliver the first graduated low tone tuning forks manufactured in America. These forks are graduated in four tone intervals from 16 to 64 double vibrations per second. They are free from overtones and guaranteed to be perfect. Otologists who have been unable to obtain such a set of instruments at any figure since the war, are now offered a superior product at a nominal price. These forks are indispensable in accurate functional testing of the ear, especially in cases of incipient conduction deafness and those in which the lower tone limit is disturbed.

No. 1 Reeder's Tuning Fork, 16 to 20 double vibrations, is 23½ inches long and weighs 7½ lbs. . . . . Price $35.00

No. 2 Reeder's Tuning Fork, 24 to 28 double vibrations, is 19½ inches long and weighs 7 lbs. . . . . Price $35.00

No. 3 Reeder's Tuning Fork, 32 to 44 double vibrations, is 17 inches long and weighs 7 lbs. . . . . Price $32.50

No. 4 Reeder's Tuning Fork, 48 to 64 double vibrations, is 14 inches long and weighs 6 lbs. . . . . Price $32.50

SHARP & SMITH

Manufacturers and Exporters of High Grade Surgical Instruments and Hospital Supplies

65 E. LAKE ST. Between Wabash Ave. and Mich. Blvd. CHICAGO, ILL.

Established 1844 Incorporated 1904

Which Will You Use?

891 DEATHS
FROM
Carbolic Acid and Mercury Bichloride Poisoning.

Dr. Wm. McNally, chemist of the coroner for Cook County, Ill., reports 781 recorded deaths due to Phenol, and 110 deaths due to Mercuric Chloride during the years 1905 to 1917 inclusive.

Doctor, will you use an antiseptic which is **Poisonous** and **Dangerous,** such as Phenol and Mercuric Chloride? Will you use an antiseptic which is **irritating** and **unstable,** such as the hypochlorites?

Will you use an antiseptic which is soothing but **inefficient,** such as many liquid antiseptics on the market—

Or will you use

CHLORAZENE?

Dakin's Antiseptic

CHLORAZENE is **fifty times** stronger in its germicidal action than Phenol. It is at least a **thousand** times more germicidal than Liquor Antisepticus and Dobell's Solution.

CHLORAZENE is non-poisonous, non-irritating, safe and stable.

Doctors, try CHLORAZENE as a gargle in sore throat, tonsillitis and mouth infections. You will find the results astonishing.

Try CHLORAZENE also in Wounds, Burns, Carbuncles, Mucous Membrane Infections, Surgery and as a General Antiseptic. You will agree that CHLORAZENE is the **Universal Antiseptic.**

For Sale At All Druggists

Chlorazene Tablets in bottles of 100, 500 and 1000.
Chlorazene Powder in hospital packages No. 1 and No. 2.

A postal card will bring literature and prices.
You might also ask for Prices on Dichloramine T, Procaine, Barbital and Digipoten.

THE ABBOTT LABORATORIES
Home of the Dakin Products
ALL AMERICAN—ALWAYS AMERICAN
Home Office and Laboratories, Dept. 82, Chicago
New York Seattle San Francisco Los Angeles Toronto Bombay

HOLLISTER LIGATURES

Our Testing and Standardizing Laboratories

IN the manufacture and sterilization of surgical gut as conducted in our Plant and Laboratories, every detail is under the constant observation of competent technical workers from the moment of the animal's slaughter.

To facilitate this work we maintain a most complete series of laboratories—Physical, Chemical and Bacteriological, equipped to the last detail with apparatus calculated to insure accuracy, uniformity and the maximum of protection to the surgeon who discriminates in the selection of his surgical ligatures.

Sterility, tensile strength and elasticity are here determined for the finished product under the most favorable but exacting conditions, and to these laboratories are brought systematic reports for the bacteriological chemist in charge as the material in process of manufacture is carried through to completion.

Unless the source of supply of the raw material is under the immediate observation of the catgut manufacturer from the killing of the sheep to its manufacture into the twisted strand and final sterilization under the same personal control, surgical catgut will always be an enigma and a source of anxiety and controversy to operating surgeons.

A copy of our pamphlet "FROM ABATTOIR TO TUBE" will be mailed to you on request, together with samples of Hollister "TUBES OF DISTINCTION."

Hollister Ligatures can be obtained wherever surgical supplies are sold

HOLLISTER-WILSON LABORATORIES

4444-46-48 So. Ashland Ave. CHICAGO, U. S. A.

"TUBES OF DISTINCTION"

Medico-Mechanical Treatment in Cases of Motor Disturbances and Muscular Debility

There is no remedy which, in cases of accidents and affections of the joints and muscles, will restore the regular use of the limbs more quickly than early Medico-Mechanical treatment.

It is obvious that active exercise of the entire musculature will essentially change the conditions of the circulation, hence necessarily also act favorably upon a part in which an obstruction to the circulation is manifest (engorgement, œdema, change of tension due to pressure, with all its consequences).

This apparatus for the upper extermities is used for: Bending of the Hands, Stretching of the Hands, Lowering of the Arms, Raising of the Arms, Extension of the Arms, Rotation of the Arms, Rotation of the Forearms, Rotation of the Arms in Alternation, Bending of the Forearms, Extension of the Forearms.

In the next issue we will show the apparatus for the Lower Extremities

Send for Our Booklet on Combination Apparatus

The Kny-Scheerer Corporation

404-410 West 27th Street - - - - - NEW YORK, U. S. A.

Tycos $25.00

For your own information and benefit, have a talk with the owner of a *Tycos* Sphygmomanometer, or, better still, have a demonstration at your dealer's. It will gain your good will, as will the daily use hold it.

The expenditure for a *Tycos* Self-Verifying Sphygmomanometer makes you rightly feel the soundness of your judgment, for the extra quality means extra service. It satisfies the practitioner completely—the reason it holds the unchanging loyalty of users.

Tycos Fever Thermometers

Tycos Urinary Glassware

Taylor Instrument Companies

ROCHESTER, N. Y. 701

There's a Tycos and Taylor Thermometer for every purpose.

HYCLORITE HYPOCHLORITE

HYCLORITE

In Empyema

The use of Hyclorite in 1:1000 dilution for irrigating empyema cases after lobar pneumonia is enabling surgeons to discharge their patients in much shorter time than with previous methods of treatment. Hyclorite acts promptly, yet without irritation.

Hyclorite is always ready for immediate use.

Just add water and apply.

Hyclorite is prepared to a definite hypochlorite strength and alkalinity.

Solutions made from Hyclorite keep much longer than ordinary Dakin's solutions.

There is no waste, testing, or waiting in making a Dakin's solution from Hyclorite.

Price, 32 oz., $1.25

Order From Your Supply House

Accepted by the Council on Pharm. and Chem. for inclusion in N. N. R.

GENERAL LABORATORIES

4712 South Dickinson St.

MADISON - - WISCONSIN

Gwathmey Apparatus

The advantage of the "Sight Feed"

is not—to ***set*** the proportion,

it is—to ***get*** the proportion.

Nor is it—to know the amounts in liters or gallons,

but it is—to know what you are doing.

As an indicator for the quick obtainance and safe maintenance of uniform anesthetic conditions the visible gas flow of the "Sight Feed" is absolutely reliable and permanently so.

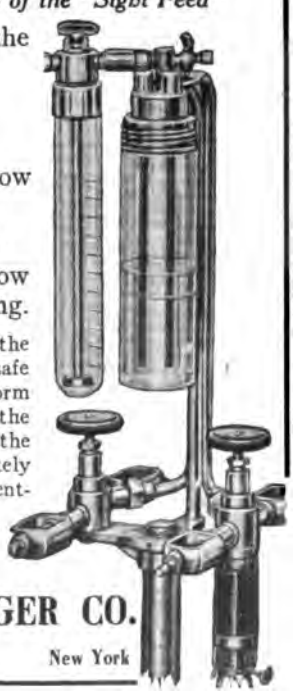

Write for Our 1919 Catalog

THE FOREGGER CO.

47 West 42nd St. New York

National

High Pressure

Sterilizer

The most widely used sterilizer in in America. Adopted and used by the U. S. Army and Red Cross. More than 4,000 in use in hospitals and doctors' offices in America. The National grows in popularity because it delivers

Sterilized "Bone Dry" Dressings in Half the Usual Time

Low cost because simple in construction
Requires little care, occupies small space
Operates under steam pressure 1 to 30 pounds at temperature of 212 to 260 degrees. Made in three sizes that meet every demand.

Doctor's $60; Medium $85; Hospital $145

Most good supply houses sell the National under our absolute guarantee. Order from your dealer. If he hasn't what you want, write us your requirements.

Northwestern Steel & Iron Works

883 Spring Street

Eau Claire, Wisconsin

Pratt-Lowman
Self-Retaining Retractor

for use in the open method of repairing fractures especially in connection with the Albee Motor Saw method.

Devised by Major John B. Lowman, M.C., and Captain R. B. Pratt, M.C., U. S. Base Hospital No. 38.

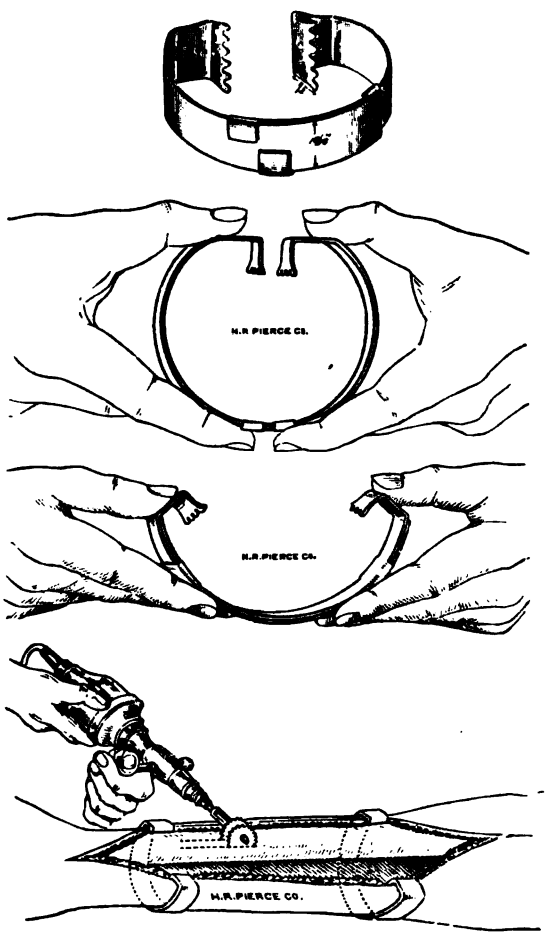

It affords the following advantages:

SIMPLICITY
No parts to be lost. Easy to clean, sterilize, manipulate.

DURABILITY
It not only gives RETRACTION of tissues, but also DEPRESSION of them with an uncomplicated automatic lock in any degree of retraction. Pressure upon its lower surface by the weight of the limb forcing it against the operating table only serves to increase retraction and locking.

It does away with retraction by assistants and with this the danger of extra hands in the operative field and leaves the operator unhindered in the use of the electric saw and drill.

It leaves the bone in a higher plane than the surrounding tissues and so obviates the danger of the saw, drill or spinning shaft engaging with the soft tissues or toweling.

In conjunction with an orthopedic table, assistants can be dispensed with during that stage of the operation in which the saw or drill is in use.

It is a useful addition in a teaching clinic in that it renders the field of operation more visible to spectators.

Made in several sizes.

Manufactured by

HARVEY R. PIERCE COMPANY

1801 Chestnut Street *The Modern Surgical Instrument Store* **PHILADELPHIA**

PITTSBURGH SALES OFFICE: 3030, 3031, 3032, 3033 JENKINS ARCADE

February Contents—Six War Clinics

Surgical Clinics of Chicago

Contribution by Major Kellogg Speed, M. C., *France.*

Gunshots of Right Scapular Region and of Left Knee.—Technic of operation; roentgenoscopy; Carrel-Dakin treatment; septic knee-joints—drainage plus motion and no splinting.

Gunshot of Left Side of Neck.—Nerve and spine lesions; treatment.

Through-and-Through Bullet Wound Just Below Lower Border of Popliteal Space.—Blood-vessel surgery; indications for operation; amputation; treatment of nerve sheath; false aneurysm; ligation of popliteal.

Shrapnel Wound Just Above Elbow.—Severed brachial artery and median nerve; rules for nerve injuries above elbow; technic of nerve suture.

Grazing Gunshot Wound with Soiled Edges.—DePage Anesthesia—formula.

Contribution by Lieut.-Col. Frederic A. Besley, M. C., *France.*

Secondary Hemorrhages in War Surgery: Careless use of Carrel-Dakin solution as factor; treatment; shock.

Clinical Lecture by Dr. V. D. Lespinasse, *Northwestern.*

Blood Transfusion: Methods to obviate clotting; indications; blood—Moss test; iridioplatinum tubes; cylinder citrate method; citrate method.

Clinic of Dr. Carl Beck, *North Chicago.*

I—Restoration of eyelids. II—Reconstruction of injured nose. III—Construction of new nose.

Clinic of Dr. Frank E. Simpson, *Cook County.*

Radium in Epithelioma of base of tongue and epiglottis; carcinoma of tongue; epithelioma of face.

Clinic of Dr. Arthur Dean Bevan, *Presbyterian.*

Obstruction of Ileum Due to Tuberculous ulcerations.
Injuries of Shoulder-Joint.
Bismuth Paste in Intestinal Fistula.
Spina Bifida: Operations; results.
Carcinoma of Face: Cancer paste; electric cautery; Thiersch Grafts.
Carcinoma of Axilla.
Sarcoma of Labium: Operative technic.

Clinic of Dr. John R. Harger, *University of Illinois.*

I—Sarcoma of Liver in Child. II—Sarcoma of Testicle with Metastasis to Lung.

Clinic of Dr. E. L. Moorhead, *Mercy.*

I—Gynecomazia or Gyrecomastia. II—Intraligamentous Uterine Fibroid Complicating Pregnancy. III—Compound Fracture of Ankle-Joint. IV.—Impacted Intra-Articular Fractures of Neck of Femur.

Clinic of Dr. Thomas J. Watkins, *St. Luke's.*

Postoperative Catheter Cystitis.

Clinic of Dr. A. J. Ochsner, *Augustana.*

Hypospadias: Technic of operation.
Excision of Ganglion from Hand.

Clinic of Dr. Gustav Kolischer and Dr. J. S. Eisenstaedt, *Michael Reese.*

Traumatic Rupture of Kidney.
Nephrolithiasis.
Removal of Stone.
Impacted Ureteral Stone.
Syphilis of Bladder.

Clinic of Dr. Chas. M. McKenna, *St. Joseph's.*

Suprapubic Prostatectomy. Technic.
Short-Circuit of Vas Deferens for Sterility.
Tuberculosis of Kidney—Nephrectomy.

Clinic of Dr. M. J. Hubeny, *Henrotin Memorial.*

Roentgenologic Demonstrations of Unusual Genito-Urinary Conditions.

Clinic of Dr. Geo. E. Shambaugh, *Presbyterian.*

Acute Mastoiditis with Infection of Deep-Seated Pneumatic Cells.
Disturbance of Equilibrium.
Vertigo Caused by Intracranial Disease.
Squamous-Cell Carcinoma of Larynx.
Laryngeal Papilloma. Operative technic.

Clinic of Dr. E. H. Ochsner, *Augustana.*

Sinus Disease, one case following influenza.

Clinic of Dr. M. A. Bernstein, *Wesley Memorial.*

Talipes Cavus: Four types; operative technic.

Clinic of Dr. Daniel A. Orth, *St. Mary's.*

Strangulated Femoral Hernia. Technic.

Issued serially, one octavo of 225 pages, illustrated, every other month (six volumes a year). Per Clinic Year (February to December): Cloth, $14.00 net; Paper, $10.00 net.

W. B. SAUNDERS COMPANY, West Washington Sq., Phila.

London: 9, Henrietta St., Covent Garden Australian Agcy: Centreway, 263 Collins St., Melbourne

Electrically Lighted Instruments

From the best material obtainable and by skilled workmen E. S. I. Co. instruments are made. Not alone are we the originators, but, as well, we are exclusive manufacturers of the most valuable diagnostic instruments in use. Their position is firmly established among the profession and their usefulness is unquestioned.

All our instruments may be operated upon our tungsten battery or upon commercial current by means of the socket current controller here illustrated.

Koch, Swinburne, Young, Gordon and MacGowan Urethroscopes
Braasch Cystoscopes, E. S. I. Co. Vaginal Specula

These and many other instruments are described and illustrated in our Catalogue, a copy of which will be mailed on request.

For your own protection be sure every instrument is marked "E. S. I. Co."

ELECTRO SURGICAL INSTRUMENT CO.
ROCHESTER, N. Y.

AMERICAN PRECISION WORKS

135 Cedar Street, New York City

WE REPAIR

KOLLMANN DILATORS OF ANY MAKE AND EQUIP SAME WITH

NEW-SAFETY PRESSURE GAUGE-NEW

WE DEVELOP

INVENTIONS AND MANUFACTURE ALL KINDS OF SPECIAL MEDICAL APPARATUS.



The
Pad Without a Fault

It has none of the drawbacks of other electric pads. It is so near perfection that it is

Guaranteed For One Year

The Goodwill Thermostatic control gives positive temperatures ranging from 100° to 180°. Used and endorsed by leading hospitals and physicians. *Money back if not satisfied.* Price $7.00. Order to-day.

GOODWILL ELECTRIC CO.
59 E. VAN BUREN ST. DEPT. A CHICAGO



McIntosh No. 4 Polysine Generator

Success in Electro-Therapy

MANY a practitioner can trace the origin of his success to the purchase of some piece of good apparatus which enabled him to individualize his system of treatment and give his patients something which they were not getting elsewhere.

With the McIntosh No. 4 Polysine Generator shown you have a means of combating the long train of sequelæ to abdominal insufficiency—conditions in which the slow sinusoidal current is unexcelled.

Ask for an Interesting Booklet "Sinusoidal Therapy" and Get Our Proposition

McINTOSH BATTERY & OPTICAL COMPANY

Eastern Office and Service Station
1777 Broadway, New York

Main Office and Factory
217-223 N. Desplaines St., Chicago

A New Blakiston Book

The After-Treatment of Wounds and Injuries

By R. C. ELMSLIE, M.S., F.R.C.S.

Brevet-Major, R.A.M.C., Special Military Surgical Hospital, Shepherd's Bush; Surgeon-in-charge, Orthopædic, Physical Exercise and Massage Departments, St. Bartholomew's Hospital

144 Illustrations. Ready

"It is a practical guide, based upon considerable experience in a Military Orthopædic Hospital."

P. BLAKISTON'S SON & CO. - Philadelphia

ON APPROVAL BLANK

P. BLAKISTON'S SON & CO.
1012 Walnut St., Philadelphia Date_____

Please send me, for 10 days' examination_____

_____ I will remit in 30 days for books I keep

Name_____ Address_____

"If Mahomet Won't Go to the Mountain, the Mountain Must Come to Mahomet."

CABOT CASE RECORDS

Edited by RICHARD C. CABOT, M.D., and HUGH CABOT, M.D.

A weekly series of diagnostic problems checked by necropsy which

Bring the Hospital to You

Its Wards, Its Laboratories, Its Operating Rooms, Its Necropsy Table, Its Lecture Amphitheaters and Class Discussions. The papers are so arranged that

The Busy or the Isolated Man Can Have the Privilege and Stimulus

of the original clinico-pathological exercises held at the

MASSACHUSETTS GENERAL HOSPITAL

Discussions by Dr. Richard C. Cabot and Dr. Hugh Cabot have now been resumed after their absence in war service in France.

Published by the Massachusetts General Hospital, Boston.
Subscription $5.00 per annum in advance.

Sample Copies and Rates to Medical Societies Will Be Sent On Application

In Two Volumes, with many Illustrations and Plates. Large 8vo. Cloth Gilt, Bevelled Boards, $10.00 net.

SURGICAL CONTRIBUTIONS from 1881-1916

By RUTHERFORD MORISON, M.B., F.R.C.S. (Edin. and Eng.)

With a PREFACE and FULL SUBJECT INDEX, Contributed by
W. D'OYLEY GRANGE, M.D., C.M.

VOL. I.—GENERAL SURGERY, $3.50 net. VOL. II.—ABDOMINAL SURGERY, $6.50 net.

"The Author has brought his views up to date.....We are surprised with the vast amount of original work.....The author's teaching aims primarily at the attainment of the thorough grasp of the principles ot surgery.....these are put in a helpful way..... The book will be widely read and used as a book of reference."—BRIT. MED. JOURN.

"There are few who will not profit from an examination of these volumes; on nearly every page are to be discovered points of utmost importance."—LANCET.

"These volumes show that their author was not only a very capable surgeon, but a clear thinker and a lucid writer."—MED. JOURN. OF AUSTRALIA.

New York: WM. WOOD & CO. Bristol, Eng.: JOHN WRIGHT & SONS, Ltd.

Do You Want the Highest Order of Serological Diagnosis?

Send Your Specimens to us for

Wassermann and Hecht-Gradwohl Tests,
Gonorrheal Complement Fixation,
Tuberculosis Complement Fixation.

All other Laboratory Tests.

Gradwohl Biological Laboratories.

R. B. H. GRADWOHL, M.D., Director.

928 N. Grand Ave. ST. LOUIS, MO.

Applied in a Minute and Holds Forever!

The E-Z Self-Cementing Self-Vulcanizing PATCH

A Permanent, Economical Patch for Repairing Rubber Gloves

The E-Z Patch is applied so easily and quickly that its very simplicity will appeal to you — to say nothing of the many dollars it will save. A little sandpaper and a drop of gasoline are the only things required.

The moment the E-Z Patch is subjected to heat, it vulcanizes and becomes an integral part of the object. Repeated sterilization only makes the patch hold better. There's no danger of infection.

THE E-Z PATCH COMPANY
AKRON, OHIO

Send for Trial Envelope Containing 6 for 25c
Hospital Size Package, 50 for $1.00
Samples on Request

B&B *Surgical Dressings*

The Standard for 25 years

BAUER & BLACK
Chicago New York Toronto

WE CAN SUPPLY YOU WITH

Gauze and Bandages

Prices upon request

The Good Manufacturing Co.
156 N. Wells Chicago

NEW LIPPINCOTT BOOKS **JUST ISSUED**

Hirst's ATLAS OPERATIVE GYNECOLOGY

By BARTON COOKE HIRST, M.D., *University of Pennsylvania*

Octavo **300 Pages** **210 Illustrations, Nearly All in Colors** **Cloth, $7.00**

This work has been confined strictly to conditions peculiar to women. The text has been subordinated to the illustrations, which are very large, clearly colored and show the separate steps of each operative procedure.

McDonald's ESSENTIALS OF SURGERY

For Students and Senior Nurses

By ARCHIBALD L. MCDONALD

Crown Octavo **265 Pages** **46 Illustrat'ons** **Cloth, $2.00**

This book covers the general principles of surgical diseases and pathological changes which result; the more important surgical lesions of the body are considered. The matter is presented simply and it covers most thoroughly the field of its title.

Fuch's TEXT-BOOK OF OPHTHALEOLOGY

By ALEXANDER DUANE, M.D., *Surgeon Ophthalmic and Aural Institute, New York*

Octavo **1067 Pages** **462 Illustrations** **Cloth, $7.00**

New 6th, edition of this well-known, universally used masterpiece is just from the press.

THE ELEMENTARY NERVOUS SYSTEM

By G. H. PARKER, SC.D., *Prof. of Zoology, Harvard University*

12mo. **229 Pages** **83 Illustrations** **Cloth, $2.50**

This is the second book issued in our Series of Monographs on Experimental Biology, written by a number of most prominent American biologists. As experimental biology and general physiology are one and the same science, the Series of Monographs will include the field of traditional general physiology. The volume first published was on Forced Movements, Tropisms and Animal Conduct, by Jacques Loeb, of the Rockefeller Institute. Many others are in preparation, and their publication will follow at short intervals. Full descriptive list on request.

Wilson and Potter "INTERNAL MEDICINE"

3 Octavo Volumes **Over 700 Pages Each** **448 Illustrations** **14 Plates** **Desk Index** **Cloth, $15.00**

This is a new practice in a most practical and usable form, with two volumes devoted exclusively to Diagnosis, written by Wilson, of Jefferson Medical College, Philadelphia. The third, by Potter, of Columbia University, is devoted to Treatment, and is based on the celebrated Ortner's Treatment.

INTERNATIONAL CLINICS

1st Volume; 29th Series

Octavo. 300 Pages **Illustrations: 5 Colored; 21 Black and White Plates** **Subscription Only Cloth, $2.50**

This first volume of the 29th Series contains the usual article on Progress of Medicine during 1918; eight live practical Clinics; a Symposium on influenza; four articles on Medicine; one on Public Health and four articles on Surgery, one a Symposium on Surgery of the Thorax.

J. B. LIPPINCOTT COMPANY

LONDON: *Since 1875* — 34 Bedford St., Strand

PHILADELPHIA: *Since 1792* — East Washington Square

MONTREAL: *Since 1897* — Unity Building

William Wood & Company's Latest Books

ROBERTS

War Surgery of the Face

A TREATISE ON PLASTIC RESTORATION
AFTER FACIAL INJURY

By John B. Roberts, A.M., M.D., F.A.C.S.

Professor of Surgery in the University of Pennsylvania Graduate School of Medicine; Lecturer in the Civilian School of Plastic and Oral Surgery established in Philadelphia by the Surgeon General, U. S. A. Prepared at the suggestion of the Subsection on Plastic and Oral Surgery connected with the office of the Surgeon General.

Octavo, 450 pages, illustrated by 256 engravings and 5 full-page plates. Muslin, $4.50 net.

DELAFIELD and PRUDDEN

A Text-Book of Pathology

With a Final Section on

POST-MORTEM EXAMINATIONS AND THE METHODS OF PRESERVING AND EXAMINING DISEASED TISSUES

By Francis Delafield, M.D., LL.D., and T. Mitchell Prudden, M.D., LL.D.

ELEVENTH EDITION

Revised by Francis Carter Wood, M.D.,

Director of the Pathological Department, St. Luke's Hospital, New York; Director of Cancer Research, Columbia University, New York. The text has been largely rewritten, the revision of the chapters on Tumors, on the Urinary Organs, on the Reproductive Organs of the female, and on the Bones and Joints especially having been very complete.

Royal Octavo, 1360 pages, profusely illustrated by 809 line and half-tone cuts in the text, printed in black and numerous colors, and fifteen full-page plates, in black and colors. Extra muslin, $7.50 net; half morocco $8.50 net.

CAMUS

Physical and Occupational Re-Education of the Maimed

By Jean Camus and Numerous Collaborators

Authorized Translation by W. F. Castle, R.N.

12 mo. 208 pages, with 64 illustrations. Extra muslin, $2.00 net.

COBB

The Organs of Internal Secretion

THEIR DISEASES AND THERAPEUTIC APPLICATION

By Ivo Geikie Cobb, M.D., M.R.C.S.

Late Assistant to Out-Patient Physician, the Middlesex Hospital

SECOND EDITION

12 mo. 288 pages. Muslin, $2.50 net

WILLIAM WOOD & COMPANY, 51 Fifth Avenue, New York

REBMAN COMPANY

141 W. 36th St. NEW YORK

NOTED BOOKS

PSYCHOLOGY

BLOCH—The Sexual Life of Our Time.....$6.00

FOREL—The Sexual Question. Illustrated.....$5.00

GILBERT—True and False Sex Alarms.....$1.25

KISCH—The Sexual Life of Woman. Illustrated.....$6.00

KRAFFT-EBING—Psychopathia Sexualis.....$4.00

SKIN

GARDNER—Iconograms. 150 colored lifelike illustrations. Art. Leather. .....Price, $15.00

KINGSBURY — Portfolio of Dermochromes. (*New Edition.*) Full Leather, 3 vols. (*Subscription*).$27.00

NEISSER - JACOBI — Iconographia Dermatologica. Seven Parts, ready now. Per issue.....$3.00

SABOURAUD—Regional Dermatology.....$3.50

NERVOUS SYSTEM

BELOUSOW—Delineation of the Nervous System of the Human Body. Illustrated charts in many colors. With explanatory text...Price, $12.00

BING—Regional Diagnosis.....$3.00

BING—Textbook of Nervous Diseases.....$5.00

TANZI—Mental Diseases. 132 illustrations.....$7.50

SURGERY

BOCKENHEIMER & FROHSE—Typical Operations in Surgery. 60 plates in colors. Half leather..... .....Price, $16.00

FLUHRER—The Principles of Treatment of Broken Limbs. Illustrated. .....Price, $3.00

GOULEY—Surgery of Genito-Urinary Organs.....Price, $2.00

KOPETSKY — Surgery of the Ear. Illustrated with 63 half-tones and line drawings. 8 charts and 4 colored plates.....Price, $4.00

KRAUSE (Fedor) — HEYMANN — EHRENFRIED — Surgical Operations. (Six vols.) Vol. I. 294 illustrations, mostly in colors.....$7.00 Vol. II. 373 illustrations, mostly in colors $7.00

KRAUSE—Surgery of the Brain. With 199 (17 of which are in colors) illustrations in the text, 122 figures on 60 Plates in colors and 2 Half-tone Plates. Over 1,200 pages. 3 vols., Art. Leather.....Price, $20.00

PELS-LEUSDEN — Surgical Operations. 668 illustrations. 750 pages. .....Price, $5.00

ROMER—Modern Bonesetting. Illustrated $1.75

RUMPEL — Cystoscopy in Surgery. 107 illustrations (85 in colors)..... .....Price, $6.00

All these books are printed from plates made in this country from type set in the United States and* PAID FOR SOLELY BY AMERICAN CAPITAL. *There are no foreign interests represented therein.

The Last Word in Reconstructive Surgery

Specimen illustration, reduced, from case reports

Plastic Surgery of the Face, Head, and Neck

With Stereoscopic Demonstrations and Case Reports

By JOSEPH C. BECK, M.D., F.A.C.S., and IRA FRANK, M.D., F.A.C.S., Chicago, Ill.

SINCE the outbreak of the war plastic surgery has assumed a position of unprecedented importance. This work was published to bring before the profession the most important and least difficult operations about the head and neck which can be performed by anyone having sufficient surgical training. The work is authoritative and up-to-date and incorporates the work done by the authors in the plastic and oral surgery schools of the U. S. Army. The stereoscopic pictures have been made as natural as possible, that is, actual reproductions from cadavers. The manual covers: Historical Resume of Plastic Surgery, Palatoplasty, Cheiloplasty and Meloplasty, Blepharoplasty, Primary Principles of Technic, Prosthesis in Reconstruction of Face, New Method of Using Silver Wire in Bone Surgery, Directions for Use of Stereoscope, and complete case reports and illustrations.

This work is composed of:—

(1) A manual containing 132 pages describing the various plastic surgery operations and 33 case histories and illustrations.

(2) A series of 107 stereoscopic pictures or slides, arranged in sets showing various operations in plastic surgery, printed on heavy cardboard, with complete descriptions of operations.

(3) A hand-stereoscope, with eye-piece and framework made of high-grade materials, ready for use.

All packed in a strong, cloth-covered box so that they can be easily handled and filed away.

The Price of complete set, as mentioned above.....$7.00

Greatly reduced specimen slide. Complete description on reverse. Beck and Frank have prepared for this work 107 stereoscopic illustrations, arranged in sets. An examination of these slides will show their value over the usual flat photographs.

Send in your order today. No need to write, just sign the attached coupon and mail

C. V. Mosby Co.—Medical Publishers

801-809 Metropolitan Bldg., St. Louis, U. S. A.

Canadian Agency: McAinsh & Co., Ltd., Toronto
London Agency: Hirschfeld Bros., Ltd., London

CUT HERE AND MAIL TODAY

Date.....

C. V. MOSBY CO.
Metropolitan Building, St. Louis, Mo.

GENTLEMEN:

Please send me Beck and Frank's "Plastic Surgery" with stereoscope, for which I enclose $7.00, or you may charge to my account.

Name .....

Street .....

Town.....State .....

Surg., Gyn. & Obstet.

What Authorities Say of This Unique New Macmillan Book

DISPENSARIES

Their Management and Development

A Book for Administrators, Public Health Workers and All Interested in Better Medical Service for the People

By MICHAEL M. DAVIS, Jr.
Director of the Boston Dispensary, and

DR. ANDREW R. WARNER
Superintendent of the Lakeside Hospital, Cleveland, Ohio

Cloth, small 8vo, 438 pp., $2.25

Dr. Charles V. Chapin, Supt. of City Health Dept., Providence, R. I.: "It is a most excellent and useful book. It would be well, indeed, if 'Dispensaries' could be read by those members of the medical profession who have been inclined to look upon the dispensary as an enemy of the practicing physician, for it is clearly shown that this is not so. The parts of the book dealing with the details of dispensary organization and management will prove most helpful to all who have any responsibility in such matters."

Journal of American Medical Association: "The authors discuss in a comprehensive manner the proper management of modern dispensaries, from the small dispensary handling only a few cases daily, or the special dispensary with but a single class of cases, to the great general dispensary, with its many clinics, handling 100,000 or more cases annually. Every phase of the subject, including the financing of such institutions, the question of free and pay patients, efficiency tests, the follow-up system, and social service in all its departments, is covered in a very thorough manner. *Not only physicians but those laymen who are interested in the great problems of public health* will find in this excellent volume *much that is of interest and also of great value.*"

The Survey: "There are few men in the country who would be better able to present the subject in all its ramifications than the authors. The greatest interest in the book, however, lies in the clear exposition of the social significance of the dispensary, its relation to the public and to the medical profession, and in discussion of the many intricate problems which the modern dispensary presents in its relation to social and public activities."

Table of Contents

Section I. Historical:
How Dispensaries Began.
The Public Health Motive and the Efficiency Idea.
Present Scope and Extent of Dispensaries in the United States.

Section II. Fundamental Principles:
Who Are Dispensary Patients?
Who Should Be Dispensary Patients?
The Ten Essentials of a Clinic.
Medical and Administrative Organization.
Social Service.

Section III. Technique:
Dispensary Buildings.
Dispensary Clinics; Equipment; Organization; Education and Preventive Medicine.
Dispensary Clinics continued: Specialties and Treatment Clinics; Laboratory; X-Ray Department; Pharmacy.
The Management of an Admission System.
Records and Statistics.
Follow-Up Systems.
Efficiency Tests.
Finance.

Section IV. Special Types:
The Out-Patient Department of the Small Hospital.
The Public Health Dispensary and the Health Center.
The Specialty Center and the Pay Clinic.

Section V. Public Problems:
Dispensaries and the Medical Profession.
The Efficient Dispensary of the Future.
Financing Better Medical Service.
The Organization of Dispensary Service for a Community.
Conclusion.

Suggestions for By-Laws and Rules of a Dispensary:

Send for Medical Catalog of Other New Important Books

The Macmillan Company

64-66 Fifth Avenue - - - - NEW YORK

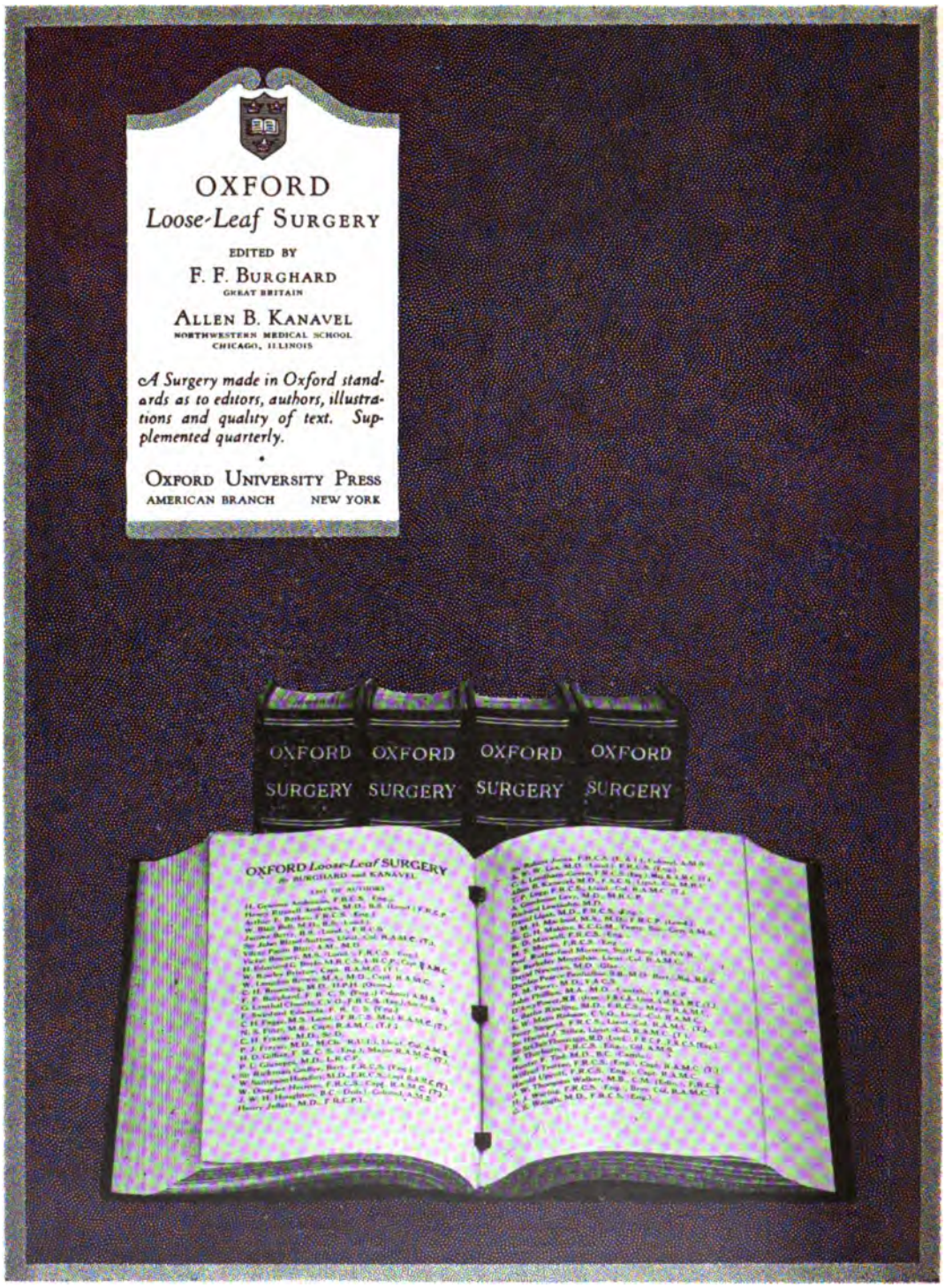
OXFORD
Loose-Leaf SURGERY
EDITED BY
F. F. BURGHARD
GREAT BRITAIN
ALLEN B. KANAVEL
NORTHWESTERN MEDICAL SCHOOL
CHICAGO, ILLINOIS
A Surgery made in Oxford standards as to editors, authors, illustrations and quality of text. Supplemented quarterly.
OXFORD UNIVERSITY PRESS
AMERICAN BRANCH NEW YORK
OXFORD SURGERY
OXFORD SURGERY
OXFORD SURGERY
OXFORD SURGERY
OXFORD Loose-Leaf SURGERY

Just Off Press

Whitman's Orthopaedic Surgery *New (6th) Edition*

The crippling accidents of War and recent epidemics of poliomyelitis have definitely established the place of orthopaedic surgery in the popular mind.

The revision of this standard American authority has been most thorough, as is evidenced by references to the most recent literature and the inclusion of the most up-to-date practices. Sixty-three additional illustrations have been inserted.

Orthopaedic surgery is presented in its most comprehensive aspect, as reflected by its literature and by the work of the more important clinics of this and other countries. Military Orthopaedics and the *early development of practical reconstruction* are fully set forth in an exceptionally well-illustrated chapter.

The author emphasizes throughout preventing or correcting deformity—preserving or restoring function. He has taken pains to describe systematic methods of examination that lead to early diagnosis; to explain the significance of the symptoms and physical signs that establish it; to indicate in natural sequence the principles of treatment and to describe simple and direct methods by which these principles may be effectively applied.

You get, in this book, the most recent methods of diagnosis and differential diagnosis; full information on the newly invented appliances and their use and all newer methods of treatment. The technique of all operative procedures, of bone grafting, nerve grafting, tendon and muscle transplantation, surgery of peripheral nerve injuries, etc., is given in detail.

Octavo, 914 pages with 767 illustrations. By Royal Whitman, M.D., M.R.C.S., Eng., F.A.C.S.; A Director of Military Orthopaedic Teaching, Chairman of the Medical Advisory Board for Orthopaedics in New York City; Associate Surgeon to the Hospital for Ruptured and Crippled; Orthopaedic Surgeon to the Hospital of St. John's Guild; Corresponding Member of the British Orthopaedic Society, etc., etc. *Cloth, $7.00 net.*

Simon's Human Infection Carriers *Just Ready*

Just off the press—this work covers the all-important topic of Preventive Medicine. How to recognize the carrier, with a detailed description of the laboratory methods involved; the management of the carrier, with the medical or even surgical treatment involved; the occurrence of active and passive carriers; duration of the carrier state; numerical relation between patients and carriers; habitat and virulence of the organisms; mode of infection; concrete examples illustrating the danger of the carrier to others—in other words, everything that medical science can do to prevent spreading of infection.

12mo. 250 pages. By Charles E. Simon, B.A., M.D., Professor of Clinical Pathology, University of Maryland School of Medicine and College of Physicians and Surgeons, Baltimore, Md. *Cloth, $2.25 net.*

Second Editions of War Manuals 1, 2, 3 and 4 are now ready

LEA & FEBIGER

Established 1785

PHILADELPHIA | **NEW YORK**

LEA & FEBIGER, 706 Sansom St., Philadelphia.
Send me new edition of Whitman and Simon's Infection Carriers as checked (X). Check for $ ..... enclosed or charge my account. S.G.&O.

Name .....
Address .....
City ..... State .....

Lukens Sterile Catgut

TRADE (Bartlett Process) MARK

Make the Test Yourself

Compare It Point for Point With Any Other Catgut

We Will Send the Samples

It is sterile, antiseptic, strong, supple, elastic; free from excess oil; will not untwist in using and is more than usually resistant to absorption.

Sizes 00-4 Plain *Sizes 0-4 Tanned*

C. DE WITT LUKENS CO.
4908 Laclede Avenue
ST. LOUIS MO., U.S.A

FOR SALE BY ALL DEALERS.

The thought behind the tube—
"the patient on the table"
Not "good enough"-but the best from every standpoint-alone assures that degree of "Catgut Safety" demanded when the patient on the table is "ONE OF MY OWN FAMILY."
Only on this peculiarly personal basis is "Van Horn" Catgut supplied to the profession.
Van Horn
Johnson & Johnson
VAN HORN and SAXTELL DEPARTMENT
NEW BRUNSWICK, N.J.

RADIUM

Salts of Any Desired Purity

STANDARD APPLICATORS

Guaranteed by U. S. Bureau of Standards Certificate

RADIUM EMANATION STATIONS

We furnish Scientific Installations designed to efficiently separate the Emanation from Radium.

The Emanation can be readily put into applicators, leaving the entire supply of Radium Intact.

Write us for information and estimates.

THE RADIUM COMPANY OF COLORADO

DENVER *Incorporated* COLORADO

PURVEYORS TO HIS BRITANNIC MAJESTY'S GOVERNMENT

(870)

THE MEYER MULTOSCOPE

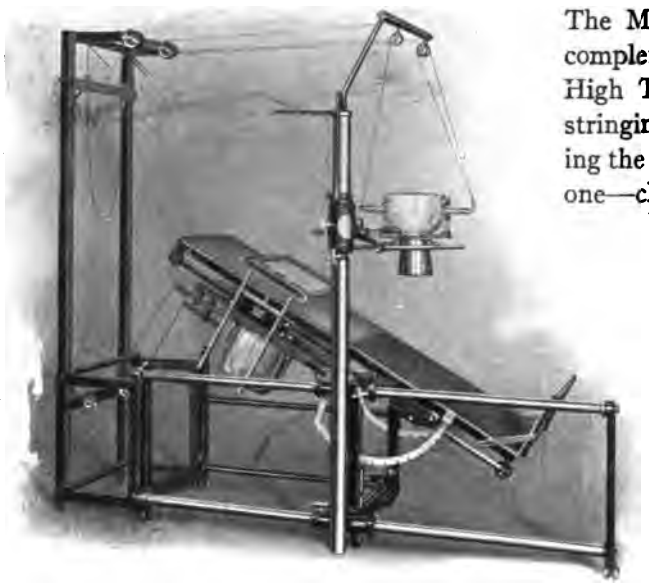

The Meyer Multoscope is furnished complete with Self Contained Aerial and High Tension Switch, eliminating the stringing of wires in a room and making the placing of the apparatus a flexible one—changeable as desired. No current wasted in excess wiring. The last word in classiness.

It covers every phase of Modern X-Ray Work.

Send for the
MULTOSCOPE BULLETIN

Price complete $1100.00

THE WM. MEYER COMPANY

817 WASHINGTON BLVD. **CHICAGO, ILL.**

ANNOUNCEMENT

AN EPOCH-MAKING ADVANCE IN THE ROENTGEN ART

The Wappler Electric Company announces the production of a new Roentgen Ray Tube known as

NITROKEN

This new gas tube remains stable during heavy prolonged exposures and cannot be over-reduced

Full technical and commercial information will be sent upon request

WAPPLER ELECTRIC COMPANY, Inc.
173 E. 87th Street, NEW YORK. U. S. A.



The Surgeon

is generally called upon for advice as to

Artificial Limbs

Why not recommend one that is sure to be SATISFACTORY?

Our Latest Model

with Adjustable Leather Socket, Cordless Ankle, Felt or Sponge Rubber Foot, Ball-bearing Joints

assure the patient of comfort and perfect locomotion.

Our GUARANTEE Covers All Repairs

Write for Catalogue

FEICK BROS. COMPANY

809 Liberty Ave. Pittsburgh, Pa.

HAVE YOUR

Colostomy Patients

wear a comfortable and effective appliance which lies flat and does not show through the clothing.

Devised by DR. J. COLES BRICK

Brick's Colostomy Appliance

Price $5.00, including two rubber bags and an adjustable strap to fit any patient. Discount to physicians.

WM. V. WILLIS & CO.

Surgical Instruments

134 So. 11th St. Philadelphia, Pa.

Prof. Anderson

Blasts Every Food Cell in Whole Wheat and Rice

Prof. A. P. Anderson, formerly of Columbia University, solved the problem of steam exploding ALL the food cells in whole grain. The best other forms of cooking, baking or toasting fail to do that.

He seals the grains in guns, and revolves the guns for sixty minutes in 550 degrees of heat. Thus the moisture in each food cell is changed to steam.

When the guns are shot the steam explodes. In every kernel occur over 100 million explosions—one for every food cell.

The grains come out in bubble form, eight times normal size. They are thin, flaky, toasted tidbits with a nut-like taste. With cream and sugar or in bowls of milk they are veritable food confections.

The result of this process is easy, complete digestion. Whole grains are made inviting. Thousands of physicians, in many conditions, now advise this form of grain food.

The Quaker Oats Company

Sole Makers

Puffed Wheat
Puffed Rice
Corn Puffs

All Steam-Exploded Grains (3070)

Fluoroscopic Diagnosis

as one of the important routine methods in the busy roentgen laboratory, is now generally considered a very essential procedure.

The Victor Horizontal Roentgenoscope

is the ideal specialized apparatus for horizontal fluoroscopy, this latest product of the Victor designers embodying every essential for the most practical and reliable construction.

A centralized control gives to the operater complete control, *with one hand on one control arm*, of every manipulation for moving the x-ray tube and fluoroscopic screen and for varying the aperture of the shutter—leaving the other hand entirely free.

All parts of the body are in range of the fluoroscopic field—even the largest patient—without changing his position, as the wide range of movement of the tube box, laterally and longitudinally, obviates this.

The fluoroscopic screen moves in unison with the tube, the screen staging being attached to the tube carriage, so the screen is brought automatically into the field of observation.

Ease of manipulation is due to ball bearing rollers, every desired movement responding instantly to the touch. *Write for Bulletin 231, giving full particulars.*

VICTOR ELECTRIC CORPORATION

Manufacturers of a Complete Line of Roentgen and Electro-Medical Apparatus

CHICAGO
236 S. ROBEY ST.

CAMBRIDGE, MASS.
66 BROADWAY

NEW YORK
131 E. 23d ST.

Sales and Service Stations:

NEW YORK, N. Y.
131 E. 23d St.
CAMBRIDGE, MASS.
66 Broadway
CHICAGO, ILL.
30 E. Randolph St.
236 S. Robey St.
PHILADELPHIA, PA.
25 S. 17th St.
SEATTLE, WASH.
823 White Bldg.
PORTLAND, ORE.
803 Morgan Bldg.
KANSAS CITY, MO.
414 E. 10th St.
BIRMINGHAM, ALA.
619 Brown-Marx Bldg.
DETROIT, MICH.
103 Broadway

CINCINNATI, OHIO
231 Fourth St.
ALBANY, N. Y.
82 S. Grove Ave.
LOUISVILLE, KY.
433 Atherton Bldg.
ROCHESTER, N. Y.
840 Genesee St.
NEW ORLEANS, LA.
606-608 Maison Blanche
LOS ANGELES, CAL.
4002 Walton Ave.
MINNEAPOLIS MINN.
220 La Salle Bldg.
AUSTIN, TEXAS
708 Colorado St.
TORONTO, CANADA
24 Hayter St.

CLEVELAND, OHIO
505 Frederick Bldg.
PITTSBURGH, PA.
620 Fulton Bldg.
FT. WAYNE, IND.
1333 Calhoun St.
DES MOINES, IOWA
518-22 Utica Bldg.
WINNIPEG, CANADA
Keewayden Block
VANCOUVER, CANADA
536 Smythe St.
SAN FRANCISCO, CAL.
334 Sutter St.
BUFFALO, N. Y.
318 Pearl St.
ATLANTA, GA.
515 Hurt Bldg.
CHARLOTTE, N. C.
11 Dartmouth Pl.

Eastman Dupli-Tized X-Ray Films

THIS roentgenogram of the frontal sinus was made on Dupli-Tized Film, with two intensifying screens, in 5 seconds, at 18 inches, with a 10 M. A. Army Type Coolidge Radiator Tube and 5-inch spark. With Dupli-Tized Films you can shorten the exposure, thus minimizing the danger to the patient and still obtain the maximum result.

Ask your dealer for Eastman Dupli-Tized X-Ray Films.

EASTMAN KODAK CO., ROCHESTER, N. Y.

Difficult Diagnosis

Diagnostic X-Ray plates possess a density sufficient for the most difficult diagnosis —and at the same time are the fastest X-Ray plates made.

They possess a power for sharp contrast equal to detecting the most delicate details. They give the roentgenologist a portrayal that facilitates interpretation.

Diagnostic X-Ray plates are equally excellent for direct and screen work. One plate for both purposes standardizes technique, development, and results. Made from new glass only—fixes out stain-free and absolutely clear.

AMERICAN PHOTO CHEMICAL COMPANY
ROCHESTER NEW YORK

For Sale by Leading Supply Houses

DIAGNOSTIC

Thoroughness in Fluoroscopy Depends, in the End, on the Definition of the Screen Image. Selection of the Proper Focal Spot is therefore Vital.



Radiator Type Coolidge X-Ray Tube

FLUOROSCOPY

The exceptionally fine focus of the Radiator Type Coolidge X-Ray Tube makes it particularly valuable to the Roentgenologist for Fluoroscopy.

The wealth of detail of the screen image makes attainments that were the exception before the advent of this tube, the rule with it.

This tube is especially adapted for use with all types of fluoroscopes. It operates satisfactorily on all interruptless machines and induction coils.

Immediate Shipment Can Be Made

General Electric Company

General Office Schenectady, N.Y.

35B-11

Campbell ELECTRICS LYNN, MASS.

EXPERIMENT AND UNCERTAIN RESULTS ARE ELIMINATED WHEN YOU INSTALL

Campbell Roentgen Apparatus

Sure-X Interrupterless Transformer
Tube Tilt Table
Stereoscopic Tube Stand
High Frequency Coils
Electro-Therapeutic
and Roentgen Accessories

Send for Literature

CAMPBELL ELECTRIC CORPORATION
LYNN, MASSACHUSETTS

Storm Binder and Abdominal Supporter
(Patented)

Adapted to use of men, women and children, for any purpose for which an abdominal supporter is needed. **High and Low Operations, Ptosis, Pregnancy, Obesity, Hernia, Relaxed Sacro-Iliac Articulations, Floating Kidney, etc.**

Folder on request—with prices, materials and physicians' testimonials

Mail Orders filled at Philadelphia within 24 hours

Katherine L. Storm, M. D.
1541 Diamond Street, Philadelphia

SKELETONS

We have secured a large stock of

Selected Skeletons

Prices and descriptions gladly furnished on application

TRUAX
CHARLES TRUAX, Incorporated
141 N. Wabash Ave. CHICAGO



CONNELL GAS OXYGEN APPARATUS

ANAESTHESIA
APPARATUS AND APPLIANCES

THE CONNELL GAS OXYGEN METER MEASURE APPARATUS, Four Models

THE ANAESTHETOMETER
DELIVERS AUTOMATICALLY ANY VOLUME AND PERCENTAGE OF ETHER VAPOR WITH MATHEMATICAL ACCURACY

CONNELL SUCTION INSUFFLATION APPARATUS
A MOTOR BLOWER MAINTAINING THE STANDARD OF EFFICIENCY SET FOR OUR OTHER MACHINES

SEND FOR OUR BOOKLET *Scientific Anaesthesia*
IT DESCRIBES THE VARIOUS MACHINES WE MAKE

SCIENTIFIC APPARATUS COMPANY, Inc.
162 WEST 34th STREET - - - NEW YORK, N. Y.

"Vanta" Abdominal Binder

KNITTED of soft wool—firm but elastic—it gives just the protection and abdominal support needed, yet always adjusts itself to the full or empty stomach.

A big improvement on the old-fashioned inelastic strip of flannel. Ties with three little bows of *twistless* tape—no dangerous pins—no troublesome sewing.

We would like you to know, Doctor, what an excellent binder this is. Mail us your card, or write on professional letterhead, and we will gladly send you a sample binder free.

EARNSHAW KNITTING COMPANY
1461 West Jackson Blvd - Chicago

The Abdominal Binder illustrated above is only one of the many Vanta Garments that enable baby to be dressed from top to toe without a single pin or button. Our booklet, "Baby's Outfit," describes and illustrates the entire line. May we send you a copy?

50% BETTER

Prevention Defense Indemnity

1 All claims or suits for alleged civil malpractice, error or mistake, for which our contract holder,
2 Or his estate is sued, whether the act or omission was his own.
3 Or that of any other person (not necessarily an assistant or agent).
4 All such claims arising in suits involving the collection of professional fees.
5 All claims arising in autopsies, inquests and in the prescribing and handling of drugs and medicines.
6 Defense through the court of last resort and until all legal remedies are exhausted.
7 Without limit as to amount expended.
8 You have a voice in the selection of local counsel.
9 *If we lose, we pay to amount specified, in addition to the unlimited defense.*
10 The only contract containing all the above features and which is protection per se. *A sample upon request.*

The MEDICAL PROTECTIVE CO. *of* Fort Wayne, Indiana

Professional Protection Exclusively

You'll Get New Health and Strength in This Mile High Region!

Superb climatic conditions, at this season, in fact all the year, makes the Pikes Peak Region a favorite sojourn for rest and health seekers. Your time is spent in the open—out in the sunshine that pours down so freely and bountifully—hiking if you wish over the mountain trails—motoring or riding a horseback over magnificent roads—drinking from health-giving mineral springs—hunting, golfing and all out-of-doors sports and diversions. Health and invigorating rest is yours amid such environment.

Interesting literature will be sent you on request. *Address:*

Climatic Conditions Committee
Chamber of Commerce
151 Independence Bldg. Colo. Springs, Colo.

RADIUM RENTAL SERVICE

By The Physicians' Radium Association of Chicago

(Incorporated under the laws of Illinois, "Not for Profit")

BOARD OF DIRECTORS
William L. Baum, M. D.
N. Sproat Heaney, M. D.
Frederick Menge, M. D.
Thomas J. Watkins, M. D.
Albert Woelfel, M. D.

MANAGING DIRECTOR
Albert Woelfel, M. D.

ESTABLISHED to make Radium more available in the *Middle States* and to furnish advice based on extensive observations, about its approved therapeutic uses. Maintains the equipment, large and complete in its makeup, that is needed to meet the special requirements of any case in which radium therapy is indicated. Radium loaned to any responsible physician. Moderate rental fees charged.

For Full Particulars Address

THE PHYSICIANS' RADIUM ASSOCIATION

1104 Tower Bldg., 6 N. Michigan Ave., Chicago Telephones, Randolph 6897-6898

An Unparalleled Success

Camp Physiological Belts

have been established and proven a positive essential as an aid in the treatment of abdominal prolapse and in post-operative conditions. This System of rigid, non-elastic supports has been adopted by eminent specialists in surgery and gynecology throughout the world.

In addition to the specific types already tested and approved by the profession, we present herewith still another form, one of great interest to all obstetricians.

The accompanying photographic illustration shows a Maternity Belt; the graphic feature of which is an even, well-distributed support, without constriction.

The "block-and-tackle" system of lacing applied to Camp Belts, together with the extra lacing over the abdominal wall, give unusual flexibility of adjustment and gradual adaptability in increase of size.

This Maternity Belt may be worn with perfect comfort during the entire period of pregnancy.

New York, 373 Fifth Ave.
San Francisco, 330 Sutter St.
Buffalo, 70 W. Chippewa St.
St. Paul, 422 Peoples Bank Bldg.
Portland, Ore., Woodlark Bldg.
Rochester, 1141 Granite Bldg.
Columbus, 104 N. High St.
Utica, 314 Kempf Bldg.
Houston, 203 Foster Bldg.

Goodwin Corset Shops

Boston, 637 Boylston St.
Los Angeles, 220 W. 5th St.
Davenport, 209 Main St.
Cincinnati, 433 Race St.

Philadelphia, 1120 Walnut St.
St. Louis, 513 Olive St.
Omaha, 1704 Douglas St.
Minneapolis, 816 Nicollet Ave.

Chicago, 57 E. Madison St.
Pittsburgh, 2006 Jenkins Arcade Bldg.
Detroit, 313 David Whitney Bldg.
Kansas City, 413 Altman Bldg.
Jamestown, 514 Prendergast Ave.
Toledo, 219 Superior St.
Spokane, 827 Sprague Ave.
Indianapolis, 55 Monument Place
Denver, 1764 Broadway

Address all correspondence to

S. H. CAMP & COMPANY, Manufacturers, Jackson, Michigan

speaking of cascara

our demand for F. E. Cascara Aromatic U. S. P.—always small—has dwindled down to the vanishing point; so we will not even list it in our new catalog—ready by the way in May.

But the demand for F. E. Cascara Aromatic S&D—that is growing constantly and rapidly and is taxing our best efforts to supply.

Another proof that "quality pays."

SINCE 1860 Sharp & Dohme
CAREFUL CONSCIENTIOUS CHEMISTS

Authorities on Corpus Luteum

For Correcting Abnormal Ovarian Functionation, Amenorrhea, Dysmenorrhea, Nervous Irritability

CURTIS F. BURNAM, M.D., Baltimore, Johns Hopkins Medical School: "Corpus Luteum Extract, with Suggestions as to Its Use in Gynecologic Practice," *Journal of the American Medical Association*, August 31, 1912.

ADAM F. LEIGHTON, JR., M.D., L.M. (Dublin), Portland, Maine: "The Use of Luteum Extract in the Treatment of Menstrual Disorders," *American Journal of Obstetrics and Diseases of Women and Children*, November, 1915.

OLIVER T. OSBORNE, M.A., M.D., New Haven, Connecticut, Medical Department, Yale University: "Ovary: Corpus Luteum," *New York Medical Journal*, September 7 and 14, 1918.

Reprints or Abstracts of These Papers Sent Upon Request

Corpus Luteum of the Sow—Lutein Tablets, H. W. & D.
2 grain, 100 in a tube 5 grain, 50 in a tube

HYNSON, WESTCOTT & DUNNING - Baltimore

NEOSALVARSAN

(Neoarsphenamine-Metz)

Now Ready for Distribution

Manufactured by

H. A. Metz Laboratories, Inc.

122 Hudson Street

NEW YORK



THE BATTLE CREEK SANITARIUM AND HOSPITAL—Established 1866

Medical Surgical Orthopedic
Neurological Obstetrical Reconstructive

Educational Departments

Training School for Nurses Normal School of Physical Education School of Home Economics and Dietetics
Students received on favorable terms Registered trained nurses, dietitians and physical directors supplied

Descriptive literature mailed free upon request

THE BATTLE CREEK SANITARIUM
Box 243, BATTLE CREEK, MICHIGAN

Surgical Technique: Instruction and Practice

AN ORIGINAL plan of teaching Surgical Technique, giving the instruction, and enabling the doctor to do the operations over and over, until he has mastered all details. Particular attention is given to the table toilet, and the work is performed as humanely as if the operations were being done upon an anaesthetized human. *The operations are all performed by the student.*

Each table is furnished with the same instruments that are to be found in any well-equipped operating room, and gowns and gloves are supplied to each student.

The Laboratory is open daily from 8:30 to 5 o'clock, which makes it possible for the man whose time away from his practice is limited, to get the work in the shortest possible time.

Special courses may be had in surgical anatomy on the cadaver.

Northeast Corner of Operating Room

The L. of S. T. of Chicago

Gentlemen: Send me information regarding the above.

Name.....
City.....
State.....

Personal Instruction, Actual Practice, and Exceptional Equipment. Course Completed in 7 Days (50 hours), Minimizing Time Away from Practice.

As to the Plan, Time, Fee, etc., Address

The Laboratory of Surgical Technique

Phone Midway 4896 **7629 Jeffery Ave., CHICAGO**

Stanolind

Reg. U. S. Pat. Off.

Surgical Wax

A new dressing for burns, granulations and similar lesions.

Manufactured by the Standard Oil Company of Indiana, and guaranteed by them to be free from deleterious matters, and so packed as to insure it against all contamination.

Stanolind Surgical Wax has a sufficiently low melting point so that when fluid the possibility of burning healthy tissue is precluded.

Its correct ductile and plastic features make it adaptable to surface irregularities without breaking.

When properly applied it adheres closely to sound skin, yet separates readily and without pain from denuded surfaces.

Stanolind Surgical Wax when applied in proper thickness maintains a uniform temperature, promoting rapid cell growth, and assisting nature to make repairs quickly.

Stanolind Petrolatum

A New, Highly Refined Product

Vastly superior in color to any other petrolatum heretofore offered.

The Standard Oil Company of Indiana guarantees, without qualification, that no purer, no finer, no more carefully prepared petrolatum can be made.

Stanolind Petrolatum is manufactured in five grades, differing one from the other in color only.

Each color, however, has a definite and fixed place in the requirements of the medical profession.

"Superla White" Stanolind Petrolatum.

"Ivory White" Stanolind Petrolatum.

"Onyx" Stanolind Petrolatum.

"Topaz" Stanolind Petrolatum.

"Amber" Stanolind Petrolatum.

The Standard Oil Company, because of its comprehensive facilities, is enabled to sell Stanolind Petrolatum at unusually low prices.

STANDARD OIL COMPANY

(Indiana)

Manufacturers of Medicinal Products from Petroleum

910 S. Michigan Avenue Chicago, U. S. A.

764

New York Post-Graduate

Medical School and Hospital

Courses arranged for the general practitioner in all branches of medicine. Separate courses on every subject and Special Practical Courses, where individual instruction is given in the following subjects:

Anaesthesia; Colon and Rectal Diseases; Complete Eye Seminar, embracing seven Special Courses; Ear Operations (Cadaver); Nose and Throat Operations on the Cadaver and in the Operating Rooms; Bronchoscopy; Nose and Throat Pathology; Abdominal Diagnosis; Physical Diagnosis; Diagnosis and Treatment of Constitutional Diseases of the Adult; Dietetic and Metabolic Problems; Infectious Diseases; Neurology; Stomach Diseases; Infant Feeding and Diagnosis; Intubation and Lumbar Puncture; Practical Pediatrics; Cystoscopy—Male and Female; Diagnosis and Office Treatment of Gynecological Cases; Gynecological Operations on the Cadaver; General Surgery on the Cadaver; Genito-Urinary Surgery on the Cadaver; Military Orthopedic and Bone and Joint Surgery; Treatment and Care of Fractures; X-Ray and Laboratory Work.

The Hospital has a bed capacity of over 400. The average number of patients admitted daily to the Dispensary is 800. The Hospital and teaching facilities are as extensive during the summer months as during the winter session. Cadaver courses omitted during June, July, August and September.

Through the courtesy of the Secretary, a two-day complimentary ticket is given, which enables the visiting physician to decide upon the courses best suited to his purpose and to meet the instructors in the various departments before registering for any work.

For Further Particulars Address

SECRETARY OF THE FACULTY

305 East Twentieth Street **NEW YORK CITY**

SURGERY, GYNECOLOGY AND OBSTETRICS

AN INTERNATIONAL MAGAZINE, PUBLISHED MONTHLY

VOLUME XXVIII APRIL, 1919 NUMBER 4

THE SURGICAL TREATMENT OF EMPYEMA

BY ALEXIS V. MOSCHCOWITZ, M.D.
Major, Medical Corps, U. S. A.

MY interest in empyema was stimulated by an investigation which I and my adjunct, Dr. A. O. Wilensky, instituted in the year 1914. In tabulating statistically the results in 299 consecutive cases observed in Mount Sinai Hospital, New York, during the preceding 10 years, we discovered that the mortality reached the formidable figure of 28 per cent. This was a rude shock to my complacency engendered largely by the conventionally indifferent attitude of most surgeons toward this malady. Of course, it is barely possible that our mortality is an unusual one; but conversations with numerous surgeons throughout the country lead me to believe that most of them suffer from a similar delusion that their mortality in empyema is lower than it really is.

For this reason, I deemed my appointment to the Empyema Commission as a most welcome opportunity, not only to study the disease *en masse*, but, what we so frequently miss in civil practice, to observe the disease from its very inception. This paper is based entirely upon our experiences on 140 cases, observed first in Camp Lee, and subsequently at General Hospital No. 12, Biltmore, North Carolina.

As is already known, the vast majority of these empyemata are due to infection by a hæmolytic streptococcus, and are coincident with or follow a peculiar form of organizing bronchopneumonia, the pathology of which has been ably described by W. G. MacCallum. Most of the cases follow measles. Despite the extraordinary incidence of the streptococcus as the infective agent, these empyemata, except in the earliest stages, do not differ very markedly in their clinical aspects from the empyemata observed in civil practice, which are usually due to the pneumococcus. Nevertheless, it is interesting to observe that even in civil practice, as the records of 574 examinations of pleural exudates in Mount Sinai Hospital show, 133 were caused by a streptococcus. The significance of these figures did not, regrettably, appear to us.

For purposes of study, streptococcus empyema must be divided into three stages: (1) the formative, (2) the acute, and (3) the chronic stage.

I. THE FORMATIVE STAGE

The formative stage is one of the most, if not the most interesting phase of the entire problem. I shall discuss only certain aspects of these phases.

The most striking feature, in contradistinction to cases seen in civil life, is the extremely rapid formation of the pleural exudate. We have seen cases, in which a pronounced exudate developed two days after the very onset of the illness; cases of three or four days' duration are quite common.

The extremely rapid formation of the exudate and its still more rapid infection with myriads of virulent streptococci demand an explanation. It has always seemed to me that such gross infection of the pleural cavity cannot be accounted for by the mere contact extension of the intrapulmonary lesion. My reasoning was based, first, on an analogy derived from a study of peritonitis. Every surgeon with any experience knows that the most pronounced and diffuse forms of peritonitis are due to a rupture of an intra-abdominal viscus. Of course we sometimes see a very extensive peritonitis when there has been no perforation, but these are admittedly uncommon. Second, years ago I made the significant observation that in a number of cases of empyema that came to autopsy there was found a pinpoint perforation of a subpleural pulmonary abscess. This observation struck me forcibly, and I often wondered how common such origins for empyemata might be. For these reasons, I was specially interested in the observation of autopsy results in Camp Lee, and was gratified to note that such perforations were quite frequently encountered. Such origins are furthermore confirmed by other evidences in patients who recover, particularly the development of pleuropulmonary fistulas, as determined by irrigations with Dakin's solution, by X-ray examinations, and by actual inspection at subsequent operation.

The treatment of the cases in this, the formative stage of an empyema is principally that of the underlying malady, and may be termed in very crude language "supportive." Of tremendous importance, and in some cases even of deciding moment, is the question of nutrition. I cannot enter into a detailed discussion of this phase at this place, but refer all those interested to the preliminary report of the Empyema Commission, which was published in the *Journal of the American Medical Association* for August 3 and August 7, 1918.

Whenever there is a suspicion of an exudate into the pleura, its presence and character should be verified by exploratory aspiration. In the early stages this fluid is varicolored and only slightly turbid; occasionally it is sanguinolent. The early turbidity is only partially due to the presence of pus cells, although a number of these can be discerned on microscopic examination; more frequently it is due to the presence of myriads of streptococci. As already stated, the exudate usually teems with streptococci, but, peculiar as it may appear, the streptococci, in spite of the apparently excellent nutritive medium, not only do not multiply, but on the contrary they frequently disappear altogether; and large bottles of exudate may keep sweet for an indefinite length of time.

The most important advice which the Commission offers as regards the treatment of these empyemata during this stage, is not to operate. When the fluid causes a serious embarrassment of the respiration and circulation, as evidenced by dyspnœa, cyanosis, and rapid pulse, it should be relieved very promptly by evacuating it with a Potain or Dieulafoy aspirator. This procedure should be repeated as often as indicated, if necessary even daily. In rare instances this procedure may even be curative. Exception to this rule of non-operative treatment is made only in cases of acute and progressive hydro- or pyopneumothorax which result from the rupture of a large subpleural pulmonary abscess, communicating with a bronchus of considerable size. In these, very prompt operative interference is indicated.

This recommendation of delayed operation is based upon the marked improvement in the mortality statistics since the adoption of this course, and also upon the very high mortality in camps in which operations were undertaken promptly upon the discovery of the infected exudate. These are the practical reasons, but there are sound theoretical grounds as well. At an early stage of an empyema the fluid is free within the pleural cavity, and there are practically none, or only very slight limiting adhesions; in other words, we are dealing with a free hydrothorax, or if one so chose to call it, a pyothorax. If an operation is undertaken at this stage, we convert the only slightly dangerous hydrothorax into the extremely dangerous hyperacute pneumothorax. This brings about the justly dreaded fluttering of the mediastinum with ultimate fixation on the opposite side of the thorax. Therefore, instead of attaining

the desired object, namely, to relieve the embarrassed respiration and heart action, the operation only aggravates it.

There are a number of other, perhaps less important, reasons which favor a delayed operation. The patients are usually very ill from the pneumonia, with its attendant high toxicity, so that even the simple operation of thoracotomy or rib resection, done under local anæsthesia, is badly borne. Miller, in his report, records that many of his patients died promptly after the operation.

Nor can I see any very material advantage in operations which may be termed "intermediate"; for instance the institution of permanent drainage of the pleura by means of a trocar, and subsequent introduction of a catheter. Even with the greatest precaution, air enters the chest sooner or later, with consequent collapse of the lung. Attempts at maintaining a continuous negative pressure have not been very successful.

The after-treatment of early operations is particularly difficult. If a collapse of the lung has once occurred, the organ rapidly becomes adherent in its new location, usually high up in the thorax and close to the vertebral column. If such a patient is fortunate enough to recover from the primary insult, there is usually formed an enormous cavity, which requires a long time and multiple operations before final closure is obtained. Some of the worst cases I have had to treat were such as were operated on in the earliest stages.

It may be argued, that, inasmuch as we have learned that early operation is best for peritonitis, therefore early operation should be advocated for suppurative pleurisies. It must not be forgotten, however, that even if the pleura is anatomically and physiologically identical with the peritoneum, we are dealing in the thorax with certain static conditions, which are entirely lacking in the abdomen; furthermore we must recognize that the functions of the thoracic viscera are vital, and that the cessation of these functions for even a very short period is incompatible with life; a function, the dignity of which is at no time approached by the abdominal viscera.

At this stage the empyema is not the serious element in the illness; it is the pneumonia. In view of these facts I can only close this part of my paper with the urgent admonition *nil nocere*.

If the patient is not operated upon at this stage the exudate loses its seropurulent character and becomes converted into frank thick, creamy pus. Coincident with this conversion a most important change occurs upon the pleural surfaces; adhesions form between contiguous portions of the visceral and parietal serosa at the periphery of the exudate, which collects in the supradiaphragmatic portion of the thorax. In other words, by waiting we have converted the pre-existing free, seropurulent pleurisy, into a closed purulent pleurisy, or empyema, shut in everywhere by limiting adhesions; and thus we have arrived at the second stage.

In anticipation of what I shall have to say later on concerning recurrences, or relapses of empyemata, I shall briefly mention in passing, that in a certain number of cases the process is not quite as simple as this. Adhesions may form in other portions of the thorax, and give rise to abscesses, which may exist singly or in combination with the classical type of empyema. I believe the term "multilocular" empyema, is better than the conventional one of "encapsulated" empyema for these cases, because strictly speaking every true empyema is encapsulated.

2. THE ACUTE STAGE

When this stage has been reached the general condition of the patient has improved to a very marked degree. The temperature is usually lower, and all symptoms and physical signs are improved.

This is the most propitious time for operation. As the lung is adherent at the periphery of the pus, there is no more danger of a further collapse of the lung. The lung is already compressed to the extent of the encapsulated pus, and no matter how large an opening is made, the lung cannot collapse further.

From a viewpoint of therapeutics this part of my paper is perhaps the most important. Trivial as the operation is, each step requires the greatest punctiliousness in its carrying out.

Before the operation a final X-ray or fluor-

oscopic examination is made, in order to determine the most favorable site for the operation.

The subsequent steps may be subdivided under the following headings:

1. *Anæsthesia.* All operations at this stage can and should be carried out under local anæsthesia. Novocaine or procaine in 1 or 2 per cent solution is the anæsthetic of choice. The line of the incision is first injected endodermatically, and from this area the deeper tissues are very thoroughly infiltrated. A simple intercostal incision is preferable. If, however, resection of the rib is considered advisable, it is important to destroy the great sensibility of the periosteum by injecting it separately; a step which can be readily accomplished with a fine hypodermatic needle. On the other hand the division of the rib does not appear to be particularly painful. I believe that with the exercise of care and gentleness a general anæsthesia is hardly ever necessary. In some cases I have attempted conductive anæsthetization of the nerve trunks, but I am not certain that I would ever have been completely successful without any additional local infiltration; failure to obtain a perfect anæsthesia was very probably due to faulty technique.

2. *The superficial incision.* (*a*) *The site of the incision.* In general the site of the incision depends upon the location of the empyema as guided by the physical examination and the X-ray plates. The incision must fulfill two purposes: first, it must afford adequate drainage, and second, it must permit appropriate medication of the cavity. The drainage must be free and unobstructed both in the recumbent and erect posture. In the most common location of empyemata, i.e., those which occupy the lower part of the thorax, the incision is made in the eighth intercostal space, just behind the posterior axillary line. Theoretical objection might be raised to this location by the fact that the ascent of the diaphragm, which occurs in the course of healing of every empyema, might cause a kinking of the drainage tube; but in practice this does not occur. Obviously when the empyema is localized in other portions of the thorax, the incision is made directly over its site and at its most dependent portion.

b. The incision of the extrapleural soft parts. The cutaneous incision should be of ample length (two to four inches, depending upon the amount of adipose tissue present), so that with proper retraction all subsequent steps can be carried out under the guidance of the eye. It is important to remember that the incision made, with the arm hyperadducted, will shift when the dependent position of the arm is restored. If this is not considered, the surgeon finds that his cutaneous incision is not in alignment with the pleural incision. This is a circumstance which is extremely annoying in the after-treatment, and may require a second incision at right angles to the first. It is readily obviated by outlining the incision while the arm is in the adducted position.

3. *The incision of the pleura.* In primary operations proper drainage is obtainable, in about 90 per cent of the cases by a simple intercostal incision of the pleura. This is one of the points wherein I differ from the usually accepted teachings, that resection of the rib is an absolute essential. I have not encountered in a single instance the frequently discussed and greatly feared compression of the drainage tube. In secondary empyemata, however, i.e., those in which one empyema cavity had already been drained, and the healing of which has caused a certain amount of approximation of the ribs, one to two inches of the lower rib exposed in the operation must be resected.

I am in favor of simple intercostal incision, because it is simple, takes little time, and especially because the drainage opening is just as ample as after rib resection. Furthermore, this procedure is seldom followed by necrosis of the ends of the divided rib, a not infrequent cause of persistent sinuses.

4. *Drainage material.* Drainage is made through a single large size rubber tube of rather a stiff quality, and about one foot long. The tube is forced through a tiny perforation in a piece of rubber dam, approximately four inches square, which is fixed to the tube with a thread at a distance from 2½ to 4 inches from its thoracic end, depending upon the thickness of the chest wall. Near the thoracic end one large fenestra is cut into the tube.

The pus is slowly evacuated. I do not irrigate the cavity upon the operating table, not from any fear of the irrigation, but in order not to prolong the operation unduly. If anything appears to be definitely settled in surgery, it is, that under no circumstances should an empyema cavity be irrigated; there is not a surgical textbook, which does not deal with definiteness regarding this point. Explanations are given for this definiteness, which, if critically analyzed, however, will be found not to explain at all. Personally I believe there is a fairly good reason for it, which, however, has not been recognized until now, namely, the frequently existing communications of the pleural cavity with the bronchial tree. As already stated, I do not irrigate the cavity upon the operating table for other reasons; as will be shown, however, I do so very soon thereafter.

The drainage tube is introduced into the thorax so that the fenestra is just inside. This must be gauged with some care, in order to permit the rubber dam to be flush with the skin. No sutures are ever employed, and the external incision is simply packed with gauze. After cleansing the skin, the rubber dam is laid smoothly upon it, and its edges firmly attached by broad strips of adhesive plaster. A dressing is so applied that the tube (temporarily clamped) finds free egress.

Upon reaching the ward a simple combination instillation and suction apparatus is attached to the drainage tube by means of a T tube; at a convenient point a second attachment is made for a bottle to receive the discharges escaping from the empyema cavity.

Once an hour, or more or less frequently as indicated, the syphon part of the apparatus is discontinued by clamping, and the instilling part of the apparatus, a Dakin container, is opened, and the requisite amount of solution is allowed to run in. After the lapse of five minutes the suction apparatus is reopened, and the solution plus secretions syphoned out. The suction is continued until the next period of instillation.

The advantages of this combination apparatus, consisting of drainage tube, instillation apparatus, suction apparatus, and receiving bottle, are the following:

1. All the discharges are collected into the receiving bottle, and in consequence the wound does not require any change of dressings. I usually avoid for one week or 10 days the dressing of patients connected with the apparatus.

2. The cavity is perfectly dry, and there being no retention of pus, fever does not arise.

3. An early opportunity is given to permit a prompt and efficient use of Dakin's solution.

4. The vacuum created aids to a limited extent in the expansion of the lung.

After-treatment. All patients are dressed only once in 24 hours. All the old dressings, including Carrel tubes and "safety valves" (to be subsequently described) are removed and are replaced by fresh ones. All rules as enunciated by Carrel for the preservation of a perfect asepsis are rigidly adhered to, except some trivial details, as will be mentioned.

After cleansing the skin with a dry cotton sponge, followed by a sponge moistened with alcohol, a soft rubber catheter (about 22 F.) is connected with a Dakin container, and is introduced into the empyema cavity. The cavity is thoroughly flushed, the patient being turned from the lateral to the prone position, and vice versa, until the return flow is perfectly clean.

From one to four Carrel tubes are now introduced into the cavity, the object being to distribute them into various portions of the cavity. In very long or irregular cavities we occasionally made use of tubes which were armed with a silver wire stylette. A short drainage tube, with one fenestra guarded by a safety pin, so-called "safety valve," is finally introduced, to permit a free escape of the Dakin solution and secretions.

Right here I might digress for a moment in order to mention, that the rationale of the entire postoperative treatment must be thoroughly understood. One must not fall into the error of thinking that there is something supernatural in Dakin's solution as far as the cure of an empyema is concerned. All that the Dakin's solution can do, or is expected to do, is to sterilize the cavity. This, however, it cannot do if the other surgical principles are neglected.

The vicinity of the wound is protected by sterile vaseline gauze strips. At a distance from the wound the skin is protected from irritation, by the application of a stiff zinc oxide ointment, which was found to be rather more efficacious in this respect than vaseline.

A few small fluffs of dry sterile gauze are placed next to the wound, and a more liberal use of reclaimed gauze, or absorbent cotton, completes the dressing, and is held in place by a firm binder. The Carrel tubes emerge on top of the binder, usually in the vicinity of the shoulder.

Definite instructions are given for the instillation of the requisite amount of Dakin's solution; the quantity depends upon the size of the cavity, and varies from 25 cubic centimeters to 100 cubic centimeters (in general about one-half of the volume of the cavity); it is distributed in equal amounts through all the tubes. Directions are also given as to the intervals between instillations; I have found hourly instillations to be most satisfactory.

The dressing is not touched for 24 hours. The quantities of Dakin's solution used saturate the dressings, but upon inquiry patients did not complain of this seemingly annoying drawback.

Cases which are complicated by pleuropulmonary fistulas, particularly those of large size, cannot be irrigated with large amounts of Dakin's solution, because of the very irritating cough which results from overdistention of the cavity; they tolerate, however, hourly instillations of the requisite amounts in perfect comfort.

Already at the first dressing the discharge has lost its frankly purulent character. Usually the cavity is perfectly dry, as all the discharges find egress through the "safety valve." It is almost marvelous to see the effect of a properly carried out treatment. All pus and odor disappear as if by magic.

In some of the cases of long standing, i.e., those in which the drainage was for a while imperfect, we had an opportunity to observe the character of the discharge. Its consistency was not unlike that of uncooked white of egg, in which there were enmeshed a few grayish or reddish particles. When sterilization became more complete, the discharge lost this appearance, and the irrigation was followed by small hæmorrhages. We interpreted the first finding as due to the liquefying action of the Dakin's solution upon the dense fibrinous deposit upon the pleura; and the hæmorrhages as due to irritation of pleural granulations.

It is most interesting to follow in cases recently operated upon the changes caused by the Dakin's solution upon the infected pleura. When an empyema is operated upon the pleura is found coated throughout by a soft grayish deposit of varying thickness composed of pus and fibrin. As sterilization proceeds, this coating disappears very rapidly, exposing a smooth glistening surface; particularly upon the pulmonary side, it is so thin, that the underlying lung tissue becomes readily visible and recognizable.

Twice a week smears and cultures are made from the cavity. When very low counts are obtained, these are made daily. When sterility is reached and is continued for several days, all tubes are left out and the Carrel-Dakin treatment is discontinued. Prompt and permanent healing is the result in many instances; in one case in 13 days.

In a few cases I have attempted a plastic closure of the fistulous opening, but the results attained did not warrant me in continuing this practice. Moreover I do not see any particular indication for doing so. If the cavity is not sterile a premature closure of the wound is sure to be followed by an infection, with subsequent breaking down of the suture line; if on the other hand it is sterile the wound closes so promptly, that even the trivial operation of refreshing the edges and suturing is uncalled for.

Considerable importance is ascribed by most surgeons to the use of blowing bottles in order to encourage the lung to expand. I will not deny that this device may help, but I have found that most patients, after the first enthusiasm of a new toy, discontinue its use. I have found more benefit in properly and systematically carried out light exercises; I encourage particularly light work around the wards, which keeps the patients interested and amused.

In the early part of my paper I have already emphasized the importance of keeping up the nutrition of the patients.

3. THE CHRONIC STAGE

In this group I would place only the following cases:

1. Cases which do not heal within a "reasonable" time.
2. Cases of recurrence within the old empyema cavity.
3. Cases, in which a second pus focus is discovered, at some distance from the original focus.
4. Cases of pus collections within the parenchyma of the lung.
5. Cases of bronchocutaneous fistulas.

I. *Cases which do not heal within a "reasonable time."* The word "reasonable" permits a wide latitude in its interpretation. My views regarding the manner in which an empyema heals have undergone a very radical change, since my experience in the military service. I conceived that healing occurred only by a process of obliteration of the pleural cavity, due to adhesions resulting from a granulomatous change in the pleura. Only when the entire affected pleural surfaces became adherent did the drainage opening close. When a cavity still persisted I observed that the opening showed no tendency to close.

Since this epidemic has been in existence I have been able to observe the following variations:

1. The far-reaching observations at the War Demonstration Hospital of the Rockefeller Institute have taught us that empyema cavities can be rendered bacteriologically sterile by means of the Carrel-Dakin treatment, and the drainage opening can then be closed by secondary suture. In a fair percentage of cases union with definite closure occurs. I am not aware that the progress of healing has as yet been described in detail by the originators of the method, but from personal observations, I have found that a certain amount of exudation occurs, though not to the full extent of the cavity. In the course of time this secondary exudate becomes absorbed, and is replaced by the slowly expanding and adhering lung.

2. In a few cases of healed empyema I have found on casual physical and X-ray examination, a very definite closed pneumothorax, usually at the site of the original empyema; in one case at some distance from it. I watched these cases with great care, and certainly also with fear, but found that the expected reaccumulation of pus did not occur; on the contrary, the cavity disappeared within about a month's time, the lung expanded and completely replaced the pneumothorax.

3. We also had the following very unusual experiences. Originally they were cases of empyema, which secreted large amounts of pus; when they came under my care, however, there existed only a small sinus, which led into a large cavity. The peculiarity of these cases lies in the fact that in spite of little treatment, these sinuses persisted for a long time, without any apparent discharge, or at most a few drops in the course of a week. Ultimately, however, these cases closed up completely, and remained closed to date.

4. Finally we have made the following observations. We have seen cases that were long under treatment with Dakin's solution. No hæmolytic streptococci were found for a long time. The cavities were X-rayed periodically, found to be smooth and simple, and while at the beginning a certain amount of concentric diminution was noted, these cavities finally remained stationary. In civil practice, such cases would indicate some variety of secondary operation. However, in view of the three possibilities just related, a chance was taken, and all treatment was discontinued. We were surprised to see such cases heal permanently.

It is seen, therefore, that in addition to the hitherto known, so to say, the classical method of the healing, there exist at least four other methods. It is on this account that I find difficulty in exactly defining the words "reasonable time." In general I would say that in the light of our present knowledge, I would exclude from this group simple cases, in which the pleura is smooth, in which the cavity is not of extreme size, and cases that are not complicated by side pockets or lateral sinuses; in other words, I would not include in this group any empyema cavity which is

amenable to treatment by the Carrel-Dakin method.

If we examine the cases which cannot be remedied by even long-continued treatment by the Carrel-Dakin method, we will find the following:

1. Cases which are complicated by large pleuropulmonary fistulas.
2. Cases with retained foreign bodies.
3. Cases with side pockets.
4. Cases with lateral branch sinuses.
5. Cases with necrotic ribs.

II. *Cases of recurrence within the old empyema cavity.* Broadly speaking these cases are always a reflection upon the surgeon in attendance, for it means that drainage and antiseptic treatment of the cavity have been discontinued prematurely. To my mind such cases are particularly liable to occur if the sinus or external incision is closed operatively, because not infrequently good judgment is supplanted by haste. Even the strictest precautions, such as smears and bacteriological cultures, do not always furnish a reliable guide to the presence or absence of microorganisms existing within the empyema cavity. It again only proves the absolute value of the well recognized axiom in medicine, that a negative proof is no proof. That it can occur also in those cases which have been allowed to close spontaneously, is well proven by the fact, that we encountered re-collections of fluid in eight of our cases. Six of these had definite collections of pus, containing streptococci; two were found to contain sterile serum. For simplicity's sake I have grouped them all under one heading, though it is evident that the last two were milder and simpler, and disappeared spontaneously.

III. *Cases in which a second pus focus is discovered at some distance from the original empyema.* In a previous portion of my paper I have already discussed the manner of formation of an empyema cavity. Occasionally encapsulation of the pus occurs elsewhere than in the supradiaphragmatic portion of the thorax, and as a result we may have two or more separate empyema cavities. At the time of the first operation usually only one, the larger and lower one, is opened. Sooner or later, however, it is noted, that the patient does not improve; and after physical and X-ray examination, sometimes even long after the main cavity is healed another pus focus is found. In only one case did we find that the second pus focus broke through into the primary cavity; usually it requires a second independent operation for drainage; their most frequent location was in front, overlying the apex of the lung, and toward the apex of the axilla.

Incidentally I may mention that at postmortem examinations, soon after my arrival at Camp Lee, we frequently encountered small encapsulated collections of pus, which were located behind the costal cartilages, approximately between the anterior sharp margin of the upper lobe and the mediastinum; but we have never seen such in any patient who survived.

IV. *Cases of pus collections within the parenchyma of the lung.* As already stated in a preceding portion of my paper, I am firmly convinced that most, if not all, cases of empyema have their origin in one or more small subpleurally situated pulmonary abscesses, which perforate into the pleural cavity. I do not refer to these at this point. I refer now to an encapsulated collection of pus within the parenchyma of the lung, not connecting with either the pleura or with a bronchus of appreciable size. In the former case it usually evacuates itself into the pleura, in the latter through a bronchus. The recognition of encapsulated abscesses of small size is very difficult on ordinary physical examination. Lately Lieutenant Stevens of the Empyema Commission has demonstrated by means of stereoscopic X-ray plates, that certain findings are quite characteristic of most pulmonary abscesses. These are the gradual formation of interstitial lung markings, usually definitely radiating throughout the lung tissue from the central focus of infection, and, if the abscess be near the periphery a corresponding thickening of the pleura over it. It is surprising that these abscesses are not encountered more frequently in the chronic stage; I believe this is due to the fact, that most of these patients succumb in the acute stage.

V. *Cases of bronchocutaneous fistulas.* Bronchocutaneous fistulas must not be confused

with the so frequently mentioned pleuropulmonary fistulas. Their etiology is of course the same, namely, a rupture of a subpleural pulmonary abscess. The difference between the two lies in the fact, that whereas pleuropulmonary fistulas are comparatively easy to cure (in fact not infrequently they close spontaneously), bronchocutaneous fistulas never close spontaneously, and usually require rather complicated procedures before a cure is obtained. The fistula usually communicates with a bronchus of some size. Their occurrence is readily explained by an adhesion of that part of the lung which bears the fistula; finally the mucous membrane of the bronchus grows outward and the cutaneous epithelium grows inward, until the two meet, and a so-called "lip fistula" forms. We have had cures in three cases of this nature.

The diagnosis of some of these conditions is self-evident; in others the diagnosis is exceedingly difficult. Constant care and attention is required to avoid numerous pitfalls and surprises. It is not within my domain to discuss the various physical signs; there is one point, however, which has struck me forcibly, and which I have not seen mentioned in any one of the reports published from various camps. It may be accepted as a proven fact that when a patient is healed and cured of his empyema, the cure is to all intents and purposes perfect. Such a cured patient feels well, he eats well, and he sleeps well; furthermore he has no fever, and he gains enormously in weight; in fact many of the patients not only attain their normal weight, but even go beyond it. In the presence of a slight evening rise of temperature, when accompanied by a loss of weight, one should not permit himself to be deluded with the erroneous and yet frequently prevailing idea, that the patient is suffering from a latent tuberculosis. We at least have not found tuberculosis in a single instance. When these symptoms are present a thorough physical examination is rigidly indicated. At some point in the thorax a suspicious area will be found, which upon aspiration will yield pus; when this abscess is evacuated all symptoms disappear promptly.

In draining cavities most important information can be obtained as regards their outline, extent, and volume by means of stereoscopic X-ray plates, after injection with some substance opaque to the rays. We have tried numerous substances, particularly sodium and potassium iodide, 15 per cent neutral thorium nitrate solution; barium; and finally have arrived at the conclusion, that when "properly used" bismuth subnitrate or subcarbonate gives the most satisfactory results. I have purposely availed myself of the expression "properly used" in discussing this phase of the subject, because in addition to the well known toxicity of bismuth salts, my co-worker upon the Commission, Lieutenant Stevens, found another very important drawback, namely, that in the form as originally used, i.e., a vaseline paste, it frequently failed to give a correct picture of the cavity. This is due to the fact that pastes, even if properly heated, congeal so rapidly during the process of injection, that the air contained in the cavity cannot be displaced outward, but is compressed into the uppermost part of the cavity, and forms an effective barrier to the proper filling of the cavity. On several occasions we found upon the operating table, instead of the expected short sinus, as outlined with bismuth paste, a sinus several inches longer. The inefficacy of bismuth pastes was clearly demonstrated upon the re-examination of several cases under our observation. Lieutenant Stevens found a solution of the problem by substituting sterilized cotton seed oil for the vaseline. A special report upon the subject is now in preparation; suffice it to say for the present, that since using this method we are no longer troubled by deceptive pictures. Incidentally I believe, that the danger of bismuth poisoning is thus not only minimized, but practically excluded, as the oil mixture escapes at once.

X-rays are particularly useful in exposing conditions in an empyema cavity the existence of which renders them difficult to sterilize with Dakin's solution. I refer especially to branch pockets, sinuses, and pleuropulmonary fistulas.

COMPLICATIONS OF EMPYEMA

The local complications of an empyema are readily recognized, and readily coped with. I maintain that an ordinary empyema has no

distant complications. Positive blood cultures in empyema are so exceptional that one is forced to the conclusion that complications which occur in the course of an empyema, such as endocarditis, pericarditis, joint infections, peritonitis, etc., are due not to the empyema, but to the pneumonia.

TREATMENT OF CHRONIC CASES

I have purposely entered into the minutest details in the description of the treatment of the acute stage of the disease, because I am convinced that if the directions given are carefully followed, chronic cases will occur less than we have been accustomed to meeting them, and if they do occur, their treatment will also be materially simplified. For the sake of completeness permit me to begin with those cases which I did not classify as chronic, but which custom has hitherto placed in such a category.

1. *Large empyema cavities.* It is difficult to connote what we mean by the term "large." We must recollect that extremely large cavities are always the result of a mistake; namely, a too early operation, because adhesions have not had time to form. Our experience has also led me to believe that even cavities of very large size, if properly treated, and for a sufficient length of time with Dakin's solution, will eventually diminish in size. I believe this diminution depends upon several factors; upon the elevation of the diaphragm; the approximation of the ribs to one another; and finally upon the solvent action of Dakin's solution upon the dense fibrous deposit which covers the visceral pleura, thereby permitting a re-expansion of the lung. If the cavity has diminished to its minimum as ascertained by means of measurements and X-ray, and has become stationary; and furthermore if the cavity has been sterile for a long time, a chance may be taken to permit a closure of the sinus, by simply discontinuing all treatment. If the outline of the cavity is so complicated that sterility is not obtainable one of the major operations is indicated. My own preference is for a simple Schede operation, resecting all of the ribs which form the roof of the cavity.

There are several minor points regarding this operation which are worthy of being alluded to. In contradistinction to similar cases in civil life, these patients are usually in the very best condition, and stand a general anæsthetic perfectly well; in fact their condition, even after the resection of 5 or 6 ribs, is so good that they insist on leaving their bed upon the day succeeding their operation. A single straight incision over the greatest diameter of the cavity usually gives ample exposure. I found some difficulty in my earlier cases in the after-treatment, when parts of ribs lying in front of the scapula were resected, because of the subsequent tendency of the scapula to cover the opening which has been made. Therefore, I have lately carried my incision backward between the internal scapular and vertebral lines. This made the operative procedure somewhat more tedious, but it rendered the postoperative treatment so much easier that I recommend this step very highly.

Some difficulty is encountered in excising the rib which has been resected at the first operation, on account of grotesque spur and ring formations, and fusions with the ribs on either side.

The intercostal tissues are ligated *en masse* at both ends; the intervening portions are excised. All ribs are resected subperiostally; all the tissues, particularly the greatly thickened parietal pleura, are excised. We had attempted in some cases, particularly favorable for the procedure, to excise the fibrous deposit covering the visceral pleura (Delorme), but contrary to our experience in civil life with pneumococcus empyema, we found it difficult to remove this deposit without causing excessive trauma to the underlying lung. Such trauma is undesirable because it prevents the early application of Dakin's solution. In a few cases I made criss cross incisions of the pleura (Ransohoff), but have not noted any marked inflation of the lungs. In another series of cases I have merely curetted the fibrous deposit, and believe that I have seen a more rapid formation of granulations.

The wound is simply packed, and no sutures are introduced. At the first dressing, from 4 to 6 days after operation, the tampons are

removed and treatment with Dakin's solution is carried out until final healing occurs.

2. *Treatment of chronic empyema sinuses.* The chronic empyema sinuses may be divided into two classes: (a) those that are sterile, and (b) those that are infected.

a. Sterile, sinuses heal permanently upon discontinuing all treatment. Only in rare instances does a reaccumulation of pus or serum occur.

b. Infected sinuses. In the treatment of these it is absolutely necessary to find the reasons for the infection. The most frequent causes and their treatment are the following:

a. Accidentally lost foreign bodies such as sponges, drainage tubes, rubber dam, etc.

b. Necrotic ribs.

c. Branch sinuses and irregular side pockets of the main sinus, which can not be reached perfectly for an adequate treatment with Dakin's solution to permit sterilization; these usually require a Schede operation for a perfect exposure.

d. Pleuropulmonary fistulas. As already pointed out in a previous portion of my paper pleuropulmonary fistulas are very common; most of them are small and heal quite readily and spontaneously during the acute stage. If not they are usually of large size, and connect directly with a bronchus. The non-healing is due to two conditions: first, because the bronchial epithelium has grown outward and lines the termination of the channel; and second, because the mouth of the sinus is continually held open by the dense fibrous deposit upon the visceral pleura. Their treatment is rather difficult; I have succeeded in most cases with the following procedure. An adequate exposure of the mouth of the sinus is an absolute essential, and is readily obtained by means of a Schede operation. The lung is then very thoroughly mobilized at the margins of the cavity; a step which, in spite of the density of the adhesions, is quite readily done, and with some care without undue traumatization of the lung. This simple mobilization of the lung is, I believe, the most important part of the operation, as it allows of approximation and healing of the margins of the fistula. In a few cases I have excised a small wedge-shaped piece of the lung surrounding the fistula, and closed it by a few catgut sutures.

The primary dressing of these cases is very important. I lay considerable stress upon the fact that no gauze should come in contact with the fistula. I dress these cases by interposing between the fistula and the gauze a sterilized piece of rubber dam. In many cases I have found the fistula closed at the first dressing, 6 or 7 days later; if not, I employ dressings saturated with dichloramine-T.

3 and 4. *Pus collections at some distance from the original empyema and reaccumulations of pus in the original cavity* usually require costatectomy. An intercostal incision as in primary empyemata is insufficient, because the healing of the first empyema has caused too much approximation of the ribs for adequate drainage.

5. *The treatment of lung abscesses* opens up a chapter almost foreign to the theme under discussion; I shall mention only one important point, namely, that I believe that in these cases a simple adequate incision and drainage is sufficient, and that owing to the already existing massive adhesions between the visceral and parietal pleura, this is usually quite a simple procedure.

6. *The treatment of bronchocutaneous fistulas* is a somewhat more difficult procedure. It requires adequate mobilization of the lung, usually obtained by means of a Schede operation, followed by excision of entire fistulous tract, with or without subsequent suture.

The objectionable feature of the treatment of all cases complicated with a pulmonary fistula, except occasionally in the acute stage, arises from the fact that they do not permit of treatment with Dakin's solution for self-evident reasons. In these cases, at least until the fistulous portion has closed, I have used quite successfully dichloramine-T in small quantities, and have found it a good substitute, though not as satisfactory as Dakin's solution.

It is apparent that the subject of empyema is by no means as simple as it has hitherto been regarded. I have merely skimmed it superficially, but I shall feel that I have been amply repaid for the preparation of this paper, if I have stimulated further study of the many remaining unsolved problems.

EMPYEMA

Analysis of 70 Cases at Base Hospital, Camp Jackson, South Carolina

By CARL EGGERS, M.D., New York
Major, Medical Corps, U. S. A.

As in many of the other cantonments so at our hospital the subject of empyema has been one of the important surgical conditions that has come up for consideration. Due to the frequency of its occurrence and its high mortality, it has attracted considerable attention and the interest manifested in it has been enhanced by the widely different results that have been reported. The rapidly fatal outcome following early operation on a number of patients showed us that we were apparently dealing with a condition somewhat different from what we had ordinarily considered empyema at home and that therefore different treatment was required. Upon investigating more carefully it was found that we were confronted with two different conditions, one an empyema following the usual lobar pneumonia, the other following secondary pneumonia. The object of this paper is to demonstrate that the widely different results obtained and the various opinions expressed are due to this difference in cases. We will show that those cases following a primary pneumonia, usually lobar in character, and caused by the pneumococcus, give results in the army hospitals as good as those obtained in civil life, while the empyema following secondary pneumonias is extremely severe and has a high mortality. We were not, as some people believed, dealing with a new disease, but with conditions that are less frequent in civil practice. For instance, measles which furnished a large number of pneumonias is rather infrequent in adult life under ordinary conditions, or at least we do not see any large number of cases at one time, but it is a common and severe disease in camp. Other diseases also, such as tonsillitis, bronchitis, and influenza are apt to be more virulent when occurring in epidemic form; they may be of streptococcic origin and the pneumonia following is often bilateral bronchopneumonia. It is these various groups that have furnished our severe empyema cases with a high mortality. Our ideas in regard to the treatment of empyema following primary lobar pneumonia have not undergone changes, but in regard to those following secondary pneumonia, we have been impressed with the influence of the antecedent disease on the course, and we have learned that the results obtained depend very much on the type of organism producing the infection and also on the procedure followed in treatment. Apparently there is a certain time when conservative methods should be followed and a period when radical surgical methods should be resorted to.

This paper is based on the study of 70 cases that have come to operation in the ten months, period from November 1, 1917, to September 1, 1918, up to about the time of the influenza epidemic, but not including any of the latter cases. The subject is presented from a surgical standpoint. No attempt will, therefore, be made to go into bacteriology or pathology in detail. During the early part of the period covered, our laboratory was in a stage of development and was overwhelmed with a meningococcus sepsis epidemic. As a result, bacteriological examinations of pneumonia and empyema cases were not made as frequently as is now the case. However, a positive finding is present in most of the cases and in the few in whom none was made, we have grouped a patient with the class of cases to whom he clinically corresponds.

The frequency of the disease in the different months of the period is illustrated by the accompanying chart, which shows it to be most common in the winter months when acute respiratory diseases are at their height (Chart 1).

ETIOLOGY

The statement is frequently made that men of the South are more prone to pneumonia and empyema than the Northerners, and again

that those from rural districts are more often affected than those from urban districts. In a given camp this statement is difficult to prove or disprove. Our troops, for instance, were nearly all from Southern States and had led an outdoor life. It is only by a comparative study of the statistics from various camps, available at the Surgeon General's Office, that definite conclusions in this respect can be drawn. Of our 70 cases, 64 or 91 per cent were from the Southern States and 52 or 74 per cent were farmers or laborers leading an outdoor life. Though many of our soldiers were former cotton mill workers, who in appearance were rather poor physical specimens, not one of our empyema patients was drawn from that class. The frequency of malaria and hookworm infection and the incidence of pellagra in the South have been cited as predisposing causes. Their rôle is a secondary one in that they lower the general resistance of the patient. Ten of our patients showed hookworm, though not all had their fæces examined, and two had malaria in a chronic form. It does not appear that the percentage of colored soldiers affected with empyema was higher than that of the whites. Of our 70 cases, 57 were white and 13 colored.

In considering the exciting causes it is found that pneumonia preceded the empyema in nearly every case. Many of them were primary lobar pneumonias, while the majority were secondary to some acute infectious condition.

These secondary pneumonias are divided as follows: 23 following measles; 7, bronchitis; 3, influenza; 2, tonsillitis; 1, otitis media; 1, meningitis; 1, abscess of cheek; 1, tonsillectomy; 1, following an anæsthetic; and 3 following typhoid inoculation.

The incidence of pneumonia following typhoid inoculations is of great interest. Patients usually state that they have had a cough, which became aggravated immediately after the injection. The relation between typhoid inoculations and acute respiratory diseases merits investigation.

We had only three cases that were originally diagnosed as pleurisy. Whether they developed a pneumonic process before going on to empyema formation is doubtful. In these

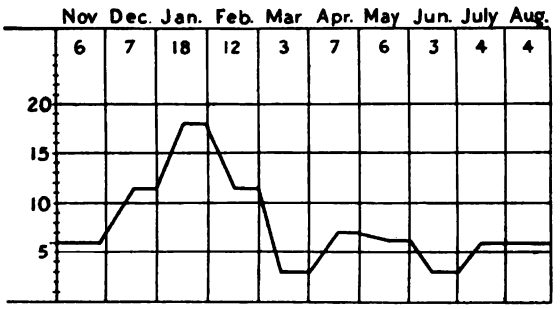

Chart 1.

cases the question may well be raised whether there was not some lung focus present that ruptured externally and produced the empyema. Upon going into the history of these so-called primary pleurisies it is found that they have not been well for some time, that they have had a cough and a cold in the chest.

Among either groups of the above-cited cases may be those with a general sepsis, in which the localization in one or both lungs and a subsequent empyema are but manifestations of a general septic process. Other parts of the body may likewise be affected and play an important rôle in the course of the disease, they may even be the more important factor.

TYPES OF EMPYEMA

If one sees a large number of these patients he is struck with the fact that they differ a great deal. Some correspond more to the type which we have been accustomed to see in civil life, others are of a degree of severity that leads to a fatal issue in a short time. The noticeable fact attracting attention in many of the patients is the early formation of large amounts of fluid. This fluid is usually thin, dishwater like and contains flocculi of fibrin. Because they differ in their course and prognosis and in order to facilitate study and to bring out the essential differences between the various types of empyema we have divided them into those following: (1) primary pneumonia, (2) measles pneumonia, (3) other secondary pneumonias, and (4) primary pleurisy.

Another classification based on the bacteriological findings, allows us to group them into those caused by the pneumococcus and those caused by the streptococcus. Other varieties

of organism we did not encounter in our 70 cases. In the final analysis this classification is the more important one because when looking over the entire series it is found that cases due to the pneumococcus, although more severe in those following a secondary than in those following a primary pneumonia, give about uniformly good results, while the prognosis in streptococcus infections is always grave and the complications many.

1. *Empyema following primary lobar pneumonia.* It is not always possible or at least not easy to differentiate strictly between primary and secondary pneumonia, because at the time when empyema and pneumonia are most frequent very many people have some respiratory affection. However, we have put into this class all those cases of lobar pneumonia that had a sudden onset though some of the patients may have had a cough preceding it. Table I given below embraces 24 cases. The process involved either one or several lobes or even both sides, in some cases simultaneously, in others successively. With the exception of two cases, one of which was due to the streptococcus, the other to a mixed infection, they were all caused by the pneumococcus.

It will be seen by looking over this table that fluid was usually found within two or three weeks after the onset of the pneumonia and that operation was performed as soon as the presence of pus was demonstrated. In five cases, 6, 8, 9, 16, and 20, the empyema was of the small encapsulated variety. This accounted for the late finding of pus in two of them. One patient had been returned to duty, Case 16, apparently well, and came back about three months after the onset of his pneumonia with a small encapsulated empyema, apparently interlobar in character.

Complications in this group have been few. There were three patients with an otitis media, Cases 3, 12, and 14. Two patients, Cases 12 and 23, had a parotitis that did not go on to suppuration. Pericarditis was diagnosed in Case 20 and was found at autopsy in Case 2. A few patients had superficial abscesses and one of them, Case 22, had a large abscess of the rectus abdominalis resembling a full bladder, and another one of the back. The former was sterile while the latter contained pneumococci.

Three cases of this group ended fatally: Case 15 had a positive blood culture of Type I pneumococcus. He died with symptoms suggesting meningitis. Case 18 died 11 days after the onset of his disease and one day after operation. During the latter, pockets were broken up with the aid of the finger, and it is possible that this had something to do with the fatal outcome. The fact that it occurred so soon after would indicate this. It certainly does not seem wise to carry on extensive manipulations when operating for empyema especially not early in the disease. An autopsy was not performed in these cases.

Case 2 died of a streptococcus sepsis 21 days after the onset of his pneumonia. Autopsy revealed consolidation of the entire left lung and an extensive pericarditis with serosanguinous effusion.

It may be stated that empyema following primary lobar pneumonia which attacks the patient while in good health, not weakened by antecedent disease, usually runs a shorter course than the other varieties. In the list given in Table I the average length of time from admission to the hospital until the patient returned to duty was 2 to 3 months. The few patients who were confined a long time had extensive secondary operations performed. They will be described in detail further on.

2. *Empyema following measles pneumonia.* These cases have been put into a class by themselves because they are usually very sick and the mortality is higher than in the other varieties. The group comprises 23 cases, 17 of which had a broncho and 6 a lobar pneumonia preceding the empyema. Thirteen cases were caused by the pneumococcus and ten by the streptococcus (Table II).

The complications in this group have been many and in a few cases they have contributed toward a fatal outcome. Ten patients developed a suppurative otitis media, two of them bilateral. We encountered several superficial abscesses and one deep abscess of the rectus abdominalis. There was one extensive cellulitis of the back taking its origin from the empyema wound, and another one of the neck leading to suppuration and rupture into the

pharynx. There was one patient with a peritonitis and one with a non-suppurative parotitis. Patient 35 deserves special mention. He was first taken sick on November 21, 1917, with mumps. On December 19, 1917, he developed measles and on the 22d a bilateral bronchopneumonia. The following day symptoms of meningitis manifested themselves. These two diseases, pneumonia and meningitis, then ran their course. For the latter he received intraspinal and intravenous injections as practiced at this camp leading to a complete cure. The pneumonia became complicated by a right sided empyema showing a pure culture of streptococci In spite of this he made a good recovery and was returned to duty, March 31, 4 months after the onset of the mumps.

The mortality was high, for in 9 patients, or 39 per cent, a fatal outcome is recorded. All of these cases had a bronchopneumonia, 6 due to the streptococcus and 3 due to pneumococcus. It will be noted that 6 of the patients who died were operated on early, from 2 to 9 days after the onset of the pneumonia. Of the 3 who died after a late operation, 2 had extensive lesions and really succumbed to a general sepsis. Those who died after an early operation died very promptly, one on the day of the operation, 3 on the following day, 1 two and 1 four days later. This to us has seemed of some significance and we have tried to discover the reasons for it, which will be considered somewhat in detail under treatment.

Case 42 had a double bronchopneumonia, left empyema, and pericarditis with effusion.

The course has usually been a long one for, regardless of the time following the onset of the measles or pneumonia, the average stay of patients in the hospital was 3½ to 4½ months.

Altogether it must be said that measles pneumonia is an extremely severe disease. Several of the patients had been discharged to duty after measles and were returned with a pneumonia. Others were sent on long journeys before they were well. The frequency of pneumonia in patients so treated would indicate that exposure has a great deal to do with its development after measles. To guard against it, therefore, and in order to prevent empyema, patients should be put to bed early. They should be kept warm and well protected and in the hospital long enough to be sure of complete cure.

3. Empyema following other secondary pneumonias. This group of 20 cases includes all those patients who developed empyema secondary to pneumonia following upon some other acute infection, aside from measles. Simple cough we have not considered as an etiological factor, but rather those conditions that made the patient sick and were then followed by a pneumonia. The reason is that the vitality of these people is frequently undermined and the pneumonia developing is more apt to be bronchopneumonia and frequently is bilateral in character. Of this series fourteen followed lobar and 6 bronchopneumonia. Fourteen were due to the pneumococcus, 4 to the streptococcus, and 2 were mixed infections of both these types.

It will be seen in surveying Table III that the course of the disease varied considerably. Some patients recovered promptly, while others had a prolonged convalescence, necessitating a stay in the hospital of from 4 to 5 months. The complications were not many but they were extremely severe and contributed considerably to the fatal terminations. Of the four streptococcus cases the only one who recovered was one treated by repeated aspirations and late operation. Another one, Case 48, treated in the same way, was doing well and was apparently on the road to recovery when he developed a suppurative peritonitis and a general sepsis and died. Both patients with a mixed infection died. Of this series 7 cases ended fatally.

The autopsy records of 5 of them are given below:

Case 50. Lobar pneumonia, bilateral, pleuritis right, 400 cubic centimeters of fluid; empyema left; old tuberculosis, right apex; luetic aortitis; luetic cirrhosis of liver; fibrous perisplenitis.

Case 51. Empyema, right; cornification of right lung; numerous abscesses of body; acute endocarditis; infarcts of spleen, and infarcts of kidneys.

Case 52. Pyopneumothorax, right; abscess right lung; pneumonia, right lung.

Case 60. Lobar pneumonia, left; encapsulated pus pocket, left, due to perforation of lung abscess; empyema, left.

CASE 62. Empyema, right; pleurisy, left; pneumonia, left upper and right lower lobes; thrombosis, left lateral sinus.

4. Empyema following primary pleurisy. We had only 3 patients who can be put into this class. That a condition exists in which the pleural involvement is apparently the chief factor must be conceded. These 3 patients had not been well for some time before the intrathoracic condition assumed alarming proportions and made them seek medical aid. When they came under observation they were very sick and prostrated.

CASE 69 illustrates a type in which there is apparently first an involvement of the pleura and a secondary invasion of the lungs. Eight days after the onset of pleurisy and after a rather benign course, there was severe and extensive pulmonary involvement which in turn was followed by empyema.

CASE 70 was one of those who was prostrated early. He was admitted on the day of the acute onset, was cyanotic and dyspnœnic, and his chest was filled with thin turbid fluid. An immediate operation was deemed advisable and was performed. The course was extremely severe, an acute pneumothorax supervened, and a cellulitis spread from the edges of the wound, involving practically his entire trunk. The distress of the pneumothorax was somewhat alleviated by packing the opening from day to day. Whether in this case aspiration at first would have had the desired effect is questionable. He made a good recovery.

DIAGNOSIS

Though according to textbooks the detection of fluid in the thoracic cavity should be quite easy, it is by no means always that. It is by the careful examination of the chest, done daily and recorded on the chart that the presence of fluid is first suspected. By this systematic work, the variation in signs from the previous day or days will be noted. Displacements of the heart are of great value. By having had the patient under observation for some time, one is familiar with the organism causing the infection and can be on the lookout. It is important that the presence of large amounts of fluid be detected early and that it be submitted to bacteriological examination, because one is guided in the treatment largely by the laboratory findings. It is interesting with what rapidity the fluid sometimes develops. However, at times all physical signs fail, and it is familiar to those who do much of this work how deceptive signs may be. It is probably not putting it too strongly when we state that fluid in the chest may give the exact physical signs of a pneumonia and *vice versa*. Therefore when a suspicion of fluid exists, whether early in the disease or because the lung condition does not clear up as promptly as it should, one should never hesitate to use the aspirating needle. If properly introduced no harm can result. It should be of sufficient length and caliber and be introduced attached to the syringe with the piston pushed down. In this way the entrance of air is prevented. There is no place of selection for the exploration, it must be done wherever the fluid is suspected.

If these means fail, the X-ray has proved of great value, particularly in the smaller encapsulated varieties of empyema. In doubtful cases, therefore, an X-ray should be made, preferably a stereoscopic, and if a focus is found, exploratory puncture should be done under guidance of the plate. The fact that two of our patients, Cases 16 and 67, were sent to duty after their pneumonia and later returned for an encapsulated empyema might suggest that all pneumonia patients should be X-rayed before being discharged.

CLINICAL CONSIDERATIONS

In order to treat empyema intelligently and to get the best results it is essential that the physiology and the mechanics of respiration be understood. We must know what happens if a normal pleural cavity is incised and left open. A condition of so-called open pneumothorax will ensue which means air will enter from without and in time cause the lungs to collapse. In addition to that this now positive pressure in the pleura will force the mediastinum over to the other side and embarrass thereby not only the respiration, but also the circulation. It is for this reason that an open pneumothorax is so much feared on the battlefield.

Now these factors play a rôle and an important one, in the treatment of empyema. To appreciate this properly we must visualize to ourselves what an empyema really is. Is it to be considered a collection of pus only, the residue of an inflammatory process, in

other words, a simple abscess, or is it an exudation fluid accompanying an acute inflammation and existing simultaneously with it? The answer to this is that it may be either, at the time that we are called to see a patient and it is up to us to determine which it is, for on that depends the treatment. In the former case when it is simply an abscess of the pleura, surrounded by an abscess wall, the treatment is manifestly quite simple, for incision followed by evacuation of the pus will give prompt relief and no embarrassment of the respiration will ensue. On the other hand, if the fluid present is accompanying an active inflammatory process of the pleura and the underlying lung, the conditions are entirely different. No protective abscess wall has formed, no or few adhesions are present, and if such a thorax is opened we are confronted with all the dangers of an open pneumothorax. The fluid will, of course, be evacuated but its place is promptly taken by air, and this air, representing a positive pressure, will bring about collapse of the uninvolved lung and produce displacement of the mediastinum. The question then arises, how are we to apply this knowledge to the treatment of an individual case? In order to do that we must know certain other facts. Clinical observation and studies at the autopsy table have taught us that pneumococcus infections of the pleura have a tendency to form pus early and that this pus becomes walled off early. We further know that in a pneumococcus lobar pneumonia the pleural involvement is usually confined to the involved portion of the lung. In a pneumococcus bronchopneumonia the conditions are somewhat different but the general characteristics of the organism remain the same. In these cases, therefore, operation is indicated as soon as the presence of pus is demonstrated.

In streptococcus infection of the lung with secondary pleural involvement on the other hand conditions are different. The entire pleural layer, both visceral and parietal, often becomes involved very rapidly and a profuse exudation of serum takes place. There is no early tendency to walling off and no protective barriers have formed. This extensive involvement is partly due to the fact that many of the streptococcus pneumonias are secondary pneumonias, they are usually bronchopneumonias with various small foci scattered throughout the lung causing a secondary involvement of each overlying portion of the pleura. Suppuration of this fluid, meaning by that a change to actual pus, occurs rather late, often only after several weeks have passed. However, with the change of fluid to real pus protective barriers form and it is then safe to operate.

Aside from the danger of pneumothorax, there is one other very important factor that must constantly be borne in mind; namely, the condition of the lungs at the time that operation is contemplated. This applies to the lung of the infected side as well as that of the opposite side. These patients are all very sick and we must be careful not to do anything that will aggravate their condition. Opening a thorax while the pneumonia is still active will increase the strain on both the respiration and circulation. Here again there is a marked difference between the two varieties of infections. We know that pneumococcus lobar pneumonia usually runs a short course. When we are, therefore, called in to see such a case on the tenth or fourteenth day we know that the pneumonia has probably cleared up, and if pus is found we know it is safe to proceed with the operation. With a pneumococcus bronchopneumonia a little more care is necessary and it may be well at times to postpone the operation a few days, perhaps doing an aspiration in the meantime.

In the streptococcus pneumonias we usually find numerous foci of infection; one may clear up while another forms. Several lobes or even both sides may be affected simultaneously or successively. Opening such a thorax will diminish the patient's chance of recovery, for a pneumothorax will form as stated above, and there will be collapse of all uninvolved portions of the lung. And as frequently the other side is also partly involved we increase the strain instead of decreasing it.

What then can be done to benefit these patients, what is the correct procedure to give them the best chance for recovery? Unfortunately some of these patients seem doomed from the beginning; they are simply over-

come by the severity of the infection, and there is nothing known to us at present that will save them. The first temptation is to operate at once. As a matter of fact that was the procedure we followed at first until the promptly fatal results in a number of cases pointed that out as the wrong treatment. Heroics are apparently not in place with this work and it requires almost that to operate on patients in that condition. They are in great distress as a result of sepsis, the involvement of the lungs, the embarrassed circulation and the presence of the fluid. Operating on such a patient will release the septic fluid, but nothing else. It will not improve the lung condition or the circulation, quite the contrary, it will bring about the collapse of the uninvolved lung tissue on the affected side, and force the mediastinum over to the already overburdened other side. This to our mind accounts for the rapidly fatal results in some of the cases given in the tables.

The one object gained by operation, namely the removal of the fluid, can be obtained by aspiration without the dangers attending an early operation. This treatment suggested itself to us early in the period covered and though followed hesitatingly at first, we have gradually become more convinced of its efficiency and now apply it in all properly selected cases. Aspirations are repeated as often as indicated, sometimes only one or two are done, then again several, depending on the case. As soon as the fluid becomes suppurative, indicating thereby that adhesions are forming or have formed, and we feel reasonably sure that the pneumonia has subsided, we operate. No matter which organism is responsible for the infection, the aim should be not to operate while the pneumonia is active.

It is only when considering the accumulated amount of septic fluid in the chest as the principal factor in the disease that an early operation seems indicated. There are apparently those cases that are swamped with a streptococcus infection and its chief or only localization is in the pleural sac. In such a case removal of the fluid by early operation is perhaps the only chance a patient has, and one should go ahead fearlessly. However, even in these cases complete aspiration may produce as good results without the dangers attending an operation. It is a question whether the lung is ever involved in such a condition. Patient 70 belongs to this class. To prevent the pneumothorax one may use any one of the methods of closed bottle drainage. The great objection to them is that they are cumbersome, easily deranged, and contribute to the discomfort of the patient. During the early days after operation, however, a Brewer tube with a negative pressure bottle system does excellent service.

Though operation is delayed in the type of cases outlined above, one should not wait until a thickened pleura has formed, favoring chronic cavity formation later on. The old rule to evacuate pus as soon as formed applies here also. Each case must be judged on its own merits, there is no absolutely fixed rule, but the considerations outlined above should guide us to reach a decision in a given case. If called in therefore to see a patient with a view to operating we must come to a conclusion after considering his general appearance, his present temperature and pulse, the antecedent disease, the length of time since the onset of pneumonia, the type of fluid found and the organism producing the infection.

SURGICAL TREATMENT

It must be borne in mind that in a military hospital where changes in the staff are frequent it is difficult to control all details of treatment. However, a certain uniformity of opinion has prevailed, especially in regard to the time of operation.

In very sick patients we have done and continue to do an intercostal incision frequently in bed, and without removing the patient to the operating room. Novocaine in ½ per cent strength is used and the incision is made just long enough to allow the introduction of drainage tubes. Whenever the condition of the patient allows it, which is usually the case, he is taken to the operating room and rib resection is done. In only two patients has ether been used. All others were operated upon under local anæsthesia, using ½ per cent novocaine. We have used either one large fluted tube or a double drainage tube. There

seems to be no difference in the reaction or the result. The tubes should be just long enough to insure a free flow but not so long as to impinge against the lungs. A large pad and firm binder are applied and the patient is encouraged to rest on the operated side. We were not in the habit of washing out, but large masses of fibrin were removed at the time of operation. In the latter part of the period covered we began to use Dakin-Carrel treatment quite extensively and would introduce the tubes either at the time of operation or on the following day. In the wards we use Gatch bed frames which allow a Fowler position. They contribute greatly to the comfort of the patient. In the first days following an operation, we use morphine in sufficient amount to overcome the distress and severe dyspnœa. There is one complete dressing a day at which time the cavity is irrigated and the tubes cleaned or changed. Outer pads are changed as necessary. At the time of dressing the patient's back also receives attention, his skin is thoroughly cleaned and an alcohol rub given.

In regard to the use of antiseptic solutions, we have used everything from normal saline, boric acid, cherry red iodine, and peroxide, to Dakin's solution. When looking over our entire series it is impossible to state truthfully that any one method has yielded uniformly good results. Dakin treatment was used faithfully, and in the hands of men taught at the Rockefeller Institute. In some cases it was used early, beginning on the day of operation. In the older cases later, to help clean them up. We obtained very good results in some cases but had equally good results in some parallel cases, in which nothing but simple drainage was used. Any very striking results showing marked superiority over other methods were not observed. Two of the cases treated with Dakin solution and closed with secondary suture when the wound was apparently sterile, had to be reopened. Attention must be called to the fact that though the cavity does apparently become sterile, as evidenced by a clear mucoid discharge, pus may be situated in some dependent portion of the cavity, and the irrigating fluid is prevented from acting on it by the presence of this mucoid covering. It is, therefore, important that the position of the patient be changed from time to time, especially that it is changed during the irrigation. All patients operated upon since September 1, 1918, have at once been put on Dakin treatment and it is being continued until a cure is obtained. None of those cases are included in this series. They will be reported upon at a later date.

From our observations the most important points in the treatment, both in order to get a cure and to get an early cure are to drain at the most dependent part in order to prevent collections of pus from forming and to keep this drainage opening sufficiently wide to allow free drainage. As healing progresses not the caliber of the tube, but rather its length, should be reduced, for this very reason, viz.: to get good drainage, a rib resection is preferable to an intercostal incision.

It is also important to encourage deep breathing and light arm exercise. To prevent reinfection of the cavity the fistulous opening and the surrounding skin must be kept scrupulously clean. An occasional application of iodine to the former is of benefit.

The length of time from the onset of pneumonia to the discharge of the patient or from the time of the operation until the wound was closed varied so much that no clue was found which would guide us to get a uniformly good result in a very short time. So many factors enter in and materially influence the course of the disease.

As will be noted from a perusal of the attached tables, the duration of the disease was usually shortest in those cases of empyema following primary lobar pneumonia of pneumococcus origin.

The remarks about treatment are incomplete without calling attention to the importance of diet. The patients are usually in poor physical condition when they come to the surgeon and their emaciation increases rapidly as suppuration continues. We have been very fortunate in having the full cooperation of the administrative personnel in the treatment of these patients. Anything that was procurable has been obtained for them. In addition to their regular meals they

would receive milk, raw eggs, etc., at two hour intervals and in that way we have succeeded in keeping up their strength to enable them better to overcome the infection.

All empyema patients are kept in a special ward or wards depending on the number in the hospital at any one time. They occupy beds on the sunny side in order to have the benefit of the sunlight. The temperature is kept comfortable, we do not believe that very cold air is of benefit. As soon as we feel it is safe for the patients to be up, we encourage them to sit up in a chair for a short time every day. By means of the Gatch springs they have become accustomed to the sitting posture and the transition from that to out of bed is easy for them.

SECONDARY OPERATIONS

In empyema one is by no means always dealing with a single cavity and the main cavity may have several smaller pockets communicating with it. With the existing tendency to walling off, one of these pockets may become partially or entirely shut off from the main cavity. Such a condition is favored by inadequate drainage. We have repeatedly observed secondary pus pockets break spontaneously and empty through the thoracic fistula. In other cases we have aided such a rupture by the introduction of a dressing forceps. In some cases it became necessary to enlarge the drainage opening by simple stretching, and in four patients, Cases, 53, 57, 64, and 13, in whom a primary intercostal incision had been done, a secondary rib resection had to be performed.

In one case, No. 10, who had a persistent fistula leading to a deep seated small cavity, we resected two ribs under local anæsthesia, mobilized the lung, excised the fistula, and cleaned out the cavity. Immediate Dakin treatment was started, flushing the wound every two hours. After a week the tubing was removed and the cavity allowed to close. There was no communication with a bronchus and the treatment was well borne.

In three cases we had to do an extensive rib resection with decortication of the lung. On account of the interest attaching to the condition we shall report them in detail.

Case 5 was first operated upon October 21, 1917, a part of the eighth rib being resected. On account of profuse drainage which did not diminish, he was again operated upon January 28, 1918, and the seventh and eighth ribs were resected for the greater part of their length. The thickened pleura was incised in several places to allow expansion of the lung. The patient's condition was so poor that extensive decortication could not be done. The drainage diminished but did not cease; therefore a counter incision was made anteriorly February 4, 1918. He improved considerably, but as he complained of pain in the chest and did not gain as rapidly as he should, an X-ray was made. It revealed an encapsulated empyema higher up. This was drained on April 2, by resecting part of the fifth rib anteriorly. Recovery was uneventful after that. He returned to duty, July 16, 1918.

The importance of the X-ray in the diagnosis of empyema was not fully appreciated by us in the beginning. It is now used by us not only in the original diagnosis whenever doubt exists or we want to localize a pocket exactly, but it is also used to follow up the case after operation. Whenever a patient is not doing well and physical signs fail, we resort to the X-ray, with most gratifying results.

Case 68. An intercostal incision was made for empyema on October 21, 1917. Drainage continued profuse, therefore the cavity was injected with bismuth and an X-ray plate was made. It showed a cavity reaching upward to the supraclavicular space. Operation January 9, 1918: resection of six inches of the eighth, seventh, sixth, fifth and fourth ribs and 1 inch of the third rib. The thickened pleura and intercostal tissues were divided and the pleura stripped off. The visceral layer of the pleura was then stripped off the lung and the pericardium carrying this dissection upward to remove the dome of the cavity. The lung expanded at once. Reaction was good. The cavity was closed February 27, 1918, and the patient returned to duty March 16, 1918.

Case 17. Operation was done October 24, 1917, for right empyema. An intercostal incision was made. The patient was extremely ill. During the course of his disease he developed an acute necrosis of both superior maxillæ. The entire bony alveolar processes were cast off in a short time, leaving an opening into the antrum on either side. The intermaxillary bone did not slough away and was later used for the attachment of a plate. The empyema showed no tendency to heal. Bismuth paste injection revealed a rigid cavity extending upward to the clavicle. Operation January 24, 1918, through large curved flap incision. The skin, pectoralis major and minor, were pushed upward, and the ribs exposed. About 4 inches of the fifth and fourth ribs, 3 inches of the third, and 1 inch of the second rib were then resected. The thickened parietal pleura and intercostal muscles forming the anterior wall of the cavity were divided. The pleura which in parts was ¼ inch thick, was removed. The visceral pleura was then stripped off the lung, which

expanded as soon as released. A small gauze strip was inserted into the cavity and the wound was then closed. The patient reacted well. After operation there was some bloody, frothy expectoration, but no other untoward result. Convalescence was slow. He was returned to duty, June 21, 1918.

There was only one lung abscess in this entire series that came to operation. He deserves mention.

CASE 24. The diagnosis was made by puncture, obtaining the same foul-smelling material which he was expectorating. It was confirmed by the X-ray. The odor was so offensive that isolation became necessary. The abscess was secondary to lobar pneumonia, due to pneumococcus type 2, which began 14 days before the abscess was recognized. The exploring needle withdrew air and foul-smelling, thick pus. The X-ray showed a lobulated cavity of the upper portion of the right lower lobe, surrounded by an area of infiltrations. Operation July 13, 1918: resection of 3 inches of the seventh and eighth ribs under local anæsthesia. Parietal pleura separated from chest wall to mobilize it. Exploratory punctures were then done and when the abscess was entered the needle was left in place. A circular silk suture was then inserted at a distance of 1 inch from the needle, suturing the visceral to the parietal pleura. A narrow bladed knife was then placed alongside the needle into the cavity and the opening widened so soon as pus was obtained. After cleaning out the cavity a gauze strip and rubber tube were inserted and another gauze strip was placed between the chest wall and the parietal pleura in order to keep them separated.

Recovery was uneventful. Dakin treatment was not borne well on account of a communication between the cavity and a bronchus. Iodoform gauze was, therefore, used in packing. The patient improved rapidly as the discharge diminished. It became necessary later to remove the silk suture. Recovery was complete and the patient was returned to duty November 13, 1918.

PROGNOSIS AND FINAL RESULTS

Enough has been said in the presentation of the various groups to indicate that empyema is a serious condition and that its development after pneumonia requires thorough study before operation is resorted to. This is especially true of the streptococcus infections. The patients are usually in poor condition as the result of the preceding infection and their resistence is low, so that any additional strain may determine a fatal outcome. Some patients seem simply doomed from the beginning and any measures known to us at present are without avail. We must, therefore, be very careful not to do anything that will diminish their chances of recovery.

It should be borne in mind, however, that though some of the deaths are attributed to empyema, because it was the condition for which the patient was operated upon, other lesions of a general sepsis or the lung condition itself was really more responsible.

Taking the various groups once more and studying them in relation to the final results, we find there were:

Following primary pneumonia 24 cases with 3 deaths, or 12 per cent;

Following measles pneumonia, 23 cases with 9 deaths, or 39 per cent;

Following other secondary pneumonias, 20 cases with 7 deaths, or 35 per cent;

Following primary pleurisy 3 cases with no deaths.

If we classify the cases according to the organism producing the infection, instead of according to antecedent disease, we find that there were:

54 pneumococcus cases with 9 deaths, or 17 per cent;

16 streptococcus cases with 10 deaths, or 62 per cent.

Taking our total of 70 cases, we find that there were:

19 deaths or 27 per cent, 48 cured or 69 per cent, and 3 in the hospital, or 4 per cent.

The three patients remaining in the hospital are doing well and promise to go on to complete recovery, so that the total will be 73 per cent cured.

All patients listed as cured have been returned to duty. This includes those patients with extensive rib resection.

TABLE I.—CASES OF EMPYEMA FOLLOWING PRIMARY LOBAR PNEUMONIA

Name	Race	Onset of Pneumonia	Organism	Aspirations	Operation	Side	Type Fluid	Time since Onset	Result	Total Time
1. B., A.	W.	Jan. 8	Pneum.	Jan. 19	Jan. 19	L.	Pus	11 days	Cured, duty Mar. 19	2½ mos.
2. B., J. H.	W.	Jan. 25	Strept.	Feb. 1–260 ccm. Feb. 2–300 ccm. Feb. 3–480 ccm. Feb. 6–pus	Feb. 9	L.	Thin pus	15 days	Died, Feb. 15	21 days
3. B., T.	W.	Dec. 10	Pneum.	Dec. 26	Dec. 28	R.	Pus	18 days	Cured, duty Mar. 15	3 mos.
4. C., L.	W.	Jan. 4	Pneum.	Jan. 10	Jan. 10	R.	Pus	6 days	Cured, duty Mar. 16	2½ mos.
5. C., E. R.	W.	Oct. 6	Pneum.	Oct. 21	Oct. 21	R.	Pus	15 days	Cured, duty July 16	9½ mos.
6. D., D. E.	W.	Jan. 16	Pneum.	Feb. 2	Feb. 2	R.	Pus	17 days	Cured, duty Apr. 12	3 mos.
7. D., M.	C.	Aug. 8	Pneum.	Aug. 17–30 ccm. serous Aug. 20–70 ccm. serofibrinous	Aug. 22	R.	Pus	16 days	Doing well in hospital	
8. F., A.	C.	Aug. 14	Pneum.	Sept. 8	Sept. 8	R.	Pus	25 days	Cured, duty Nov. 3	2 mos.
9. H., W.	W.	July 18	Pneum.	July 25–1 ccm. sanguinous July 28–5 ccm. sanguinous Aug. 7–pus	Aug. 7	R.	Pus	20 days	Cured, duty Nov. 13	4 mos.
10. J., A.	C.	May 16	Pneum.	May 21–25 ccm. turbid fluid May 27–350 ccm. pus	May 27	L.	Pus	11 days	Doing well in hospital	
11. L., B.	C.	Aug. 22	Pneum.	Aug. 28–60 ccm. sl. purulent	Aug. 30	L.	Pus thin	8 days	Cured, duty Nov. 16	3 mos.
12. M., R. F.	W.	Dec. 4	Pneum.	Feb. 3	Feb. 6	R.	Pus	33 days	Cured, duty Mar. 26	3½ mos.
13. N., B.	W.	May 4	Pneum. and Strept.	May 10–50 ccm. turbid	May 12	L.	Pus	8 days	Doing well in hospital	
14. O., C.	W.	Jan. 18	Pneum.	Feb. 5–280 ccm. pus Feb. 8–pus	Feb. 9	L.	Pus	22 days	Cured, duty Mar. 19	2 mos.
15. O'N., B.	C.	Mar. 9	Pneum.	Mar. 18–serous Mar. 26–pus	Mar. 26	R.	Pus	17 days	Died, April 1	23 days
16. P., W	W.	Apr. 6	Pneum.	July 6	July 18	R.	Pus	3½ mos.	Cured, duty Oct. 15	6 mos.
17. R., W.	W.	Sept. 25	Pneum.	Oct. 25	Oct. 24	R.	Pus	29 days	Cured, duty June 21	9 mos.
18. R., W.	C.	May 8	Pneum.	May 18	May 18	R.	Pus	10 days	Died, May 19	11 days
19. S., E.	W.	Dec. 16	Pneum.	Dec. 26–750 ccm. pus	Dec. 27	R.	Pus	11 days	Cured, duty Mar. 15	3 mos.
20. S., D.	W.	Dec. 7	Pneum.	Dec. 13–200 ccm. seropurulent Jan. 18–pus	Jan. 19	R.	Pus	43 days	Cured, duty Mar. 15	3 mos.
21. S., E.	W.	Apr. 16	Pneum.	Apr. 20–clear Apr. 22–clear Apr. 23–280 ccm. turbid fluid	Apr. 28	R.	Pus	12 days	Cured, duty June 8	7 weeks
22. W., D.	C.	Nov. 5	Pneum.	Nov. 23	Nov. 23	R.	Pus	18 days	Cured, duty July 26	8 mos.

TABLE I.—CASES OF EMPYEMA FOLLOWING PRIMARY LOBAR PNEUMONIA—*Continued*

Name	Race	Onset of Pneumonia	Organism	Aspirations	Operation	Side	Type Fluid	Time since Onset	Result	Total Time
23. W., J.	W.	Dec. 22	Pneum.	Dec. 31–30 ccm. Jan. 1–30 ccm. Jan. 4–250 ccm. serosanguinous Jan. 8–460 ccm. pus	Jan. 11	L.	Pus	20 days	Cured, duty Mar. 6	2½ mos.
24. K., W.	W.	June 22	Pneum.	July 12–foul pus	July 13	R.	Pus	21 days	Cured, duty Nov. 13	4½ mos.

TABLE II.—CASES OF EMPYEMA FOLLOWING MEASLES PNEUMONIA

Name	Race	Onset of Measles	Onset of Pneumonia	Type	Organism	Aspirations	Operation	Side	Type of Fluid	Time since Onset Pneumonia	Complications	Cavity closed	Result
25. A., J. W.	W.	Dec. 1	Dec. 24	Bron.	Strept.	Dec. 26	Dec. 26	L.	Pus	3 days?	general cachexia		Died, Dec. 27
26. A., W. G.	W.	Jan. 7	Jan. 14	Lobar	Pneum.	Jan. 22 — pus	Jan. 24	R.	Pus	10 days	Otitis media	Apr. 6	Cured, duty Apr. 18
27. A., H.B.	W.	May 6	June 3	Bron.	Strept.	June 5—15 ccm. cloudy fluid	June 5	L.	Thin pus 150 ccm.	2 days	Otitis media	Nov. 1	In hosp. doing well
28. C., H. M.	W.	Nov. 17	Dec. 7	Bron.	Pneum.	Dec. 11 — clear fluid Jan. 3 — pus	Jan. 3	R.	Pus	27 days	None	Feb. 18	Cured, duty Mar. 5
29. C., J. C.	W.	Dec. 3	Dec. 21	Bron.	Strept.	Jan. 1—540 ccm. thin purulent fluid	Jan. 4	R.	Pus	14 days	Otitis media. Suppurative perilaryngitis and tracheitis		Died. Jan. 12
30. C., J. W.	W.	Jan. 15	Feb. 1 Apr. 9	Bron. Bron.	Pneum. Pneum.	April 13 — clear April 14 — 1100 ccm. thin turbid	Apr. 14	R.	Thin pus	5 days	Otitis media Acute nephritis		Died, Apr. 18
31. D., W.	W.	Nov. 12	Dec. 1	Bron.	Pneum.	Dec. 6—thin pus Dec. 12—thick pus	Dec. 14	R.	Pus	14 days	Otitis media	Feb. 15	Cured, duty Feb. 19
32. D., L. A.	W.	Nov. 15	Dec. 3	Lobar	Pneum.	Dec. 12 — pus	Dec. 15	L.	Pus	12 days	Otitis media	Feb. 18	Cured, duty Mar. 15
33. G., H.	C.	Apr. 24	May, 24	Lobar	Pneum.	May 29 — cloudy fluid July 7 — 30 ccm. pus	July 7	L.	Pus	44 days	None	Aug. 29	Cured, duty Sept. 20
34. H., W. A.	W.	Oct. 24	Nov. 14	Bron.	Strept.	Nov. 30 — 600 ccm. sero-purulent	Dec. 2	R.	Sero-purulent	18 days	Otitis media		Died, Dec. 4
35. H., C.	W.	Dec. 19	Dec. 22	Bron.	Strept.	Jan. 6 — serous fluid Feb. 25 — pyopneumothorax	Feb. 26	R.	Pus	35 days	Meningococcus meningitis. Multiple joint swellings	Mar. 28	Cured, duty Mar. 31
36. J., W.	W.	Dec. 18	Dec. 27	Bron.	Strept.	Jan. 18 — purulent 100 ccm. fluid. Jan. 27 — pyopneumothorax	Jan. 27	R.	Pus	31 days	Otitis media bil. Abscess rectus abd. Abscess olecranon.	Mar. 13 Mar. 13	Cured, duty Mar. 19
37. K., T.	W.	Nov. 30	Dec. 15	Lobar	Pneum.	Dec. 27 — thin pus Dec. 29 — pus	Dec. 30	L.	Pus	15 days	None	Apr. 17	Cured, duty Apr. 18

TABLE II.—CASES OF EMPYEMA FOLLOWING MEASLES PNEUMONIA—*Continued*

Name	Race	Onset of Measles	Onset of Pneumonia	Type	Organism	Aspirations	Operation	Side	Type of Fluid	Time since Onset Pneumonia	Complications	Cavity closed	Result
38. O., B.	W.	Jan. 14	Feb. 2	Bron.	Pneum.	Feb. 22 — straw colored fluid Feb. 26 — pyo-pneumothorax	Feb. 26	R.	Pus	24 days	Otitis media, bil. Abscess of toe. Cellulitis of back. Peritonitis (?). General sepsis.		Died, March 6
39. P., H.	W.	Nov. 2	Nov. 11	Bron.	Strept.	Nov. 19	Nov. 19	R.	Thin pus	8 days	None		Died, Nov. 21
40. P., L. E.	W.	Nov. 13	Nov. 20	Bron.	Strept.	Nov. 22	Nov. 22	R.	Thin pus	2 days	None		Died, Nov. 23
41. P., J. E.	W.	Nov. 21	Dec. 1	Bron.	Strept.?	Dec. 23 — serous fluid	Jan. 9	R.	Pus	39 days	None	Mar. 23	Cured, duty Mar. 26
42. P., A.	W.	Jan. 25	Feb. 5	Bron.	Strept.	Feb. 13 — cloudy fluid Feb. 14 — 350 ccm. cloudy fluid	Feb. 14	R.	Cloudy fluid	9 days	Abdominal distention		Died, Feb. 15
43. R., S. A.	W.	Nov. 15	Nov. 29	Bron.	Pneum.	Dec. 6 — 500 ccm. serous fluid	Jan. 15	L.	Pus	47 days	None	Mar. 7	Cured, duty Mar. 10
44. T., J. G.	W.	May 4	May 14	Bron.	Pneum.	May 18	May 18	L.	Pus	4 days	Otitis media		Died, May 18
45. V. A., T. B.	W.	Nov. 8	Dec. 1	Bron.	Pneum.	Jan. 24 — pus	Jan. 28	L.	Pus	58 days	Parotitis, non-suppurative	Mar. 1	Cured, duty Mar. 9
46. W., H. W.	W.	Nov. 15	Nov. 26	Lobar	Pneum.	Dec. 26 — pus	Jan. 3	L.	Pus	38 days	None	Feb. 25	Cured, duty Mar. 5
47. W., A. L.	W.	Nov. 28	Dec. 19	Lobar	Pneum.	Jan. 15—240 ccm. Jan. 16—150 ccm. seropurulent	Jan. 19	L.	Pus	31 days	None	Mar. 20	Cured, duty Mar. 28

TABLE III.—CASES OF EMPYEMA FOLLOWING OTHER SECONDARY PNEUMONIAS

Name	Race	Antecedent Disease	Onset of Pneumonia	Type	Organism	Aspirations	Operation	Side	Type of Fluid	Time since Onset Pneumonia	Complications	Result
48. G., G.	W.	Influenza	Feb. 1	Lobar	Strept.	Feb. 5—340 ccm. ser. Feb. 6—300 ccm. ser. Feb. 8—830 ccm. ser. Feb. 15—160 ccm. ser. Feb. 23—pus	Feb. 23	L.	Pus	22 days	Peritonitis	Died, March 24
49. L., B.	W.	Influenza	Jan. 28	Lobar	Strept.	Jan. 29—185 ccm. ser. Feb. 1—180 ccm. ser. Feb. 3—450 ccm. ser. Feb. 6—280 ccm. turb. Feb. 8—560 ccm. turb. Feb 12—440 ccm. pus	Feb. 13	R.	Pus	16 days	None	Cured, duty June 15
50. W., P. W.	W.	Influenza	May 10	Lobar	Pneum.	May 15—cloudy fluid May 16—cloudy fluid	May 19	L.	Pus	9 days	Bilateral involvement	Died, May 24
51. A., H. A.	W.	Bronchitis	Jan. 8	Bron.	Strept. and Pneum.	Jan. 30—serous fluid Feb. 2—800 ccm. bloody fluid	Feb. 5	R.	900 ccm. bloody fluid	28 days	Parotitis supp. l. Multiple joint involvement. Phlebitis l. femur. Cellulitis of neck.	Died, Feb. 15
52. H., C. H.	W.	Bronchitis	Jan. 1	Bron.	Strept.	Jan 15—thin pus	Jan. 15	R.	Thin pus	4 days	None	Died, Jan. 25

TABLE III.—CASES OF EMPYEMA FOLLOWING OTHER SECONDARY PNEUMONIAS—*Continued*

Name	Race	Antecedent Disease	Onset of Pneumonia	Type	Organism	Aspirations	Operation	Side	Type of Fluid	Time since Onset Pneumonia	Complications	Result
53. J., R. C.	W.	Bonchitis	Dec. 16	Bron.	Pneum.	Jan. 14—serous fluid Jan. 29—pus	Jan. 30	R.	Pus	14 days	None	Cured, duty Apr. 20
54. M., H. G.	W.	Bronchitis	Dec. 29	Lobar	Pneum.	Jan. 4—10 ccm. bloody Jan. 10—250 ccm. seropurulent Jan. 13—pus	Jan. 28	L.	Pus	30 days	None	Cured, Mar. 19
55. McC., O.	W.	Bronchitis	Mar. 21	Lobar	Pneum.	Mar. 23—cloudy fluid Mar. 25—cloudy fluid	Mar. 25	R.	Sanguinous fluid	4 days	Erysipelas face	Cured, duty May 15
56. O., H.	C.	Bronchitis	Mar. 28	Lobar	Pneum.	April 19—pus	Apr. 19	R.	Pus	22 days	None	Cured, duty Aug. 14
57. P., G.	C.	Bronchitis	Jan. 18	Lobar	Pneum.	Jan 30—pus	Jan. 30	R.	Pus	12 days	Bronchial fistula	Cured, duty July 28
58. McC., J.	W.	Tonsillitis	Dec. 8	Lobar	Pneum.	Dec. 26—Pus	Jan. 2	R.	Pus	25 days	None	Cured, duty Apr. 18
59. P., C. T.	W.	Tonsillitis	Apr. 23	Lobar	Pneum.	April 25—serous April 28—pus	Apr. 28	R.	Pus	5 days	None	Cured, duty June 3
60. G., McC.	W.	Tonsillectomy	Jan. 30	Bron.	Strept.	Feb. 2—serous fluid Feb. 5—700 ccm. ser. Feb. 6—560 ccm. ser. Feb. 10—250 ccm. turbid	Feb. 13	L.	Thin turbid fluid	14 days	Pericarditis Pneumothorax	Died, Feb. 26
61. D., A.	C.	Abscess of cheek	June 7	Lobar	Pneum.	June 22—25 ccm. thin pus	June 22	R.	Thin pus	15 days	None	Cured, duty Sept. 21
62. M., B.	W.	Otitis media and mastoid	Apr. 2	Lobar	Strept. and Pneum.	April 8—bloody serum	Apr. 8	R.	Bloody serum	6 days	Mastoid, thrombosis, lateral sinus	Died, April 9
63. R., V.	C.	Anæsthesia	Mar. 8	Lobar	Pneum.	Mar. 27—turbid fluid	Mar. 27	R.	Thin pus	19 days	None	Cured, duty July 26
64. J., E.	W.	Meningitis	Apr. 17	Lobar	Pneum.	Apr. 20—30 ccm. ser. Apr. 29—pyopneumothorax	Apr. 30	R.	Pus	13 days	None	Cured, duty Aug. 20
65. D., F.	W.	Antityphoid Inoculation	May 17	Bron.	Pneum.	May 18—thin pus	May 18	L.	Thin pus	1 day	Pericarditis	Died. May 20
66. H., E.	W.	Antityphoid Inoculation	Apr. 18	Bron.	Pneum.	Apr. 19—600 ccm. cloudy fluid Apr. 20—1250 ccm. cloudy fluid	Apr. 21	R.	Thin pus	3 days	Pericarditis, dry	Cured, duty Aug. 16
67. W., H.	C.	Antityphoid Inoculation	June 4	Lobar	Pneum.	July 12—pus	July 13	R.	Pus	9 days	None	Cured, duty Aug. 19

TABLE IV.—EMPYEMA FOLLOWING PRIMARY PLEURISY

Name	Race	Onset	Aspirations	Operation	Type fluid	Side	Organism	Result
68. D., H. B.	W.	Oct. 18	Oct. 21 — pus	Oct. 21	Pus	L.	Pneumococcus?	Cured, duty Mar. 16
69. R., R. M.	W.	May 8	June 2 — cloudy fluid June 17 — pyo-pneumothorax	June 17	Pus	R.	Pneumococcus	Cured, duty Nov. 14
70. V., G. E.	W.	Feb. 12	Feb. 13 — turbid fluid	Feb. 13	Turbid fluid	R.	Streptococcus	Cured, duty May 4

A REVIEW OF THE TREATMENT OF PURULENT PLEURITIS (EMPYEMA) AT CAMP PIKE BASE HOSPITAL

By Lieutenant VICTOR P. DIEDERICH, M.C., U. S. A.
Chief of the Empyema Section, Base Hospital, Camp Pike, Arkansas

THE following report is based on an experience of nine months in the treatment of purulent pleuritis, embracing the months of March to December, and includes 147 cases. It covers not only three seasons which are of importance in discussing this condition, but also includes the pleuritis following three distinct types of primary infection, which are even more important, namely, influenza followed by hæmolytic streptococcus or pneumococcus pneumonia, measles followed by hæmolytic streptococcus or pneumococcus pneumonia, or primary lobar or bronchopneumonia caused by the pneumococcus or hæmolytic streptococcus or both.

The course and outcome of purulent pleuritis are most assuredly dependent to a very large extent upon the antecedent infection and for this reason it is important to remember, that the surgical treatment of this condition is often a secondary matter.

The term empyema certainly has played a large and often dangerous part in the selection of various types of surgical intervention in the treatment of purulent pleuritis. It has been a most misleading term, because of the fact that many cases of purulent pleuritis, encountered during the past year, have not answered the description generally understood to mean empyema.

A review of the literature of the past brings forth two principal types of treatment:

1. Open methods, either by rib resection or intercostal thoracotomy with permanent drainage.
2. Closed method by repeated aspirations.

The open method with resection of one or more ribs was and is recommended by some. This method was modified by various men, for the improvement of drainage and production of negative pressure, such as the syphon pump, Brewer tubes, rubber suction bulbs, rubber flaps to cover outlet of tubes, allowing egress but no ingress of air into the pleural cavity.

A method used in Europe and to some extent in this country, was the introduction of a catheter as a means of aspirating the pleural cavity. Irrigations were considered dangerous and seldom used until lately.

The closed method with frequent paracentesis and aspirations was recommended by some and Murphy advised the injection of 2 per cent formalin in glycerine after aspiration as a means of sterilizing the pleural cavity and aiding absorption of the exudate.

The subject of treatment as discussed in textbooks as a rule, consisted of a description of one or more types of operations, these usually being emphasized, while little or no reference was made to the type of infection or the stage of the disease, with the exception of the last stages when decortication, thoracoplasty, or bismuth paste injection were recommended. This condition persisted up to the present year and even now we find reports in various journals where the treatment recommended consists of rib resections, aspirations, aspirations with rib resections later, and catheter drainage by means of one or more catheters, some advising irrigations, and others not. This most striking difference in methods, apparently with often almost equally good results, must most assuredly be dependent on some common factor, the result of selected cases or else a coincidence.

The object of this paper, therefore, is an attempt to analyze the reason for this apparent difference in methods with equally good results and apparent similarity of methods with strikingly different results, with a view of establishing a clear conception of when one method should be used and when another.

The following statistics are compiled in three-month periods, therefore, covering the

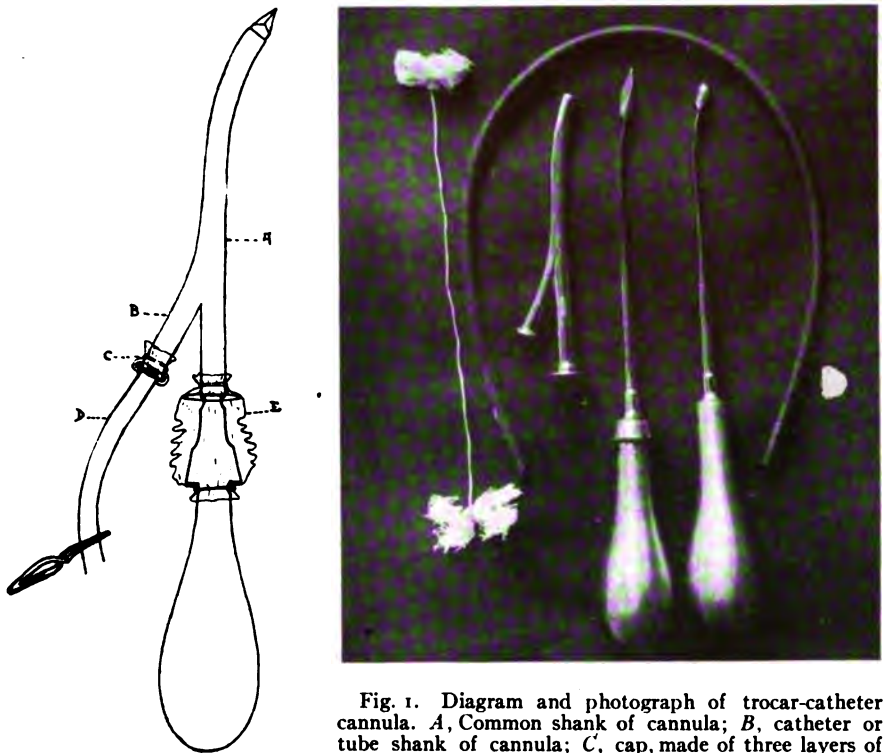

Fig. 1. Diagram and photograph of trocar-catheter cannula. *A*, Common shank of cannula; *B*, catheter or tube shank of cannula; *C*, cap, made of three layers of dental dam with small perforation in center to admit tube tightly; *D*, tube — standard Carrel-Dakin tubing — clamped shut; *E*, thin rubber tube or condom tied over handle of trocar and outlet of cannula making an airtight connection.

various seasons and also three distinct main types of primary infection as mentioned above. They include 225 cases. Of this number 147 came under my care during their entire course, while 78 who had been admitted to the empyema ward during the months of January and February include 30 who died before March 1 and 48 on whom I did the postoperative dressings.

JANUARY AND FEBRUARY SERIES

This series in which I took no part in the treatment except the later after-treatment includes the cases occurring during the severe winter months, when patients were kept indoors, when the hæmolytic streptococcus infection was most virulent and measles was a frequent primary infection. Because an entirely different method of treatment was employed in this series from that which was used in the later cases I am including this series for comparison:

		Per cent
During the month of January:		
Number of cases admitted	63	
Deaths	30	47.6
Method of treatment:		
Rib resection	63	
Deaths	30	47.6
During the month of February:		
Number of cases admitted	15	
Deaths	1	
Method of treatment:		
Rib resections	13	
Deaths	1	6.9
Aspirations	2	
Deaths	0	

MARCH, APRIL AND MAY

The majority of cases admitted during March and April were suffering from a hæmolytic streptococcus infection and many were still suffering from an active pneumonia. They were also handicapped in so far as climatic conditions were unfavorable. Until the latter part of March all cases were kept indoors.

Fig. 2. Diagrammatic sketch showing course of tube through chest wall. Tissue flap at *A* acts as valve flap.

		Per cent
During the month of March:		
Number of cases admitted	14	
Deaths	5	35.7
Method of treatment:		
Rib resection	14	
Deaths	5	35.7
During the month of April:		
Number of cases admitted	16	
Deaths	1	
Method of treatment:		
Rib resection	4	
Deaths	1	.25
Aspirations	1	
Deaths	0	
Trocar thoracotomy:		
Catheter aspiration and irrigation	11	
Deaths	0	
During the month of May:		
Number of cases admitted	12	
Deaths	1	
Method of treatment:		
Rib resection	0	
Aspirations	4	
Deaths	1	25
Trocar thoracotomy:		
Catheter aspiration and irrigation	8	
Deaths	0	

JUNE, JULY AND AUGUST

The cases admitted during these months with a very few exceptions had primary lobar or bronchopneumonia. They were usually men who had been in camp for several months, and, consequently, hardened and in better condition than those in the preceding series. The weather conditions were also favorable.

		Per cent
During the months of June, July and August:		
Number of cases admitted	12	
Deaths	0	
Method of treatment:		
Trocar thoracotomy with catheter aspiration and irrigation	15	
Deaths	0	

SEPTEMBER, OCTOBER AND NOVEMBER

(Influenza Period)

This period was undoubtedly the most severe. The majority of the patients had passed through an attack of the influenza which was followed usually by bronchopneumonia, sometimes lobar pneumonia and often both. They entered the empyema ward, as a rule, still suffering from an active pneumonia, not infrequently bilateral. Of this series 9 per cent had a bilateral empyema.

		Per cent
During the months of September, October and November:		
Number of cases admitted	88	
Deaths	20	22.7
Method of treatment:		
Aspirations	27	
Deaths	13	48.09
Thoracotomy	61	
Deaths	7	11.47
Bacteriology of this series:		
Number of cases	88	
Deaths	20	22.7
Culture of pleural fluid in above 20 cases:		
Hæmolytic streptococcus was found in	18	
Hæmolytic streptococcus and pneumococcus in	1	
Pneumococcus type in	1	
Pleural fluid examinations in the entire series:		
Number of cases cultured	88	
Streptococcus hæmolyticus	44	50
Streptococcus non-hæmolyticus		3.40
Streptococcus and pneumococcus		13.68
Streptococcus and influenza bacillus		2.20

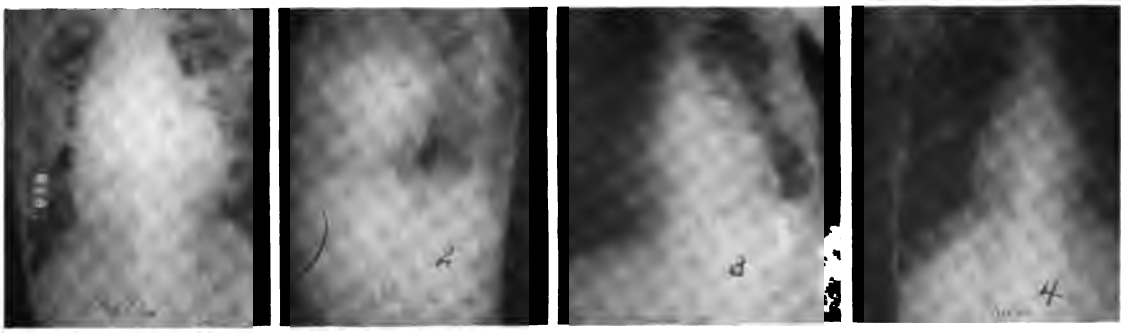

Fig. 3. Case 51. Midpleural empyema (left). *1*, Patient lying on breast. X-ray of encysted empyema between inner surface of left lung and mediastinum. Note resemblance to shadow of purulent pericarditis or effusion. The straight edge on left side differentiates it from a precardial affair which would be bowl-shaped. *2*, Lateral view of same case showing that pus extended posteriorly, thus enveloping root of lung. This also helps to differentiate it from a precardial affair. *3*, Patient lying on back; shows tube *in situ*, it having been inserted anteriorly. *4*, Patient lying on breast. View showing patient after he had entirely recovered. Compare this case with Fig. 4.

		Per cent
Pneumococcus	27	29.51
Type I		1.13
Type II		3.40
Type IIa		4.54
Type III		7.95
Type IV		3.40
Undetermined		9.09
Pneumococcus and influenza bacillus		1.13

Resections total, 94, 37 deaths, or 39.7 per cent; aspirations total, 34, 14 deaths, or 41.1 per cent; trocar-catheter, total 9, 7 deaths, or 8.05 per cent.

An analysis of the above four series of cases brings out the following very interesting results, which, in some respects, are apparently very contradictory both here as well as to the results obtained at other camps:

During the months of January and February, 1918, at Camp Pike, practically all cases of purulent pleuritis were treated by primary rib resection. From what I saw of the latter part of this series during the month of March, I would say that it was the rule to do a rib resection as soon as fluid was found in the pleural cavity, providing it contained organisms, irrespective of whether it was serofibrinous, seropurulent or purulent. It was classed as empyema and treated according to the textbook teaching for this condition.

During the month of January, 63 cases were admitted and 30 died, a mortality of 47.6 per cent. In February, 15 cases were admitted and one died. Here in two successive months we have two series of cases both treated by the same method. One with a mortality of 47.6 per cent and the other with a mortality of 6.9 per cent. No irrigations were used.

Had the results of February been used as a criterion, resection would probably have been recommended. Four times as many cases were admitted in January as February. In March the mortality rose again to 35.7 per cent and dropped to 6.2 per cent in April; however, in April the treatment was changed to that used at the present time; namely, trocar-catheter with Dakin's irrigations. It is fair to assume that during January the virulence of the infection was at its height, and the majority had an active hæmolytic streptococcus pneumonia, when they entered the empyema ward. The drop in the number of cases in February would lead one to suppose that the epidemic was on the decline. The majority of these cases were patients who had recovered from their pneumonia or had pneumococcus infections while the earlier ones were mostly hæmolytic streptococcus infections.

The same effect can be seen in the results obtained by other methods. During the month of April, May, June, July and August when no severe epidemic or pneumonia existed in camp, the mortality by the trocar-cannula method was nil in a series of 34 cases. It would have undoubtedly been higher had this same number of cases been treated in January and February. This was

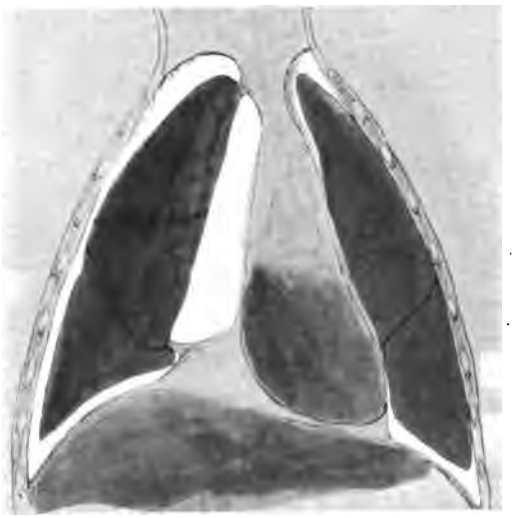

Fig. 4. Sketch from photograph of autopsy showing encysted empyema on the inner surface of right lung, also empyema of right and left pleural cavities. (Pus collections shown in white.) Purulent bronchitis and bronchopneumonia of both lungs.

shown in the recent influenza epidemic of October and November, when out of 61 cases treated by the trocar-cannula method the mortality was 11.47 per cent, a marked increase in death rate over the summer months and yet much better than 47.6 per cent by the resection method used in January, February, and March. This point is again emphasized by the mortality of 48 per cent in 27 cases who were aspirated during the influenza period.

A word might be said here regarding the high mortality of the cases aspirated. Some have recommended the aspiration method. Results have been published which were excellent so far as low mortality is concerned. Our experience at this camp has been that although aspirations in the early stages should be done in the great majority of cases, it will be necessary to do a thoracotomy later and to irrigate the empyema cavity.

The mortality of 41.1 per cent in cases who had merely been aspirated during the recent epidemic means that those were cases who were still suffering from an active pneumonia. They were referred to the empyema service because fluid containing organisms had been found. At autopsy these cases showed not only an active pneumonia, but very frequently serofibrinous or seropurulent fluid was found at aspiration or autopsy, in quantities insufficient to have caused death.

A small percentage of those cases aspirated repeatedly, preparatory to insertion of a tube by means of a trocar and cannula, recovered before it became necessary to use a tube.

In view of the above facts, we may say therefore, that the status of the aspiration method is, that it is to be used as a preliminary method, in those cases with serofibrinous or seropurulent fluid, when pneumonia often is still present and adhesions have not formed to wall off the empyema cavity and attach the lung about the abscess cavity to the chest wall. After these adhesions have formed, by which time the fluid is purulent, irrigations can be used and pneumothorax if produced, is limited to the abscess cavity. Collapse of large portions of the lung is thereby avoided, an important factor, especially at the time when there is little healthy functionating lung tissue present. Also by this means, a small percentage of cases will recover without further surgical intervention.

The use of 2 per cent formalin in glycerine after aspirations was tried in three cases before we began using the trocar-cannula method. In my opinion the method offers little improvement over the simple aspiration method. Thoracotomy must be resorted to later and convalescence of the patient is unnecessarily prolonged, with the exception of that small percentage of cases, who get well without resorting to anything after simple aspirations have been done.

Primary rib resection, especially in those virulent hæmolytic streptococcus and pneumococcus infections as seen in the recent epidemic will, I am sure, be condemned when its results of last winter are compared with those obtained by the combined aspiration and trocar-catheter method as used at this camp.

Looking at the statistics from April to December, we find that 95 cases have been treated by this method with 7 deaths, or a mortality of 7.05 per cent. Results which would compare favorably with these I feel

Fig. 5. Empyema patient being irrigated.

Fig. 6. Convalescent empyema patient. Small scar one inch below and three inches posteriorly to left nipple was the site of thoracotomy. Note expansion of patient's chest.

would be the same series of cases treated by the method as outlined by the Empyema Commission at Camp Lee last spring.

They recommend aspiration followed by rib resection and irrigation with Dakin's solution. They recommend resection on the ground that the good surgical principle of free drainage should be used once the empyema cavity has been walled off.

I have had no experience with this method; inasmuch as those cases with rib resections last spring who were irrigated with Dakin's solution had not had preliminary aspirations. The results with the trocar-catheter method, however, have been too good to wish trying anything else.

The average length of time elapsing between the thoracotomy and the closure of the chest was 40 days. From present indications this time will be considerably shortened in the present series. The rapidity of closure is greatly dependent upon the thoroughness in which irrigations and aspirations are done, and with over 50 cases to be irrigated from 4 to 8 times in 24 hours it is easy to see that organization and sufficient help are important factors in the management of these cases.

The treatment is carried out in the following manner:

After a diagnosis of pleural effusion has been made, the pleural cavity is aspirated with a syringe and the specimen sent to the laboratory. Those cases who are still suffering from pneumonia and are in a critical condition, are not moved from the medical ward until one or two aspirations have been made. In the meantime a report has been made from the laboratory, giving the type of organism in the fluid. Those cases with hæmolytic streptococcus are sent to the streptococcus empyema ward and those with pneumococcus are sent to the pneumococcus ward. All cases in these wards are kept on the porches.

The frequency of aspirations is dependent on the rapidity with which fluid re-accumulates. In the hæmolytic streptococcus cases, while the fluid is serofibrinous it accumulates very rapidly. Often two and occasionally four aspirations are necessary in 24 hours. This is especially true if there is a pneumonia or purulent bronchitis present on the opposite side when every bit of available lung tissue is necessary. In the course of a week or ten days the fluid accumulates slowly, at which time aspirations are done every third or fourth day. In the hæmolytic streptococcus cases, the fluid now becomes thick and creamy in consistency and is usually of a slightly greenish tinge. Aspiration by means of a needle even of large caliber becomes difficult and it is then time to do a trocar thoracotomy. In cases of bilateral empyema, aspirations are continued even longer.

In the meantime stereoscopic X-ray pictures have been taken one or more times and a definite idea obtained as to the extent and character of the cavity. The progress of the

patient is often stormy during this period and as mentioned before, pneumonia is usually present during this time. There is usually a marked improvement following each aspiration.

TROCAR THORACOTOMY

The principle upon which I have based the trocar thoracotomy technique is that of preventing ingress, but allowing outlet of air from the pleural cavity.

The matter of allowing air into the pleural cavity is not a serious one after the empyema cavity has become walled off, and yet I feel that in those instances, especially with rib resections where there is a continuous rush of air in and out of the cavity, patients do not do as well as they should.

Any method of drainage through the chest wall is bound to leak air after a few days. This method, however, prevents leakage of air for a week and often much longer and even after that, it acts as a valve allowing the air to escape freely but allowing very little to enter.

The location and limits of the cavity having been established, a site for the thoracotomy is selected. It is unnecessary to select the most dependent portion of the cavity, as the tube passes to the bottom of it. If possible a site is selected near the anterior axillary line. This is done because the heavy muscles of the back are avoided, thereby reducing discomfort and pain from the tube and dressing. The wound is also kept in better condition.

With 5 per cent procaine and adrenalin, dermal, subcutaneous and intercostal anæsthesia is produced at the site of operation. The skin is then punctured with the point of a scalpel, sufficiently to allow a snug passage of the trocar. This puncture wound is made at least one inch below the upper border of the rib or in other words over the interspace below the one to be punctured. The trocar and cannula with a tube inserted (Fig. 1), are then passed through the puncture wound and upward over the outer surface of the rib, until it reaches the upper margin of the rib. When the upper margin of the rib is reached the tip of the trocar is pointed inward and hugging the upper margin of the rib closely, thereby avoiding the intercostal vessels, it is forced into the cavity.

The trocar is then withdrawn from the cannula sufficiently to allow the Dakin tube, which is held in the extra arm of the cannula (see Fig. 2), to be pushed into the cavity. The rubber fittings about the outer ends of the cannula prevent any air from entering the pleural cavity about the trocar or tube. The outer end of the tube has been clamped before, and when it has been inserted deep enough into the cavity, the cannula is withdrawn over it. The tube is then clamped near its entrance into the skin thereby allowing the clamp to be removed from the outer end, when the cannula can be slipped off from the tube entirely.

A 50-cubic centimeter Leur syringe is then attached to the tube and the cavity aspirated. The cavity is then irrigated with normal saline solution. If the patient does not cough, Dakin's solution is used. Only a very few cubic centimeters are injected at first. This is done because of the fact that, occasionally, there is a pulmonary fistula connecting with the cavity, through a ruptured subpleural abscess. In this case, the Dakin solution enters the lung and a severe attack of coughing is caused. If this be the case, the solution is discontinued and salt solution or no irrigations are used. This condition, however, is not very common and irrigations with Dakin's solution are continued until the fluid returns clear. When the syringe is detached the tube is always clamped, thereby allowing no air to enter the pleural cavity.

The tube is attached to the skin by means of two linen threads fastened to the skin with adhesive. The tube is then passed through a 10-inch square cotton pad. This is covered with another and these are held in place by adhesive.

Patients are irrigated with Dakin's solution from 6 to 8 times in 24 hours. Irrigations may be done by removing only the outer pad. Each irrigation is continued until the solution returns perfectly clear. A small quantity, 5 to 30 cubic centimeters, is allowed to remain in the cavity.

The use of Dakin's solution to irrigate these cavities is undoubtedly of great value. In those cases, however, with pulmonary fistula, Dakin's solution can not be used. Even a few cubic centimeters passed into such cases is sufficient to set up a severe attack of coughing and the patient will say usually that he feels as if he were being strangled. In these cases the cavity is irrigated with salt solution and the patient is made to lie on the side involved.

We have used optochin (ethylhydrocuprein) in 1 per cent solution in pneumococcus cases, especially in those who have pulmonary fistula. Results have been better than where salt solution was used but not as good as in those cases where Dakin's solution was used.

A few days after thoracotomy has been done, patients are given blow bottles. The amount of this exercise is controlled entirely by the patient's condition. At the end of two weeks, at which time the patient is usually in good condition, he is blowing the bottles from eight to fifteen times daily. That is, he has emptied from eight to fifteen gallons of water during the day. From X-ray controls we have found that these exercises undoubtedly aid in the expansion of the lungs. After a few days of irrigation the fluid from the cavity becomes clear, somewhat gelatinous, and then mucilaginous in character.

A specimen is then taken in the morning and sent to the laboratory for a smear count. When the fluid shows no organisms by smear count, a culture count is made. If this is negative, on two successive days, after no Dakin's solution has been left in the cavity for eight hours, the thoracotomy wound is closed.

The patient is taken to the operating room and thoroughly irrigated with Dakin's solution. Under local anæsthesia the fistula is excised very easily. This is done to decrease any danger of contamination of the cavity from infection which might result from the fistula.

Blowing the bottles is discontinued for five days; the two silkworm sutures are then removed, and in a few days the patient begins his blowing exercises again.

NUTRITION

An important factor is the nutrition of these patients. Every effort is made to keep the nutrition up to the very highest point. They are fed frequently. Besides their regular meals, they are given egg-nogs, milk, ice cream or cocoa between meals.

Another important factor is the keeping up of the morale and consequently a good appetite of these patients. Constant attention to those things which make them happy and comfortable is very necessary. First of all in cold weather it is important to be constantly on the watch to see that they are well blanketed. Games and music by means of a Victrola were supplied occasionally. Above all a discussion of cases, either by nurses and officers in the presence of patients was never tolerated. Another point which is so often overlooked: Whenever a patient entered a ward *in extremis* and the prognosis was grave, he was not put in a small room inside because he was expected to die, but was put on the end porch with plenty of fresh air, but isolated from the other patients. It is remarkable what effect one death in a ward has on the morale of the patients. When patients were convalescing they spent part of their time folding dressings and reclaiming washed gauze. Another point which adds greatly to their comfort and for which they are probably most thankful is regular shaving and a haircut. Convalescents were used for this purpose. In other words the ward was made a happy community, every one helped his neighbor and the result was happy patients with a good appetite.

The only control of their metabolism was their general condition and weight. They were weighed regularly every week. Gains as high as eight pounds a week have been recorded.

After patients were strong enough to take exercise, they were put in classes and given breathing exercises twice daily. They have all left the hospital in the best of health and spirit, some weighing more than ever before and pictures of health.

Of the series treated during the early summer months I have found by correspondence that they are feeling very well and there

have been no recurrences. Of those cases on whom resections were done, five have recurred to my knowledge.

SUMMARY AND CONCLUSIONS

Summing up the subject of empyema as I have seen it at Camp Pike Base Hospital, I would say that it, together with pneumonia, is the condition demanding the most attention and care. The cases have come usually in waves and at times when the hospital was severely taxed both for help and space. These waves have followed epidemics such as measles and influenza which had undermined the health of the men.

Under conditions such as these, the factor which was of vital importance was organization, in other words team work. With the ever changing personnel this was doubly necessary, with vigilance both day and night.

Prophylaxis. Nothing probably has been so thoroughly proven relative to this subject, as the importance of crossed infections in pneumonia, empyema, both during their primary infection as well as later.

Therefore, all hæmolytic streptococcus infections as well as carriers should be isolated. If not pneumococcus cases may develop hæmolytic streptococcus pneumonias. The same is true of pneumococcus cases of different types. They should be separated so that a type II pneumococcus does not contract a type IV pneumococcus pneumonia, *et cetera.* If this is carried out in the contagious wards, the percentage of hæmolytic streptococcus pneumonias and purulent pleuritis will certainly be extremely small.

TREATMENT

The treatment of purulent pleuritis resolves itself into two phases, the *early phase* when pneumonia is still present, and when the presence of infected fluid in the pleural cavity is only a menace, when in quantities large enough to embarass respirations or heart action, by displacing the thoracic viscera. A small quantity of fluid may be of benefit to the inflamed pleura by separating it, and also splinting the lung. During this stage aspirations should be done. They should be done with the greatest care to avoid injuring the lung and producing a pneumothorax.

In my estimation aspiration increases to some extent the formation of pockets, but this even is of less danger than an early pneumothorax, whereby the lung is often completely collapsed. If pockets are produced, they can be easily taken care of by the trocar-cannula method.

The late stage. When the fluid has become distinctly purulent and as mentioned above, the pus has become walled off, it is time to do the trocar thoracotomy. This should be done according to the technique as described above.

Blowing against positive pressure with the blow bottles is of distinct value in aiding the expansion of the lungs.

Patients must be kept out of doors and warmly clothed.

Nutrition is highly important. Hæmolytic streptococcic cases become emaciated very rapidly. Keeping them in a happy frame of mind improves their appetites and hastens their convalescence.

Dental hygiene. Care of the teeth and mouth was insisted upon.

Medication. Digitalis was not used. In cases of failing heart action ice bags were placed over the precordium and camphorated oil given subcutaneously.

Glucose in a 25 per cent solution was given intravenously in those cases entering the wards with a pneumonia and showing signs of dehydration and acidosis. This solution as well as normal saline was prepared in 500-cubic centimeters Erlenmeyer flasks. This method is very simple, rapid and a distinct improvement over many others. Two hundred and fifty cubic centimeters were given in one hour and this repeated in 12 hours until the patient showed considerable improvement and was taking sufficiently of liquids by mouth.

Liquids. Patients were required to take liquids in the form of water, milk, and lemonade very freely, especially during the early stages.

Tonics. Iron, quinine and strychnine were given in all cases to improve their appetite.

Exercises. After the wounds were closed and the patients were well along to convalescence, they were put in classes and given breathing and setting up exercises twice daily, which was gradually increased. They were then also given light ward duties, such as looking after the blow bottles, shaving, *et cetera.*

CONCLUSIONS

Constant attention and the very best of care are absolutely necessary on the part of the doctor, nurses and corpsmen to get good results in the treatment of purulent pleuritis.

The trocar-cannula thoracotomy followed by the insertion of the Dakin-Carrel tube, according to the method I have described affords the following advantages:

1. The operation is very simple and can be done with the patient in bed as easily as can a paracentesis (see Fig. 5).

2. If done properly, no air enters the pleural cavity for several days.

3. Because of the flap-valve character of the opening, air passes from the pleural cavity much easier than it enters; consequently there is a continuous automatic production of negative pressure in the cavity, at least relative if not absolute as compared with the normal.

4. Dressings are never soiled and therefore they give the patient very little discomfort.

5. In cases with multiple pockets and pus in inaccessible places it is very advantageous (see Figs. 3 and 4).

6. There is no resultant deformity of the chest (see Fig. 6).

7. Convalescence is rapid and no recurrence has occurred.

Dakin's solution is of distinct value both for its antigermicidal properties as well as solvent action in these cases. It not only dissolves the exudate but aids the expansion of the lung by quickly removing the heavy plaques of fibrin from the pleural surface and preventing a fibrous thickening of the pleura.

Note.— The tube may be attached to a combined suction and irrigating apparatus.

Since this report was submitted twelve more cases have been treated by the trocar-cannula method with excellent results.

OBSERVATIONS ON EMPYEMA

By J. GARLAND SHERRILL, A.M., M.D., F.A.C.S., Louisville, Kentucky
Lieutenant Colonel, Medical Corps, U. S. A.

THERE is no subject of more importance for the consideration of the profession at this time than that of empyema. The virulence and extent of the epidemic of the past winter, with its high ratio of incidence and excessive mortality at the height of the epidemic, make it a problem not only for the army but for the civil population as well.

It has been the experience of most surgeons in civil practice that patients suffering from empyema usually get well, and the problem has not been to obtain recovery from the immediate illness, but to prevent the condition from becoming chronic and resulting in a persistent fistula. This to some extent has been due to the fact that in civil practice these patients come to the surgeon after they have passed through an attack of pneumonia, and attention has been called to the pleurisy by the persistence of the fever and the respiratory distress. The physical signs at this time conclusively show the presence of fluid in the thorax, and no great diagnostic acumen is needed to determine the presence of pus. In thoroughly equipped hospitals, and particularly those of the army where every laboratory facility is afforded, the diagnosis is made so promptly that the fluid in the chest may scarcely show a discoloration from the presence of the pus-producing organisms. Because of this fact there has been a tendency to open the chest or begin other surgical

measures immediately while the pneumonic process has not completely subsided. The natural result of this early intervention has been a high rate of mortality, so high in fact that it is far above that seen in civil practice prior to the present epidemic. The early intervention, however, does not entirely explain the high mortality, for in civil hospitals there has also been an increase in the death rate from this affection. In fact, some of these patients come into the hospital with a purulent peritonitis in addition to an empyema; pericarditis is a not infrequent accompaniment, and a few cases may show small multiple furuncles in the skin, endocarditis, arthritis or otitis media; and in some where this is not the case the patient is immediately overwhelmed.

It is necessary, therefore, to look further for an explanation of the severity of the infection. A particular form of organism first suggests itself as a cause, but the bacterial flora found were streptococci, pneumococci, and staphylococci, — well-known strains of pathogenic organisms. There were found in these cases, however, a preponderance of the type of streptococcus which has the power of producing hæmolysis, the streptococcus hæmolyticus, which seemed to have an unusually toxic effect. The mixed types were also found to produce particularly severe results. In the latter part of the epidemic there seemed to be a considerable diminution in the virulence of the infective organism, the streptococcus hæmolyticus at this time being no more virulent apparently than other forms. This at least was my observation, as I recall five cases occurring in the late spring in which this organism was found, without mortality.

It is not fair to compare the high death rate in the early weeks of the epidemic or at its height with that of its decline, since all epidemics end by such a decline in the virulence of the infective organism. It is fair, however, to compare two methods of treatment when applied side by side, and also when one plan has a persistently high mortality and another employed immediately and almost coincidentally shows a very low death rate or none at all.

When I was first placed in charge of the empyema ward at Camp Sherman the mortality was depressingly high, notwithstanding the fact that one of the approved methods of treatment was being employed. This was so noticeable that I asked myself the question whether it was as good as the plan so long in vogue in civil practice. Up to this time aspiration repeated at intervals had been tried and abandoned, thoracotomy with the employment of Carrel-Dakin fluid being the method then used. It is but fair to say that there was a slight but not material difference in the technique from that which I had observed at the Rockefeller Institute, in that two tubes large enough to admit in the lumen of each a Carrel tube, were inserted through a thoracotomy wound, and through the latter the antiseptic solution was instilled. In every other detail the treatment was as directed at the Rockefeller Institute. These patients did fairly well for several days, the amount of the discharge was lessened, and no appreciable odor was found about the ward. The bacterial count apparently was diminishing from day to day, but it seldom remained low long enough for one to feel safe in attempting to close the chest wound. I saw several wounds closed in from nine to twelve days at the Rockefeller Institute with apparent success. The fluid was checked properly and carefully by the laboratory force so that its strength and alkalinity were known to be all that could be desired. Notwithstanding this fact a number of these patients who apparently had been doing fairly well began to show gradual prostration, slight irritation about the wound which appeared as a brawny, glazed, toughened skin, and a thickened, dry pleura. The secretion from the chest was greatly diminished and in a short time ceased entirely. It was found that only by the immediate discontinuance of the treatment could the irritation be checked. If the treatment was continued these patients became weaker, suffered from nausea, pain in the chest, vomiting, with a temperature normal or slightly subnormal, finally dying in exhaustion. In similar cases, where the treatment was immediately discontinued on the first sign of irritation, recovery followed. These results induced the conclusion that the use of a 2

per cent solution of formalin in glycerine, a method which had been employed for some years in old cases of empyema, would be more efficacious than the Carrel-Dakin fluid, and it was at once substituted.

The results following the change of treatment were very striking to those who had not been familiar with this method. It had been employed by us so long and with such satisfactory results that we pictured just what it would do. The mortality promptly fell from over 50 per cent to 5 per cent, a remarkable difference. With this result it was no difficult matter for us to have the old method of John B. Murphy tried, consisting in the removal by thoracentesis of the pus from the pleural cavity, and through the same syringe to insert one ounce of glycerine and formalin. This is readily accomplished without pain or much distress, and should be repeated every third or fourth day until the fluid is perfectly clear and sterile.

To one not familiar with the change resulting from this simple treatment the result is spectacular. After the first treatment there is an immediate change in the color of the fluid and a very small amount of pus collects at the bottom of a test tube in which collected; on the second treatment the fluid becomes clear but rather deeply pink; and usually after the third treatment the fluid is a clear yellow sterile fluid. The quantity shows a gradual reduction, and although there is immediately after the injection an increase of fluid in the chest, it is rapidly diminished by absorption.

The advantages of this method are very apparent even to the most casual observer. There is no necessity of an open wound, and with care the slight danger from tapping need not be considered; the recovery is more rapid than by any other method, and it does not leave the chest impaired because the affection does not become chronic and pleural adhesions do not cripple the lung.

There are one or two other points worthy of mention: First, the solution must be made the day before it is used, because it takes eighteen hours for solution of the formalin in the glycerin, and if the injection is made into the pleura when there is a connection between the cavity and a bronchus a very distressing cough will be excited. The patients so treated begin at once to show improvement, their appetite becomes voracious and they take on flesh. If the bronchus communicates with the pus cavity, simple tapping may be employed or an open operation done, since cough and dyspnœa are excited by fluid entering the bronchus.

A most simple method of applying an antiseptic to the chest cavity has been devised by Captain A. E. Mozingo who had charge of the empyema ward at the Walter Reed General Hospital during and prior to my service there. This consists of a stab wound made in the eighth interspace just large enough to admit a small drainage tube. After the tube is inserted the chest is freed of its fluid by means of a suction syringe and negative pressure. The tube is fastened to the chest wall by a safety pin and kept closed by a serrefine. Captain Mozingo developed this method to employ Carrel-Dakin fluid, which was instilled every two hours, left for fifteen minutes, and then withdrawn, the pleural cavity being kept under negative pressure. I consider this to be one of the best methods offered for the application of any antiseptic, but suggested to Captain Mozingo that a large trocar carrying a small catheter through its lumen would make the installation of the tube even simpler, and do away with repeated aspirations and the pain, etc., incident thereto.

Some patients remain in the hospital as long as one hundred and twenty days under the Carrel-Dakin method which allows the disease to become chronic, a condition that can be avoided by the formalin method. Particularly is this true where the method of Murphy is successful, since these cases are relieved so promptly that there is but little opportunity for pocketing of pus by formation of adhesions. Graduated breathing exercises will materially aid in the expansion of the lung. This is a valuable measure also where the open operative procedure has been employed.

I wish particularly to emphasize the necessity to use every effort to avoid chronicity and sinus formation. After satisfactory drainage is established the lung should expand promptly, and when it fails to do so after

suppuration is checked by formalin and the fluid becomes clear, then prompt and radical measures are indicated. Only by the prompt adoption of such plan can these patients be brought to a recovery within a reasonable time. Some of them will recover with a chest greatly crippled, and these are the cases in which treatment has been delayed. Such patients as this latter class rarely make soldiers fit for full duty. Many of those treated early and properly may be promptly brought to a duty status, that is within three to six weeks; cases running as long as two to four months are always more or less crippled in their respiratory function.

It would be unwise to leave this subject without placing emphasis upon the fact that some cases are fatal from the inception of the disease. All serous membranes may be involved and the patient die of an overwhelming toxæmia for which neither medical nor surgical skill offers at present any satisfactory remedy. It is doubtful if, in the presence of pericarditis, peritonitis and empyema combined, anything more in an operative way is justifiable than aspiration followed by the injection of formalin, and in some of these cases where the toxæmia is terrific it may be well to defer this measure until the patient adjusts himself somewhat to the combat. Certain it is that distressing dyspnœa or cardiac distress is sufficient reason for aspiration, which must be done slowly and with care in these serious cases. It should not be repeated with such frequency as to tax the patient's strength or to deplete him because of the loss of large amounts of fluid. No matter how carefully done there is always the possibility of contamination of a simple pleural effusion.

The open operation has one advantage in suppurative pleurisy, and that is in the ready removal of the large masses of fibrinous lymph so often seen. This is particularly the case where rib resection is done. The Carrel-Dakin fluid also will probably remove this lymph because of its solvent action upon animal structures. It has seemed to us possible that this solvent action after the lymph was removed continued in a destructive way upon the pleura itself. It is an established fact that it acts in this way on the peritoneal structures. We were not permitted by autopsy finally to determine this point, but hope to do so experimentally when the occasion permits. In some chronic cases where the Carrel-Dakin method had failed and subsequently formalin had been ineffectual, it was evident that pus pockets and a rigid lung existed, and rib resection was necessary. This step should be undertaken as soon as it is evident that healing will not occur without it.

My observation of over one hundred cases in army hospitals leads me to recommend the following as the most satisfactory plan of treatment yet offered:

1. Diagnostic tap as soon as the presence of fluid is suspected. This should not be repeated with unnecessary frequency, owing to the likelihood of the development of empyema. If the fluid is at all cloudy, an injection of one ounce of a 2 per cent formalin solution is advisable at this time, a culture of the fluid being taken before injection.

2. If there is evidence of pus in the chest cavity, aspiration with the injection of one ounce of a 2 per cent formalin and glycerine should be made. This solution should stand for 24 hours before use, because it takes sixteen hours for a complete solution. This injection should be repeated every third day, the pleural fluid having been removed prior to the injection. Care should be observed that the aspirator needle is in the pleural sac, otherwise considerable pain will result from injection into the soft tissues of the chest wall. Within a week this method will usually clear up the purulent condition and with the assistance of breathing exercises will promptly restore the patient to a duty status. The great advantage of this method, which was first proposed by John B. Murphy, lies in the fact that the condition does not become chronic and therefore the lung does not remain collapsed but distends to fill the chest cavity as the clear serum, remaining after treatment, is absorbed.

3. Failure to clear up the pus by this method may be followed by open operation, either thoracotomy or costatectomy, which can usually be accomplished under local anæsthesia. However, I have found that the ad-

ministration of chloroform in no way prejudices the chances of recovery. Open operation should not be done until the pneumonic process has subsided. The objection to thoracotomy lies in the fact that close proximity of the ribs impairs drainage and makes likely rib necrosis from pressure of the tube.

4. Cases which come to the service and are already chronic with pleural adhesions and pocketing of pus cavities, will demand the removal of portions of one or two ribs and the separation of the pleura from the chest wall by the hand of the operator. The insertion of some form of drainage, which will provide for a negative intrathoracic pressure, should be employed. I have found the combination consisting of a stiff rubber tube, one-half inch in diameter, connecting with a collapsible rubber tube, just large enough to fit over it snugly, draining into a bottle, to be most satisfactory. This allows the escape from the chest of pus and air but prevents any air entering through the tube, making an automatic pump which permits the gradual distention of the lung and obliteration of the suppurating cavity.

5. The use of the Carrel-Dakin fluid will remove the large amounts of lymph which are so frequently found in these cases. It will diminish the odor, lessen the discharge, and oftentimes entirely sterilize the cavity. This will permit closure of the wound, as soon as the bacterial count shows the cavity to be surgically clean. I do not think it has any advantage as an antiseptic in these cases over formalin and glycerine. A valuable method of its employment is the insertion of a small rubber tube through a stab wound which will diminish the necessity for dressing and enable one to put in the chest cavity any antiseptic solution which may be desired and to withdraw the same, at the same time establishing negative pressure within the chest. (A. E. Mozingo, Captain, M. C.)

6. In the very old cases, one of the well established very radical operations should be employed but only after the injection of formalin and glycerine into the chest pockets and plugging of the drainage tract, as this will in the great majority of cases result in a cure.

7. Beginning just as soon as the patient is able to be out of bed, graduated exercises should be employed to encourage the distention of the lungs. This I consider is one of the most valuable portions of the treatment.

NEGATIVE PRESSURE VERSUS FREE OPEN DRAINAGE IN THORACIC EMPYEMA

By J. CHRISTOPHER O'DAY, M.D., F.A.C.S., Honolulu, Hawaii
Formerly of Portland, Oregon

NEGATIVE pressure drainage has for its object certain phases that do not belong to the ordinary methods of drainage and which by some of its advocates are believed to be of considerable advantage in attaining ultimate results. These advantages may thus be enumerated: It reestablishes and maintains the normal relation between the lung and the affected cavity during the time drainage is necessary and when no longer necessary to have left the lung capable of filling the space it filled prior to the onset of the infection; it prevents pneumothorax; it prevents the likelihood of introducing secondary infections.

When should thoracic empyema be drained?

What are all the factors to be considered?

How should it be drained?

If we can become impressed with the truth that each case of thoracic empyema has peculiarities of its own, it will bring us to realize that the greatest success can only obtain with a plan that may be adjusted either to establishing or delaying drainage according to the exigencies presenting.

With an unresolved pneumonia of the op-

Fig. 1. Semidiagrammatic illustration of the bronchi of the lung, etc., representing the greater number of square inches of surface.

posite lung, drainage, especially a drainage that might admit air, might be hazardous. This class of cases argues strongly in favor of negative pressure drainage; yet, the inevitable mishaps, likely in opening the chest, expose the patient to a risk that had better be avoided by the aspirating of such quantities as are necessary to relieve the pressure until resolution of the opposite lung has taken place.

While this delay in the establishment of adequate drainage may jeopardize the integrity of the lung of the empyemic side, the risk is justified because it is selecting the lesser of two existing evils. In that class of cases where the lung of the opposite side is free from any involvment, all else being equal, nothing is to be gained by delay.

We are now squarely to face with the consideration of the kind of drainage to be employed. Should it be free open, a stab wound or negative pressure? Seriously, then, what are all the factors to be considered before deciding upon the precise way the drainage should be made?

Experiments[1] by me to ascertain the difference in the duration of a pneumothorax produced by nitrogen gas and one by atmospheric air, demonstrated that the normal lung may be kept in a state of collapse for months without losing a particle of its elasticity. This is not true of an infected or inflamed lung, for an inflammatory or infectious process, with its inevitable exudate, infiltrate, and subsequent fibrosis, if allowed its way, ties the lung from within and so thickens its cortex that re-expansion will never again meet the confines of the original respiratory excursions. Indeed, may I add that it is to this very fibrosis that pneumothorax in the obliteration of tuberculous cavities owes its success.

When drainage, for any reason, has been deferred and the mischief of the delay has been imposed, the resulting thickening of the cortex, together with whatever degree of impairment has befallen the normal elasticity of the lung itself, must, in the very nature of the pathology attained, bear a direct relation to the length of time in which the delay occurred. Upon this alone will the size of the dead space between the two pleuræ depend, and, once this dead space has been established, no scheme of negative pressure will be capable of drawing the fibrous or inelastic lung into former relations.

All streptococcic pneumonias do not result in thoracic empyemas. An abscess may form adjacent to a bronchus and even rupture into it, but pyogenesis within the chest comes only as an evidence that the infection has found its way to the periphery. Nor is it necessary that the entire periphery be involved before the pyogenesis begins, for a comparatively small

[1] Internat. J. Surg., 1911, Nov.

area has been observed in association with the entire cavity filled with pus. It may be well, at this juncture, to remember that the mere coming in contact with pus does not cause the pleura to thicken or become fibrous. Such a change can occur only within the area where the infection has found its way to the cortex. Often such areas are segregated by a zone of inflammatory adhesions between visceral and parietal pleuræ, localizing the subsequent abscess and often giving rise to the multiple cavities whose presence have infrequently baffled the skill of the best.

THE PNEUMATICS OF THE LUNGS

To compute the power of a given pressure of gas, steam or air the number of square inches of space and surface must be included. For example, if the bore of an engine's cylinder is twenty-four inches in diameter, that engine has a greater power than one with a cylinder whose bore is but twelve inches. The difference in the number of square inches determines the power. My alluding to this bit of scientific mechanics is to emphasize the fact that the same principle reckons with the inner and outer surface of the lung. The number of square inches represented by the manifold bronchi, bronchioli and alveoli are greatly in excess of those representing the surface. It is this, plus the normal elasticity of the lung, that makes complete collapse of the lung impossible with a plus pressure pneumothorax. It is also the excursion of exaggerated respirations lengthening the excursion of the collapsed lung to the approximation of the chest wall. This is where we have an advantage in conserving the lung's elasticity during the period it is threatened, but to gain this advantage all prejudice toward a free open drainage will have to be set aside.

We know that the pathology resulting from thoracic pyogenesis is destined to distort the lung and whether that lung is left in a state of partial collapse or kept fully inflated by the application of negative-pressure drainage, the same fate will befall it if exudate and infiltrate organizes while it is immobile, the ultimate result being that in the one case the lung cannot properly inflate while in the other it will be unable properly to compress.

Fig. 2. Case 1.

CHRONIC THORACIC EMPYEMA

In dealing with the old cases our course is usually clearly marked. We may be quite right in looking forward to finding a considerable dead space. A chronic fistula is to be no surprise. Lastly, we may find it necessary to perform an Estlander or a Schede to close the space and cure the fistula. All this is stereotyped treatment for this all too familiar result of empyema of the chest. It is also good treatment, but much of it might be prevented by a more judicious application of drainage in the beginning. But in the recent cases—the cases recognized before aught has impaired the lung's integrity—what, then, should be our method of attack? It should be one capable of preventing or minimizing the impairment of function inevitable to the process we know to be going on. This is the time when the whole crux of the situation should be squarely met and whatever is decided on as the best can only be the best if resting on a painstaking consideration of every factor involved; moreover, it makes for the best there is in surgery by forcing our mind into an attitude whereby it is unwilling to become indifferent to conserving the lung's function so soon as pus is made to appear at some point of opening. The integrity of the lung cannot be safeguarded in the presence of inadequate drainage. The lengthened excursions of exaggerated respirations are only possible with

Fig. 3. Case 2.

wide open drainage and to them alone must we look for the preventing of the exudate and infiltrate organizing *en masse*. Another important advantage of free open drainage is observed with each forced inflation. The outward excursion gathers up and sweeps the pus to the outlet.

WHAT CONSTITUTES FREE OPEN DRAINAGE

The walls of the usual abscess are, as a rule, self-collapsing after incision. We recognize the exception in the abscess of osteomyelitis. We, too, are only too well acquainted with the methods that have been put forth to aid in the closing of inelastic or uncollapsible bone cavities. We know the shortcomings of every method expounded. We know that early drainage prevents the destruction which gives rise to these cavities, "a gimlet hole," as Murphy used to put it.

Chest abscesses are not unlike the abscesses of bone cavities. They will not fall together after incision. Upon the conservation of the lung's integrity alone should the issue be met. Drainage must not be haphazard; it must be definite, and definite to a purpose, i. e., free enough that no resistance is offered the outward excursion of the lung by the escaping contents having to compress against the increased velocity of too small an opening, for just so soon as compression of surrounding air or pus begins, the advantage to be gained, by

Fig. 4. Case 3.

the bronchi of the lungs representing the greater number of square inches of surface, is immediately lost.

CASE 1. Persistent pyrexia, after drainage made by the usual rib resection, bespoke the presence of isolated cavities. An opening large enough to insert the hand enabled finding and opening three segregated areas. Following this procedure the temperature soon became normal and recovery was rapid. A small fistula persisted a few months.

CASE 2. Most unusual. Every symptom of thoracic empyema, confirmed by aspiration, present. Upon opening the chest no pus was found. Introducing a finger the visceral pleura was felt to be thickened and bulging over a fluctuant mass. An opening large enough to admit the hand was made. The lung was unwilling to collapse. No respiratory movements were noticed. There were no adhesions between visceral and parietal pleuræ notwithstanding pressure contact. The abscess was large and subcortical. The thickened cortex was made to herniate through the opening. In 24 hours it was freely incised and drained. Recovery.

CASE 3. Traumatic pneumonia result of fall through elevator shaft. Complete consolidation of left lung. Partial consolidation of the right. Before resolution was completed in the left lung, pyogenesis began in the right chest. Aspiration was resorted to, it being believed unsafe to open and drain in the presence of the unresolved condition of the opposite lung. Several ounces of pus were withdrawn. No further drainage became necessary as both sides, from the time of aspiration, progressed to complete recovery. Note the equal sides of the chest.

THE EMPYEMA PROBLEM[1]

By EMIL G. BECK, M.D., F.A.C.S., Chicago
Surgeon to the North Chicago Hospital

THERE has never been a greater opportunity to study empyema than at the present time. The country is passing through a second epidemic of pneumonia, the consequence of which is the accumulation of a very large number of cases of empyema and lung abscess. The first epidemic in the fall of 1917, lasting through the winter, was largely confined to the military camps and was mainly due to the streptococcus hæmolyticus, often associated with the pneumococcus. The second and more virulent epidemic, which began in the summer of 1918, swept the country from the Atlantic to the Pacific and did not spend its ravages on the camps alone but attacked as well the civil population. This epidemic appears to be of a different type from that of the previous year, being preceded in a large percentage of cases with what is now commonly called Spanish influenza.

Previous to these epidemics empyema was not a common complication of pneumonia; lung abscess was more frequent. We were not accustomed to watch for empyema in each case which recovered from pneumonia. It was somewhat surprising, therefore, that during the epidemic in September, October, and November, 1917, at the different camps, there appeared among the soldiers a very large number of cases of empyema after bronchopneumonia. It was evident that we had to deal with an unfamiliar type of infection. Not only were the complications more common but the mortality also was very high, ranging in various localities from 20 to 60 per cent. At Camp Pike they had from September, 1917, to September, 1918, 1285 cases of pneumonia, with a total average mortality of 26 per cent. Empyema complicated 9 per cent of these cases of pneumonia. Similar reports came from other cantonments. It was evident that this was an infection of a more virulent variety than we had treated in previous years. The anatomical conditions of these cases of empyema were likewise different. In the ordinary case of former times, as a rule, the pleural sac was found filled with pus. In the type which occurred in 1917 many cases had multiple, locked-off compartments filled with pus; sometimes abscesses were found in the spleen, liver, and abdominal cavity. It resembled more a pyæmia, with constant pleural involvement. In the present epidemic of influenza, pneumonia in a most violent form, with high and rapid mortality, asserted itself again, and thus we anticipated that empyema might also arise a little later in the recovered cases, and this proved to be the fact. I am informed that at the Great Lakes Base Hospital 250 cases of empyema following the last epidemic have already developed from recovered cases of pneumonia.

We must expect the same complications to follow the cases among the civil population, and in fact they have already begun to appear.

In a report published in the *Journal of the American Medical Association*, November 16, from Camp Sherman (Ohio), of 2,001 cases of pneumonia resulting from 7,618 cases admitted for so-called influenza, 842 died, leaving 1,159 which recovered. The writer of the article stated that at the time of publication only one case of empyema had developed in these 1,159 recovered cases. Suspecting that more cases might have developed since the report, I inquired and received reply from Major A. Friedlander, in which he states that since writing the article there had developed about 150 cases of empyema from the 1,159 which had recovered from the pneumonia.

This indicates that the empyema may develop very slowly and may not be diagnosed until several weeks after the patient had apparently recovered.

We shall learn many new facts from the present epidemic. The reports from the different camps, in which they have had the

[1] Read before the Western Surgical Association, December, 1918; and before the Academy of Surgery, Buffalo, December, 1918.

Fig. 1. Unresolved pneumonia. Upper left lobe involved.

great advantage of treating many cases of the same type by one method, are gradually finding their way into the medical literature and from them we can learn the most. It is somewhat early, however, to make comparative studies, since the reports from many camps are still missing. At the present time we must be satisfied with such analysis of the subject as our present knowledge offers, and in attempting this I shall try to answer the following questions:

1. How shall we explain this unusual virulence and high mortality of the pneumonia and empyema?
2. How shall we recognize an empyema as early as possible?
3. How shall we differentiate an empyema from a lung abscess?
4. What means other than operative may be employed to cure empyema?
5. How shall we proceed with an operation after we have made a diagnosis?
6. What operation is the most desirable, resection of a rib or drainage between the ribs? Local or general anæsthesia?
7. What method of drainage shall be introduced?
8. What shall be done to produce disinfection and closure of the pleural cavity in the shortest possible time?
9. What are the causes of non-closure of drained empyemata?
10. What shall be done with chronic suppurative cases with sinus or lung abscess or empyema, which have persisted in spite of treatment?

Fig. 2. Bronchopneumonia. Left side involved. Note scattered shadows representing small areas involved.

VIRULENCE AND HIGH MORTALITY

Thus far no one has ventured to make a positive statement to explain the cause of

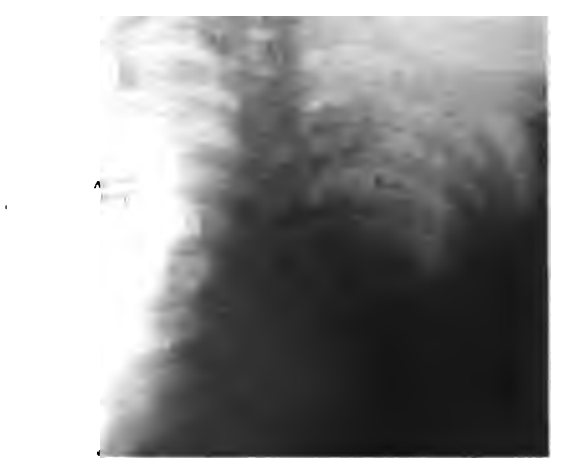

Fig. 3. Right pleura filled with fluid, except extreme apex.

the high mortality and the frequency of complications. The causative factor is not definitely known. It has been suggested that the organism causing the epidemic is an ultramicroscopic one not yet demonstrated, or the influenza bacillus which prepared the body for the pneumococcus and streptococcus invasion. The susceptibility or rather lack of immunity against this new type of infection is another theory advanced. One fact seems to stand out very plainly, namely, that robust adults are more susceptible than the very young children or people above fifty. This is just the reverse of the usual. It is also apparent that persons afflicted with asthma, chronic bronchitis, or pulmonary tuberculosis are more often spared than the perfectly healthy.[1] Alcoholism, which is considered a predisposing factor to pneumonia, cannot be claimed to be so in this epidemic. Young soldiers, rarely alcoholics, and young women are the most susceptible victims. The almost universal fatality in pregnant women also indicates that we are dealing with a new type of disease.

[1]A very convincing illustration of this fact appears in the *Monthly Bulletin of the Municipal Tuberculosis Sanatorium* of Chicago in December, 1918.

Of 1551 cases with pulmonary tuberculosis from six institutions, only 85, or 5.4 per cent were afflicted with influenza, only 8 cases had pneumonia as a complication, and only 1 case terminated fatally. In four of the institutions, as shown in the detailed report, there was not a single case:

	Patients	Incidence of Influenza
Municipal Tuberculosis Sanatorium	587	35
Oak Forest Infirmary	560	50
Cook County Hospital	154	0
Chicago-Winfield Hospital	55	0
Chicago Fresh-Air Hospital	102	0
Edwards Sanitarium	95	0

It is also remarkable that the cases of glandular tuberculosis were more predisposed than the pulmonary cases. Of 154, 46.2 per cent had contracted influenza, thus bringing the pulmonary type down still lower.

Comment upon this report: Is it not likely that the secondary infection in tuberculosis which is usually a streptococcus is the immunizing factor in these tuberculous individuals? Why should influenza spare the pulmonary tuberculous individual and not the glandular tuberculous? Answer: The glandular is not complicated by a secondary streptococcus.

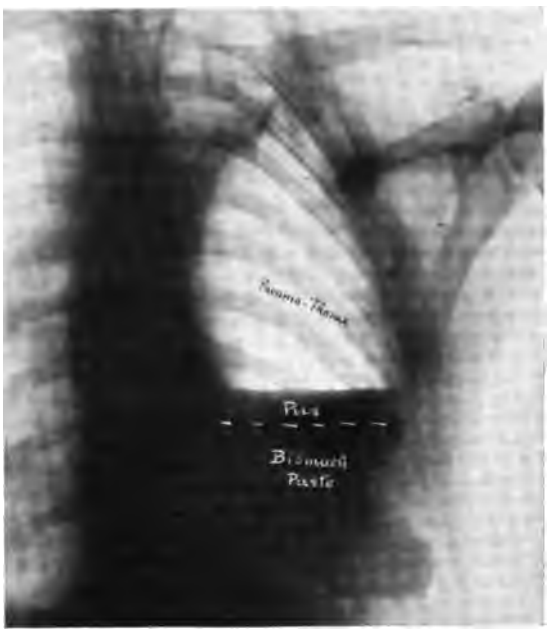

Fig. 4. Empyema. Cavity half filled with fluid, patient in sitting posture. Some paste at the bottom.

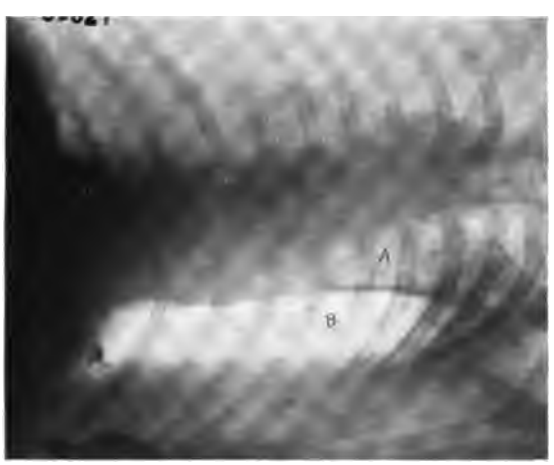

Fig. 5. Same case as in Figure 4. Patient lying on affected side. Note change in fluid gravitation: *a*, retracted lung, *b*, pneumothorax, *c*, fluid at bottom.

Fig. 6. Same patient as in Figure 4, lying on unaffected side. Fluid gravitating toward the middle line: *a*, retracted lung, *b*, fluid, *c*, pneumothorax.

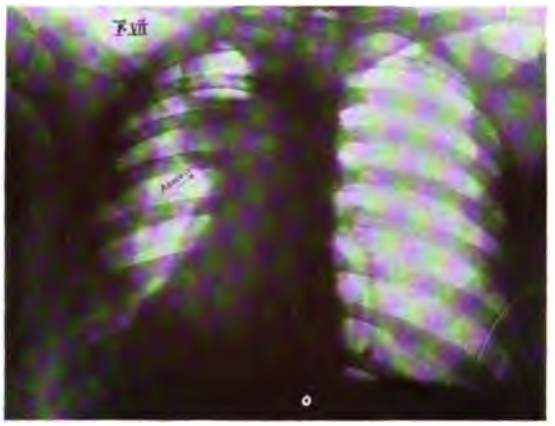

Fig. 7. Lung abscess. Somewhat unusual shape, as though it originated in the mediastinum.

The mortality rate depends largely upon the violence of the initial attack. Those who are unfortunate in receiving a severe initial blow rarely recover; cases have been reported which terminated fatally within 12 hours, from apparently perfect health to a corpse within half a day. These patients seem to die from lack of oxygen rather than from the toxic effect of the poison. The lungs are congested to such a degree that the air cannot enter the vesicles and the patient dies practically from suffocation, or rather from drowning. The heart and kidneys are not sufficiently affected to cause death. Whenever a patient has stood the first shock and bridges over the first week of illness, he has a fair chance for recovery; an index of which is found in the rise of the polymorphous leucocytes in the blood, which at the outset is very low, often as low as 4,000 and gradually rises to 10,000 or 12,000.

That the patient does not die from influenza seems certain. Only 8 per cent of the fatal cases at Camp Custer produced cultures of the Pfeiffer bacillus from the secretion of the cut lung and only 3 per cent from the blood, while 78 cases produced one or the other types of the pneumococcus and 142 cases the streptococcus. It is, therefore, evident that further investigation will be necessary to determine the real cause. Our present knowledge is too meager to establish it.

EARLY RECOGNITION OF EMPYEMA AND DIFFERENTIATION FROM LUNG ABSCESS

It is unnecessary to discuss here the usual physical signs and the part the history bears upon the differential diagnosis. We shall consider only the methods which are corroborative, namely, the stereoroentgenogram and the probatory puncture.

As soon as percussion and auscultation have convinced us that a certain portion of the chest is normal, it is our duty to take a stereoroentgenogram of the entire chest. The following conditions must be considered: (1) unresolved lobar pneumonia; (2) acute active bronchopneumonia; (3) fluid in the pleura, serous or purulent; (4) lung abscess; (5) pneumothorax; (6) acute pulmonary tuberculosis.

The correct interpretation of the stereoroentgenogram in the differentiation of the conditions just mentioned is of paramount importance and for this reason I shall present here a roentgenogram of each type, to demonstrate differential points.

Unresolved pneumonia. A dense shadow corresponding to any of the five lobes, with the rest of the lung comparatively normal, indicates an unresolved pneumonia. Figure 1 illustrates a typical case. We note that the left upper lobe on the side is quite distinctly outlined in contrast to the rest of the lung tissue. An abscess rarely produces a shadow which would correspond to the shape of a single lobe. It would produce transparent areas representing lung tissue around the abscess and possibly show a dense shadow of the abscess wall which the unresolved pneumonia does not produce.

2. *Bronchopneumonia* gives an entirely different picture. At times both lungs are involved and the picture resembles more that of an advanced tuberculosis of the lung. The entire lung, or parts of it, is studded with shadows varying in size from that of a hazelnut to that of an egg; these shadows sometimes merge into one another and leave transparent areas between them (Fig. 2).

3 *Fluid in the pleural cavity.* When the pleural cavity is entirely filled with fluid, the lung is compressed toward the hilus. If no adhesions are present it retracts upward and

Fig. 8. Tuberculous abscess: *a*, formation of abscess wall, *b*, abscess wall not so well defined.

posteriorly. The roentgenogram of this condition will present a shadow resembling ground glass, nearly equal in density throughout the entire area occupied by the fluid. This, however, is true only when the patient is on his back while the roentgenogram is being taken, because the fluid gravitates and covers the entire posterior area of the pleural cavity (Fig. 3). In cases in which the quantity of fluid is not large and the roentgenogram is taken in the standing or sitting posture, we will obtain a characteristic picture: the fluid will gravitate into the lowest part of the pleura and produce a dense shadow up to its upper margin—above that there will be a distinct pneumothorax (Fig. 4). Another roentgenogram taken in the lateral position, namely with the patient lying on the affected side, will produce a shadow corresponding to the level of the fluid along the outer part of the chest, and a pneumothorax between the margin of the retracted lung and the level of the gravitating fluid. This is clearly illustrated in Figure 5. If the same patient is turned on the unaffected side the fluid will gravitate toward the middle line and leave a pneumothorax externally (Fig. 6).

The roentgenogram will give us scant information as to the character of the fluid,

Fig. 9. Pneumothorax. Retracted lung is upward. Cavity below filled with air.

except that the purulent fluid is likely to give a denser shadow than the serous. It requires probatory puncture to settle this question.

4. *Lung abscess.* The diagnosis of a lung abscess is more difficult. A patient may have had an encapsulated pocket of pus in his lung for months and even years before a diagnosis is made. Its location by physical examination is more difficult because it is usually centrally located and, as a rule, much smaller than an empyema (Fig. 7). The tuberculous abscess has a distinct wall and is more often multiple and therefore much more easily diagnosed than that resulting from a pneumonia or other causes (Fig. 8). When a patient gives a history of having suddenly spit up a quantity of pus and continues to expectorate purulent material, the presence of a lung abscess must be considered. After an abscess has ruptured into a bronchus, its localization becomes more difficult still, because the sac has collapsed, and a proba-

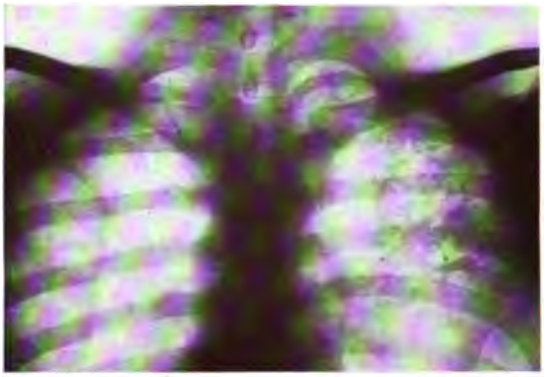

Fig. 10. Roentgenogram showing healed tuberculosis.

tory puncture will in most instances fail to strike the pus cavity.

5. *Pneumothorax.* There should be no difficulty in diagnosing a pneumothorax, as the physical signs are very characteristic, especially the hyper-resonance. The roentgenogram, however, is most convincing. We find here the absence of shadows in a well defined area which means that the lung has retracted and the space is not occupied by fluid but by air which, of course, produces no shadow whatever. Figure 9 illustrates a typical pneumothorax.

6. *Advanced pulmonary tuberculosis* with abscess will in the roentgenogram resemble very much a bronchopneumonia, showing areas of infiltration of different sizes, and thus the history and clinical findings must assist us in our diagnosis. The healed out tuberculous process, however, gives a characteristic picture, namely, an apparently transparent lung with fine linear markings, corresponding to the bronchi, with many small, distinctly outlined shadows of calcified deposits and many concrete shadows resembling snowflakes, which represent the fine scars remaining from a healed out tuberculosis. Figure 10 illustrates such a case

Probatory puncture. The probatory puncture should never precede the roentgenogram, because the latter will assist us in choosing the place for the introduction of the needle. The indiscr minate use of the probatory puncture is a dangerous procedure. One should strike the pus, if it is there, the very first time. I should not advise more than three punctures. If after the third puncture the pus cannot be found, the case should be studied further by other means.

The danger of introducing the needle consists in puncturing healthy lung and carrying the infective material into it and causing secondary abscesses. One might push the needle beyond the confines of a small abscess and thus get no result. In withdrawing the needle one should use some suction at three or four different depths. The pus at times is so thick that it will not flow through a very small calibered needle, thus a suction syringe should always be attached to the needle.

The character of the pus is of great diagnostic value. A smear preparation as well as culture should be made from the same at once and if the fluid is of serous character it should be placed in a test-tube, to see how much sedimentation will occur within 24 hours.

NON-OPERATIVE TREATMENT

The introduction of antiseptics into the fluid within the pleural cavity has been advocated for a number of years. Treatment with 2 per cent formalin and glycerine was introduced by Murphy and has been used extensively by Kreuscher, his former assistant. It is supposed to sterilize the fluid within the cavity, and is gradually absorbed, thus making its withdrawal unnecessary. It seems to produce earlier closure following drainage; one or two cases were cured without opening, and it has made unnecessary extensive thoracic surgery. It cannot be used in children or in cases with tuberculous etiology but gives its best results in empyema following pneumonia or ordinary pleurisy, after the pleuritic effusion has become purulent.[1] The chief objection to the formalin is that it produces a great deal of pain. The method is not extensively employed; the reason for this is not quite apparent.

Repeated puncture and withdrawal of small quantities of the fluid at regular intervals has been found effective by a number of surgeons at the military camps. The gradual withdrawal of the fluid by means of a syringe has the advantage of being comparatively

[1]Dr. Kreuscher's personal communication.

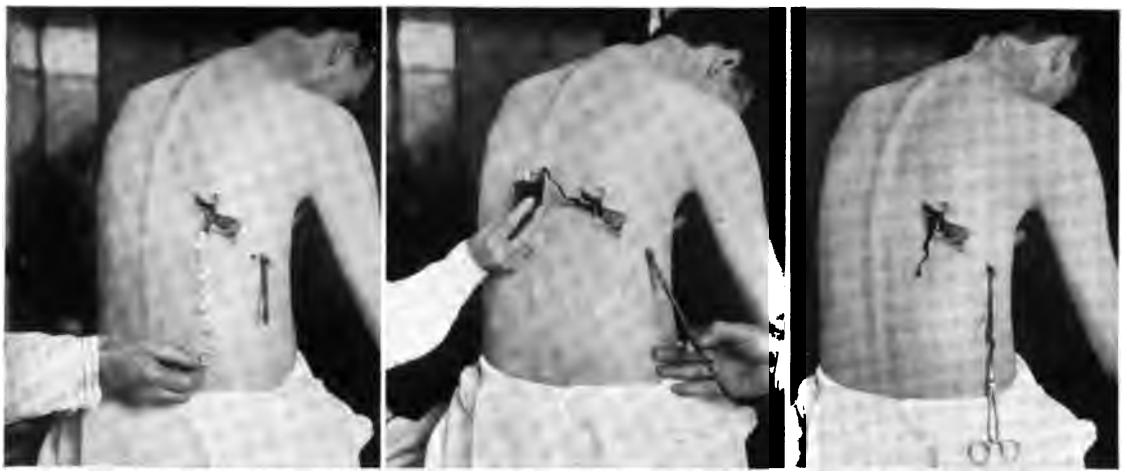

Fig. 11 Fig. 12. Fig. 13.

Fig. 11. First step. Large rubber tube removed. Tape attached to catheter, ready for insertion.

Fig. 12. Second step. Tape soaked in 20 per cent argyrol drawn through both drainage openings by removing the catheter.

Fig. 13. Tape in place, to remain until discharge ceases.

harmless but it carries an uncertainty of a final cure. We cannot hope to withdraw every drop of the pus from the pleural sac and since we are bound to leave a certain quantity, the question must arise in our mind, what becomes of the residue? Will it be absorbed? If nature is able to absorb a residue of pus, why cannot she absorb the entire quantity? The advocates of the repeated puncture method must clear up this point by citing a sufficient number of cases with control of roentgenogram comparative studies.

Vaccine therapy is too large a subject for this paper, but it must be taken into consideration. Personally I have had no experience whatsoever; there are a number of articles, some speaking favorably, others unfavorably, about this method of treatment.

WHEN TO OPERATE

During the present epidemic, we have noted that in the very acute cases of pneumonia a serous fluid, very septic in character, is frequently thrown out into the pleura and compresses the affected lung. This clear fluid will gradually assume a purulent character. If we withdraw about 10 cubic centimeters of this fluid every 24 hours and pour it into a test tube we will note that the sediment of these samples will vary. The amount of the grayish purulent material settling at the bottom of the tube will be greater each day, so that the fluid drawn on the tenth day might contain as much as 30 to 40 per cent of sediment and 60 to 70 per cent of clear serous fluid. It is, therefore, very difficult to say at what particular stage of purulization we shall regard the case as one of empyema. Experience has shown that it is not safe to operate in the acute stages when the fluid is still serous. In the report of the Empyema Commission, in charge of Major Dunham, at Camp Lee, the following statement is made:

"Our observations force us to the conclusion not only that a late operation has decreased the risk of death but also that it has in general been followed by a less troublesome convalescence. Almost without exception the cases in which at the present time there are still large cavities are ones in which operations were performed early. Whether or not the fact that the operation was performed late or in the postpneumonic stage of the disease, has borne a direct relationship to the more rapid postoperative obliteration of the cavity, cannot be definitely answered. The observation may be only a coincidence, but yet it has been so striking as to suggest that a definite casual relationship has existed."

Whether the deduction of the Empyema Commission, namely, that the mortality is

Fig. 14. Roentgenogram showing two separate cavities on the same side: *a*, bismuth paste gravitating when patient is in sitting posture; *b*, abscess cavity in front of the apex, filled with bismuth.



Fig. 15. Long sinus leading into the small pocket in the apex.

due to the sudden pneumothorax, is correct or not, the fact remains that very early operation is dangerous and should not be undertaken. The theory of the pneumothorax alone does not appeal to me as being the great factor in producing the death rate, because the lung had constantly been in a state of compression by the fluid previous to operation. The lung was immobilized by the fluid and the sudden withdrawal of the fluid releases this immobilization and thereby aggravates the condition because at this time the lung is still in an acute state of inflammation. Another cause which might be responsible for the mortality is the operation itself. The resection of a rib, although not very extensive, opens a sufficiently large wound surface for secondary infection and absorption of micro-organisms, which are contained in the apparently harmless fluid (but very septic, in fact usually the streptococcus). The patient has not as yet acquired sufficient immunity against this particular micro-organism. This is not entirely theoretical. It has been proven in a number of cases that where the blood cultures were free from micro-organisms just before operation, positive blood cultures could be obtained 24 hours later. I cite from the article[1] by the Empyema Commission, Camp Lee, Virginia:

"There is great danger of producing a blood stream infection, evidently because of absorption of streptococci from the surfaces of a fresh wound. That this is a real danger is shown by the fact that in two cases of early operation cultures from the blood were sterile before operation, while cultures from the blood taken 24 hours after operation showed numerous hæmolytic streptococci."

It is evident that after the fluid has become purulent, it has lost a great deal of its virulence, at least to the same individual in whose chest it has formed. In other words, it has become cold. We know from experience that the longer pus has been retained within a certain location in the body, the less virulent or toxic it is. We may therefore con-

[1] J. Am. M. Ass., 1918, Aug. 3. 367.

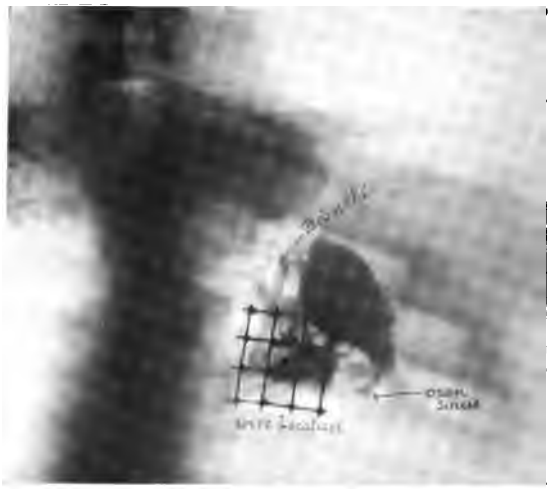

Fig. 16. Roentgenogram showing communication of abscess in the lung with the bronchus.



a *b* *c* *d*

Fig. 17. The four types of syringes generally employed: *a*, blunt tip glass syringe, employed in most cases of sinus; *b*, glass syringe with long nozzle, suitable for empyema cases; *c*, dental metal syringe used in small sinuses about the teeth and for pyorrhœa; *d*, metal syringe, olive-shaped tip, used in rectal fistula and small sinuses elsewhere.

clude, that it is much safer to defer the operation until the fluid has become distinctly purulent, although it is perimissible or even advisable to withdraw small quantities with a small cannula to relieve distressing symptoms.

CHOICE OF OPERATION, ANÆSTHESIA, DRAINAGE

The simplest operation must appeal to us as the most desirable. The method advocated[1] by Major Hugh McKenna, of Chicago, appears to be the simplest. It consists in introducing a catheter size No. 14F. by means of a trocar or cannula, just large enough to thread the catheter into the pleural cavity. As soon as the pus escapes through the catheter the cannula is withdrawn; about 100 cubic centimeters of the pus is then withdrawn by means of an aspiration glass syringe. If the pus is too thick for aspiration, a small amount of neutral solution of chlorinated soda (Dakin's solution) is allowed to run in, which dilutes the pus and renders it easier to withdraw. My reasons for endorsing this method are the following: First, the operation is so simple that the patient takes no more risk than in the ordinary probatory puncture. Second. the wound produced by this operation is so small and the catheter is hugged by the tissues so closely that an infection of the wound is not likely to take place. Third, the fluid can be withdrawn gradually—about 100 cubic centimeters every 24 hours, without allowing any air to enter the cavity, thus preventing a pneumothorax. For this reason a clamp should be placed on the catheter during intervals of evacuation. The lung is likely to re-expand gradually as the amount of fluid within the pleura diminishes. However, even this operation should not be performed in the very acute stages, while the fluid is still serous, because at that stage the lung itself is in an acute state of pneumonia and should therefore remain undisturbed. By permitting a lung which is acutely inflamed to expand, we open widely the door for death. Whether the drainage of pus in the cases thus treated will persist or whether pus will reaccumulate after closure the future only will tell. So far the reports have been very favorable but it is rather early to pass judgment.

The counter-drainage method. At the North Chicago Hospital we have during the past

[1] J. Am. M. Ass., 1918, Aug. 31, 743.

Fig. 18.

Fig. 19.

Fig. 20.

Fig. 18. Technique in injecting pleural sinuses.
Fig 19. Illustrates the application of adhesive plaster around the granulating wound.

Fig. 20. Single drainage before skin-sliding operation (Case 1).

five years employed a method of draining empyema which proved most satisfactory. It was introduced by Dr. George Dohrmann and carried out in some 30 cases, with only 1 death. (A child died suddenly on the fourth day after operation, cause unknown.) The remaining cases closed without any recurrence. The method is the following: A section of about one inch of the eighth or ninth rib is resected posteriorly under local anæsthesia. The pleura is exposed and incised about one-half of an inch. Before any pus can escape, the index finger is pushed through into the pus cavity, thus almost entirely blocking the opening against escape of pus. A curved artery foceps is then inserted along the index finger and directed anteriorly and downward to the lowest point of the empyema cavity. Pressing the tip of the forceps against the inner chest wall, between the ribs, will raise the skin and indicate the place for the counter incision, which is quite easily made under local anæsthesia by the assistant. A soft rubber catheter, No. 12 or 14, is then grasped with the forceps and pulled through. This catheter has three or four small openings in the center. A large size rubber tube is then slipped over the catheter and introduced into the drainage opening of the resected rib. This rubber tube is sewed to the skin, so as to make it airtight. A glass connecting tube is then fitted into the large rubber tube, which drains the pus into a flask, either through suction or natural gravity. The patient is allowed to sit in a recumbent position in bed immediately after the operation.

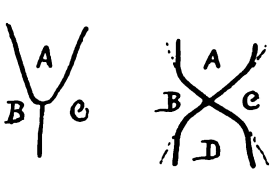

Fig. 21.

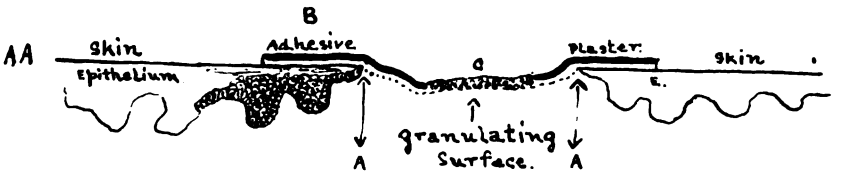

Fig. 22.

Fig. 21. Types of incision in skin-sliding operation: Y-shape incision at left: *a*, long upper flap; *b*, and *c*, obtuse lateral flaps. X-shape incision at right: 4 flaps of nearly equal size and shape.

Fig. 22. Sketch illustrating the theory of the regeneration of the skin underneath the adhesive plaster: *a*, margin of growing epithelium; *aa*, normal skin; *b*, adhesive covering edges of skin and granulation; *c*, granulating surface.

Fig. 23. Microscopic section of new growth of skin two years after formation.

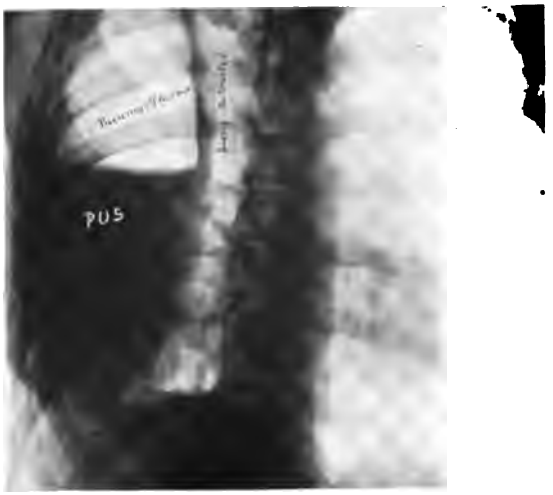

Fig. 24. Roentgenogram of Case 1, showing size of cavity, partly filled with pus. Patient in sitting posture.

Four days later the large tube should be removed; the catheter remains in place and drains from both sides for two weeks. By this time the discharge has usually greatly diminished and we are ready for a new step in the after-treatment.

A tape about one-quarter of an inch in width is attached to one end of the catheter by means of a silk thread and the catheter is withdrawn, thus pulling the tape into its place. This tape then serves as a drain for the cavity, simliar to that of a "seton." The tape is soaked in a 20 per cent argyrol solution before its introduction. This tape is left in the cavity until the discharge of pus ceases, and this has been the result in practically every case in which this method has been employed.

The three steps of the after-treatment are illustrated in Figures 11, 12, and 13.

I would place this operation second to that recommended by Major McKenna, because it is not quite as simple as his. I describe it here because the end-results of the counter-drainage operation have been so satisfactory, and should this simple drainage by means of a catheter not accomplish the final results, the counter-drainage operation would then be the one most likely to be adopted.

In regard to simple drainage such as we have been accustomed to do, I wish to offer a few suggestions: first, that the most advantageous location for introducing drainage is posterior and as low as possible, preferably the ninth rib, providing it is certain that the cavity extends that low. If the angle of the diaphragm and chest wall is obliterated by adhesions, the insertion of the tube may have to be higher and the eighth or seventh rib may be chosen of necessity, but by all means it should be done posteriorly. I recommend posterior drainage for two reasons: It is the most desirable point for draining in the lying as well as the sitting posture. Most of the chronic persistent sinuses after resection that have come under my observation, have been on the anterior chest wall, along the fourth or fifth rib, or in the axillary line, sometimes as high as the arm pit. Very few cases persist in draining when the opening has been made very low posteriorly.

In introducing a large rubber tube, care should be taken that it does not protrude too far into the pleural cavity. It it can be fixed so that it is just level with the inner chest wall, it will prevent the friction of the lung against the edge of the rubber tube. The suction method for re-expansion of the lung is to be highly recommended, but it must be done systematically and without any undue force.

Fig. 25.

Fig. 26.

Fig. 27.

Fig. 25. Condition before operation, with sketch of proposed Y-shape incision (Case 2).

Fig. 26. Skin flap, muscles and fat still attached; raised, and pus cavity opened. The floating pus is clearly seen.

Fig. 27. The cavity has been fully exposed, and the muscles and fat have been removed. The skin flap is ready for insertion.

Local anæsthesia should be employed almost exclusively. I shall not waste any time in describing the technique of resection of the rib for empyema, but I cannot refrain from mentioning one point which has been very helpful to me, namely, instead of making a straight incision over the rib which is to be resected, I make a curved incision and thus the field is opened up and the operation performed much more qucikly.

RAPID CLOSURE IN AFTER-TREATMENT

What shall be done to produce disinfection and closure of the pleural cavity in the shortest possible time?

The flushing of empyema cavities with disinfecting fluids was extensively used until about fifteen years ago. Weak solutions of permanganate or iodine or boric acid were the favorite solutions employed. The practice was then discontinued until during recent years when Doctor Carrel renewed the interest of the profession in this treatment by showing his good results from flushing infected wounds and pus cavities with what is now known as the Carrel-Dakin solution. The pros and contras for this method are very numerous. The method is on trial. Judging from the reports in the literature the results will justify its employment in the future. Personally I have had too little experience with it to justify any definite conclusions of my own. As to its technique I refer the reader to the description by the Empyema Commission[1] in its report in the *Journal of the American Medical Association*. One of the most important advantages of the use of Dakin's solution which I have observed in the cases in which I employed it, was its solvent action on fibrinous adhesions of the lung. It was noted that many cases of empyema which had recovered retained blocked-off abscess cavities due to fibrinous adhesions of the lung. The employment of the Carrel-Dakin solution dissolved these adhesions and the pus cavity was thus opened, emptying its pus into the main cavity, from which it drained freely. This, no doubt, saved a great many from secondary operations. I desire to illustrate a typical case of this nature:

A man of thirty, previous health good, became suddenly ill with an infection of his throat. Severe pneumonia followed. The temperature was 103 to 105° for 10 days, at the end of which time the left

[1] J. Am. M. Ass., 1918, Aug. 3, 372.

chest was filled with a fluid. After probatory puncture (pus with numerous streptococci), an inch of the ninth rib was resected posteriorly under local anæsthesia; a counter-opening was made at the same time anteriorly, and a large perforated catheter was introduced, passing through both openings. This drainage was kept up for two weeks. The patient improved rapidly, the pus gradually becoming thicker and more purulent. The catheter was then removed and the cavity injected with 300 grams of bismuth paste, a mixture containing 10 per cent bismuth subnitrate and 90 per cent vaseline. A set of stereoroentgenograms was taken with the patient in a horizontal position. From a single roentgenogram we would judge that the entire left chest cavity is filled with the mixture. The stereoscopic set of roentgenograms, however, definitely proves that this is not the case. We note that the mixture simply gravitated to the posterior surface of the pleural cavity, producing a shadow covering the greater part of the left chest. (Plate I.) The mixture does not fill the entire depth of the pleural space; the heart and the retracted lung are in front of it. This fact can only be visualized by the stereoscopic roentgenogram, the single plate is misleading. The interesting finding of another abscess, and proof of this is given in another roentgenogram, patient in the sitting posture (Fig. 14). The bismuth mixture has now gravitated downward and left the upper two-thirds of the cavity empty and thus transparent. The mixture accumulated at the bottom, giving a square-shaped shadow, *A*. We note, however, that a portion of the mixture has been retained in a pocket in the upper anterior portion of the chest. It evidently ran anterior to the lung at the apex. The mixture here gives a distinct outline of a locked-off abscess, with a distinct waterline mark on its upper margin, *B*. Such roentgenograms as this are essential for a correct diagnosis and greatly facilitate the treatment.

Fig. 28. Size and location of cavity outlined by injection of bismuth paste.

It will depend upon the final results whether the irrigating method will become a permanent armamentarium in the treatment of these cases. We must take into account, that heretofore we have been accustomed to promise our patients a closure of an empyema in at least 19 out of 20 cases and this was done when we treated them by simple drainage without irrigation. If the irrigating methods will produce better results than that, they will retain their place; if the percentage of discharging sinuses will be larger than before, the profession will be tempted to return to simple drainage without irrigation. We must not be misled by some adverse reports on the Carrel-Dakin solution, for it is quite possible that some did not obtain the desired results because they did not follow the technique laid down by Carrel in its finer details. If one desires to employ another man's method, he must follow it to the letter and not try to make modifications of his own. I believe this has been the case in the use of the bismuth paste method of treating sinuses. It is, of course, possible that the type of cases with which we are dealing now will not yield the same good results with simple drainage as the cases did in former years, but since there has been no trial made of simple drainage on as large a scale as that of the flushing method with Carrel-Dakin solution, the question is open to investigation.

The cases which do not yield to the flushing method should be treated with the injections of bismuth paste. It is unnecessary here to go into this method of treatment in detail, since I have, from time to time, published the technique as well as the results obtained, but since empyema is now so prevalent and the use of the paste will probably be much greater in these cases than ever before, I believe it will be of advantage to give some of the important points in the correct technique, which is so essential for the attainment of good results. The injection of bismuth paste serves two purposes, first diagnostic, second therapeutic.

Diagnostic points. The various shapes of these empyema cavities can be best visualized by filling them with bismuth paste and then taking a set of stereoroentgenograms.

Such roentgenograms will give a clear picture of the size, location, and depth of these cavities. Studying them we can define with accuracy the boundries and anatomical relations of the cavity and thus plan our operation and treatment accordingly. In some cases the pleural surfaces adhere and nearly obliterate the entire pleural space and leave a long sinus leading into a pocket not larger than a crab-apple (Fig. 15). The injection of bismuth into the sinus will likewise give a clear picture of the existing conditions. In some instances roentgenograms will show a straight channel from the skin opening in the chest wall leading directly into a bronchus, which indicates that the preexisting cavity has shriveled down to a straight sinus, but did not close on account of the communication with the bronchus.

The introduction of the catheter into an empyema for the purpose of estimating the extent or size of the cavity is not a reliable one. I prove this by exhibiting Plate II.

In this particular experiment I have introduced two catheters alongside of each other into the opening, in order to ascertain whether they will lie parallel after introduction. A view of the stereoscopic roentgenogram clearly demonstrates the fallacy of trying to ascertain the boundaries. One of the catheters runs up into the apex and makes a small curve and the other curls upon itself and points downward after it has reached halfway into the empyema cavity.

Multiple abscesses in the lung may be shown by injecting them with bismuth paste, even if they communicate with the bronchi, because they very often communicate and septa only separate these cavities (Fig. 16). I also wish to illustrate a case in which two abscesses, one above the other, distinctly outlined, which do not communicate, appear in one lung (Plate III).

To determine the presence of a communication between the abscess cavity and the bronchus the injection of bismuth paste is most dependable, because the patient will cough up the mixture. As soon as the existing cavity has been completely filled, the overflow will penetrate into the bronchus and the patient will get a coughing spell during which he will eject some of the paste. A word of caution is here necessary, namely, that the paste should in such case be injected very slowly and the patient asked not to inhale during this injection, for he may aspirate some of the mixture into the other side of the lung, while it is passing up through the trachea. It may also produce a choking spell if a large amount of the paste is forced into the trachea. For this reason the mixture must be liquid. We realize that as the trachea is several inches long and its lumen not very wide, it is very easy to clog up this lumen by a column of thick paste and the patient would be unable to inspire any air whatsoever. When there is an accumulation of pus in the abscess cavity the paste mixture will displace this pus, drive it into the bronchus, and the patient will cough up a quantity of pus before any paste will appear in the expectoration.

It is of course absolutely necessary that when a foreign body is the cause of the abscess that it be localized before any treatment is attempted. Here the stereoroentgenogram is almost indispensable for the determination of the exact location of the foreign body. An extensive study of this subject will be found in my publication entitled, "The Localization of Foreign Bodies by means of Stereoroentgenograms," published in the *Stereo-Clinic*, in 1917. Without the help of stereoroentgenograms I should have been very much handicapped. These have been a most useful adjunct in my armamentarium for the treatment of chronic empyema.

After a satisfactory anatomical diagnosis has been made by means of these roentgenograms, the next step is to ascertain the character and quantity of the discharge. In some cases it is a green, foul-smelling pus, in some a serous, semipurulent fluid resembling dirty dishwater; in others a creamy, or chocolate-colored thick pus. The color of the pus depends very often upon the substances which have been used in the treatment. Irrigations of permanganate or silver nitrate especially change the character and color of the secretion. We invariably take a culture and smear of the pus and whenever it seems necessary we inject one or two

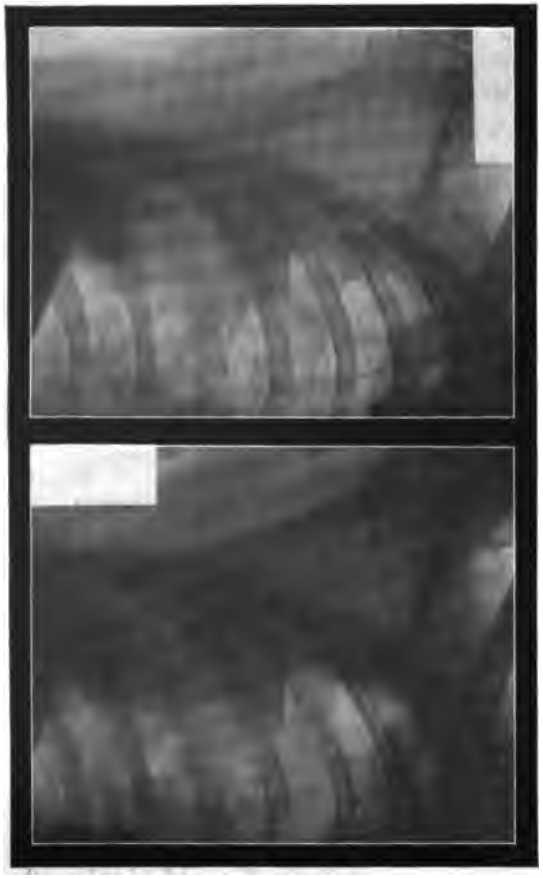

Plate III. Two distinct abscesses not communicating; the upper containing some pus, the lower some bismuth paste. Only stereoroentgenograms will show this condition.

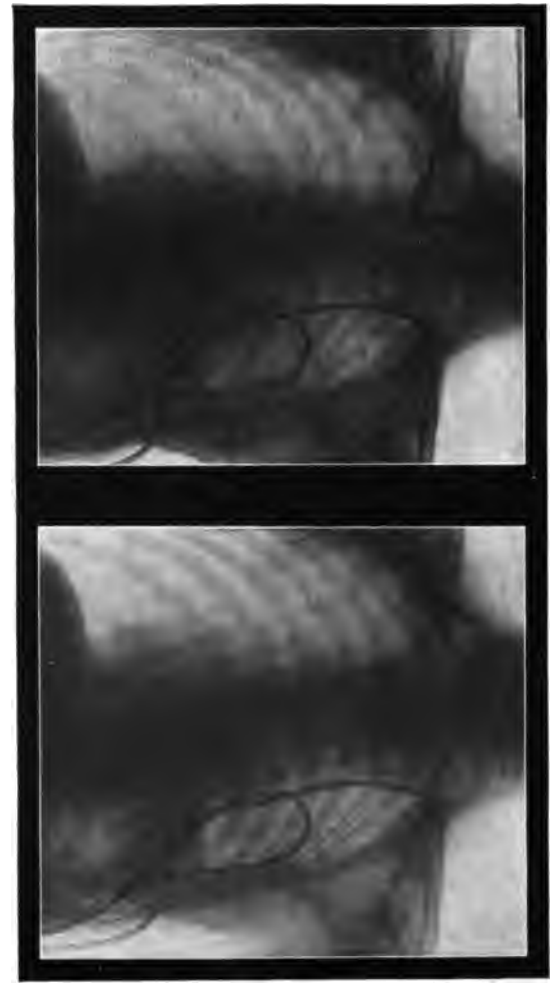

Plate II. Two catheters inserted into one cavity, proving fallacy of estimating size of cavity by catheter.

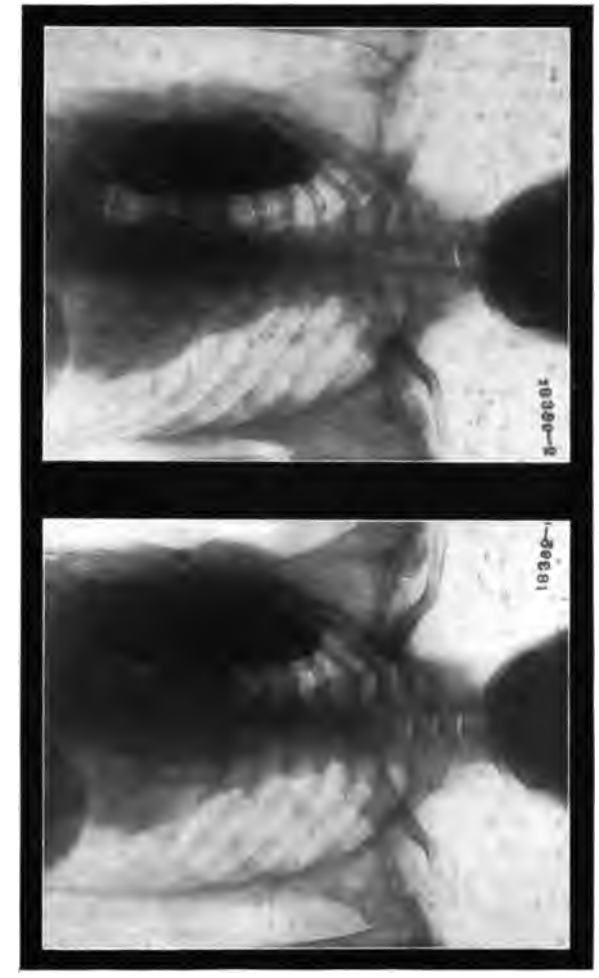

Plate I. Bismuth paste filling the posterior portion of cavity, following influenza.

Plate VI. Condition of cavity of second case five weeks after operation. Illustrating also adhesive plaster method of regeneration of skin. Note regeneration of skin on all orders.

Plate V. Regeneration of skin complete. Patient able to use the arm.

Plate IV. Condition two weeks after skin-sliding operation, showing deep cavity still granulating.

guinea pigs with a 10 per cent solution of this pus. In practically all the cases we find the staphylococcus; in addition to this we find the streptococcus in about 20 per cent of the cases. The tubercle bacillus is rarely found in the secretion, even in the cases in which the empyema is positively of tuberculosis origin.

We have made one remarkable observation in this connection, namely, that in the cases known to be of tuberculous origin in which tubercle bacilli could not be found in the secretions, the bacilli would appear after injecting the cavity with bismuth paste and were then present within 24 hours in very large numbers in each smear preparation, often as many as a hundred in each field. This surprising finding was verified in a number of cases during the past ten years. These tubercle bacilli, however, differ somewhat in their appearance and staining qualities from those which we usually find in tuberculous sputum; they are beaded, resembling somewhat a miniature chain of streptococci, staining also much darker than the tubercle bacillus usually does. The number of these bacilli gradually diminish and within 2 or 3 weeks the secretion will be free from the same.

My explanation for the appearance of these bacilli after the injection is the following: The tubercle bacilli live within the walls of the sinuses or the abscess wall and not in the secretions. It requires a local leucocytosis to provoke their exit. The injection of a substance like bismuth subnitrate produces a leucocytosis within the walls and by this means the bacilli are carried out in the discharge. I am of the opinion that the modus operandi consists in a battle between the tubercle bacilli and the leucocytes, resulting in the death of the bacilli and their expulsion into the secretions. Possibly the same may be true in the case of other micro-organisms and this would in a degree account for the surprisingly rapid sterilization of large infected cavities. I have as yet no confirmatory laboratory evidence of the above theory, but the theory seems plausible and is supported by clinical evidence.

Therapeutic points. Bismuth paste treatment. This is the most conservative and at the same time the most effective treatment of these chronic discharging sinuses of the chest. This opinion is not based alone on my own experience in over 150 cases but from reports and observations of many large hospitals in this country and abroad, as well as from my observations at the Great Lakes Base Hospital. By this time the bismuth method is well known, and the results from its employment and its dangers are well defined. After ten years of trial it has retained its place and is employed more extensively now than ever. The reports in the literature indicate that at least four out of five cases of the very old neglected suppurative empyemata or lung abscesses may be cured by this simple procedure. Ochsner, of Chicago, reported to the American Surgical Association on June 4, 1909, 14 cases of empyema, all of which had been operated upon (two by Estlander's operation) with sinuses in all cases persisting nevertheless. He applied the bismuth paste in each of these cases, with the result that 12 cases healed completely and two were still under treatment at the time and very much improved; others have reported equally good results. In my own series of 150 cases approximately 80 per cent were cured by the bismuth injection treatment alone.

Technique of bismuth paste treatment. Before the treatment is instituted a set of stereoroentgenograms of the entire chest (plate size 14x17) should be taken in order to visualize if possible the retracted lung, adhesions, thickened pleura, or discover foreign bodies if such be present. The cavity is then injected with a 10 per cent bismuth-vaseline paste.[1]

When the cavity or sinus is completely filled with this mixture, another set of stereoroentgenograms is taken. This set will illustrate the exact size of the cavity and its relation to the ribs and other structures in the chest. The second set of stereoroentgenograms shows that the cavity is entirely filled with bismuth and usually marks the inner boundary of the cavity formed by thickened pleura. The sizes and shapes of these cavities vary greatly; no two are alike.

[1] In former years I employed a mixture containing 30 per cent bismuth subnitrate, but found that the above mixture produces equally good results and is not likely to cause bismuth absorption.

The paste is not supposed to be retained in the cavity and allowed to remain there for absorption. Many have the idea that the paste serves as a filling substance to obliterate dead space. This is an error which might lead to serious complications, especially bismuth intoxication. The paste is to remain about two to five days and if it does not spontaneously escape, it should be drawn out by means of a catheter attached to a suction syringe.

In order that the mixture may be correctly prepared, I here include a formula and rules by which it has been prepared at the North Chicago Hospital for the past twelve years.

Apparatus.

1. Bismuth subnitrate, C. P.
2. Yellow vaseline (best grade).
3. White wax.
4. Large porcelain mixing bowl.
5. Spoon.
6. Large enamel jar with cover for storing paste.
7. Several small enamel jars with covers for liquefying paste at time of use.
8. Adhesive straps for the covers of the jars, to keep moisture and dirt from contaminating the paste.
9. Water bath for heating paste.
10. Sterile rubber gloves, towels, etc., for aseptic technique.

Bismuth paste is a ten per cent mixture, one part of bismuth subnitrate to nine parts of vaseline with a small amount of white wax (2 ounces to 10 pounds of paste). The mixing bowls, jars, and spoon are sterilized; the vaseline is sterilized for 20 minutes in the original container in the autoclave. The bismuth subnitrate is sterile when it comes from the manufacturer and so does not have to be resterilized. The mixing bowls and jars must be absolutely dry, as the slightest amount of water produces a curdling of the paste.

The bismuth subnitrate is poured into the mixing bowl and all lumps smoothed out with the spoon. A sufficient amount of vaseline, which is still in a liquefied condition from the sterilizing, is slowly poured into the bismuth, to make a stiff paste. This mixture is then stirred for an hour until it is a smooth, bright yellow, homogeneous paste. This is the most important step in the process and if not carried out carefully, the paste will not be homogeneous.

To the balance of the nine parts of the liquefied vaseline, a small amount of white wax, which has been heated to liquefaction is added (2 ounces to 10 pounds) and then this mixture is gradually added to the thick paste, stirring it constantly. The resulting product should be a light yellow, smooth, homogeneous paste, which, on cooling, becomes congealed without the precipitation of the bismuth.

At the time of use, small amounts of this paste (8 to 10 ounces) are transferred to small jars, in which the paste is liquefied and from which it is used. These jars should not be more than half full and great care should be taken not to get any water into the paste while heating it.

The syringes that are used are both glass and metal (Fig. 17); the barrel holding from one-half to two ounces of paste. These syringes have different shaped points and nozzles, according to the demands of the case. The syringes are sterilized and kept in sterile towels until they are to be used, when they are filled with liquefied paste.

The treatment should be controlled by repeated bacteriological examination of the secretions. No attempt should be made to irrigate the cavity before the injection. The patient should be placed in such a recumbent position that the sinus opening is on the highest level. This will allow the air to escape while the bismuth is being injected. A two-ounce syringe is filled with the liquefied paste, the long nozzle of this syringe, as shown in Figure 18, is introduced into the sinus and the paste slowly injected into the cavity. Upon withdrawal of the syringe some bubbles of air will escape. A second syringe full is introduced in the same manner and as a rule this will fill most of the smaller cavities, which is indicated by the overflowing of the mixture from the sinus. At times, however, it requires 10 to 12 ounces, or even more, to fill an empyema. No attempt is made to plug the opening for the retention of the paste. A simple sterile dressing, with a snugly fitting bandage, is applied. A greater part of the paste will escape within 24 hours.

The first injection does not always produce permanent healing. It requires at times repeated injections during several months, but whenever the discharge changes from pus to a serous character, the injection should be stopped, because healing will usually follow. Only when the discharge continues to be purulent should we consider a more radical procedure.

Causes of non-closure of drained cases. I have tried to ascertain why some cases respond to the bismuth treatment and why others do not and I have come to the conclusion that whenever the cavity holds more than 200 grams it will be less likely to heal by bismuth injections. Cases which com-

municate with the bronchi are also more resistant than simple empyema. Some cases will heal shortly after the injection and remain closed for a year or two and the patient be in good health, often gaining as much as 30 pounds, and then the sinus will reopen. The injections are then to be repeated. Closure usually follows for another year or two, and the patient may have another relapse after a long period. The patient often prefers to keep up treatment in this way, not being much inconvenienced and perfectly well in the intervals.

In studying a large series of cases which failed to close, the following causes have been found to be the factors:

1. In many cases the retracted and infiltrated lung tissue cannot expand sufficiently to fill the dead space existing between itself and the rigid chest wall. Nature tries to diminish this space by contracting the chest wall, so that the ribs almost overlap and in many cases there are no intercostal spaces except at the insertion of the ribs at the spine. The diaphragm very often is drawn up two or three inches in ts attempt to obliterate the space. The pleura also thickens and diminishes this space to a certain degree. Nevertheless there often remains a cavity holding two or three hundred cubic centimeters of fluid.

2. The pleura often contains micro-organisms which cannot be reached by flushing with any antiseptic solution, and thus the secretion of pus continues indefinitely.

3. At times there are foreign bodies present, such as rubber tubing, which has slipped in unknown to the surgeon and remained there, keeping up suppuration.

4. In cases of abscess of the lung, the tendency to non-closure is greater because there is usually a communication with the bronchus, which is very often dilated, and reinfection of the abscess cavity after drainage keeps up the suppuration.

5. These chronic suppurative abscesses are often multiple, and when one or two are opened, the drainage and suppuration persist in many small recesses, and only communicate through the branches of the bronchi.

6. In abscesses due to tuberculosis of the lung, the reason for non-closure is still more apparent when we consider the pathology of the tuberculous lobe.

Bearing in mind these various causes for non-closure, the treatment in each case will naturally consist in removal of the cause if this be possible. If the cause is not removable, as for instance, the extreme size of the pus cavity, we are face to face with a most difficult situation. The patient has then the choice either of enduring his trouble and being satisfied with daily dressings or of taking the risk of an extensive operation.

WHAT SHALL BE DONE WITH CHRONIC SUPPURATIVE CASES WHICH PERSIST IN SPITE OF TREATMENT?

During the past seven years I have employed a method of obliterating these very large cavities or those which persist in discharging on account of communication with the bronchus, which I believe is simpler and less dangerous than the extensive Estlander, Schede, or decortication of the lung. I have described the same in full in the March, 1918, number of SURGERY, GYNECOLOGY AND OBSTETRICS, p. 259, but since then I have introduced new features in this operation, and in order to make the subject here complete I will recapitulate the essential points of this rather new procedure. I am informed by a number of confrères who have already employed this operation that they have found it very satisfactory.

SKIN-SLIDING OPERATION FOR EMPYEMA

This procedure aims at the obliteration of the pleural space, as does the Estlander or similar operations. It differs, however, in this respect, that in the skin-sliding operation we transform the suppurating cavity into a skin-covered surface, so that it is a continuation of the outer chest wall, while in the other procedures an attempt is made at re-expanding the lung or caving in of the chest wall to meet the retracted lung.

This epidermization of the exposed lung is accomplished by removing as much as possible of the muscles, ribs, and the thick parietal pleura over the pleural dead space,

exposing thereby the retracted lung surface and then initiating the growth of skin over the exposed lung by shifting a long skin flap into the deepest recess within the pleural space. This skin flap will serve as a starting point for the regeneration of the skin from its edges until the entire denuded surface is covered by an epithelial growth.

The regeneration of the skin from the edges will take place only if we prevent the granulations from rising too high above the level of the skin edge, and for this purpose we have introduced the adhesive plaster method for regeneration of the skin described below.

The size and shape of the skin flap should be planned beforehand and the incision made accordingly. In most cases I have employed a Y-shaped incision, which produces really three flaps, as shown in Figure 21. Flap *A* is longer and narrower and is intended for the deep recess in the apex, while flap *B* and flap *C* have obtuse angles and will usually reflect over the dome of the diaphragm and the mediastinum. In other cases different incisions, such as the X incision or the "trap-door" incision may be more suitable. These are also illustrated in Figure 21. In order to review the technique of this operation, I cite from my previous publication:

The patient is placed in a semi-recumbent posture and is anæsthetized either by local or general anæsthesia. Before incising the skin a rubber catheter is introduced into the existing sinus and kept there as a guide. The incision is then made to suit the individual case, choosing one of the incisions illustrated in Figure 21. The flaps at first contain the skin, fat, and muscles, in order that the skin may keep its circulation, until it is ready to be inserted. Then follows the resection of as many ribs as seems necessary to expose the lung to its fullest extent. Three to five is usually sufficient. This should include, as a rule, the third rib, because this gives us access to the deepest part of the cavity and facilitates the insertion of the flap into the same. The greater part of the pectoral muscles must often be divided or dissected to make the exposure sufficient. A straight incision is then made upward through the pleura, starting from the sinus in which we have placed the catheter and carried to the highest point possible, up to the second rib. The edges of the thickened pleura are then retracted by strong Volsellum forceps and the cavity inspected. All of the parietal pleura is now dissected away clear to the edges of the dissected ribs on either side, but no attempt is made to peel off any of the visceral pleura, or to resect the parietal pleura covering the first or second ribs at the apex. The muscles and fat are now freed from the skin flap and cut off. The tip of the skin flap is then grasped by an artery forceps and carried to the farthest point upward into the deepest part of the cavity so that its raw undersurface lies snugly against the parietal pleura underneath the first and second ribs. Gauze is packed rather tightly against it to keep it in place. In order to prevent retraction of the skin flap, the forceps may be kept *in situ* for 24 hours, the gauze packing keeping it in place. Another precaution may be taken by fastening the skin by means of a stitch taken through the base of the skin flap to the tissues over the second or third rib. It may be advisable to introduce a small drain beneath the base of the skin-flap to prevent the possibility of suppuration underneath the flap. At this stage the operation is completed. The two lower skin-flaps require no special attention; they will adjust themselves.

During the entire procedure it is rarely necessary to use any suture material. The operation should not take more than 100 minutes, in the more extensive cases, and can be done in less than 60 minutes in the less extensive ones.

After-treatment. The packing should not be removed for 48 hours. By this time the flap will be firmly adherent. It is best, however, to take the precaution to keep a spatula in contact with the skin flap, so that it will not be torn off in removing the gauze. The removal of dry gauze may sometimes be so painful as to necessitate a gas anæsthesia and for this reason we introduce at the second dressing gauze strips which have been soaked in vaseline. Within one week the raw surfaces, including those which have been caused by the denudation of the skin, will be covered

sufficiently by granulations to begin the application of adhesive strips for skin regeneration. The method is as follows:

The zinc oxide adhesive plaster as an aid to skin regeneration. This consists in pasting adhesive plaster strips about a half to three-quarters of an inch in width, along the edges of the granulating wounds, so that the margin of the skin, as well as the granulation surface is covered (Fig. 19). The adhesive plaster serves the same principle that wire does for a vine; the granulations will be kept down to the level of the margin of the skin and the epithelial cells will regenerate along the under surface of the adhesive plaster (Fig. 22). On removing the first dressing of the adhesive strips we will note a bluish margin along the edges of the skin, which represents the new growth of cells during the twenty-four hours. The adhesive plaster is not put on at the next dressing but plain gauze is applied, in order to give the newly formed growth a chance to become more substantial. Thus the adhesive plaster is applied every second dressing, or every forty-eight hours, alternating with gauze dressings.

It has been questioned whether a true regeneration of epithelial cells takes place, since some of the new formed skin resembles scar tissue. We have proved beyond doubt that true regeneration of epithelium does take place, which proof will be published in a special article. However, we here wish to illustrate the microscopic sections of some of the newly formed skin removed from cases in which we performed secondary operations in which epithelial regeneration took place (Fig. 23).

For illustration of the skin-flap operation I desire to cite two typical cases:

CASE 1. *Chronic empyema*, 10 years' duration, with drainage. Miss F. L., age 19, developed an empyema on the right side at the age of 9. This was drained and she was apparently well until she was 14; then she developed fever and pain in the right chest. The chest was reopened and large quantities of pus evacuated, whereupon the wound healed up again. Shortly after, fever again developed and it was then advised to drain permanently as shown in Figure 20.

She came under the care of my brother, Carl Beck, in June, 1915. Injections of bismuth were tried for a time and the condition improved but the cavity was so extremely large that a permanent obliteration could not be expected. (Fig. 24.) Therefore, on February, 1916, Carl Beck performed a modified Schede operation. A circular flap and the muscle were dissected down to the ribs and a part of the fourth, fifth, sixth, and seventh ribs was resected anteriorly. The pleura was then incised at the seventh rib, where drainage had been established, and the incision continued up to the third rib. The cavity was packed with several pieces of gauze and the wound temporarily closed with three stitches of catgut.

The second step of the operation was done ten days later and this consisted in trying to obliterate the space by pressing in the right breast. This procedure, however, was not found effective, since the cavity itself reached far into the apex, and besides the pleura was constantly secreting pus. He therefore decided to denude the skin from the breast, making a large-size flap, amputating the breast and the pectoral muscles and shifting the skin flap up into the apex. This was done in May, 1916. No attempt made to produce lateral flaps.

The entire denuded area was left uncovered for the adhesive plaster method of reconstruction of the skin (Plate IV). Healing took place rapidly and with the aid of adhesive plaster the entire cavity was now lined with skin, entirely dry, and the girl is in perfect health and able to do general housework. She has no deformity of the spine, only the unsightly depression in her right chest wall (Plate V), which of course is only visible when she is undressed.

CASE 2. *Chronic empyema*, draining 3 years, complicated with acute influenza-pneumonia.

A Bulgarian laborer, S. K., age 33, developed empyema in 1915, and drainage was performed two weeks after an illness which was probably pneumonia. This left a small sinus draining anteriorly, as shown in Figure 25.

The previous treatment of this case consisted in irrigations and also injections of bismuth paste (Fig. 28), which improved it for six months, during which time the sinus was closed and then reopened. It was finally decided to do a skin-sliding operation. A Y-shaped incision was made, such as is shown in Figure 25. The two principal steps in the operation are illustrated in Figures 26 and 27. The first one illustrates the resection of the skin flap, including the muscles (for those are not to be removed until the skin is to be shifted into the cavity), the pleura is already opened and we notice the floating pus within. In the second we have already dissected away the muscles and widely exposed the pleural cavity. The skin flap here is being held up by two forceps. This upper flap was inverted and pushed against the under surface of the remaining chest wall, thus adhering to the parietal pleura. The entire cavity was then packed snugly with gauze, to keep the skin in close contact with the pleural surface and favor adhesion.

Subsequent history. The patient did very well for five days. On the fifth day he developed all the symptoms of influenza, the epidemic in the meantime having begun in Chicago and a number of the nurses as well as patients having contracted the disease, The temperature rose to 105° and 106° within 24 hours and all the symptoms of an acute pneumonia in the exposed lung developed. We could watch the inflammatory condition by ocular inspection. The thickened pleura which covered the lung at the time of operation became now a transparent, succulent membrane with a whitish covering, congested blood-vessels, and in some portions dark spots like gangrenous areas were developed. Twenty-four hours later a hæmorrhage took place from the surface of the lung, which was controlled by the application of Monsell's solution and the lung was tightly compressed with gauze, which was kept in place by adhesive plaster.

We could now observe the progress of the disease during the daily dressings. Hæmorrhages took place during the dressings sufficient to be alarming. The patient, however, did not succumb to this affection. After two weeks he began to gain, the lung gradually changing to its former appearance and granulations forming around the edges of the lung.

I illustrate in Plate VI. the present condition, the case being still in the hospital. Regeneration of the skin is taking place rapidly, so that I expect a complete and similar result as in the former case cited.

COMMENTS

This method of treatment of apparently incurable empyemata is still in the developmental stage and will no doubt be developed to greater perfection, but I am certain that it has a great many advantages over the extensive operations which have heretofore been performed for this condition.

Since there is no suturing done in this operation after the resection of the rib and excision of the pleura, the operation is completed in one-half the time that we would require in the Estlander. We are finished with the operation just about the time when we would expect to have the greater part of the work before us.

SUMMARY

1. The treatment of empyema has, through the occurrence of new types, become a new problem and on account of its enormous prevalence will require a revision and modification in methods of treatment.

2. The correct treatment of the early stages will prevent the majority of the chronic suppurative sinuses.

3. When sinuses persist in spite of all previous treatment the bismuth paste, if correctly applied, will eliminate approximately 80 per cent of such cases.

4. The residue of such cases as are not amenable to the bismuth treatment may be cured by the skin-sliding operation, provided the technique is followed as outlined in this paper.

PERFORATED GASTRIC AND DUODENAL ULCERS[1]

By H. M. RICHTER, M.D., F.A.C.S., Chicago

THE treatment of perforated duodenal and gastric ulcer is a settled problem to most surgeons; to the student of the literature of the subject it becomes obvious that each has settled it in his own way, and that the solutions arrived at have little in common except the necessity for closing the perforation. Based on a personal experience of 17 cases, and a study of some 50 odd cases operated upon in Cook County Hospital in a period of five years, the writer offers the following suggestions:

1. The peritonitis resulting from a gastric or duodenal perforation is but slightly if at all infective during the first hours following the accident and, therefore, it must not be treated as a suppurative process.

2. The degree of patency of the pylorus after closure of the perforation alone does not determine the indication or otherwise for a gastro-enterostomy.

3. The operators's technique, quite irrespective of the method he uses, determines in a high degree, his mortality.

The peritonitis. The normal stomach and duodenum are practically sterile much of the time. In the presence of an ulcer this is not the case, but the amount of infective material present must usually be very slight. It is a very common experience, borne out by the histories of the cases here studied, that many of the patients give no history suggestive of any degree of pyloric obstruction. Not rarely the perforation is the first evidence of the presence of an ulcer; usually the history is that of an active ulcer of the type likely to be accompanied by a hyperacidity and rapid emptying of the stomach. The ulcer itself is an infective process; but the stomach contents are practically sterile and when emptied into the peritoneum produce the violent reaction of a chemical irritant. Some years ago I published a report of a case in which there was a widespread fat necrosis, and some experimental work in which I succeeded in producing a typical widespread fat necrosis by making a perforation of the duodenum. Several of the cases in the series studied in this paper present such a peritonitis with fat necrosis. All this reaction is, however, a chemical reaction; it calls for mechanical emptying of the peritoneal cavity. The one thing that logically is to be avoided is the leaving of gauze or tubes in such a peritoneum for drainage. Such drainage must surely entail the danger of infection to the already badly damaged peritoneum. Where actual solid masses of food are present, an incision in the midline below should be made of sufficient length easily to investigate the more dependent parts of the abdomen and remove them, or, if too numerous, and the condition of the patient forbids, drainage may here be instituted. But this is an exceptional occurrence. It has not occurred in my own experience, though the perforation often follows the ingestion of food, and some particles may be found in the peritoneum. When it is remembered that in the vast majority of cases, the perforation is very small (less than 5 millimeters in diameter), it will be readily understood that the expression "the peritoneum was full of food" is usually imaginative rather than descriptive. That drainage cannot materially aid the escape of solid food masses, and that in my cases recovery occurred without such drainage, must be regarded as evidence of a positive value of the uselessness of the attempt to drain. Drainage instituted because of the presence of solid food masses must be regarded rather as a safety factor in the event that suppurative peritonitis should develop; but since the gauze and tubes will surely be walled off from the free peritoneal cavity many hours before the development of the suppuration that they are intended to relieve, the futility of the procedure must be obvious. In my earlier cases, in which I was accustomed to drain, I was struck by the obvious ineffectiveness of the procedure. Data are lacking as to the exact time elapsing between the perforation and the operation, but among those personally

[1]Read before the Western Surgical Association, Chicago, December, 1918.

operated upon one was twenty-five hours old. Among the records of Cook County Hospital, several cases are included in which the perforation was a number of days old; in these instances the perforation must have been incomplete giving time for walling off processes to develop. Here actual suppuration might easily have been present and drainage of the local abscess justified.

First, then, I should conclude that drainage is almost always uncalled for in early perforations of gastric or duodenal ulcers. Drainage may be instituted (1) in late cases (after 18 hours); (2), the rare instance of inadequate closure of the perforation due to physical inability adequately to invert the lesion; and (3), where gross masses of stomach contents are spilled into the peritoneum.

Gastro-enterostomy. Is a gastro-enterostomy called for after closing a perforated ulcer? Diametrically opposite views are presented in a most arbitrary manner. Deaver always does a gastro-enterostomy; others never do a gastro-enterostomy. It seems to me that gastro-enterostomy has a double function to perform; first and obviously to relieve existing obstruction due to the inversion of the ulcer, and second, and of fundamental importance, the therapy of the existing lesions in the stomach.

First of these, the relief of obstruction, applies only to duodenal and pyloric ulcers. When *adequately inverted*, these should almost always produce obstruction. It is no evidence of skill that such an obstruction is avoided; rather it is frequently an evidence of inadequate inversion of the calloused ulcer. Moreover, that clinical patency is found to be present, when at operation obstruction seemed likely, is evidence only that the stomach is capable of compensating for a high degree of obstruction, *which it should not be called upon to do*, as we hope to show.

The therapy of the existing stomach lesions. It is agreed that the perforation is one of the surest cures for gastric ulcers. It is a cure for the ulcer involved in a limited number of cases (70 per cent — Paterson); but in from 20 per cent to 50 per cent of the cases of active ulcer causing perforation, the lesion is multiple. The autopsy findings at Cook County Hospital are incomplete on this phase of the subject; the only patient of my series who came to autopsy showed seven active ulcers; two besides that which perforated were extensively necrotic, four were in various stages of activity. The value of jejunostomy in such a case can hardly be overestimated; not merely its late effect, but its immediate action on the perforation and on the active ulcers.

There is a note in some of the records that the stomach wall is found too friable for suture. Such a statement is evidence that the operator lacks a proper apprehension of the principles underlying the closure of a perforated ulcer. The perforation is but a small portion of the gross ulcer. In closing the perforation the entire ulcer should be embedded. It is for this reason that the lumen of the pylorus and duodenum will usually be closed if an ulcer is adequately enfolded.

Excision of the ulcer. Excision of the ulcer, its closure with free facial transplants, the cauterization of the perforation, etc., are all unnecessary complications of the technique of treatment. In the presence of an emergency fraught with danger, these unnecessary additions to the operation are uncalled for. Through-and-through suture grasping the entire ulcer as well as the perforation is effective in destroying the lesion.

THE OPERATOR'S TECHNIQUE

Technique, after all, plays an important part in results, irrespective of the type of operation followed. Although there is found to be a benign peritonitis during the early hours following the perforation, the abdominal viscera will not withstand excessive traumatism. Whatever operation is done, it must be carried out with a minimum of handling of the parts. The statement, "contents poured from the perforation while the stomach was being drawn from the abdomen" is evidence of poor technique. The rate of traumatism per minute inflicted upon a patient if it could be indicated by a definite unit of measurement would surely be found to vary 1,000 per cent in the hands of different operators, and this materially influences results. A further evidence that the operator's technique plays

quite as important a rôle in mortality as his method of treating the perforation, is indicated by the fact that several series of perforations have been reported in which the mortality was low, though some were treated by gastro-enterostomy and others not. Examples of this are Deaver's statistics of 40-odd cases with one death, in all of which he did a gastro-enterostomy, and the work of others, in which gastro-enterostomies were not done, and in which the mortality was almost equally low. The elements of technique which play an important rôle in the mortality may be covered in a few words: First, the incision should be ample to afford the operator easy access to the upper abdomen. The pyloric end of the stomach and duodenum must be so exposed that they can be viewed *in situ* with a minimum of disturbance. Such an exposure enables the operator to find the perforation without loss of time, and, what is more important, without pulling the parts out of their normal position.

It is said to be difficult at times to find the perforation, and it has been suggested to give methylene blue in order to facilitate locating it. In three cases among the 50 operated upon in Cook County Hospital it is noted that the perforation was not found during the operation. I have had no experience of this kind, and I think it likely that a free exposure would practically obviate its occurrence.

Upon locating the perforation, if leakage is taking place, a finger should be placed upon it until a through-and-through running suture can be so placed as to whip it in. There is no occasion for any special type of suture. The object is immediately to close the leak. The perforation and the ulcer, of which it is a small part, should now be thoroughly infolded with as many sutures as are required adequately to accomplish the purpose. When the perforation lies close to the pylorus and the area of induration is wide, it may be desirable to turn the first portion of the duodenum acutely upon the stomach and suture it there. The essential step at this part of the technique is to bring good broad peritoneal surfaces together. Fowler's position, nothing by mouth, and the use of large quantities of water per rectum constitute an important part of the after-treatment.

Of the 17 cases personally operated upon drainage was instituted in 6 or 7 of the cases, being used in all of the earlier cases. In all but one instance where drainage was used it was through an extra suprapubic incision. In one case drainage was carried down to the perforation itself. In this case the perforation opened up within 48 hours and all stomach contents were discharged almost as quickly as swallowed. The patient died within a few days, and this constituted the only operative death in 16 consecutive cases. In one case in which drainage was not instituted a subphrenic abscess formed, followed by a pleural empyema. This patient died in the fourth week following operation, after making a prompt primary recovery. The extension of the infection to the pleura was probably due to inadequate drainage of the subphrenic abscess. The seventeenth case of the series died of a generalized peritonitis. Examination at autopsy showed the presence of seven active gastric ulcers.

ARE WE JUSTIFIED IN REMOVING A COMPARATIVELY HEALTHY GALL-BLADDER[1]

By W. H. MAGIE, M.D., F.A.C.S., Duluth, Minnesota

THIS short paper is based upon my personal experience in three hundred operations upon the gall-bladder and bile-ducts.

There has been, and still is, quite an animated discussion going on as to the relative value of cholecystostomy and cholecystectomy. There is no doubt that both methods of securing the same result have their advantages in properly selected cases. While looking over the literature of surgery of the gall-bladder, one is impressed with the wide difference of opinion existing among different authors. There is no department of surgery in which there is a greater difference of opinion than in surgery of the gall-bladder.

My object in presenting this paper is to make a plea in favor of saving the gall-bladder in at least a majority of the cases. The physiologists as well as surgeons are of the opinion that the gall-bladder has a function, and when we admit it has a function, we are compelled to admit that function, whatever it may be, should be conserved. It is claimed that its chief function is the storage of bile and that the bile, while in the gall-bladder, undergoes certain chemical changes that better fits it to participate in the processes of digestion and that at certain intervals this bile is discharged into the duodenum. These intervals correspond with the early stages of digestion. Again there is another theory, more recently put forward, concerning an additional function of the gall-bladder; that it acts as a pressure gauge keeping up the intrabiliary pressure. That the gall-bladder has a function of storing bile there can be no doubt. I have never seen an empty or collapsed gall-bladder when examining it during the course of operations in the upper abdomen. The fact that it is always filled with bile goes to prove that it has much to do with keeping up and regulating the pressure in the bile-ducts and liver. This theory is supported by the results of experiments upon animals. Eisendrath and others, have shown that when the gall-bladder is removed in dogs the remaining cystic duct dilates as do the common and hepatic ducts. The dilatation of the cystic ducts takes on the appearance of nature making an effort to reproduce the gall-bladder. This same dilatation of the cystic duct has been observed in man after cholecystectomy. This effort of nature to reproduce the gall-bladder is evidence that the gall-bladder not only has the function of storing bile, but also has a pressure regulation function upon the biliary system. These facts should be taken into consideration where the question of cholecystectomy versus cholecystostomy, is to be decided.

Some years ago, while discussing the relative merits of cholecystectomy versus cholecystostomy with one of the most popular surgeons of this country, he made the statement that "every gall-bladder that could be saved, should be saved; that removing the gall-bladder is like burning the bridges behind an advancing army; that it was valuable for drainage purposes especially in cases of cholecystitis accompanied by cholangeitis with swelling and plugging of the hepatic ducts as well as the common and cystic ducts with tarry bile."

Two years ago, while visiting this surgeon at his clinic, I saw him remove what looked to me very much like a normal gall-bladder. In reply to my question as to what percentage of gall-bladders he removed, he stated, "about 97 per cent." This answer was a very unexpected one, although I knew that his mind had greatly changed during the intervening years. The more we study statistics of gall-bladder surgery, the more confused we become, due to the fact that there is a wide difference in results even among the very best surgeons in our country, as well as surgeons of the countries across the Atlantic. To account for this wide difference of opinion is impossible. One class of surgeons has ability

[1] Read before the Western Surgical Association, Chicago, December, 1918.

and experience equal to that of the other class, but still results are very widely apart. How can we reconcile these widely divergent results? Probably, as in the case of the surgeon who informs me that he had to reoperate about one-third of his cholecystostomies, he left many gall-bladders that should have been removed at the first operation.

The first object we wish to obtain in many of these cases is the saving of human life, as many of these cases are very seriously ill when they reach the surgeon's hands. When to operate in many cases is a very important question and the outcome will depend on a decision as to the most opportune time for operation. An inopportune time for operation may account for the great difference in the percentage of mortality reported by different surgeons.

One of the most remarkable things I have observed is the great recuperative power the gall-bladder possesses. In my early experience before we were removing as many gall-bladders as we are now, we were astonished to see a great majority of our empyemic gall-bladders get well and stay well after drainage. If such results can be obtained from empyemic gall-bladders, we surely can expect a mildly diseased one to recover and become again a functioning organ.

It is generally conceded that cholecystectomy has much greater mortality than cholecystostomy. If so, then this consideration also should bear weight in making up our decision. Personally, I have had no mortality in my cholecystostomies, while on the other hand, my mortality following cholecystectomy has been about the average mortality, if not greater than that of other surgeons.

Recognizing the fact that the gall-bladder is not a vital organ and that man seems to get along very well without it, it still may be true that our patient does not get along so well without it as if he had it still functionating. Owing to the great difficulty in following up our cases, this question is often a very hard one to decide. The facts are that we have no means of knowing how much better off a patient might have been, if the gall-bladder had not been removed. Again, as to the morbidity following cholecystostomy, we encounter a wide difference of opinion. One surgeon makes a statement that "fully one-third of his cases treated by cholecystostomy had to be reoperated upon;" others have put the percentage of reoperated cases as low as 5 per cent. In my own experience, my cholecystostomy cases have not required reoperating in more than 5 per cent, and in every case where reoperation was necessary, it was on account of overlooked stones or stricture of cystic duct. In case of overlooked stones, the gall-bladder was simply reopened and stones removed and drained as before. In case of cystic duct obstruction, either an anastomosis with the duodenum was made or the gall-bladder removed.

I am of the opinion, that long-continued drainage followed with daily irrigation of the gall-bladder, after the removal of the drainage tube, contributes greatly to the thorough and complete cure of the pathological condition. Irrigation is also desirable for the purpose of washing out any overlooked stones that may have been left. I have on several occasions washed out, or at least have had stones present themselves at the gall-bladder sinus, as large as a good-sized marble, when they were easily removed. That drainage also has a good effect in the cases complicated with cholangeitis, when the ducts are clogged with thick tarry bile, there can be no doubt.

What are the indications for cholecystostomy? In the writer's experience, all cases of acute cholecystitis of only a few days' duration; also some cases of acute cholecystitis that have had previous attacks, provided the gall-bladder walls are not much thickened and free from adhesions that would indicate previous serious attacks, provided also, that the cystic duct is open and gall-bladder contains bile. Many acute gall-bladders contain but little bile at operation, due to swelling of cystic duct but within a day or two after drainage is established and sufficient time has elapsed for the swelling to have been reduced, the bile escapes freely through the drainage tube. All cases of simple cholelithiasis, when gall-bladder shows little signs of ever having been infected and when exploration of the interior shows a comparatively healthy mucous membrane.

When should cholecystectomy be resorted to? (1) In all cases of hydrops with stricture of the cystic duct; (2) in many cases of acute gangrene or threatened gangrene of the gall-bladder; (3) in all cases complicated with imbedded stones in the cystic duct with ulceration produced by contact with the imbedded stone that when healed would probably cause stricture; (4) in all very thick-walled gall-bladders due to fibrous or calcareous degeneration; (5) in all cases of ulceration due to pressure of large stones; (6) in cancer of the gall-bladder where the disease is limited to the gall-bladder.

PAROTITIS AS A POSTOPERATIVE COMPLICATION[1]

By CLIFFORD U. COLLINS, M.D., Peoria, Illinois

IN the year, 1915, four of our patients developed parotitis and three of them died. This was considered a sufficient reason for making a study of the subject, which was done. The things that were learned from that study seemed to be valuable, because we have had only two cases of parotitis since, both postoperative, and neither one died.

First, we went over our records and found that in six thousand one hundred patients who had been operated on, seven had developed parotitis, and one patient developed parotitis and died while waiting for operation. A study of these cases was made which follows.

All of these eight patients had been in the same hospital, which had no special significance, we thought, because practically all of our operative work is done at this hospital. Five were males and three were females. All of these eight patients had had abdominal operations except one and he had an abdominal infection, peritonitis following appendicitis. Three were operated on for obstruction of the bowels, two were operated on for ulcer of the stomach, one had a panhysterectomy done, and two had peritonitis. Two of the patients had fæcal fistulas and one had a colostomy when the parotitis developed. In five patients both glands were inflamed and in three patients the right gland only was affected. Five patients died while three recovered. Of the five that died three had abdominal conditions that might have caused death anyway, but in two of the five patients the parotitis was evidently the principal cause of death.

In six of the patients there was no positive evidence of suppuration in the glands. Two recovered without suppuration and four died. Of the four that died, three died in such a short time after the parotitis developed that there was hardly time for suppuration to become manifest. In two of the patients suppuration became apparent and the glands were drained.

It was deemed significant that seven of these patients had had abdominal operations and the other one had an abdominal infection, peritonitis. The seven patients operated on had received scopolamine $\frac{1}{100}$ grain and morphine, $\frac{1}{6}$ grain as a preliminary hypodermic before the operation. As is well known scopolamine dries up the secretions of the mouth and salivary glands. But one patient had not been operated on and had not received scopolamine. So evidently scopolamine was not a factor in the production of parotitis in that patient. All of the patients had been on the Ochsner treatment and nothing had been administered by the mouth for several days. An effort had been made to supply these patients with sufficient water by administering salt solution and bicarbonate of soda solution per rectum.

After a study had been made of our case records a study was made of the literature. Nearly all of the cases of post-operative parotitis reported in the literature followed abdominal operations. This seemed to be significant.

[1]Read before the Western Surgical Association, Chicago, December, 1918.

One of the most interesting articles we found was by H. B. Rolleston and M. W. B. Oliver.[1] They studied 1000 cases of gastric ulcer treated in St. George's Hospital in twenty years from 1889 to 1908. These patients were all treated medically and not surgically. In 470 patients treated by oral starvation there were 21 cases of parotitis or 4.5 per cent, while in 530 patients who were allowed something by mouth there were two cases of parotitis or 0.4 per cent. These two patients were on rectal feeding but had been allowed to suck a little ice. It should be noticed that these patients were suffering from an abdominal condition, gastric ulcer, that food and drink had been interdicted by the mouth in practically all of them, and none of them had been operated on. It is evident therefore that some factor other than something pertaining to a surgical operation was a cause of the trouble in these patients. The authors sum up their conclusions as follows:

"1. Secondary parotitis may complicate cases of gastric ulcer treated medically by oral starvation.

"2. That it occurs ten and a half times more frequently in such cases of gastric ulcer than in cases allowed fluid by the mouth.

"3. That it is an outcome of the dry condition of the mouth and that mouth washes do not prevent its recurrence.

"4. That it is more often unilateral than bilateral.

"5. That suppuration occurs in about one-fourth of the cases and that this constitutes a grave complication."

Curiously enough there is an article in the same journal by W. S. Fenwick entitled, "The Prevention of Parotitis during Rectal Feeding."[2] He believes that the infection ascends Stenson's ducts. He tried various measures to keep the mouth clean during the rectal feeding but they were not successful. Then he made an effort to promote a continuous flow of saliva by having the patient chew horse radish, pieces of raw meat at intervals, or keep a pebble constantly in the mouth. He finally had the patients suck an India rubber teat about two inches long which produced the desired effect. He said the patients sucked the teat for hours at a time and thus kept the mouth clean and moist. After he adopted this method he treated more than 300 cases of hæmatemesis by rectal alimentation without being troubled in a single instance by parotitis.

An article by Jacob Frank[3] discusses the different theories and sums up as follows:

"1. That it is highly probable that secondary parotitis is due to an ascending infection of Stenson's duct.

"2. That the onset of this complication may be prevented by attending to the following details: (a) mouth carefully cleansed before and after operation; (b) everything used for the anæsthetic should be sterile; (c) the anæsthetizer should avoid pressure on the gland while attempting to elevate the jaws during anæsthesia.

"3. When the swelling does not show any tendency to decrease in size, in about four days, it is advisable not to wait for fluctuation, as the location of the pus is beneath the dense parotid fascia. Therefore, free incision and drainage should be resorted to early."

From the study of our cases we are inclined to agree with Frank's conclusion, that the cause is usually an ascending infection from the mouth. All of our patients had been on the Ochsner treatment and fluids had been withheld by the mouth. Two of our patients had a fistula of the small intestine which allowed the liquid contents of the small intestine to escape before the fluid portion was absorbed. Both of these patients died. We became convinced that the parotid glands in our patients had become inactive because nothing had been taken into the mouth to excite activity of the gland, and that this inactivity predisposed the gland to infection. We also became convinced that our patients had not received enough fluid and this further contributed to inactivity of the parotid glands and dryness of the mouth. A study of the practical results of trying to give fluids per rectum convinced us that the patient did not get near as much fluid by that method of administration as we had tried to make ourselves believe that he did. When we put good

[1] Brit. M. J., 1919, May 29.
[2] Brit. M. J., 1909, May 29.
[3] Surg., Gynec. & Obst., 1912, xiv, 469.

honest nurses in charge of the proctoclysis and received honest reports we found that about half of the patients retained very little, if any, of the fluid. The remaining half of the patients retained perhaps half of the amount of the fluid administered. After two or three days' administration the rectum usually becomes irritable and retains none of the fluid. At least this has been my experience, and I would like to know whether I am alone in this experience.

So we decided that our first problem was to keep the parotid gland actively secreting and passing a current of secretion down Stenson's duct into the mouth, and our second problem was to keep the patient's body supplied with sufficient fluid.

In solving the first problem we tried the use of chewing gum but it did not seem to work well. Perhaps the ingredients of the brands of chewing gum defeated our purpose. At any rate we discarded chewing gum after a trial with it. Then we tried letting the patients chew on a rubber nipple following the suggestion made by the English author quoted above. While we were doing this a colleague called attention to the fact that acids excited the parotid gland secretion, as evidenced by the diagnostic measure of having a patient suspected of having mumps try to eat a sour pickle, and suggested the use of acids. We then tried putting a lemon drop in the nipple. Finally we gave the patients old-fashioned lemon stick candy to suck and that gave the best results. Whenever it is deemed best to withhold food and drink by the mouth for a time as in stomach operations, peritonitis, or paralytic ileus, for example, the patient is given a stick of lemon candy to suck but not to eat. It excites a flow of saliva and keeps the parotid gland active. Obervation has seemed to show that there is not enough secretion swallowed at one time to excite peristalsis of the stomach or bowels. At least the patients did not complain of peristaltic pains while using the candy.

The second problem of supplying the patient with sufficient fluid was solved by following the suggestion of Kanavel[1] and putting the hypodermoclysis needles in the axillæ, and leaving them *in situ* as long as necessary in order to save the patient the pain of reinsertion. A pint of normal salt solution may be given every three or four hours in this manner, and you know that the patient's body receives the entire amount of the fluid. We have left the needles in four or five days and the patients did not complain of discomfort. Incidentally, we believe that in our practice this measure has saved lives in other conditions as well as postoperative parotitis. Sometimes we keep the solution going continuously through the needles into the tissues for several hours.

If the inflammation has not been prevented by the above means, a free incision with adequate drainage should be instituted early, in about four days, if the inflammation is not subsiding by that time. The capsule or fascia covering the gland is so dense that it takes a long time for the pus to work through and give evidence of its presence on the surface of the skin. It usually works along beneath the fascia and breaks into the external auditory canal.

Vilray P. Blair[2] makes a plea for the early institution of surgical treatment on the third or fourth day, and shows a cut of the incision he uses. He claims that this incision heals spontaneously with a hardly noticeable scar. This incision has been used by the writer a few times and the results so far corroborate the claims of Blair.

CONCLUSIONS

1. Postoperative parotitis is more apt to occur after abdominal operations than operations on any other part of the body.

2. Its development is favored by a dry condition of the mouth and a lack of fluids in the body.

3. The infection usually ascends through Stenson's duct.

4. In patients whose abdominal condition makes it necessary to withhold food and drink from the mouth and stomach for a time, prophylactic treatment should be instituted.

5. The mouth should be kept clean and moist by its own secretions and the body should be abundantly supplied with water.

[1]Surg., Gynec. & Obst., 1916, xxiii, 483.

[2]Med. & Surg., 1917, March

6. A good way to excite the secretions of the mouth and to keep a current of saliva flowing *down* Stenson's duct is to allow the patient to *suck* on a stick of lemon candy after operation.

7. A very accurate and effective way to supply the body with fluid is to administer salt solution by hypodermoclysis. If this is done according to Kanavel's directions, there will be no pain in the administration and very little discomfort.

8. If the prophylactic treatment fails and parotitis develops and the inflammation is increasing, or is no better by the third or fourth day, the gland should be uncovered by a free incision and punctured in several places with blunt forceps and the incision packed with wet sterile gauze as suggested by Blair.

OBSERVATIONS REGARDING THE INDICATIONS FOR THE OPERATION OF CRANIAL DECOMPRESSION

By WILLIAM SHARPE, M.D., New York
Professor of Neurological Surgery, New York Polyclinic Medical School and Hospital

THE operation of cranial decompression has been so frequently misinterpreted and even confused with other cranial operations that it seems advisable to state its indications and contra-indications, and to describe the type of decompression with its most satisfactory technique.

As is indicated by the name of the operation, a cranial decompression presupposes the presence of an increased intracranial pressure; if there is not present an increased intracranial pressure then the operation cannot be described as a decompression, but rather as a craniotomy (if the bone-flap is replaced), or a craniectomy (if the bone-flap is permanently removed). In the recent literature, the term decompression is commonly used to indicate merely a trephine opening, and in may instances the dura not even opened or allowed to remain opened; surely a small trephine opening in itself with the dura opened may theoretically be, to a certain extent, a decompression, but its decompressive effect is practically almost negligible; again, to replace a bone-flap even though the dura is allowed to remain open is not a decompression because the decompressive effect of the operation is nullified. It would seem, therefore, that the three qualifications essential to a cranial decompression (in order that it be correctly considered as such) are:

1. The presence of an increased intracranial pressure.

2. The removal of a large area of the vault —usually 3 inches in diameter.

3. The dura to be opened and allowed to remain open; as the dura is inelastic in adults, no decompressive effect can be obtained unless the dura is opened, and if a permanent decompression is desired, then the dural opening must not be resutured but allowed to remain open.

Cranial decompressions were commonly performed in the past over the upper areas of the vault. Many disasters resulted from this prodecure; in fact, the operation of cranial decompression for this reason was practically discredited and it remained an operation of the last resort until Cushing placed the operation upon a rational basis. In patients having a marked increase of the intracranial pressure as in brain tumor, not only was the operative damage to the underlying, highly developed cerebral cortex a frequent result of such decompressions situated over the upper portions of the vault and thus followed by paralyses, impairment of the special senses, and only too frequently the immediate death of the patient, but the insecure closure of the operative wound (merely covered by the scalp) permitted huge herniæ cerebri to occur and only too frequently their end-result, fungi cerebri and the death of the patient after months of a vegetative existence. It is no surprise therefore that a few years ago the operation

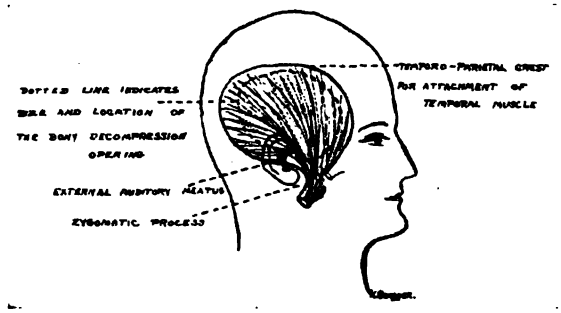

Fig. 1. The anatomical relations of the right temporal muscle with its attachment to the parietal crest above and to the inferior maxilla beneath, the zygoma below. Its diameter is usually 3 inches and more in adults, and forms ideal protection for the bony decompression opening.

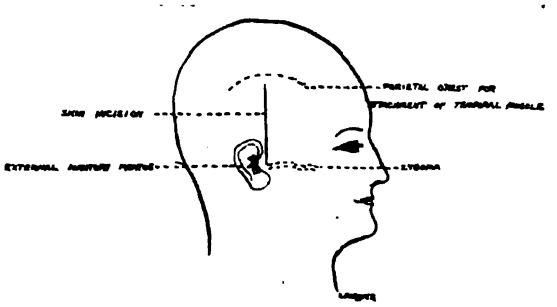

Fig. 2. The vertical skin incision of about 3 inches extending from the zygoma upward to the parietal crest and no higher—a very important factor in obtaining a firm closure.

of cranial decompression was avoided as long as possible—even at the risk of the delay producing an impaired vision and even blindness itself, and it is this transmitted dread and fear of cranial operations that have retarded the development of brain surgery possibly more than any other factor. Cranial operations as now performed, are no longer such extreme risks while the operation of cranial decompression is in itself no greater risk than the usual abdominal operation. This advance is due chiefly to better team work of the surgeon and the neurologist, a more practical conception of the purpose of the operation of cranial decompression, and then a most important factor, an improved surgical technique.

The operation of cranial decompression may be considered as a means solely of decompression, then of decompression plus exploration, and lastly of decompression plus drainage. The following intracranial conditions as benefited by the operation of decompression may be classified briefly as follows:

A. Decompression alone.

1. Brain tumors.

1. Irremovable tumors.

a. Large midbrain and basal tumors.

b. Large subcortical tumors, the removal of which would produce grave impairments, such as paralysis.

2. Selected cases of cerebral spastic paralysis due to an intracranial hæmorrhage at birth.

B. Decompression and exploration.

1. Brain tumors—non-localizable tumors, usually situated in the frontal and temporosphenoidal lobes.

2. Brain abscess—non-localizable abscesses—usually situated in the temporosphenoidal lobes.

3. Selected cases of organic epilepsy—Jacksonian in type or associated with increased intracranial pressure.

C. Decompression and drainage.

1. Brain injuries with or without a fracture of the skull.

2. Hydrocephalus—either of the internal or of the more common external type.

3. Brain abscess.

4. Early localized meningitis especially due to otitic infections.

There are several other intracranial lesions for which the operation of cranial decompression has recently been advocated, notably the condition of apoplexy. It is possible in rare and selected cases of cortical apoplexy alone, and at times in ventricular hæmorrhage (although the diagnosis and operative drainage should be almost immediate in order to have the patient survive), that the operation of cranial decompression and drainage might be considered in order to obtain the greatest ultimate improvement, but to advise this operation for the usual form of epilepsy—the internal capsular type, which occurs in 90 per cent of these patients—is a most unsurgical procedure; not only do these latter patients not have an increased intracranial

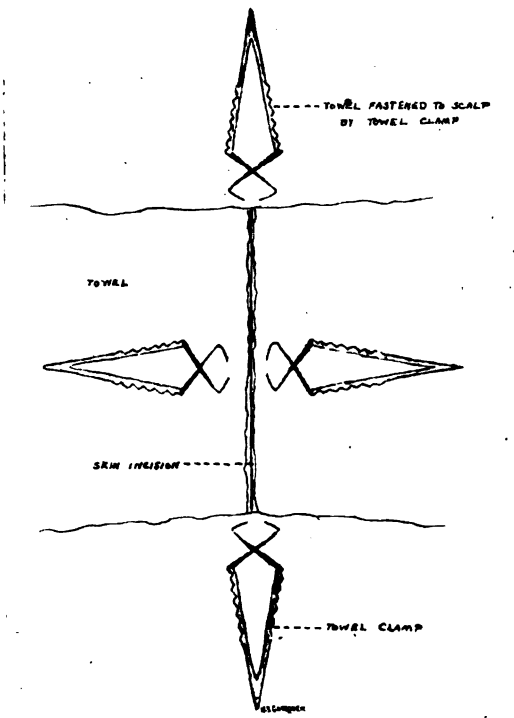

Fig. 3. The method of covering the skin (and thereby lessening the danger of infection) by clamping the towels to the skin itself; a wider exposure of skin is not only not necessary but is dangerous. The lobe of the ear cannot be made surgically clean.

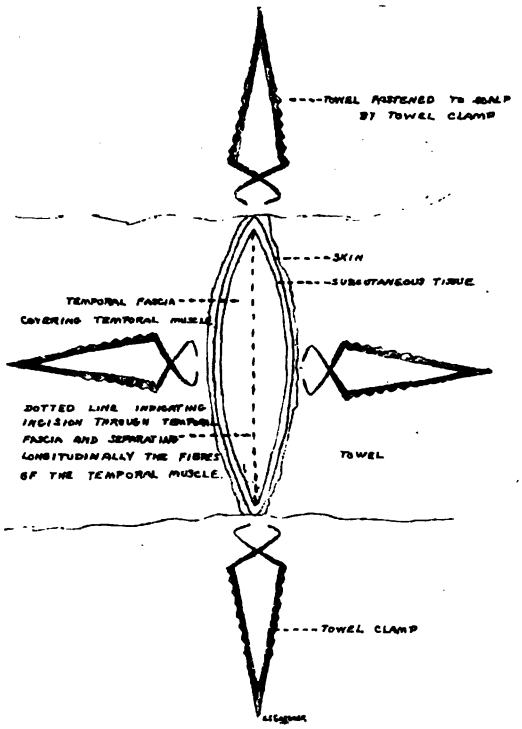
TOWEL FASTENED TO SCALP BY TOWEL CLAMP
SKIN
SUBCUTANEOUS TISSUE
TEMPORAL FASCIA
COVERING TEMPORAL MUSCLE
DOTTED LINE INDICATING INCISION THROUGH TEMPORAL FASCIA AND SEPARATING LONGITUDINALLY THE FIBRES OF THE TEMPORAL MUSCLE.
TOWEL
TOWEL CLAMP

Fig. 4. The skin incision down to the underlying temporal fascia. By the method of manual traction-pressure upon the edges of the scalp incision, the bleeding is practically nil; small curved hæmostats are now attached to the subcutaneous fascia and any possible bleeding points are compressed by the hæmostat being turned down.

pressure and therefore the operation described in the literature cannot be a decompression, but the operative damage resulting from the attempt to insert a needle into the internal capsule drain the hæmorrhage (even if it would drain) would be far greater than the impairment caused by the lesion itself; besides, some of the patients reported have been operated upon late when no drainage of the hæmorrhage would be possible; and even in the early cases operated upon, it must be remembered that the hæmorrhage into the internal capsule is not a free one, but it is enmeshed among the capsular fibers giving the appearance almost of liver tissue, and surely such hæmorrhage cannot be drained. To advise, therefore, a cranial operation upon such patients merely because medical treatment has not caused a marked improvement is surely not rational surgery.

There may be selected cases of acute cerebral œdema due to such toxic causes as occur in uræmia and certain other toxic conditions where, after medical treatment has failed, a cranial decompression might be advisable to lessen a high intracranial pressure and thus to a certain extent, spare the vision and avoid a medullary compression and its resulting œdema—always fatal. No cranial operation however, should be considered in these patients until repeated lumbar punctures have been proven inadequate. This work, however, is only in the experimental stage, and must be considered as a possible aid only in very selected cases.

The cranial decompressions of choice are the subtemporal decompressions for supratentorial lesions and the suboccipital decompression for infratentorial lesions. Naturally, the subtemporal decompression as a decom-

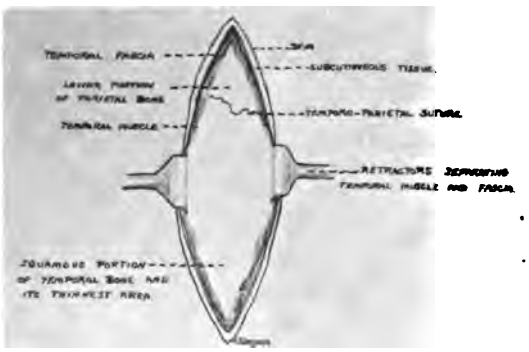

Fig. 5. The retraction of the temporal muscle and fascia exposes the underlying lower portion of the parietal bone and the squamous portion of the temporal bone; an area of bone of 3 inches in diameter can thus be exposed and removed.

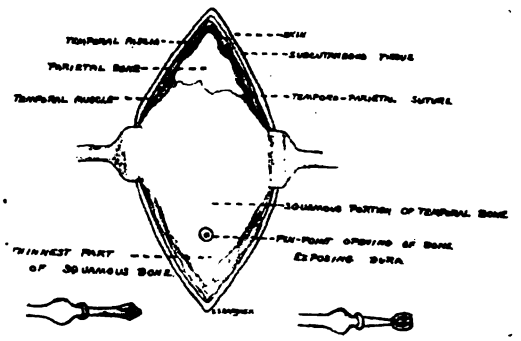

Fig. 6. At the thinnest part of the squamous bone the Doyen perforator, is used to make a pin point opening down to the dura, and then the Doyen burr, enlarges the opening down to the dura so that small rongeurs can be inserted to remove the bone.

pression alone is of little or no benefit for infratentorial lesions and should never be used in such conditions unless as a means of ventricular drainage (as in case of ventricular blockage); infratentorial lesions such as cerebellar tumor and abscess are always more effectively treated by the suboccipital operation of decompression, exploration and drainage. In this paper, however, the term cranial decompression means the subtemporal operation—the most satisfactory and effective method of decompression for supratentorial lesions; the vertical incision alone is used. (The advantages of this method of cranial decompression are detailed at the end of the paper.)

Let us consider briefly the three main purposes of the subtemporal decompressions:

A. PRIMARILY AS A MEANS OF LESSENING AN INCREASED INTRACRANIAL PRESSURE

1. *Brain tumors.* As the percentage of malignancy in brain tumors is high (almost 80 per cent), they naturally form a very discouraging part of brain surgery; then again, if the tumor is not malignant in itself, yet it may be so situated in the mid-brain or base that to remove it would either cause the immediate death of the patient or such a marked mental, physical or sensory impairment that it would not be justifiable; that is, the condition of the patient might be worse than before the operation. It is not creditable to brain surgery to remove the tumor (even if benign) if the mental and physical condition of the patient is worse than before the operation—the patient remaining a derelict.

It is in these very patients that, in order to lessen the headache and to save the vision, an early subtemporal decompression on one side and, if necessary, on both sides of the skull is most strongly to be advocated. Not only will the general condition of the patient be improved and blindness avoided, but the tumor may not continue to enlarge and may remain stationary and even become smaller apparently, and thus the patient be spared indefinitely; this is particularly true in young adults—the diagnosis being a tuberculoma of the mid-brain; the œdematous "wet" brain of the so-called pseudo-tumors might be also included. To allow these patients with a high degree of "choked disc" to develop a secondary optic atrophy and its resulting blindness merely because the tumor is considered an irremovable one or cannot be localized is an opinion that cannot be too strongly condemned. The operation of cranial decompression is no longer such a formidable procedure that it should be delayed and postponed until the life itself of the patient is endangered; to operate upon these patients blinded by long-continued intracranial pressure is most depressing and possibly hardly justifiable.

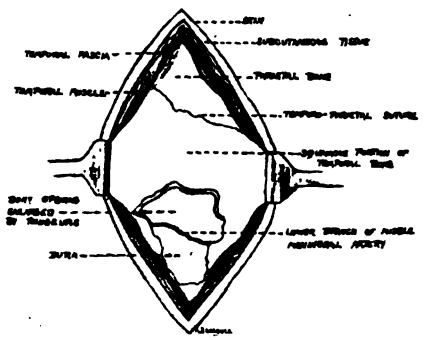

Fig. 7. (at left). Bony opening being enlarged by rongeurs backward, downward, and upward, but not forward, until last, on account of the middle meningeal artery lying adjacent to the anterior portion of the bony exposure. If the artery should be torn the hæmorrhage can be very easily controlled either with bone wax, a silver clip, or, if necessary, by a small packing of gauze tape.

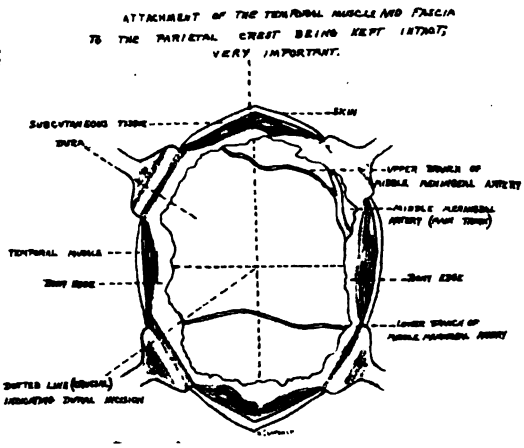

Fig. 8. Final size of bony opening, about 3 inches in diameter. The underlying dura is now opened as widely as possible by crucial and later stellate incisions. The dural hook and grooved director are first used, then the spoon spatula and dural scissors to enlarge the dural opening.

2. *Selected cases of cerebral spastic paralysis due to an intracranial hæmorrhage at birth.* These patients were formerly classed in that large group due to Little's disease and thus confused with cases of lack of development of the cerebral cortex and its pyramidal tracts, and also with those cases resulting from a former meningo-encephalitis—an infectious destructive process and naturally conditions which cannot be benefited by any cranial operation. But patients having a spastic paralysis due to an intracranial hæmorrhage at birth, not only can be differentiated by the presence of an increased intracranial pressure as ascertained both by the ophthalmoscope and more accurately by a measurement of the pressure of the cerebrospinal fluid at lumbar puncture by means of the spinal mercurial manometer, but those latter patients can be markedly improved by a lessening of this increased pressure by means of a simple subtemporal decompression. Naturally, only those patients having an increased intracranial pressure can be benefited and are therefore the only ones that are operated upon; out of a series now of almost 1800 patients that I have personally examined only 378 of them revealed the presence of an increased intracranial pressure, that is, about one out of every five patients examined, and these are the only ones for whom a cranial decompression can be of any benefit. The best results are obtained when the condition is diagnosed at the time of birth or shortly after it—and it very easily can be by the presence of blood under pressure in the cerebrospinal fluid at lumbar puncture; then, a modified cranial decompression with drainage of the free hæmorrhage will in many cases obtain a normal child. (Even repeated lumbar punctures with drainage may suffice if the intracranial hæmorrhage is not too large and the pressure too high; in these latter cases, of high intracranial pressure the cranial operation of opening the parieto-squamous suture combined with a modified subtemporal decompression and drainage is advisable; the dura must always be opened.) The older the child, the less is the improvement that can be ultimately obtained by the operation of merely lessening the increased intracranial pressure resulting from the earlier hæmorrhage; frequently a mild secondary external hydrocephalus results in these patients from the blockage of the stomata of exit of the cerebrospinal fluid in the cortical veins and sinuses; this condition can be drained accord-

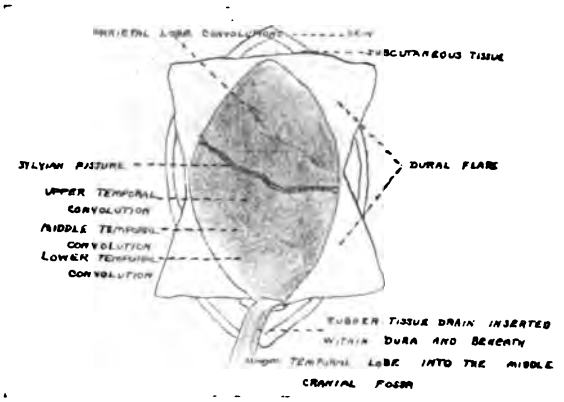

Fig. 9. (at left). The dural flaps opened showing the underlying cerebral cortex of the lower parietal lobe and upper portion of the temporosphenoidal lobe. Hæmorrhage and excess cerebrospinal fluid can thus be removed and a "waterlogged" brain be decompressed. A rubber tissue drain is inserted at lower angle of incision, as indicated.

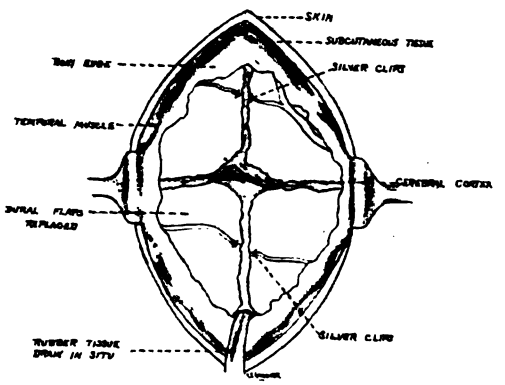

Fig. 10. Dural flaps replaced but not sutured so that a permanent decompression results. The silver clips can be seen clamping the meningeal branches in the dura. The rubber tissue drain is left *in situ*. Closure of the incision is now begun.

ingly at the same time by a modified decompression operation (vide Hydrocephalus).

The pathology of intracranial hæmorrhage in the patients is very instructive. It was formerly believed that the hæmorrhage always caused a primary destruction of brain tissue and therefore, no regeneration being possible, that these patients were all hopeless. As permission for a postmortem examination is obtained before operation upon each patient, it has been very surprising to ascertain, either at the operation or at autopsy, that the intracranial hæmorrhage caused a primary destruction of brain tissue in only 26 patients out of 364 patients operated upon; that is, in only 7 per cent. The death-rate of these operations was only 38 out of the series of 374 operated patients—that is, a mortality of only 10+ per cent, and a postmortem examination was made in each case. The hæmorrhage is almost always a supracortical one with later cystic formation, so that the mental and physical impairments in these patients are due to the increased pressure of the overlying lesion—both a general and a localized increase of the intracranial pressure. It is the lessening of this increased intracranial pressure in these selected patients that permits a marked improvement in them, both mentally and physically.[1]

[1] Internat. Clinics, 1917, iii, series 27.

B. DECOMPRESSION PLUS EXPLORATION

1. *Brain tumors.* Infratentorial growths are more easily localized than are the ones situated above the tentorium, so that if the former cerebellar tumors can be excluded, then it is a question of ascertaining the cerebral hemisphere in which the lesion is placed; at times, the clinical signs point very clearly to the location in the hemisphere, and yet only too frequently it cannot be definitely and accurately elicited; these are the patients who should not be permitted to develop a secondary optic atrophy and even blindness itself while an accurate localization in the hemisphere is being sought; an early subtemporal decompression will not only lessen the intracranial pressure but it will afford a practical means of locating the lesion by exploratory punctures—it being possible to explore carefully the entire ipsolateral hemisphere; if the tumor is found (and it very frequently is found in the comparatively silent area of the temporosphenoidal lobe directly beneath the subtemporal incision so that it can be removed immediately), then the proper method of removal can be used, and if the tumor is not found (also unfortunately, a frequent occurrence) then a decompression has at least been performed, the headaches improved and the vision spared so that a later localization of the tumor

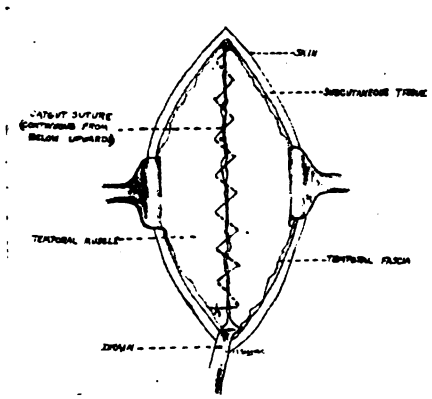

Fig. 11.

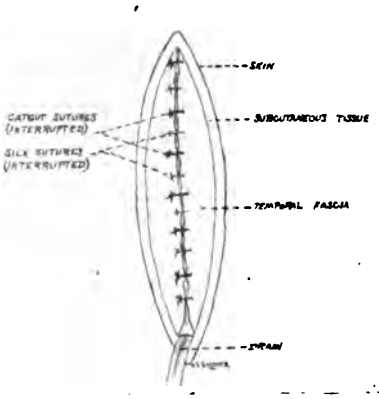

Fig. 12.

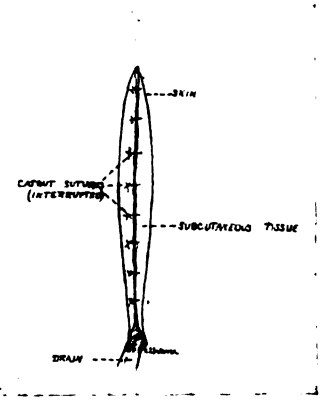

Fig. 13.

Fig. 11. Continuous catgut suture (from below upward) is used to approximate the fibers of the temporal muscle over the bony opening.

Fig. 12. Interrupted small black silk sutures alternating with the interrupted catgut sutures for closure of the temporal fascia, making a firm approximation possible. The silk sutures are permanent sutures and prevent an opening of the incision if the catgut sutures should be absorbed too early.

Fig. 13. Subcutaneous fascia sutured with interrupted catgut; continuous catgut (loosely) may be used in children in order to hasten closure in special cases.

may occur and its removal be possible and—the patient not blind. The lateral ventricle may also be tapped with a ventricular puncture needle to ascertain whether it is dilated or not; if dilated then the tumor would necessarily be either basal posteriorly or even subtentorial; ventricular drainage temporarily might be instituted to improve the general condition of the patient until the tumor, if subtentorial, could be removed. To perform large osteoplastic "flap" operations over the parietal lobe in search of a tumor which may not be present even in the underlying hemisphere, and if present, then possibly at the base or in extreme frontal or occipital portions and very frequently in the lower portion of the temporosphenoidal lobes—situations requiring another incision and removal of bone in order to approach the tumor—such tremendous bone-flap operations should never be performed unless it is surely known that the tumor can be removed through the incision; if the tumor is not found and the intracranial pressure is high, then great difficulty will be encountered in making a firm closure without causing a definite damage to the more highly developed parietal cortex; in these cases a simple subtemporal decompression would permit an accurate localization of the tumor—whether frontal, occipital, parietal, temporosphenoidal or basal—and then the tumor could be removed later through the appropriate incision.

2. *Brain abscess.* The great majority of brain abscesses are cerebral and situated usually in the temporosphenoidal lobe adjacent to the ear involved—otitic disease being the most common cause of brain abscess formations. As in brain tumors, infratentorial cerebellar abscesses are more easily diagnosed than the supratentorial temporosphenoidal ones, so that if cerebellar abscess can be excluded, then the operative approach of choice is through the "clean" subtemporal area and not through the "dirty" infected field of the mastoid incision; all drainage operations for brain abscess are really exploratory procedures, as the abscess may not be present or not found, and if the dural incision has been made through the infected mastoid area then the danger of causing a diffuse meningitis is very great indeed. If, however, the subtemporal exposure has been made and if the abscess is not found, then at least a decompression has been performed and the danger of a meningitis is slight, and if the abscess is found, then it can be freely and safely drained through the lower angle of the subtemporal incision. Not only does the decompression incision

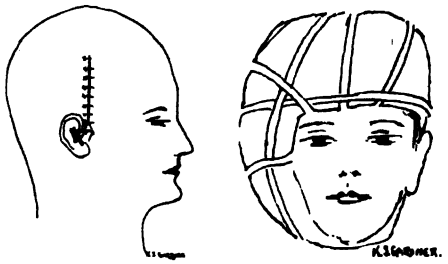

Fig. 14. (at left.) Final closure of skin incision with interrupted small black silk sutures. Drain allowed to remain *in situ* for one or two days, according to the drainage of blood and cerebrospinal fluid.

Fig. 15. Roller bandage of sterile gauze applied to head and firmly anchored by several adhesive strips. A small cotton pad placed behind the ear lobe prevents its painful compression against the head.

afford better drainage for the deeper subcortical abscesses by means of the double glass tubes, but the opportunity afforded of locating these deep abscesses is much greater and easier through the wider exposure of the decompression incision.[1]

3. *Selected cases of epileptiform convulsions —Jacksonian in type or associated with an increased intracranial pressure.* The surgical treatment of organic epilepsy is most discouraging, and no cranial operation should ever be advised in cases of long standing in the belief that the condition can be cured. In only very selected cases of short duration where the attacks are definitely of the Jacksonian localizing type and where there is a marked increase of the intracranial pressure (still persisting after an interval of at least three months has elapsed since the last attack), is the operation of cranial decompression and exploration or any cranial operation justifiable; even in the most carefully selected cases the results are not encouraging, and yet good result and apparently even a cure is occasionally obtained in these patients. Cranial surgery, however, cannot be said to offer much hope to these patients, except possibly to these very early selected patients as described above. To operate upon old chronic cases of whatever severity is hardly justifiable. Even the removal of the primary cause of the cortical irritation with its resulting convulsions—such as a cortical tumor, old depressed fracture of the vault and the cyst formation due to a former supracortical hæmorrhage may result in only a temporary cessation of the convulsions in the older patients; but these patients should be diagnosed early, the irritating lesion removed and then the outlook is not so gloomy; besides removing the lesion itself, it is always wiser in these patients to relieve permanently the intracranial pressure due to the resulting cerebral œdema of trauma by means of a subtemporal decompression.

[1] The Laryngoscope, St. Louis, 1914, March.

C. DECOMPRESSION PLUS DRAINAGE

1. *Brain injuries with or without a fracture of the skull.* The mortality of brain injuries with or without a fracture of the skull has been notably decreased within the past decade; the former death-rate of 50 per cent and even higher has been reduced in several hospitals to 30 per cent and even lower. This marked improvement is due to a more general appreciation of the important factor of increased intracranial pressure in these patients and if present, then the most satisfactory method of relieving it by means of the subtemporal decompression. As is well known, it is not the fracture in these cases nor the hæmorrhage in itself that is so dangerous, but rather the presence of a high intracranial pressure—whether due to hæmorrhage or œdema—and its consequent medullary compression and the only too frequently resulting medullary œdema that render these cases so serious—not only as to life but also to their future normality.

Formerly, the treatment of these patients had been so discouraging that it became a commonly accepted belief that they would all "get along just as well without operation as with operation." This statement is perfectly true for over one-half of the patients—there being no increased intracranial pressure in practically this percentage, and naturally no operation (except in depressed fractures of the vault) would be indicated; but of the remaining patients upon whom a cranial operation was performed, the resulting high mortality—in many hospitals being 80 per cent and even higher—was due chiefly to the operative method used—in almost all

cases the extensive osteoplastic "flap" operation being performed and the dura very frequently not even being opened (and therefore no real decompression possible) or a small and totally inadequate trephine opening—the size of a one-half dollar piece and even smaller being considered as a sufficient operative procedure—these two operative extremes—the former tremendous operation of great risk to these seriously injured patients and the latter so-called operation of no possible, or if possible, then of very slight benefit to the patients—these two operations were usually performed either during the period of initial shock within a few hours after the injury when it is now realized that no operation should ever be performed as it is merely an added shock to the patient and takes away the patient's chance of surviving the shock, or the operation was performed during the terminal period of medullary œdema in the hope that the patient would be given a chance to recover; these patients when they have once reached this stage all die—operation or no operation. Naturally, under these conditions, the operative mortality was very high. More recent observations, however, in a series of over 500 patients, have confirmed a growing belief in the following cardinal principles in treating brain injuries with or without a fracture of the skull:[1]

1. All depressed fractures of the vault should be elevated or removed for fear of later complications, particularly epilepsy.

2. The presence of a fracture in patients having brain injuries is not an important factor in their treatment; the patients most seriously injured very commonly have no fracture at all, and conversely, the less serious of brain injuries are frequently associated with tremendous linear fractures of the vault —an important channel however of lessening an increased intracranial pressure by the drainage of free blood and excess cerebrospinal fluid or œdema, and thus a cranial operation be avoided. Naturally, basal fractures into the middle ear and especially into the nasal and pharyngeal cavities may permit an infective meningitis, and yet this grave complication is comparatively rare.

3. The expectant palliative medical treatment of quiet, ice helmet, catharsis and liquid diet is sufficient for over one-half of the patients having little or no increase of the intracranial pressure.

4. A marked increase of the intracranial pressure (as revealed in slightly over one-third of these patients by the ophthalmoscope and the measurement of the pressure of the cerebrospinal fluid at lumbar puncture by means of the spinal mercurial manometer) and *not* by the late and extreme pressure signs of medullary compression (such as a pulse-rate of 50 and lower, Cheyene-Stokes respiration and pulse, a high blood pressure and profound unconsciousness) should be lessened by a cranial decompression and drainage—not necessarily at the site of the fracture if present and by no means over the upper cortical areas, but rather by means of the subtemporal decompression—the safest and most effective means of decompression, drainage and closure, possible in these patients. The dura must always be opened (except in the cases of simple extradural middle meningeal hæmorrhage which are rare) and allowed to remain open for a permanent decompression and drainage of the consequent traumatic cerebral œdema so common in these patients. If the intracranial pressure is extremely high, then a bilateral subtemporal decompression and drainage may be necessary —apparently in about 5 per cent of patients.

5. There are two periods in the treatment of these patients when no operation is advisable—no matter how seriously the patient is injured nor how high the intracranial pressure may be; these periods are—first, the stage of initial shock immediately following the brain injury when the pulse-rate is 120 or higher; any operation during this period of traumatic shock is merely an added shock to the patient and takes away the patient's chance of surviving the shock; if, however, he does survive the shock, then he does so in spite of the operation; and the second period in which no operation should be performed is the stage of medullary œdema—the terminal moribund period—operation or no operation; when once the pulse has reached its lowest level of medul-

J. Am. M. Ass., 1916, lxvi, May 13.

lary compression and then begins to ascend rapidly to 100, 120, 140 and higher, then an operation does not "give the patient a chance" (as formerly advocated), but merely hastens the exitus. If these two periods in the operative treatment of brain injuries are avoided and the latter of these—medullary œdema—usually can be anticipated, then the mortality of brain injuries will be decreased to 30 per cent and even lower, while the operation of decompression and drainage will cause not only the recovery of patients as to life but also as to their future normality.

2. *Hydrocephalus*, both of the internal and also of the more common external type. A diffuse meningitis is the usual primary cause of this condition; if the ventricles are blocked by exudate or adhesions in the aqueduct of Sylvius or at the foramina of Majendie and Luschka, then the internal type of hydrocephalus results, but if this ventricular blockage does not occur yet a hydrocephalus of the external type develops because the cerebrospinal fluid cannot be excreted as normally through the cortical veins and sinuses on account of their blockage by the former meningeal exudate.

In the operative treatment of hydrocephalus either of the internal or external type, it is obvious that to drain merely the blocked cerebrospinal fluid of the ventricles into the subarachnoid or subdural spaces, by means of corpus callosal punctures or tubes, would, even if these openings remained patent, only change an internal hydrocephalus into an external one—with resulting little, if any, impairment The object therefore, of all operative procedures in these patients is to drain continuously and permanently the blocked cerebrospinal fluid beyond the cerebrospinal canal—that is, into the blood stream (the ideal method and not yet practicable permanently) or into the extradural tissues, such as the subcutaneous tissues of the scalp, rich in lymphatics. The subtemporal decompression permits such drainage of the ventricles when blocked and of the subarachnoid and subdural spaces (in the more common type of external hydrocephalus) by means of several linen strands extending from the ventricles outward through the temporal lobe (a comparatively silent area), and from the subarachnoid and subdural spaces outward beyond the opened dura into the subcutaneous tissues of the scalp in a stellate manner.[1] At present, this method of drainage through the subtemporal decompression assures an excellent drainage to all but apparently the most severe types of internal hydrocephalus; naturally, the earlier the operation is performed following the development of the hydrocephalic condition, the greater is the chance of the child to approximate normality.

3. *Brain abscess.* As stated above, the usual type of brain abscess situated in the contiguous temporosphenoidal lobe following otitic disease is most safely and effectively drained through the lower angle of a "clean" subtemporal decompression by means of double glass tubes, so that the inner tube may be used to drain the abscess while the outer tube remains always *in situ*, and thus the abscess, when once found, is not lost. Apparently, a large decompression opening tends to lessen the danger of a complicating meningo-encephalitis—almost always fatal, whereas the opening through the "dirty" field of the mastoid not only increases the danger and lessens the opportunity of a careful exploration of the adjacent brain in search of the abscess, but it does not provide a satisfactory and efficient drainage for the deeper subcortical brain abscesses; again, to puncture the dura blindly with a knife through the mastoid opening or any dural exposure is most unsurgical.

4. *Early localized meningitis.* Similar to brain abscess formations, localized meningitis must frequently results from pre-existing otitic and sinus disease; cranial fractures are also another common cause. Here again, in the early patients, in whom lumbar punctures do not reveal the presence of an active organism in the cerebrospinal fluid and therefore indicating that the meningeal infection has not yet become a diffuse process, the operation of subtemporal decompression and drainage will offer a definite chance of recovery—although the prognosis is most unfavorable; it seems that in only the early

[1] Am. J. M. Sc., 1917, April.

and still localized conditions of meningitis will the operation be of any benefit.

The technique of the operation of cranial decompression is described briefly in the accompanying sketches; the vertical incision and not the former curved one is most satisfactory.

The advantages of this subtemporal decompression are the following:

1. It exposes, as widely as necessary, a comparatively "silent" area of the brain, the temporosphenoidal lobe, and therefore any operative damage to the exposed cortex will not appear clinically; also, in patients having a high intracranial pressure the danger of a hernial protrusion of a highly developed area of the brain with resulting paralysis, etc., cannot occur.

2. Being situated midway between the frontal and occipital lobes, it permits the careful exploration of all parts of the ipsolateral hemisphere; ventricular puncture is also possible.

3. It exposes the area of the middle meningeal artery so frequently injured in the traumatic cases, and also affords excellent drainage to the middle cranial fossa at its lowest point—a very important factor in the treatment of brain injuries.

4. A firm closure of the decompression opening is obtained by means of the strong temporal muscle and its overlying fascia with their strong attachment to the parietal crest *intact*—a most important requisite in patients having a high intracranial pressure; hernial protrusions with their frightful fungi are most rare.

5. Technically, the operation is less difficult than other cranial operations in that the skull opening is made through the thinnest portion of the vault—the squamous portion of the temporal bone.

6. The vertical incision is preferable to the former curved one in that it renders more possible a careful hæmostasis of the scalp by means of the method of manual pressure—traction and the clamping of the main branch of the temporal artery at the very beginning of the operation, whereas the curved incision passes through the various branches of the vessel in the scalp and they must be clamped individually; again, the vertical incision not only permits drainage at the lowest point of the skull, but it makes possible a large subtemporal bony opening without risk of loosening the attachment of the temporal muscle and fascia to the parietal crest, and thus a firm closure with no danger of cerebral hernia is assured.

7. The great frequency of temporosphenoidal lesions such as tumors, abscesses, and brain injuries make this routine exposure of the subtemporal decompression a most important aid in the treatment of underlying subarachnoid lesions.

CONCLUSIONS

The operation of cranical decompression is one that should be used much more frequently than it is at present; especially is this true in the conditions of brain tumor, brain abscess, brain injuries and in selected cases of spastic paralysis due to an intracranial hæmorrhage at birth.

The subtemporal method of cranial decompression is the ideal route; besides being less difficult technically, it exposes an area of the brain most frequently involved. This permanent decompression opening does not weaken the skull in that the thick overlying temporal muscle protects it most adequately so that hernial cerebri are not to be feared.

The operative mortality is low. Patients with intracranial conditions should not be permitted to become blind or to reach the dangerous stage of medullary compression without a subtemporal decompression being performed early.

DEPARTMENT OF TECHNIQUE

INTERPOSITION OPERATION FOR THE CURE OF PROLAPSUS UTERI AND CYSTOCELE

By FREDERICK W. JOHNSON, M.D., F.A.C.S., Boston
Gynecologist-in-chief, Carney Hospital
AND
LOUIS E. PHANEUF, M.D., Boston
Assistant Visiting Gynecologist, Carney Hospital

THE excuse for reporting our experience, in operating on 90 cases, and the end-results in 68 of them, is that practice has taught us a technique which not only facilitates the operative procedure, but secures excellent end-results and is attended with almost no danger and no shock. Our mortality has been nil.

Most cases of prolapsus with the usual attending cystocele, rectocele, and relaxation of the pelvic outlet occur in elderly and old women, a class of women who demand an operative procedure that is attended with as little danger and shock as possible. Almost all our patients were from the laboring class and as soon as possible were obliged to return to their homes and household duties, just the class that would put any operation for prolapsus and cystocele to its severest test.

The interposition operation described by Thomas J. Watkins, of Chicago, is the foundation on which we have built. The drawings, which were made from case No. 85, show in what way our procedure differs.

The following questions were sent to 90 patients, and 68 replied. The first was operated on May 31, 1909, and the last May 5, 1918, an average of about ten a year. Eighty-nine were operated on at the Carney Hospital.

1. Did the operations relieve you of the troubles of which you complained?
2. Is there falling down of the parts?
3. To what extent has your general health been improved by the operations?

One patient, sixty years of age, had no return of the procidentia for nearly one year, then a ventral fixation was done, there being no return of the cystocele. This also failed and she died two years later. Five had return of the procidentia soon after the operation, but no return of the cystocele. One had partial relief. One died during childbirth one year after the operation The doctor did not answer our letter asking for particulars. One has a twenty-two months old girl, was the "easiest of all her labors," no return of the "falling down of the parts." Four were relieved for various periods of time, now there is "falling down of the parts." One died of cerebral hæmorrhage two months after the operation.

From answers received from 68 patients it appears that 54 have been wholly relieved of the "troubles complained of" at the time of the operations; there has been no "falling down of the parts," and there has been "improvement in their general health.'

This is certainly gratifying as we know of no other operation for prolapsus uteri and cystocele, attended with almost no danger and no shock, that gives as good end-results. It is an operation from which elderly and old people recover quickly.

It was found necessary to repair or amputate the cervix in 55 of the cases, and Crossen's or Emmet's operation for relaxed pelvic outlet and rectocele was done in 76. The oldest patient was sixty-nine, the youngest twenty-one. In one case there was procidentia where pregnancy and childbirth had not been the cause. Forty-six were between fifty and sixty-nine years of age, while thirty were between forty and fifty.

The five cases in which there was return of the procidentia soon after the operation, and the cases in which there was only partial relief were among our first, and failure was due to not carrying out in detail the technique which experience showed us was necessary.

In every case in which there is a relaxed pelvic outlet a Crossen or, if there is much of a rectocele, a Bandler operation should be done.

Pregnancy should not occur after this operation.

In most operations for cystocele only the vaginal mucosa is removed and a return of the

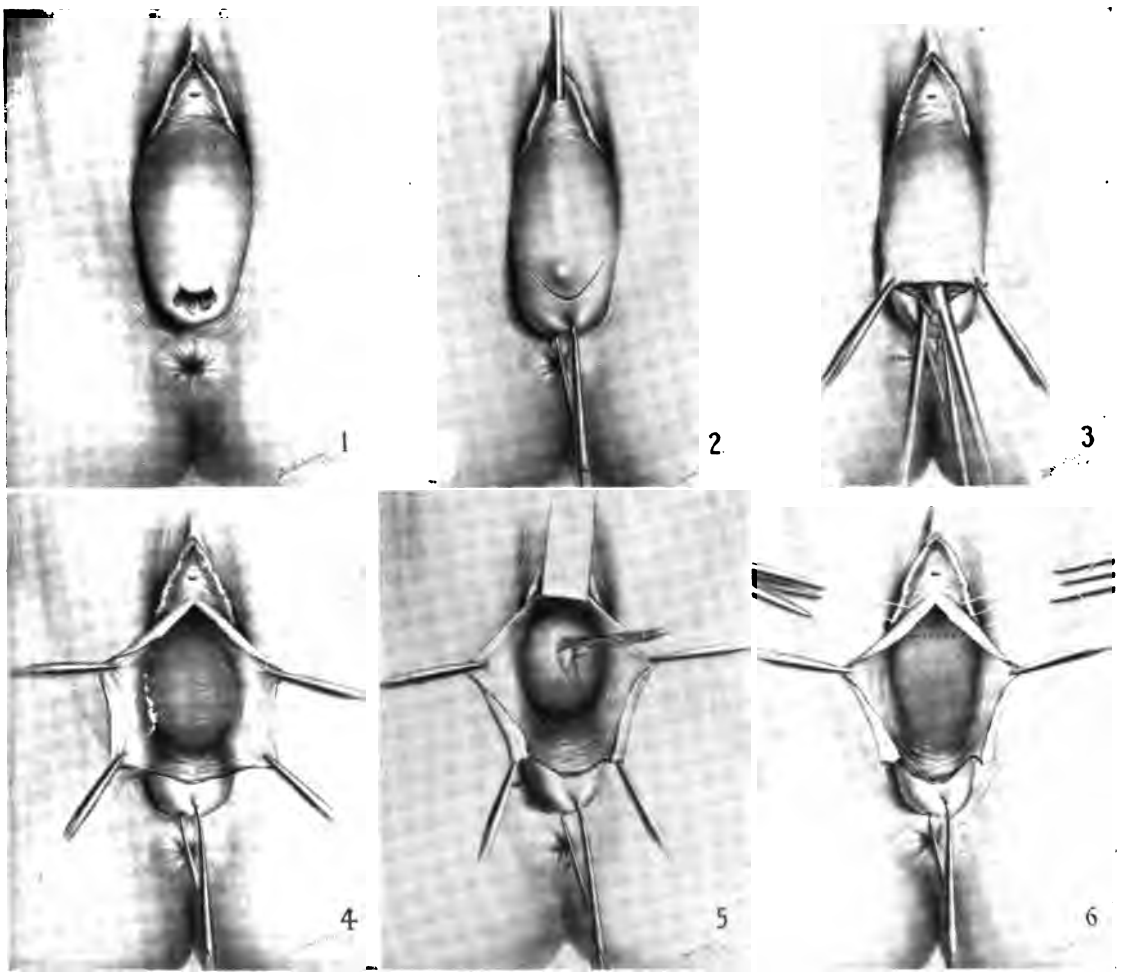

Fig. 1. Case No. 85.

Fig. 2. Same case. Male sound in the bladder, with point toward operator, to indicate where first incision is to be made.

Fig. 3. Upper edge of first incision, drawn down and held taut by two Ochsner clamps, while the bladder is being separated from the fascia of the anterior vaginal wall, by curved sharp-pointed scissors.

Fig. 4. Bladder freed entirely of fascia from fundus to vesical neck.

Fig. 5. Peritoneum has been opened and uterus is being delivered into vagina.

Fig. 6. First three sutures of silkworm-gut passed through vaginal mucosa, fascia, and deeply into anterior surface of the fundus uteri. These sutures remain *in situ* one month.

cystocele is almost certain to take place. It is only by separating the *fascia* completely from the bladder, removing what is necessary of it with the vaginal mucosa, to get rid of the cystocele, and then fastening the fascia and mucosa to the whole extent of the anterior surface of the uterus down to the cervix that one can secure a permanent anteversion of the uterus and an obliteration of the cystocele so that it will not return.

It is very difficult at the best to remove the fascia from the bladder in strips with scissors, and in some cases it is impossible. If the anterior vaginal wall, fascia and mucosa, is separated from the bladder first by curved pointed scissors (Fig. 3) and then by blunt gauze dissection no fascia will be left on the bladder. The fascia with its overlying vaginal mucosa will be an entity, and can be used to the greatest advantage.

It is necessary to cut through the fascia in the median line down to cervical tissue at the base of the bladder, sweeping it off from side to side until the whole base of the bladder is free. The

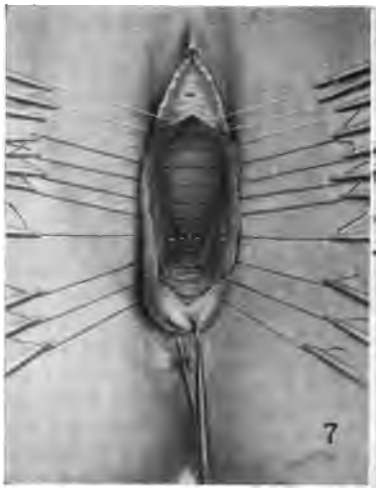

Fig. 7. Slack of anterior vaginal wall (cystocele) has been cut away. Vaginal mucosa and fascia are sutured to the anterior uterine wall from fundus to cervix with chromic catgut. A most important suture (marked red) is the one at the junction of corpus uteri and cervix. This straightens out the uterus, and throws the cervix back.

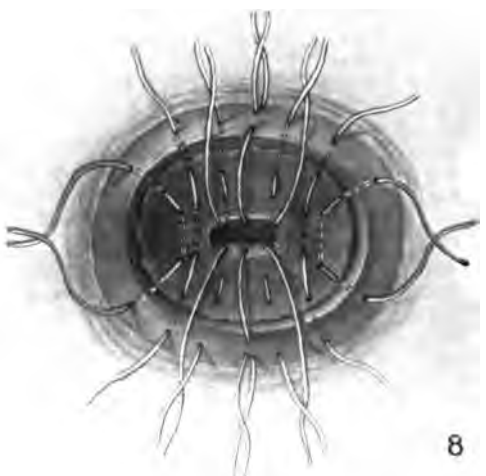

Fig. 8. Amputation of the cervix uteri. The two red sutures are most important ones.

Fig. 9. Cervix amputated and operation for interposition finished.

Fig. 10. Crossen's operation for relaxed pelvic outlet finished.

Fig. 11. The location of the incision for opening the pelvic floor. The author prefers to place the incision well within the vaginal opening, as indicated by the heavy black line. *xx* indicates the area to be caught by the forceps. This marks the end of the incision and is situated on each side just below the opening of vulvovaginal gland.

Fig. 12. Estimating the size of the repaired opening, by bringing together the extremities of the intended incision.

Fig. 13. Opening the pelvic floor with sharp-pointed scissors.

Fig. 14. Freeing the edges of the vaginal flap, preparatory to catching it with forceps.

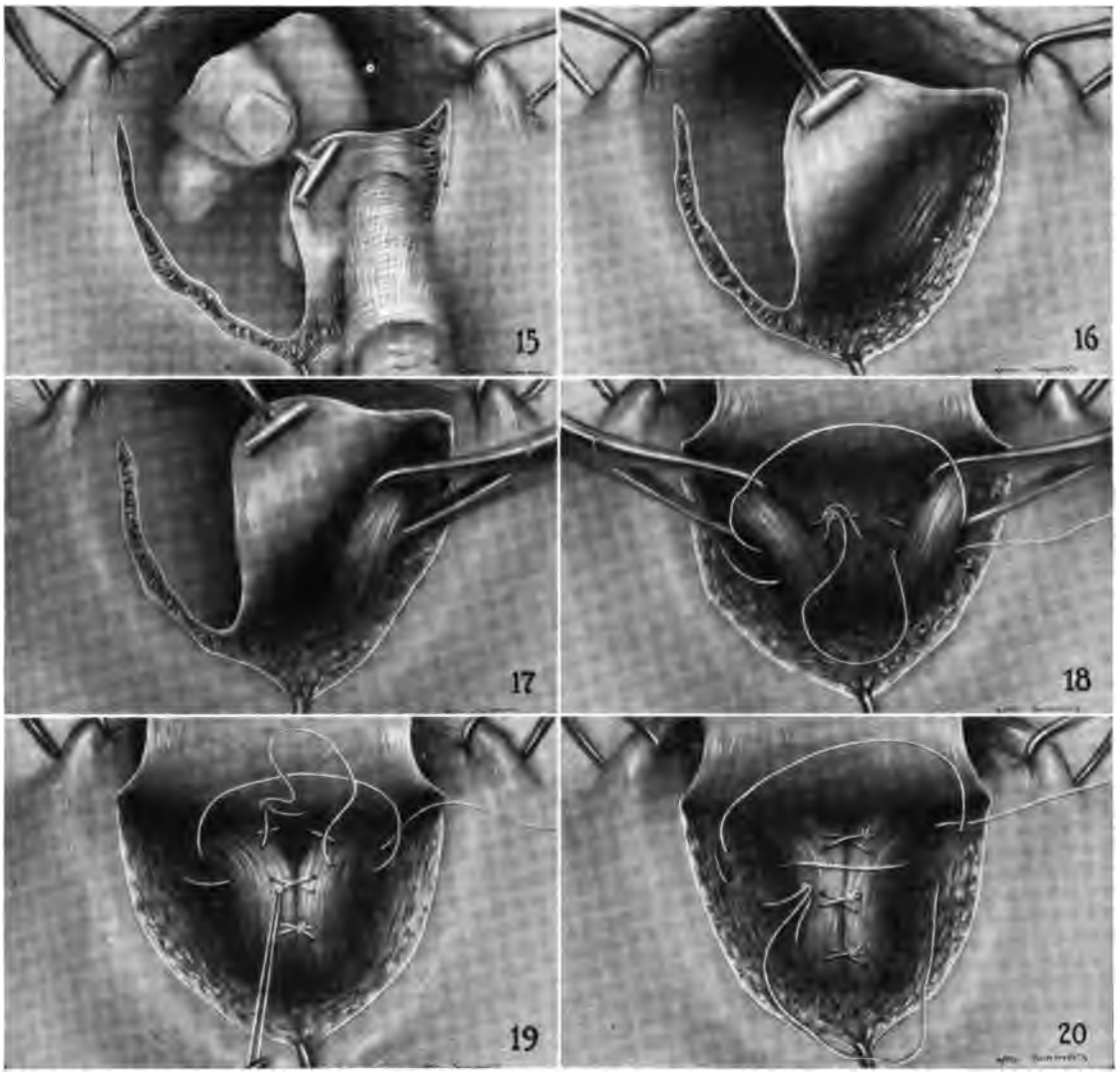

Fig. 15. Rolling off the underlying tissues from the vaginal wall with the gauze-covered finger. The motion is that of a push and a roll combined, and is made against the left forefinger which furnishes the counter pressure. The fingers are shown ungloved for better identification and appreciation of relations. They are of course gloved in the work.

Fig. 16. The flap has been turned back on the left side, showing the pelvic sling exposed in the depth of the wound.

Fig. 17. The sling caught with forceps and brought out for better identification and more accurate passing of the sutures.

Fig. 18. Sling brought into view on each side, and the first approximation suture passed. It is well to make two rounds with the suture before tying.

Fig. 19. First suture tied and left long as a tractor. Second suture passed and tied (below first), and third suture being introduced.

Fig. 20. All the sling-approximation sutures tied. The first suture passed through the more superficial tissues.

bladder is freed by gauze dissection from the fascia on the sides, and toward the urethra as far as necessary to take in the slack of the anterior wall, leaving enough to prevent too great traction when the sutures are tied.

When this is thoroughly done the bladder will slide off very easily from the anterior surface of the uterus before the index finger.

Freeing the bladder in this way allows it to be easily pushed up, and consequently it is not

Fig. 21. Superficial perineal tissues approximated over the deep sutures. The excess of vaginal flap is being excised.

Fig. 22. Closing the vaginal wound.

Fig. 23. The vaginal wound closed. If a continuous suture is used it should be locked securely at intervals.

NOTE.— We use interrupted sutures throughout in the closure, see Fig. 10.

pressed upon by the fundus uteri when it is delivered into the vagina, and when it is fastened there.

It is very necessary to the patient's after-comfort that the bladder lie smoothly, not in folds, and the base be not elevated on the posterior surface of the fundus uteri. In many of the long standing cases there is a chronic cystitis at the base of the bladder which is caused by residual urine containing colon bacilli, and if possible this condition should be cured before an operation is attempted.

The bowels are not moved for seven days. The catheter is not used unless necessary, and after each voiding the parts are sprayed. After forty-eight hours, a short vaginal douche of sterile water is given through a soft catheter, morning and night.

For diet the white of an egg in one-third tumbler of flavored water is given every three hours when the patient is awake, for six days. As much water as the patient desires is given.

For the relaxation of the pelvic outlet we have used the operation described by H. T. Crossen, of St. Louis, in his *Operative Gynecology*, from which, with the author's permission, we have copied the drawings which we have used to illustrate this article.

UNUNITED FRACTURE OF THE PATELLA AND OF THE OLECRANON

BY FRED H. ALBEE, M.D., SC.D., F.A.C.S., NEW YORK
Professor and Director of Department of Orthopedic Surgery, New York Post-Graduate Medical School and Hospital

FRACTURES of the patella and the olecranon are analogous in so many of their clinical features that the writer has chosen to discuss them both in the same article. In both instances muscular action tends to produce wide separation of the fragments. The patella and the olecranon each overlies an important joint.

In treating a *fresh* fracture of either of these structures, the bone-graft is not recommended, its use being reserved for cases of long-continued non-union or mal-union. Furthermore the use of silver wire is condemned as a fixative agent because of its lack of strength and treacherous nature. The wire gives way particularly at the knot or twist. The latter defect was thoroughly established by the writer some years ago in a Government testing-machine for determining tensile strength. In many instances the wire cracked at the twist without the knowledge of the surgeon. A further objection to silver wire is that it is non-absorbable, acts as a foreign body and exercises a directly destructive influence on the bone with which it comes in contact. For these reasons kangaroo tendon is a far more preferable material for fixation purposes in all fractures.

FRACTURE OF THE PATELLA

Fracture of the patella is of two kinds: (1) transverse, and (2) vertical, irregular, or comminuted. The subjects are usually adult males.

1. *Transverse fracture.* This type is usually the result of muscular action, and usually occurs

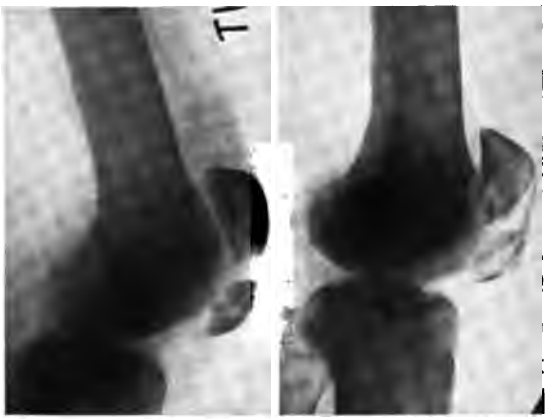

Figs. 1 and 2. Fracture of the patella before and after the insertion of an inlay bone graft. Figure 1 shows the separation of the fragments and the tilting forward of the proximal surfaces. In Figure 2 the approximation of the fragments and correction of their forward tilting are readily appreciable, while the outlines of the inlay graft and the progress of osteogenesis are well shown. The roentgenogram shown in Figure 2 was taken 8 weeks after implantation of the graft.

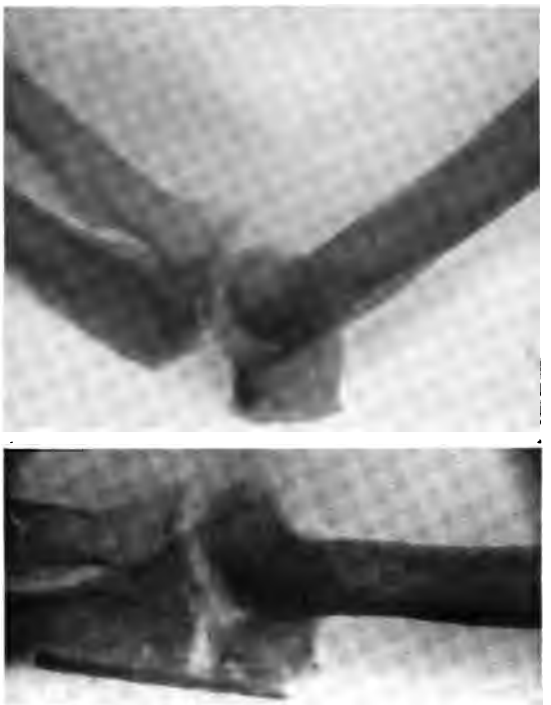

Figs. 3 and 4. Fracture of the olecranon before and after operation. Figure 3 illustrates the wide separation of fragments due to action of the triceps muscle, while Figure 4 shows the close approximation of the fragments secured by the inlay bone graft and the rapid osteogenesis which has taken place.

in an effort to prevent falling. With the knee bent at an angle of 60° to 90° and the ligamentum patellæ taut and drawn tightly against the femoral condyles, the pull of the quadriceps the largest muscle in the body, is suddenly exerted with full force at its insertion on the top of the patella, fracturing the latter and tearing the lateral expansions of the quadriceps tendon. The degree of separation of the fragments varies: There is always considerable, and there may be extreme, separation, the upper fragment sometimes being drawn up to the middle of the thigh.

The line of fracture is regular and almost exactly transverse. After the accident, tags of torn periosteum and fascia fall in between the fragments and become quickly adherent. The fragments are often rotated forward or backward on their transverse axes. Long-standing cases have an elongated fibrous band connecting the fragments.

Although the patient can walk, he does so with difficulty, swinging the leg forward and locking it in hyperextension before putting his weight upon it, but in some cases pain prevents the patient from walking and also from lifting the foot when lying down.

The diagnosis of transverse fracture is evident at a glance upon inspection of the roentgenogram. Clinical diagnostic features are: (a) inability to extend the leg, to raise the foot from the bed while recumbent, and voluntarily to straighten the flexed knee; (b) rounded swelling of the knee the result of effusion; (c) palpation of the fragments, the interval between them, and their mobility.

This fracture occasionally requires differentiation from rupture of the quadriceps and from rupture of the ligamentum patellæ or tearing out of its insertion, viz.:

1. *Quadriceps rupture.* The patella can be moved downward *in toto*, leaving a palpable gap *above* it, at the site of rupture.

2. *Rupture of the ligamentum patellæ or avulsion of its insertion.* The patella can be moved upward *in toto*, leaving a gap *below*, at which point the signs and symptoms are localized.

Treatment. Autogenous bone-graft for ununited transverse fracture of the patella. The usual treatment for fracture of the patella consists of exposing the line of fracture and uniting the fragments with either absorbable or non-absorbable sutures. Formerly, metal wire, such as silver

Fig. 5. Fig. 6. Fig. 7.

Figs. 5, 6, and 7. Fracture of the patella before and after correction by inlay bone graft. The three photographs are of the same case. In Figure 6 the outline of the graft is seen in relief in the anteroposterior view. In Figure 7 the graft is seen in profile while behind it and between the patellar fragments abundant osteogenesis is taking place.

or phosphorbronze wire was used; but recently the surgical pendulum has been swinging away from non-absorbable material and kangaroo tendon has been largely used. The metal wire formerly used was as a rule either placed in a drill hole in each fragment, or in such a way as to encircle the patella.

The degree of separation of the fragments in these fractures depends largely upon the amount of laceration of the capsule and connective tissue on either side of the patella. Muscle pull may interfere with the union of the patella fragments, however carefully the clots and fibrous material are cleaned from between them or whatever may be the material used to hold the fragments in close apposition. Not infrequently a re-fracture occurs, either immediately or remotely after operation, in spite of every precaution. Fibrous union, with a varying degree of separation of the fragments and a proportional amount of disability in the extremity, is a more frequent unfortunate result. To remedy either of these conditions, Rogers has suggested that an autogenous bone graft be taken from the crest of the patient's tibia and implanted on the front of the patella to bridge the line of fracture. It is believed that this is an important step and that it offers a trustworthy means of relieving this condition. It would seem, however, that Rogers' technique can be much improved by using the author's inlay method, which he has not only applied to relieve fibrous union and re-fracture, but which he offers as a means of securing immediate and solid bony union in certain fresh fractures of the patella (see Figures 1, 2, and 5 to 19). In other words, the inlay graft is a reliable preventive of fibrous union and re-fracture, as well as a remedy for those conditions when they already exist, and it obviates the employment of a foreign body. Besides affording slight and imperfect contact, a graft placed on the anterior surface of the patellar fragments is likely, on account of its superficial location, to produce pressure necrosis of the soft overlying tissues.

Technique. As in all bone-graft operations on the extremities, a tourniquet is applied to the upper portion of the thigh. The fracture fragments are approached by a U-shaped flap the apex of whose convexity lies over the ligamentum patellæ, its base over the femoral condyles or by the incision shown in Figure 8. All fibrous tissue between the fragments is carefully removed; in the case of re-fracture or fibrous union, the fragment ends are freshened (Fig. 9). The fragments are approximated, and the lateral rents in the fibrous capsule are repaired at the sides with interrupted sutures of medium kangaroo tendon (Fig. 10). The central portion of the anterior surface of the patella is then denuded of its periosteum and peri-osseous tissues by turning back laterally flaps of these structures on each fragment (Fig. 11).

An outline of the bone to be removed, about one and one-fourth by three-fourths of an inch, is made on the anterior surface of the patella with the point of a scalpel. With the small motor-saw, cuts are made to a depth of one-third of an inch along the outlines already made (Fig. 13). The fracture surfaces of the patellar fragments are tilted forward and with the small motor saw and a

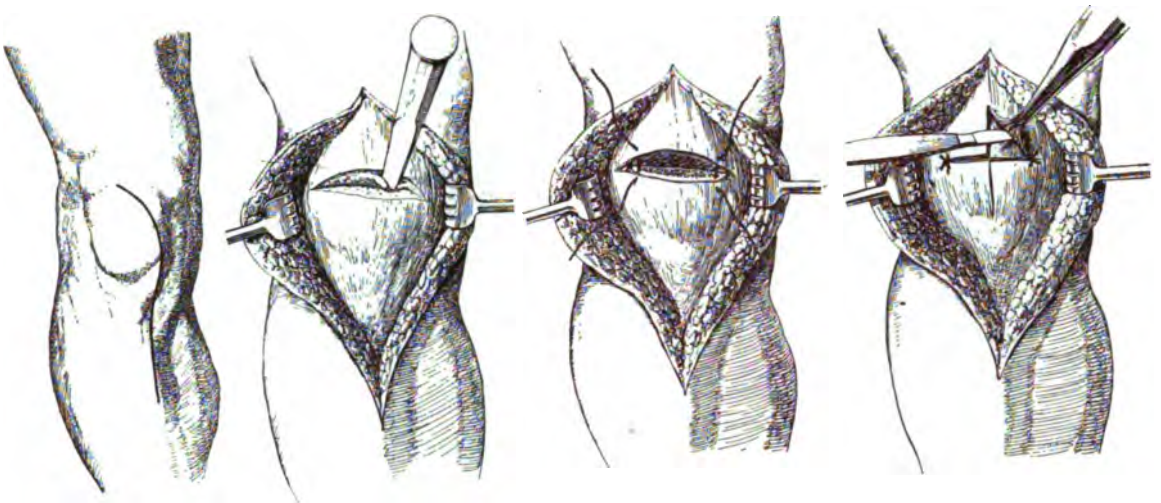

Fig. 8. Fig. 9. Fig. 10. Fig. 11.

Fig. 8. Semilunar and vertical skin incision used by the writer in exposing the patella for the repair of an ununited fracture.

Fig. 9. Removing the fibrous tissue from between the patellar fragments by means of a sharp thin osteotome.

Fig. 10. Lateral rents in the fibrous capsule are partially sutured at the sides with interrupted sutures of small kangaroo tendon.

Fig. 11. Central portion of anterior surface of patella is being denuded of its periosteum and perilosseous tissue by turning back to each side flap on each fragment.

narrow thin sharp osteotome the bone within the previously made saw-cuts is removed to a depth of one-third of an inch from the anterior patellar surface (Fig. 14).

With the patellar fragments in good apposition careful measurements are made of the inlay gutter with calipers. The antero-internal surface of the upper portion of the tibia, where the surface is broad and the cortex thin, is exposed and, by means of the caliper measurements or a wax model of the gutter in the patella the outline of the inlay graft required is made in the periosteum (Figs. 16,and 17.) The cortex in this portion of the tibia is of the proper thickness for the graft. The inlay is inserted with its periosteal surface anterior, and the periosteal flaps of the patella are pulled over it with interrupted chromic catgut sutures. The rents in the capsule are then sutured with kangaroo tendon as far as the sides of the patella (Fig. 19.) To insure greater fixation, the fragments are securely held by a figure-of-eight suture of medium-size kangaroo tendon passed laterally to the anterior portion of the ligamentum patellæ and quadriceps tendon, directly above and below the fractured bone, crossing in front of the transplant. The skin incision is closed by a continuous suture of No. 1 plain catgut. The limb is immobilized in a plaster-of-Paris splint for four weeks.

This operation is of the greatest advantage where there has been a fibrous union in an old case and a separation of the fragments coincident with a shortening of the quadriceps tendon and muscle; and when the fragments cannot be brought into close apposition this space can be spanned by a long graft, which, as the result of hypertrophy, will entirely, or to a large degree, fill in the hiatus between the fragments. It is advisable to stimulate osteogenesis by placing fragmented grafts about the inlay.

2. *Vertical, irregular, or comminuted fracture of the patella.* This type is due to direct trauma, usually a fall. There is little, if any, separation of the fragments. The lines of fracture are irregular, and may be ragged. There is no interposition of soft tissue between the fragments, The fracture is frequently compound.



Fig. 12. A type of the inlay graft used by the writer for the repair of fractures of the patella.

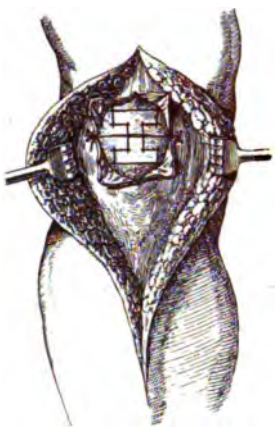

Fig. 13.

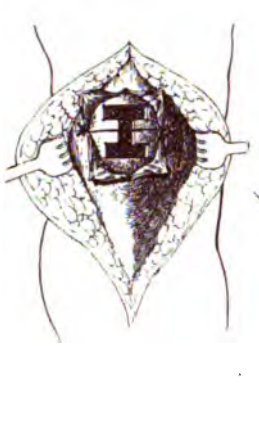

Fig. 14.

Fig. 15.

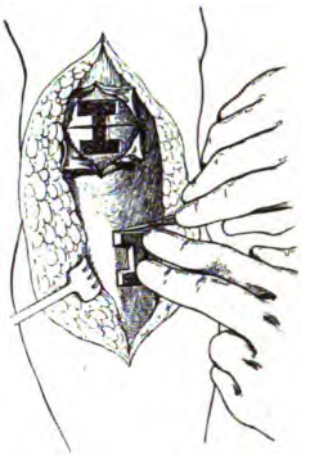

Fig. 16.

Fig. 13. An outline of the bone to be removed, about 1¼ by ¾ inches, has been made on the anterior surface of the patella with the scalpel. With the writer's small motor saw cuts have been made to a depth of one-third of an inch along the outlines thus made.

Fig. 14. The fracture surfaces of the fragments have been tilted forward and with small motor saw and narrow thin sharp osteotome the bone within the previously made saw cuts has been removed to a depth of one-third of an inch from the anterior patellar surface.

Fig. 15. Melted paraffin has been poured into the "mold" in the patella. After hardening the model is pried out of its bed with a narrow thin osteotome.

Fig. 16. The wax model of the gutter in the patella is laid upon the antero-internal surface of the upper portion of the tibia and the graft outlined in the periosteum.

The diagnosis of this type depends chiefly on roentgenography, in the absence of which pain, loss of function, localized tenderness, mobility of the fragments, and the very small interval between them (in contradistinction to wide separation in transverse fracture) are sufficient.

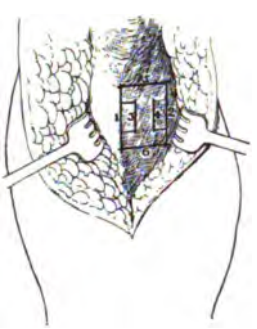

Fig. 17.

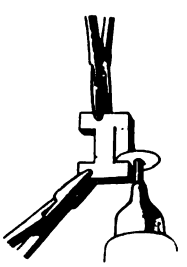

Fig. 18.

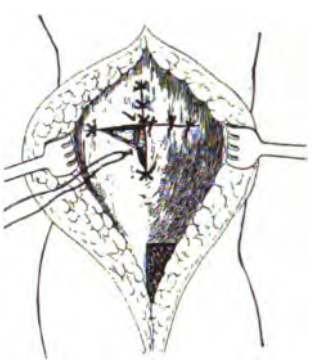

Fig. 19.

Fig. 17. The material for the inlay is removed from the tibia *en bloc*, by cutting with the small motor saw along the outlines previously made with the wax model. The cuts should be made in the manner shown in this figure and in sequence as indicated by the small numbers, *1*, *2*, *3*, *4*, *5* and *6*. The block of bone is then lifted from its bed with a narrow thin osteotome.

Fig. 18. After its removal the graft material is held with two pairs of hæmostats, while the two longitudinal cuts are connected by cross cutting with the small motor saw and the two intervening portions of the bone are removed.

Fig. 19. The inlay has been inserted with its periosteal surface anterior and the periosteal flaps of the patella are pulled over it with interrupted chromic catgut sutures. The capsule rents are here shown sutured with kangaroo tendon. The fragments are still more securely held together by a figure-of-eight suture of medium kangaroo tendon which is passed laterally through the anterior portion of the ligamentum patellæ and quadriceps tendon, directly above and below the fractured bone, crossing in front of the transplant. The skin incision is closed by a continuous suture of No. 1 plain catgut and the limb immobilized in a plaster-of-Paris splint for 6 weeks.

Treatment. These cases, due to direct trauma with little or no separation of the fragments, do well under immobilization in a plaster-of-Paris splint from toes to groin and continued for a period of five to six weeks. Or a posterior wire splint can be used with the leg strapped to it and elevated on pillows to relax the quadriceps, and with coaptation splints applied to the front of the thigh, to insure its relaxation. At the end of five to six weeks, the patient can get about on crutches with a light posterior splint on the leg, and massage combined with very light passive motion may then be instituted. Weight-bearing should be cautiously used, at first without flexion.

FRACTURE OF THE OLECRANON

This not uncommon fracture is due either to direct trauma (the usual cause) or to overactivity of the triceps. In most cases the fracture is clean cut and transverse, and there may be considerable separation of the fragments. In children the fracture may result from a fall on the elbow.

The symptoms consist of loss of active extension of the forearm, of varying degrees of severity. With the forearm extended, mobility and crepitus may be obtained by grasping and moving the olecranon. Roentgenography offers the most certain means of diagnosis.

Treatment. In fresh fractures of the olecranon, exposure by incision, drilling the fragments, and the insertion of kangaroo tendon for their fixation is believed to be the best method of treatment. In ununited fractures of this process, the inlay graft, held in place by kangaroo tendon, can be easily applied on account of the superficial location of the olecranon, and promises better results than are offered by any other procedure (Figs. 3, 4, 20, and 21.) The graft is inlaid to the tip of the olecranon, on the one hand, and as far into the shaft on the other as the amount of bone sclerosis indicates. A sliding graft, or one obtained from the tibia may be used, as conditions indicate; or a peg graft may be used instead of the inlay, as the surgeon may elect. For this particular fracture, the peg should be made with a generous head; this can be easily done by not pushing the graft completely into the dowel-cutter. The forearm is flexed, and the insertion of the triceps into the olecranon split in equal halves down to the bone; the center of this end surface of the olecranon is then selected and a drill hole (using the proper size drill) is bored completely through the olecranon fragment and into the long (shaft) fragment of the ulna for a distance of approximately 1¼ inches. The drill is then withdrawn, and the peg (about ¼ inch in diameter) driven home. The dowell peg in this instance is obtained from the tibia and sharpened by means of the author's motor lathe.

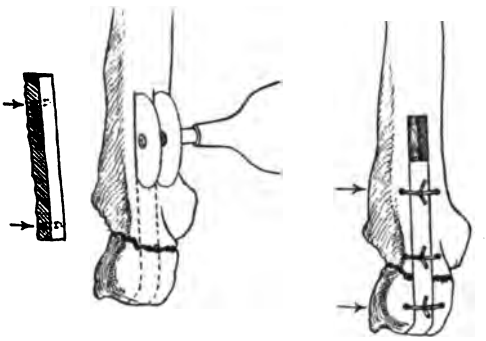

Fig. 20. Technique of sliding inlay graft for fracture of the olecranon process. Arrows indicate drill holes in graft.

Fig. 21. The inlay graft is held firmly in place with kangaroo tendon.

SOME TECHNICAL POINTS IN GASTRO-ENTEROSTOMY AND GASTROPLICATION[1]

By A. SCHWYZER, M.D., F.A.C.S., St. Paul, Minnesota

THE technique of gastro-enterostomy has been established for such a long time and has been so copiously discussed and illustrated, that I hesitate to present a few minor points, which may have been part of the technique of many others. Nevertheless they seem of sufficient interest to be discussed in brief. They apply to the side-to-side methods. The Y-shaped gastro-enterostomy is not considered in this paper.

The bugbear of gastro-enterostomy has been for a long time the vicious circle; and it has never quite disappeared. No doubt, atony of the stomach walls is an important factor in its formation. The surgeon therefore has to do everything possible to secure an easy outlet from the stomach and to avoid the creation of any difficulty of passage. The manner of attaching the gut, whether this be in the iso- or the anti-peristaltic sense, has produced much discussion. The easy floating away of the efferent loop has always been the one factor considered, though this is perhaps of less importance than what happens to the afferent loop. Nevertheless it must be admitted that, in case the efferent loop should become fixed, even in a moderate way, by postoperative adhesions, a kink may be disastrous. While a free intestinal loop, even if kinked, may easily move on its contents, the difficulty at the site of the gastro-enterostomy lies in the circumstance that the peristaltic wave of the gut, when it passes the gastro-enterostomy opening, loses much or most of its chymus, in case the stomach is greatly relaxed. The *vis a tergo* thus is lacking. Under these conditions it is possible that even comparatively slight obstacles become serious. Antiperistaltic attachment of the jejunum may give better results to many operators, because by this procedure the inlet is kinked off, a beneficial feature in itself.

If the pylorus is patent, food will pass through it even after gastro-enterostomy, and will appear at the afferent loop. The afferent opening will, therefore, not have the same tendency to contract and remain contracted as the distal jejunum, which in case of atony of the stomach is not forcibly offered food. Now as soon as there is no free outlet from the lower opening, the duodenum and the jejunum above the gastro-enterostomy will become distended. In vicious circle the afferent loop becomes so ballooned that the efferent opening is compressed and pushed out of the way. To guard against all this we should bear in mind the picture of this fully established vicious circle. We, therefore, have to see that the afferent opening cannot become too large, because by enlarging it annexes that originally neutral territory, the portion of gut which lies between the two ends of the gastro-enterostomy incision. It annexes it for the formation of a wide funnel, and the lower jejunal opening is then pushed to the wall and more or less shut by a spur. Besides the guarding against a too wide upper opening we must remember that the upper loop can become very large and bulging. Even if the upper opening is reduced in size, the distended loop above it, though very short, could become so large that it might compress the outlet. For this reason we do well to fix the afferent gut for some distance on the stomach. For the efferent gut it is desirable that it lead rather freely away from the stomach, and that its opening be somewhat funnel-shaped. To accomplish this in posterior gastro-enterostomy we have for years used the following simple means (Figs. 1 and 2):

First. The stomach is drawn through the slit in the mesocolon as far as is feasible.

Second. The edge of the mesocolon is fastened to the stomach as far on the periphery as possible. In front the mesocolon is often really fastened to the anterior wall of the stomach by grasping the stomach wall through the omental attachment, where it can be had between vessels.

Third. The gastro-enterostomy is made large enough to allow the tips of the four fingers in it.

Fourth. The loop is attached in the isoperistaltic sense; and the stoma extends from a point about halfway between the greater and lesser curvatures on the afferent (left) side to close to the greater curvature on the efferent end. Thus, after the stomach is replaced, the gastro-enterostomy opening has a downward course on the posterior wall of the stomach, and is as much a postero-inferior outlet as can well be procured.

Fifth. After the posterior Lembert suture is placed, the gut incised down to the submucosa, the second suture applied and the mucosa opened, we then make it a point to grab with the third suture a broad edge of mucosa. It never appealed to me to excise the mucosa. What protects the tissues against secondary ulcer on the suture line

[1] Read before the Western Surgical Association, Chicago, December, 1918.

Fig. 1.

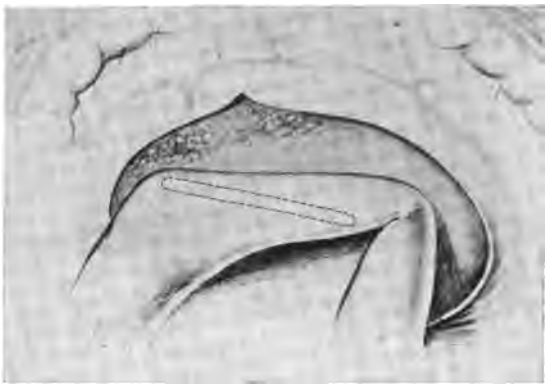

Fig. 2.

is the mucosa, and for this reason we prefer to secure a bulky covering by pulling ample mucosa over the wound. For the same reason that we are principally concerned to secure a tight covering with mucosa, we do not lay great stress on carefully inverting the mucosa when the anterior half of this suture is placed. If the edges are somewhat everted, the suture does not look as neat; but seen from inside there is no exposed submucosa. The middle suture buries this eversion, and the sewing goes more quickly.

Sixth. The anterior Lembert suture is placed in such a manner that, after the distal half is finished in the ordinary way, it not only pulls the jejunum on the proximal half over to the left and upward by a slanting direction of the suture (see Fig. 1), but the suture in its progress toward the left angle gradually includes broader peritoneal surfaces and thus pulls the gut over onto the stomach. This creates a narrowing and a kinking of the afferent gut, and at the same time brings about a broader agglutination at the point where the most pulling is to be expected. The lower jejunal opening is drawn into a more favorable position and its lumen is held open and free from obstructing folds, while the upper opening is rendered rather inaccessible from the gastro-enterostomy side. This point I have demonstrated many times and it appears to be of value. The sketch shows the suture in a somewhat exaggerated way to emphasize its peculiarity. In reality it is usually preferable not to grasp quite as much surface, and to increase the effect to the desired degree by a few additional interrupted sutures. The kinking and therefore comparative inaccessibility for food of the afferent loop is probably, as mentioned before, a beneficient feature in the antiperistaltic attachment method; and this principle is underlying in Polya's attachment of the gut after resection of the stomach. We make use of this same principle whenever an anterior gastro-enterostomy has to be performed, and the necessity of making an entero-anastomosis in this procedure is thus avoided.

In ulcers of the lesser curvature excision is advised by leading authorities. Rutherford Morison, however, among others had good results with gastro-enterostomy alone. End-result inquiry in our very small material yielded the following results: Of ulcers of the lesser curvature distinctly away from the pyloric area there were in our material ten cases. In two a resection of the stomach, including the pylorus, was performed; both report themselves as well (after 3½ and 2 years). Another case, after good operative recovery, could not be traced. One case, operated upon 1½ years ago, is greatly improved. The remaining six cases were entirely relieved by the operation.

In these cases the aim was to make the opening in the stomach away from the pyloric grinding mill, but still at the bottom of the stomach. Furthermore, we were anxious not only to make the outlet extra large, but to pull enough stomach through the mesocolon to have it pouch. If a rapid and free emptying is particularly desired, an elliptical excision of the edge of the gastric muscularis, not necessarily including the mucosa, may be of assistance.

GASTROPLICATION

Atony of the stomach with a sagging downward and a dilatation of this viscus is a condition which is found in patients who usually have suffered for a long time from stomach symptoms due principally to retention and from a reduced nutrition.

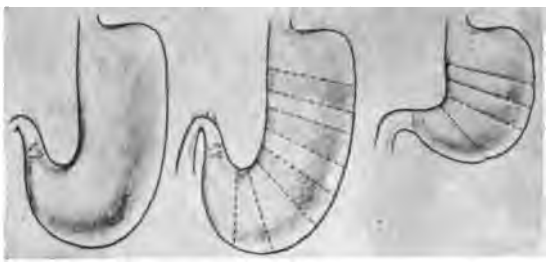

Fig. 3.

Time does not permit dwelling upon the different methods of treatment in these cases with their mostly unsatisfactory results. Suffice it to add that, though the surgeon withholds operating as long as he can, he may be driven by the severity of the symptoms and the prolonged misery of these patients to try operative relief. Bircher as the first one offered a reefing of the stomach which produces horizontal folds, through which the greater curvature is raised and its distance from the lesser reduced. Now on examination, these stomachs, for the most part, show that even the lesser curvature has greatly sagged down and the whole organ is like a long bag hung up only on the two ends, i.e., the cardiac and the pyloric area. On the pyloric side the attachment is not to the pylorus proper so much as to the first portion of the duodenum, where the fixation occurs by the gastroduodenal artery, the bile ducts and the extraperitoneal attachment to the pancreas. A kink in the uppermost portion of the duodenum is the consequence. The kink in its turn causes a more or less marked retention with a gradual dilatation as a further result.

Gastroplication as advised by Bircher creates longitudinal folds in the stomach. The whole organ assumes the shape of a long sausage. The sagging of the lesser curvature is not changed and the acute angle at the outlet is not improved. However, if the folds are made in a transverse direction, the stomach is very much shortened by them. The degree of shortening can indeed be chosen by the operator. He can make as many transverse folds as seems necessary. Through this the stomach is lifted toward the cardia, and the lesser curvature is shortened and stretched. The kink at the duodenum is effectively counteracted.

In general one is very reluctant to credit any operation of this type with much merit, and let me add that I myself am not enthusiastic about such methods. Nevertheless one is at times confronted with a case in which the ptosis is so severe that some corrective measure, perhaps in addition to a drainage operation, appears desirable. Even admitting that the stomach probably undoes our folding after a while, and conceding that improvement after these operations, when done in conjunction with a drainage operation, is principally to be attributed to the latter, our experience leads us to believe that there is some merit in the procedure. The posterior wall was left untouched in our cases. It could of course be reached to some extent through an opening in the gastrocolic ligament; but it seemed too much surgery in view of the moderate promise of such a surgical interference.

In the course of a study of the end-results of our stomach operations during the last fifteen years, we have found thirteen cases of severe dilatation and ptosis. In one we simply made a gastro-enterostomy and had a good result. In the remaining 12 cases we performed the transverse reefing of the stomach. However, on account of a distinct retention we added a gastro-enterostomy in six instances and a pyloroplasty twice. In four cases nothing but the reefing was done. The questionnaire yielded the following end-results:

Two only slightly, if any, improved after 2 and 4⅓ years.
Two improved after 3⅓ and 6½ years.
Four greatly improved after 5¾, 6½, 6¾ and 7⅓ years.
One practically well after 5½ years.
Three very well after 5½, 9⅓ and 14 years.
One not found (after good operative recovery).
The four cases with nothing but a gastroplication are:
One slightly improved after 4⅓ years.
One greatly improved after 6¾ years.
One very well after 9⅓ years.
One not found.

I simply give these data for what they are worth. The indications for such a procedure are surely very limited and rather rare, but as long as plication is still done now and then in cases of an extreme condition, it seemed permissible to bring this modification to your attention, because it corrects, or helps to correct, the kink at the outlet of the stomach.

A SUMMARY OF THE SURGICAL TREATMENT OF GOITER[1]

By MILES F. PORTER, M.D., F.A.C.S., Ft. Wayne, Indiana

GENERALLY speaking, surgical services are sought by goiter patients, because of (1) toxic symptoms, (2) pressure symptoms, (3) deformity, and (4) a combination of these difficulties.

When patients with symptomless goiters seek the services of the surgeon for fear their benign goiters may become troublesome, and not until then, will there be achieved all that is possible in the relief and cure of this disease.

I should like to repeat here what I have said in effect several times before,[2] namely, that the wisdom of removing simple goiters for fear of their becoming toxic is quite as evident as is the wisdom of removing warts, moles, scars, etc., for fear of their becoming malignant. Subtotal thyroidectomy is the operation of choice in all patients who are good surgical risks. "Safety first" is the slogan here as universally elsewhere and therefore the incision should be ample and located with a view to an adequate exposure of the gland. Whether or not the muscles should be divided on one or both sides depends upon the individual case. The rule should be to divide the muscles when necessary to secure adequate exposure of the operative field. When divided, the section should be made as near the upper attachment as possible. It is preferable to grasp all the tissues, including the superficial fascia and muscles on the side or sides to be divided with two forceps and make the incision between. Properly placed sutures will coapt all structures divided and effectually prevent hæmorrhage.

For circumscribed hypertrophy, cysts or adenomata, the incision may with safety be made relatively small, provided it be properly located. There is no orthodox incision for goiter.

In cases of general hypertrophy wherein subtotal removal is contemplated, a full exposure of the gland should be secured not only for the sake of safety, but for the further purpose of enabling one to judge more accurately of the characters presented by the different parts of the gland. In a previous paper[3] I called attention to the fact that the hyperactive portions of the gland could usually be distinguished from the normal or inactive portions. It is generally believed, I think, that the hyperactive gland structure is usually red, rather firm, and somewhat resembles beef steak. On the contrary, it has been my observation in quite a number of cases, that the hyperactive, trouble-producing portion of the gland, as indicated by the microscopic picture present, is often, if not usually lighter in color and softer than the normal gland structure. Further observations made since those upon which the statements made in the paper above referred to were based, confirm the conclusions reached therein.

With the style of dress commonly worn by women today, it is quite impossible to locate the incision so that the scar will be covered. It follows, therefore, that the scar should be as inconspicuous as possible. To achieve this end, the incision should be made to follow the natural folds of the skin, the skin should be cut through at right angles to the surface, and the skin wound should be closed with subcuticular sutures with the aid of adhesive plaster, if necessary, to perfect the coaptation. A stitch scar in a place where it attracts attention is a surgical sin. No other method of wound closure with which I am acquainted gives as good medical results as the one here recommended.

Lobectomy is frequently an unsatisfactory operation in that it leaves the neck asymmetrical and often fails to give adequate relief.

The portions of the gland structures to be left after thyroidectomy should be selected, in so far as is possible, with a view of avoiding future asymmetry. One should leave not any more gland structure than would amount to one-fifth the normal — the aim should be to leave normal gland tissue. Non-functionating gland tissue is useless, and hyperplastic tissue, if left, will keep up the symptoms of intoxication for a longer or shorter time, and sooner or later degenerate and become useless. That it will not always be possible to select normal tissue to leave, I am of course well aware, but I am convinced that efforts made along this line are well worth while.

It is perhaps better always to divide the isthmus completely when it can be done without additional risk. This procedure is advised with a view to the relief or prevention of the pressure symptoms. Preservation of the posterior capsule will effectually protect the parathyroids and recurrent laryngeal nerves. Drainage adds both to the safety and comfort of the patient and it is, therefore, seldom wise to omit it. Strips of rubber dam make the

[2] Detroit M. J., 1915, March.

[3] Ann. of Surg., Phila., 1916, October.

[1] Read before the Southern Surgical Association, Baltimore, December, 1918.

best drainage material. Drains should be removed as soon as the discharge becomes negligible, usually at the end of 48 or 72 hours after the operation.

Adhesion of the skin to the larynx or trachea is not an infrequent cause of annoyance. This can be avoided by securing the interposition of a layer of cellular tissue between these structures.

Generally speaking, ether anæsthesia is the safest and most satisfactory. To this rule there are of course exceptions, but they are rare. It is generally conceded that when a patient dies from appendicitis it is almost always because someone has blundered. The sooner it is generally conceded that it is a grievous error for a goiter patient to put off consulting the surgeon until the time for safe surgery is past, the sooner will the number of goiter deaths be decreased. In the present state of our knowledge concerning goiter there is no excuse for any but a very small proportion of goiter patients first seeking surgical relief after the time for safe surgery is past.

For the preparation of the sub-standard risks for the major operation, injections of boiling water into the gland substance is more effectual than any other known procedure. In a large percentage of patients with small goiter of the diffuse hyperplastic variety, injections of boiling water should be the treatment of choice in that it is efficacious and entails less risk and less loss of time than any other method of treatment equally efficient. This method of treating goiter has already been published.[1] It is now in quite general use and a detailed presentation of the subject is unnecessary.

In closing I should like to urge the especial importance of foci of infection in goiter patients. Not infrequently the removal of these foci will cause the goiter symptoms to disappear. To allow such foci to remain after thyroidectomy is to invite a recrudescence of the goiter symptoms. Besides it should be remembered that thyroidectomized patients are especially vulnerable.

[1] Surg., Gynec. & Obst., 1915, xx, 15.

BOOKS RECEIVED

Books received are acknowledged in this department, and such acknowledgment must be regarded as a sufficient return for the courtesy of the sender. Selections will be made for review in the interests of our readers and as space permits.

QUARTERLY MEDICAL CLINICS. A series of consecutive clinical demonstrations and lectures. By Frank Smithies, M.D., at St. Augustana Hospital, Chicago. St. Louis: Medicine and Surgery Publishing Company, Inc., vol. i, No. 1, 1919.

INFECCIONES DE TIPO GRIPAL. By Antonio Piga and Luis Lamas. Madrid. vol. 1, 1919.

SURGERY OF THE THORAX AND VISCERA; Symptoms, Diagnosis, Indications and Treatment. By Benjamin Merrill Ricketts, Ph.B., M.D., LL.D., F.A.C.S. Cincinnati, 1918.

NOTES ON PATHOLOGICAL AND OPERATIVE OBSTETRICS. By Lyle G. McNeile, M.D. Los Angeles: Division of Obstetrics, College of Physicians and Surgeons, Medical Department of the University of Southern California, 1919.

ANNUAL SUBSCRIPTION: UNITED STATES AND CANADA, $10.00; FOREIGN, $12.00 (£2 10s.)

Volume XXVIII MAY, 1919 Number 5

Surgery, Gynecology and Obstetrics

WITH

International Abstract of Surgery

EDITORIAL STAFF

FOR AMERICA

William J. Mayo, M.D.

E. Wyllys Andrews, M.D. J. Clarence Webster, M.D.

L. L. McArthur, M.D. E. C. Dudley, M.D. Frederic A. Besley, M.D.

A. J. Ochsner, M.D. C. S. Bacon, M.D. Carl Beck, M.D.

Thomas J. Watkins, M.D. John L. Porter, M.D. William R. Cubbins, M.D.

FOR THE BRITISH EMPIRE

Sir Arthur Mayo-Robson, C.B., C.V.O., D.Sc., F.R.C.S.

Sir Berkeley Moynihan, C.B., M.S., F.R.C.S. Thomas W. Eden, M.D., F.R.C.S.

Sir Harold J. Stiles, M.B., F.R.C.S. (Edin.) Henry Jellett, M.D., F.R.C.P.I.

James Rutherford Morison, M.B., F.R.C.S.

Franklin H. Martin, M.D., Managing Editor

Allen B. Kanavel, M.D., Associate Editor

EDITORIAL AND BUSINESS OFFICES: 30 N. Michigan Ave., Chicago, Illinois, U. S. A.

PUBLISHERS FOR GREAT BRITAIN: Bailliere, Tindall & Cox, 8 Henrietta St., Covent Garden, London, W. C., England

A Great Surgery

Read what the Medical Press says

SAUNDERS, *Publishers* SEE PAGE 13

Entered as second-class matter May 22, 1913, at the postoffice at Chicago, Ill., under the Act of Congress, March 3, 1897.

Published monthly. Copyright, 1919, by The Surgical Publishing Company of Chicago.



USE
Paragon X-Ray Plates

They are FAST, CLEAN, BRILLIANT

And if you want to see the finest results your apparatus will produce

TRY THEM

THEY MAKE GOOD, as proven by the constant increase in repeat orders received.

IF YOU are not using them, some one else may make the diagnosis you failed on by not taking every opportunity to improve the standard of your work.

Hundreds are building reputations by their use. *Why Not Join Them?* We will help you with technical advice if needed.

If your dealer has no *fresh* Paragon plates in stock, write us, for quick shipment.

We Also Supply

Lower Priced X-Ray Plates
Barium Sulphate for Stomach Work
Dental X-Ray Films and Mounts
Developing Tanks—Soapstone or porcelain enameled, 1, 4 or 6 compartments
Developer Chemicals
Intensifying Screens
Filing Envelopes
Radiator or Regular Coolidge Tubes
X-Ray Protective Materials

Complete Price List and Discount Sheet on request. YOUR NAME should be on our mailing list for monthly X-Ray Bulletin.

PARAGON X-RAY PLATES

Geo. W. Brady & Co. 756 S. Western Avenue **Chicago**

SAVE TWO-THIRDS

Sherman's Bacterial Vaccines, when administered early, will reduce the average course of acute infections like Pneumonia, Broncho-pneumonia, Sepsis, Erysipelas, Mastoiditis, Rheumatic Fever, Colds, Bronchitis, etc., **to less than one-third their usual mortality and duration.**

Sherman's Bacterial Vaccines are prepared in our specially constructed Laboratories, devoted exclusively to the manufacture of these preparations and are marketed in standardized suspensions.

Write for literature.

MANUFACTURER OF BACTERIAL VACCINES

G. H. SHERMAN M.D.

Detroit, Mich. U.S.A.

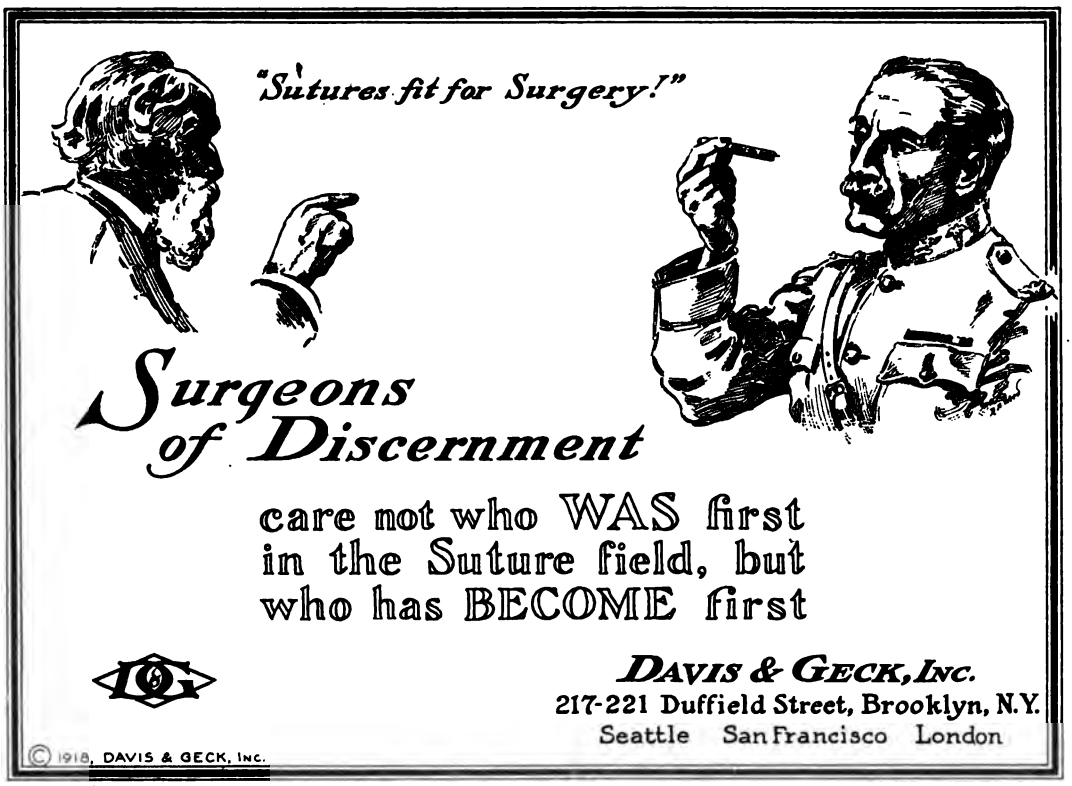
"Sutures fit for Surgery!"
Surgeons of Discernment
care not who WAS first in the Suture field, but who has BECOME first
DAVIS & GECK, INC.
217-221 Duffield Street, Brooklyn, N.Y.
Seattle San Francisco London
© 1918, DAVIS & GECK, INC.

CONTENTS—MAY, 1919

ORIGINAL ARTICLES

1. PANCREATIC LYMPHANGITIS WITH AND WITHOUT JAUNDICE. *John B. Deaver, M.D., F.A.C.S., Philadelphia* 433

2. PRACTICAL CONSIDERATIONS WITH REGARD TO PERMANENT COLOSTOMIES. *W. E. Sistrunk, M.D., F.A.C.S., Rochester, Minnesota* 436

3. THE TREATMENT OF HODGKIN'S DISEASE. *Curtis F. Burnam, M.D., F.A.C.S., Baltimore* .. 440

4. ECTOPIC OR PELVIC KIDNEY. *E. S. Judd, M.D., F.A.C.S., and S. W. Harrington, M.D., Rochester, Minnesota* 446

5. THE TREATMENT OF THE UNDESCENDED OR MAL-DESCENDED TESTIS WITH PARTICULAR REFERENCE TO END-RESULTS; REPORT OF 415 CASES. *William B. Coley, M.D., F.A.C.S., New York* 452

6. PROSTATECTOMY, WITH ITS PREPARATORY AND POSTOPERATIVE TREATMENT. *Bransford Lewis, M.D., B.Sc., F.A.C.S., St. Louis* 459

7. POLYPOSIS OF THE STOMACH. *D. C. Balfour, M.D., F.A.C.S., Rochester, Minnesota* 465

8. THE RÔLE OF THE CYSTIC DUCT IN RECURRING CHOLECYSTITIS. *J. Earl Else, M.S., M.D., F.A.C.S., Portland, Oregon* 467

CONTENTS CONTINUED OPPOSITE NEXT PAGE

EMPYEMA TROCAR

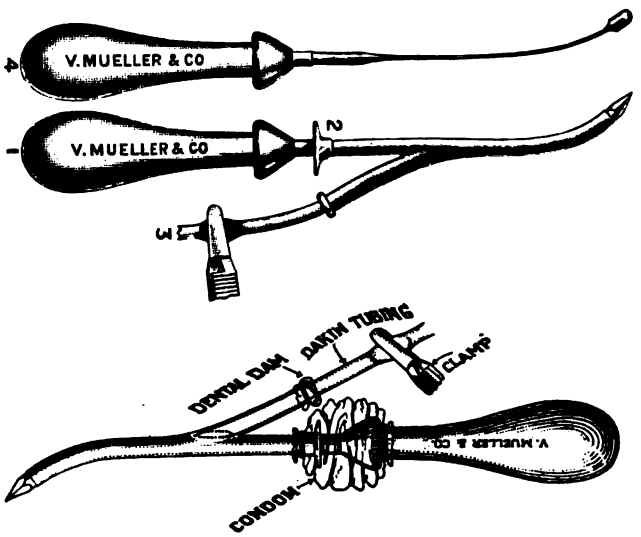

Devised by

VICTOR P. DIEDERICH
Lieut. M. C., U. S. A.

and employed in

Trocar Thoracotomy

At the Base Hospital, Camp Pike, Ark., and other army hospitals.

This important instrument has been developed by us in accordance with Dr. Diederich's instructions.

Supplied complete with accessories and directions by

V. MUELLER & CO., 1771-1783 Ogden Ave., Chicago

Economy of Gas Control of Flow
Simplicity of Operation

Use S. S. White Nitrous Oxid and Oxygen. Always reliable. For sale by dealers in surgical or dental supplies.

You should know more about these features of S. S. White Nitrous-Oxid-Oxygen equipment (with ether attachment) for surgical anesthesia.

—

Fully described in Catalog R—mailed free upon request.

The S. S. White Dental Manufacturing Company

"Since 1844 the Standard"

PHILADELPHIA

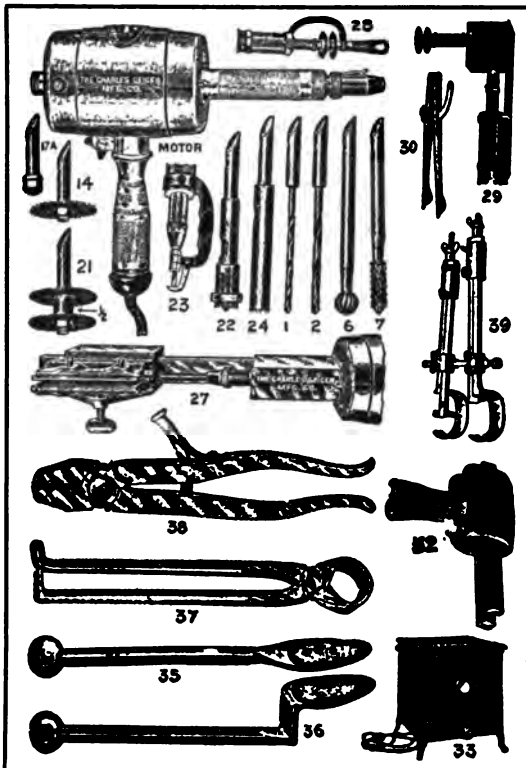

Dr. Charles Geiger's

Electro-Operative Surgical Bone Instruments and Accessories

These instruments are made especially for transplanting bone, dowel making and cranial work. **Water is not required** to keep the cutters from burning the bone when using these instruments, **because of their slow speed.**

A few of the many advantages not found in any other motor bone instruments are: Slow speed, sterilization of motor, its great power, simplicity of chuck, and firmness with which it can be held. Sterilizable shell is included in the set.

Write F. A. Davis Pub. Co., Philadelphia, Pa., for Dr. Charles Geiger's book on **"MODERN OPERATIVE BONE SURGERY."**

The Charles Geiger Mfg. Co.

St. Joseph, Missouri, U. S. A.

CONTENTS—MAY, 1919—CONTINUED

ORIGINAL ARTICLES — CONTINUED

9. NOTES ON TWO SIGNS IN CHRONIC APPENDICITIS. *Robert T. Morris, M.D., F.A.C.S., New York* 472

10. CONGENITAL DIVERTICULA OF THE INTESTINES; REPORT OF A CASE OF A TUMOR GROWING FROM THE TIP OF AN APPARENTLY CONGENITAL DIVERTICULUM IN THE LOWER SIGMOID REGION. *William T. Black, M.D., F.A.C.S., Memphis, Tennessee* 473

11. WAR AMPUTATIONS. *Captain Philip D. Wilson, M.C., U.S.A* 478

12. SYPHILITIC INDURATION OF THE VULVA; WITH REPORT OF FOUR CASES. *J. F. Gallagher, M.D., F.A.C.S., Nashville, Tennessee* 482

13. NEW-GROWTHS OF THE TESTIS; THEIR SYMPTOMATOLOGY, PATHOLOGY, DIAGNOSIS, AND TREATMENT. *C. R. O'Crowley, M.D., F.A.C.S., and Harrison S. Martland, M.D., Newark, New Jersey* 486

14. THE RADICAL OPERATION FOR TERATOMA TESTIS; WITH THE REPORT OF FIVE CASES. *Frank Hinman, M.D., F.A.C.S., San Francisco, California* 495

15. SPLENECTOMY IN DISEASES OF THE SPLEEN; REPORTING FOUR OPERATIVE RECOVERIES. *E. M. Prince, M.D., Birmingham, Alabama* 509

CONTENTS CONTINUED OPPOSITE NEXT PAGE

Success in Treating Infections

Light rays are now recognized to be the most effective means for producing the active hyperemia essential to increased leukocytosis for relief of infections and pain.

Treating a Bullet Wound

Ask for free copy of the reprint by A. J. Ochsner, M.D., LL.D., F.A.C.S., Chicago, entitled "Practical Value of Electric Light in the Treatment of Infections."

Radio-Vitant Applicators

Are extensively used in both the surgeon's office and hospital.

Specially adapted for use in the patient's home under supervision of the surgeon.

Standardized in the Surgeon-General's Office for use in the Military Reconstruction Hospitals.

Proven by practical experience to be far superior to vibrators, high frequency currents, "high candle-power lamps," etc., for local applications in the relief of pain and inflammation.

Type L4 Applicator $27.50

Our guarantee, entire satisfaction or money back

BURDICK CABINET COMPANY

614 Venetian Bldg. Chicago, Ill.

201 Madison Ave. Milton, Wis.

CONNELL GAS OXYGEN APPARATUS IS DIFFERENTLY BETTER

The Connell machine can be easily remembered as the only machine applying the accuracy of metric dosage to the administration of gas and oxygen.

It has its meter right before the operator's eyes. It shows at a glance just how much gas and oxygen are being delivered, contributing to the economy of gases and the comfort and safety of the patient.

It is the only machine employing the drop method of ether administration. The ether dropper and sight feed are located between the meters and before the operator's eyes.

Double set of tanks in either the smallest or largest size. Control valves are supplied for each tank. It has an ether coil vaporizor which is highly efficient and is equipped with an absolutely safe lamp.

There are other points which are fully set forth in our carefully prepared book on anæsthesia. We have a copy ready for mailing to you. *May we have your name and address?*

SCIENTIFIC APPARATUS CO.

162 WEST 34th STREET NEW YORK

Your Pharmacist Knows

Send for beautifully illustrated catalog, in four colors, showing the complete line of Lilly Aseptic Metal Pocket Cases

YOUR pharmacist knows the care required to make a snow-white hypodermatic tablet of even texture, accurate grainage and dependable solubility.

Hand moulding hypodermatic tablets is more than a matter of routine; it is a definite responsibility. A hypodermatic injection is often an emergency measure; the physician relies upon it to produce results—quickly.

Ask your pharmacist for something more than a tube of hypodermatic tablets—specify Lilly's.

Drop One In Water; Watch It Disappear

ELI LILLY & COMPANY, Indianapolis, U. S. A.

NEW YORK CHICAGO ST. LOUIS KANSAS CITY NEW ORLEANS

CONTENTS—MAY, 1919—CONTINUED

DEPARTMENT OF TECHNIQUE

16. GYNECOLOGICAL PELVIC DRAINAGE; INDICATIONS, METHODS, AND MATERIALS. *J. Wesley Bovée, M.D., F.A.C.S., Washington* 514

17. RECONSTRUCTION OF THE UTERUS. *Charles B. Robins, M.D., F.A.C.S., Richmond, Virginia* 516

18. THE USE OF CONTINUED EXTENSION BY MEANS OF A NEW EXTENSION FRAME IN THE BLOODLESS REDUCTION OF CONGENITAL DISLOCATION OF THE HIP. *John W. Churchman, M.D., F.A.C.S., New Haven* 518

19. A GAUZE SPONGE SPONTANEOUSLY EXPELLED FROM THE URINARY BLADDER. *G. Paul La Roque, M.D., F.A.C.S., Richmond, Virginia* 522

TRANSACTIONS OF SOCIETIES

CHICAGO SURGICAL SOCIETY

PAPILLOMA OF THE LARGE BOWEL. *Jacob Frank, M.D.* 524

HERNIA. *Jacob Frank, M.D.* 524

STONE IN THE BLADDER. *Jacob Frank, M.D.* 524

OSTEOMYELITIS OF THE CLAVICLE. *Carl B. Davis, M.D.* 525

ARTERIOVENOUS ANEURISM AFFECTNG THE BRACHIAL PLEXUS. *Lawrence Ryan, M.D.* 526

CORRESPONDENCE

ACCIDENTS FROM LOCAL ANÆSTHESIA. *Dr. J. Schoemaker* 528



Graduated Low Tone Tuning Forks

Devised by DR. W. G. REEDER

Important Announcement

WE are now able to deliver the first graduated low tone tuning forks manufactured in America. These forks are graduated in four tone intervals from 16 to 64 double vibrations per second. They are free from overtones and guaranteed to be perfect. Otologists who have been unable to obtain such a set of instruments at any figure since the war, are now offered a superior product at a nominal price. These forks are indispensable in accurate functional testing of the ear, especially in cases of incipient conduction deafness and those in which the lower tone limit is disturbed.

No. 1 Reeder's Tuning Fork, 16 to 20 double vibrations, is 23½ inches long and weighs 7½ lbs. . . . . Price $35.00

No. 2 Reeder's Tuning Fork, 24 to 28 double vibrations, is 19½ inches long and weighs 7 lbs. . . . . Price $35.00

No. 3 Reeder's Tuning Fork, 32 to 44 double vibrations, is 17 inches long and weighs 7 lbs. . . . . Price $32.50

No. 4 Reeder's Tuning Fork, 48 to 64 double vibrations, is 14 inches long and weighs 6 lbs. . . . . Price $32.50

SHARP & SMITH

Manufacturers and Exporters of High Grade Surgical Instruments and Hospital Supplies

65 E. LAKE ST. Between Wabash Ave. and Mich. Blvd. CHICAGO, ILL.

Established 1844 Incorporated 1904

THE

RADIUM INSTITUTE

1604 Mallers Bldg., 59 E. Madison St.

Cor. Wabash Ave., Telephone Randolph 5794

C H I C A G O

DR. FRANK E. SIMPSON

COUNCIL

DR. F. A. BESLEY — DR. E. C. DUDLEY
DR. A. R. EDWARDS — DR. O. T. FREER
DR. M. HERZOG — DR. L. E. SCHMIDT
DR. G. F. SUKER

TREATMENT of Malignant and Benign Growths with Radium; Postoperative Prophylactic Radiations following the Surgical Treatment of Cancer.

Radium is indicated in inoperable malignant conditions. By its use an inoperable case may become operable.

We desire to confer and co-operate with surgeons, assuring them adequate amounts of Radium to meet the requirements of patients referred to us.

Sterilize Your Dressings in Half the Usual Time with the National High Pressure Sterilizer

Minutes are often of vital importance and in all such cases the time saved with the National is of inestimable value. Sterilizes perfectly. No auxiliary apparatus required for drying—dressings are absolutely dry and ready for use the minute removed.

More than 4,000 National Sterilizers now in use in hospitals, laboratories, private offices and in U. S. Army and Red Cross hospitals. Simple, safe, easy to use. Two styles, three sizes—

Doctor's $60, Medium $85, Hospital $145



Equipped with gas or gasoline burner or steam coil as required. Sold by the best supply houses everywhere under our guarantee of absolute satisfaction to the user. If your dealer hasn't the size you require, write direct to

NORTHWESTERN STEEL & IRON WORKS
884 Spring Street
EAU CLAIRE, WIS.

INDEX TO ADVERTISING

Surgical Instruments and Apparatus

American Precision Works..... 14
Bauer & Black..... 36
Bard-Parker Co..... 14
Burdick Cabinet Co..... 4
Electro Surgical Instrument Co... 16
Feick Brothers Co..... 14
Charles Geiger Mfg. Co..... 3
Goodwill Electric Co..... 16
Kny-Scheerer Corporation..... 10
McIntosh Battery & Optical Co.. 16
V. Mueller & Co..... 2
Northwestern Steel & Iron Works 7
Harvey R. Pierce Co..... 12
John D. Pollard, M.D..... 14
Sharp & Smith..... 6
Haynes Stellite Co..... 27
Taylor Instrument Companies.... 15
Truax, Inc..... 33
Victor Electric Co..... 28
Wappler Electric Co..... 32

Hospital Supplies

Bauer & Black..... 36
Bramhall, Deane Co..... 15
Burdick Cabinet Co..... 4
General Laboratories..... 15
Good Mfg. Co..... 36
Kny-Scheerer Corporation..... 10
V. Mueller & Co..... 2
Northwestern Steel & Iron Works 7
Harvey R. Pierce Co..... 12

Post-Graduate Instruction

Laboratory of Surgical Technique 38
New York Post-Graduate Medical School and Hospital..... 40

X-Ray Apparatus, Tubes, Plates, Etc.

American Photo Chemical Co.... 30
Geo. W. Brady & Co.....2nd cover
Campbell Electric Co..... 34
Eastman Kodak Co..... 29
General Electric Co..... 31
Wm. Meyer Co..... 32
Victor Electric Co..... 28
Wappler Electric Co..... 32

Catgut—Ligatures

Armour & Co.....4th Cover
Davis & Geck, Inc..... 1
Hollister-Wilson Laboratories.... 11
Johnson & Johnson..... 25
C. DeWitt Lukens Co..... 24

Anæsthesia Apparatus

Foregger Co..... 15
Safety Anæsthesia Apparatus Concern..... 36
Scientific Apparatus Co..... 4
S. S. White Dental Mfg. Co..... 2

Corsets, Bands, Etc.

Earnshaw Knitting Co..... 16
Katherine L. Storm..... 37

Rubber Goods, Gloves, Etc.

E-Z Patch Co..... 33

Foods

Quaker Oats Co..... 33

Medical Books

Bailliere, Tindall & Cox..... 17
P. Blakiston's Son & Co..... 17
Lea & Febiger..... 23
J. B. Lippincott Co..... 22
C. V. Mosby Co..... 21
Oxford University Press..... 20
Quarterly Medical Clinics..... 17
Rebman Company..... 19
W. B. Saunders Co.....Cover and 13
Wm. Wood & Co.....17 and 18
John Wright & Sons, Ltd..... 18
Year Book Publishers..... 18

Pharmaceuticals

Abbott Laboratories..... 8
Armour & Co.....4th Cover
Cutter Laboratory.....3rd Cover
General Laboratories..... 15
Hynson, Westcott & Dunning 4th Cover
Eli Lilly & Co..... 5
H. A. Metz Laboratories, Inc.... 35
Sharp & Dohme..... 34
Dr. G. H. Sherman.....2nd Cover
Standard Oil Co..... 39

Radium

Physicians' Radium Association.. 25
Radium Chemical Co..... 9
Radium Company of Colorado... 26
Radium Institute..... 6

Miscellaneous

Battle Creek Sanitarium..... 38
Gradwohl Biological Laboratories. 18
Medical Protective Co..... 18

CHLORAZENE

Dakin's Universal Antiseptic

Helped To Win The War



Every Doctor in America Should Know

that Chlorazene (Abbott), Doctor Dakin's wonderful war antiseptic is FIFTY TIMES more powerful in its germicidal action than Carbolic Acid and at least a thousand times more powerful than Dobell's Solution or Liquor Antisepticus.

You should know, too, that Chlorazene is Non-Poisonous, Safe, Stable and Non-Irritating

Chlorazene is successfully used as a gargle, as a douche, for wounds, in surgery, in gum infections, ocular inflammations and genito-urinary practice.

ORDER NOW THROUGH YOUR DRUGGIST OR DIRECT FROM OUR HOME OFFICE OR BRANCHES

Chlorazene Tablets 4.6 grs. each, bottles of 100, 500 and 1,000. Chlorazene Powder, Hospital package No. 1 makes 1 gallon 1% solution. Hospital package No. 2 makes 5 gallons 1% solution.

CHLORAZENE SURGICAL CREAM IN 3½ OUNCE JAR

Send for literature and prices on Chlorazene, Dichloramine-T, Chlorcosane, Barbital (Veronal) and Procaine (Novocaine) and other American-made drugs. *Specify Abbott's to insure purity.*

THE ABBOTT LABORATORIES HOME OFFICE AND LABORATORIES **DEPT. 82, CHICAGO, ILL.**

All American. Always American. Headquarters for the Dakin Products.

New York Seattle San Francisco Los Angeles Toronto Bombay

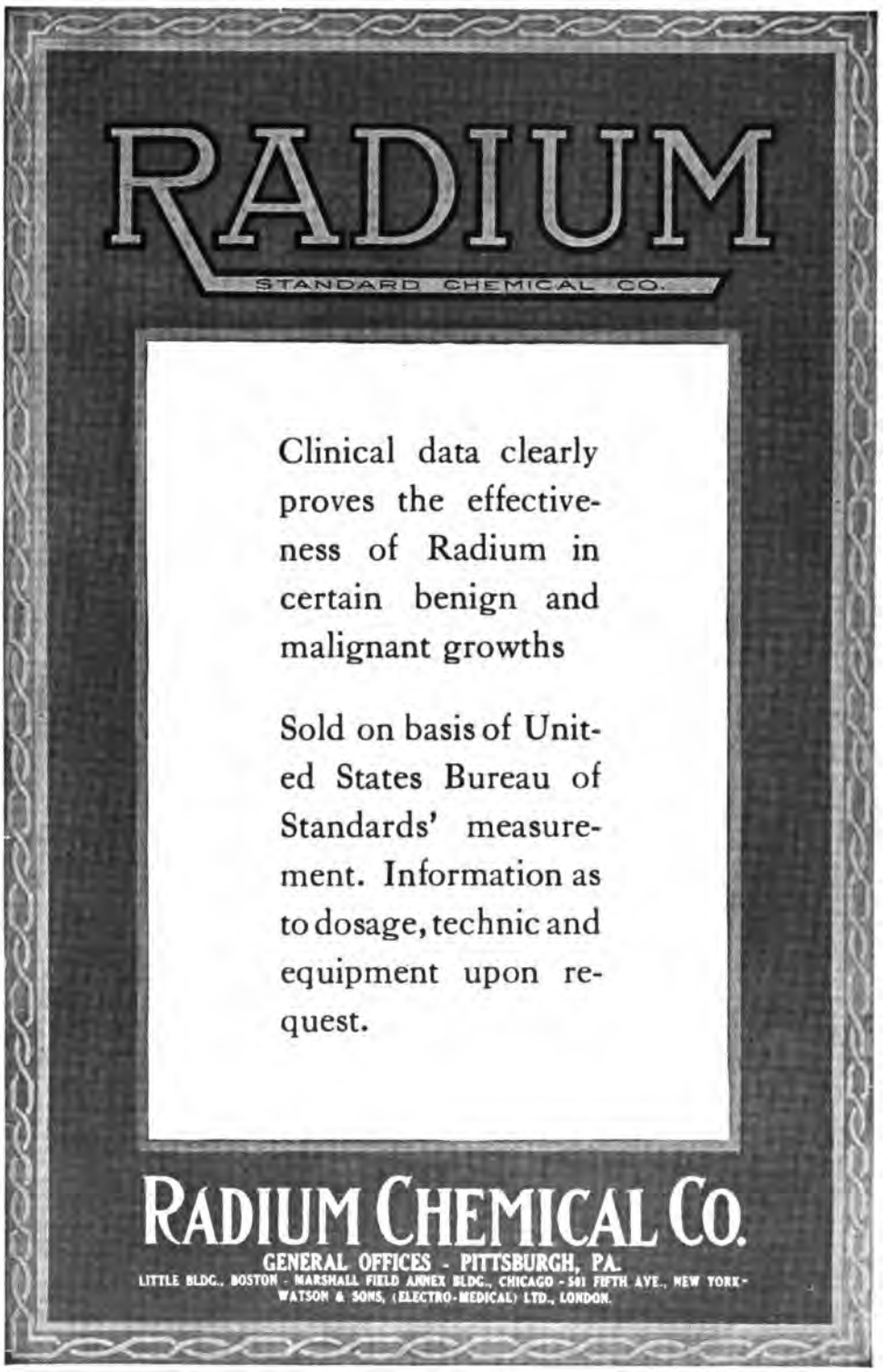
RADIUM
STANDARD CHEMICAL CO.
Clinical data clearly proves the effectiveness of Radium in certain benign and malignant growths
Sold on basis of United States Bureau of Standards' measurement. Information as to dosage, technic and equipment upon request.
RADIUM CHEMICAL CO.
GENERAL OFFICES - PITTSBURGH, PA.
LITTLE BLDG., BOSTON - MARSHALL FIELD ANNEX BLDG., CHICAGO - 581 FIFTH AVE., NEW YORK -
WATSON & SONS, (ELECTRO-MEDICAL) LTD., LONDON.

Medico-Mechanical Treatment in Cases of Motor Disturbances and Muscular Debility



There is no remedy which, in cases of accidents and affections of the joints and muscles, will restore the regular use of the limbs more quickly than early Medico-Mechanical treatment.

It is obvious that active exercise of the entire musculature will essentially change the conditions of the circulation, hence necessarily also act favorably upon a part in which an obstruction to the circulation is manifest (engorgement, œdema, change of tension due to pressure, with all its consequences).

This apparatus for the lower extremities is used for: Bending of the Knees, Extension of the Knees, Bending of the Foot, Extension of the Foot, Rotation of the Leg in the Hip Joint.

Send for Our Booklet on Combination Apparatus

The Kny-Scheerer Corporation

404-410 West 27th Street - - - - - NEW YORK, U. S. A.

Bacteriologic Control of Manufacturing Process

WHEN you consider the normal bacterial flora of the intestinal tract, and the immediate and disastrous effects of putrefaction upon the integrity of catgut, the necessity for skillful and scientific bacteriologic control is apparent.

The Hollister - Wilson Laboratories had its inception in the conviction of Mr. B. K. Hollister that proper manufacturing methods demanded oversight and control of the raw material. In making an alliance with Wilson & Co., Packers, to whom The Hollister - Wilson Laboratories are subsidiary, the necessary co-operation has been secured to insure that the material used in ligature and suture manufacture will be handled in a way to make certain of complete protection of the product from contamination.

The Hollister-Wilson line of ligatures has these manifest advantages:

1.—An unlimited supply of selected raw material.

2.—Rigid bacteriologic control from "Abattoir to tube."

3.—Assurance of tensile strength by the limitation of bacterial action (only possible where the supervision of raw material can be successfully applied).

4.—Perfect sterilization.

There is a definite relationship between properly made ligatures and your surgical reputation.

Our complete illustrated catalog sent upon request

Hollister Ligatures may be obtained wherever Surgical Supplies are sold

HOLLISTER-WILSON LABORATORIES

4444-46-48 South Ashland Ave. **Chicago, Illinois**

"TUBES OF DISTINCTION"

Pratt-Lowman
Self-Retaining Retractor

for use in the open method of repairing fractures especially in connection with the Albee Motor Saw method.

Devised by Major John B. Lowman, M.C., and Captain R. B. Pratt, M.C., U. S. Base Hospital No. 38.

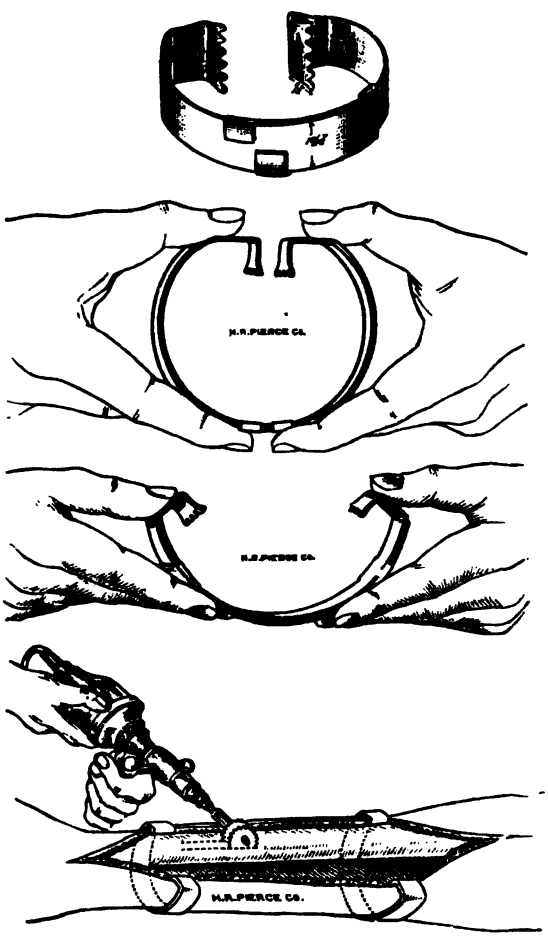

It affords the following advantages:

SIMPLICITY

No parts to be lost. Easy to clean, sterilize, manipulate.

DURABILITY

It not only gives **RETRACTION** of tissues, but also **DEPRESSION** of them with an uncomplicated automatic lock in any degree of retraction. Pressure upon its lower surface by the weight of the limb forcing it against the operating table only serves to increase retraction and locking.

It does away with retraction by assistants and with this the danger of extra hands in the operative field and leaves the operator unhindered in the use of the electric saw and drill.

It leaves the bone in a higher plane than the surrounding tissues and so obviates the danger of the saw, drill or spinning shaft engaging with the soft tissues or toweling.

In conjunction with an orthopedic table, assistants can be dispensed with during that stage of the operation in which the saw or drill is in use.

It is a useful addition in a teaching clinic in that it renders the field of operation more visible to spectators.

Made in two sizes; larger size for femur; smaller size for tibia and humerus. Used in pairs. Either size per pair, $8.00.

Manufactured by

HARVEY R. PIERCE COMPANY

1801 Chestnut Street *The Modern Surgical Instrument Store* **PHILADELPHIA**

PITTSBURGH SALES OFFICE: 3030, 3031, 3032, 3033 JENKINS ARCADE

Medical Press Endorses Warbasse's Surgical Treatment

Journal Missouri State Medical Association

"*Some one had to do it.* At last we have a really comprehensive treatise written by one man who combines good surgical judgment with clear, modest, attractive literary style. The text is amplified by twenty-four hundred cuts—clear and instructive. This work is the most noteworthy general treatise on surgery since Gross and Agnew."

New York State Journal of Medicine

"The author's style is clear, his descriptions are exact and brief, his judgments are to be relied upon, and disclose the results of a naturally critical, judicial temperament brought to bear upon surgical problems."

Journal Iowa State Medical Society

"Dr. Warbasse is well known to the medical profession as an active contributor to medical literature, particularly in the field of surgery. With an abundance of material at hand, he now presents to the profession a treatise on the science and practice of surgery."

Annals of Surgery

"Dr. Warbasse has laid us all under obligations by bringing out a work so full and elaborate, in which he has indicated his judgment as to the value of the infinite number of surgical procedures which the last thirty years has crowded upon the attention of the surgical world. The 2400 illustrations are of the kind which *really illustrate.*"

Journal Indiana State Medical Association

"The whole work is founded on the conception of contributing something that will add to the highest ideals of surgery. The book is well written, and is as concise as consistent with comprehensiveness and clearness."

Northwest Medicine

"This work is a classic and should be in the possession of every practitioner. It is not only valuable as a guide to the operating surgeon, but stands out as a signpost, pointing the way to the general practitioner or the internist. The elaborate profusion of illustrations of an eminently practical nature often speak volumes in themselves."

Three octavos, totaling 2687 pages with 2400 original illustrations *and separate desk index volume.* By JAMES PETER WARBASSE, M.D., Surgeon to the Wyckoff Heights Hospital, Brooklyn, N. Y. Per set: Cloth, $30.00 net.

SIGN AND MAIL THIS ORDER FORM TODAY

W. B. SAUNDERS COMPANY, West Washington Sq., Phila.

Please send me Warbasse's Surgical Treatment (three volumes and a separate desk index volume) and charge the $30.00 to my account.

Name_____ City_____

Street_____ State_____

A Sharp Knife for the Surgeon

Patented



Blade No. 20 Handle No. 4



Blade No. 21

The **Bard-Parker Knife** is distinctive on account of its superior sharpness, convenience and economy.

A handle and 12 blades (6 of each size), as illustrated, $2.50.

Ask Your Dealer

BARD-PARKER CO., Inc., 37 E. 28th St., New York

Pollard High Tension Stethoscope

A 'scope with which you can hear the heart sounds through an overcoat, coat and vest, and with which you can easily hear the fetal heart sound. The regulation binaurals are used on this stethoscope.

Try it a week; if not satisfied return and your money will be cheerfully refunded.

Price, postpaid in the U. S., $6.00

John D. Pollard, M.D.

2755 Jackson Blvd. CHICAGO, ILL.

The Surgeon

is generally called upon for advice as to

Artificial Limbs

Why not recommend one that is sure to be SATISFACTORY?

Our Latest Model

with Adjustable Leather Socket, Cordless Ankle, Felt or Sponge Rubber Foot, Ball-bearing Joints

assure the patient of comfort and perfect locomotion.

Our GUARANTEE Covers All Repairs

Write for Catalogue

FEICK BROS. COMPANY

809 Liberty Ave. Pittsburgh, Pa.

"AMERICAN PRECISION"

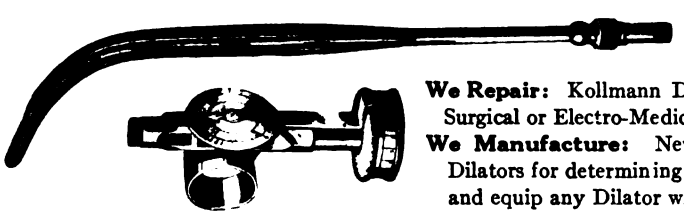

We Are

Dilator Specialists

We Repair: Kollmann Dilators of any make, and other Surgical or Electro-Medical Apparatus and Devices.

We Manufacture: New Safety-Pressure Gauges for Dilators for determining the amount of pressure applied, and equip any Dilator with same.

We manufacture DILATORS for the largest surgical supply houses

AMERICAN PRECISION WORKS, 135 Cedar Street, NEW YORK CITY

Meets in Full Measure the Exacting Demands of the Practitioner

SELF-VERIFYING



Tycos

Through the entire complex process in its manufacture, our years of experience is reflected.

$25.00

Complete with pocket carrying case and sterilizable sleeve, at your surgical instrument dealers.

A postal brings booklet on blood pressure tests which is authoritative

Tycos Fever Thermometers

Tycos Urinary Glassware

Taylor Instrument Companies

ROCHESTER, N. Y. 30

HYCLORITE

HYCLORITE

Reducing Temperature and Pulse

Surgeons recognize the great value of Hyclorite in reducing temperature and pulse to normal in cases of infected tissue wounds and fractures. Hyclorite cleans the wound through solvent action and prevents toxemia through its oxidizing action on toxins as formed.

This action of Hyclorite has been demonstrated successfully in a large number of injury cases in industrial hospitals.

Hyclorite is always ready for immediate use.

Just add water and apply.

Hyclorite is prepared to a definite hypochlorite strength and alkalinity.

Solutions made from Hyclorite keep much longer than ordinary Dakin's solutions.

There is no waste, testing, or waiting in making a Dakin's solution from Hyclorite.

Price, 32 oz., $1.25

Order From Your Dealer

Accepted by the Council on Pharm. and Chem. for inclusion in N. N. R.

GENERAL LABORATORIES

4713 South Dickinson St.

MADISON - - WISCONSIN

Gwathmey Apparatus

The advantage of the "Sigbt Feed"

is not—to ***set*** the proportion,

it is—to ***get*** the proportion.

Nor is it—to know the amounts in liters or gallons,

but it is—to know what you are doing.

As an indicator for the quick obtainance and safe maintenance of uniform anesthetic conditions the visible gas flow of the "Sight Feed" is absolutely reliable and permanently so.

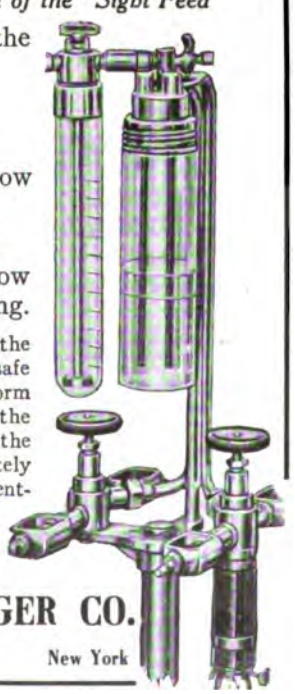

Write for Our 1919 Catalog

THE FOREGGER CO.

47 West 42nd St. New York

Deane's Patented

STERILIZERS

are recognized as the standard by leading surgeons everywhere. The Eclipse door is a guarantee of safety and efficiency, for it cannot leak or open while there is any pressure in the chamber. Made of very finest materials and in various sizes and combinations.

Our Advisory Department is at your service at any time.



Send for our Catalogue.

BRAMHALL, DEANE CO.

263N West 36th St. NEW YORK, N. Y.

Electrically Lighted Instruments

From the best material obtainable and by skilled workmen E. S. I. Co. instruments are made. Not alone are we the originators, but, as well, we are exclusive manufacturers of the most valuable diagnostic instruments in use. Their position is firmly established among the profession and their usefulness is unquestioned.

All our instruments may be operated upon our tungsten battery or upon commercial current by means of the socket current controller here illustrated.

Koch, Swinburne, Young, Gordon and MacGowan Urethroscopes
Braasch Cystoscopes, E. S. I. Co. Vaginal Specula

These and many other instruments are described and illustrated in our Catalogue, a copy of which will be mailed on request.

For your own protection be sure every instrument is marked "E. S. I. Co."

ELECTRO SURGICAL INSTRUMENT CO.
ROCHESTER, N. Y.

"Vanta" Abdominal Binder

KNITTED of soft wool—firm but elastic—it gives just the protection and abdominal support needed, yet always adjusts itself to the full or empty stomach.

A big improvement on the old-fashioned inelastic strip of flannel. Ties with three little bows of *twistless* tape—no dangerous pins—no troublesome sewing.

We would like you to know, Doctor, what an excellent binder this is. Mail us your card, or write on professional letterhead, and we will gladly send you a sample binder free.

EARNSHAW KNITTING COMPANY
1461 West Jackson Blvd - Chicago

The Abdominal Binder illustrated above is only one of the many Vanta Garments that enable baby to be dressed from top to toe without a single pin or button. Our booklet, "Baby's Outfit," describes and illustrates the entire line. May we send you a copy?

The
Pad Without a Fault

It has none of the drawbacks of other electric pads. It is so near perfection that it is

Guaranteed For One Year

The Goodwill Thermostatic control gives positive temperatures ranging from 100° to 180°. Used and endorsed by leading hospitals and physicians. *Money back if not satisfied.* Price $7.00. Order to-day.

GOODWILL ELECTRIC CO.
59 E. VAN BUREN ST. DEPT. A CHICAGO

McIntosh Universalmode
(Trade Mark)



FREE - "Electro-Therapeutics Condensed"

A handy manual containing the latest clinical data on electro-therapeutical treatment and shows where the use of this modern agency is indicated. Also shows the very latest development in electro-therapeutical apparatus.

It Tells You Why

THE UNIVERSALMODE IS SUPREME

Galvanic, Faradic, Sinusoidal, Cautery, Vibration, Air Diagnostic Light in Their Highest Efficiency.

The result of over forty years of experience as manufacturers of Electro-Therapeutical and X-Ray Apparatus.

McINTOSH BATTERY & OPTICAL CO.

Eastern Office and Service Station 1777 Broadway, New York

Main Office and Factory 217-223 N. Desplaines Chicago, Illinois

Please send a copy of "Electro-Therapeutics Condensed" and complete details regarding your special offer on the Universalmode

Name_____

Address_____

A New Blakiston Book

The After-Treatment of Wounds and Injuries

By R. C. ELMSLIE, M.S., F.R.C.S.

Brevet-Major, R.A.M.C., Special Military Surgical Hospital, Shepherd's Bush; Surgeon-in-charge, Orthopædic, Physical Exercise and Massage Departments, St. Bartholomew's Hospital

144 Illustrations. Ready

"It is a practical guide, based upon considerable experience in a Military Orthopædic Hospital."

P. BLAKISTON'S SON & CO. - Philadelphia

ON APPROVAL BLANK

P. BLAKISTON'S SON & CO.
1012 Walnut St., Philadelphia

Date_____

Please send me, for 10 days' examination_____

_____ I will remit in 30 days for books I keep

Name_____ Address_____

NOW READY

Third Edition Thoroughly Revised
With New Illustrations

Munro Kerr's Operative Midwifery

A Guide to the Difficulties and Complications of Midwifery Practice

Royal Octavo. Pp. xvi. + 725. With 308 Illustrations. Price in Britain 25/- Net.

By J. M. MUNRO KERR, M.D., C.M., Glasg., Fellow of the Royal Faculty of Physicians and Surgeons, Glasgow; Hon. Fellow, American Gynæcological Society; Professor of Obstetrics and Gynæcology, Glasgow University (Muirhead Chair); Obstetric Physician, Glasgow Maternity Hospital; Gynæcologist, Royal Infirmary; Past President of the Glasgow Obstetrical and Gynæcological Society.

"We regard this book as the most considerable addition to English obstetrical literature that has been made for a long time."—*British Medical Journal.*

New York - Wm. Wood & Co.
Fifth Avenue

London - Bailliere, Tindall & Cox
8 Henrietta Street, W. C. 2

Ready May 15th

Quarterly Medical Clinics

"The Clinic Carried to the Busy Practitioner"

A New and Unique Publication of Extraordinary Merit

Vol. I, No. 2 January-April, 1919

These Clinics are a Series of Consecutive Clinical Demonstrations and Lectures for Practitioners and Students, given at Augustana Hospital by

FRANK SMITHIES, M.D., F.A.C.P.

Associate Professor of Medicine, School of Medicine, University of Illinois; Gastro-Enterologist to Augustana and U. S. Marine Hospitals, etc.

Press Comments

It will be worth the while for any physician seeking up-to-date information to keep in touch with this publication.— *Northwest Medicine.*

Quarterly Medical Clinics is destined to be a valuable and popular addition to medical literature.— *New York State Journal of Medicine.*

This Quarterly bids fair to become a most valuable addition to medical periodical literature.— *Southern Medical Journal.*

Folder Setting Forth Contents Furnished on Application

Annual Subscription
Five Dollars, Paper
Eight Dollars, Cloth

Single Copies
One Dollar and a Half, Paper
Two Dollars and a Quarter, Cloth

Sign and Mail Today. You Can't Afford to Miss a Number

Medicine and Surgery Publishing Co., Inc. S.G.O. 5-19
Metropolitan Building, St. Louis, Mo.

Gentlemen:—Enclosed find $.....for an Annual Subscription to QUARTERLY MEDICAL CLINICS, beginning January, 1919.

Name..... Street.....

City..... State.....

The 1919 Practical Medicine Series

of Year Books

Published at monthly intervals beginning in April.

$2.50 $2.50 $1.00 $1.40 $1.00 $1.00 $1.40 $1.40

Every page of every volume is direct and to the point, yet covering with the utmost completeness what one wishes to know in the wide range of recent medicine and surgery.

The subscription price for the eight volumes is $10.00. Individual volumes are sold at the prices shown under the cut. *Carriage charges prepaid.*

THE YEAR BOOK PUBLISHERS

304 S. Dearborn St., Chicago

Our Blood Chemical Tests to Estimate Operative Risk Are Being Widely Used

Write Now for Special Containers

Our Complement Fixation Tests for Syphilis, Tuberculosis and Gonorrhea have found special favor among careful physicians. All other laboratory aids.

Gradwohl Biological Laboratories.
928 N. Grand Ave. ST. LOUIS, MO.
R. B. H. GRADWOHL, M.D., Director.
(On Leave in Service)
CARL POWELL, Acting Director

50% BETTER

Prevention Defense Indemnity

1 **All claims or suits for alleged civil malpractice, error or mistake, for which our contract holder,**
2 **Or his estate is sued, whether the act or omission was his own.**
3 **Or that of any other person (not necessarily an assistant or agent).**
4 **All such claims arising in suits involving the collection of professional fees.**
5 **All claims arising in autopsies, inquests and in the prescribing and handling of drugs and medicines.**
6 **Defense through the court of last resort and until all legal remedies are exhausted.**
7 **Without limit as to amount expended.**
8 **You have a voice in the selection of local counsel.**
9 ***If we lose, we pay to amount specified, in addition to the unlimited defense.***
10 **The only contract containing all the above features and which is protection per se.** ***A sample upon request.***

The MEDICAL PROTECTIVE CO.
***of* Fort Wayne, Indiana**

Professional Protection Exclusively

In Two Volumes, with many Illustrations and Plates. Large 8vo. Cloth Gilt, Bevelled Boards, $10.00 net.

SURGICAL CONTRIBUTIONS from 1881-1916

By RUTHERFORD MORISON, M.B., F.R.C.S. (Edin. and Eng.)

With a PREFACE and FULL SUBJECT INDEX, Contributed by W. D'OYLEY GRANGE, M.D., C.M.

VOL. I.—GENERAL SURGERY, $3.50 net. **VOL. II.—ABDOMINAL SURGERY, $6.50 net.**

"The Author has brought his views up to date.....We are surprised with the vast amount of original work.....The author's teaching aims primarily at the attainment of the thorough grasp of the principles of surgery.....these are put in a helpful way..... The book will be widely read and used as a book of reference."—BRIT. MED. JOURN.

"There are few who will not profit from an examination of these volumes; on nearly every page are to be discovered points of utmost importance."—LANCET.

"These volumes show that their author was not only a very capable surgeon, but a clear thinker and a lucid writer."—MED. JOURN. OF AUSTRALIA.

New York: WM. WOOD & CO. **Bristol, Eng.: JOHN WRIGHT & SONS, Ltd.**

REBMAN COMPANY

141 W. 36th St.
NEW YORK

NOTED BOOKS

ANATOMY

BARDELEBEN and HAECKEL—Applied Anatomy—One volume—204 colored wood cuts, with explanatory text.....$8.00

MORTON — The Abdomen Proper — Colored plates—Analytical—Synthetical—(Constructive—Destructive)—With explanatory text—One volume.....$6.00

TOLDT—Atlas of Anatomy for Students and General Practitioners.—*Revised Edition.*—1505 illustrations.

VOLUME I

A.—The Regions of the Human Body (Figures 1 to 5).
B.—Osteology (Figures 6 to 377). With Index.
C.—Arthrology (Figures 378 to 498). With Index.....$6.00

VOLUME II

D.—Myology, with a Supplement on the Anatomy of Hernia (Figures 499 to 640). With Index. E.—Splanchnology (Figures 641 to 932). With Index.....$7.00

VOLUME III

F.—Angeiology (Figures 933 to 1123). With Index. G.—Neurology. H.—The Organs of the Senses (Figures 1124 to 1505). With Index.....$11.00

Three Volumes complete, $24.00

BLOOD

EHRLICH — Anemia — Many colored illustrations..... $4.00

STERN—Bloodletting, Theory and Practice $2.50

SCHLEIP—Hematological Atlas..... $6.00

DIAGNOSIS

ABRAMS—Diagnostic Therapeutics—Illus.$6.00

ADAM — Ophthalmoscopic Diagnosis—18 illustrations in the text. 86 colored figures... $7.00

BASS and JOHNS — Practical Clinical Laboratory Diagnosis—117 textual figures and 19 plates in colors..... $6.50

CORNWALL — A Clinical Treatise on Diseases of the Heart—Diagnosis and Treatment.. $1.50

BING—Regional Diagnosis..... $3.00

FOSTER — Diagnosis from Ocular Symptoms..... $6.00

HART — The Diagnosis and Treatment of Abnormalities of the Myocardiac Function—248 illustrations..... $4.50

SCHMIDT—Malignant Tumors..... $4.00

EAR

BRAUN and FRIESNER—The Labyrinth—50 textual figures. 34 half-tones on 32 plates $4.50

KOPETSKY — Surgery of the Ear—63 half-tones and line drawings, 8 charts and 4 colored plates..... $4.00

RUTTIN—The Labyrinth..... $2.50

EYE

ADAM — Ophthalmoscopic Diagnosis—18 illustrations in the text. 86 colored figures... $7.00

FOSTER—Diagnosis from Ocular Symptoms $6.00

GREEFF — External Diseases of the Eye—84 colored illustrations. (*New Edition*).... $7.00

HIRSCHBERG — The Treatment of Shortsight—12 illustrations..... $1.50

ROEMER — A Text-Book of Ophthalmology in the Form of Clinical Lectures—186 black and white illustrations in the text and 58 figures in colors. 896 pages. (*New Edition*) .. $6.00

SCOTT — Refraction and Visual Acuity—18 illustrations, 190 pages..... $2.00

FOOD

CARRINGTON — Vitality, Fasting, and Nutrition—Illustrated..... $5.00

COMBE — Intestinal Auto-Intoxication... $4.00

GOULEY—Dining and its Amenities..... $2.50

GOURAUD—What Shall I Eat?..... $2.00

STERN—Fasting and Undernutrition in the Treatment of Diabetes..... $2.00

WEGELE —Therapeutics of the Gastro-Intestinal Tract..... $3.50

HISTOLOGY

KRAUSE—(Rudolf) Normal Histology, Including Microscopical Anatomy—502 pages, 30 figures in the text, 208 magnificent illustrations in many colors on 98 plates. Part I.....75c
Part II..... $5.50

KRAUSE (Rudolf)—Textbook of Histology. Illustrated..... $3.00

Archives of Diagnosis.
Quarterly.....$2.00 per annum
Foreign, $2.50 Single copies, 75 cents

Archives of Radiology and Electro-Therapy
Monthly.....$7.50 per annum
Single copies, 75 cents including postage.

Our books are printed from plates made in this country from type set in the United States and* PAID FOR SOLELY BY AMERICAN CAPITAL. *There are no foreign interests represented therein.

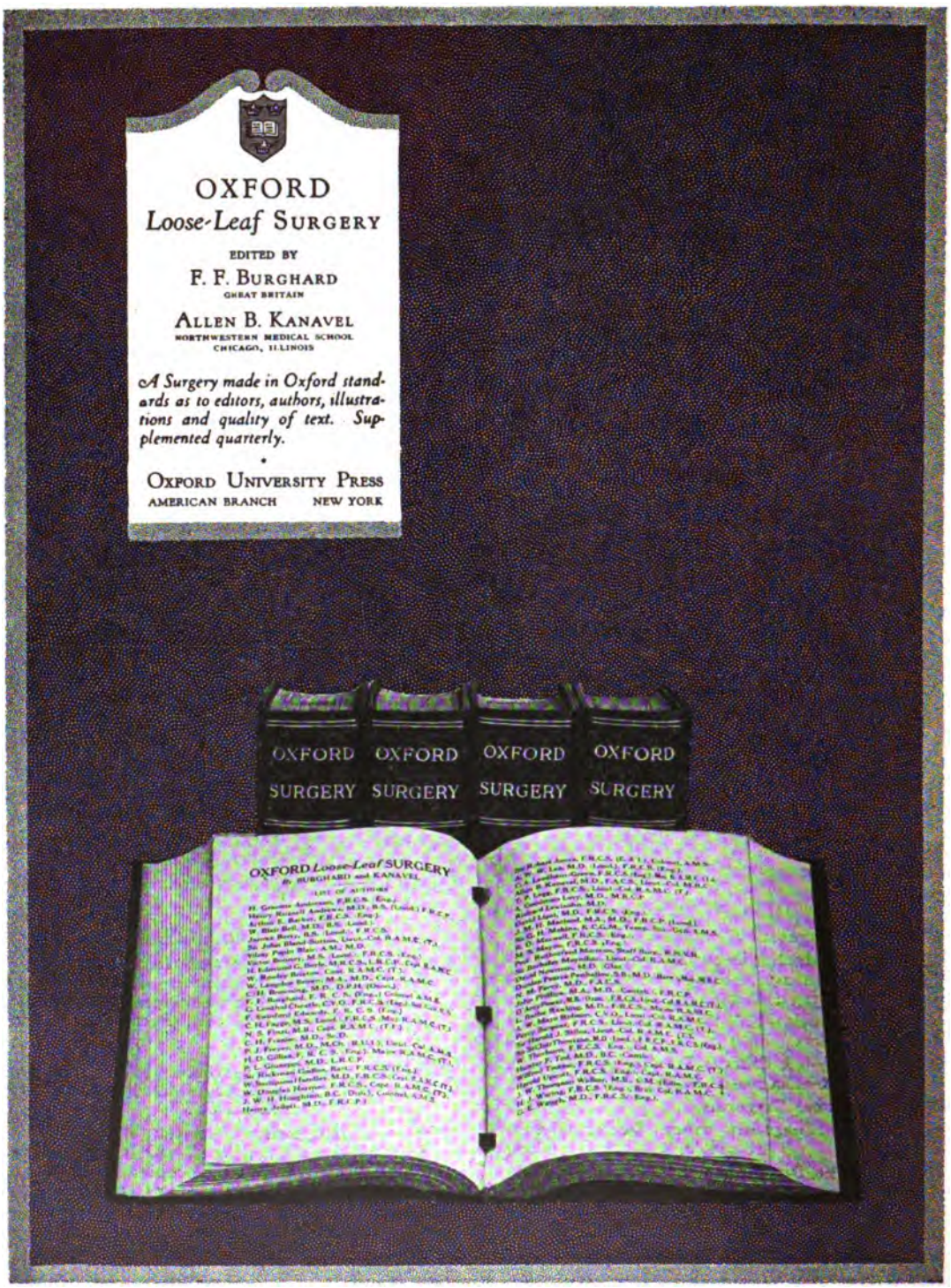
OXFORD
Loose-Leaf SURGERY
EDITED BY
F. F. BURGHARD
GREAT BRITAIN
ALLEN B. KANAVEL
NORTHWESTERN MEDICAL SCHOOL
CHICAGO, ILLINOIS
A Surgery made in Oxford standards as to editors, authors, illustrations and quality of text. Supplemented quarterly.
OXFORD UNIVERSITY PRESS
AMERICAN BRANCH NEW YORK
OXFORD SURGERY
OXFORD SURGERY
OXFORD SURGERY
OXFORD SURGERY
OXFORD Loose-Leaf SURGERY

An Important New Book for Surgeons

Greatly reduced illustration, showing one of the 250 beautiful engravings in this book.

The Operations of Obstetrics

Embracing the Surgical Procedures and Management of the More Serious Complications.

By FREDERICK ELMER LEAVITT, M.D., Formerly Assistant Professor of Obstetrics and Gynecology, University of Minnesota; Obstetrician to the City and County Hospital, St. Paul Hospital, the Bethesda Hospital, etc., St. Paul, Minn.

466 pages, 6x9, with 250 original engravings.
Price, silk cloth binding, $6.00.

The subject of obstetrics is presented from the operator's point of view, only enough pathology and physiology being introduced to give reason for and insight into the various procedures described. Treatment of the subject from this angle finds justification in the hope that the general practitioner, as well as the specialist in obstetrics, will find such a book helpful. It is the last word in surgical procedures and in the management of the more serious complications in the operations for obstetrics. The 250 illustrations form a special feature of this work. The various steps in each operation, the various positions, instruments, etc., are shown by beautiful engravings made from original drawings prepared by the author or by artists under his personal supervision.

The Entire Subject Is Covered in a Masterly Manner

1. Disinfection, Posture, Instruments, Anesthesia.
2. Indications and Conditions.
3. Artificial Interruption of Pregnancy.
4. Artificial Dilatation of the Cervix.
5. Operations Designed to Increase the Pelvic Diameters.
6. Correction and Treatment of Faulty Attitudes and Prolapsed Parts.
7. Version.
8. Breech-Birth.
9. Forceps Operations.
10. Perforation and Cranioclasis.
11. Embryotomy.
12. Cesarean Section.
13. Vaginal Cesarean Section.
14. Third Stage of Labor.
15. Postpartum Hemorrhage.
16. Rupture of the Uterus.
17. Lacerations of the Cervix.
18. Lacerations of the Vagina.
19. Pressure Injuries of the Cervix and Vagina.
20. Injuries of the Vulva and Perineum.
21. The Hemorrhages of Childbirth.
22. Multiple Birth.
23. Transverse Position.
24. Deflections of the Head.
25. Prolapse of the Umbilical Cord.
26. The Contracted Pelvis.
27. Eclampsia.
28. Birth Complicated by Tumors.
29. Malformations and Anomalies.
30. Spontaneous Abortion.
31. Asphyxia of the Newborn.
32. Extrauterine Pregnancy.

☞ You should have this important new book in your library. It is beautifully printed on heavy coated paper and handsomely bound in silk cloth. No need to write a letter—just tear off and sign the attached coupon, and Mail—but do it today, NOW, before you lay aside this journal.

CUT HERE AND MAIL TODAY

Please send me one copy of *Leavitt's new book on "Operations of Obstetrics,"* for which I enclose my check for $6.00, or you may charge to my account.

Name.....
Street.....
Town.....State.....

THE C. V. MOSBY CO., MEDICAL PUBLISHERS

801-809 Metropolitan Building, ST. LOUIS, U. S. A.

Send for Complete Catalogue of Medical Books

[Canadian Agency: McAinsh & Co., Ltd., Toronto, Canada]
[Great Britain House: Hirshfield Bros., Ltd., London]

C. V. MOSBY COMPANY
G. & O. Surg.
St. Louis

NEW LIPPINCOTT BOOKS **JUST ISSUED**

Hirst's ATLAS OPERATIVE GYNECOLOGY

By BARTON COOKE HIRST, M.D., *University of Pennsylvania*

Octavo **300 Pages** **210 Illustrations, Nearly All in Colors** **Cloth, $7.00**

This work has been confined strictly to conditions peculiar to women. The text has been subordinated to the illustrations, which are very large, clearly colored and show the separate steps of each operative procedure.

McDonald's ESSENTIALS OF SURGERY

For Students and Senior Nurses

By ARCHIBALD L. MCDONALD, M.D.

Crown Octavo **265 Pages** **46 Illustrations** **Cloth, $2.00**

This book covers the general principles of surgical diseases and pathological changes which result; the more important surgical lesions of the body are considered. The matter is presented simply and it covers most thoroughly the field of its title.

Fuch's TEXT-BOOK OF OPHTHALMOLOGY

By ALEXANDER DUANE, M.D., *Surgeon Ophthalmic and Aural Institute, New York*

Octavo **1067 Pages** **462 Illustrations** **Cloth, $7.00**

New 6th, edition of this well-known, universally used masterpiece is just from the press.

THE ELEMENTARY NERVOUS SYSTEM

By G. H. PARKER, SC.D., *Prof. of Zoology, Harvard University*

12mo. **229 Pages** **53 Illustrations** **Cloth, $2.50**

This is the second book issued in our Series of Monographs on Experimental Biology, written by a number of most prominent American biologists. As experimental biology and general physiology are one and the same science, the Series of Monographs will include the field of traditional general physiology. The volume first published was on Forced Movements, Tropisms and Animal Conduct, by Jacques Loeb, of the Rockefeller Institute. Many others are in preparation, and their publication will follow at short intervals. Full descriptive list on request.

Wilson and Potter "INTERNAL MEDICINE"

3 Octavo Volumes **Over 700 Pages Each** **448 Illustrations** **14 Plates** **Desk Index** **Cloth, $15.00**

This is a new practice in a most practical and usable form, with two volumes devoted exclusively to Diagnosis, written by Wilson, of Jefferson Medical College, Philadelphia. The third, by Potter, of Columbia University, is devoted to Treatment, and is based on the celebrated Ortner's Treatment.

INTERNATIONAL CLINICS

1st Volume; 29th Series

Octavo. 300 Pages **Illustrations: 5 Colored; 21 Black and White Plates** **Subscription Only Cloth, $2.50**

This first volume of the 29th Series contains the usual article on Progress of Medicine during 1918; eight live practical Clinics; a Symposium on Influenza; four articles on Medicine; one on Public Health and four articles on Surgery, one a Symposium on Surgery of the Thorax.

J. B. LIPPINCOTT COMPANY

LONDON: *Since 1875* — 34 Bedford St., Strand

PHILADELPHIA: *Since 1792* — East Washington Square

MONTREAL: *Since 1897* — Unity Building

NEW BOOKS AND EDITIONS

AARON—Diseases of the Digestive Organs

Full information as to symptoms; analysis of stomach contents, duodenal contents and feces; diagnosis and both medical and surgical treatment.

Octavo, 818 pages, 158 engravings, 24 plates. By CHARLES D. AARON, Sc.D., M.D., Professor of Gastro-Enterology, Detroit College of Medicine and Surgery, etc. *New (2d) Edition.*
Cloth, $7.00 net.

SIMON—Clinical Diagnosis

This revision contains much new and important material—the leading text in its field.

Octavo, 854 pages, 207 engravings, 28 plates. By CHARLES E. SIMON, B.A., M.D., Professor of Clinical Pathology and Physiological Chemistry, University of Maryland and College of Physicians and Surgeons, Baltimore. *New (9th) Edition.*
Cloth, $6.00 net.

SIMON—Human Infection Carriers

The recognition, control and management of the carrier. The call today is for men trained in this work.

12mo, 250 pages. By CHARLES E. SIMON, B.A., M.D., Professor of Clinical Pathology and Physiological Chemistry, University of Maryland and College of Physicians and Surgeons, Baltimore.
Cloth, $2.25 net.

CUSHNY—Pharmacology and Therapeutics

New matter on the disinfectants, ipecacuanha alkaloids, digitalis, opium alkaloids and methods of physiological assay. Based on the new U. S. P.

Octavo, 712 pages, 71 engravings. By ARTHUR R. CUSHNY, M.A., M.D., F.R.S., Professor of Pharmacology, University of London; Formerly Professor of Materia Medica and Therapeutics, University of Michigan, etc. *New (7th) Edition.* Cloth, $4.50 net.

HARE—Practical Therapeutics

The practical and rational application of treatment. The lessons gained from the war as to treatment of Shock and Collapse; Ambrine and Paraffine in Burns; Carrel's Methods; Intravenous Injections; Transfusion; Dichloramine-T and Chlorcosane, etc., are all set forth clearly and fully.

Octavo, 1023 pages, 145 engravings, 6 plates. By HOBART AMORY HARE, M.D., B.Sc., Professor of Therapeutics, Materia Medica and Diagnosis, Jefferson Medical College, etc. *New (17th) Edition.*
Cloth, $5.50 net.

BROWN—Oral Surgery

Important changes in war surgery — the wonderful plastic operations and prosthetic devices for reconstruction, etc.

Octavo, 734 pages, 570 engravings, 20 plates. By GEORGE V. I. BROWN, D.D.S., M.D., F.A.C.S., Major, M. R. C., etc. *New (3d) Edition.* Cloth, $7.00 net.

GRAY—Anatomy

The World's Standard on Anatomy.

Imperial Octavo, 1396 pages, 1247 large and elaborate engravings, mostly colors. Revised by WARREN H. LEWIS, B.S., M.D., Professor of Physiological Anatomy, Johns Hopkins University. *New (20th) Edition.*
Cloth, $7.50 net; Three-Fourths Leather, $9.00 net.

BACON—Manual of Otology

The text on suppurative inflammation of the labyrinth entirely rewritten and thorough revision on adenoid growths, enlarged tonsils, submucous resection of nasal septum, etc.

12mo, 583 pages, 204 illustrations, 2 plates. By GORHAM BACON, A.B., M.D., F.A.C.S., Formerly Professor of Otology, College of Physicians and Surgeons, Columbia University; Aural Surgeon, New York Ear and Eye Infirmary, etc.; and TRUMAN L. SAUNDERS, A.B., M.D., Assistant Professor of Laryngology and Otology, College of Physicians and Surgeons; Assistant Surgeon, Bellevue Hospital, etc. *New (7th) Edition.* Cloth, $3.00 net.

TREVES—Surgical Applied Anatomy

Every chapter revised, considerable new material and twenty-seven new illustrations introduced.

12mo, 702 pages, 153 illustrations, 74 in colors. Revised by ARTHUR KEITH, M.D., LL.D., etc. Hunterian Professor and Conservator of the Museum, Royal College of Surgeons of England, etc., and W. COLIN MACKENZIE, M.D., F.R.C.S., etc., Member of the Council of the Anatomical Society of Great Britain and Ireland. *New (7th) Edition.* Cloth, $3.25 net.

KOPLIK—Diseases of Infancy and Childhood

Intensely clinical in value. Much new material on acidosis, the infectious diseases, meningitis, tuberculosis, diseases of the ductless glands and blood and on the various problems of Infant Feeding.

Octavo, 928 pages, 230 engravings, 25 plates. By HENRY KOPLIK, M.D., Attending Pediatrist, Mt. Sinai Hospital; Ex-President of American Pediatric Society, etc. *New (4th) Edition.*
Cloth, $6.00 net.

CABOT—Modern Urology

By eminent American authors. The standing of the contributors assures, and press reviews acclaim it to be the most thorough and modern work in this field.

Two octavo volumes of over 700 pages each, with 632 engravings and 17 plates. Edited by HUGH CABOT, M.D., F.A.C.S., Chief of the Genito-Urinary Department, Massachusetts General Hospital; Assistant Professor of Genito-Urinary Surgery, Harvard, etc.
Cloth, per Vol., $7.00 net.

CROTTI—Thyroid and Thymus

Giving the details as to the symptoms, diagnosis and both medical and surgical treatment of goiter and all diseases of the thyroid and thymus as practiced by the world's leading authorities.

Imperial octavo, 570 pages, 96 engravings, 33 colored plates. By ANDRÉ CROTTI, M.D., F.A.C.S., Formerly Professor of Clinical Surgery, and Associate Professor of Anatomy, Ohio State University; Surgeon to Grant and Children's Hospital, Columbus.
Half Morocco, De Luxe, $10.00 net.

LUMB—Systematic Treatment of Gonorrhea

A thoroughly practical handbook giving the practical details of methods of treatment found most valuable in thousands of cases. Covers Pathology and Bacteriology, Urinalysis, Routine Treatment, Special Treatments (Vaccines, Electro-Chemical, Mercury Compounds), Complications, Chronic Cases, Test of Cure, etc.

12mo, 119 pages. By N. P. L. LUMB, Captain, Royal Army Medical Corps. Cloth, $1.50 net.

VEDDER—Syphilis and Public Health

How to prevent Syphilis, including methods both for the individual and the community; its prevalence and means of transmission are the main points of this book.

12mo. 315 pages. By COL. E. B. VEDDER, M.D., M.C., U. S. A.
Cloth, $2.25 net.

WHITMAN—Orthopaedic Surgery

Just off press and embodying the most recent methods of diagnosis and differential diagnosis, new appliances and new methods of treatment. The technique of all operative procedures; of bone grafting; nerve grafting; tendon and muscle transplantation; surgery of peripheral nerve injuries, etc., is given in detail.

Octavo, 914 pages with 767 illustrations. By ROYAL WHITMAN, M.D., M.R.C.S., Eng., F.A.C.S.; A Director of Military Orthopaedic Teaching; Chairman of the Medical Advisory Board for Orthopaedics in New York City; Associate Surgeon to the Hospital for Ruptured and Crippled; Orthopaedic Surgeon to the Hospital of St. John's Guild; Corresponding Member of the British Orthopaedic Society, etc., etc. Cloth, $7.00 net.

Tear this page out, check books wanted. Have them charged, or enclose remittance, as you prefer

Lukens Sterile Catgut

TRADE (Bartlett Process) MARK

Make the Test Yourself

Compare It Point for Point With Any Other Catgut

We Will Send the Samples

It is sterile, antiseptic, strong, supple, elastic; free from excess oil; will not untwist in using and is more than usually resistant to absorption.

Sizes 00-4 Plain *Sizes 00-4 Tanned*

C. DE WITT LUKENS CO.
4908 Laclede Avenue
ST. LOUIS MO., U.S.A

FOR SALE BY ALL DEALERS.

The thought behind the tube—
"the patient on the table"
Van Horn
Not "good enough"—but the best from every standpoint—alone assures that degree of "Catgut Safety" demanded when the patient on the table is "ONE OF MY OWN FAMILY."
Only on this peculiarly personal basis is "Van Horn" Catgut supplied to the profession.
Johnson & Johnson
VAN HORN and SAWTELL DEPARTMENT
NEW BRUNSWICK, N. J.

RADIUM RENTAL SERVICE

By The Physicians' Radium Association of Chicago

(Incorporated under the laws of Illinois, "Not for Profit")

BOARD OF DIRECTORS

William L. Baum, M. D.
N. Sproat Heaney, M. D.
Frederick Menge, M. D.
Thomas J. Watkins, M. D.
Albert Woelfel, M. D.

MANAGING DIRECTOR

Albert Woelfel, M. D.

ESTABLISHED to make Radium more available in the *Middle States* and to furnish advice based on extensive observations, about its approved therapeutic uses. Maintains the equipment, large and complete in its makeup, that is needed to meet the special requirements of any case in which radium therapy is indicated. Radium loaned to any responsible physician. Moderate rental fees charged.

For Full Particulars Address

THE PHYSICIANS' RADIUM ASSOCIATION

1104 Tower Bldg., 6 N. Michigan Ave., Chicago **Telephones, Randolph 6897-6898**

The Radium Company of Colorado, Inc.
Denver, Colorado

Announcing an Exhibit

of Special Interest
to the

RADIUM THERAPEUTIST

at the

American Medical Association
June 9th to 13th, 1919
Atlantic City

Space 133~134, Balcony Ballroom
near A.M.A Exhibit

Mines
Naturita, Colo.

New York Office
50 Union Square

Reduction Works
Laboratories
Denver Colo.

An Announcement

SURGICAL instruments may now be had in Stellite, the Master Metal.

Stellite alloys have attracted the attention of the scientific and commercial worlds since their discovery, several years ago, by Elwood Haynes. Mr. Haynes is the inventor of America's first automobile and one of the first (if indeed not the first) of the discoverers of alloy steels. As a metallurgist of international fame, he sought for a metal of exceptional properties, meant to perform exceptional tasks. The super metal that crowned his efforts he named Stellite from the Latin word *stella*—a true star metal. Stellite is harder than steel. Stellite blades will hold their edge many times longer than the best steel blades. Stellite blades may easily be resharpened, should they become dulled.

Stellite is immune to heat, and to the action of all antiseptic compounds.

Stellite contains no iron. It will not rust, stain or corrode.

Surgical and dental instruments made from Stellite are in no sense experiments, but have triumphantly passed the most rigorous tests. Many thousands were purchased by the Surgeon General of the United States Army for use over seas during the war.

Instruments of this wonder metal are now available for home use. Stellite is the metal ideal for the dentist and surgeon.

We would be pleased to explain the Master Metal to you more fully.

THE HAYNES STELLITE COMPANY

Surgical Instrument Department KOKOMO, INDIANA

MY friends will be glad to know that I consider the Victor "Model Snook" Roentgen Apparatus is a very satisfactory technical development of the original Snook Roentgen Apparatus, which I had the privilege of presenting to the medical public in 1907.

I believe that with its recent improvements the Victor "Model Snook" is the best X-Ray machine of the present day art.

H. Beckley Snook

Full particulars are given in the new "Model Snook" bulletin which is just off the press. A copy will be sent on request — and without the least obligation.

VICTOR ELECTRIC CORPORATION

Manufacturers of a Complete Line of Roentgen and Electro-Medical Apparatus

CHICAGO
236 S. Robey St.

CAMBRIDGE, MASS.
66 Broadway

NEW YORK
131 E. 23rd St.

Sales and Service Stations:

NEW YORK, N. Y.
131 E. 23d St.
CAMBRIDGE, MASS.
66 Broadway
CHICAGO, ILL.
30 E. Randolph St.
236 S. Robey St.
PHILADELPHIA, PA.
25 S. 17th St.
SEATTLE, WASH.
823 White Bldg.
PORTLAND, ORE.
803 Morgan Bldg.
KANSAS CITY, MO.
414 E. 10th St.
BIRMINGHAM, ALA.
619 Brown-Marx Bldg.
DETROIT MICH.
103 Broadway
CINCINNATI, OHIO
1021 Union Central Bldg.
ALBANY, N. Y.
82 S. Grove Ave.
LOUISVILLE, KY.
433 Atherton Bldg.
ROCHESTER, N. Y.
840 Genesee St.
NEW ORLEANS, LA.
606-608 Maison Blanche
LOS ANGELES, CAL.
930 Hill St.
MINNEAPOLIS MINN.
220 La Salle Bldg.
AUSTIN, TEXAS
708 Colorado St.
PITTSBURGH, PA.
620 Fulton Bldg.
FT. WAYNE, IND.
1333 Calhoun St.
DES MOINES, IOWA
518-22 Utica Bldg.
TORONTO, CANADA
24 Hayter St.
WINNIPEG, CANADA
Keewayden Bldg.
VANCOUVER, CANADA
536 Smythe St.
SAN FRANCISCO, CAL.
334 Sutter St.
BUFFALO, N. Y.
318 Pearl St.
ATLANTA, GA.
515 Hurt Bldg.

Eastman Dupli-Tized X-Ray Films

THIS interesting film radiograph of a bladder stone in a fleshy person, shows how effectively Dupli-Tized Films may be used in diagnostic work of this kind.

Films are flexible, easy to handle; light and compact for filing, unbreakable and cost less than plates.

Ask your dealer for Eastman Dupli-Tized X-Ray Films.

EASTMAN KODAK CO., ROCHESTER, N. Y.

Distinct Differentiation

Distinct differentiation in fine tissue work is facilitated by the use of Diagnostic X-Ray Plates. They show a wealth of detail—a clear cut contrast—that is of exceptional value in the portrayal of kidney and gall bladder work.

Combined with density, contrast, detail, the Diagnostic X-Ray Plate possesses superior speed. It is the fastest plate made—100% faster than others.

Only new selected glass, free from flaws, is used in their manufacture. Equally good for direct and screen work.

AMERICAN PHOTO CHEMICAL COMPANY
ROCHESTER NEW YORK

For Sale by Leading Supply Houses

DIAGNOSTIC

The Essential Definition of Image is Assured by Correct Use of the Proper Size Focal Spot.



The Radiator Type Coolidge X-Ray Tube

Highest standards of diagnosis depend upon the correct use of a tube having a fine focus.

The Radiator Type Coolidge X-Ray Tube is characterized by its exceptionally fine focus.

Immediate Shipment Can Be Made

General Electric Company

General Office Schenectady, N.Y.

35B-12

THE MEYER MULTOSCOPE

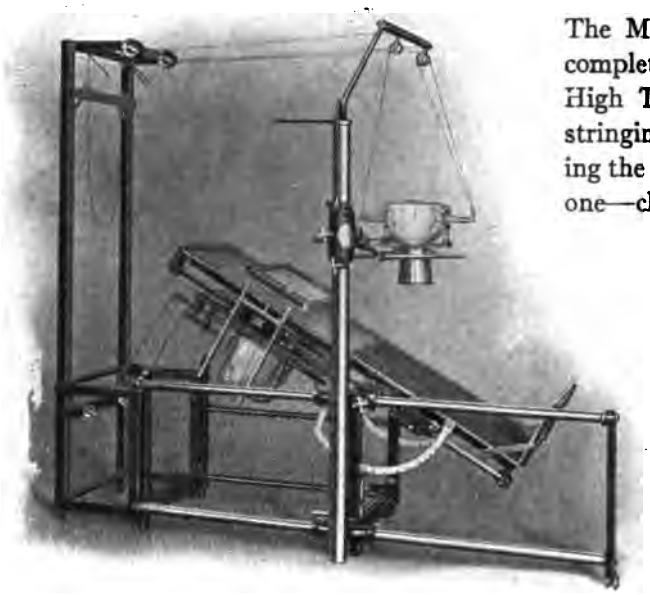

The Meyer Multoscope is furnished complete with Self Contained Aerial and High Tension Switch, eliminating the stringing of wires in a room and making the placing of the apparatus a flexible one—changeable as desired. No current wasted in excess wiring. The last word in classiness.

It covers every phase of Modern X-Ray Work.

Send for the
MULTOSCOPE BULLETIN

Price complete $1100.00

THE WM. MEYER COMPANY

817 WASHINGTON BLVD. **CHICAGO, ILL.**

ANNOUNCEMENT

AN EPOCH-MAKING ADVANCE IN THE ROENTGEN ART

The Wappler Electric Company announces the production of a new Roentgen Ray Tube known as

NITROKEN

This new gas tube remains stable during heavy prolonged exposures and cannot be over-reduced

Full technical and commercial information will be sent upon request

WAPPLER ELECTRIC COMPANY, Inc.
173 E. 87th Street, NEW YORK. U. S. A.

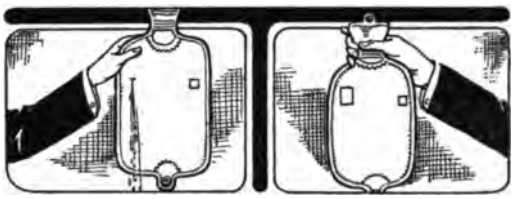

Patch— All Your Leaking, Punctured

HOT WATER BOTTLES

With the Never-Failing, Cleanly

E-Z SELF CEMENTING SELF VULCANIZING **PATCH**

WIDELY used in hospitals everywhere because so easy and clean to apply—no tedious, sticky messes of glue or cement—just a little touch of gasoline and on goes E-Z patch to STAY. During sterilization or boiling it becomes actually vulcanized to the bag; can't peel or tear off. Have some handy—they will save time and money.

PRICES
E-Z Patches for Hot Water Bottles, Four for 25c; Hospital Size Pkg., Twenty for $1.00.

THE E-Z PATCH CO.
Manufacturers of Patches for Surgical and Household Rubber Goods
AKRON - - OHIO

SKELETONS

We have secured a large stock of

Selected Skeletons

■

Prices and descriptions gladly furnished on application

TRUAX
CHARLES TRUAX, Incorporated
141 N. Wabash Ave. CHICAGO

62 Dishes For 30 Cents

5 Cents Per 1000 Calories

We feel that women should be told the food value and economy of oats.

The 30-cent package of Quaker Oats serves 62 big dishes. The same calory value in meats, eggs, fish and fowl will average ten times its cost.

Here are some comparisons, based on current prices:

Cost Per 1000 Calories

Quaker Oats 5c	Veal Cutlets 57c
Round Steak 41c	Fresh Fish 60c

The oat is also vastly better food. It is almost the ideal food in balance and completeness.

Yet ten people can be fed on Quaker Oats at the cost of feeding one on meat.

Quaker Oats

The Queen Grains Flaked

Quaker Oats are flaked from queen grains only—just the rich, plump, flavory oats. We get but ten pounds from a bushel. This means an extra-flavory oat dish without extra price.

The Quaker Oats Company
Chicago

[3076]

Campbell

EXPERIMENT AND UNCERTAIN RESULTS ARE ELIMINATED WHEN YOU INSTALL

Campbell Roentgen Apparatus

Sure-X Interrupterless Transformer
Tube Tilt Table
Stereoscopic Tube Stand
High Frequency Coils
Electro-Therapeutic
and Roentgen Accessories

Send for Literature

CAMPBELL ELECTRIC CORPORATION
LYNN, MASSACHUSETTS

Drop it into the barrel

of your aseptic hypodermic syringe—"it" being an S&D hypo-tablet—add a few minims of clean cold or warm water, shake once, perhaps twice, and you have a solution that's limpid, accurate, non-irritating.

Could anything be easier or simpler? Or safer?—the risk of irritation being about nil with skill and a clean syringe and needle.

Most druggists supply; yours will if you ask him.

SHARP & DOHME
the hypodermic tablet people

Salvarsan
(Arsphenamine-Metz)
AND
Neosalvarsan
(Neoarsphenamine-Metz)

WE have greatly improved the methods of manufacture of these standard remedial agents. Official tests show they possess a relative fixity of arsenic content entirely in keeping with the original formulas.

We have no hesitation in asserting that Salvarsan and Neosalvarsan are now THE arsenical preparations *par excellence.*

With this great improvement in quality we have reduced the prices to such an extent that these valuable drugs are now available for much more extended use in private practice.

SALVARSAN
(Arsphenamine-Metz)

0.1 gram	$ .60	per ampule
0.2 "	.75	" "
0.3 "	.85	" "
0.4 "	1.00	" "
0.5 "	1.25	" "
0.6 "	1.50	" "
1.0 "	2.00	" "
2.0 "	3.75	" "
3.0 "	5.50	" "

In Cartons containing 10, 25 or 50 Ampules
(May be assorted sizes)
10 per cent discount

NEOSALVARSAN
(Neoarsphenamine-Metz)

Dosage I,	0.15 gram	$ .75	per ampule
" II,	0.3 "	1.00	" "
" III,	0.45 "	1.25	" "
" IV,	0.6 "	1.50	" "
" V,	0.75 "	1.75	" "
" VI,	0.9 "	2.00	" "
" X,	1.5 "	3.00	" "
" XX,	3.0 "	5.50	" "
"XXX,	4.5 "	8.00	" "

In Cartons containing 10, 25 or 50 Ampules
(May be assorted sizes)
10 per cent discount

NOVOCAIN is again obtainable in any required amounts, both in powder form and tablets.

If your druggist cannot supply you with Salvarsan, Neosalvarsan or Novocain, forward order direct to us.

H. A. METZ LABORATORIES, Inc.
122 Hudson Street **NEW YORK**

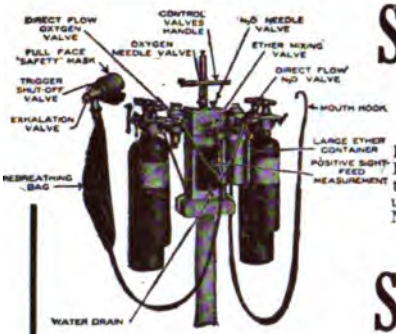

SAFETY GAS-OXYGEN APPARATUS

Simplifies the administration of
NITROUS OXIDE and OXYGEN
with or without an Ether Sequence
Major or Minor Surgery—Obstetrics—Dentistry

Positive mixtures instantly obtained, accurately maintained and clearly shown by the New Sight-Feed-Measurement, which is controlled by a simple water column. No gauges or springs to get out of order.
Complete outfits for Private and Hospital use.
Write for booklet containing full information

SAFETY ANAESTHESIA APPARATUS

CONSCERN
Ogden Ave. and Randolph St., Chicago, Ill.

Positive Sight-Feed Measurement

B&B *Surgical Dressings*

The Standard for 25 years

BAUER & BLACK
Chicago New York Toronto

WE CAN SUPPLY YOU WITH

Gauze and Bandages

Prices upon request

The Good Manufacturing Co.
156 N. Wells Chicago

Bound Volumes

Surgery, Gynecology and Obstetrics is especially designed for binding in book form. Our standard volumes are substantially bound in an extra good grade of blue art canvas, stamped in gold. Each volume consists of six numbers: two volumes to the year, January to June and July to December.

Surgery, Gynecology and Obstetrics with International Abstract of Surgery, per volume $7.50
Surgery, Gynecology and Obstetrics *without* the Abstract, per volume - - - - - 4.00
International Abstract of Surgery, per volume - - - - - - - - - - 4.00

We Can Supply All Back Numbers in Bound Volumes Except Vol. II

Back Numbers Returned for Binding

Where copies are returned by subscribers in exchange for bound volumes, the charge per volume for binding will be as follows:

Surgery, Gynecology and Obstetrics with International Abstract of Surgery, per volume $2.75
Surgery, Gynecology and Obstetrics, per volume - - - - - - - - - - 1.75
International Abstract of Surgery, per volume - - - - - - - - - - 1.75

The prices quoted above include carriage charges on shipments to points in the United States and Canada. Express or freight charges on journals returned for binding must be prepaid.

The Storm Binder and Abdominal Supporter

(Patented)

General Support

Sacro-Iliac Special

Maternity

STORM Binders are being worn in Asia, Africa, Europe, Australia, South America and North America—all the continents—and in the Islands of the Sea—Porto Rico, Tasmania, Philippines, New Zealand, and the others—**because physicians know the superiority of The Storm over ordinary belts.** We have submitted the evidence—demonstrating what The Storm will do: The members of the Medical Profession are the judges and from far and near come their orders to us giving their verdict in favor of The Storm

The surgeon in the metropolitan hospital and the general practitioner in the rural district alike approve and order The Storm for their patients. Our work is in co-operation with the physician and our entire resources are always at his command to secure the support desired for any condition.

The Storm Binder is for General Support in visceroptosis, obesity, general relaxation of abdominal walls, etc., etc.

The Storm Binder is for Special Support in hernia, relaxation of the sacro-iliac articulations, floating kidney, descent of stomach, colon and intestines.

The Storm Binder is for Post-Operative Support of incisions in upper, middle and lower abdomen, as after operations upon stomach, gall-bladder, liver, appendix and pelvic organs.

The Storm Binder is for Maternity Cases, relieving the nausea and discomforts of pregnancy.

The Storm Binder is for any purpose for which man, woman or child needs an abdominal supporter.

Ask for Illustrated Folder, giving details of adaptability, construction, prices, materials, testimonials of physicians and full instructions for ordering by mail.

Mail Orders Receive Immediate Attention

KATHERINE L. STORM, M.D.

1541 Diamond Street **PHILADELPHIA**



THE BATTLE CREEK SANITARIUM AND HOSPITAL—Established 1866

Medical Surgical Orthopedic
Neurological Obstetrical Reconstructive

Educational Departments

Training School for Nurses Normal School of Physical Education School of Home Economics and Dietetics
Students received on favorable terms Registered trained nurses, dietitians and physical directors supplied

Descriptive literature mailed free upon request

THE BATTLE CREEK SANITARIUM
Box 243, BATTLE CREEK, MICHIGAN

Surgical Technique: Instruction and Practice

AN ORIGINAL plan of teaching Surgical Technique, giving the instruction, and enabling the doctor to do the operations over and over, until he has mastered all details. Particular attention is given to the table toilet, and the work is performed as humanely as if the operations were being done upon an anaesthetized human. *The operations are all performed by the student.*

Each table is furnished with the same instruments that are to be found in any well-equipped operating room, and gowns and gloves are supplied to each student.

The Laboratory is open daily from 8:30 to 5 o'clock, which makes it possible for the man whose time away from his practice is limited, to get the work in the shortest possible time.

Special courses may be had in surgical anatomy on the cadaver.

Northeast Corner of Operating Room

Personal Instruction, Actual Practice, and Exceptional Equipment. Course Completed in 7 Days (50 hours), Minimizing Time Away from Practice.

As to the Plan, Time, Fee, etc., Address

The Laboratory of Surgical Technique

Phone Midway 4896 7629 Jeffery Ave., CHICAGO

The L. of S. T. of Chicago

Gentlemen: Send me information regarding the above.

Name.....

City.....

State.....

Stanolind

Reg. U. S. Pat. Off.

Surgical Wax

Alleviates Pain

When the wax film is laid on a denuded surface the patient is relieved of pain immediately.

Until after the healing process has started, Stanolind Surgical Wax should not remain on the wound longer than twenty-four hours.

Later the wound may be cleansed and redressed every forty-eight hours.

In removing the dressing, when that portion adhering to the uninjured skin has been loosened, the entire film may be rolled back without causing the least pain, or without injury to the granulations.

Stanolind Petrolatum

For Medicinal Use

In five grades to meet every requirement.

Superla White, Ivory White, Onyx, Topaz and Amber.

Stanolind Petrolatum is of such distinctive merit as to sustain the well-established reputation of the Standard Oil Company of Indiana as manufacturers of medicinal petroleum products.

You may subject Stanolind Petrolatum to the most rigid test and investigation—you will be convinced of its superior merit.

STANDARD OIL COMPANY

(Indiana)

Manufacturers of Medicinal Products from Petroleum

910 S. Michigan Avenue Chicago, U. S. A.

765

New York Post-Graduate

Medical School and Hospital

Courses arranged for the general practitioner in all branches of medicine. Separate courses on every subject and Special Practical Courses, where individual instruction is given in the following subjects:

Anaesthesia; Colon and Rectal Diseases; Complete Eye Seminar, embracing seven Special Courses; Ear Operations (Cadaver); Nose and Throat Operations on the Cadaver and in the Operating Rooms; Bronchoscopy; Nose and Throat Pathology; Abdominal Diagnosis; Physical Diagnosis; Diagnosis and Treatment of Constitutional Diseases of the Adult; Dietetic and Metabolic Problems; Infectious Diseases; Neurology; Stomach Diseases; Infant Feeding and Diagnosis; Intubation and Lumbar Puncture; Practical Pediatrics; Cystoscopy—Male and Female; Diagnosis and Office Treatment of Gynecological Cases; Gynecological Operations on the Cadaver; General Surgery on the Cadaver; Genito-Urinary Surgery on the Cadaver; Military Orthopedic and Bone and Joint Surgery; Treatment and Care of Fractures; X-Ray and Laboratory Work.

The Hospital has a bed capacity of over 400. The average number of patients admitted daily to the Dispensary is 800. The Hospital and teaching facilities are as extensive during the summer months as during the winter session. Cadaver courses omitted during June, July, August and September.

Through the courtesy of the Secretary, a two-day complimentary ticket is given, which enables the visiting physician to decide upon the courses best suited to his purpose and to meet the instructors in the various departments before registering for any work.

For Further Particulars Address

SECRETARY OF THE FACULTY

305 East Twentieth Street **NEW YORK CITY**

SURGERY, GYNECOLOGY AND OBSTETRICS

AN INTERNATIONAL MAGAZINE, PUBLISHED MONTHLY

VOLUME XXVIII MAY, 1919 NUMBER 5

PANCREATIC LYMPHANGITIS

WITH AND WITHOUT JAUNDICE[1]

BY JOHN B. DEAVER, M.D., F.A.C.S., PHILADELPHIA

DURING the past decade disease of the pancreas has been productive of a considerable amount of literature for some of which I have to acknowledge responsibility. The pancreas is so commonly involved at operation for upper abdominal conditions that I have thought it worth while again to direct attention to it and to consider the relation between the pancreatic lymph glands and other abdominal viscera.

The gall-bladder, bile-ducts, pyloric region of the intestines and the second part of the duodenum, through their efferent lymph channels, are placed in intimate relation to the head of the pancreas, and it is the head of the pancreas that is most frequently involved in pancreatitis associated with other upper abdominal diseases. The course of infection has time and again been observed at the operating table in gall-bladder diseases. Inflammation of the gall-bladder is followed by enlargement of the cystic lymph glands, periductal lymphangitis, enlargement of the glands at the head and at the margin of the pancreas and often of the regional lymph channels at the head of the pancreas.

"The lymph drainage from the head of the pancreas passes through the lymph glands of the common and hepatic ducts. A cholecystitis causing great enlargement of these glands can produce pressure and jaundice, or a lymphœdema or a lymph-borne infection of the head of the pancreas, just as at times lymphœdema is seen in the arm following amputation of the breast and removal of the axillary glands. The gland group in both instances drains three regions."[2]

Induration of the head of the pancreas about the common duct is present in 35 to 40 per cent of diseases of the gall-bladder, not only in cases with common duct stone, but also in many cases where the gall-bladder is only slightly diseased but in which there is enlargement of the lymph glands draining the gall-bladder, and also in a number of cases of strawberry gall-bladder with or without stones.

In the course of my abdominal work I am becoming more and more convinced that the first stage of chronic pancreatitis is nearly always disease of the pancreatic lymph glands. This primary disorder can rarely, if ever, be diagnosed before operation, nor is a preoperative diagnosis of chronic pancreatitis always possible. In both conditions the predominant symptoms are those of some upper abdominal disease, with which they are more often than not associated, principally gall-bladder disease, peptic ulcer, disease of the liver, or appendicitis. In the absence of definite indications of calculi, the appearance of jaundice serves to suggest the possible cause of the trouble. The onset of jaundice in these cases, as a rule, is gradual and its

[2] C. J. Mayo. Collected Papers, Mayo Clinic, 1916. viii. 280.

[1] Read by title before the Southern Surgical Association, Baltimore, December, 17–19, 1918.

intensity, variable at first, is apt to be more constant than when due to stone or stones in the common duct. The difficulties of diagnosis are illustrated by the following cases, recently operated upon by me at the Hospital of the University of Pennsylvania:

The patient, male, aged 18 years, gave as his chief complaint jaundice, nausea, and pain and weakness of the muscles of the lower extremities.

The pain began four days before admission and two days later jaundice set in, first on the face and then covering the entire body, the skin becoming a muddy yellow. There was considerable nausea, vomiting, some spitting of blood, dizziness and languor.

Physical examination in addition to the jaundice showed slight epigastric pulsations, absence of peristalsis, abnormal breathing. No areas of tenderness were noted. The liver was palpated at the costal margin, liver dullness was percussed 8 centimeters below the costal margin. The liver extended from the eighth rib to the end of the costal margin in the right mammary line.

Two days after admission the patient vomited medicine, food, and a small amount of blood. Vomiting and evidence of bleeding continued at intervals for several days. The symptoms finally yielded to treatment and the patient was able to go home much improved one month after admission. Nineteen days later he returned, giving a history of having vomited two days previously, but which he attributed to dietary indiscretions. Jaundice was still marked, and general weakness and stiffness of the lower extremities were present. He also complained of bladder irritability and nocturnal frequency.

Examination showed an increased enlargement of the liver which was found to extend four finger breadths below the costal margin. Palpation of the gall-bladder was doubtful. There was some tenderness over Mayo-Robson's point. The patient later became stuporous, and the temperature rose to above 104°F. Vomiting continued. The attending physician diagnosed enlargement of the gall-bladder and referred the patient to me for operation. I found the gall-bladder to be slightly enlarged but normal in appearance. The bile in the gall-bladder also was apparently normal, but its mucous membrane was granular in appearance. The pancreas was enlarged and slightly congested. The liver was very large and congested. Adhesions between the gall-bladder and the duodenum gave evidence of old inflammation of the gall-ducts. Our operative diagnosis was, therefore, acute obstructive cholangitis. Operation consisted of draining the gall-bladder. The postoperative course was most stormy, variations in temperature giving a genuine "steeple chart." The patient finally got well.

E. A. Graham[1] has recently demonstrated that enlargement of the liver is a feature in 87 per cent of cases with disease of the biliary tract; a rather too large percentage I am inclined to think. Nevertheless he finds that this enlargement occurs regardless of whether or not calculi are present or whether or not there is obstruction of the cystic duct, and states that, "if cholecystitis is well-established it is very probable that ascending infection of the liver may constantly recur, possibly through the lymphatics surrounding the bile passages." We all know that a gall-bladder once infected rarely regains its normal condition. Its walls have a tendency to harbor bacteria, which in turn may lead to infection of the liver through the lymph channels around the biliary tract.

[1] Surg., Gynec. & Obst., 1918, xxvi, 521.

The following case recently operated upon by me at the Lankenau Hospital well shows pancreatic lymphangitis as the precursor of a pancreatitis which was without doubt obviated by operation.

The patient, a married woman aged 42 years, gave a history of eleven years of abdominal pain often severe enough to require morphia for relief. There was no constancy in the time of the attacks, nor was there any relation to food intake. Four days before admission she experienced one of the very severe attacks, and after this became slightly jaundiced. There was no history of vomiting or nausea during the attacks.

Her youngest child is eighteen months old; pregnancy was normal.

Physical examination showed jaundice involving the entire body. The tongue was covered with a thick grayish coating. Teeth fair. Abdomen: tenderness in the gall-bladder area and increased rigidity in upper right rectus. Diagnosis: gall-bladder disease.

A severe attack of pain the day after admission required morphia for relief. Jaundice increased. At operation the following day, the liver was found to be enlarged and congested. The gall-bladder distended and chronically inflamed. The gall-bladder was removed and when opened was found to contain muddy bile and many stones. The cystic duct was opened and muddy bile exuded. Some adhesions around the hepatic flexure of the colon were released. The pancreatic lymph glands were very much enlarged. The head of the pancreas was slightly enlarged. A chronically inflamed appendix was removed. Jaundice began clearing the day after operation. The patient is still in the hospital and is doing well.

These pancreatic and peripancreatic inflammations as I have elsewhere pointed out, are comparable to cervical adenitis following

tonsillitis, or inguinal adenitis after an infection of the extremity. The subsidence of the infection in the gall-bladder is steadily followed by subsidence of the lymphangitis. In view of the fact that in the present state of surgery we have no successful means of directly attacking the chronically diseased pancreas, it is obvious that early treatment of this "prepancreatitis," if I may coin the term, is most desirable. Medical treatment is slow, not always successful, and offers no assurance of freedom from recurrence. Surgery gives reasonable assurance of removing all foci of infection and consequent freedom of recurrence.

Disease of the prepancreatic lymph glands without jaundice is demonstrated in the following instance.

Male, age 39, admitted to the Lankenau Hospital, complaining of upper abdominal distress after eating. The history shows seven years of periodic attacks of epigastric pain four to six hours after meals, relieved by alkalis. Also nocturnal pain relieved by food. There is no constipation; no history of jaundice nor of gall-stone colic; no nausea or vomiting. Physical examination is negative except for the abdomen. The abdominal wall is relaxed; peristalsis active. The stomach capacity is 2700 cubic centimeters. We were unable to wash out the stomach entirely. The stomach is slightly ptosed. X-ray confirmed gastroptosis and demonstrated pyloric obstruction. Diagnosis: duodenal ulcer. At operation, adhesions running across the duodenum to the gall-bladder causing partial obstruction were released. There were enlarged glands along the neck of the gall-bladder and along the common duct. A spastic hourglass contraction of the duodenum relaxed under manipulation.

The peripancreatic lymph glands were enlarged and hard. The head of the pancreas was large and hard. Some perisplenic adhesions were released. A large chronic indurated ulcer was present at the junction of the pylorus and duodenum, the injection extending down into the duodenum and upward along the lesser curvature of the stomach. An anterior gastrostomy brought to view a large bleeding ulcer, one inch in diameter. Considerable blood was found in the stomach. The opening in the stomach was closed with chromic gut and linen. Posterior gastro-enterostomy was done. A chronically diseased gall-bladder was removed. The cystic and common ducts were found to be patulous. A fibrous appendix was removed. This patient made an uneventful recovery and has been entirely relieved of his symptoms.

Without enlarging upon the pathology and the surgical details of the question, I have cited these cases in order to emphasize the importance of early surgical treatment of upper abdominal disease before a possible pancreatitis has time to get in its destructive work.

PRACTICAL CONSIDERATIONS WITH REGARD TO PERMANENT COLOSTOMIES[1]

By W. E. SISTRUNK, M.D., F.A.C.S., Rochester, Minnesota
From the Mayo Clinic

EACH year we see a number of patients in whom we find it necessary to make permanent colostomies. As a rule, these colostomies are made in certain patients selected from a group of cases in which it has been found necessary to excise the rectum and sphincter muscles for cancer, and in cases of inoperable cancer of the rectum. The patients thus operated on have given us excellent opportunities to test the various types of operations and to note the annoying conditions which may arise following a permanent colostomy.

In reviewing briefly the anatomy of the lower colon, it will be remembered that the posterior one-third of the descending colon from the splenic flexure to the sigmoid, usually lies behind the peritoneum. This portion of the bowel has, as a rule, a very short mesentery, and often is more or less fixed to the posterior abdominal wall. Near the beginning of the sigmoid flexure the peritoneum completely surrounds the bowel, and the mesentery supplying this portion becomes much longer; it usually measures from three to six inches in length.

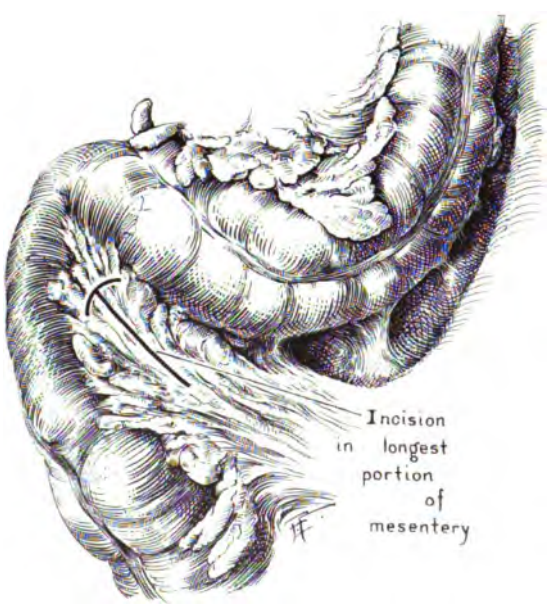

Fig. 1. Near view of sigmoid flexure showing the long mesentery in comparison with the short mesentery above it, and also the incision in the mesentery when the sigmoid flexure is used for making a colostomy.

Nearly every type of colostomy that has been suggested and that seemed practical has been used in the Mayo Clinic, but up to the present time, operations or procedures undertaken with an idea of giving the patient control of the bowel passages have almost always proved disappointing. Until recently we made the majority of colostomies through an oblique, muscle-splitting incision in the left inguinal region. The loop of bowel brought up for the colostomy was supported by a glass rod, a rubber tube, a piece of skin or silk-worm sutures, and was cut across five or six days following the operation. Many of the colostomies made in this manner were perfectly satisfactory. In a few of the cases there was a tendency toward the development of a ventral hernia into the tissues surrounding the colostomy. More frequently, however, the tendency has been toward a retraction of the loop of bowel in which the colostomy was made, allowing in some instances, the proximal end of the bowel to discharge a part of its contents into the distal end. We also have found, in instances in which the bowel was cut off at or near the level of the skin, that there is a tendency on the part of the skin to contract around the opening in the bowel, thus narrowing it sufficiently to interfere with the proper discharge of fæces. In looking back on the group of colostomies made in this manner it is easy to explain the reasons for the development of most of these conditions. The incision was made over a portion of the bowel which was more or less fixed, and if the sigmoid flexure was pulled up and used as a loop for the colostomy this was often ele-

[1] Presented before the Southern Surgical Association. Baltimore, December 17-19, 1918.

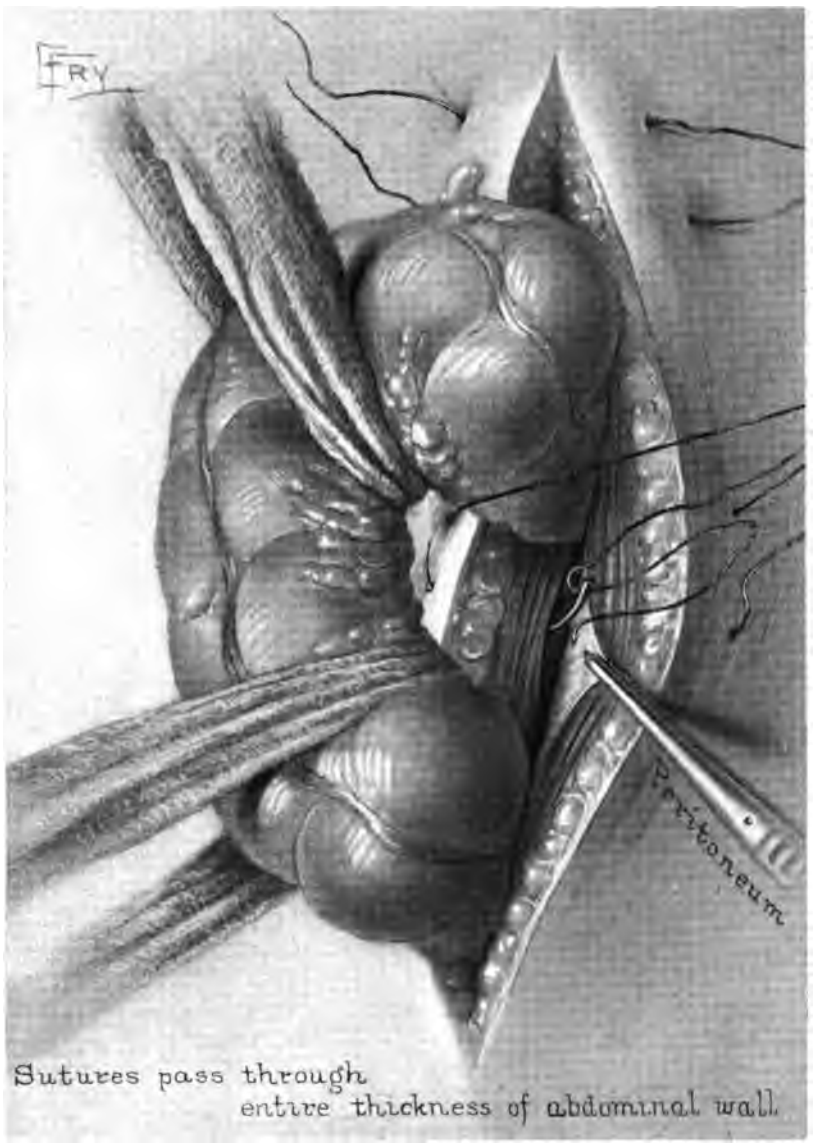

Fig. 2. Edges of the opening in the mesentery of the sigmoid being held widely apart by gauze while a portion of abdominal wall is being closed through the opening.

vated with considerable difficulty. After the colostomy had been made, the edges of the abdominal wall were separated for a distance of from two to three inches by two limbs of bowel and the mesentery supplying the loop used for the colostomy. This, naturally, left a large opening through the abdominal wall which in some instances permitted a herniation of the loop; or allowed the loop to retract or pull inward toward the abdominal cavity.

In many of the operations for excision of the rectum, a segment of the sigmoid is left between the colostomy and the site where the bowel is cut off in making the excision of the rectum. In such instances, if the co-

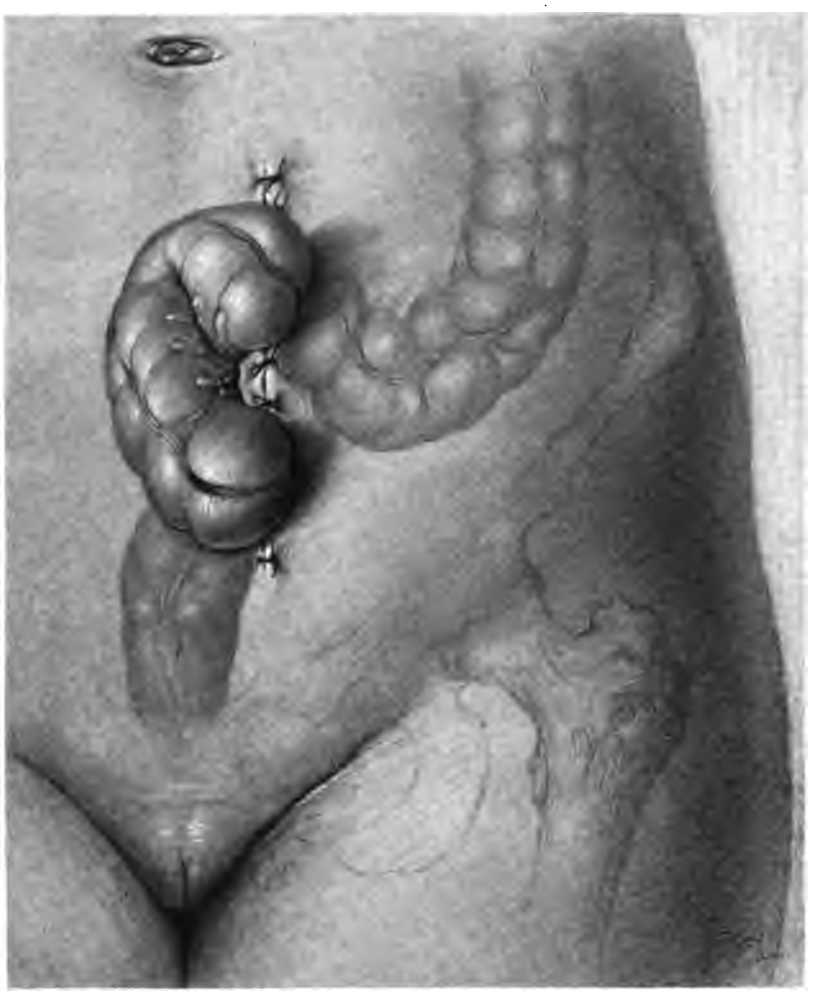

Fig. 3. Unopened loop of bowel brought out for colostomy after the abdominal incision has been completely closed.

lostomy retracts sufficiently to permit the distal end to empty its contents into the segment, the fæces gradually accumulate and produce a large painful tumor. Occasionally we have found it necessary, either to remove this segment or to empty it and perform a plastic operation which will more widely separate the ends of bowel.

We are now making a colostomy very similar in type to the one described by Mixter. As a rule this colostomy is made through a straight incision placed below and about one inch to the left of the umbilicus.

An incision of this type possesses distinct advantages. Through it a thorough exploration of the abdominal cavity may be made. If it is found necessary, a primary resection of the bowel is possible, or, the first stage of the three-stage Mikulicz operation can be done. The incision may be extended in either direction, and if, after the exploration, it is decided to make a colostomy, this is made through the center or upper end of the incision.

OPERATION

The colostomy is made in a loop of the sigmoid flexure; this portion of the bowel is chosen because of its extreme mobility and

the length of its mesentery. After the loop has been lifted out of the abdominal cavity, an incision from one and one-half to two inches in length is made through its mesentery, parallel to the direction of the blood-vessels, and extending upward nearly to the bowel. A second incision, about one inch long, is then made across the end of the first incision quite near the mesenteric attachment of the bowel. Two strips of gauze are placed in the upper end of this T incision and when these are pulled apart a good sized opening through the mesentery is created. The two sides of the entire abdominal wall near the center of the abdominal incision are sutured through this opening in the mesentery. The remaining portions of the incision are then closed; a small bite of the bowel is included in two of the sutures to prevent the possibility of herniation of a loop of small intestine. When the gauze has been removed a glass rod or rubber tube is placed through the opening in the mesentery between the skin and bowel to serve later as a guide in cutting across the bowel (Figs. 1, 2, 3, and 4).

If necessary for gas distention, a small opening may be made in the bowel any time after twenty-four to forty-eight hours, and in from five to six days the bowel is cut across completely with the cautery. As a rule, however, the patients pass gases very readily through the knuckle which has been brought up, and it is unnecessary to disturb it before five or six days. After the loop has been cut across it will be found that the two ends of bowel are separated by the entire abdominal wall for a distance of from one to one and one-half inches and that the cut ends of bowel protrude for a distance of an inch or two above the skin. These may later be cut shorter if thought necessary.

Fig. 4. Ends of the bowel after it has been completely cut across.

The advantages of an operation of this type can be readily seen. In our hands it has obviated some of the difficulties which have often followed other types of colostomies.

THE TREATMENT OF HODGKIN'S DISEASE[1]

By CURTIS F. BURNAM, M.D., F.A.C.S., Baltimore

FEW morbid processes present greater variations in rate of progress and more protean clinical manifestations than does Hodgkin's disease. Its course may be run in a few weeks or extend over years. Tumefaction may be pronounced and the constitutional disturbance slight; but often the exact reverse is true. The primary lesion may appear in the neck, in the mediastinum, in the abdomen or in all these places simultaneously. The patient may come to us for help for pruritus with or without skin rash, for a chronic cough or dyspnœa, for œdema of the leg, or for an invasive breast growth. Periods of quiescence and rapid progress alternate in some cases; in others there is a steady march of the disease. Without treatment all recorded cases have ended in death. There is no authentic report of a spontaneous cure, although it is quite possible that such do occur.

Over a period of six years I have treated more than a hundred cases of Hodgkin's disease and malignant lymphoma or lymphosarcoma, which resembles it so closely clinically. I have in preparation a detailed case and statistical report of this series. I shall not, however, describe individual cases in this paper nor give a critical review of the very valuable studies in recent literature, although such a review is almost indispensable to an adequate presentation of the progress being made in the knowledge of the etiology, pathology, and treatment of the disease. I must confine myself to a few practical conclusions drawn from my own experiences.

DIAGNOSIS

Exact diagnosis is necessary as a preliminary to adequate treatment, and such diagnosis rests on X-ray, blood and tissue examinations as well as on a careful general physical examination.

In the advanced stages, tissue examination is the most reliable single criterion. By this

Fig. 1a (at left). Miss K. A. D. (1897). Hodgkin's disease with general involvement and marked pruritus. Photograph taken September 8, 1915, before treatment.

Fig. 1b. Miss K. A. D. (1897). Photograph taken October 11, 1915, after three radium treatments. Complete disappearance of all evidence of trouble. Well at present. Cure has lasted more than three years.

[1] Presented before the Southern Surgical Association, Baltimore, December 18, 1918.

Fig. 2a (at left). Mr. F. G. (2399). Hodgkin's disease. No tissue. Blood not characteristic. Photograph taken April 6, 1916, before treatment.

Fig. 2b. Mr. F. G. (2399). Photograph taken April 17, 1917, after five treatments. No treatments since. At present no evidence of trouble. Well for nearly three years.

Fig. 3a (at left). Miss D. E. (2290). Chronic Hodgkin's disease with extensive involvement of skin and clavicle, and infiltration of breast. Photograph taken February 23, 1916, before treatment.

Fig. 3b. Miss D. E. (2290). Photograph taken October 17, 1916, after ten exposures to radium. Still under treatment. At present her arm is greatly swollen but her general health is good.

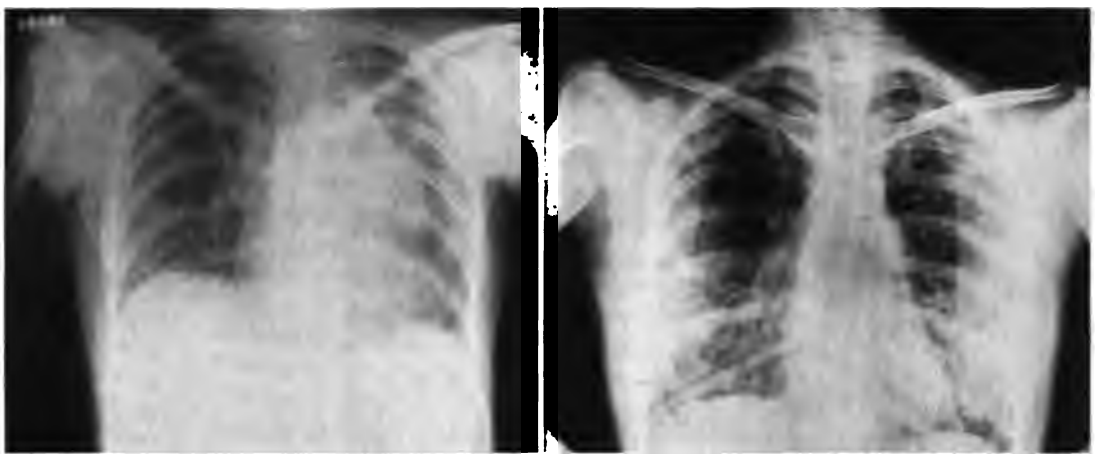

Fig. 4a (at left). Mrs. R. L. (126). Lymphosarcoma of mediastinum and neck. Diagnosis from tissue. Roentgenogram taken June 14, 1913, before treatment.

Fig. 4b. Mrs. R. L. (126). Roentgenogram taken May 4, 1917, after eight treatments. After three treatments the chest was negative. In the spring of 1917, a recurrence appeared which was dissipated by further treatment. Perfectly well ever since.

method, the typical Dorothy Reed Hodgkin's disease, lymphosarcoma, tuberculosis, syphilis, and the metastatic tumors are readily separable. In very early lesions, it may be impossible to distinguish between lymphosarcoma, Hodgkin's disease, simple hyperplasia and tuberculosis, as they all have more or less the microscopical characteristics of lymphosarcoma.

As a routine diagnostic measure, I advocate the removal of at least two isolated glands. I have seen no spread of the disease as a consequence of this procedure. On the contrary, attempted removal of large masses, as in block dissection of the neck, frequently aggravates the disease.

As to whether there is a common etiologic cause of Hodgkin's disease and lymphosarcoma, I am unprepared to express an opinion, but until such relationship is shown to exist I feel that they should be considered as separate diseases.

Blood examinations are relatively much less valuable than tissue examinations. A positive finding of Bunting's blood picture does not necessarily mean that the patient has Hodgkin's disease, nor does a negative finding show the absence of such disease. For, out of 34 cases where the tissue showed positive Hodgkin's disease, the blood was positive in only 21 instances and was negative in 13. Moreover, out of 26 cases where the tissue showed positive lymphosarcoma, 3 cases showed the blood which Bunting has designated as characteristic of Hodgkin's disease.

X-ray examinations are indispensable in determining mediastinal and chest involvement. They frequently prove the presence of marked trouble, when neither the history nor ordinary physical examination suggests it.

TREATMENT

The medicinal treatment of Hodgkin's disease is most unsatisfactory. A few apparent cures from salvarsan and other forms of arsenic are on record. My impression is that when arsenic is forced it tends usually to make the disease progress more rapidly.

Vaccines made from the diptheroid organism have been extensively used but with indifferent results. I have had no personal experience with them.

Under the influence of the splendid work of Bunting and Yates, there has been a marked revival in favor of surgical removal of Hodgkin's glands — a procedure which had been well nigh abandoned because of the impression that it was not only useless but harmful. There can be no question, however,

Fig. 5a (at left). R. F. (2471). Acute Hodgkin's disease. Patient was extremely ill with huge masses in neck, chest, and abdomen. There was high fever and marked emaciation. Roentgenogram taken April 7, 1916, shows chest condition before treatment.

Fig. 5b. Miss R. F. (2471). Roentgenogram taken March 15, 1918, shows improved condition two years later after a series of radium treatments. General condition at present satisfactory, although there was a recurrence in one and one-half years. Still under treatment.

that their more satisfactory experiences are due to the invariable and immediate employment of X-ray treatment in conjunction with the operative removals.

X-ray therapy in Hodgkin's disease is not new. It has been widely practiced ever since Nicholas Senn's report now nearly twenty years ago. That the X-ray has a very beneficial effect both in ameliorating constitutional symptoms and in reducing tumor there can be no question. Nevertheless, few if any, authentic cures by this method are on record.

While many of our patients had been treated both operatively and with X-ray, I have made use only of radium, combining it in some cases with rest in bed, forced feeding and iron in the form of Blaud's pills.

Most of the patients were in advanced stages of the disease. Many of them were acute cases, some of them practically in articulo mortis.

I have excluded from consideration only those cases in which the disease was limited to the tonsil, where it is difficult to classify as Hodgkin's, lymphosarcoma or hyperplasia. Most satisfactory results have been obtained in this group, which doubtless contains instances of Hodgkin's disease.

In general I find that better results are obtained in cases where the tissue examination shows lymphosarcoma than where it shows Hodgkin's disease, and in Hodgkin's disease where the characteristic polymorphonuclear leucocytosis is not present.

Chronic cases are more favorable than acute. Intensive prolonged exposures, very satisfactory in some chronic cases, are quite unsuitable in acute cases.

In a chronic case limited to one set of glands a single exposure may lead to a cure, which has, in one case, extended over five years. Heavy exposures in acute Hodgkin's disease are usually followed by rapid reduction in the size of the gland masses but with no corresponding improvement in the blood or the patient's general condition. In these acute cases rest in bed, forced feeding and mild fractional radiation are indicated. This method of treatment we have used for only about one and one-half years, and are consequently unable to report on the results. Acute cases treated more than one and one-half years ago with the heavy dose method are dead with the exception of Miss R. F., aged 18. This girl was admitted to the hospital on April 6, 1916, with high fever, a great mass in the abdomen, and another in the chest; she was extremely emaciated and evidently dying. Under treatment there was apparent complete cure lasting for more than

Fig. 6a (at left). Miss L. L. (3971). Mediastinal tumor with tissue and blood both characteristic of Hodgkin's disease. Roentgenogram taken May 23, 1918, before treatment.

Fig. 6b. Miss L. L. (3971). Roentgenogram taken October 18, 1918, after four radium treatments. It was impossible to give heavy dosage in this case, so frequent, light treatments were used. Still being treated.

one and one-half years. There was then an extensive abdominal recurrence which is at the present time yielding to treatment.

Rest and abundant feeding are of great importance in the chronic cases. Heavy work and exposure readily lead to relapse.

The most unsatisfactory chronic cases are those with very little glandular enlargement but with marked constitutional symptoms and changes in the blood. In two or three cases of this kind met with there has been but little amelioration of the patient's condition following treatment.

In every case where the infection is limited to isolated groups of glands, such as one side of the neck and axilla, a complete disappearance of the glands can be looked for with confidence. Where the disease is extensive, especially in mediastinal cases, this is more uncertain.

In chronic Hodgkin's disease the disappearance of the gland masses is almost invariably accompanied by improvement in general health, gain in weight, disappearance of pruritus and the return of the blood to a normal appearance.

TECHNIQUE

Treatment must be so planned that adequate radiation will be applied to all parts of the body affected by the disease. At the same time great care must be taken to avoid injury of normal structures, particularly the skin. It is probably desirable even in early localized cases to radiate all the regions of the body in which Hodgkin's disease is likely to appear. There is apparently no effect on gland masses when not directly radiated.

The guide to treatment is to be found in the effect on the gland masses, the blood, the appetite and the general health of the individual case. No fixed plan of treatment is possible as a routine measure. The dose that is effectual in causing gland disappearance in one case may be many times greater than that required in another case. One patient may suffer with loss of appetite, fever, and general malaise from a treatment which when given another causes none of these disturbances. I should say that several hundred milligrams is a workable minimum for use in the treatment of Hodgkin's disease. In a few cases we have used as high as fifty gram hours in a single dose.

Gamma radiation from radium placed at a distance from the surface varying from one and one-half to five inches, has been used — the length of the exposure being inversely proportional to the amount of radium employed.

Fig. 7a. Mr. C. S. B. (2255). Hodgkin's disease with cervical, mediastinal, and axillary involvement. Tissue and blood both characteristic. Roentgenogram taken February 7, 1916, before treatment.

Fig. 7b. Mr. C. S. B. (2255). Roentgenogram taken March 6, 1917, after three treatments. Patient has been well for nearly three years.

GENERAL RESULTS

The reduction of gland masses, amelioration of discomforts and improvement in general health already referred to occur in most cases and sometimes are most striking in the very advanced stages. It seems to me that we may confidently look for permanent cure in an increased proportion of these patients with further improvement in our methods of treatment. It is, of course, impossible to fix any definite time limit as an indication that the disease will not recur. I recently had the experience of an extensive abdominal recurrence and death in a patient apparently well for four years from a pharyngeal and neck lymphosarcoma.

Excluding all patients where apparent cure has been less than three years, we have had, where lymphosarcoma was diagnosed, 2 cases perfectly well and without signs of trouble for more than five years; one an extensive neck case, and one an abdominal case. Four cases have been apparently well for over three years; 1 with pharyngeal and neck involvement, 1 with mediastinal, 1 with tonsil, neck and groin, and 1 case with neck and axilla involvement.

Excluding all patients where apparent cure has been less than three years, we have had, where Hodgkin's disease was diagnosed, 1 patient with mediastinal and neck involvement well for four years, and 2 cases well for more than three years. One of these had neck, axilla, groin and iliac glands; the other groin, axillary, neck and mediastinal involvement.

While there is no objection to the complete surgical removal of a localized group of glands, if it is followed by radiation, it does not seem to me that this is necessary.

ECTOPIC OR PELVIC KIDNEY[1]

By E. S. JUDD, M.D., and S. W. HARRINGTON, M.D., Rochester, Minnesota
From the Mayo Clinic

RENAL ectopia, or congenital misplacement of the kidney, is a condition in which the kidney has never occupied its normal position; it is to be distinguished from the movable kidney which has wandered from its normal position. Renal ectopia is due to developmental defects of the renal anlage. The renal buds appear on the dorsal aspect of the wolffian duct, shortly after it has reached the cloaca, as a thickening and bulging of the wall which soon develops into a narrow stalk capped with a mass of mesoblastic tissue, designed to be the future kidney. These buds grow dorsally during their process of development, in ascent from in front of the second sacral vertebra, rotate to a lateral position on either side of the vertebral column, and reach their normal position in the lumbar region about the end of the second month. It is not until after they have reached this position that they receive vascularization. This process of ascent and rotation may stop at any point during its course or it may not be instituted at all; thus the kidney never reaches its normal height and becomes permanently fixed in an abnormal location. Variations in size and form often follow from its adaptation to its surroundings, and are governed to some extent by environment and developmental defects. Often there is an associated defective development of mueller's duct, which does not normally develop until after the primitive kidney has reached its final height, which accounts for the frequent association of genital malformations with ectopic kidney.

Renal malposition is comparatively rare but occurs often enough to interest diagnosticians, and a sufficient number of such cases develop pathologic conditions requiring surgical intervention, to interest the surgeon. The condition has been recognized for centuries, and was well known to the early writers of the sixteenth century, but it was then of anatomic interest only. Cases were reported by Bauhinus and many others. The

Fig. 1 (154170). Left ectopic kidney; moderate clubbing and dilatation of calyces. Lead catheter in the right ureter showing the right kidney in normal position.

Fig. 2 (229728). Solitary right ectopic kidney. Pelvis small and irregular in shape situated opposite middle of sacrum. Ureter short and tortuous.

[1] Presented before the Southern Surgical Association, Baltimore, December, 1918.

Fig. 3 (225346). Pelvic outline extending below the crest of the ilium. Right ectopic kidney.

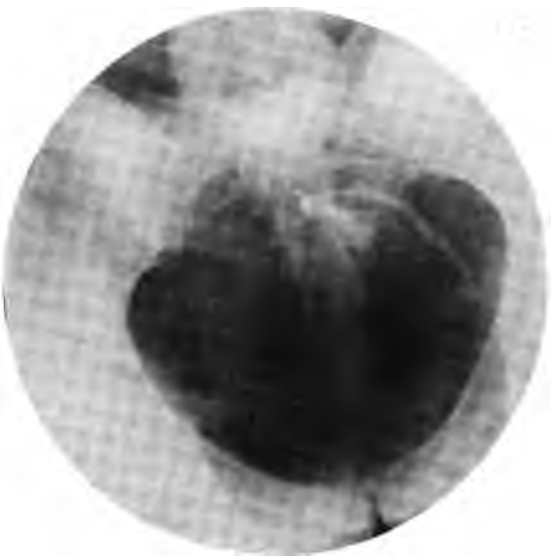

Fig. 4 (17834). Left ectopic kidney obstruction to left ureter just outside the bladder.

frequency of the occurrence of misplaced kidney has been variously stated by different authorities: Naumann, in 1897, reported 21 cases in 10,177 necropsies at the Kiel pathologic institute. Gerard, in 1903, estimated its occurrence as 1 in 2,500. Guizzetti and Pariset, in 1910, reported 18 cases in 20,000 necropsies. Within the last two decades the condition has become of surgical interest, and with the accurate means of diagnosis now used is steadily growing in clinical importance. Dorland, in 1911, collected 121 clinical cases from the literature, about 100 of which had been published since 1898. In less than one-third of them the symptoms were due to displacement or disease in the ectopic kidney. Plummer, in 1913, reported 67 cases, collected by Strater in 1906, to which he added 17, making a total of 84 clinical cases. Operations were done in 63 of Strater's 67 cases; 48 were some type of operation on the kidney.

Our series comprises 19 cases of ectopic kidney which have been selected from the records of the clinic. In 9 of these, operations were done because of pathologic conditions in the misplaced kidney. In the remaining 10 cases the condition was discovered either during the course of some other operation or in making a routine examination of the kidney. In these 10 cases the kidney, while misplaced, was not producing any symptoms and apparently was functionating normally.

ANATOMIC FEATURES

The ectopic kidney shows some distinct anatomic features, mostly in its blood supply.

Fig. 5 (184087). Left ectopic kidney with moderate hydronephrosis.

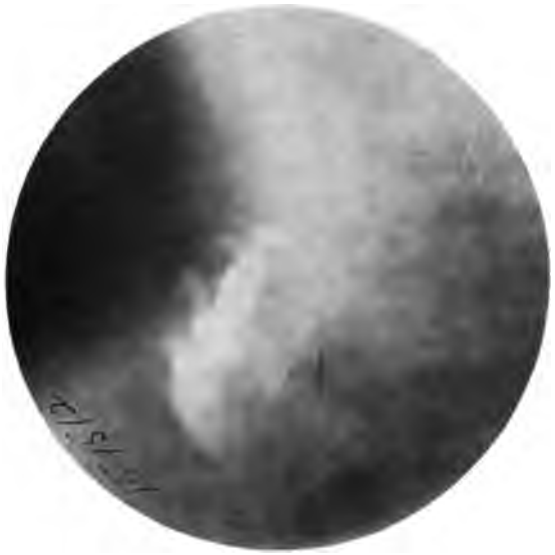

Fig. 6 (151512). Right ectopic kidney with hydronephrosis.

Fig. 7 (120522). Right ectopic kidney with reduplication of pelvis.

It is usually approximately normal in size when not diseased, although it may be smaller than normal. It may be oval or pyramidal in contour, depending somewhat on the surrounding structures, and it may retain its fœtal lobulations. The origin of the blood-vessels supplying the misplaced kidney is always lower than normal. The arterial supply is very liberal; as many as six vessels entering the kidney have been reported. These vessels may come from the lower few inches of the aorta, from a branch of the aorta, or from both. The usual origin is the lower few inches of the aorta, especially at the bifurcation, but it may be the common iliac, the midsacral or inferior mesenteric. As a rule the veins correspond to the arterial supply, but an anomalous arrangement is frequently found. The ureter is generally shorter than normal; usually takes a short tortuous course to the bladder and enters it in the normal position. The pelvis of the kidney and the ureter are usually on the anterior side of the kidney, and in this manner they retain their fœtal relation. The pelvis is not always fully developed. The position that such a kidney assumes varies greatly depending on the time at which the normal process of development ceases. Its most frequent location is entirely within the small pelvis behind the uterus, to one side, or resting on the promontory of the sacrum or sacro-iliac joint. It is sometimes located in the iliac fossa, and rarely in the abdominal wall. It is usually firmly fixed in the position assumed, due chiefly to its vascular pedicle. It may become

Fig. 8 (212352). Left ectopic kidney with pyonephrosis and stones.

movable from trauma or pregnancy. A pelvic kidney is much more frequently found on the left side than on the right, and it is usually on the side where it normally belongs, although crossed ectopic kidneys are quite often seen. Occasionally both kidneys are in the pelvis, and rarely an ectopic supernumerary kidney may be found. The adrenal glands develop independently; they are always found in their normal position and never accompany the ectopic kidney. It is interesting to note the frequency with which genital malformations of both sexes are associated with dystopia of the kidney, particularly in cases of single pelvic kidney. The genital defect, if unilateral, is found on the same side as the ectopic kidney. The more frequent defects are the imperfect development or the entire absence of the uterus and the vagina. There may be an absence of vulvar and urethral openings, and atrophic and undescended testicle is often seen. In quite a number of the reported cases there has also been an imperfect development of the urinary bladder. Definite mental disturbances have been observed to be associated with ectopic kidney, and are believed to be the stigmas of degeneration, due to developmental defects. Ectopic kidneys are usually normal and although they are subject to all the pathologic conditions to which a normal kidney is subject, they are only discovered by chance during an examination, or at necropsy. When any lesion exists in the kidney, there seems to be a tendency for it to become hydronephrotic, probably because of the short ureter and poorly formed pelvis and ureter. The surrounding structures may also play a part in this condition. Stones are frequently found in these kidneys, as is also cystic degeneration and tuberculosis.

CLINICAL FEATURES

From clinical observations it appears that pelvic kidney occurs more often in females than in males, but at necropsy, it is found as often in the male. This is undoubtedly owing to the fact that the misplaced kidney in the female is more prone to cause symptoms which simulate disease of the uterus and adnexa, and also menstrual disturbances. When the ectopic kidney is pathologic the symptoms are the same as when the condition is present in a normally placed kidney. The diagnosis depends on the physical findings, the X-ray and the kidney examinations. The diagnosis, ordinarily, is not easily made, but there are some physical findings which are of aid. The palpation of a tumor through the abdominal wall or rectum especially with the absence of the kidney from its normal position, is suggestive of the condition. The absolute and relative fixation of the tumor and often the palpation of the lobulations of a kidney, the depression in the hilus, and at times the pulsation of a large artery on its anterior wall, may be noted. The presence of genital malformation associated with a pelvic tumor should lead one to suspect ectopic kidney. Cystoscopic examination and pyelography give the most accurate data, and it is on these data that a definite diagnosis is made. Frequently the cystoscope reveals certain fairly characteristic features, especially the pulsation in the trigone from an underlying large renal artery. The ureteral meatuses are usually normal but the ureter from the ectopic kidney is much shorter and may be coiled and distorted. The pyelogram shows the abnormal position of the pelvis and makes it possible to determine whether or not the kidney is pathologic. The presence of stones also is shown.

The differential diagnosis is more difficult in the female than in the male because of the frequency with which the ectopic kidney causes symptoms referable to the adnexa. In many instances a pelvic kidney has been called an ovarian cyst and explorations have been made with the idea that the condition is a cyst in one of the ovaries. A pyonephrosis in an ectopic kidney has been mistaken for pyosalpinx. The most common error in diagnosis in the male has been in differentiating between the dystopic kidney and inflammation in the appendix. In two of our cases it was quite difficult to determine whether the symptoms were being produced by the appendix which showed a slight degree of inflammation or whether the symptoms were produced by some infection which was located in the pelvic kidney.

TREATMENT

From a surgical point of view the treatment of ectopic kidney differs in no essential from the treatment when the organ is in its normal position. The mere fact that the kidney did not rise to its normal position does not indicate that it requires treatment. If the kidney is functionating normally in its malposition, under ordinary circumstances it should not be disturbed. A few instances have been reported in which a kidney in the pelvis was interfering with pregnancy, and apparently was the cause of repeated miscarriages. In such cases it might be advisable to attempt to raise the kidney to a higher position. Ordinarily, it is difficult to change the position of the ectopic kidney because the blood-vessels in the pedicle are short and the kidney is rather firmly fixed. In some cases, however, in which the kidney is producing symptoms such as would be caused by an intermittent hydronephrosis, although the function may be normal, it would seem advisable to attempt to change its position, and possibly to do a plastic operation at the point of obstruction. This was done in one of our cases, and quite a satisfactory result was obtained. In some of the reported cases in which a nephrorrhaphy had been done, it was necessary subsequently to remove the kidney.

The problems presented by the ectopic kidney during pregnancy and parturition are often difficult to decide, but fortunately most deliveries are accomplished without surgical intervention. We have not observed a case of pregnancy complicated in this manner, but from reported cases it would seem that the amount of hindrance to labor depends on the amount of narrowing of the true pelvis, and also on the degree of fixation of the kidney. It has been suggested that if the condition is noted early in the pregnancy and if it seems to narrow the pelvic inlet sufficiently to hamper labor, an attempt should be made to anchor the kidney above the brim of the pelvis. It has also been suggested that a nephrectomy should be done under such conditions, but we believe that instead of doing a nephrectomy which might be quite a serious procedure, it would be best to wait until during the last stages of pregnancy, and then perform a cæsarean section.

The surgical treatment of pathologic conditions in the ectopic kidney is practically the same as for like conditions in normally placed organs. In all cases in which there is destruction of kidney tissues, impaired function, and a normal kidney on the opposite side, a nephrectomy is certainly indicated. Before considering nephrectomy in such cases, however, it is very important to determine the condition of the opposite kidney. In three of our cases, the ectopic kidney was solitary, and in all it seemed to be the cause of the symptoms.

REVIEW OF 19 CASES

Nine of the nineteen cases of ectopic kidney of this series were operated on for some pathologic condition in the kidney.

In one case an exploration was made to determine the nature of a pelvic tumor which proved to be a fairly good kidney, lying within the pelvis. It was freed from its pelvic attachment and a fixation was made as high up as possible. This seemed to relieve the patient for some time but she returned in fourteen months with symptoms somewhat the same.

In the second case, a diagnosis of a functionless right kidney with hydronephrosis and tumor was made. An exploration revealed an ectopic kidney. Nephrectomy was done with satisfactory recovery.

In the third case, the patient gave a history of gall-bladder trouble. Physical examination revealed a rather firm mass in the right abdomen, and exploration showed the mass to be an ectopic kidney, which was freed and fixed in a higher position. The condition of the gall-bladder was remedied at the same time. This patient's convalescence was uneventful.

In the fourth case, the patient complained chiefly of female trouble, namely, attacks of pelvic pain on either side which required rest in bed for several days at a time. Examination showed a small mass in the left iliac fossa, and a deformity of the vagina and uterus. At operation a pyonephrotic left kidney was found. The ureter was about three inches long and there were three renal arteries, all coming from the common iliac. The kidney was removed. Convalescence was satisfactory except for a phlebitis in one of the saphenous veins.

In the fifth case, the complaint was kidney trouble. Bacilli of tuberculosis had previously been found in the urine and a diagnosis of tuberculosis of the right kidney was made. At operation the kidney was definitely tuberculous, and was situated in the right iliac fossa. The blood supply came from three large vessels from the lower aorta.

In the sixth case, the complaint was of frequent and painful micturition, and a cystocele. The cystosopic examination showed a pyonephrosis on

the right side. The combined functional test was only 35 per cent in two hours. At operation a small kidney was found lying in the pelvis, with a hydronephrosis and some infection. The ureteropelvic juncture was a definite stricture which was incised and a plastic operation done. The convalescence was satisfactory.

In the seventh case, the chief complaint was left lower abdominal pain. The physical examination was negative, with the exception of tenderness in this region. Obstruction was encountered 10 centimeters up the left ureter and a pyelogram showed that the left kidney was lying in the pelvis, and that the pelvis of the kidney and the calyces were dilated. The arterial and venous blood supply was characteristic of an ectopic kidney. A nephrectomy was done and the patient made a good recovery.

In the eighth case, the patient complained of a combined urinary and fæcal fistula in the left inguinal region. The fistula had persisted since an operation for the drainage of a large abscess in this region some weeks previously. Soon after drainage was established, stones, urine, and fæces began to discharge. Examination revealed an obstruction of the ureter, and X-ray examination showed multiple stones in the pelvis and calyces of a pelvic kidney. Two subcapsular operations were performed; the infected kidney tissues and a large number of stones were removed.

In the ninth case the patient had complained of pain through the pelvis and a left hydronephrotic pelvic kidney was discovered during an exploration. The diseased kidney was removed, and the patient made a good recovery.

In one case an exploration was made which revealed an absence of the right kidney and a congenital malformation of the liver and duodenum. The left kidney was large and was situated in the region of the sacro-iliac joint. Fortunately, the absence of the opposite kidney was discovered before anything had been done to the pelvic kidney.

In four of the series the condition of congenital misplacement of the kidney was discovered during the course of some other operation, and in most instances the position and condition of the kidney probably had nothing to do with the production of the patient's symptoms. In two cases, the kidneys were discovered while an operation was being performed for appendicitis, and in both instances the appendix showed definite inflammation. In view of the fact that the symptoms subsided after the appendix had been removed, the position of the kidney apparently had nothing to do with the symptoms. One of these patients, a young married woman, came for consultation because of repeated miscarriages. The pelvic kidney was thought at first to be an ovarian cyst, but on exploration it was found to be a kidney apparently in good condition. The uterus was lifted up in the pelvis by shortening the ligaments; nothing was done with the kidney. I was unable to get a late report in this case, so do not know whether the condition was remedied. In one case, the pelvic kidney was discovered while an operation was being done for congenital absence of the vagina.

In five cases of the series the malposition of the kidney was discovered in a routine examination by means of a pyelogram. In all of the five cases, the kidney was apparently normal with the exception of its position. In two instances the pelvic kidney was found to be a solitary kidney. In one there was lack of development in other regions, and in one there was a reduplication of the pelvis (Figs. 1–8).

SUMMARY

In conclusion it may be stated that this particular malposition of the kidney occurs rarely. The kidney may functionate in a perfectly normal manner in this position and it may never be discovered or if discovered it will not require treatment. The condition is of interest when the kidney becomes involved in some pathologic process such as hydronephrosis, pyonephrosis, or tuberculosis. Under these conditions the location of the kidney may be misleading in the diagnosis, which, however, can accurately be made by a careful examination of the bladder, meatus, and kidney by means of the cystoscope, the ureteral catheter, and the pyelogram. After the diagnosis has been established, the treatment is the same as for a pathologic condition of a kidney in its normal location.

REFERENCES

1. Dorland, W. A. N. A consideration of renal anomalies; with the presentation of two unique cases. Surg., Gynec. & Obst., 1911, xiii, 303–319.
2. Gerard, C. Les anomalies congénitales du rein chez l'homme; essai de classification d'après 527 cas. J. d'anat. et physiol., Par., 1905, xli, 241; 411.
3. Guizzetti, P., and Pariset, F. Beziehungen zwischen Missbildungen der nieren und der Geschlechtsorgane. Arch. f. path. Anat., etc., Berl., 1911, cciv, 372–392.
4. Naumann, H. Ueber die Haeufigkeit der Bildungsanomalien der Nieren. Kiel: Peters, 1897, 53 pp.
5. Plummer, S. C. Dystopic kidney. Surg., Gynec. & Obst., 1913, xvi, 1–14.
6. Straeter, M. Beitraege zur Pathologie und Therapie der kongenitalen Nierendystopie. Deutsche. Ztschr. f. Chir., 1906, lxxxiii, 55–103.

OPERATIVE TREATMENT OF UNDESCENDED OR MAL-DESCENDED TESTIS WITH ESPECIAL REFERENCE TO END-RESULTS

A Report of 415 Cases[1]

By WILLIAM B. COLEY, M.D., F.A.C.S., New York
Attending Surgeon to the Memorial Hospital and the Hospital for Ruptured and Crippled

IN the Out-patient Department of the Hospital for Ruptured and Crippled, from 1890 to 1918, there have been observed 80,736 cases of inguinal hernia in the male, of which 1,357 or 1.68 per cent were associated with undescended or mal-descended testis. From 1890 to 1918, 4,453 cases of inguinal hernia in the male have been operated upon, of which number 334 or 7.5 per cent were associated with undescended testis.

Of 1,040 cases of hernia in adults operated upon at the Memorial Hospital by Dr. William A. Downes and the writer, 49 or 4.71 per cent were associated with undescended testis.

In a paper read before the New York Surgical Society on April 22, 1908, I reported 126 cases of undescended testis which I personally operated upon, and which had been traced as far as possible to end-results.

While a number of articles have been written upon the subject since that date, there is still more or less doubt in the mind of the medical profession as to the indications for surgical treatment and still a wide difference of opinion as to the best method of operation. Even at the present time, no large statistics exist in which the end-results of operative treatment have been given, and the present paper has been written chiefly with the hope that some further light may be thrown upon the question as to the condition of patients with undescended testis many years after operation.

In my earlier paper I dwelt with considerable detail upon the various theories as to the causative factors connected with the development of the undescended or mal-descended testis, and described the various types of undescended or mal-descended testis usually observed.

As regards the etiology of the condition, the theory that a mechanical obstruction of some sort due to inflammation, adhesions formed during fœtal life is the principal cause, has been strongly advocated by Buedinger and has found many adherents. Buedinger operated upon 24 cases of undescended testis of the inguinal variety, and states that he found mechanical obstruction of some sort in 15 of these 24 cases.

As I stated in my former paper, Odiorne and Simmons, of Boston, have made an important contribution to our knowledge of the pathology of the undescended testis in their paper published in the *Annals of Surgery*, December, 1904. They found a marked tendency to thickening of the tunica albuginea in nearly all of the specimens examined and an increased amount of interlobular connective tissue.

More recently, Uffreduzzi,[2] of Carle's Clinic in Turin, has made perhaps the most exhaustive study of the pathology of the retained testicle that has yet been published.

His observations upon the etiology of the undescended testis are of special interest. He states that the explanations offered by many of the earlier writers are exceedingly naive, in that these writers frequently confound the cause of the anomaly with its result. Kocher explained the incomplete descent of the testis as well as the atrophy of the gland by an inflammatory process during intrauterine life, but was unable to support his hypothesis by objective findings. The theory that the non-descent of the testis is dependent upon mechanical obstruction due to peritoneal adhesions occurring during fœtal life, was originally advanced by Cloquet and Wrisberg, and later strongly advocated by Buedinger and supported, he believed, by numerous necroscopic and operative findings. Buedinger goes so far as to state that in his opinion mechanical obstruction caused by such ad-

[2] Arch. f. klin. Chir., c, No. 4, and ci, No. 1.

[1] Read before the Southern Surgical Association, Baltimore, December 17–19, 1918.

hesions accounts for retention of the testicle in 96 to 97 per cent of the cases and that the instances in which a congenital origin of retention is apparent, will amount to not more than 2 to 3 per cent.

Uffreduzzi disagrees entirely with Buedinger's conclusion, and in regard to the great frequency of such cicatrices, he states that no other investigator has found them in any such proportion as Buedinger. Lanz stated that he found no such cicatrices in any of his 51 cases, nor did Uffreduzzi himself observe a single such case.

My own observations based upon our experience at the Hospital for Ruptured and Crippled, and other hospitals, are in accord with Uffreduzzi. I have found no evidence of old adhesions. Uffreduzzi lays far more stress upon the element of heredity as a cause of ectopia, a theory first advanced in the classical paper of Godard's. The latter states that the descent of the testicle as it takes place in man is nothing but an example of the phylogenetic migration as it gradually takes place in zoological evolution. Hence, some authors consider retention of the testicle a simple continuation of a condition that is normal in certain animals, and that a retained testicle must be looked upon as a sign of arrested development.

I have personally operated upon a boy of thirteen years with double abdominal ectopia, who has a younger brother of 12, also with abdominal ectopia.

Uffreduzzi states that in the great majority of cases of ectopic testicle there are other signs of degeneration. In 24 cases examined by himself, he invariably found a greater or less number of distinct anomalies, physical as well as mental. In one case bilateral cryptorchism was associated with true hermaphroditism. This extremely rare form of hermaphroditism, of which only two other cases are recorded in the literature, represents one of the most serious forms of degeneracy known.

On basis of his investigations, Uffreduzzi concludes that retention of the testicle is hardly ever an isolated fact, but merely a local expression of infantilism, i.e., of a serious retardation in the development of the entire individual, which may be more or less pronounced and is nearly always accompanied by other bodily or mental abnormalities.

Uffreduzzi has made an exhaustive study of the literature with reference to developmental anomalies of this kind in idiots and mentions Bournville and Sollier's statistic, comprising 758 cases of idiots which show such anomalies as phimosis, hypospadias, atrophy, retention of the testicle, various malformation of the penis, in a considerable number of cases.

Kneckt's statistic, covering 379 individuals belonging to this group, shows: phimosis 51 times; bilateral retention of testicle 11 times; atrophy of the testicle 18 times; epispadias twice, hypospadias 5 times; varicocele 12 times.

Uffreduzzi's own examinations made at Morro's Institute for Insane, covering 100 cases, show 47 simple epileptics; 7 epileptic idiots; 12 cretins; 14 phrenosthenics. In 18 of these 100 cases he found an ectopic testicle (6 bilateral and 12 unilateral).

Personally I believe that Uffreduzzi goes somewhat too far in his claim that in the great majority of cases of ectopic testicle there are other signs of degeneration. I believe a study of the statistics will show that while these various types of abnormal mental development have associated with them a large proportion of undescended or mal-descended testis, it does not necessarily follow that the reverse is true. Such a statement as Uffreduzzi's should be based upon evidence obtained from a very large number of cases of undescended testis. Our own observations at the Hospital for Ruptured and Crippled based upon 1,357 cases of undescended testis show that marked signs of physical or mental abnormalities are only associated with double undescended testis, and in but a moderate proportion of these. As regards the unilateral, undescended or maldescended testis we have found no evidence showing that this is usually or frequently associated with other abnormalities.

As regards the pathology of the undescended testis, owing to the fact that we have from the beginning, strongly advocated attempting to save the undescended testicle and not to sacrifice it, we have had very little material

for pathological investigation. Uffreduzzi states that the structure of the retained testicle varies greatly in the individual cases. The principal changes that are nearly always found are thickening of the tunica albuginea, and of the basement membrane of the tubules, and a great increase in interstitial cells. The epithelial lining of the tubules also shows very marked changes, the epithelial cells being few in number and more or less degenerated and irregular in shape.

In a chapter on the pathology of the retained testicle, Uffreduzzi discusses the various complications that are apt to accompany the condition of ectopic testicle and which, in order to differentiate them from the congenital complications, he designates as secondary or acquired. Among these are: pain and nervous disturbances; specific or chronic inflammation; gangrene and incarceration of the testicle; torsion of the cord in a series of 80 cases of torsion of the cord collected by Uffreduzzi, a retained testicle was found in 60 per cent).

The most common complication of undescended testicle is hernia of the congenital type, although in rare cases, it may be acquired. In all but two or three cases we have found a potential or actual hernia of congenital origin. Further complications are hydrocele of the cord and neoplasms.

That the retained testicle frequently becomes the seat of tumors, was first claimed by Lecomte, in 1851, and has since been confirmed by many others.

In my former paper[1] on the "Treatment of the Undescended or Mal-descended Testis," I stated that there was considerable difference of opinion in regard to the question of whether the undescended testis predisposes to malignant degeneration, and cited the various views pro and con. McAdam Eccles in his Jacksonian Prize Essay, 1903, stated that he had made an examination of 48,000 males with hernia at the London Truss Society, and found 2 per cent or 854 cases with undescended or mal-descended testes. Yet, in this entire series there was not a single case of sarcoma observed. He further stated that of 40 cases of sarcoma of the testis observed in one of the large London Hospitals during a period of 20 years, there was only one case of sarcoma of the undescended testis. From this fact he concludes that the generally accepted opinion that malignant disease is more common in the undescended than the normal testis, is not well founded. For many years I was inclined to agree with Eccles' opinion but further observations convinced me that it was wrong.

In my paper upon "Cancer of the Testis" with a report of 64 cases, read before the Southern Surgical and Gynecological Association, December 15, 1914, I stated that in 12 cases the sarcoma or malignant disease was associated with an undescended testis, and discussed the question of the relative frequency at considerable length. Different writers give different opinions as to the relative frequency of cancer of the normally descended and mal-descended testis. Odiorne and Simmons, in a review of 54 cases of malignant disease of the testicle observed at the Massachusetts General Hospital, found 6 or 11 per cent in which the disease occurred in the undescended testis; of these four were in the abdominal cavity and two in the inguinal canal. Rademacher gives the proportion of malignant abdominal to malignant inguinal testicle as 1 to 8. Meiser found 64 malignant inguinal against 4 abdominal testis. Bulkley, however, at the Presbyterian Hospital, found 2 cases of malignant abdominal to 12 cases of malignant inguinal testis. An analysis of the cases observed by Chevassu, Odiorne and Simmons and the Presbyterian Hospital records, show the proportion as 1 to 5. My own statistics show almost the same proportion, viz., 12 undescended testis in a total of 64 cases of sarcoma of the testis, or about 1 to 5½.

If sarcoma of the testis shows a relative proportion of incidence of 1 in the undescended testis to 5½ or even 8 in the testis in the scrotum, we have only to show that the relative proportion of undescended testis to normally placed testis is about 1 in 50 to prove that the abnormally placed testis is more prone to malignant disease than the normally placed.

With regard to the functional value of the undescended testicle, there is still a wide

[1] Ann. Surg., Phila., 1908, Sept.

difference of opinion, some writers going so far as to state that it has no functional value whatever and for that reason advocate its removal. Uffreduzzi believes that a considerable number of undescended testes, 10 per cent; retain the power of reproduction. While the data at present is insufficient to enable one to express a positive opinion it is probable that Uffreduzzi's estimate is not far from correct. Aside from any functional value that the testis may possess there is another strong ground for preserving it, particularly in children, and that is for the reason that the interstitial cells, which are always present have an important influence in developing the male characteristics of the child.

From January 1, 1890, to January 1, 1918, there have been operated upon at the Hospital for Ruptured and Crippled 334 cases of undescended testis, and since that time 31 additional cases (of these cases, 200 were operated upon by the writer personally, and the remainder by William T. Bull, John B. Walker, William A. Downes, J. P. Hoguet and the assistant surgeons); adding to these 50 cases operated upon at the Memorial Hospital we have a total of 415 cases of undescended testis. A most careful attempt has been made to trace these to final results.

In 49 cases the testis was found in the vicinity of the external ring just above the pubic bone; in 17 cases it was found in the upper scrotum; in 4 cases in the mid-scrotum, and in 16 cases it was impossible to locate it in any position (probably it had retracted in the abdominal cavity or had become too atrophied for palpation).

Age, as far as known, of patients operated upon for undescended testis.

	Cases
Under 5 years	33
5 to 10 years	160
10 to 15 years	133
15 to 20 years	29
20 to 30 years	16
30 to 40 years	7
40 to 50 years	5
Over 50 years	1
Total	384

The different varieties of ectopia or malposition of the testis are associated with slightly different types of sac, or variations in the size and location of the vaginal peritoneum.

The most common type of ectopia is that in which the testis occupies a position in the inguinal canal, between the internal and the external ring. An interesting point in connection with this form of ectopia is that while the testis never goes beyond the external ring the tunica vaginalis may extend down beyond the external ring even beyond the bottom of the scrotum. In certain cases this pouch passes beneath the deep fascia and finds its way down into the perineum, and in some still more rare cases, it passes down into the thigh.

The next most common type of ectopia is that known as "inguino-superficial" in which the vaginal process passes out of the external ring then turns directly backward and upward and extends 2 to 3 inches toward the anterior superior spine. In these cases the testis usually occupies the distal portion of the sac and rests on the outer surface of the aponeurosis directly beneath the skin and superficial fascia.

It is evident that a diagnosis should be made in these cases before operation, otherwise in cutting down to the aponeurosis, the first landmark of the incision for Bassini's operation, one would first pass through the testis before reaching the aponeurosis. The testis can be so easily felt in this superficial condition that a diagnosis should practically without exception be made.

This type, which was a few years ago regarded as extremely rare is comparatively common, seventy-seven cases having been observed in the statistics which have been kept at the Hospital for Ruptured and Crippled.

Another type is the inguino-perineal in which the vaginal process for some unknown reason, instead of entering the scrotum passes beneath the deep fascia and extends into the peritoneum for a varying distance sometimes reaching nearly to the anus. I have observed 8 cases. In these cases the cord is usually normal in length and by making a new pouch in the scrotum the testis and cord can easily be transplanted in the scrotum without any tendency to retraction. In

some of these cases the testis is normal in size and in other cases it is atrophied.

In a considerable number of cases a bilocular sac has been found in which the testis occupies the upper loculus which lies between the inner and external oblique muscle, the lower portion of which extends into the scrotum. In a smaller number of cases I have observed a bilocular sac, in which the upper portion assumes the inguino-superficial variety resting upon the aponeurosis beneath the skin and superficial fascia, and the lower loculus, extending down into the scrotum. In these cases the testis usually occupies the upper loculus.

Operative procedure. The method employed at the Hospital for Ruptured and Crippled since 1890 has been practically the Bassini operation without transplantation of the cord, namely: Bassini's incision, freely opening the aponeurosis of the external oblique well beyond the internal ring, surrounding the cord and hernial sac, which latter has always been found present with only two exceptions. Then the lower portion of the tunica vaginalis is grasped by an artery clamp and by traction the testicle is brought down as far as possible. The next step is separation of the sac from the cord, high up, just outside the internal ring. In children this requires very careful and delicate dissection with thumb forceps as the cord is usually greatly enlarged and spreads out in a fan-like manner over an area of the sac one inch in width. If the dissection has been begun at the right layer, the sac can be easily isolated and is then tied off as high as possible. In most cases of inguinal and in many cases of the abdominal ectopia the cord can be freed sufficiently to permit the testicle to be brought at least into the upper portion of the scrotum, in most cases into the lower part, with the sacrifice of but few, if any, of the veins. Except in a very few of the early cases, I have never made any attempt to anchor the testis in the scrotum, but rely upon careful freeing of the cord high up and the removal of all fascial bands. Suturing of the testicle within the scrotum is, in my opinion, of little value. If there is any tension, the scrotum is retracted up toward the external ring. The canal is then closed by the modified Bassini method, without the transplantation of the cord. The cord is brought out at the lower end of the wound. The internal oblique is then sutured to Poupart's ligament over the cord. Great care is taken in placing the lowermost suture, which should include the reflected portion of the external oblique as well as the conjoined tendon and Poupart's ligament on the other side. This suture, when tied, makes but a very small external ring, too small ever to permit the testis to retract into the canal, even should it reach the ring.

In cases in which it is found difficult to get the testis into the scrotum, and this is particularly true in the abdominal variety of ectopia, the admirable procedure advocated by Bevan, has been found of great value. In these cases we may remove not only the fascial bands, but practically all the veins and vessels, with exception of the vas and the spermatic artery.

Another excellent feature of Bevan's technique described in the *Journal of the American Medical Association*, 1903, is a purse-string suture in the region of the external ring, including the superficial and deep fascia, which not only prevents the testicle from entering the canal, but also from passing up on top of the aponeurosis.

Brief notes regarding patients traced from 10 to 20 years:

One patient, 15 years old, traced 19 years, testis in good position.

One patient, 13 years old, traced 20 years, testis atrophied and retracted to external ring.

One patient, 12 years old, traced 19 years, testis normal; patient married and has two children.

One patient, 10 years old, traced 14 years, testis found in normal condition.

One patient, 6 years old, traced 13 years, testis not felt.

One patient, 12 years old, traced 11 years, testis just below external ring.

One patient, 11 years old, traced 11 years, testis not down.

One patient, 11 years old, traced 11 years, testis not felt.

One patient, 10 years old, traced 12 years, testis normal in size and position.

One patient, 14 years old, traced 12 years, testis found in inguinal region superficial to aponeurosis.

One patient, 10 years old, traced 12 years, testis atrophied and situated at the spine of the pubis.

One patient, 12 years old, traced 10 years, position of testis not stated.

One patient, 7 years old, traced 11 years. testis atrophied, lying on top of external oblique.

One patient, 10 years old, traced 10 years. The testis was situated well down in scrotum and was half the normal size.

One patient, 18 years old, traced 10 years—double one side in scrotum ⅗ normal size—other side not felt.

Cases traced from 5 to 10 years.

One, 5 years old, traced 7 years, testis atrophied, outside of external ring.

One, 9 years old, traced 8 years, testis normal size, at bottom of scrotum.

One, 11 years old, traced 6 years, testis just without external ring.

One, 4 years old, traced 5 years, position of testis not stated.

One, 11 years old, traced 8 years, testis down and normal in size.

One, 5 years old, traced 6 years, position of testis not stated.

Double inguino-superficial, 10 years old, traced 5 years, position of testis not stated.

Boy, 8 years, inguino-superficial, traced and well 5 years, position of testis not stated.

Double, 11 years old, traced and well 8 years, size of testes not stated, right in scrotum; left in mid-scrotum.

Double inguino-superficial, boy 12 years old, traced 9 years, position and size of testes not stated.

Boy of 4, traced 5 years, position of testis not stated.

Boy of 14, inguino-superficial, traced and well 9 years, position of testis not stated.

Boy of 7, traced 9 years, testis can be easily pulled down into bottom of scrotum.

Boy of 14, double, traced 7 years, right testis, inguinal left, abdominal type, position of testes not stated.

Boy of 13, properitoneal, traced 7 years, testis outside of external ring, freely movable.

Boy of 6, traced 6 years, testis small, at bottom of scrotum.

Boy of 11, traced 6 years, testis half normal size, position external ring.

Boy of 4½, traced 8 years, testis not felt.

Boy of 8, traced 8 years, testis just above external ring.

Boy of 5, traced 5 years, testis at external ring.

Boy of 11, traced 5 years, both testes in bottom of scrotum.

Boy of 14, traced 5 years, position of testis not stated.

Boy of 13, double inguino-superficial, traced 5 years, both testes in scrotum and freely movable.

Boy of 10, traced 3 years, position of testis not stated.

Boy of 9, traced 5 years, position of testis not stated.

Final results in the cases observed at the Hospital for Ruptured and Crippled:

Traced and Well	Number of Cases
More than 20 years	1
From 10 to 20 years	16
From 5 to 10 years	41
From 2 to 5 years	60
From 1 to 2 years	31
From 6 months to 1 year	21
Less than 6 months	15
Not traced	149
Total	334

In the cases of adults as far as results are known, the testis has shown a greater tendency to remain in the scrotum than in children. The most important end-result in an adult is that in the case of W. N. male, who had double undescended testes 30 years, who was operated upon in 1895 on the left side by Dr. Schoonmaker, of Yonkers, and in 1910 on the right side by myself, at the Memorial Hospital. He was married in 1902 and had a child born in April, 1903.

This case is of particular interest, inasmuch as it is the second case that I have been able to find recorded in which a patient suffering from double undescended testes has become a father.

Another interesting case:

W. G., 37 years old, was operated upon 23 years ago for a right undescended testis. I had an opportunity of examining this patient on December 11, 1918, and found the testis absolutely in the bottom of the scrotum. It was normal in size and felt just a little less firm in consistence that the opposite testis. The patient was married two years ago and up to the present time has had no children. In this case, I think, the longest period has elapsed since the operation (23) years.

CONCLUSIONS

A careful study of our cases, together with the literature of the subject, has led to the following conclusions:

1. That in most cases of undescended or mal-descended testis, the etiology points to a congenital origin, often influenced by the element of heredity and frequently associated — particularly in the double variety — with other developmental defects.

2. The atrophy usually found in the undescended or mal-descended testis is not the

result of the mal-position. The change in structure and the atrophy are merely coincident, being due to congenital causes.

3. The question of the functional value of the undescended testis, cannot be definitely answered in an individual case. It may be stated, however, as a general rule that an undescended or mal-descended testis, with which there is associated a marked atrophy, has little or no functional value. However, I believe with Uffreduzzi that in a considerable number of cases of undescended testis, spermatogenesis is retained.

4. The ectopic testicle is practically always associated with an open vaginal process of peritoneum; i. e., there is usually present a potential hernia. This vaginal process is almost invariably a congenital affair, for the reason that its position is entirely independent of the location of the testis.

5. Torsion of the cord is more frequently observed in the undescended testis than in the normal testis.

6. The undescended testis shows a greater tendency than the normal testis to malignant degeneration.

7. Operation should be advocated in children who have reached the age of 8 or 10 years, for the following reasons: (a) Operation permits the radical cure of the hernia with which the undescended testis is practically always associated and which often cannot be controlled with a truss without causing pain and irritation to the testis. (b) By bringing the testis down into the scrotum before the age of puberty, there is a possibility of causing further and more normal development of the testis.

8. Operation in adults or children over the age of 14 should be even more strongly urged. for the following reasons: (a) In order to cure the accompanying hernia, as has already been stated; (b) in order to place the testis in a position in which it is much less subject to trauma; (c) in order to lessen the chances of malignant degeneration.

9. The end-results in our series show that it is possible to cure the hernia in practically all cases. Unfortunately, in only a comparatively small number of cases did we find the testis occupying the bottom of the scrotum in the cases observed, several years after operation. The atrophied testicle is generally found to have retracted to mid-scrotum or in the region of the external ring and in a position somewhat less liable to trauma than before operation. The result accomplished by the operation, the cure of the accompanying hernia, would seem to justify advocating operation for the undescended testis in adults.

10. The question of whether the traumatism incident to the operation on the undescended testis might not favor the development of malignant disease, is one that should be considered — however at present it cannot be answered definitely. It should be noted that in none of the series of cases operated upon at the Hospital for Ruptured and Crippled during the past twenty-nine years has malignant disease been known to develop; however I have personally observed one case of sarcoma of the testis in which the disease was either present at the time or developed shortly after the operation for undescended testis; possibly it had already started at the time the operation was performed. (The operation was performed by another surgeon.)

These conclusions differ slightly from the conclusions of my earlier paper. In that paper I stated that the undescended testis is almost invariably of little or no functional value. I believe this statement is somewhat too strong and should be modified to the extent that the undescended testis is probably of functional value in not more than 10 per cent of the cases.

I still believe that the undescended testis should never be sacrificed in children and that the practice which obtains in some of our hospitals, of removing the undescended testis in a large number or even in the majority of cases, is greatly to be deprecated. Even if the testis be of little functional value, it nevertheless is of great value in developing the male characteristics in the child and promoting general health. In the adult it should likewise be retained for its influence upon the mentality and for the moral effect if for no other reason.

As regards the age for operation, I still believe that operation is seldom indicated

under the age of 8 years. If the hernia is so slight as to be of little or no importance, it is better to wait until the child is 10 to 12 years old before operating.

I still believe that abdominal ectopia, unless double, had best be left untreated, inasmuch as the operation is a difficult one and by no means free from risk.

In children, however, I would never allow a case of double undescended testes to reach the age of puberty. In these cases it is safer to do the operation in two stages, operating on one side at a time.

It is interesting to note that there has been no death in this entire series of 415 operations.

PROSTATECTOMY, WITH ITS PREPARATORY AND POSTOPERATIVE TREATMENT[1]

By BRANSFORD LEWIS, M.D., B.Sc., F.A.C.S., St. Louis

If one would do satisfactory and *successful* prostatic surgery, he should give close and searching attention to three phases of treatment, namely: (1) preparatory, (2) operative, and (3) postoperative.

The first of these is by some esteemed too lightly, leading to disaster in individual instances that might assuredly be avoided. Strong convictions on this point inspire serious questioning, for instance, of the propriety of operators making rapid-transit trips into the country, operating and returning home on the same day, without knowing any of the elements of diagnosis or providing any of the various conditions deemed essential to success by practically all of the leaders in this work of the present day. The wonder is that any success can be attained by the use of such precipitate and impolitic methods. In the writer's opinion this is unpreparedness to the degree that seriously prejudices the chances of the patient and brings discredit on a special line of surgery that, under proper and conservative conditions, works wonders for a very miserable portion of humanity.

The most experienced operator cannot always tell, on the first interview with a patient, as to whether an operation will be necessary or even advisable. Many patients with marked prostatic obstruction and in serious condition of health may be brought to permanent recovery without any operation; and it requires definite study and observation over a number of days, sometimes, to bring these to recognition.

In many others — indeed, in a very large proportion of them — even if operation be advisable or necessary, preliminary drainage through the retained urethral catheter is of the utmost importance, converting a critical situation into a satisfactory and safe one; or supplanting agony with quiet and comfort, preliminary to operation.

These considerations are vital in their bearing on final success, but are necessarily ignored when the rapid-transit plans alluded to are adopted.

PREPARATORY TREATMENT

Besides information on the physical condition and functional activity of the heart, kidneys, and alimentary tract required in all such cases prior to undertaking operation, accurate estimates should be made on the following in particular:

1. Hæmoglobin percentage.
2. Cell count.
3. Blood pressure.
4. Phthalein output of the kidneys.
5. Urine quantity and amount of solids in 24 hours.

Gross deviations from the normal in these should be corrected or improved before operating. Fortunately this is possible in practically all cases, through the various measures of drainage, heart-toning and alimentary regu-

[1] Read before the Southern Surgical Association, Baltimore, December 18, 1918.

lation now generally utilized. Proctoclysis, drop method, of 5 per cent sodium bicarbonate solution, six hours daily, proves of wonderful efficacy in restoring the functions of a dilapidated old man, undermined by urinary obstruction, retention, infection, pain, recurrent chills and fever. But *efficient drainage* is the *sine qua non* of all requirements, before, during, or after operation. Interrupted catheterization in no sense fulfills the demands in urgent cases. It occasions much suffering each time it is used, in the badly inflamed cases; and is often attended with steadily increasing difficulty of introduction, all of which is done away with by binding the catheter in the urethra with string and a few pieces of adhesive plaster judiciously applied. Nothing gives such immediate comfort as this, in many instances; and once attained such drainage can be continued until the critical situation is over and all things are favorable, or as nearly so as they may be made for the operation. It gives opportunity for daily irrigations, whose effects may be both soothing and antiseptic. In a particularly difficult and complicated case of 70 years of age the writer kept a catheter in the urethra for nine months before bringing the patient to a condition appropriate for operation; after which the operation was done with success and prompt recovery.

Hæmoglobin above 60 per cent is favorable; 50 per cent is questionable; 40 per cent unfavorable; 30 per cent fatal, in connection with prostatectomy.

While the phthalein output should be above 30 per cent for two hours to present a promising outlook, I believe the requirements are not so rigid as with the hæmoglobin percentage; and that patients can be carried through to success, in the face of very low phthalein percentage, if all precautions are taken in regard to preparation, anæsthesia, and postoperative care. At least, we have had such experiences. Low phthalein returns do not lead us to abandon operation but impel us to adopt all the different measures of safety and conservatism that have been instrumental in lowering the death rate of prostatectomy of late years.

A peculiar fact pertaining to some cases of chronic prostatic obstruction, apparently in fair general condition, is that they are really on the verge of a renal break down, ready to be toppled over into urinary suppression and death by any untoward or unusual circumstance. This portentous condition (impending acidosis) is often to be detected not so much by the quantity of urine passed in 24 hours as by the quality: An enormous quantity of clear, limpid urine is poured out, but of low specific gravity (1.003–1.005) and lacking in solids and urea-content. Acetones may be present. Beware of such cases, and install the therapeutic measures with the utmost caution from every standpoint. Activity or inactivity is liable to be equally disastrous. The patient has simply postponed the definite effort at recovery for too long a time. He has reached a dangerous state and doesn't for a moment suspect it. I have seen such patients dead in two or three days from the time of the upset, and without any operation being undertaken or any serious measures being adopted. Suppression of urine, uræmia, acidosis, whatever the terms applied, the outcome is death, and represents the fallacy and danger of procrastination.

CHOICE OF OPERATION

Without going into a discussion of the merits and demerits of the two methods of removal of the prostate, suprapubic and perineal, the writer after a considerable experience with both has adopted the suprapubic method as the one of choice *because it gives the better results*. It is free from a number of momentous objections that unavoidably pertain to the perineal operation, such as ineffectual urinary control, sexual disability, urethrorectal fistula, etc.

One or two stage operation. While a one-stage suprapubic prostatectomy may with confidence and safety be carried out in a patient of middle age and good general condition, there is no doubt about the marked and distinct advantages presented by the same operation done in two stages in the decrepit patient of advanced years and weakened resisting powers. The opportunity presented by the two-stage operation of establishing a firm adhesion between

bladder and abdominal walls is scarcely less valuable than that of establishing suprapubic drainage. Infection of the loose connective tissues surrounding the bladder and extensive suppuration in these is one of the most serious dangers attendant on suprapubic work. Once established, such suppuration is difficult of control and the condition may rapidly become formidable. The ounce of prevention consists in attaching the bladder firmly and permanently to the abdominal wall around the opening in the bladder by means of chromatized catgut sutures.

Since adopting this technique, further described below, the writer has had no semblance of deep spreading infection in any case. Its protecting influence was markedly shown in a recent case in which through inadvertent deviation from the prescribed technique an infection of the suprapubic wound occurred; but this infection did not spread beneath the muscles or in the cellular tissue about the bladder because of the close and firm attachment between the bladder and abdominal wall which had been provided.

Because of these considerations and their bearing on events *subsequent* to the operation, the author deems exactitude of technique logically carried out as well worth while, even though the steps may seem more formidable than the ones of former days for getting into the bladder. It is easy enough to get into a bladder; but getting out again with a healed wound and a recovered patient — that is the question for our consideration.

CHOICE OF ANÆSTHESIA

If the patient be vigorous in health and condition, ether may be given with impunity, but if very old, debilitated or septic, it may not be justifiable to deprive him of the well-defined advantages presented by local anæsthesia for the first stage, and a very transient gas or ether anæsthesia, or preferably, caudal (sacral) anæsthesia, for the second. This plan is practically free from shock in all cases; and there is seldom disturbance of the alimentary tract.

Spinal anæsthesia is commended as serviceable by some operators, but the writer views it as the most dangerous of all methods of anæsthesia. His personal acquaintance with some seven or eight instances in which death was attributable directly to spinal anæsthesia used by operators well versed in its technique has led him to this conclusion. He knows of no death so far reported from the use of caudal anæsthesia, although there have been instances in which physiological effects have been observed.

SUPPORTIVE MEDICATION

Very many cases demand the supporting influence of digitalis preliminary to operation, of diuretics and the free ingestion of fluids, water, milk, buttermilk, and possibly pituitrin hypodermatically to arouse alimentary activity. A laxative effect is preferable to too much purging before operation.

OPERATIVE TECHNIQUE—TWO-STAGE OPERATION

First stage, local anæsthesia. Light nourishment is not objectionable previous to transferring the patient to the operating room.

1. A hypodermic of ¼ grain morphine, 1/150 grain atropine is given 15 minutes prior to operation.

2. The bladder is given a final irrigation with warm boric acid solution, and the catheter retained in the urethra by means of a small strip of adhesive running from the penis to the catheter. Six or 8 ounces are left in the bladder. Iodine is applied to the skin.

3. Using procaine and potassium sulphate solution (2 per cent each, equal quantities), a linear area is injected about 3 to 4 inches in length in the midline of the skin above the symphisis pubis (Schleich method). An incision is immediately made through this line down to the rectus muscles, which are separated in the midline by the fingers and the scalpel handle. The injections of anæsthetic fluid are repeated as often as may be necessary to avoid pain and apprehension on the part of the patient. It is unnecessary to cause pain in this procedure.

4. When not objectionable from the standpoint of obesity, difficult respiration, cardiac, renal or arterial complications, the patient is now placed in a moderated Trendelenburg position. It is probable that the Trendelen-

burg posture is not as innocuous as it is generally considered to be, so that its duration should be shortened as much as possible. It is desirable to have the dome of the bladder project well up into the wound. This may be effected by adding, if necessary, a few ounces of fluid to the contents of the bladder, through the catheter which still lies in the urethra.

At the bottom of the wound and still covering the bladder are the loose prevesical tissues and the lowermost fold of the peritoneum, so merged together that they are not always distinguishable. Not a few good operators have inadvertently cut the peritoneum and have had to take time to stop and sew it up — an unnecessary delay. The writer avoids this by invariably laying aside the knife and using the gauze covered forefingers to separate the tissues, strip up the peritoneum and definitely expose the bladder. The latter is recognizable by its muscular bundles and large veins. Three retractors maintain the exposure: right, left, and upward, the latter with a piece of gauze under it to protect the peritoneum which is pushed well upward.

6. Then, removing one lateral retractor, a chromatized catgut "fixation suture" is placed. It is passed through the fascia and muscle (rectus) of one side, then penetrating the full thickness of the musculature of the bladder, at a point ¾ inch from the midline, it is directed downward for ¾ inch before emerging, passing again through the rectus muscle and fascia of the same side. Another suture is applied similarly on the opposite side, after which a third is applied crosswise above, just below the margin of the peritoneum. These three sutures, when tied later, draw the bladder up squarely against the under surface of the abdominal wall, making a firm agglutination that prevents the burrowing or spreading of infection, that is one of the most serious complications of suprapubic cystotomy. At present the sutures are left untied and are used as anchorages on the bladder wall. The bladder is now emptied by attaching a long rubber tube to the catheter and syphoning the contents into a waste-basin.

This allows the apex of the bladder to sink down into the pelvis, but it is readily brought back and controlled by means of the three fixation sutures.

7. A narrow sharp bistoury is made to puncture the bladder wall (always anticipating with local anæsthesia); the incision is extended above and below sufficiently to provide for the easy introduction of a finger, and, later, of the large Marion drainage tube. By syphoning the fluid out before making the incision a relatively dry operative field is obtained, instead of the sloppy one usually encountered in cystotomy.

8. Through the bladder wound the offending prostate is felt, the catheter is recognized and indicates the exact location of the inner urethral orifice, and the presence or absence of a foreign body is determined. The catheter is then removed, being no longer of use.

9. The Marion tube, containing a perforated stopper, and catheter, is now inserted into the bladder. The three fixation sutures previously placed are tied, drawing the bladder firmly against the abdominal wall, as before described, and obliterating spaces for seepage. The long ends of these sutures may be tied about the Marion tube for anchorage. The remainder of the wound is brought together, the muscle layers with catgut, the skin with silkworm gut. It is often advisable to place a small cigarette drain in the lower angle to drain the prevesical space. Dress and return to bed.

10. For effecting continuous drainage a rubber tube is attached to the Marion tube catheter, intermittent suction being added by means of a Bremerman apparatus or some similar appliance. The patient is made to change position occasionally from his back to either side, and liquids or light nourishment are given from the beginning, there being no shock or alimentary disturbance to deal with.

Any undue amount of pain is controlled with codeine or morphine; and continuation of the proctoclysis, six hours daily, is wonderfully efficient for promoting activity of the kidneys.

Operative interval. From the first to the second stage of the two-stage procedure a

week or two weeks may elapse, according to the condition of the patient and the rapidity of his recuperation from previous disability. Improvement may be noted not only in his daily declarations on the subject, but also in the responses to the several laboratory tests.

Second stage. At the end of this interval when conditions are found satisfactory it is proper to carry out the second stage of the operation, namely, the removal of the prostate.

1. With the patient under gas-ether, or simply ether anæsthesia and again in the semi-Trendelenburg posture if permissible, the Marion tube is removed. Its ample diameter has maintained such a good-sized opening into the bladder that it may be unnecessary again to enlarge the wound except very little at its central portion. The forefinger of the left hand is inserted into the rectum to afford counter-pressure and to elevate the prostate into the wound.

2. If we are dealing with a "small hard prostate" its mucosa may be dense and resistant to the attacking finger, in which case it may be of advantage to use the double cutting blades for slitting the prostatic urethral mucosa, as first suggested by Spitzer, and as modified by the author. This admits the glove-covered finger to the line of cleavage to better advantage in certain cases.

Cleavage is best begun at the prostatic apex on one side, the finger separating and at the same time hooking the offending lobes backward (upward). No objection can be made to the endeavor to bring out the prostate in one or two pieces, although this is not always feasible. A medium sized lobe-forceps held by an assistant and grasping a recalcitrant lobe sometimes gives gratifying service and permits the peeling off of attached mucosa. Every piece of prostatic outgrowth should be removed, including that under the trigone.

3. Some oozing or bleeding may follow the removal of the lobes. It may be controlled in either of several ways: Direct suturing; packing with gauze; or preferably, temporary hot gauze pressure, followed by the placing of a Hagner or Pilcher rubber air-bag, with which continuous pressure is made against the walls of the prostatic cavity for 12 or 24 hours, relaxation being permitted when the risk of bleeding has subsided. If the bleeding should be renewed at a later time it is easy again to inflate the bag and re-establish the pressure. If there is no serious bleeding and the pressure-bag is omitted, the writer is accustomed to place a *retained catheter* in the urethra at this time, adjusting it perfectly by means of a silk suture placed through its eye-end, drawn out of the suprapubic wound and affixed to a strip of adhesive plaster attached to the abdomen. The placing of this catheter at this time is for the purpose of avoiding the necessity of introducing it one or two days later when the various conditions are less favorable. It is highly objectionable to try to pass a rubber catheter through the recently wounded prostatic urethra, the walls of which are raw and very susceptible to infection.

4. The Marion tube is again made to drain the suprapubic wound at least 24 hours, serving for easy removal of clots in case of necessity, and the catheter it contains makes direct connection with the long rubber tube leading into the drainage-bottle. Interrupted suction as before is utilized for inducing good drainage.

5. *Suturing of the wound.* The opening in the bladder is first narrowed by chromic catgut suturing until it hugs the Marion tube snugly. The muscular layers of the wound are brought together with the same material; after which interrupted sutures of silkworm-gut are placed through the skin, one of these being tied round the Marion tube for anchorage. It is considered essential to leave a small cigarette drain in the lower angle of the wound, at least as deep as the prevesical space; to be removed within the first day or two.

AFTER CARE

Renewal of the proctoclysis (of sodium bicarbonate solution 5 per cent) may profitably be instituted on returning the patient to bed. This supports both renal and cardiac activity. Hypodermics of ampoules of pituitrin every 4 hours will have a similar influence

on the intestines, avoiding stagnation and flatulence. These three functions of the kidneys, heart and alimentary tract are of supreme importance in the next three or four days. If they are kept intact there is little likelihood of anything going wrong.

The patient should be encouraged to take fluids as soon as the stomach is settled; and to turn on either side, as well as on the back.

Sedatives are indicated if the patient is in pain or unable to sleep; veronal and trional, 5 grains each, at bed time, for the latter.

The Marion tube having performed its office of protection against clot formation is removed in the first 24 hours, being replaced with a smaller elbow-tube or large catheter; or if conditions seem especially favorable, dependence may be placed for drainage on the catheter that was tied in the urethra after the operation. Closure of the bladder wound may be expedited by tying at this time (second or third postoperative day) the sutures attached to each side of the bladder wound, and left long for that purpose.

Naturally one must use judgment in adopting one course or another, always acting on the safety-first policy with regard to drainage, and possible infection. Without free and adequate drainage complications are sure to arise. To secure this free drainage, some surgeons go to the length of leaving the suprapubic wound wide open and without a tube of any sort, the urine seeping up into thick pads of absorbent cotton that obviously require frequent changing.

This seems to the writer a most miserable and unwholesome plan and as unnecessary as it is unattractive. As a matter of fact, a mild degree of infection nearly always occurs in that portion of the wound through which drainage is maintained; but with the protecting measures fully carried out as described, it is practically never serious and should not retard the closure of the wound, which should occur in from two to three weeks. During this time the urethral catheter is used for continuous drainage. Being already in place, the evils of attempting to introduce it under adverse conditions (through a disorganized prostatic urethra, etc.) are avoided; and its cleansing is easily accomplished by drawing it up through the wound by means of the thread previously mentioned. This gives complete control and without any disturbance. After a week or ten days, when the wound becomes small, the thread is cut off and the catheter is still retained, this time by means of adhesive strips on the penis.

The patient is permitted to sit up in bed about the fourth day after either the first or second stage of operating, but nothing is to be gained in having him get out of bed at this early period, as has been claimed by some operators.

Within 24 hours after operation it is found useful to add one or two grains of calomel, in half grain doses to the pituitrin; followed a few hours later by a mild saline laxative. After this a daily dose of one of the neutral oils is serviceable.

POLYPOSIS OF THE STOMACH[1]

By D. C. BALFOUR, M.D., F.A.C.S., Rochester, Minnesota
From the Mayo Clinic

THE benign tumors of the stomach, fibromata, myomata, and adenomata, because of their relatively low incidence, obscure symptomatology, and unknown etiology have always been of great interest, particularly from a surgical standpoint. It was, then, with considerable satisfaction that we recently added to our collection of benign gastric tumors a perfect specimen of the rarest member of the group, a gastric polyposis. The fact that this is the first time the condition has been found in approximately 69,000 abdominal sections in the clinic, 8,000 of which were for gastric lesions, and that a correct diagnosis was established before operation, is sufficient to make the case most unusual.

Case 250518, a man, aged thirty-one, came to the Clinic November 8, 1918, because of "stomach trouble"; a careful elicitation of the history disclosed relevant facts as follows: In 1910 the patient began to have periods of unexplained loss of appetite; during the following five years this periodic anorexia was a great annoyance. The symptom which finally brought him to the Clinic, pain with an empty stomach, first manifested itself in 1915. For a short time after its onset the pain showed some periodicity, but during the greater part of the three years it has occurred daily. The patient described the pain as a cramp beginning in the right and in the left hypochondrium and radiating toward the midline of the epigastrium; it was not associated with burning or with the usual subjective symptoms of hyperacidity, although it occurred only when the stomach was empty. He further stated that the stomach seemed to empty very rapidly and that the period of freedom from cramps after the ingestion of food had become increasingly shorter. By frequent eating he had kept his distress at a minimum and his nutrition was practically normal. There had been no nausea or vomiting or evidence of gastric bleeding. The patient had been discharged from the army in 1917 on a diagnosis of pulmonary tuberculosis, and after five weeks in a sanitarium, home treatment was maintained until June, 1918.

The physical examination did not disclose any abnormal findings. There were no evidences of pulmonary lesion either clinically or by X-ray, and the Wassermann test was negative. The test-meal showed an absence of free hydrochloric acid and the presence of a considerable quantity of epithelium. This achylia explained in a measure the symptoms of which the patient complained, and considered with the character of the gastric pain and the fact that it had been continuous over a period of almost three years, practically excluded gastric or duodenal ulcer. The only clue which led to preoperative diagnosis, was secured by X-ray examination. The entire pyloric end of the stomach exhibited a diffuse mottled appearance, apparently well demarcated both at the pylorus, and at a line about 4 inches

Fig. 1 (250518). The mottled appearance (dark areas) in the roentgenogram are shadows due to the polypi in the stomach. See specimen Figures 2 and 3.

Fig. 2. Photograph of specimen.

[1] Presented before the Southern Surgical Association, Baltimore, December, 1918.

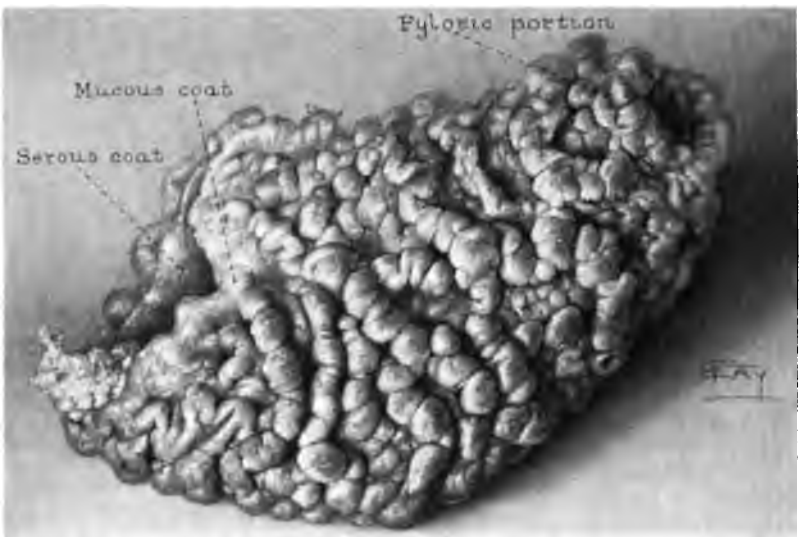

Fig. 3. Drawing of polyposis of the stomach. Stomach turned inside out.

from the pylorus. Dr. Carman, after a re-ray, at which any possibility of complicating factors, such as the patient's having taken food before the examination was excluded, made a diagnosis of gastric polyposis (Fig. 1).

The operation was done November 19 by Dr. Sistrunk. On inspection the stomach was found to be normal in appearance; on palpation, however, a soft, doughy thickening of its wall extending from the pylorus to a line about 5 inches above was immediately evident, and although this did not give the sensation of an actual tumor, the lines of demarcation were quite definite and corresponded with those apparent in the roentgenograph. Resection was carried out along these lines; about two-fifths of the stomach was removed. Continuity was reestablished by the method which we have found most satisfactory, that is, antecolic end (gastric) to side (jejunum) anastomosis. Immediate examination of the tumor showed a most typical example of the condition which has been described as gastric polyposis. Examination of the mucous membrane of the stump of the stomach showed that the polypoid changes did not entirely cease at the line of resection, and that small globular masses were present at various points on the mucous membrane, particularly along the summit of the rugæ, which in turn were very markedly hypertrophied. This finding created some uncertainty as to the ultimate result, but it is not unreasonable to hope that the removal of the greater portion of the diseased tissue will have a curative effect on the isolated tumors that were not removed.

Further study of the resected stomach revealed that it conformed to the type of polyposis which has been described by the French (Menetrier) as *polyadenomes polypeux*. The fresh specimen exhibited no changes except in the mucous membrane. No infiltration of the coats had taken place, and the specimen could readily be turned inside out. The mucous membrane was highly congested and tumors of various sizes were distributed over the entire surface. These tumors were globular and were arranged noticeably in rows in the transverse axis of the stomach; the masses were in close apposition to each other, as is shown in Miss Fry's drawing (Fig. 3). The intervening mucous membrane between the rows showed a few much smaller isolated globular elevations (Fig. 2). The great majority of the elevations were of the size of a hazel nut, and 250 of them could easily be counted; individually they were soft and velvety to the touch, and gave no macroscopic suggestion of malignancy or of destruction of tissue. A section of the gastric wall containing a tumor examined microscopically showed the bulk of the tumor to be composed of a tremendously hypertrophied mucous membrane. No hyperplasia of glandular element was of a character to suggest malignancy. The pathologists believe the condition is not malignant; this

corresponds with the generally accepted view. The patient made a very satisfactory recovery, and returned to his home December 16, 1918.

From a study of this case in conjunction with such cases described in the literature, it would appear that gastric polyposis has sufficient characteristics to be classified as a separate entity and should not be confused with single polyps or papillomatous masses (the latter usually malignant) occasionally found in the stomach, and to which the term gastric polyposis has at times erroneously been applied. No positive etiologic factors are known, and elaborate investigations in our own case, both before and after operation, failed to reveal any clue. It should be emphasized in this instance that the condition would have been quite unsuspected had it not been for the roentgenograph and its interpretation. It is also of interest that in the only other similar case described in this country — that of Myer — a pre-operative X-ray diagnosis was made by Carman. The age of the patient, 31 years, is unique because it is the earliest age at which the condition has been recognized. The accurate and early diagnosis, leading to the correct indications for treatment, is an excellent illustration of the advanced methods of diagnosis available to the clinician of today.

REFERENCES

1. CAMPBELL, A. M. Benign tumors of the stomach. Surg., Gynec. & Obst., 1915, xx, 67-71.
2. CARMAN, R. D., and MILLER, A. The Roentgen Diagnosis of Diseases of the Alimentary Canal. Philadelphia: Saunders, 1917, 241-243.
3. MYER, J. S. Polyposis gastrica (polyadenoma). J. Am. M. Ass., 1913, lxi, 1960-1965; also: Tr. Am. Gastro-Enterol. Ass., 1913, xvi, 113-126.

THE RÔLE OF THE CYSTIC DUCT IN RECURRING CHOLECYSTITIS[1]

BY J. EARL ELSE, M.S., M.D., F.A.C.S., PORTLAND, OREGON
Assistant Professor of Surgery, University of Oregon Medical School; Member of the Staff of the Emanuel Hospital

CLINICALLY the pathologic processes involving the cystic duct which serve as factors in recurring cholecystitis may be divided into, first, those that interfere with the lumen of the duct and thus cause stagnation in the gall-bladder making it a good incubator in which bacteria may grow, and, second, those that harbor infective organisms which may pass up into the gall-bladder with the bile as it flows upward.

Before taking up a discussion of the pathologic processes, it is best to review briefly the anatomy and physiology. The cystic duct is about 3.7 centimeters in length and averages about 3 millimeters in diameter. It leaves the gall-bladder with somewhat of an S-shaped curve and passes downward and inward between the layers of the lesser omentum to unite with the hepatic duct to form the common duct. It has three coats which are from within outward: mucosa, muscularis, and fibrosa.

The mucous membrane is continuous with that of the gall-bladder and like that is lined with columnar epithelium. Mucous glands are found beginning on the surface of the mucosa and extending through into the deeper layers. The glands consist of a straight portion lined with columnar epithelium (Fig. 1) and a coiled portion in which the cells may approach the cuboidal (Fig. 2).

A series of valves known as the valves of Heister are alternately arranged along the entire length of the duct (Fig. 3). The valves are crescentic in shape and extend transversely. At the upper end they are thicker, closer together and project well into the lumen. They gradually diminish in size, become farther apart and irregular in distribution, as the lower end of the duct is approached. In the center of the valves are found connective tissue and muscle fibers. They are covered with mucous membrane like the remainder of the duct

[1] Read before the Surgical Section of the American Medical Association, Chicago, June, 1918.

Fig. 1. Straight portion of mucous gland lined with columnar epithelium.

Fig. 2. Coiled portion of mucous gland lined with cuboidal epithelium.

Fig. 3. Heisterian valves showing more or less hypertrophy.

except mucous glands are not present. Moynihan states that these valves are folds of mucosa, but this is an error, for muscle fibers from the muscularis enter the valves.

The muscular coat is made up of circular, longitudinal and diagonal fibers of which the circular predominate. The amount of muscle is greatest near the gall-bladder, whence it gradually decreases, there being the least near the juncture with the hepatic duct. The circular fibers extend into the heisterian valves as do also the ends of some of the longitudinal fibers so that when the muscle of the duct contracts the folds become erect and are drawn closer together thus interfering with the size of the lumen by narrowing it and also by drawing the valves nearer each other. In pathologically enlarged valves the lumen may be entirely closed by the mere contracting of the longitudinal fibers bringing the valves together. The diagonal fibers do not enter into the formation of the valves.

The fibrous layer is made up of connective tissue loosely connected with that of the lesser omentum.

The function of the cystic duct is not merely that of a tube connecting the gall-bladder with the other ducts, but through the valves and its muscles the flow in and out of the gall-bladder is regulated to a certain extent and through the peristaltic muscular contractions the duct has expulsive power.

PATHOLOGY

Only a brief résumé of the pathology will be given; the lesions will be considered according to the following outline:

I. Obstruction, partial or complete.
   A. Intrinsic or those which lie in the lumen or extend into it.
   B. Intramural or those which involve the wall of the duct.
   C. Extrinsic or those which lie outside of the duct and produce obstruction by pressure or by angulation through pulling the duct out of its normal position.

II. The processes which harbor infection are classified as:
   A. Intrinsic or those in which the organisms grow within the lumen.
   B. Intramural or those processes in which the organisms are harbored within the wall of the duct and thence discharged into the lumen.

I. Obstruction. A. Intrinsic.

1. Foreign bodies. Gall-stones are the most frequent. Plugs of mucus sometimes obstruct although probably not so frequently as was formerly supposed. Worms and echinococcus cysts have been reported as found in the cystic duct.

2. Pathology of the heisterian valves. While undoubtedly other processes occur, up to the present I have observed only three: œdema, acute inflammation, and chronic hyperplasia. The œdema here referred to was a part of a general œdematous condition involving the remainder of the duct as well. The acute inflammation was a part of a general process involving the entire duct and gall-bladder showing nothing characteristic in the valves.

The most important lesion is chronic

Fig. 4. Hypertrophied heisterian valves showing manner in which obstruction is produced.

Fig. 5. Marked hypertrophy of an heisterian valve.

Fig. 6. Villous growth in a cystic duct.

hyperplasia, because it interferes with the lumen of the duct more or less. The hyperplasia may involve all of the valves or only a part of them (Fig. 4). The valves, instead of being narrow, projecting folds, become broad, blunt, projecting masses which may lie so close together that when the circular fibers of the duct contract they are erected and thrown inward so that they may pass while the longitudinal fibers draw them together at their bases until they may nearly or entirely touch, thus producing a partial or complete obstruction. In this manner a biliary colic may be produced that is identical clinically with that produced by gall-stones. Sometimes but a single valve is enlarged in which case the hypertrophy may be more marked (Fig. 5). Occasionally they are larger than the lumen of the duct and as viewed by the microscope are bent upon themselves so as to extend lengthwise of the duct, usually pointing downward. When there is marked hypertrophy, contraction of the circular fibers down upon the valve will completely occlude the duct.

Histologically the hyperplasia is due mainly to connective-tissue increase although sometimes there is hyperplasia of the muscle fibers as well. I have seen dilated mucous glands in some of the enlarged valves although I have never seen glands in normal valves.

3. *Ulcers.* Ulcers are the result of pressure from stones, the action of infective organisms within the duct or the toxin of such organisms and infection within the walls of the duct with sloughing of the infected area into the lumen. Some ulcers show considerable induration. Interference with the lumen comes through induration and muscle spasm.

4. *Carcinoma.* I have never observed a primary carcinoma of the duct.

B. Intramural lesions.

1. *Strictures may be congenital or acquired.* The acquired usually follow injury from gall-stones, the healing of ulcers or intramural infection.

2. *Localized* infection may be due to organisms coming through the blood stream, extension into the mucous glands or by direct extension from within or without.

3. *Cysts* or other *enlargements* of the mucous glands.

4. *Hyperplasia.* (a) Hyperplasia of the muscle is usually the result of a partial obstruction of the cystic or common ducts. (*b*) Connective-tissue hyperplasia is usually preceded and accompanied by a chronic infective process.

5. *Œdema* of the cystic duct may be a part of a general œdematous process, a part of an œdema involving the gall-bladder and ducts or the cystic duct alone, or a portion of it may be involved, in which case it is usually the result of an infection, foreign bodies within the duct or other irritating processes.

6. *Tumors.*

C Extrinsic.

1. Angulations due to adhesions, constricting bands or displacement of the duct.

2. Pressure from tumors, enlarged glands, inflammatory or similar lesions.

II. Processes which harbor infection. A. Intrinsic.

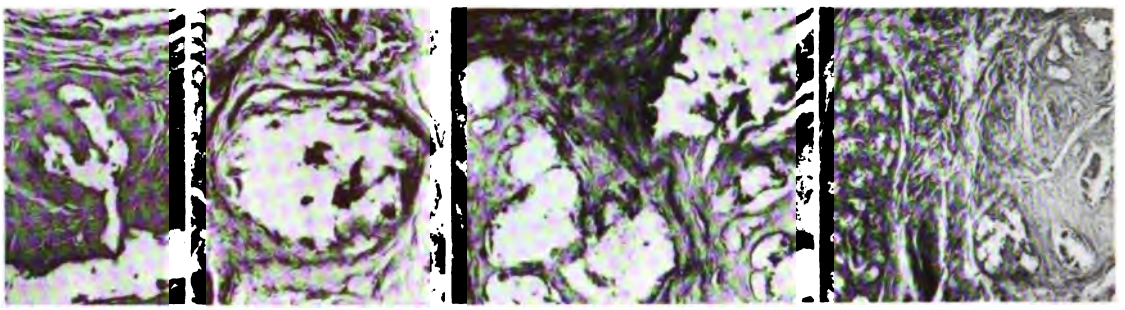

Fig. 7. Fig. 8. Fig. 9. Fig. 10.

Fig. 7. Dilated mucous gland showing bifurcation.
Fig. 8. Markedly distended mucous gland adjacent to others showing but slight distention.
Fig. 9. Group of distended acini.
Fig. 10. Hypertrophy of the mucous glands.

1. Foreign bodies by interfering with the lumen, lowering the resistance through pressure or the formation of pockets which hold bile or the secretion of the mucosa or its glands, predispose to bacterial growth.

2. Obstructive lesions through producing a stasis predispose not only to bacterial growth but also to the extension of the bacteria to the gall-bladder.

3. Villous growths. The mucosa of the cystic duct like that of the gall-bladder shows a predisposition to a fine villous growth in the presence of chronic irritation. The villi have a delicate connective-tissue framework containing tiny blood-vessels and are covered with columnar epithelium. They do not grow as large as those in the gall-bladder, are not so numerous, and do not anastomose so freely. They are not large enough to interfere with the lumen but may harbor bacteria (Fig. 6).

4. Ulcers when present are a continuous source of infection.

B. Intramural.

1. The lesions of the mucous glands are the most important lesions in this class. They do not differ materially from those of the mucous glands of the gall-bladder, except that bile pigment, so far as I have been able to observe, is never found in them. The principal lesions are:

a. Simple infections within the glands. The lumen becomes distended with an accumulation of desquamated epithelium, pus cells, bacteria, and mucus.

b. Periglandulitis. This is an advanced stage of the former and in addition to the above findings there is a round cell infiltration, œdema and congestion about the glands.

c. Intramural abscess. In the presence of an intense infection or when there is not free drainage in milder infections breaking down and abscess formation may occur. They may be single or multiple. After abscess formation has taken place the duct of the gland may open and the abscess discharge into the lumen of the cystic duct. the abscess may rupture either externally or internally or the process may go on to resolution.

d. Perforation as mentioned above may take place either into the duct or into the lesser omentum or into the peritoneal cavity.

e. Chronic infection. The gland becomes more or less distended with detached and broken down epithelium, pus cells, bacteria and mucus. About the duct is a round cell infiltration. The duct may remain open or open intermittently, discharging its contents, including bacteria, into the cystic duct. In case the duct becomes permanently closed it may heal, the infection may become latent. an intramural abscess may develop or there may be distention due to retained secretions.

f. Intramural cysts. Distention of the glands may occasionally be due to back-pressure but it is usually the result of the obstruction of the duct with the retention of the secretions, for otherwise bile pigment would be found in the cysts (Fig. 7, 8, and 9).

g. Adenoma. I have seen marked hypertrophy of the glands, but none to such an extent that the term adenoma could be applied to it, yet I believe it is possible that they do occur (Fig. 10).

h. Primary carcinoma. I have not observed any up to the present.

CLINICAL SIGNIFICANCE

Clinically the obstructive lesions can best be classified according as they produce permanent complete obstruction, transitory complete obstruction, permanent partial obstruction or transitory partial obstruction.

In the obstructions the involvement of the gall-bladder may completely overshadow the cystic duct clinically. The following conditions have been observed as the result of such obstruction: acute and chronic cholecystitis, hydrops, empyema, sclerosis and calcification. The latter two occur only with the permanent complete obstruction while the former three occur with any form of obstruction, but more often probably with the transitory types especially those resulting from foreign bodies.

Excluding the symptoms that come from the gall-bladder involvement, with permanent complete obstruction, pain may be entirely absent and when present is usually dull and never colic-like. Tenderness is present.

The transitory complete obstruction, on the other hand, is usually accompanied by pain which may be colic-like at first, but if the condition persists without an occasional remission or when due to a stone and the stone does not pass on downward or becomes loosened, the pain soon loses its colic-like character. Infection is very frequently present.

Permanent partial obstruction is accompanied with tenderness and pain of a more or less dull character. There may be occasional attacks of colic-like pain. Hypertrophy of the muscle of the duct above the obstruction and of the gall-bladder occurs.

In transitory partial obstruction there is tenderness present and pain varying with the degree of obstruction. When the lumen is markedly encroached upon there may be a colic that cannot be distinguished from gall-stone colic, regardless of what may be the cause. It is produced by the intense muscular contractions that are attempting to force the contents of the duct or gall-bladder or both by the obstruction. This condition is often accompanied by more or less infection.

Obstructive lesions by forming pockets or otherwise causing retention harbor infective organisms and thus predispose to infection of the rest of the biliary tract or through the blood stream elsewhere in the body.

The glands of the cystic duct become of importance clinically, first when they become infected: (a) By discharging organisms into the duct which may pass upward with the bile into the gall-bladder or downward into the common duct, whence they may ascend to the liver;

b. By acting as a focus whence organisms may go into the blood stream.

c. By perforation into the lesser omentum or peritoneal cavity and thus there may result an abscess in the former case or a peritonitis, local or general, in the latter.

d. Through the action of the toxin absorbed.

Second, when they become distended and encroach upon the lumen of the duct.

The positive diagnosis of lesions of the cystic duct will rarely be made clinically or with the exception of stones or other masses, upon gross examination. In the majority of cases the microscope will be required.

The clinical indications are for cholecystectomy. Drainage will relieve secondary lesions but it would not have any influence upon permanent strictures, could not guarantee that transitory strictures might not return and in the case of infected glands there would be but little influence upon the deeper portions.

NOTES ON TWO SIGNS IN CHRONIC APPENDICITIS[1]

By ROBERT T. MORRIS, M.D., F.A.C.S., New York

ONE of the most frequent visitors to the doctor's office is the patient with indefinite pain of transitory character belonging to the right side of the abdomen. If the patient consults the surgeon the latter is prone to find symptoms of chronic appendicitis and he sometimes alarms the patient with a prognosis of impending disaster if the appendix is not removed. When this same patient enters the office of the internist with the appendix in the form of a question mark, the internist is prone to treat the matter lightly and to say that the pain is caused by gas in the cæcum and ascending colon, a condition which is recognized readily on percussion of the abdominal wall. The greater number of these patients belong to the neurasthenic group; patients with stigmata of decline presenting objective signs in stigmata of arrested development of various structures of the body. The appendix vermiformis, as a vestigial structure with a tendency to undergo involution changes of its various coats, appears to undergo involution earlier in patients of the neurotic group. Involution changes which normally might become marked in the average individual at perhaps fifty years of age may appear in the patient with stigmata of decline at the twenty-fifth year of age. The appendix undergoing involution change with connective-tissue replacement of its coats becomes a source of irritation to the ganglia of the autonomic and sympathetic nervous system. Nerve elements remain in such an appendix until practically all other structures have disappeared and these nerve elements are irritated by the contracting of hyperplastic connective tissue. Irritation calls for a special determination of blood supply to that point, and the control of the blood supply belongs in the domain of sympathetic nerve function. When the message from the irritated appendix is registered for a sufficiently long time upon the ganglia relating to the cæcum and the ascending colon, the muscular coats of the cæcum and the ascending colon eventually become exhausted. This part of the bowel then becomes more or less permanently distended with gas and gives us an important differential diagnostic sign belonging to chronic appendicitis but not to acute appendicitis. I call it the cider barrel sign for the purpose of making a picture, because percussion upon the normal left side of the abdomen elicits a note suggestive of a cider barrel in October, while percussion over the distended bowel on the right side brings out a note suggestive of the cider barrel in March.

Another sign belonging to chronic appendicitis and not to acute appendicitis relates also to sympathetic nerve ganglia, apparently due to persistent registering of impulses. It is not unlikely that the impulse extends in an afferent way to a segment of the spinal cord and then proceeds efferently to one ganglionic point and at the same time to the skin in the zone described by Head as belonging to the appendix. The ganglionic point apparently relates to what anatomists sometimes now speak of "as the fused ganglion" consisting of the second and third right lumbar sympathetic ganglia. Hyperæsthesia of the fused ganglion will be in evidence if we make pressure deeply and slowly upon the patient's abdominal wall about an inch and a half to the right of the navel and a trifle caudad. When we find this tender point distinctly in evidence and standing alone without tenderness of the left lumbar ganglia there appears to be definite evidence that we are dealing with the appendix as the source of trouble.

Chronic appendicitis relates most frequently to an irritative lesion rather than to an infective lesion. It belongs most often to that irritation of nerve elements by the contracting connective tissue which belongs to involution change. The irritative feature, however, may belong to ordinary scar tissue which has followed an infective involution of the appendix. In chronic appendicitis cases the two signs here described appear to have distinct diagnostic value. When the source of the

[1]Read before the meeting of the Southern Surgical Association, Baltimore, December 17, 1918.

irritation is in the vicinity of the pylorus or gall-bladder we find Mayo-Robson's tender point relating to the first sympathetic lumbar ganglion on the right side. When the sympathetic lumbar ganglia of both right and left sides are found to be tender on pressure we may look to the pelvis for the source of irritation. The pelvic ganglia receive and distribute impulses over such a large area that a chronic source of disturbance in the pelvis seems to be registered upon both right and left sympathetic lumbar ganglia instead of on the ganglionic point on the right side belonging to the appendix.

CONGENITAL DIVERTICULA OF THE INTESTINES

Report of A Case of a Tumor Growing from the Tip of an Apparently Congenital Diverticulum in the Lower Sigmoid Region[1]

By WILLIAM T. BLACK, M.D., F.A.C.S., Memphis, Tennessee

THE vitelline duct, which is attached to the ileum, should disappear between the sixth and seventh weeks of intrauterine life. At this time it should change from a tube to a cord, which in turn melts away, leaving the bowels free from their connection to the umbilicus. When the cord remains we have a diverticulum. Diverticula are either congenital or acquired. This paper deals only with the congenital or inherited type. A true diverticulum is the remains of the vitelline or omphalomesenteric duct, that is its intra-abdominal portion. Lavata, in 1671, was probably the first to call attention to the diverticulum, and later Ruysch described it more accurately. It remained for Meckel, by whose name the diverticulum is named, to give to the world its true pathological and surgical significance. The acquired types have assumed their importance, both from a pathological and a surgical view point, and have been elaborated upon by many able writers, and will not be discussed in this report. Meckel's diverticulum is estimated to be present in about 2 per cent of people. It varies in length from 1 to 20 centimeters, and may be found from 30 to 290 centimeters (the average distance being 100 centimeters) above the ileocæcal valve (in the child the distance is less) where the yolk stalk is attached. In cases where the lower limb of the primitive intestinal loop has undergone excessive development, it may be found in the cæcum or colon.[1] At times it remains patent throughout, and there may be present fæcal matter exuding from the umbilicus, or it may be closed on the intestinal side and open at the umbilicus, but usually, however, the distal end is closed and the proximal end open. It varies in size from a very small cord-like structure to one as large, or even larger, than the lumen of the gut. There may be smaller false diverticula connected with a true diverticulum. It may be bulbous at its distal extremity and narrow at its intestinal end.

Both extremities may be occluded and patulous in the center. Sometimes there remains only a fibrous cord and at times only blood-vessels. It usually arises from the convex side of the gut, but may spring from the mesenteric side, and may have a mesentery of its own. Wellington says that in about one-third of the cases it is attached to the umbilicus, or adherent to some other part of the anatomy.

A pre-operative diagnosis of the presence of a diverticulum cannot be positively made. A probable diagnosis may be made in those with a fæcal discharge at the umbilicus. A discharge of any kind at the umbilicus, with a sinus or a growth, present is suggestive. Especially is this true in children, where the child is afflicted with gastro-intestinal symptoms. Right-sided abdominal pain, which continues or follows the removal of the appendix, after a

[1] Binnie's Surgery, 1917.

[1] Read before the Southern Surgical Association. Baltimore, December 17-19, 1918.

careful inspection of other organs, which are found to be normal, is suggestive to a certain extent (if adhesions can be ruled out) of a diseased diverticulum. The X-ray may assist in a pre-operative diagnosis.

Mumford estimates that 13 per cent of the diverticula become inflamed or diseased. The principal danger then lies in these 13 per cent of cases, for we all know the frequent occurrence of intestinal obstruction produced by a diverticulum. In 22 cases at the St. Thomas Hospital from 1887 to 1908, 63 or 6 per cent died — a mortality of 1 per cent higher than that from all other sources (including cancer). Hilgenreiner's report of 102 collected cases in 1902, shows a mortality of 71.5 per cent. Murphy stated that 5 or 6 per cent of intestinal obstructions were due to diverticula. The majority of people who possess diverticula are without symptoms. Diseased diverticula will produce symptoms in proportion to the extent of the pathology present. Symptoms simulating an acute or chronic appendix may be present. The symptoms of obstruction or symptoms due to growths, which spring from them, give the usual symptoms of such conditions.

The following patient came under my service at the Baptist Memorial Hospital, in October, 1918:

Mrs. Mary S., age 59; white; female; American; did housework and work in the field. Her family history is negative. She denies previous history of syphilis, cancer, tuberculosis, insanity, etc. She had the usual diseases of childhood. The patient married at the age of 14. Her physical and mental appearance is fair. The patient began four years ago to have pain in right iliac region, sharp and shooting in character. This was not accompanied by any gastro-intestinal disturbances. The pain subsided in about three weeks. Some time later she discovered a lump in her abdomen, which was movable but not accompanied by pain. The tumor did not disable the patient in any way, causing only slight discomfort and constipation. The abdomen commenced to enlarge about two years ago, and has continued to enlarge ever since. The abdomen was largest on the left side. The tumor seemed to stay the same size for 12 or 15 months, then began to enlarge rapidly, with symptoms of bearing down pain in pelvis, and backache, dyspnœa, etc.

The patient first menstruated at 14 years; regular, 28-day type, 4 or 5 days' duration, quantity of flow normal. The menopause occurred at the age of 50.

The patient is the mother of eight children, the oldest 44 years old, the youngest 17. Her labors were normal. She was not attended by a physician during any of her labors. She had one premature labor at eight months. No complication or sequelæ followed any of her confinements. She has no leucorrhœa; she is constipated, micturition has been frequent for past few months. She suffers from indigestion of late. Nervous symptoms are negative. Previous treatment—medical.

Physical examination shows a well-developed, poorly-nourished woman. She has lost several pounds in weight during the past few months. The skin is jaundiced and wrinkled. The eyes are normal, the teeth bad, and the breath foul.

Thoracic cavity negative. Blood pressure: systolic, 155; diastolic, 110. The abdomen is distended to about the size of a nine months' pregnancy. A tumor hard and irregular in outline, except on the upper, right side, fluctuates on palpation. Flatness is noticeable over the entire abdomen, except that a tympanitic note is present over the colon. There is no area of tenderness. The spleen and kidneys are not palpable. The liver is normal. Except for slight emaciation, the extremities are normal. Urinalysis negative.

Blood count: leucocytes, 6,800; reds, 4,048,000; polymorphonuclears, 80 per cent; small lymphocytes, 12 per cent; large lymphocytes, 4 per cent; eosmophiles, 2 per cent.

Wassermann test negative.

The general appearance of vulva is normal. There is a slight leucorrhœal discharge. The perineum is negative. The cervix is pushed up under the pubic region. The uterus is pushed forward. The appendages are not palpable. A large mass is present.

A pre-operative diagnosis of either a large subserous myomata with cystic degeneration or an ovarian tumor was made. The patient was operated upon on October 4, 1918, under ether anæsthesia. A median abdominal incision was made from the pubes extending up nearly to the ensiform cartilage. A large, irregular, cauliflower-shaped tumor, filling the entire pelvic and abdominal cavities was found. The tumor showed marked cystic degeneration. No free abdominal fluid was present. Weight of tumor, 4,260 grams.

There were two large cysts at the upper right portion, each about the size of a large grape fruit, filled with chocolate-colored fluid. The tumor was entirely free, not connected with any structure, except at its origin. However, in one place, one cyst was adherent to the anterior abdominal parietal peritoneum, just below and to the right of the umbilicus. The adherence of the cyst to the peritoneum was loosened, and the mass lifted out of the abdominal cavity. The origin of the tumor sprang from the tip end of a diverticulum. The diverticulum had its origin in the lower portion of the sigmoid (rectosigmoid region). It sprang from the convex side of the gut. There was no mesentery on the diverticulum. It was about 11 centimeters in length

Fig. 1. Rough sketch showing attachment of tumor to diverticulum.

and about the size of the little finger. The diverticulum was caught with two clamps and cut. A probe was pushed through the diverticulum to the gut to confirm its character. A purse-string suture was passed around the gut end, and the stump was treated as the stump of an appendix is usually treated. I was surprised to find such an origin, as I expected to find the origin of the tumor coming either from the ovary or the uterus. There was not an adhesion to any abdominal or pelvic structure, except where the cyst was attached. The uterus and appendages were normal. This mass had every appearance of springing from only the endothelial side of the intestine (diverticulum). I noticed particularly the absence of large blood-vessels running through the diverticulum, as one would expect to find in so large a tumor. There was a small mass in the hilum of the spleen. There was no evidence of metastasis in any other organ.

The following is the pathological report on the specimen sent by Dr. H. T. Brooks, professor of pathology, at the University of Tennessee:

The specimen, as a whole, would probably fill a one and one-half to two gallon bucket. The external surface showed many small, and a few large, papillary projections. Here and there were large and small fluctuating masses indicating the presence of cysts. Everywhere the tumor had a markedly gelatinous appearance. Sections through the tumor showed cysts of varying sizes; one holding a pint or more of fluid. The fluid was brownish in color. The contents of the cyst showed no mucin.

Microscopical examination of the six different areas of the tumor showed several layers of epithelial cells, with no indication of downgrowth into the stroma. The several layers of cells, however, point to a malignancy. The stroma everywhere showed extensive myxomatous changes and this accounts for the gelatinous appearance of the tumor. (It was my impression at first sight of gross inspection, that it was due to a mucous degeneration on the part of the epithelial cells. This, however, was incorrect.)

Diagnosis: malignant cystadenoma, the stroma of which has undergone an extensive myxomatous change.

The following is the report from the Pathological Laboratory of Dr. William Krauss, Memphis, Tennessee:

First report. Examination of specimen submitted shows bad fixation. Such tissue is apt to be autolytic and consequently indistinct. Two areas have been picked out. The most developed cells have the characteristics of the fibroblasts from endothelia. The younger ones sometimes in islands are normal and rather small, but evidently purely endothelial cells. The stroma is myxoid. I regard it as myxoma, springing from the serosa and preserving some of the characteristics of endothelial origin. This report was based on small sections of tumor sent to him.

Second report. The following is the report upon the tumor mass submitted to me after I had reported on the sections made from smaller pieces.

The entire mass impregnated with formaldehyde weighed 1420 grams, about three pounds. It is bluish white in color, translucent, very lobulated, with numerous fine cauliflower exuberances. Many of the warty masses are cystic. Some of the cysts are imperfectly formed, the tissues gradually merging into a mucoid material. The larger, older cysts

are smooth walled with patches of cauliflower protruding into them. These contain clear serous fluid, and remind one of papillary ovarian cystoma.

Microscopically the stroma is partly fibrous and partly mucoid with islands of proliferating endothelia, often seen to connect with spaces that have a very primitive structure and lined by round and oval cells with vesicular nuclei. Fixation, however, is not good. The covering of the entire polypoid mass is very scanty, and shows thickening only in a few places. The stroma is the only active tissue, and the blood supply is exceedingly scanty.

Diagnosis: Fibromucous peritoneal polyp. Although the gross resemblance to an ovarian tumor is striking, there is nothing in the histology to suggest any ovarian origin.

(The above were specimens obtained by Dr. William Krauss, from about one-third of the tumor, which was sent to him.)

The following report was given by Dr. W. G. MacCallum, of the Johns Hopkins University:

The specimen appears to me to be a papillomatous growth composed of very loose and œdematous stroma, rather more dense near the surface, and forming large round papillary masses. It is in protected places, covered with a layer of epithelium, which is in places cylindrical, although usually cubical or flattened. In exposed places the epithelium is rubbed off, and the superficial layer of the stroma appears as though the basement membrane had been lifted off by a fluid.

There was a wall on both sides of which the papillary masses seemed to project, but the sections do not show this; probably those cut deeper in the block will do so. I enclose three sections.

From the above reports the tumor is evidently potentially a malignant type. The tumor was in the stage of regression, which probably was due to a poor blood supply. There were no vessels of any size in the diverticulum, and the growth probably received its principal sustenance from the peritoneal fluid. Unless the small mass in the hilum of the spleen was a coincidence, then one would naturally think the tumor was a malignant one and this a metastatic growth. I am unable to account for such a mass as this growing from only the outer coat of the diverticulum. If it was a malignant tumor, I am unable to find an exciting cause. It is improbable to suppose that peristalsis, or the movements of the other viscera, could produce any irritation. It is possible that, when the patient had the severe pain in her abdomen four years ago, she had a diverticulitis, or that an ulceration might have been produced from within, which extended to the outer portion of the diverticulum, or what probably occurred was a perforation. The formation of a malignant growth can at times be accounted for by the retention of hardened fæcal matter, or concretions acting as a predisposing or exciting cause. The retention of dry fæcal matter, or foreign bodies in this location, is favored by a constriction at the sigmoido-rectal portion. We have in the lower sigmoid, in the embryological stage a dilated or pouch-like condition present. This dilatation may continue in the adult as an embryonal defect, which might further assist in the retention of fæcal matter. This dilatation might have been the source of the diverticulum. Strictures, or growths of the rectum, hæmorrhoids or any inflammatory process involving the rectum would naturally resist the proper expulsion of the intestinal contents. Too long retention of this fæcal matter or concretions, might in a certain percentage of cases produce an erosion or ulceration, which might act as a starting point of a precancerous lesion. The same might apply to a diverticulum in this region.

In the case reported, however, there was no hardened fæcal matter, or foreign bodies, present, and the diverticulum and sigmoid were macroscopically normal everywhere, (except at the attachment of the growth). The principal etiological factors can best be explained through an embryological condition or fœtal rest, or transplantation of tissue from some other organ, or started as an inflammatory process. I am unable to find in the literature, at my disposal, a description of a similar case. Doubtless, however, other cases have been observed and recorded of a like character. A congenital diverticulum is unusual in this portion of the gut, and can only be accounted for through an error in embryological development.

Bizé in 1904, Devé in 1906, Denuicé in 1908, report cases of small pancreatic tissues, growing from the tip end of Meckel's diverticulum. Colmers in 1906 published an article upon intestinal cysts and their treatment. He says: "Raesfeld was the first to describe

an enterocystoma, and that he drew attention to the fact that it developed from a Meckel's diverticulum" — (Cullen).

Cullen, Cowardine, Rimbach, Roth, Tideman, Colmers and others have reported cystic tumors connected with the remains of the omphalomesenteric structure. In Rimbach's case, the tumor was as large as a man's head and adherent to the omentum.

Most of the reported cases have been small tumors, usually cystic and connected with Meckel's diverticulum in the iliac portion of the intestinal tract, or at the umbilicus. Mayo reports the rupture of a sigmoid diverticulum, which was thought to be congenital in type, forming an abscess in the pelvis. Cases of carcinoma are reported where a diverticulum is involved secondarily by contiguity of tissue. The treatment of an inherited diverticulum depends upon whether the organ is diseased, upon its location and upon its structure and size. All diseased diverticula, when attached to some other structure at its distal end, should be removed. Those with small proximal openings, and all found in the large gut (where solid fæces are found) should be removed. When the vitelline duct remains as a cord, or set of blood-vessels, it should be excised. Large normal diverticula, discovered accidentally in the small intestine (where we have only liquid fæces), should be left alone, for the fear of increasing mortality.

CONCLUSION

This tumor was connected only to the serosa side of the diverticulum. Potentially it was a malignant growth. A diverticulitis, or perforation, could be assigned as a predisposing or exciting cause, although it could be attributed to a fœtal inclusion. This diverticulum had the characteristics of a congenital type, but it is possible for it to be of the acquired type. Unless one can palpate the uterus and ovaries, a differential diagnosis cannot be made between a uterine myomata, with a pedicle, or an ovarian tumor, and a tumor growing from a diverticulum in the lower sigmoid region.

REFERENCES

1. MUMFORD. Practice of Surgery.
2. TAYLOR. Cancer.
3. HARBIN, R. M. Meckel's diverticulum; with special reference to the umbilicus; disorders of infancy. South. M. J., 1917, Feb.
4. DACOSTA. Surgery.
5. MOYNIHAN. Abdominal Operations.
6. BINNIE. Treatise on Regional Surgery, 1917, ii, 193.
7. MAYO, W. J. Acquired diverticulitis of larger intestine. Surg., Gynec. & Obst., 1907, v, 8.
8. MCGRATH, B.F. Intestinal Diverticula; Their Etiology and Pathogenesis.
9. CULLEN. The Umbilicus and Its Diseases.
10. PRENTISS. Textbook of Embryology.
11. MAYO CLINIC. Collected Papers, 1912.
12. KELLY and HURDON. The Vermiform Appendix and Its Diseases.
13. BURGHARD. A System of Operative Surgery. ii, 541.
14. DELAFIELD and PRUDEEN. Textbook of Pathology.
15. ADAMI. The Principles of Pathology. 9th ed.

WAR AMPUTATIONS

By CAPTAIN PHILIP D. WILSON, M.C., U.S.A.
Chief of Amputation Service, U. S. Base Hospital No. 9, American Expeditionary Forces

THE Interallied Surgical Conference at its meeting in 1917 came to the following conclusions in regard to the subject of amputations.

"Primary amputations or those delayed 24 or 48 hours will be made as nearly as possible at the site of fracture by simple section of the soft parts or with slight trimming of the bone; in less grave cases the amputation will be made as near as possible to the level of the fracture.

"Amputation for infection will be made by simple cross section or with very short flaps fixed in eversion. The stump will be regularized, if this is necessary, when the wound is disinfected and when all possible extension of the soft parts has been obtained.

"The technique in cases of retarded amputation will be governed chiefly by the indications of prosthesis. .

"In cases of fissured fractures extending very high the fissured fragment may be preserved but disinfection of the wound must be practiced."

For years the dominating idea in determining the surgical procedure of amputations has been to obtain a stump able to bear weight upon its end. The various osteoplastic methods which have been introduced are witness to this fact. Surgeons generally have had the impression that no satisfactory prosthesis could be applied, for example, to the leg in the absence of the ability of that stump to bear pressure upon its end. This impression is erroneus. Up to the present, end-weight bearing ability when present, except in the comparatively rare cases of Syme's amputations and disarticulations of the knee or hip, has been almost altogether disregarded by artificial limb manufacturers. In cases of thigh amputation the principal support is taken upon the tuberosity of the ischium with secondary support upon the soft parts of the stump; in amputations below the knee upon the shelving under surface of the plateau of the tibia. Cases provided with apparatus in this manner walk extremely well without any bearing whatever upon the end of the stump.

This does not mean to say that end-weight-bearing is not desirable. It should be developed and used whenever possible. The work of Hirsh and Lisle has shown that this ability is largely a matter of treatment and that it can be developed in a large percentage of stumps by the systematic use of end-pressing exercises or end-pounding during convalescence.

In general, however successful, end-weight-bearing demands certain qualities of the stump itself such as good covering for the end of the bone, mobile non-adherent flaps, absence of terminal scars, and mobility of the scar. In order to obtain these, infection and aseptic healing are essential. In war wounds primary healing, even when the amputation has been made well above the level of the lesion and the wound sutured is exceptional; generally the stump becomes badly infected or distended with gas and opening of the flaps or reamputation becomes necessary. In this way the desired end has been defeated and yet there has been a needless sacrifice in the length of the stump.

A stump is above all things a lever and its most important asset is length. Valuable as end-bearing power may be when properly put to use, it is small in importance when compared with length. As between the method of operation which will save to the patient the maximum length of stump and another which will shorten the bone in order to obtain end bearing, at the most problematical, the choice should go without doubt to the former.

The only way to judge amputation cases is by the result obtained when the stump is fitted with prosthetic appliances. From this standpoint there can be no question that the best results are secured in those cases where the operator abandons the classical methods

and attempts to save the maximum length by section at the level of the wound while at the same time making provision for dealing with the omnipresent infection by leaving the wound wide open. The care of creating a sound, useful stump is left to a secondary surgical intervention. Many of the resulting stumps fail to meet our old definitions of what constituted healthy stumps and some demand still further surgical treatment, but as a whole the gain has been great because there has been a general saving in length. Examination of three hundred amputated French soldiers, six months or more after healing of their wounds, showed only 20 per cent with what might be considered as classical stumps. Seventy per cent had terminal scars, which were adherent to the bone in 50 per cent. The end of the bone was protruding under the skin in 20 per cent. Practically all of these cases were wearing artificial limbs, usually of a poor type, and in spite of it they uniformly walked well.

The tendency of distinguished allied surgeons during the past year has been more and more in the direction of ceasing to regard amputations as a special group of cases requiring a special operative technique and instead to class them with all other war wounds and amenable to exactly the same rules of surgical procedure.

The limb is divided at the level of the lesion. The contused and injured or infected tissues are excised and when it is possible to obtain sound short flaps from in front of or behind the missile tract these are preserved but packed wide apart. Long flaps are usually dangerous as they tend to fall together, despite care, and interfere with drainage.

The treatment of the end of the bone is variable and depends upon conditions and the probability of remaining infection. Where it has been possible to do thorough excision of all damaged or infected tissue all projecting bone may be removed, but when it is probable that infection will develop it is better to leave the bone long and postpone the shortening of it to the secondary operation. It is fairly certain that the aperiosteal method of dealing with the end of the bone gives the best results. Formation of osteophytes around the end of the bone in war amputation stumps has been extremely common. This is probably due in large measure to the shredding of the periosteum preparatory to sawing the bone. With care this may be prevented and with a curette the periosteum is removed on a surface of one-quarter inch above the level of the section. Similarly the medulla of the bone should be curetted for about the same distance. In the absence of infection with this method, the end of the bone becomes more or less absorbed and rounded and the formation of osteophytes is minimized.

The vessels should be ligated with as little dissection as possible. It does not matter if they project upon the surface of the wound. The treatment of the nerve ends demands special care. A good method is to draw down upon the nerve, separate and peel back its sheath and divide it as high as possible by a wedge-shaped or fish-tailed incision. The end of the sheath is then drawn down and ligated. Formation of neuromata and painful nerve endings are avoided in a very large percentage of cases treated in this manner.

In a certain number of primary amputations, the stumps so prepared may be closed by delayed primary suture similarly to other war wounds and subject to the same criteria; that is, bacteriological investigation and clinical appearance. The probability of this procedure may be estimated fairly well at the time of the primary operation and in that case the operation itself, the preparation of flaps, etc., will be governed accordingly.

Where delayed primary union is not possible or when infection is expected, progressive sterilization of the wound should be practiced. In this connection the method of applying the Carrel tubes that is in use at La Panne is of value. To square pieces of gauze corresponding in size to the cross section area of amputation stumps, at various levels are stitched Carrel tubes in the position and proximity desired. These are prepared beforehand and sterilized. They are applied directly to the wound and afford a sure manner of holding the tubes in place. The troublesome slipping and change in position of the tubes is thus avoided, and by using 8 to 12

tubes, effective distribution of the disinfectant is obtained.

The application of extension to the skin of the stump has proved of great value and its more general use would be desirable. This is particularly advisable in thigh and upper arm cases. The amount of retraction of muscles and skin which occurs is often remarkable. In thigh stumps particularly even quite long flaps apparently disappear totally in the course of two or three days. Such a wound may then appear as almost a plane surface. The application of traction will, however, make these flaps reappear. Needless sacrifice of length in many stumps may be saved by its more general use. Where traction tends to close the wound it cannot be successfully used when infection is present. This cannot happen when the flapless method of amputation has been used. In this case the use of traction tends mechanically to favor wound disinfection as the surface remains a plane section instead of becoming conical as retraction occurs.

Traction may be applied either by means of a pulley and weight or by using a modified Thomas splint. Each method has its advantages. The extension splint is best adapted for use at the front as it is more compact and can be used for transportation, whereas the method with the pulley and weight is best suited to the needs of the base hospital.

The splint is a modification of the ordinary Thomas Ring apparatus used for fracture cases. It is shorter and the side bars instead of being parallel are divergent. At the foot end is fastened a square upright frame which serves at the same time as a support for the apparatus and a point of attachment for the extension. The stump is supported on flannel strips fastened to the side bars in the ordinary manner. The traction may be applied either by strips of adhesive plaster or by flannel strips and glue. These are fastened to the skin two inches above the wound and run the entire length of the stump. The number of these to be used and their arrangement depend upon the shape of the wound and the level of the amputation. The ends of the strips are fastened to a steel ring larger in diameter than the end of the stump. The ring is important because it prevents pressure upon the wound edges and also equalizes the pull. It has two lateral projections which rest upon the side bars of the frame. It is fastened to the end piece either by coiled steel wire springs or rubber tubing which gives the necessary traction pull. Change of dressing is very easy as the traction bands are simply unhooked from the ring and the latter passed upward over the end of the stump giving an unobstructed view of the wound. This splint immobilizes the stump completely and is very comfortable for the patient.

When the pulley and weight method is used the splint is unnecessary. The ring is retained as it simplifies dressings, but the traction is furnished by a cord and weight, the latter from 3 to 6 pounds, depending upon how much the patient can stand. The comfort of the patient is much increased if the stump is supported upon a swath the ends of which are fastened to short steel bars suspended by cords from an overhead pulley and counter balanced by weights. When arranged in this manner the patient can lift himself easily and move about in bed and nursing is simplified.

It is exceedingly important with any apparatus that tends to elevate the stump to guard against the contracture of certain muscle groups with resulting limitation of joint motion. One of the most frequent causes of failure to develop the maximum benefit from the prosthetic appliances in amputation cases is this limitation of the full range of motion at the joint. Very few thigh cases retain their power of hyperextension at the stump and flexion contractures are the rule; below the knee limitation of extension; in the forearm loss of supination; in the upper arm limitation of abduction are the other common impairments. Precisely those motions are limited which are most necessary to the welfare of the cripple. They are often due to prolonged immobilization of the stumps in bad position and can in large measure be prevented. Systematically each day beginning after operation the stump must be made passively to execute in its entirety the motion that is most likely to be affected.

For thigh cases who are too ill to turn over on their faces for the purpose of making hyperextension of the stump another maneuver is substituted. With the patient lying flat on his back, a pillow is introduced under the buttocks to elevate the hips. The sound leg is then fully flexed on the abdomen to tilt and fix the pelvis. The stump will be found pointing in the air and it suffices to move this backward as far as possible while at the same time the crests of the ilia are held down by the nurse effectively to guard against flexion contracture. In cases of amputation of the leg, the knee should be fully flexed and extended. In amputations of the upper arm the stump should be abducted completely each day. Its maintenance in the abducted position by means of the special traction splint is also advisable and the passive exercise of the stump is then not necessary. Similarly care should be exercised in stumps of the forearm to put them through the normal range of supination and pronation. These simple exercises require very little time and trouble. The traction splint when used does not need to be removed. By removing the flannel supports the stump can be moved inside the splint.

Almost all amputation stumps require secondary operations for closure of the wound. Delayed primary union at the end of 3 to 5 days has already been mentioned and should be done in all cases where bacteriological study justifies it. Secondary suture may be done when progressive chemical disinfection of the wound is successful. In a certain proportion of cases, however, infection of the bone occurs and the bacteria become inaccessible to the solution. In these cases a simple bone shortening operation with excision of a wedge-shaped section of the soft parts may be done. The wound should be left open and it may be possible to obtain chemical sterilization and secondary suture. Even when this is unsuccessful the wound will granulate and close by epithelization in most cases. This may take time, but conservatism pays.

A certain number of the resulting stumps prove unsuitable for satisfactory use on account of protruding bone adherent to the scar, sinus formation and chronic osteomyelitis, troublesome osteophytes or painful nerve endings. Each of these conditions demands appropriate surgical treatment, but as a rule this should not be carried out until the lapse of a certain time and when more conservative measures have failed. The excision of an adherent scar with shortening of the bone in an apparently clean case may let loose dormant or encapsulated bacteria and produce reinfection. The extrusion of a sequestrum by natural means may occur after a little time and result in closure of a sinus. Perfection is difficult to obtain and should not be sought for; very often it will bring disaster.

Immediately that a stump is able to tolerate pressure on its end, steps should be taken to develop its end-weightbearing possibilities by inaugurating end-pressure exercises. The degree of pressure borne by the stump is graduated and in no case exceeds that which the patient can stand. The stump is first pressed against a box covered by a pillow resting against the foot of the bed. This is done at regular intervals during the day. Later as the end of the stump becomes toughened, the pressure exerted is increased. In the standing position, the stump is pressed against the seat of a chair at frequent intervals during the day. The force is increased until the patient is actually pounding the end of his stump against it. Care must be used in inaugurating and supervising this exercise as it often causes infection to flare up. For this reason it should not be used in cases where sinuses are present. Unfortunately the exclusion of this class of cases makes the number to whom this procedure can actually be applied comparatively small.

Massage of the muscles actuating the stump is of great value in keeping up their nutrition, and in preventing degenerative changes from prolonged disuse.

Long-continued disuse is one of the most potent factors of all in preventing complete functional restoration in cases of amputation. This has been due in large measure in the past to the improper recognition of the necessity of supplying prosthetic apparatus at an early date. It is now possible to secure cheap,

light, provisional apparatus which can be applied immediately the patient is convalescent. Its use prevents the formation of the crutch habit, hastens stump shrinkage, and at the same time provides an invaluable means for active mobilization and muscle exercise. Its early application is imperative. Surgery must devote itself to shortening the period between amputation and convalescence, if we are to secure the best results. The earlier our wounded can be made ready for provisional prosthesis, the greater will be the degree of functional restoration obtained.

SYPHILITIC INDURATION OF THE VULVA

With Report of Four Cases

By J. F. GALLAGHER, M.D., F.A.C.S., Nashville, Tennessee

To a large group of cases presenting the symptom-complex of chronic enlargement of a part with smooth or roughened skin, with or without ulceration, and microscopically characterized by increased connective-tissue formation with lymphatic dilatation (or new-growth), the term elephantiasis has been applied. This all-inclusive and meaningless term has been used to include this condition whether the underlying etiological factor would appear to be antenatal, as referred to by J. Schnitzler (1); mechanical obstruction by the removal of the lymph nodes draining the part, mentioned by Ravogli (2) and many others; recurrent streptococcic infections alluded to by Hill (3); tuberculosis, cited by Viatte (4); syphilis, referred to by Lena Kurz (5), Kelly (6), Ravogli (7), and many others; or the so-called tropical form due to the filaria sanguinis hominis (8), or the bilharzia.

Just seventy years ago Huguier (9) applied the term esthiomene to this condition when involving the vulvo-anal region, but neither he nor subsequent writers have made it clear just what is the underlying etiological factor in the condition they term esthiomene. Stein and Heimann (10) report a case and quote another from Szasz, in which there was cyst formation, using the term esthiomene, in which the causative agent was not determined. Hyde (11), Taylor (12), and Lena Kurz (13) believe all esthiomenes manifestations of tertiary syphilis.

It will be seen then that the term elephantiasis is applied to a clinical manifestation that is constant only in a very general way either in macroscopic or microscopic appearance and having a most variable etiology. The same may be said of the term esthiomene, though its use is restricted in application to the vulva. It would seem logical, therefore, to restrict these terms to a condition that has a definite pathology and etiology, or so to qualify the terms as to give an adequate conception of the condition considered; or, perhaps, to discard the terms

Fig. 1. Case 1.

Fig. 2. Case 2.

altogether. This latter I have done in applying the term "chronic syphilitic induration of the vulva" to the cases I shall report herewith. They are elephantiasic in gross appearance, they may be called esthiomenes, if that term is to be restricted to the cases in which syphilis is the causative factor, but they are syphilitic in origin, are chronic in their course, and their structure is of an indurative, œdematous type.

It is possible that what may be the largest percentage of cases that are termed esthiomene or elephantiasis vulvæ, have been considered of doubtful syphilitic origin because they are highly refractory to antisyphilitic treatment of whatever kind or intensity. Morover, the microscopic appearance of syphilitic and tuberculous lesions are often very confusing.

These cases came under observation in the Gynecological Out-Patient Department of Vanderbilt Medical School. Of the latest one thousand patients in that department, only six cases of syphilitic œdema of the vulva have been noted. Two of these were not very extensive, and only diagnosed clinically, and are omitted from this report.

CASE 1. Gussie C. A widowed, mulatto laundress of thirty, was seen first on November 11, 1917. She was born in Missouri.

The mother is living and well. The father died of cause unknown. One sister died of cause unknown. One sister living and well. She had 13 half-brothers and -sisters of whom she knows nothing.

The patient uses tobacco and alcohol. She had measles and chickenpox when a child, la grippe for four weeks, five years ago. She states she has had hæmorrhoids all her life and that she has pain and passes blood and mucus when her bowels move. Up to six days ago she got up two or three times at night to void. She often has burning on urination. No blood. Her menstrual history is entirely normal. She had a miscarriage at four months about ten years ago. The convalescence was uneventful. She denies venereal disease.

About four years ago she noticed a growth about the size of her thumb in the region of the clitoris. This has grown gradually to the present size. About seven or eight months ago she put raw bacon on the growth which caused it to ulcerate but this is now healed. At about the same time she noticed the growth about the anus. There is a burning sensation present at times, not associated with ulceration.

Physical examination shows the tonsils to be enlarged. There is a systolic murmur, almost entirely replacing the first sound, heard best at the apex. The epitrochlear and inguinal lymph nodes are palpable. There is a slight discharge from umbilicus, which is depressed. The margins are slightly hardened.

From the region of the clitoris and involving both nymphæ, a pedunculated tumor 12x15 centimeters is seen growing. On the right side of this tumor there is a small eroded surface about 4x2 centimeters. Extending from this forward is a scar. The labia majora are very much thickened, hard, not tender and have an appearance of pig skin. Covering the entire perineum and extending back to the coccyx on both sides of the anus is a huge cauliflower growth, red and having a very slight discharge. The urinary orifice is normal as are both walls of the vagina.

The urine is normal. The blood is normal save for a 4+ Wassermann.

CASE 2. Maggie McC. An unmarried negro domestic of nineteen first seen November 20, 1917. Born in Tennessee. The family history is unimportant. The patient had measles in childhood. She has lost about 30 pounds in weight in past year. She has had leucorrhœa for past three months. Periods entirely normal except that she has missed her last period. She has had no children, miscarriages, or abortions.

About eighteen months ago the patient noticed a small nodule on left side of vulva. In about three weeks this ulcerated but healed again in about two weeks. Later she noticed a swelling on the opposite side. These have grown gradually and continuously to present size. The patient states that the tumors swell, become hard and quite painful at night. Pain prevents her from sleeping.

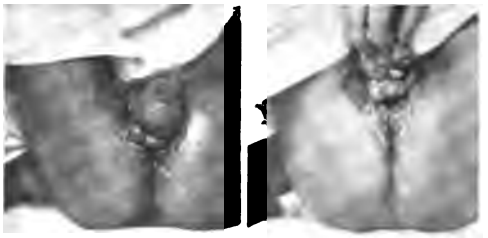

Fig. 3. Case 3.

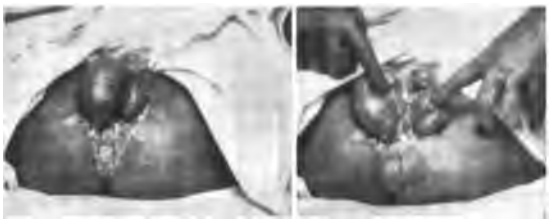

Fig. 4. Case 4.

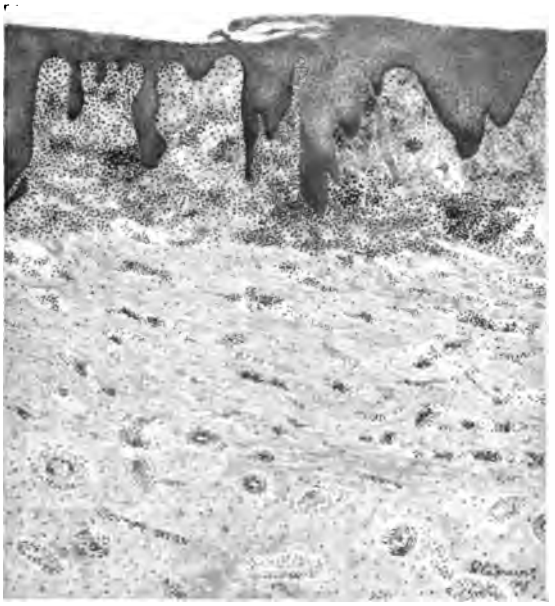

Fig. 5. Syphilitic induration of the vulva showing thickened epithelium, hyperplasis of the subepithelial connective tissue, with many new formed capillaries and many mononuclear lymphocytes.

Physical examination discloses an ulcerated area about the size of a dime on the hard palate. The lymph nodes are palpable in the inguinal region. Growing from and including the left labium is a rather soft, fluctuant not tender, tumor 12x8x6 centimeters. On the right labium is a similar mass 7x5x4 centimeters. On this mass is a small papillary mass which seems to have grown at the site of an old scar, Between the two masses and covering the labia minora, the vestibule and extending on to the perineum, is an ulcerating area covered with a foul, purulent discharge.

The urine and blood are negative. The Wassermann is negative.

CASE 3. Mary P. Mulatto housewife of 32 first seen December 9, 1917. Born in Tennessee. The family history is unimportant. The patient had measles and whooping-cough in childhood. Thirteen years ago she had typhoid (?) fever. She had fever for one year and was sick two years. She has been unable to walk since that illness on account of contractures of flexors of toes and calf muscles. Menstruation has been normal except that lately the flow continues one day more and she has slight pain in the lower abdomen. She has had no children, miscarriages, or abortions. She has had leurorrhœa for 15 years. She denies venereal disease. She has lost no weight.

About two years ago the patient noticed an enlargement on upper part of privates. This grew slowly but steadily and in about six months she noticed an ulceration underneath. The growth has gradually increased in size. There is pain, of burning character, worse at night.

Physical examination discloses a patient who is poorly nourished. The inguinal lymph nodes are palpable. Both lower extremities are rather small. There is apparently the atrophy of disuse only. The ankle-joints are fixed in extension and the toes of both feet are markedly flexed. Knee-jerks are absent.

Growing from the region of the clitoris is a growth 5x7x10 centimeters. From the lower surface of this tumor and projecting toward the vagina are two smaller growths. Involving the entire perineum and extending out on to the inguinal folds is an ulcerating area with well-marked elevated edges which are undermined. This area is covered with a foul, purulent discharge.

The blood shows a 5+ Wassermann, otherwise negative. Urine negative.

CASE 4. M. L. D. A negro "practical nurse" of 19, unmarried, was seen first February 15, 1918. Her father died of heart disease and she has an aunt who now has heart disease. The family history is otherwise negative. The patient had the diseases of childhood. For the past two months she has had a "heavy feeling" in stomach soon after eating. She has vomited several times during this time. Stomach symptoms are relieved by soda. She has a good appetite. She gets up two or three times at night to void. She denies venereal disease. Her periods began when patient was 18, they are regular. twenty-eight day type, flowing three days and using three napkins daily, moderately soiled. She has no pain. She has not menstruated during the past three months. She had had no children, miscarriages, or abortions. She had leucorrhœa for past 3½ years.

Three and one-half years ago the patient began to have a profuse vaginal discharge. In about one month a severe itching began in the perineum. This was followed by a sore which the patient believed was caused by scratching. The sore persisted and in about one year a swelling was noticed on the right side of vulva. During the past three months the left side has been enlarging. More recently a smaller tumor has appeared in the upper part of the vulva. Between these tumors and surrounding the anus an ulcer has been present since the beginning.

Physical examination. The patient looks older than age given. There is some œdema of the eyelids. The pupils are equally dilated, regular, but do not react to light and accommodation. There is an external squint in left eye; also nystagmus. There is marked deformity of front teeth. The liver is palpated one inch below the costal margin. There is a mottled appearance of skin below the knees. The postcervical, epitrochlear and inguinal lymph nodes are palpable. The reflexes are present but sluggish.

In the right labium is a tumor 10x6x4 centimeters. In the left labium one about half that size. From the

region of the clitoris another tumor 3x3x4 centimeters is seen. Beneath the tumors and extending out on the thighs and back around the anus an ulcerated area with elevated edges is seen. This extends into the vagina on the posterior wall. The vagina is constricted about one inch inside just admitting the fore finger. Rectal examination is so painful it is not attempted. The urine is normal. The blood shows a moderate leucocytosis of 12,000 and the Wassermann is 4+.

On removal all the tumors showed a marked tendency to bleed, the bases being very vascular. There seemed to be a marked arterial supply and a noticeable absence of veins. The tumor base had an almost characteristic pearly white appearance which exuded a clear serum on pressure. Histologically the specimens showed so striking a similarity in appearance that a description of one will suffice for all. Thickening of the surface epithelium with hypertrophy of the papillæ were the noticeable changes in the skin. Underneath these was a noticeable productive inflammation, lymphocytes, plasma cells and eosinophiles being present. Increased fibrous tissue with œdema and enlarged lymph spaces are noted which latter are infiltrated with lymphocytes and plasma cells. The blood-vessels show perivascular infiltration. There are giant cells but no caseous masses.

In the specimen removed from Case 3, A. A. Eggstein, of the Department of Pathology of Vanderbilt Medical School has demonstrated the presence of the spirochæta pallida. In a rather full but by no means complete survey of the literature I have not been able to find that this has been done before. Furthermore, Comyns Berkley (14) states that "up to the present time we find no cases recorded with spirochæta pallida in the tissues affected with esthiomene."

The treatment instituted was the complete removal of the growths with the sliding of skin flaps to cover denuded areas. The condylomatous or ulcerated areas were thoroughly cauterized with the actual cautery. Closure was effected by the use of interrupted silkworm-gut sutures. The after-treatment was vigorous antisyphilitic medication.

Cases 1, 3, and 4 were seen March 18, 1918.

Case 1 showed, four months after operation, although she had discontinued the antisyphilitic medication which was administered during her sixteen days in the hospital, a complete healing and a fairly normal vulva. The condylomatous growth was smaller; no raw surfaces nor any discharge.

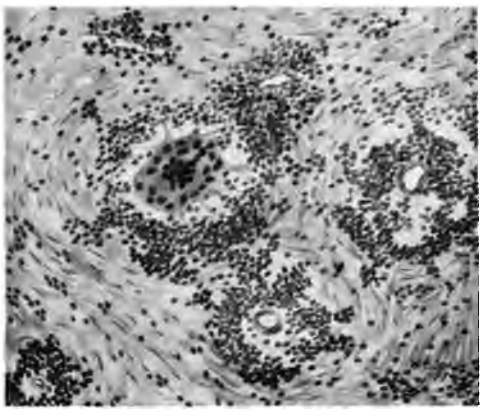

Fig. 6. Syphilitic induration of the vulva, showing hyperplasia of the connective tissue, many mononuclear lymphocytes, especially around the new formed capillaries, and a characteristic giant cell.

Case 3 had discontinued treatment also and showed no improvement other than the absence of the tumors. There were raw areas in the former sites and at the place of removal of the growth. Her Wassermann was again taken and showed a 3+.

Case 4 was given in addition to the mercury and iodides to the point of tolerance, one injection of 0.6 gm. diarsenal. After dismissal from the hospital she reported regularly for treatment. Although but one month had elapsed there was almost complete healing. The unhealed portion showed a distinctly healthy appearance. The region of the anus did not look so promising.

It is my belief that a radical removal of the growth with a complete and thorough cauterization of the ulcerated areas—cauterization a second time if need be—with intensive antisyphilitic medication will effect a cure in these cases.

REFERENCES

1. Schnitzler, J. Wein. klin. Rundschau, 1895, ix, 165.
2. Ravogli, A. Lancet-Clinic, 1916, cxv, June 17.
3. Hill. L. L. Surg., Gynec. & Obst., 1915, xxi, 334.
4. Viatte, G. Quoted by Ravogli.
5. Kurz, Lena. J. Obst. & Gynæc., Brit., Emp., xxiii.
6. Kelly. Operative Gynecology.
7. Ravogli. Loc. cit.
8. Manson. Tropical Diseases.
9. Mémoire de l'Academie Med. 1848.
10. Stein and Heimann. Surg., Gynec. & Obst., xiv, 345.
11. Hyde. J. Cutan. & Genito-Urin. Dis., vii, 121.
12. Taylor. N. Y. M. J., 1890.
13. Kurz, Lena. Loc. cit.
14. Eden and Lockyear. Gynecology, 1917, ii, 31.

NEW-GROWTHS OF THE TESTIS

Their Symptomatology, Pathology, Diagnosis, and Treatment[1]

By C. R. O'CROWLEY, M.D., F.A.C.S., and HARRISON S. MARTLAND, M.D., Newark, New Jersey

In looking through the literature upon testicular neoplasms, one is struck by the variety of diagnoses, especially from a pathological standpoint. The classification and description of tumors of the testicle in modern genito-urinary textbooks are so meagre and incomplete, to say nothing of being incorrect, that the writer thought it would be of interest to bring the subject in more or less detail before this society. The reason for such a diversity of opinions in regard to the type of tumor we are dealing with is due to the fact that the growth was not carefully sectioned or studied enough pathologically or it would have been seen, in the greater proportion of cases, that we were dealing with a teratoma. For practical purposes there exists only one tumor of the testicle, namely, a teratoma. The testicular teratoma may appear in two forms, either as a complex teratoma containing tissue representing derivatives of all three embryonic layers, or as an embryonal carcinoma, alveolar or diffuse, polyhedral or rounded cells, often with lymphoid stroma. The latter is the most common tumor of the testicle, and it may or may not be possible to find in such a tumor other evidence of teratomatous elements, but even if no other teratomatous elements are found, it seems reasonable to agree with Ewing in regarding this tumor as a one-sided development of a teratoma. In considering tumors of the testicle, nine times out of ten, we are dealing with a malignant tumor, which requires very early diagnosis and radical treatment in order to prevent metastasis and consequent death. Hence a study of new-growths of the testicle comprises the study chiefly of carcinoma of that organ.

During the past eight years we have collected at the pathological laboratory of the City Hospital, Newark, New Jersey, thirteen cases of new-growth of the testicle, a brief summary of which follows:

Case 1. Age 5 years. Duration 12 weeks.
Case 2. Age 34 years. Duration not traceable.
Case 3. Age 40 years. Duration not traceable.
Case 4. Age 52 years. Duration 2 years, 7 months.
Case 5. Age 43 years. Duration 28 months.
Case 6. Age 39 years. Duration 2 years, 3 months.
Case 7. Age 40 years. Duration 14 months.
Case 8. Age 33 years. Still living after five years.
Case 9. Age 38 years. Duration 6 months.
Case 10. Age 17 years. Duration 10 months.
Case 11. Age 30 years. Still living after one year.
Case 12. Age 45 years. Still living after one month.
Case 13. Age 32 years. Still living after 15 months.

A few points of interest might here be noted. Seven out of thirteen cases that we have been able to follow have already died, developing metastases. Of the fatal cases the youngest was 5½ years, the oldest 52. The longest duration of the disease was two years and seven months, the shortest ten weeks. Six out of the thirteen cases gave a definite history of trauma. Trauma may have been a predisposing or etiological factor in these six cases, and then again it may have been the first thing to draw the patient's attention to the tumor or its increasing size. The size is not dependent upon the length of time the tumor has existed. In one case (9) an undescended testis was the seat of the growth. In the majority of cases the growth was usually slow but progressive.

If we go back to the embryological development of the testicle, you will recall that it develops from the undifferentiated genital ridge or body which is in close proximity to the wolffian ridge or body, the latter a complex structure, which, when it reaches its usefulness, starts to retrogress. In no other part of the body is there such a complex embryological structure, therefore the adrenal, future kidney and testicle which develop in such close proximity to this region are

[1] Final report on paper read before the American Urological Association, Chicago, 1917.

Fig. 1.

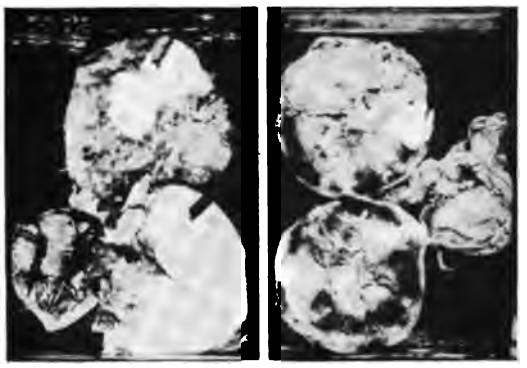

Fig. 2.

Fig. 1. Teratoma testis; this growth would be called in older classifications an "enchrondroma" of the testicle, because it is composed largely of hyaline cartilage. There is no difficulty, however, in finding numerous teratomatous elements in the tumor.

This tumor represents that class of testicular tumors in which teratomatous elements are found with ease.

Fig. 2. Teratoma testis; showing two specimens of the *common* testicular tumor. Both tumors consist almost entirely of alveolar, embryonal carcinoma with lymphoid stroma. It is only with great difficulty that other types of tissue can be found. The tumor metastases are carcinoma. Even if teratomatous elements can not be found, as often occurs, Ewing believes that such a tumor is a one-sided development of a teratoma.

These tumors represent the larger class of testicular tumors where the growth is always an alveolar, embryonal carcinoma with lymphoid stroma and in which other teratomatous elements are found with difficulty or not at all.

subject to weird embryologic processes, which result in the various complex and mixed tumors encountered in the adrenals, kidneys, and testicle.

It is through the lymph channels that metastases occur, chiefly in the retroperitoneal and lumbo-aortic nodes. The growth metastasizes as carcinoma and not as teratoma. Recurrences have occurred as early as one month following operation. Howard found that among 110,000 male patients admitted to a number of the London hospitals during a period of twenty years, there were 65 cases of malignant testicular disease, or about .06 per cent of all male patients admitted. Of 57 cases with complete histories, 9 were in ectopic testicles, 8 of these being in the inguinal canal and one just below the external ring. In 12,729 consecutive male admissions to the Presbyterian Hospital in New York City there were found 13 malignant testicular tumors. Of these, 11 were situated in the scrotum and 2 within the abdomen. Thus in 182,729 male admissions to general hospitals there were 3 cases of malignant growths of intra-abdominal testicles, or about 1 in each 60,000 cases. With such statistics it seems no more than right that we should report all cases. Coley, during the past twenty-five years, has personally observed 65 cases of sarcoma of the testicle. In 52 the disease occurred in the entirely descended testicle, and in 12 in the undescended. Seventy-five per cent occurred between the ages of twenty-five and forty-five.

CASE 1. A. B. Age 5. Well nourished, always healthy. Parents noticed a swelling of right testis which increased rapidly, reaching the size of a small hen's egg in one month's time, with involvement of the inguinal nodes and overlying skin. The tumor was removed at operation with three enlarged lymph nodes and structures extending up to the internal ring. The wound healed promptly, but after two weeks there was increasing anæmia, loss of flesh, fever, and prostration. One month later, several firm nodules appeared in the skin of face and neck. With rapidly increasing anæmia, fever, and weakness, the child died two weeks later.

Gross examination. The tumor of the testis measures 3x2½x2½ centimeters. It involves the

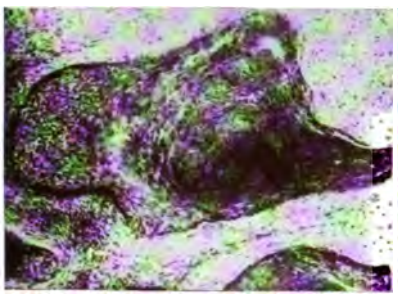

Fig. 3.

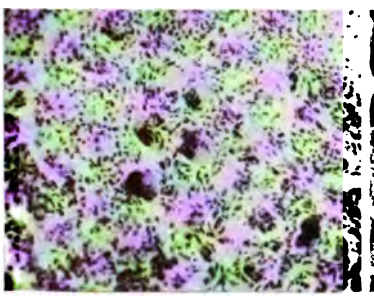

Fig. 4.

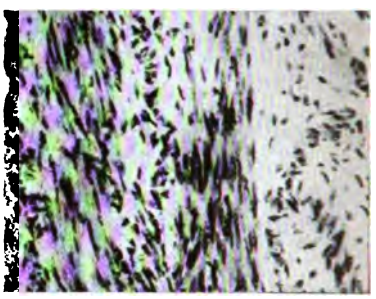

Fig. 5.

Fig. 3. Teratoma testis, showing epidermal tissue.
Fig. 4. Teratoma testis, showing giant-cells of the osteoclast type and small area of hyaline cartilage.

Fig. 5. Teratoma testis, showing smooth muscle. This tissue comes from the middle of a large growth of the testicle.

corpus highmore, rete, and epididymis and fuses their structure with the surrounding tissues. In the overlying skin there is no diffuse invasion. A circumscribed portion of intact testis which is found to be the whole organ lies at the posterior pole of the tumor sharply separated by a fibrous partition. The tumor is firm, well encapsulated, and free from necrosis.

Microscopic examination. The testicular tumor is composed of diffuse areas of small and medium sized lymphocytes. Many cells show distinct cell body. This neoplastic tissue widely separates the intact tubules of the rete and epididymis and invades the neighboring fat lobules. The larger lymph nodes are completely replaced by medium sized tumor cells. In the capsules of the main tumor, the lymph nodes, and in the adherent overlying skin there is a diffuse infiltration by small lymphocytes.

Diagnosis. Lymphosarcoma primary in the rete and epididymis. Metastases in skin, inguinal and abdominal lymph nodes, liver, and kidneys. Duration twelve weeks.

Autopsy examination. Showed extensive enlargement of the retroperitoneal lymph nodes, the largest 1¾ centimeters in diameter. In both kidneys there were areas of diffuse infiltration. The lungs and liver showed several miliary lymphomata. The spleen was moderately enlarged, section smooth, firm, grayish, follicles nearly invisible. Throughout the colon were numerous follicular ulcers. Peyer's patches were slightly swollen. Attached to the peritoneal surface of the colon were several small movable lymphomata.

The histological features of this tumor are in all respects typical of malignant lymphosarcoma. That the original tumor arose in the testis seems a necessary conclusion from the relative size of the tumors, that in the testis being much larger than any of the lymph nodes and showing local out-growths of considerable extent as well as extensions in the overlying skin. The testicular tissue was found free from invasion by lymphocytes, while the rete and epididymis were extensively involved, hence we must conclude that this tumor started in the rete and epididymis rather than the testicle proper (which is the

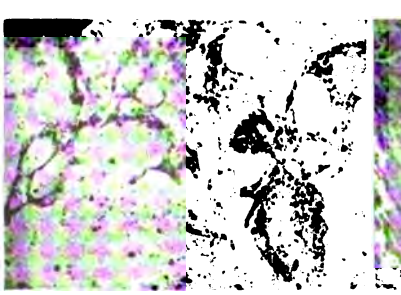

Fig. 6.



Fig. 7.

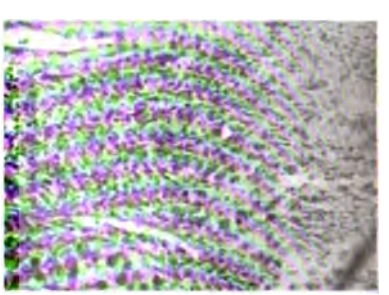

Fig. 8.

Fig. 6. Showing area of hæmangio endothelioma.
Fig. 7. Teratoma testis, showing alveolar, embryonal carcinoma with lymphoid stroma.

Fig. 8. Teratoma testis, showing alveolar, embryonal carcinoma with lymphoid stroma.

starting place of teratoma). No evidence was found of a trace of teratomatous elements.

(This case was studied by Dr. Ewing and described in his excellent paper, "Teratoma Testis and its Derivatives." *Surgery, Gynecology and Obstetrics*, March, 1911.)

CASE 2. M. G., age 34. No tuberculosis or cancer in family. Is moderately alcoholic, negative venereal. Eight years ago he was struck in left testicle by a piece of coal; he says that the testicle did not pain or swell after the injury. Five days before admission to hospital he had severe pain in left testicle, without any apparent cause. He felt along the testicle but noticed no swelling. The next morning he noticed a lump alongside of the left testicle about the size of a small peanut, very smooth, heavy and painful.

Physical examination. All viscera were in good condition. The lungs were negative. In the left half of the scrotum was felt a mass about 2 centimeters in diameter, hard, independent of the testicle but its movement limited.

Operation. An incision was made in the upper part of the scrotum 4 centimeters long, extending upward to the external ring. The epididymis was thickened, and it was drawn down and the vas ligated near the internal ring. In the globus major of the testis there was found a nodular mass, the size of a finger-nail, which encroached slightly upon the testicle. The testicle with its structures was removed. The wound healed promptly and the patient made a rapid recovery.

Gross examination. The testis measures 2.5x2.5x4 centimeters, its tunica albuginea is smooth and glistening, its parenchyma normal. Situated in the globus major of the epididymis and rete testis, but not involving the body of the epididymis, is an oval, firm mass about 1 centimeter in diameter. On section this mass is greyish white in color and there are no evidences of caseation. The rest of the epididymis is normal.

Microscopic examination. The tumor of the rete and epididymis is composed of diffuse areas of small lymphocytes. Many cells show distinct cell body. There are no areas of caseation, or other evidence of tuberculous granuloma. Occasionally there was found small acini lined with cuboidal and flattened epithelium. We do not believe these are the compressed tubules of the epididymis or vasa recti and if they are not remnants of certain embryologic tubules, they might play an important rôle in proving the teratomatous origin of lymphosarcoma.

Diagnosis. Very early lymphosarcoma of the rete and epididymis containing epithelial structures. Duration not traceable.

CASE 3. N. W., age 40. The patient has always been in perfect health. Two years ago he noticed small lump in right testicle, hard, which caused a small amount of pain on pressure. The mass gradually grew until it reached the present size. He had no pain or discomfort except increase in weight of testicle.

Operation. The testicle was removed, the epididymis appeared only slightly thickened in the globus major. The wound healed promptly and the patient quickly recovered.

Gross examination. The specimen consists of a solid tumor of the left testis measuring 6x6x9 centimeters, of firm consistency. On section the tumor cuts quite hard and is well confined to its tunica albuginea, which is thickened and laminated. The greater part of this tumor shows oval, round, and irregular branching masses of a pearly white color (cartilage). Numerous cavities from 1 to 4 millimeters in diameter filled with a colloid material of greyish to brown color are seen scattered over a large portion of the tumor. Two large cavities 1 centimeter in diameter contain yellowish colored colloid. The epididymis is not thickened.

Microscopic examination. The main part of the tumor is composed of irregular islands of hyaline cartilage. There are also present bundles of smooth muscle, considerable lymphoid stroma, areas of fibrosarcoma and a few scattered epithelial lined cavities with low cuboidal cells. Some of the larger cavities contain colloid material, resembling thyroid acini.

Diagnosis. Teratoma testis containing cartilage, smooth muscle and lymphoid tissue.

CASE 4. J. H., age 52. During the last two years the patient has noticed a slowly growing tumor of the right testis, which during the last two months has grown rapidly reaching its present size and causing considerable pain. For the last six months has lost weight and feels exceedingly weak.

Examination on admission to hospital. The patient is extremely emaciated, dyspnœic and weak. A large tumor is present in right half of scrotum, with nodular masses along cord and in inguinal canal. Considered inoperable.

Result. Died one month after admission, and autopsy showed extensive masses in retroperitoneal glands, and metastatic nodules in lungs and liver.

Gross examination. The specimen consists of a solid tumor of the right testis, measuring 7x7x8 centimeters. On section, the lower half shows oval, round, and irregular masses of cancer, yellowish in color and surrounded by fibrous trabeculæ; the upper half shows extensive necrosis with hemorrhagic extravasation. Normal testicular tissue cannot be found. The epididymis and cord are extensively involved with solid carcinoma.

Microscopic examination. The large part of the tumor is composed of large celled alveolar carcinoma with extensive areas of necrosis. There are also small areas of cartilage, fat and smooth muscle tissue. In places there is extensive lymphoid infiltration of the stroma.

Diagnosis. Teratoma testis, showing large alveolar carcinoma (sarcoma), fat and smooth muscle

Fig. 9. Case 6.

tissue, minute islands of cartilage, with extensive necrosis.

CASE 5. T. C., age 43. No cancer or tuberculosis in family. The patient has always been well, but nervous. Eight years ago he had vague stomach trouble. He denies venereal diseases and excesses.

Present history. One year ago, while stirring varnish with a big stick, he noticed a sharp pain in left inguinal region, shortly after which the left testicle began to swell. The swelling gradually became larger and firmer in consistency.

Operation. Orchidectomy, tumor of the size of an orange removed with small amount of epididymis and vas. Recovery was uneventful, with primary union in wound.

Result. Three months later, after sea bathing and considerable swimming, the patient complained of a severe chill; the next day noticed a hæmatoma in site of scar. The old scar soon broke down, with considerable oozing, and a second operation was done, removing an elliptical mass including the scar tissue and cord and vessels up to the internal ring. At the present time the wound has healed again, but in the inguinal canal near the internal ring is a nodular mass. Otherwise his health is fair. We expect this case to develop metastatic growths. Within three months he had another recurrence in same site which rapidly became tremendous in size. The patient became rapidly emaciated and cachectic and developed metastatic growths.

Gross examination. The specimen consists of a solid tumor of the left testis, measuring 5x7x7 centimeters. The tumor is well confined in its tunica albuginea, but invaded the mediastinum, rete testis, and globus major of the epididymis. The cord above is not thickened. On section the tumor presents a variety of areas, some yellowish in color (carcinoma), others shades of red (hæmorrhage). A very few minute areas of pearly white color (cartilage) can be seen near the center. Scattered over various portions can be seen small cysts 2 to 4 millimeters in diameter containing colloid. No trace of testicular tubules can be seen. The whole tumor is quite œdematous.

Microscopic examination. The tumor is composed largely of very œdematous embryonal connective tissue, which in places is so cellular and packed that it may be called fibrosarcoma and small spindle sarcoma. Scattered in the stroma are numerous collapsed and distended cavities lined with low cuboidal epithelium; some of these contain a colloid material and appear to be thyroid tissue. Numerous areas are present, composed of alveoli of large polyhedral cells with large vesicular nuclei and scant cytoplasm; the stroma around these areas is frequently infiltrated with lymphocytes.

Diagnosis. Complex teratoma with cartilage, thyroid tissue, epidermoid cysts, smooth muscle, lymphoid tissue, glandular structures, lined with cuboidal and cylindrical cells, alveolar and diffuse carcinoma. Duration 18 months.

CASE 6. T. K., male, age 30. The past history is uneventful. Two years ago the patient was hit in the scrotum on right side; soon after a mass developed which gradually increased in size. Two weeks before admission to the hospital he had sharp pain in the right lower quadrant of the abdomen. He has had pain more or less ever since, often shooting down the right leg. The pain eases when lying down.

Physical examination shows a poorly nourished, anæmic man, with a few fine and coarse râles over the lower lobes of both lungs. In the right half of the scrotum is a large firm mass 15 centimeters in diameter, with distended veins running over the tumor. The urine and blood are negative.

Operation. The tumor with the adjacent structures was removed.

Result. The patient became rapidly emaciated after the operation, and developed on the seventh rib in the left axillary line a slightly movable hard mass 3x5 centimeters, apparently connected with the rib. He died three months after the operation with physical signs of bronchopneumonia and cachexia and extreme weakness.

Gross examination. The specimen consists of a large solid tumor of the right testis, measuring 9x12x14 centimeters, in some portions quite solid, in others there is a sense of fluctuation. The tumor is well confined by its tunica albuginea, is heavy and solid. The cord is only slightly thickened. On section the tumor has a yellowish color, and shows considerable areas of necrosis and hæmorrhage. In places bright yellow (fat) masses from 1 to 4 millimeters can be seen; also cartilage areas about the same size. The large portion of the tumor is distinctly carcinomatous.

Microscopic examination is of interest because the tumor is largely composed of carcinoma, which has an arrangement in mantels around a central capillary, a "perithelial carcinoma." In many respects this tumor appears like portions of hypernephroma. Teratomatous elements are difficult to find, but are present in the form of cuboidal lined epithelial structures, small islands of cartilage, fat tissue, and smooth muscle.

Diagnosis. Teratoma testis, consisting chiefly of perithelial and alveolar carcinoma with lymphoid

stroma. Cuboidal epithelial structures, small islands of cartilage and adipose tissue, smooth muscle. Duration, two years, three months.

CASE 7. F. A., age 40. Past history and family history are negative. The patient noticed a tumor in the right half of the scrotum eight months ago. He has lost considerable flesh and strength and complains of dull aching pain in the right iliac region. He gives no history of trauma. He was under doctor's care four months before he came to hospital.

The physical examination is negative.

Operation. The usual incision was made, and the tunica vaginalis was found markedly thickened, and there were several small nodules felt along the cord. The cord was freed well above the internal ring, pushing the peritoneum away, it appeared normal and was ligated. No inguinal or femoral glands were palpable. Primary union in wound, but the patient had an afternoon temperature reaching 102° F., off and on for several days. He received 21 injections of Coley's fluid.

Result. Three months after operation the patient complained of indefinite pains in the abdomen, under the ribs and over the back of the chest. On examination he was quite dyspnœic; no local recurrence of palpable masses was found. Two months later, a mass the size of a duck's egg developed on the left side of the neck just above the clavicle. There was found an indefinite sensation of a mass near the umbilicus, with small areas of dullness plus fine râles scattered over both lungs. He was cachectic, markedly emaciated, and extremely weak. He died one month later.

Gross examination. The specimen consists of a solid tumor of the right testis measuring 4x6 centimeters, oval, quite firm in consistency, and on section yellowish in color. It is quite well confined to the testis except at its inferior pole where it infiltrated the tunica albuginea and tunica vaginalis. There is a small clot of blood in the cavity formed by the tunica vaginalis. The latter is quite thick over the adherent area. On section the tumor is composed of round and oval masses of cancer, 1 millimeter to 2 millimeters in diameter, there is extensive infiltration of the mediastinum, body, and globus major of the epididymis. The vas shows carcinoma for at least 6 centimeters above the testis.

Microscopic examination. Sections made from the center and edges of the growth show it to be composed largely of large alveolar celled carcinoma containing large vesicular nuclei, well defined nucleolus, and scanty cytoplasm. In many places a typical picture of adenocarcinoma is seen; in other areas diffuse carcinoma with lymphoid stroma. In addition there are frequent bundles of smooth muscle and small lymph nodes with germinal centers and large areas of necrosis.

Diagnosis. Teratoma testis, adenocarcinoma, alveolar and diffuse carcinoma, lymph nodes, epithelial structures, and thyroid. Duration 14 months.

CASE 8. A. G., age 33. Family history and past history are negative. Without any apparent cause two and one-half months ago an enlargement started in the right side of the scrotum without pain or other symptoms. The patient gives no definite history of trauma.

Operation. The radical operation was done. A celluloid testicle was inserted for cosmetic effect. Recovery uneventful.

Gross examination. Solid tumor of the right testis measuring 4x6x6 centimeters. The tumor is well confined in the tunica of the testis; the tunica vaginalis and epididymis are not involved. On section, hard, yellowish and grey in color, rather broad connective trabeculæ traverse tumor. A very small amount of compressed testicular tissue is seen at the lower pole lying just beneath the tunica albuginea.

Microscopic examination shows the tumor to be composed of large-celled alveolar carcinoma with lymphoid stroma and areas of necrosis. No other types of tissues were found.

Diagnosis. Carcinoma with lymphoid stroma.

CASE 9. T. W. L., age 38. Family history, past history, and personal history, negative. The patient has always been well but states that he never had but one testicle in his scrotum and that he was conscious of the presence of the other one low down in his groin. Three months ago while attempting to move a large piano he felt a snap in his left groin and when he felt of himself there he noticed he had two testicles in his scrotum, but the one on the left side was high up and much smaller. He complained of very little pain at the time but in a few weeks this left testicle started to enlarge and was quite painful, due mostly to the pulling on the cord.

Physical examination. A powerfully built, tall, and healthy looking individual. Tight up against the external ring on the left side was a firm mass the size of a small orange.

Operation. Orchidectomy.

Result. The wound healed promptly and the patient went home from the hospital in about two weeks. Within a month he started to fail, rapidly losing flesh and strength, and showed clinical evidences of metastases. He died six weeks later.

Gross examination. Solid tumor of left testicle measuring 9x9x4 centimeters, confined within tunica. No remains of testicular tissue are seen. On section, encephaloid, red and yellow areas are intermingled.

Microscopic examination. Carcinoma, alveolar, embryonal with areas of lymphoid stroma, extensive necrosis and hæmorrhage. Areas of cystadenoma. Epithelial glandular structures and smooth muscle.

Diagnosis. Teratoma testis (in an undescended testis). Carcinoma with lymphoid stroma. Cystadenoma. Epithelial structures, glandular. Smooth muscle. Duration, 6 months.

CASE 10. H. D., age 17. Family history, previous history, and personal history, negative. For the past five months the patient has noticed a

swelling in the right half of his scrotum which has slowly increased in size. There is no history of trauma. He complains of slight dragging pain, probably due to the weight of the tumor.

Physical examination reveals a well-nourished young man, with all viscera negative except the right testis, which is enlarged to about the size of a small orange. No translucency to light. Has firm feel.

Operation. Radical operation done.

Gross examination. Solid tumor of right testicle, measuring 11x6x5 centimeters. On section, the growth is soft and in places mottled reddish to greyish color.

Microscopic examination. Carcinoma with lymphoid stroma. Considerable myomatous tissue. Fibrosarcomatous areas. Small scattered amount of smooth muscle.

Diagnosis. Teratoma testis. Carcinoma with lymphoid stroma. Myoma. Fibrosarcoma. Smooth muscle.

Result. Four and a half months later the patient showed clinical evidences of metastases in the liver and lungs and died shortly after. Duration 10 months.

CASE 11. P. U., age 30. Family history, past history and personal history, negative. Two months ago while doing some gymnastic work he fell astride of a horizontal bar and that same evening he had some little pain in his right testicle. In a few days he was apparently well but about a month later his right testicle started gradually to increase in size, but with no pain.

Physical examination was negative except for a tumor mass in the right half of his scrotum.

Operation. The radical operation was done.

Gross examination. Solid tumor of the right testicle measuring 9x5x4 centimeters. Quite firm. On section, yellowish to greyish white.

Microscopic examination. Carcinoma, alveolar, embryonal with lymphoid stroma. Considerable fibroplastic tissue.

Diagnosis. Teratoma testis. Embryonal carcinoma with lymphoid stroma. Duration: patient at present writing (August 24, 1918) is alive and apparently well.

CASE 12. F. B., Male, age 45. Past history, personal history and family history negative. No history of trauma. The patient noticed a small lump in the right testicle two months ago, which has steadily grown in size until the present time.

Physical examination was negative except for a tumor mass in the right half of scrotum. No glandular involvement palpable.

Operation. Orchidectomy with removal of adjacent structures.

Gross examination. Solid tumor of the right testis 3x4x2 centimeters, tumor confined within tunica of testicle, tunica vaginalis and epididymis not involved. On section, greyish white and reddish in color. Distinctly cystic, about the consistency of a rubber sponge.

Microscopic examination. Tumor composed chiefly of adenomatous areas with cystadenoma, histologically benign. Small areas of hyaline cartilage and smooth muscle.

Diagnosis. Adenoma simplex, cystadenoma, cartilage, and smooth muscle. Teratoma. Duration: at present writing (August 24, 1918) patient is alive and apparently well.

CASE 12. G. K., male, age 32. Past history, family history, and personal history, negative. The patient thinks he was struck by a baseball in the scrotum a few years ago. He now has a swelling in the left side of the scrotum which has been gradually increasing in size for three or four months. The tumor gave no pain or light translucency.

Operation. Orchidectomy with adjacent structures.

Result. Patient made an uneventful recovery but four months later he presented himself with a growth in the site of the operative scar two-thirds as large as the original tumor. He refused further operation.

Gross examination. Solid tumor of the left testicle measuring 5x6x3.5 centimeters. On section, greyish red in color with small cystic areas.

Microscopic examination. Adenocarcinoma chiefly and small areas of carcinoma with and without lymphoid stroma, few epithelial structures.

Diagnosis. Teratoma testis, adenocarcinoma, alveolar carcinoma, lymphoid stroma, epithelial structures.

DIAGNOSIS

As a rule the patient seeks advice on account of a swelling in either side of the scrotum, which he has probably noticed for months, and the increase in size has been very gradual. Pain is usually absent, unless the tumor is large enough to give a dragging sensation from its weight. The tumor may range in size from that of a horsechestnut to that of a cocoanut, being ovoid in shape. There may be soft, semi-fluctuating areas, due either to degeneration of tissue in one part or another, or to rupture of blood-vessels within the growth producing a hæmatoma, or to both. The surface outline as a rule is well defined, smooth, and slightly lobulated. In large tumors, the epididymis is flattened out by pressure and finally becomes invaded by the growth. The tumor may feel hard or semi-solid, except when it has an associated hydrocele. The very large growths have a tense, elastic, cystic feel. The surface blood-vessels are greatly dilated and tortuous. The growth itself is non-translucent and

freely movable. Further examination very seldom reveals much of diagnostic value, the blood, urine, etc., has usually been negative.

Differential diagnosis. New-growths of the testicle are to be differentiated from tuberculosis and gumma. In tuberculous lesions, the family or personal history is of help, the growth is insidious in onset, increases in size more rapidly, is associated with pain, sometimes fever. The growth first manifests itself as a nodular mass in the tail of the epididymis. Often a chain of small nodules can be felt along the vas deferens. It is only later on in the disease that the testis in involved. Tubercle bacilli may be found in the urine, also indurations about the prostate and vesicle. Testicular tuberculosis is usually only one feature of a general genital tuberculosis. Testicular tuberculosis has recrudescences and exacerbations, suppuration, softening, breaking down, and fistula formation.

In gumma is a history of syphilis either hereditary or acquired, the testicle is evenly enlarged with a "clam shell" epididymis and nearly always has an associated hydrocele. Positive Wassermann is of help.

PROGNOSIS

The mortality is very high and Chevassu reports that of 100 cases treated by castration, 81 died, 19 recovered.

Died within 1 year	38
Died within 2 years	17
Died within 3 years	9
Died within 4 years	2
Date uncertain	15
	81

Of the writer's thirteen cases seven died as follows:

Within 1 year	3
Within 2 years	2
Within 3 years	2
	7

TREATMENT

The majority of surgeons who have operated upon these growths have done little more than castration and excision of the cord. Such a minor procedure may be sufficient in those cases where a very early diagnosis is made; in other words, before there is an invasion of the regional glands.

The only hope surgeons can have of decreasing so appalling a mortality as we have in this disease is not only early recognition of the trouble, but its removal by the radical operation. Gregoire in 1905 performed the first complete radical operation and since then there have been but few cases reported. The mere fact that we get such a high mortality from recurrence in cases of orchidectomy, where we felt the regional glands clinically gave no evidence of involvement, while in truth the microscopical examination would invariably reveal an invasion by the growth, is sufficient to justify the radical operation in every case.

Coley believes that his own series of cases show that cancer of the testis treated by simple orchidectomy, without any appreciable risk, and followed by a thorough course of treatment with the mixed toxins of erysipelas and bacillus prodigiosus (also without risk) has a far better prognosis than that subjected to the very extensive laparotomy with removal of the lumbar glands, as advocated by Chevassu, Hinman, and others.

OPERATION

The incision which has been most often employed to allow of removal of the testicle and cord and to give access to the lumbar glands commences over the upper part of the scrotum, extends up to the external ring, along the inguinal canal, and is prolonged to a point half an inch above the anterior superior spine; the incision then curves upward until it reaches the costal margin at the level of the tenth rib. At the beginning only the first part of the incision to the external ring is made and the testicle and cord are dissected free. If there is any doubt as to the diagnosis, the testicle should be incised at this point. If malignant disease is present the operation is continued. The incision is prolonged in the direction defined above and carried through the muscle of the abdominal wall until the peritoneum is reached. The cord is traced until it passes

through the internal abdominal ring, and then while the sides of the incision are strongly retracted, slight tension is applied to the cord so that its further course may be easily recognized. In its retroperitoneal course the vas is adherent to the posterior aspect of the peritoneum, and the next stage in operation consists in freeing the cord and reflecting the peritoneum mesially. The cord is traced down well into the true pelvis and there divided between two ligatures, the cut surface being treated with the cautery or pure carbolic. This may be regarded as the first stage in the operation and requires no extraordinary care. The second stage consists in the free dissection of the fascia over part of the iliacus and psoas muscle, together with the contained spermatic vessels and lymphatics, and the removal of the glands from off the inferior vena cava and aorta. When the vas has been divided the spermatic vessels are seen no longer to form a rounded bundle but to become spread out. It is therefore necessary to make a wide dissection of the fascia on the outer side and this should extend to the outer border of the psoas. On the inner side the line of division of the fascia should pass mesially so as to cross the common iliac at its bifurcation; the ureter will here be encountered and must be freely exposed. The dissection is then carried along the inner side of the common iliac vessels up to the bifurcation of the aorta. When the left testicle is affected the inner boundary is carried up along the right border of aorta, and special care must be taken not to injure the inferior mesenteric artery. When the right testicle is the seat of the tumor, the inner border is continued over the middle of the aorta. In both cases the upper limit is the upper border of the renal veins. Between these boundaries everything must be removed. During the dissection the spermatic vessels are traced up to their junction with the main vessels and must be ligated and divided. When all bleeding points have been secured the peritoneum is allowed to return into position and the abdominal wound is closed without drainage, each of the muscles being stitched up separately.

REFERENCES

Aschoff. Pathologische Anatomie. Jena: 1909.
Barrington. Lancet, Lond., 1910, Aug. 13.
Bland-Sutton. Practitioner, Lond., 1907, lxxix, Dec.
Bulkley. Surg., Gynec. & Obst., 1913, xvii, 703.
Butt and Arkin. Surg., Gynec. & Obst., xvii, 703.
Caron. Am J. Urol., 1913, ix, 483.
Chevassu. Rev. de chir., 1910, xli.
Coley. Ann. Surg., Phila., 1915, July.
Cooke. John Hopkins Hosp. Bull., 1915, June.
Davies. Lancet, Lond., 1912, Feb. 17.
Downes. Tr. N. Y. Surg. Soc., 1918, Feb. 27.
Eisendrath. Ann. Surg., Phila., 1916, lxiv, 324.
Ewing. Surg., Gynec. & Obst., 1911, xxii, 243.
Foulerton. Lancet, Lond., 1905, Dec. 23.
Glaserfeld. Ztschr. f. Krebsforsch., 1910, ix, No. 3.
Gregoire. Arch. gén. de chir., 1908, July 25.
Hinman. J. Am. M. Ass., 1914.
Houguet. Tr. N. Y. Surg. Soc., 1918, Feb. 27.
Howard. Lancet, Lond., 1910, Nov. 12.
Howard. Practitioner, Lond., 1907, lxxix, Dec.
Jamieson and Dobson. Lancet, Lond., 1910, Feb. 19.
Michon. Ibid.
Morris. Lancet, Lond., 1912, Mar. 9.
Most. Arch. f. path. Anat., etc., Berl., 1898, xliv.
Nicholson. Guy's Hosp. Rep., 1907, lxi.
Osler. Lancet, Lond., 1907, May 25.
Panchet. Arch. prov. de chir., 1910, xix.
Pringle. Lancet, Lond., 1913, Jan. 14.
Roberts. Ann. Surg., Phila., 1902, xxxvii.
Wolbarst. J. Am. M. Ass., 1907, Apr. 6.

THE RADICAL OPERATION FOR TERATOMA TESTIS

WITH THE REPORT OF FIVE CASES

BY FRANK HINMAN, A.B., M.D., F.A.C.S., SAN FRANCISCO, CALIFORNIA

TERATOMA testis treated by simple castration is a highly fatal disease with a final mortality of over 85 per cent (1). The desirability of any method of attack that will give better results is obvious. The surgical problem was reviewed by the author in 1914 and summarized as follows:

"Cancer of the testicle metastasizes in practically every case first and primarily to a limited zone of lumbar lymph-nodes which lie on the aorta for the left testicle and on the vena cava for the right, between the bifurcation of these vessels and the renal pedicle (Fig. 1). Communication between these two groups and to deeper or more distant glands occurs only secondarily.

"Involvement of these primary lymph-nodes may occur early or late, and the preoperative duration of the tumor in the testicle, its rapidity of growth or its size give no definite clinical indication of the onset or extent of such metastasis, but the probabilities increase the longer the duration and the more rapid the growth.

"The primary lymph-nodes are a very imperfect guard against secondary invasion, and metastasis to other gland areas by way of efferent lymph channels, or by blood-vessels to thoracic or abdominal organs, may occur early. Surgical treatment is of no avail after these secondary metastases have occurred. The only hope, therefore, in a radical operation is the removal of the testicle with its primary lymph area before the disease has spread beyond this zone.

"The experience of various surgeons in a total of 46 cases has demonstrated in suitable cases the feasibility and technical ease of the radical operation with a combined surgical mortality in all cases of only 11 per cent (3 deaths from pneumonia, 2 from peritonitis).

"Radical operation should never be undertaken when lumbar metastases are recognizable clinically, and is applicable only in the fairly early cases in which the disease is apparently limited. Owing to the deep position of the glands, these cases cannot always be differentiated before operation, so that every case, in which clinically there is no invasion, is suitable for radical treatment. The operation should never be performed until after the diagnosis is confirmed (by gross inspection after castration).

"Sufficient time has not elapsed and the cases are so scattered that it has not been possible to get the ultimate result in all of the patients treated radically. Forty-six per cent are alive; one for five years; one for four years, five for almost three years, two for over two years and eleven for one year or less. There is a probable cure in at least four cases which had lumbar glands invaded with cancer at the time of the operation. Simple castration could not have benefited any of these cases, and their cure is directly attributable to the early and clean removal of the affected lymph area.

"In conclusion, therefore, it may be stated that the early removal of the testicle with its primary lymph zone is the rational method of surgical treatment of teratoma testis; but the extensive nature of the operation and the fact that almost one-third of the cases thus treated were found to be inoperable warrants a very careful selection of suitable cases."

Since its publication this conclusion has been both supported and questioned. A recent criticism appears in Cabot's *Modern Urology*,[1] in a monograph on tumors of the testicle by Edwin Beer: "Even though at present the mortality of this operation is much higher than that of simple castration, experience has shown that such is the case with all new operations. The writer feels confident that during the next decade the mortality from this extensive operation will be markedly reduced. Moreover he believes that we are justified in expecting better end-results when the gland-bearing area is removed. Operations for malignant disease in

[1] Vol. i, p. 540.

other parts surely support this position. The fight against cancer cannot be half-hearted. The surgeon must strike hard or fail in his duty." A pronounced adverse opinion appeared in *Annals of Surgery*, 1915, vol. lxiv. An examination of Coley's claims,[1] that a far better prognosis is secured by orchidectomy when followed by the use of mixed toxins than by radical operation proves disappointing.

The first successful resection of the lumbar gland-bearing area was performed August 26, 1906, by Cuneo of France, who removed four enlarged lymph-nodes one of which showed teratomatous invasion and the man remained well and free of metastasis for 3 years when he was lost from observation. Raymond Gregoire introduced the operation April 20, 1905, in an inoperable case and has since done 5 operations 2 of which have been successful. Maurice Chevassu strongly champions the principles involved and has himself reported 3 cases. The seemingly extensive and dangerous nature of the operation has discouraged its general use. It is significant that from America with its high surgical standards and recognized surgical ability not a single report can be found in the literature of the successful performance of this operation.

It is the purpose of this paper to emphasize the relative simplicity and the real necessity of radical measures, and, by way of demonstration, to report five successful cases; four of whom would certainly have died from metastases if simple castration alone had been performed and in all of whom the operative difficulties were not great and the post-operative complications insignificant.

TECHNIQUE OF RADICAL OPERATION

The operation is done in two parts. In the first a simple castration is performed through a high inguinal incision. The cord is dissected high and divided upon a clamp with an actual cautery. This clamp is left in place for traction on the spermatic vessels in the subsequent procedure. If the gross pathological inspection of the tumor on section confirms a diagnosis of teratoma the second step of the operation is immediately undertaken.

Position of the patient. The position of the patient is of considerable importance in enabling one to get a satisfactory exposure of the pre-aortic area. A medium sized pad is placed under the opposite costal margin. The opposite leg is slightly flexed and the corresponding one kept straight so as to fit the hips in an oblique position. The patient should not be completely on his side but in a position halfway between the lateral and dorsal one. The usual kidney position is too extreme for satisfactory exposure. The arms should be folded in front of the patient and the sleeves pinned together to hold them in this position and the shoulders should be more nearly up and down than the hips. The position is a bent dorso-lateral one.

Line of incision. The incision is so extensive that certain nerve trunks supplying the abdominal muscles and skin areas over the hip, upper thigh and pubic regions are almost always divided. Nevertheless by curving the incision so as to follow the course of the iliohypogastric and ilio-inguinal nerves the larger and more important branches remain uninjured. The incision is extended from the high inguinal one, previously made over the external ring, to a point about 2 centimeters inside of the anterior superior spine following the general direction of Poupart's ligament and then is carried in a curved direction to about 1 centimeter below the tip of the twelfth rib which it parallels for about half its length (Fig. 2). The fascia of the external oblique is divided from the external ring in the course of its fibers (Fig. 3) and from this point the muscle bundles may be split by blunt dissection as they follow closely the direction of the skin incision. The internal oblique, transversalis, and latissimus dorsi muscles are divided with a scalpel in the line of the incision In making this long cut in the muscles the hypogastric branch of the iliohypogastric nerve should not be divided. The iliac branch, however, must be sacrificed. (In

[1] He reports 52 cases of scrotal tumors thus treated only 2 of which (both dead, Cases 9 and 41) showed involvement of the lumbar glands clinically at the time of castration. Of the remaining 50, 18 are dead, 14 have been lost from observation and 18 are living. Of these 18 who are still living 9 have well marked metastases clinically and cannot reasonably be expected to survive. Of the other 9 who show no metastasis clinically Cases 1, 2, and 15 are alive over four years since orchidectomy; Cases 37, 47, and 5, over 3 years; Case 16, over two years and Cases 21 and 25 over 1 year. Excluding the two inoperable cases and the 14 for which results are not stated the remaining 36 show a certain mortality of over 80 per cent while not one of the remaining 20 per cent has lived long enough to be pronounced cured.

none of the four cases has there been any postoperative trouble with constipation from muscle paralysis).

Stripping of the peritoneum. The only difficulty in stripping up the peritoneum is encountered in the lower portion over the iliac vessels, and in the neighborhood of the bladder (Fig. 4). As a rule the spermatic vessels, as well as the ureter, tend to strip up with the peritoneum in this portion. When this occurs it increases the difficulty of a clean dissection considerably. It can usually be prevented by putting gentle traction upon the cord at the time the peritoneum is stripped from along Poupart's ligament so as to keep the cord and its vessels recognizable. The peritoneum by gentle gauze dissection can then be stripped back without carrying the spermatic vessels with it. At the point where the vas deferens passes down behind the bladder the peritoneal boundaries may be with difficulty outlined. This dissection should be carefully completed before proceeding with that above. After the vas deferens has been divided at the point where it disappears behind the bladder, with gentle traction on the clamp holding the cord, the peritoneum usually strips back easily so as to expose the iliac vessels and the aortic bifurcation. The further retroperitoneal exposure of the abdominal aorta is usually not difficult. The gloved hand can be pushed between the parietes and the peritoneal surface, exposing in succession, the psoas muscles with the ureter overlying them, the lower pole of the kidney, and, finally, the aorta and the vena cava (Fig. 5). The peritoneal dissection should be carried high to the renal pedicle. In three cases the largest lymph-gland was found at this level and the subsequent dissection of lymphatic areas is much facilitated by a complete and thorough retroperitoneal exposure. The peritoneum with the abdominal contents behind can be held back with moist gauze sponges beneath broad retractors. In none of the cases was the peritoneum opened, except in Case 4, when in attempting to dissect out the vas deferens in the inguinal region, a small tear was made which was probably due to the fact that stripping of the peritoneum had been attempted high up before this lower exposure had been completed.

Fig. 1. Diagramatic representation of the primary lymph nodes of the testicles. (In Cases 2, 3, and 4, a gland the size of an almond with tumor metastasis was removed from position X.)

Resection of lymphatic areas. This is likewise more thoroughly done in two steps; first, dissection of lymphatic tissues from off the iliac vessels and aortic bifurcation, and second, dissection of pre-aortic lymph areas and spermatic vessels. In every case, as shown in the illustrations, there were masses of lymph tissues lying on the external and common iliacs as far up as the aortic bifurcation. This area had to be cleaned separately from the spermatic vessels. It was easily effected in the four cases by careful blunt dissection with the dissecting scissors, beginning low on the external iliac and working along this vessel to the bifurcation of the aorta. At this point lymph tissues may extend deep down on to the sacrum and care in removing them is necessary in order to avoid injury to the middle sacral artery.

The pre aortic area may be resected in one of two ways: from above downward, or blow upward. With good retraction and complete peritoneal stripping of the area a beautiful exposure is possible. Traction upon the

Fig. 2. Diagramatic representation of line of inci ion (right side) curved to follow general course of long nerves so as to prevent temporary muscle paralysis and the resultant troublesome bowel stasis.

Fig. 3. Diagramatic drawing of external oblique with fibers and muscle bundles split in line of incision. (Left side.)

clamp about the spermatic vessels is of considerable help in effecting a clean removal. The ureter should be carefully dissected free of the fascial coverings and held aside by a narrow tape as shown in (Fig. 5). In most of the cases it was found advantageous to conduct the dissection from below, upward to within a short distance of the renal pedicle, and then complete the removal of the lymph area by freeing at it its upper portion, and dissecting down to meet the former dissection. In two of the cases (2 and 4) the glands and lymph tissues were quite adherent to the vena cava in this area. Frequently there was considerable venous oozing directly from the vena cava when small veins were torn or cut at its surface, but in no instance was there difficulty in thoroughly ligating these points. In some instances a portion of the wall of the vena cava was seized in the clamp and caught afterwards in the ligature. This was particularly noticeable in Case 4 in which the adhesions were most marked. In this case metastasis to the lymph-nodes was extensive, and apparently there were numerous small venules directly from the vena cava supplying them. In all instances, by careful dissection, it was possible to remove the spermatic and lymph areas *in toto*. The spermatic artery can be easily clamped as it issues from the aorta, and the spermatic vein as it enters the vena cava or renal vein, the points being easily found when gentle traction is placed on the vessels.

Drainage. It is, of course, necessary that drainage be placed after the resection of such an extensive lymph area, and this is usually satisfactorily effected by placing a long rubber tube over the aorta down to its bifurcation and curving back above the ilium with exit at the upper back portion of the wound as for kidney drainage. (It would seem feasible in those cases with extensive gland areas and apparent metastases, to place a small rubber tube or catheter in the end of which is fastened

Fig. 4. Drawing, made at time of operation (Case 2 left side), showing lymphatics and fascias along iliacs. Stripping of peritoneum is most difficult at the lower portion where the vas deferens descends behind the bladder. The spermatic vessels tend to strip up with the peritoneum. This is prevented by gentle traction on the proximal end of the cord.

a 50 milligram tube of radium alongside of the rubber drainage tube. In this way the metastatic lymph area could be radiated from above downward by removing the catheter certain distances at intervals of one or two hours.)

Closure. Closure should be in muscle layers and thorough. The lower part is best closed as for hernia. In closing the muscles especial care should be used to avoid including in the ligatures any of the long nerves of the abdomen.

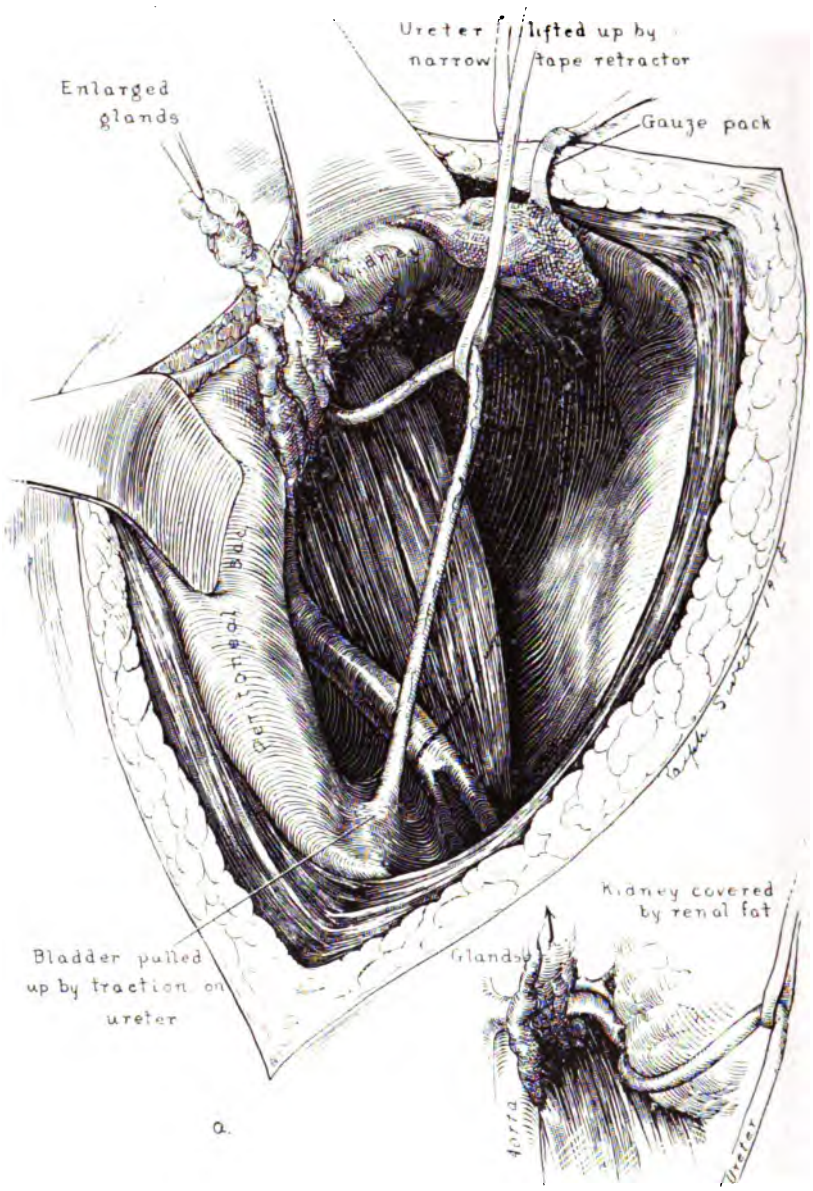

Fig. 5. Drawing showing the dissection of the pre-aortic gland area. (Case 2. left side.) The ureter is held aside by a tape. Insert shows dissection near renal pedicle. (Gland mass should lie upon vena cava between it and aorta and not as drawn.)

REPORT OF CASES

CASE 1. E.L., age 33. (S) Danish. In July, 1915, the patient first noticed that his right testicle was larger and harder than the left. In the spring of 1917 for about one week while the patient was working unusually hard it was quite painful. There is no history of trauma.

The patient's general health has always been good. Neisserian infections at 17 and 19. With the first there was swelling of the left testicle and of the prepuce. After the swelling of the prepuce had subsided the patient noticed a scar on the glans but at this time all blood tests were negative for lues. He has never had antiluetic treatment. Following

Fig. 6. Case 1. *a*, I ymphatic tissue, fat and fascia from the region of the iliacs and aortic bifurcation; *b*, tumor of testicle (much mutilated by pathologist) with lower portion of cord; *c*, spermatic vessels, fascia and glands from the region of the vena cava and aorta.

Fig. 7. Photograph of Case 1 (right side) few days before leaving hospital shows dimpling at upper part of wound where drainage tubes had exit.



Fig. 8. Photograph of specimen removed from Case 2. *a*, Large lymph gland which lay between the aorta and vena cava just below the renal pedicle; *b*, tissues from iliacs and aortic bifurcation; *c*, tumor of testicle and lower portion of cord.

the epididymitis the patient had bilateral buboes which were incised. No complication with the second attack of gonorrhœa.

Physical examination showed a rather well developed and well nourished ambulatory male. The skin was negative except for operative scars in the inguinal regions. Sclera and mucosa, negative. Lymph-nodes negative, except inguinals excised. The head was peculiarly molded. The pupils were circular and equal; react to L. and A. There was an obstruction on the right side of the nose. He had pyorrhœa; much dental work had been done. The tongue protrudes slightly to the left; thyroid negative. Chest: deep anteroposterior diameter with fairly well marked dorsal kyphosis. Lungs: resonant and breath sounds fair. Heart: pulse normal; sounds regular and of good quality; no murmurs. Abdomen; muscular, held tensely. Liver and spleen not felt. *No masses felt.* Reflexes lively. Spine: kyphosis somewhat marked in dorsal region, but mobile.

Genitals: penis circumcised, shows scar on glans from old lesion. Left testicle is of normal size. Left epididymis probably slightly enlarged at lower pole. Right testicle is a tense fairly formed non-painful oval mass 4½ by 6 centimeters with epididymis loosely attached to back of it. No fluctuation. Light not transmitted. No nodulation. There is a cord-like mass at the upper anterior pole which is painful when rolled under the finger. Vas deferens not enlarged. Skin of scrotum is freely movable over the tumor mass throughout.

Owing to the past history a tentative diagnosis of gumma was made. Three successive blood tests were all negative and two salvarsan administrations caused no noticeable change in the tumor two weeks later. The patient was advised of the probability of tumor.

Fig. 9. Photograph of patient, Case 2, taken by Dr. Craig, in Lakeport, after returning home, four months after operation.

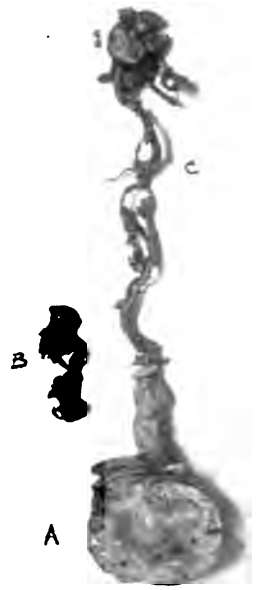

Fig. 10. Photograph of specimen, hardened in formalin, of Case 3, removed in three pieces. *a*, Testicular tumor and lower portion of cord; *b*, loose fibrous lymphatic and areolar tissue from the region of the iliacs and aortic bifurcation; *c*, spermatic vessels and lymphatics from the pre-aortic area. The large lymph gland *d*, with well marked metastasis (seen cut in half and block removed for microscopical sections from upper half) at the upper part of photograph, lay upon and between the aorta and vena cava about 3 centimeters below the renal pedicle.

Operation. December 13, 1917. The high operation for castration was performed. The testicle was enucleated from the scrotum and the cord divided with Pacquelin cautery, as far up in the inguinal canal as possible. The specimen was sectioned and found on gross inspection, in consultation with Dr. Bartlett, surgical pathologist, University Hospital, to be a teratoma. (The gross appearance of these tumors after section is quite characteristic and the importance of being able to recognize testicular malignancy in the gross is evident, if the radical operation is to be performed at the time of castration. Search of the literature reveals nothing upon the surgical pathology of these tumors.) The patient was then turned on his left side and back with a pad beneath the costal margin very much as for a kidney operation and the radical dissection of the pre-aortic lymph area immediately performed as described above.

Fig. 12. (Drawing low power magnification) of region shown in *a*, Figure 11 with cross section of long tubule, and two thyroid-like tubules at side.

Fig. 11. Drawing of cross section of testicular tumor of Case 3 showing its mixed type of architecture. The inserts show the large round vesicular tumor cell on the one side, *a*, and two thyroid gland-like ducts with cartilage formation on the other, *b*. Between is a drawing of the lymph gland shown at the upper part of Figure 10 which has the same malignant structure as the tumor of the testicle.

There was only one macroscopic gland found which lay upon the iliac vessel near that portion where the ureter crossed it. But no effort was made to find palpable glands and remove them singly. Rather was the whole endeavor one of clean complete dissection of the spermatic cord, lymphatics, blood-vessels, nerves, fascias, and fat with all ramifications out over the vena cava, aorta, ureter and the retroperitoneal muscles. There was a rather dense fibrous mass extending along the common iliac from the region where the ureter crossed to the bifurcation of the aorta and this was carefully dissected free from the blood-vessels beneath with the dissecting

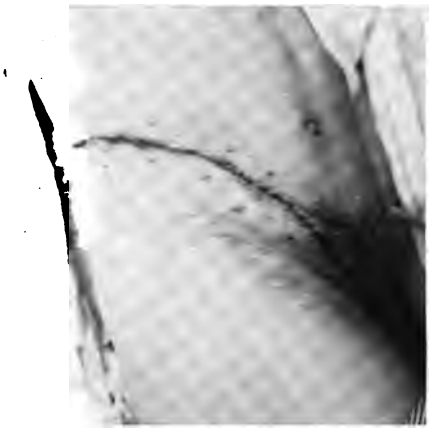

Fig. 13. Photograph of patient, Case 3, two days before discharge from hospital. (Heavy scar appearance due to wound having just been painted with iodine.)

scissors. Stripping of the fascia, the lymphatics and the spermatic vessels along the vena cava above this point was very easily accomplished. At no time was there any extensive hæmorrhage. A photograph of the specimen removed is shown in Figure 6. The peritoneum was at no point penetrated. The patient's condition at the end of the operation was good. Convalescence was uneventful until the twelfth day, when the patient complained of severe pain down the left leg (operation on right side). There was marked tenderness over the femoral vessels and distention of the superficial veins with considerable œdema. There was no rise of temperature. Pain in the leg had practically disappeared in two days but the swelling persisted for several weeks. The patient seen in consultation by H. W. Allen. The condition was attributed to a phlebitis. He left the hospital at the end of three weeks and has been seen several times since then. The soreness in the left leg persisted for a short time but he has had absolutely no tenderness or soreness in the region of his incision (Fig. 7). There has been no abdominal relaxation and during his convalescence his bowels moved regularly and without the need of any special cathartics. The patient was shown before the San Francisco County Medical Society in March and was last seen on June 1, 1918. At this time six months since operation he was perfectly well. The slight stiffness of the left leg has entirely disappeared. He has been working for some weeks. There is no evidence of recurrence locally or retroperitoneally. The abdominal scar is in excellent condition. Pathologic report: teratoma testis, no metastases to gland area found.

CASE 2. R. B. W., age 30, referred by Dr. Craig, Lakeport.

A farmer with a good family and personal history who has lived all his life in California struck his left testicle against the horn of a saddle seven years ago.



Fig. 14. Photograph of specimen of Case 4, which is a pure seminome, *1*, with metastases to large gland at *3*. *1*, Tumor and cord removed at first part of operation; *2*, lymph tissue and fascia from off iliacs and aortic bifurcation; *3*, tissues removed from pre aortic area with large gland about 2 centimeters below level of renal pedicle.

A short time afterward he noticed a small lump on the left testicle which gradually grew until within a year there was a mass twice the size of a normal testicle on this side. The condition remained unchanged until in April, 1917, when after rowing a boat it became painful, and it has since been slowly increasing in size, and is always painful after hard work. For a month there has been a fluctuant sac at the upper portion which has been tapped by Dr. Craig and considerable straw-colored fluid withdrawn. The sac quickly refills and becomes tense 3 to 4 days after tapping. A needle was thrust at the time of the last tapping into the solid lower portion with the discharge of only a few drops of blood. The patient is unusually strong and healthy and physical examination reveals nothing. The abdomen is negative. There is no tenderness nor masses. Reflexes are all active. Blood Wassermann is negative. In the left scrotum is a large ovoid mass 8x14 centimeters in size. The skin over the lower portion is reddened (probably by friction of clothes), but is everywhere freely movable over the mass. The upper portion is fluctuant and translucent and extends as a tense globular mass to the external ring. The vas can be felt at the back. It is not thickened and leads to a softer non-fluctuant mass at the base which appears to be a small remnant of the testis. In between is a third round, firmer, somewhat fluctuant tumor, the outlines of which are indistinct

Fig. 15. Drawing of tumor of Case 4 which is a pure seminal epithelioma and diffuses markedly in gross and macroscopic appearance from the tumors of the three preceding cases all of which are teratomata. Consists of hæmorrhagic and necrotic areas and of masses of active large vesicular cells as shown in inserts *a* and *b*.

because of fluid around it. A tentative diagnosis of hydrocele with either an epididimo-orchitis or teratoma was made. The absence of previous genital infection rendered teratoma likely. The patient was informed of the possibilities and his permission obtained for radical surgery if found to be indicated.

Operation, January 29, 1918. High castration. Cord dissected up into the external ring and divided with a cautery after ligation *en masse*. The testicle upon section showed macroscopically an appearance similar to that of Case 1. Dr. Rusk, the University Pathologist, confirmed the gross pathologic diagnosis of teratoma. The patient was immediately turned on his side upon a small pad and the radical operation performed. There were numerous lymphatic areas along the common iliac. The ureter was dissected free and held up by a tape and these glands with the spermatic vessels and all neighboring fascias cleanly dissected up along the aorta to the renal pedicle. A good exposure of the lower portion of the kidney and the kidney pedicle was obtained and there was an unusually large gland, just in the neighborhood of the renal pedicle which was carefully dissected free as shown in the insert (*b*, Fig. 5). The tumor, cord, glandular tissues and fascia removed are illustrated in Figure 8. There was very little hæmorrhage which was easily controlled and no injury was done to the larger blood-vessels. A long rubber tube was placed down alongside the aorta to its bifurcation and brought out at the back below the twelfth rib. The patient made a speedy and uneventful recovery. There was a slight superficial suppuration in the lower portion of the incision. The patient left the hospital on the twentieth day and has just recently been heard from

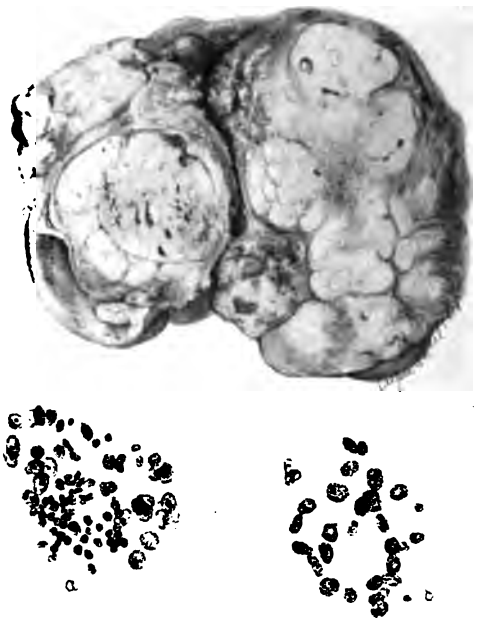

Fig. 16. Photograph of Case 4 taken October 4, 1918. Patient is on active duty in the army and has just received promotion to a majority; scar in excellent condition; no masses to be felt in the abdomen; no back or abdominal soreness.

(8 months after operation), and is apparently perfectly well. Dr. Craig saw the patient in July, 1918, when the photograph, Figure 9, was taken and states that his only complaint is slight stiffness in the left side after riding horseback all day.

Pathologic report. Teratoma testis with early metastasis in large lymph gland. Other tissues negative for metastases.

CASE 3. W. C., age 36, American (M). The patient was born in Michigan, living there till 19 years of age; Philippines and China, 19-22; then California, Philippines, middle West and California, 31-36. He was in the army for about seven years. He has worked as laborer, cook, pipe-fitter, and general handy man. He has had measles, mumps (orchitis), malaria while in Philippines; being in the hospital 2 weeks. He has had a lame back recently. This was helped by use of arch supporters. He had an operation for hemorrhoids when 34. He has had no accidents. He had a neisserian infection when 20, with no complications. A second infection at 23 with complications. Lues: Chancre in 1903. Roseola. Two years of mercury by mouth and then nothing until 6 months ago when patient felt ill and went to a doctor who found Wassermann, 3+. Since then he has received courses of intramuscular and intravenous injections, apparently no arsphenamine. His habits are good. His wife had inflamed ovaries; no pregnancies; one child by previous husband.

Last March while at work the patient slipped and apparently strained himself. The right testicle, which had been atrophied since the patient had the mumps, became swollen and tender. Navy Hospital found Wassermann positive and he was discharged. He was given some desultory local treatment and the above mentioned anti-luetic treatment. The testicle has not grown appreciably since its first appearance.

Fairly well developed and nourished man. His hair was normal. Eyes: Pupils a a; regular reaction to 1 and d. Extrinsic muscles normal. Nose: negative. Mouth: teeth show marked pyorrhœa. Ragged tonsils. Neck: cervical adenitis of moderate degree. Thorax: well clothed. Moves equally on both sides and normally. Lungs: negative. Heart: not enlarged. Sounds clear and regular. No murmurs. P_2A_2 but not accented. Abdomen: negative. Spleen and liver not enlarged. *No masses palpable.* Genitalia: penis shows scars of chancre. Left testicle normal. Right testicle entirely replaced by a tumor mass the size of a goose egg. The mass is smooth, moves freely beneath the skin, is quite hard and not very tender. It does not transmit light and is not fluctuant. Reflexes: patellars hyperactive, Achilles positive.

July 16, 1918. A diagnosis of gumma of right testicle was made and the patient discharged for treatment and observation in outpatient clinic. July 23, patient re-entered the Hospital. Had received 0.6 arsphenamine at the clinic on July 18. Examination on re-entrance showed slight though definite increase in size of the tumor. Its character otherwise was unchanged. July 24, arsphenamine 0.6 intravenously. July 26, blood pressure 125/75. The probability of malignancy was explained to the patient and his consent to operation obtained.

Operation, July 27. An incision was made over the external inguinal ring, the spermatic cord and its accompanying vessels picked up and the tumor delivered from the scrotum. On section the tumor proved to be a teratoma of the testicle. The patient was turned on his side and the radical operation immediately undertaken. A large metastatic gland which was quite adherent to the vena cava was found just under the lower pole of the right kidney. Photograph of specimen removed is shown in Figure 10. Condition of patient on leaving operating room, fair.

July 28, patient feels very sore day after operation. The wound is clean. The drain has oozed considerable blood. August 1, rubber drain removed. August 4, stay sutures removed. Several small stitch infections were touched with iodine. August 5, stitches removed. Drainage at several points along incision. Wound was closing partly *per primam* and partly by second intention. General condition of patient good. August 14, condition of patient splendid. Wound almost healed. August 18, the patient is having pain over chest on both sides near clavicle and also over precordia. No dullness to percussion. A fine crepitus is audible on expiration over small area just mesad to left nipple. The pulse is regular but poorly sustained. The dressings were changed. A small bleb containing serum was opened and treated with iodine. August 24, the patient was discharged. His condition is excellent. The wound healed as shown in photograph, Figure 13. The patient is to report to clinic for antiluetic treatment. He was last seen in my office September 20, 1918, at which time he was in excellent condition, with no abdominal masses.

Pathologic report. Teratoma testis with extensive metastases to large lymph gland. Other tissues negative for metastases.

CASE 4. V. S. P., age 29, male, referred by Major Chidester. His health is excellent. He had pneumonia at 7, typhoid at 13, no operations. He denies venereal disease. About March 1, 1918 the patient noticed that the right testicle which was somewhat undersized up to that time started to grow rapidly to the size of a lemon and was diagnosed hydrocele. There was considerable dragging pain and it interfered with walking. He was sent, for hydrocele operation, to Dr. Chidester, who found a solid tumor upon exposure and on account of not having patient's consent did not do a castration.

Physical examination shows a man weighing 210 pounds; general condition good. Eyes: myopia 20/70; ears, normal; skin and mucous membrane negative; slight bilateral inguinal adenopathy; vascular system, negative; blood pressure, 122–80; heart, normal size, no murmurs, tones good; lungs, chest well formed, good resonance, no râles. Abdomen, negative, no masses palpable. Nervous system normal. Wassermann, negative. In the right side of the scrotum is a tumor about 7x10 centimeters involving testicle. It is hard, rounded, but presents no areas of fluctuation and does not transmit light. The skin over it is freely movable. Vas deferens is not thickened. Epididymis is localized at back of mass. Left testicle, negative. July 14, 1918, he was given prevocative arsphenamine. Wassermann, July 20, 1918, again negative. The probabilities of tumor were explained to patient and consent to operation obtained.

Castration was performed through a high inguinal incision. The tumor was immediately opened and showed uniform transformation into tumor tissue with more or less extensive areas of hæmorrhagic necrosis throughout. It differed from all three former tumors in its soft, pulpy consistency and uniform greyish character.

No testicular tissue could be seen. Diagnosis of seminome was made and radical operation immediately undertaken. A very large gland was removed, as in the two previous cases, from the surface of the vena cava and aorta about 3 centimeters below the renal pedicle. This growth was quite adherent but was successfully removed together with all spermatic vessels fascia, fat, and lymphatics in one piece, Figure 14. It was in this case that the dissection was considerably helped by tying the spermatic vessels at points close to the aorta and renal vein and stripping from above downward to the adherent gland area to meet the previous dissection from below upward.

The patient made an absolutely uneventful recovery and was last seen in my office September 10, 1918. There were no abdominal masses palpable and general condition was excellent.

Pathologic report. Seminal epithelioma with extensive metastases to large lumbar lymph gland. Other tissues negative for metastases.

CASE 5.[1] E. S., age 30; plumber. Except for diphtheria as a boy, the patient has always been healthy. About the end of July or beginning of August, 1914, he struck his right testis with a hammer while at work. He became faint and sick but continued to work after a few minutes of rest. The testis was tender, but not swollen nor discolored. Within a few days it swelled up to about half its present size (that of a small fist), remained stationary for a month, then slowly grew to its present size. He has gained six pounds since the accident, feels well, but is alarmed over the swelling.

October 26, 1914. Examination shows a well built man. Internal organs normal. In the right scrotum there is a pear-shaped, soft, fluctuating swelling the size of a small fist, not tender, not translucent. The diagnosis of hæmatocele was made.

October 27, 1914. Operation at the German Hospital by Dr. Elloesser. A low inguinal incision under novocaine anæsthesia showed a smooth, soft, greyish-white tumor of the testicle, which was covered with dilated vessels. The cord was temporarily tied and the tumor incised. The section showed a greyish nodular tumor whose substance was interspersed with hæmorrhages. The diagnosis was made of a malignant tumor, and this having been explained to the patient a high castration was done. The cord was severed above the external ring at its entrance below the peritoneum. November 10, the stump of the cord is felt as a hard mass the size of a walnut leading up from which the cord is hard and the size of a lead pencil, suspicious of a carcinomatous infiltration. Re-operation is decided upon.

On November 20, the patient was re-operated upon, Dr. Rixford assisting. The incision follows the iliac crest from the upper end of the scar at the external inguinal ring to the lateral border of the quadratus lumborum. The peritoneum is separated from the posterior abdominal wall and the spermatic vessels, which remain attached to it, dissected from it. They are soft and seem normal. Careful examination of the vena cava and the aorta, and the territory between the ureter and the vena cava reveals but one small gland half the size of a bean, situated high up, where the vessels enter the right renal vein. The gland is extirpated and the vessels tied off below and above and removed. The patient is turned onto his back and the scar of the castration excised together with the adherent cord. From the infiltrated cord a nerve runs to the psoas muscle (spermatic branch of the genitofemoral) which is excised to its point of entrance into the muscle. The vas is resected to where it turns back of the bladder, about 2½ inches being removed. There was no bleeding from the retroperitoneum and but little oozing from the muscles. The exposure was excellent. The ureter appeared running through the fat, but was not touched. A small cigarette drain was placed behind the peritoneum and the rest of the wound closed in layers with silk and silkworm-gut. The incision was infiltrated with novocaine, and ether was given. The patient's condition after operation was surprisingly good until evening, when after an attack of vomiting he had a retroperitoneal hæmorrhage. He became alarmingly anæmic and his pulse rate remained high for weeks after. On November 27, the sutures were removed and about a pint of dark blood and blood clots were released from the wound. Following this there was some infection in the wound, but it finally healed without a hernia.

The patient has been examined repeatedly following operation; on January 28, 1918, he was in good health and working hard at his trade. He was shown to the County Medical Society in March, 1918. There is no sign of recurrence 3½ years after operation.

Pathologic report by Wm. Ophuls, Stanford: "Sections of tumor show tissue consisting almost entirely of very large round polygonal cell with large deeply staining vesicular nuclei. The masses of cells are imperfectly subdivided by thin connective-tissue partitions in which there are large blood-vessels. In sections from the proximal end of cord one finds in the vicinity of some of the nerves small accumulations of large cells which to my mind are very suspiciously like tumor cells."

As an illustration of the type of malignancy unsuitable for radical surgery the following case is reported:

CASE 6. Age 37; single. Two months ago the patient noticed that his right testis was beginning to swell. He had always noticed that the right testis was somewhat larger than the left one. The increase in size came on rather abruptly accompained by a slight dull pain. Growth was not associated with traumatism. At about the time that the testis began to enlarge, pain in left lumbar region often referred down into the scrotum was experienced. This pain is most severe when he is standing and disappears upon sitting down. During the last 2 weeks there has been occasional pain in the region of the left hip. There is no recent change in the appearance or size of the left testis. Sexual desire and power normal.

For the past 2 weeks nycturia (3–4) has been present, and within 2 or 3 days he has experienced considerable difficulty in voiding. There is no burning on urination; no incontinence. He has lost 25 pounds in last 2 months. His appetite is good, bowels regular.

Physical examination shows a well developed and fairly well nourished man. Ambulatory. He has

[1] I wish to thank Dr. L. L. Elloesser, San Francisco, for the notes of this case and his courtesy in allowing me to publish them.

dilated veins over cheeks. Scleræ negative. Mucous membranes negative. Hypertrophied submaxillary lymph glands. Posterior cervicals and epitrochlears palpable. Hair, scalp and nose negative. Pupils of eyes equal, regular, react to light and distance. Deaf in left ear. Teeth poorly kept. Tongue protrudes in midline without tremor. Chest well developed. Right chest more prominent than left. Movements equal. Lungs negative. Heart normal in outline, sounds good, quality, regular. No murmurs audible. Spleen not palpable, kidneys not palpable. Few dilated venules over cervical region. Prominence of ribs on left side. Immobility of lumbar spine on flexion, extension, and lateral movements. Extremities negative. Reflexes normal. In the right epigastrium can be felt large hard nodular masses, located midway between umbilicus and symphysis and extending under the border of the rectus. The glands on the right immediately at the external inguinal ring are large and firm. The superficial inguinal glands are small and the deep inguinals are not enlarged. Superficial inguinals are similar to those on right.

Genitalia: right side of scrotum is occupied by a hard tumor mass roughly cone-shaped, with the apex at the right external inguinal ring. The mass is not tender, nor lobulated nor is there any distinct separation of the mass into different portions, but there seems to be a slight change in contour at about its center. The skin is normal over it. No fluctuation present. Does not transmit light, cannot be reduced into abdomen. The epididymis is palpable and seems to be thickened. In the cord and about 2 centimeters from the mass is a small nodule 2 centimeters in diameter attached to the cord, not tender. Dimensions of the mass 12 centimeters long, 7.5 centimeters in width and 24 centimeters at its greatest circumference. Wassermann negative. *X-ray of epigastrium negative.* Prostate normal size. Seminal vesicles not palpated. Suggestion of a mass on right side, can just feel a slight fullness with tip of finger. Orchidectomy with removal of inguinal glands.

Diagnosis: mixed tumor right testicle with retroperitoneal metastases.

Condition of patient on discharge from hospital: There is still an open wound with some slough and discharge. The skin is somewhat reddened about it. The metastases (tumor masses) in the epigastrium remain about the same. The patient has lost 1½ pounds since entry. Discharged February 20, 1917.

Subsequent history: This patient was seen in the dispensary on several occasions during the next few weeks. He continued to lose weight and the abdominal masses gradually enlarged. Death occurred two months after castration.

Autopsy: Enormous metastatic tumor masses in the pre-aortic retroperitoneal space, and nodules in the liver and lungs with same histologic picture as testicular tumor.

Pathologic report. Mixed tumor of testicle, malignant.

It has been possible in each one of these five cases to perform a clean complete removal of the primary lymph zone of the testicle. No great operative difficulties were encountered. A large metastatic gland was removed from the surface of the vena cava in two of the cases with some difficulty on account of adhesions and numerous small blood-vessels. In Case 5 only was there an operative hæmorrhage that could not be immediately controlled.

Convalescence in each case has been practically uneventful. The only complication has been a phlebitis (Case 1) of the opposite leg which has cleared up completely.

These cases, furthermore, give definite and indisputable confirmation of Most's studies of the testicular lymph zone. In three cases (2, 3, and 4) an enormous lymph gland was removed from off the vena cava just below the renal pedicle. In each gland definite metastases were present. Careful pathologic study has failed to discover metastatic growth in other lymph, vascular or fascial tissues removed in these cases. Nevertheless the finding of tumor cells along the nerve trunks of the cord in Case 5 is most significant. The difficulty of microscopic recognition of early lymph metastasis is well known. And although no metastasis has been found in the tissues of Case 1, it does not necessarily follow that simple orchidectomy would have sufficed. Numerous lymph areas which correspond to the primary metastatic lymph zone, so well established experimentally and clinically, were removed. Their removal offers 100 per cent safety by Bloodgood's criteria. A cure in anyone of Cases 2, 3, 4 or 5 will have been due directly to the early and radical removal of metastatic growths. The pathology of these tumors and their metastases is of interest.[1] Only one (Case 4) is a pure seminal epithelioma (seminome), the other four being typical teratomata (teratome). The observation of Dr. Ophuls of tumor cell metastasis along a nerve trunk of the cord in Case 5 has special significance. This mode of transference has been long recognized as not infrequently occurring in tumors elsewhere, as in tumor of the jaw.

[1] It is proposed to give a detailed pathologic study of these tumors in collaboration with Drs. Rusk and Bartlet particularly with reference to their surgical pathology.

The coincidence of a strongly positive Wassermann in Case 3 emphasizes the necessity of close study of all testicular gummata and the wisdom of advising castration for purposes of diagnosis in all instances of doubt.

CONCLUSIONS

1. The radical operation for teratoma testis is justified in suitable cases by the high mortality following simple castration; by the definite experimental and surgical demarcation of the primary lymph zone, and by the possibility of the clean and complete removal of this zone.

2. The radical operation is neither technically difficult, dangerous nor mutilating as is proven by the fact that it has been successfully performed and the primary lymph zone completely removed in five cases of teratoma testis without a single troublesome operative or postoperative complication.

3. These five surgical successes indicate that the mortality from this seemingly extensive operation should be little if any greater than that following castration. All five cases enjoy perfect health now 9 months, 7½ months, 4 months, 3 months, 2 months and 3 years and 6 months, respectively, since operation.

4. The ultimate result in these five cases cannot be known for years. But the finding in four cases of metastatic tumor tissue in the lymph areas radically removed demonstrates the uselessness of simple castration and the necessity of radical surgery. A cure in any one of the four certainly, and possibly of the fifth, will have been directly due to the early and clean removal of the gland-bearing area.

REFERENCES

1. KOBER, G. M. Sarcoma of the Testicle. Am. J. M. Sc., 1899, cxvii, 535. Gives 80 per cent mortality in a 3 year time limit in 113 cases collected from the literature.
2. CHEVASSU, MAURICE. Tumeurs de testicule, Thesis de doct., Par., 1906. Gives 81 per cent mortality in a 4 year time limit in 100 cases.
3. HINMAN, FRANK. The operative treatment of tumors of the testicle. J. Am. M. Ass., 1914, lxiii, 2009. Gives 15 deaths in 18 of the Johns Hopkins Hospital cases in which the ultimate result is known and the pathologic diagnosis confirmed. The three cases are alive, 16 months, 12 and 13 years respectively. Of the other 6 cases, in which the ultimate result is known but the pathologic material was not available for personal study, five are dead and one living, 12 years. One case died of "abdominal cancer" 9 years and 7 months; and another, 8 years after castration which indicates that a 3 and 4 year time limit are too short. The series gives a certain mortality of 87 per cent.

SPLENECTOMY IN DISEASES OF THE SPLEEN

Reporting Four Operative Recoveries

By E. M. PRINCE, M.D., Birmingham, Alabama
Gynecologist and Surgeon, South Highlands Infirmary

OF the many diseases which seem to depend on some disordered secretion from the spleen, none is more interesting than Banti's disease: (1) because its pathology is not understood and leaves a wide field for speculation and a wider one for experimental study; (2) because, while we are not familiar with the pathology of this condition, we do know how this condition may be relieved. The results from surgical interference are all any one could wish for from any surgical operation. The mortality in this condition is, or should be, almost nil, if the case is properly studied and the proper measures are carried out for the protection of the patient before and during operation. When the patient is very anæmic, one should not hesitate to obtain a suitable donor and give the patient a liberal blood transfusion by one of the methods now in use. Personally, I prefer the use of the whole unaltered blood, either by the direct anastomosis of the vessel from donor to recipient, or by the use of Kimpton-Brown tubes. The latter has been much more satisfactory in my hands. It is almost needless to add that the donor should be examined with great care to ascertain that he is free from transmissible diseases.

The use of nitrous oxide anæsthesia in this condition is also a very important part of the technique, for it has been so thoroughly proven that the hæmolysis seen often after the use of ether as an anæsthetic, and the reduction in hæmoglobin, is never seen after the use of nitrous oxide. Also for the past five years I have used a slight mixture of pure CO_2 gas, prepared by the Ohio Chemical Company, with the gas oxygen. This accomplishes two purposes: (1) stimulates the patient, and (2) stimulates the respiration. This was suggested to my mind after hearing a most excellent talk at the Academy of Medicine in New York by Yandall Henderson, who had gone deeply into the subject of carbon dioxide as a stimulant. He reported several cases in which it seemed he had succeeded in almost bringing the dead again to life, by the proper use of CO_2 gas. I have found it exceedingly valuable in anæsthesia.

The operation of splenectomy is usually not a difficult one, although if there are adhesions present and the organ is a large one, it may cause some anxiety to the surgeon before he has finished the operation. If the pedicle is a very short one, it will add materially to the difficulty of the operation, just as will the same condition when encountered in nephrectomy.

The splenic artery may be ligated separately, also the veins one finds in the pedicle. I first ligate the pedicle *en masse*, and then, after removal of the organ, ligate separately the vessels, which may readily be picked up after the organ is severed. I use heavy catgut for all ligations, and have never had cause to regret its use.

The operator should be exceedingly careful not to injure the pancreas, diaphragm, colon, and stomach, as it is possible by rough handling to injure any one of these organs.

Unless there have been many adhesions broken up, accompanied by some oozing, which cannot be entirely controlled, drainage is unnecessary.

The reports of the following four cases, I think, are of interest, because two of them I have been able to follow up for ten years. One of the remaining two I have been unable to locate after one year. The last one is a recent case, of only a few months. In some respects the blood after operation, has presented many of the usual phenomena reported by other operators; in some other respects it had differed materially.

Case 1. F. D., male, age 26 born in Sicily. The family history is negative. The patient had been a farmer by occupation, a hard worker, and had never used alcohol. He had always been a



Case 4. Spleen 15½ by 19¼ inches. Weight 13½ pounds.

hearty eater. He came to America two years ago. His past illness consisted in periodic attacks of malaria. As a young man in Sicily he had a spell of fever lasting about four weeks. Six years ago he was rejected by military authorities in his native country on account of a large tumor in the left side. Up to this time the patient says he knew nothing of the existence of the tumor. He thinks he had smallpox at 19 years of age. The patient thinks he has been growing weaker for years, but only consulted a doctor two months ago for severe pain in the left side over the region of the tumor. This pain would run upward toward the left shoulder. The bowels moved regularly. He has had occasional hæmorrhages from the bowels which he supposed to be "internal piles," also one or two severe hæmorrhages from the lungs, or stomach. On examination the patient's lungs and heart were found normal. The liver was very slightly enlarged, and freely movable. There was no tenderness over the gall-bladder or appendix. The kidneys were not tender, and both could be located in the proper place. A large mass was felt in the left hypochondriac region which also extended deeply into the left lumbar region. The mass could be seen to glide under the anterior abdominal wall on deep inspiration and expiration, but seemed to be firmly fixed posteriorly, and was quite tender on palpation and percussion. The urine was negative. Taking into consideration the blood picture and history, a diagnosis of Banti's disease or splenic anæmia was made and operation advised.

Operation. Gas-oxygen anæsthesia was used. An incision about 8 inches long was made beginning under the costal margin near the ninth costal cartilage and extending downward and outward for about eight inches. The enlarged spleen was exposed.

Externally many adhesions were found to exist between this organ and the abdominal wall. The adhesions throughout were found to be plentiful and the bleeding very troublesome as every denuded area seemed to weep blood. Where the adhesions were broken up between spleen and lateral abdominal wall it became necessary to leave in two hot abdominal packs in order to control the oozing.

His convalescence was uneventful except for two elevations of temperature due to the formation of stitch abscesses.

The spleen weighed 56 ounces. The report of J. S. McLester on the pathologic findings is appended:

"The organ is firmer than normal, cuts very hard, is normal in color, .and has a greatly thickened capsule.

"In the interior of the organ is a cavity about the size of a hen's egg. Smears made from the contents of this cavity show softened splenic pulp and pus. Cultures made from this pus gave the typhoid bacillus in pure culture. This organism was identified by E. M. Mason, State Bacteriologist.

"Microscopic sections made from the organ show great increase in the size and number of the fibrous trabeculæ. The fibrous framework seems to be enormously hypertrophied. The parenchyma cells are increased in size and number, and the glomeruli can be distinguished only with difficulty. Irregularly defined patches of pigmentation are seen. There seems to be some swelling and proliferation of the endothelial cells of the cavernous veins.

"Diagnosis. Chronic interstitial splenitis."

The following blood picture of this case is interesting:

Examination of blood before operation. August 23, 1909: White blood count 1,700, red blood count 2,400,000, hæmoglobin 50 per cent. August 26, 1909: white blood count 1,800, red blood count 2,100,000, hæmoglobin 45 per cent. Blood pressure 115. Malaria, negative; Widal, negative.

Unfortunately the record of differential count before operation was lost, therefore, it cannot be given accurately and is omitted from this report.

Examination of blood after operation. August 28, 1909: white blood count 1,700, red blood count 2,850,000, hæmoglobin 60 per cent, polymorphonuclears 64 per cent, large mononuclears 7 per cent, small mononuclears 12 per cent, eosinophiles 17 per cent. Blood pressure 95. September 1: white blood count 25,800, red blood count 2,940,000, hæmoglobin 70 per cent, polymorphonuclears 68

per cent, large mononuclears 11½ per cent, small mononuclears 6½ per cent, eosinophiles 14 per cent. Blood pressure 120.

September 3: white blood count 12,000, red blood count 4,000,000, hæmoglobin 70 per cent, polymorphonuclears 88 per cent, large mononuclears 4 per cent, small mononuclears 4½ per cent, eosinophiles 3½ per cent. Blood pressure 115.

September 11: white blood count 14,000, red blood count 4,200,000, hæmoglobin 75 per cent, polymorphonuclears 72 per cent, large mononuclears 5 per cent, small mononuclears 20 per cent, eosinophiles 3 per cent.

September 15: white blood count 17,500, red blood count 4,240,000, hæmoglobin 75 per cent, polymorphonuclears 71 per cent, large mononuclears 7 per cent, small mononuclears 18 per cent, eosinophiles 4 per cent.

September 30: white blood count 14,000, red blood count 4,520,000, small mononuclears 14 per cent, eosinophiles 2½ per cent, hæmoglobin 85 per cent, polymorphonuclears 74½ per cent, large mononuclears 9 per cent.

October 10: white blood count 8,000, red blood count 5,000,000, hæmoglobin 90 per cent.

At this time (April 15, 1910) about eight months since operation the patient is in perfect health, has gained 53 pounds in weight and is at work as a day laborer.

The foregoing report was made at time of operation. This patient reported to me several times per year, for seven years, and he was still engaged as a day laborer and his health was good. Several blood examinations during this time showed his blood picture to be practically normal.

CASE 2. Splenic anæmia. Mrs. T. J., white, aged 26, married, American born, entered the infirmary November 5, 1911. Her father died when quite old of some unknown cause. Her mother died of "congestive chill." Two brothers are dead; one died in infancy, the other through accident. She has eight sisters, all living and in good health.

The patient had jaundice when 4 years old, and a second attack two weeks previous to entrance into infirmary. She does not think she ever had a spell of fever of any kind except following the birth of both her children. Menstruation began at 14 years. It was regular, scanty and lasted for only one or two days, at this time she suffered quite a little pain. She had been married about five years, and is the mother of two children, the oldest being 3 years of age, the youngest 1 year. The labors were normal but were followed by infection each time, which confined her in bed several weeks.

The present illness began five years ago with vomiting of blood, which was about half a cupful. The blood vomited was very dark red. Since this time she had vomited blood almost daily in small quantities up to October, 1910, and since then about once a month. She suffered no pain; the appetite was poor. The bowels moved from three to five times daily; there was no blood in the movements. She suffered from nausea, headache and vertigo. She said her temperature was usually elevated in the afternoon. She had no cough.

Examination revealed a very frail, anæmic woman whose skin showed a marked icteroid hue, and one would think she had lost much flesh during the past few months. She said her weight now was 90 pounds, and that she had lost 25 pounds during the past year. Her lungs and heart were found to be negative. She had no enlarged glands in the neck. The thyroid was not enlarged. The tongue was very pale, and the gums and lips showed a marked anæmia. The liver was uniformly enlarged but was freely movable on deep inspiration. The abdomen was very much distended by a large tumor which occupied the left hypochondriac region, part of the epigastric, lumbar and the umbilical regions. The tumor was slightly tender from pressure and was fixed posteriorly. The inguinal glands were not enlarged. The patient's feet and ankles showed marked œdema.

Vaginal examination revealed a retrodisplaced and fixed uterus which was quite tender. The urine showed a trace of albumin; otherwise it was negative. Blood examination November 5, 1911, revealed: white blood count, 5,850; red blood count, 1,776,000; hæmoglobin, 25 per cent (Sahli); color index, 0.89. Differential count revealed small lymphocytes, 30.6 per cent; mononuclears, 20 per cent; polymorphonuclears, 43.6 per cent; eosinophiles, 2.3 per cent; mast cells, 0 per cent; myelocytes, 3.5 per cent. On account of the long period of years covered by illness, the hæmorrhages, etc., a diagnosis of chronic splenic anæmia, or Banti's disease, was made and the patient was advised to stay in the infirmary in order to see if she could not be gotten in better condition for operation. She did not improve but seemed to grow worse.

Blood examination, November 20, 1911, revealed: white blood count, 5,400; red blood count, 1,520,000; hæmoglobin, 19 per cent (Sahli instrument used). Color index, 0.65. Differential count revealed: small lymphocytes, 22 per cent; mononuclears, 20 per cent; polymorphonuclears, 56.5 per cent; mast cells, 5 per cent; myelocytes, 1 per cent.

The patient was dismissed from the infirmary as an inoperable case, November 26, 1911, a blood examination on this date showing the same as on the 20th. She returned home, and under treatment improved to some extent and was returned for operation, March 17, 1912. Her condition at this time was not good, but was somewhat more favorable for surgical interference. The blood examination at this time revealed: white blood count, 4,500; red blood count, 2,500,000; hæmoglobin, 45 per cent. Her temperature on admission was normal, pulse 78, volume poor. The urine contained albumin. She was prepared for operation for the

following morning, and under nitrous oxide and oxygen anæsthesia the large spleen was removed. It weighed 48½ ounces. Many adhesions were encountered and the bleeding gave some trouble, but the patient left the operating table in good condition. The temperature rose at once to 103.8°, pulse 132, but they both came down to normal in a few days. For some days the patient would have a distinct rise of temperature, but the pulse remained normal or nearly so, even when one of the sharp rises of temperature would indicate that we had trouble.

The blood picture after operation was interesting. The examination was by Dr. McLester.

Blood counts. March 21, 1912: white blood count 11,200, red blood count 11,900,000, hæmoglobin 45 per cent. Differential count, 500 cells counted: polymorphonuclears 75 per cent, small mononuclears 9 per cent, large mononuclears 3 per cent, eosinophiles 12 per cent, transitionals 0.3 per cent, nucleated reds 0.4 per cent, basophiles 0.3 per cent.

March 29, 1912: white blood count 18,000, red blood count 3,000,000, hæmoglobin 55 per cent. Differential count, 500 cells counted: polymorphonuclears 78 per cent, small mononuclears 15 per cent, large mononuclears 1 per cent, transitionals 1 per cent, eosinophiles 5 per cent.

April 8, 1912: white blood count 37,700, red blood count 3,500,000, hæmoglobin 70 per cent. Differential count, 500 cells counted: polymorphonuclears 86 per cent, small mononuclears 11 per cent, large mononuclears 1 per cent, eosinophiles 2 per cent.

April 15, 1912: white blood count 17,000.

April 20, 1912: white blood count 10,000.

The characteristic blood findings in splenic anæmia are a leukopenia and anæmia of the secondary type.

The patient was dismissed from the infirmary, April 14, 1912, very much improved.

January, 1913, a report from the patient was to the effect that she had gained about 30 pounds and that her health was perfect.

Pathologic report by Dr. James S. McLester: "The spleen weighs 48½ ounces and measures 10¾ by 6½ by 3½ inches. Its surface is smooth and glistening and is perhaps a little darker in color than the normal spleen.

"The fibrous capsule is very much thickened. The cut surface shows very distinctly the fibrous trabeculæ. Microscopic examination shows that the capsule is greatly thickened and that there is some, though not marked, increase of the fibrous reticulum.

"No proliferation of the endothelial cells can be noted. The malpighian bodies, while smaller than usual, are well preserved.

"The most striking feature of the microscopic picture is the great number of eosinophiles. These cells are very frequent and are scattered evenly throughout the tissue. An average of about eight is seen to the field (section of 6 to 8 microns, Winkel 3 millimeters objective and No. 3 ocular)."

The great number of eosinophiles, suggests Hodgkin's disease. On the other hand, the clinical history, the complete absence of glandular enlargement elsewhere, the increase in the fibrous elements and the absence of endothelial growth point to the splenomegaly seen in Banti's disease. In the light of our knowledge, I think we are forced to place this spleen in the latter class.

This case I followed for a short time, and she recovered entirely, but I was unable to get her to ever return to the infirmary for examination. If this case was again to be handled by me, I would certainly give one or more blood transfusions, but at the time this case was operated upon we were not using blood transfusion. I think it unusual this case recovered, as she was certainly a poor operation risk.

CASE 3. Female, age 29. Complaint, large mass in left side and general bad feeling. The family history is negative. The patient has been in poor health for past five years or longer. She had jaundice when five years old. She had hæmorrhage from bowels in 1914. She sleeps poorly and has lost 18 pounds during the past year. She noticed a mass in the left side five years ago and this had continued growing since that time. She is the mother of five children, the youngest 2 years of age. She menstruates every 28 days, very profusely. Upon examination we find a frail woman weighing about 100 pounds. She looks anæmic and quite weak. Her chest is negative with the exception of a regurgital murmur, though this is fully compensated and seems to be giving no trouble.

Abdominal examination reveals a large tumor in the left hypochondriac region which could be readily recognized as the spleen. There were no enlarged glands about the body. The temperature and pulse were normal.

The blood examination shows: white blood count 6,000, red blood count 2,850,000, hæmoglobin 50 per cent. Differential count showed: small lymph 30 per cent mononuclears 20 per cent, polymorphonuclears 44 per cent, eosinophiles 3 per cent, myelocytes 3 per cent.

The urine was negative.

The diagnosis of Banti's disease was made in this case and operation advised. Nitrous oxide-oxygen anæsthesia was used and a spleen weighing 58 ounces was removed. The operation was quite easy as no adhesions were encountered and the pedicle was of sufficient length to permit of its easy delivery. The patient made an uninterrupted recovery and returned home on the fourteenth day. The report from her from time to time was that she was constantly improving, and fourteen months

from the time of operation I received from her husband a letter from which I quote: "You will probably be interested to know that we had a 7½-pound boy born last night. Baby and mother doing well. Mrs. H. is enjoying better health now than she has in seven years, etc."

She remained in fine health until the latter part of 1917, when she committed suicide by shooting herself. Cause of act unknown as she seemed well and happy.

CASE 4. Male, age 38. Occupation, farmer and coal miner. The patient complains of very large tumor in the left side. The family history is negative. The past history is negative, except for an attack of jaundice in 1898. He has always been healthy until six years ago, when he first noticed this tumor.

At the present time he complains of dyspnœa and palpitation of the heart. He says he has spit blood several times. He has lost much weight; he thinks about 30 pounds during the past year.

Upon examination his chest is negative. There are no enlarged glands anywhere about the body. A very large tumor can be felt that fills the entire abdomen, but one can make out the splenic notch and it seems to be the spleen. The white blood count is 2,100; red blood count 2,825,000; hæmoglobin 60; polymorphonuclears 66 per cent; small lymphocytes 27 per cent; large lymphocytes 6 per cent; basophiles 1 per cent. The urine was negative.

The diagnosis of Banti's disease was made and patient operated upon the following morning. Gas-oxygen anæsthesia was used. Owing to the size of the tumor and shortness of the pedicle it was quite a difficult operation. Some adhesions were encountered, which bled rather freely when they were severed. The patient left the operating table in good condition and made an uninterrupted convalescence. The spleen weighed 13½ pounds after all the blood was permitted to flow out. The blood from the organ weighed several pounds. I think this one of the largest spleens recorded.

The blood picture following operation is as follows:

June 10; white blood count 16,000. hæmoglobin 75 per cent, polymorphonuclears 74 per cent, small lymphocytes 18 per cent, large lymphocytes 7 per cent, basophiles 1 per cent.

Blood counts made daily after June 10, changed very little up to the time he was discharged from the infirmary. The hæmoglobin was decidedly improved and the last reading on chart was 85 per cent.

This was unusual as we are supposed, according to some observers, to have a decided reduction in hæmoglobin following splenectomy.

The report on this patient at the present time is that he is in excellent health.

The pathological report made by M. C. Winternitz is as follows:

"The specimen of spleen was sectioned. There is no marked increase of fibrous tissue and, as usual in a spleen that is greatly increased in size, the malpighian corpuscles are few and small. The sinusoids are everywhere distended and contain a much larger proportion of red blood cells than any other type. The walls of the sinuses are definitely thickened and the endothelial cells are more prominent than usual. The pulp is very cellular, the cells are chiefly mononuclear in type.

"I do not find anything specific in the spleen to indicate a special disease and this, of course, is in accord with the diagnosis you have made of splenic anæmia. Whether this could be considered a Banti spleen is a question that is open."

DEPARTMENT OF TECHNIQUE

GYNECOLOGICAL PELVIC DRAINAGE

INDICATIONS, METHODS, AND MATERIALS[1]

BY J. WESLEY BOVÉE, M.D., F.A.C.S., WASHINGTON

THE subject of employment of drainage in intraperitoneal pelvic surgery has provoked many heated discussions dating back as much as forty years. I shall not take up the relative value of capillary drainage (said to have first been used by Heister[2] in the eighteenth century) and tube drainage, though that subject is not without interest. The glass tube drain through the abdominal wound was employed in practically all operations not excepting those conditions constituting what are now called clean ones. But when one reviews the technique of intraperitoneal operations of forty years ago, it is not difficult to understand that the surgeon dreaded to close the abdominal wound completely. Kelly's clinic in Johns Hopkins Hospital showed that infection was introduced through the tube in the postoperative treatment and the use of the glass intraperitoneal drainage tube was gradually lessened. It was succeeded by the Mikulicz drain, and that by an effort to avoid drainage. The question as to whether drainage should be employed, as the practice of cleanliness and careful technique became more universal, received marked attention. The trend of the times since has been to avoid drainage to the utmost degree possible. Greater confidence in the capacity of the peritoneum to care for its injuries has been established in our profession, and some, notably, Robert Morris, of New York, have announced their preference to leave within the peritoneum pus found there, because of its food value. I am prompted at this juncture to repeat my statement to the Medical Society of Virginia,[3] in 1902, that I believe the wise pelvic surgeon never drains in clean surgery, very rarely in dealing with the late results of infectious inflammations, and very frequently when dealing with such processes in an early stage. But aside from the dangers of peritonitis and other evils that may arise from infectious materials in the pelvic portion of the peritoneal cavity there is a very common and serious condition: a peritoneal denudation, arising from the separation of pelvic adhesions in pelvic surgery. Ofttimes quite large areas of the pelvic peritoneum are denuded, and to cover them with peritoneum is often found impossible. It is with special reference to this condition that I will consider this subject a little farther along.

I believe no one will gainsay that dependency is advantageous in drainage, as serum, pus and most fluids will tend to gravitate. Therefore, for drainage of the female pelvis the vaginal route is always preferable to the abdominal. Nor is gravitation the only point of advantage of the lower route. I have not in many years seen a woman's pelvis drained through the abdominal wall that I did not think she had been unfortunate in the selection of her surgeon.

For the employment of vaginal drainage from the peritoneal cavity, I believe we are indebted to E. R. Peaslee, who, in February, 1855, after removing an ovarian tumor complicated by ascites, passed a gum elastic catheter *per vaginam* into Douglas' pouch, which was retained thirteen days.[4]

Of the many materials used for pelvic drainage, cotton gauze and rubber are by far the most commonly employed, the rubber tube or gauze for small areas and a combination of them for larger areas. Many favor the cigarette drain of a layer of thin rubber enclosing sterile or medicated gauze or rolled with the gauze. A thin rubberized paper is often substituted for the rubber. It has been claimed that such materials have at times not acted as a drain, but in an opposite way, i. e., plugged the opening into the vagina and caused an accumulation of fluid above them that found an exit through the abdominal wound, thus weakening or possibly infecting it. In 1912[5] I exhibited to the American Medical Association

[2] See Bryant and Buck. American Practice of Surgery. 1,761.

[3] See its transactions. page 199.

[4] Am. J. Obst., N. Y., 1870, iii, 309-318.

[5] J. Am. M. Ass., 1912, lix, 240-251.

[1] Presented before the Southern Surgical Association, Baltimore, December 17-19, 1918.

a rubber drain I had devised and employed for several years in pelvovaginal drainage. It consisted of a triangular piece of thin rubber, usually taken from a condemned rubber glove and attached by its narrow base to a soft rubber round rod about ¼ inch in diameter and two and a half inches in length. This bar was made to rest on the uterosacral ligaments and the thin rubber, about 4 inches in length protruded into the vagina. The lowest angle of it could be grasped with a forceps introduced through the vulva, and the whole of the drain easily and painlessly withdrawn. Ofttimes plain gauze was brought down behind it when extra covering of denuded peritoneal areas was desired. Until March, 1916, when I began the use of the paraffine-stearine gauze for this purpose, this rubber drain was used with a high degree of satisfaction, though at times its withdrawal was notably painful to the patient.

Hart E. Fisher[1] used plain surgical gauze, surgical cotton, chamois skin, gutta percha tissue, silver foil, paraffine or oiled paper, rubber dam (dental), narrow mesh fine silver wire screen, medicated gauze dressing, cold cream, and powder dressing, and he concluded that plain gauze soaked in equal parts of stearine and paraffine was perfect in its non-adhesive property and could be placed against the denuded tissue and covered with other (plain) gauze to absorb discharges coming through the special gauze, without adhesion of the dressing to the wound.

In cases in which, in the course of several days, the plain gauze was several times changed without disturbing the paraffine-stearine gauze no adhesion occurred.

His method of preparing this gauze follows:

> Paraffine wax is brought to the boiling point at three different intervals in the course of an hour and filtered through a narrowly meshed gauze. It is thus sterilized and freed from any foreign bodies such as minute particles of grit, etc.
>
> During this procedure the stearine (stearic acid) is brought to the boiling point and filtered by the same process and for the same number of times. Then equal parts of the liquid-hot paraffine and liquid-hot stearic acid are poured into a white porcelain container, again brought to the boiling point, and filtered as described above. The mixture is then ready for the sterile, wide meshed gauze, cut in sizes to suit, which is immersed in it for ten minutes to allow the gauze to become thoroughly impregnated with the fluid. The wet gauze is then removed and stretched, and the excess of mixture allowed to drain off. A jet of filtered and heated air is directed against the gauze, causing the film of wax over the meshes to melt and allowing a more uniform waxed screen. When dried the gauze is placed in a sterile container and sealed.

I have had this gauze made by this formula and again the feature of blowing hot filtered air through has been omitted, thus avoiding a very troublesome feature and as well a possible danger of contamination. The product of the curtailed process was not as smooth though by breaking it slightly when applying it no practical defect has been noticed. The pieces should be originally cut small as often but small areas are to be covered and the difficulty in making this gauze would emphasize the necessity of greater economy in its application. Parresined lace-meshed dressing, prepared by one commercial laboratory is stiffer and coarser meshed. I have used it but the meshes are too large. However, it is a fair substitute for Fisher's paraffine stearine gauze.

For two and a half years, since reading Fisher's article, I have been using Fisher's gauze for vaginal drainage from the pelvic peritoneum. It has been used largely as a casing of one or two layers surrounding plain gauze. I soon learned to suture the casing to the core of plain gauze, for in one patient the interne, Dr. Kane, removed 8 inches of the 24 inches of gauze on each of the third, fourth and fifth postoperative days. To our surprise, 3 days later the patient expelled the 24 inches of the paraffine-stearine gauze.

In a fair proportion of the work a roll of the latter gauze was used without the plain gauze core. The employment of this material for pelvic peritoneal drainage has been so satisfactory that I have adopted it to the exclusion of all other materials for this purpose. In one instance the interne was about to remove one-third of a strip of this material, 24 inches in length, on the third day after operation, from a very nervous patient. Becoming greatly excited she strained and expelled in a serpentine shape the whole of it before he could get hold of it or get her to desist from straining. These two instances tend to confirm the statement that it does not adhere to the tissues.

On applying this gauze it will be thought its rigidity renders it inappropriate, but the temperature of the body readily softens the material, causing it to mold itself as smoothly as plain gauze. This gauze, then I feel may be relied upon to protect denuded pelvic peritoneum for a sufficiently long period of time for endothelialization under it to occur, thus avoiding the much dreaded adhesions of intestine and omentum to such denuded areas; also while affording disposal of any accumulated fluids may also be itself removed at any elected time.

I may add I have had opportunity to view several months subsequently a few of the pelves thus drained and in none of them were pelvic adhesions present.

[1] J. Am. M. Ass., 1916, lxvi, 939.

RECONSTRUCTION OF THE UTERUS[1]

By CHARLES R. ROBINS, M.D., F.A.C.S., Richmond, Virginia
Professor of Gynecology, Medical College of Virginia; Surgeon, Stuart Circle Hospital; Gynecologist, Memorial Hospital

THE desirability of preserving the generative organs in women during their functionating period, particularly in young unmarried women, admits of no argument. The difficulties which beset conservatism, however, when the uterus is the seat of a growth of which fibroid tumors are the predominating type, are very great and often insurmountable. Fibroid tumors in the body of the uterus are almost invariably multiple and the distortion and deformity are so great that conservatism in the large majority of cases is out of the question. In addition, knowing that fibroids are multiple and that they grow from very small islets, the presence of palpable tumors simply indicates that others are probably present which cannot be felt, and that although the recognized tumors may be removed, others will probably develop. However, the anatomy of the uterus is particularly favorable for resection. The blood supply and the tubes entering from the sides enable us to remove whatever of the middle portion of the uterus may be desired or deemed advisable. The only things necessary are the blood supply, tubes and a continuous uterine cavity. Not all cases, however, are suitable for conservative treatment, and where the deformity is very great or the fibroids generally distributed, a conservative operation is most often impossible. Neither is the operation indicated in all cases, even when the anatomical problems may appear to be suitable. In women who have borne children and who are approaching the menopause and in whom sexual life has been satisfied, removal is undoubtedly the best operation. It is safe, the results are excellent and there remains no reason for further operation as far as the uterus is concerned. The advantages of conservatism are overborne by the prospect of further pathology.

There remains, however, a class of cases in which the opportunity for matrimony or of bearing children is a matter of such great importance that some risk is justifiable. There also remains a class of cases in which the exact pathology remains a matter of doubt, notwithstanding that every effort has been made to arrive at a diagnosis. In such cases, as has been pointed out by Deaver[2] in a most admirable paper entitled, "Anterior Transperitoneal Hysterotomy," the exact condition can be definitely determined by incising the uterus through the abdominal route and directly inspecting the interior. By this apparently radical procedure, it is possible in a number of cases to practice the greatest conservatism and if necessary to resect the uterus.

The operation which is contemplated in this paper is the bold resection of the diseased or tumor-bearing portion of the uterus and the reconstructing of the uterus by uniting the lateral portions that are left. It has many advantages over myomectomy, which is the operation with which it would most frequently be contrasted. In the first place it would save a considerable amount of time. It is far easier to resect the uterus than it is to attempt to shell out the tumors particularly if they are numerous. It would have the advantage of enabling us to inspect the uterus, both from within and from without. In that way we would be most likely to remove all of the fibroid nodules. It is much easier to secure a normally shaped uterus where the incisions are carried along lines that will secure the best apposition. It must undoubtedly be a safer operation because we do not have the numerous pockets to obliterate, and consequently there would be no dead spaces and areas for infection. The operation is a safe one because when completed there remains only a suture line which is hardly likely to give any trouble. The dangers of future rupture of the uterus, should pregnancy occur, I believe, are negligible.

I wish to report two cases in which this operation has been performed.

Case 1. Register No. 18-389. This patient was seen June 6, 1913, and at that time presented the following history. Age 36, white, female, single. The patient was contemplating matrimony. She had suffered all her life with nausea and had had pain all through the lower abdomen and at times became very sore in the suprapubic region. In the last eighteen months her flow had been irregular and for the last two or three months it had a tendency to check. She also suffered from sick stomach and indigestion. On examination she was found to be tender in the right iliac region and the uterus was markedly retrodisplaced and somewhat enlarged. At operation she was found to have a chronic appendicitis, which doubtless accounted for some of her symptoms, and in addition to the retrodisplacement of the uterus the fundus contained a fibroid together with a fibrosis which caused a marked thickening and hardening of the fundus of the uterus. In

[2] Deaver, John B. Anterior transperitoneal hysterotomy. Surg., Gynec. & Obst., 1914, 424.

[1] Read before the Southern Surgical Association, Baltimore, December 17-19, 1918.

Fig. 1. Case 2. Showing enlargement of uterus and elevation of fibroid. The fibroid is somewhat accentuated in this drawing as it really did not appear above the surface.

Fig. 2. Case 2. Showing tumor removed by elliptical incision and sutures for approximation introduced.

view of the fact that the patient was contemplating matrimony and on account of her earnestly expressed wish not to have any of her organs removed, it was determined to resect the affected portion of the uterus instead of performing a hysterectomy. This was further indicated because it was deemed advisable to clear up the pathology by securing the affected portion of the uterus for microscopic study. The resection was done by making a double V incision extending down as far as the internal os anteriorly and posteriorly. The endometrium was found to be very much thickened and fungous. This was curetted through the incision. The lateral portions of the uterus that were left were sutured to each other with interrupted sutures of Pagenstecher. The patient made an excellent recovery and was subsequently married and became pregnant. She, however, aborted at about four and half months. A year later she became pregnant again but aborted at the end of one month. However, in July, 1918, five years after the operation she was delivered of a robust full term infant, without any pathology either during the pregnancy or at time of birth.

Case 2. Register No. 22–550. This patient was seen August 29, 1917. Age 24, white, female, single. She gave the following history. She sought relief on account of a flow of blood from the vagina. Her periods commenced at fourteen years and at first she had no trouble except a tendency to go over time and a very slight dysmenorrhœa. Her periods had always been free and would last four or five days. About three or four years ago she began to suffer with indigestion, and a year later was taken with an acute attack of pain in the right iliac region and vomiting. Previous to this she had had a good many spells which were similar and which she says usually came on with her periods. She was finally operated upon and the appendix removed about two years previous to the time she consulted me. About six hours after the operation her flow came on, which was at the usual time, and she suffered considerable pain in the lower abdomen. After leaving the hospital she suffered with more pain at the time of her periods and the flow increased. Eight months previous to consulting me she had had a continuous flow for about a month and had been taken to the hospital and curetted. This, however, did not afford any relief and she continued with an irregular flow, which at times was very profuse, and on entering the hospital she presented every appearance of a person suffering from a profound anæmia. On examination her abdomen was negative. On bimanual examination the fundus of the uterus was found retrodisplaced, but no irregularities in the contour of the uterus could be detected. In view of the fact that the patient had been curetted without relief, it was determined to perform a laparotomy and explore the uterus through an incision. When the uterus was brought up a fibroid nodule could be palpated in the anterior wall, which was evidently extending into the cavity of the uterus. The tumor was removed by making a free elliptical incision and a submucous fibroid nodule about the size of a walnut was removed. The endometrium was thickened and fungous and was thoroughly curetted through the incision. The opening was then closed with Pagenstecher sutures and the displacement corrected by performing the Webster-Baldy operation. This patient was entirely relieved of all of her symptoms and is now in excellent health. In a letter just received she says she has gained in weight, walks three miles a day and suffers practically no pain with periods.

Resection offered the only satisfactory method of dealing with this case. In the first place the exact pathology would have had to be a matter of conjecture unless the uterus were examined by direct inspection and palpation, as the tumor presented on the interior of the uterus and its detection by bimanual examination was practically impossible, as the only sign elicited was a

slight enlargement. But even though the diagnosis were easy, its removal by the genital route in a virgin would have been attended with the greatest difficulty and danger.

INDICATIONS

As to the indications for this operation, we approach it from two points of view. First, incision of the uterus to expose the cavity. This presents a comparatively wide field of usefulness. We have to admit that even after making the most painstaking examination we are not infrequently in doubt as to the exact pathology. In a case of doubt it is a very easy and safe procedure to incise the uterus and inspect and palpate the cavity directly, and this is certainly indicated where the alternative proposition would be the removal of the uterus and the subsequent study of the pathology. These points and others are clearly brought out in Deaver's paper on "Anterior Transperitoneal Hysterotomy."

Second, resection and reconstruction of the uterus. We must admit that the application of this procedure is necessarily limited. However, in certain conditions it would appear to be clearly indicated in preference to removal of submucous fibroids that are still within the cavity of the uterus and also in preference to myomectomies, provided the tumors lie in such a way that they can all be removed by resection. In young unmarried women and in married women who have not had children, we would be justified in resorting to this operation in preference to hysterectomy, even though it entail the risk of another operation on account of fibroids that may develop. Every case has, of course, to be judged on its merits, and perhaps not many will arise in which we can practice this method. Certainly I have found this so in my own practice. But by study of the anatomy and pathology with the uterus in the hand and under the eye it is possible in some cases to secure very gratifying results.

THE USE OF CONTINUED EXTENSION BY MEANS OF A NEW EXTENSION FRAME IN THE BLOODLESS REDUCTION OF CONGENITAL DISLOCATION OF THE HIP

By JOHN W. CHURCHMAN, M.D., F.A.C.S., New Haven
Professor of Surgery, Yale University

IN his publications on congenital dislocation of the hip, Lorenz described so completely the pathology of the condition and indicated so well the best technique to be used in its treatment that this chapter of surgery might be regarded as closed. So excellent were the results of his method in his own hands that since his time, under the limitations distinctly set for the procedure by Lorenz himself, bloodless reduction has been — considering the difficulties to be met — one of the most successful of surgical procedures. According to Lorenz's own figures, 52.6 per cent of 680 cases were cured; extraordinarily good results for an extraordinarily bad deformity. In spite of these facts the method of bloodless reduction is not without its drawbacks. The impression of brutality made when one witnesses for the first time a hip thus reduced, is a thing not soon forgotten. The formation of subcutaneous hæmotomata from manipulations vigorous enough to result in rupture of structure is indeed the indication of a treatment of the tissues so violent as to be not without its dangers. These dangers were fully appreciated by Lorenz himself and were described in his monograph. The first of these dangers is a death rate from anæsthesia, associated with the violence of the manipulations under the anæsthetic, and higher than would be explained by the anæsthetic alone. This fact of itself is sufficient cause for desiring to do away with forced manipulation, if equally good results can be obtained without it. But in addition to the occasional deaths from this cause, Lorenz called attention to a number of other accidents which have resulted from the forcible manipulations necessary in bloodless reduction. In the 450 cases which he reviewed the following complicating accidents occurred:

Fracture of the neck of the femur	11
Fracture of the pelvis	3
Peroneal paralysis (temporary)	3
Crural paralysis (temporary)	5
Sciatic paralysis (permanent)	3
Rupture of the femoral artery without gangrene	1
Gangrene requiring amputation of the hip	1

The modification of the Lorenz technique which I wish to suggest in this paper and to illustrate by a case recently treated, aims to eliminate the risks, while adhering to the principle, of the technique; and to do this by substituting for the violent manipulations under anæsthesia a rather gradual extension. I am perfectly well aware that methods of continuous extension have been previously employed, but as I have tried to make clear in the title of this article, my own suggestion is not to *replace* the Lorenz method by a method of continuous extension, but simply to *substitute* for the purely manipulative procedure of Lorenz, the gradual method of continuous extension. For this purpose a new type of extension frame has been devised, and by its use it has been possible to do what I have never hitherto accomplished, namely to put extension on the leg in any desired position of abduction and at the same time to keep up any desired type of rotation. By use of this frame the position of the leg, so far as abduction or adduction is concerned, may be changed at will, and when so changed the straps which are maintaining rotation may also be readily and instantly changed. We have found that by using this type of extension frame the muscles may be stretched gradually, just as in the Lorenz method they are stretched suddenly, to any desired degree and absolutely without pain; and that the head of the femur may be gradually laid into the position desired, purely by the method of extension and rotation, or by these methods

Fig. 1. Deformity presented on admission.
Fig. 2. Position of femoral heads on admission.

supplemented by the slightest possible manipulation of the head of the femur.

The reduction of the dislocation having been brought about in the manner described, the case must be handled exactly as indicated by Lorenz; for it is an error to imagine that the Lorenz method of hip reduction consists only in manipulative procedure, and does not include the fixation of the reduced femur in such fashion as to lead to pressure of the femur on the acetabulum by supporting the body weight. It should, therefore,

Fig. 3. Extension frame applied to foot of bed, legs abducted to form with each other an angle of practically 180°. The pins carrying the weight pulleys are shown attached close to the end of the extension frame (position on December 7, see diagram, Fig 13.)

Fig. 4. Lateral view of apparatus. The small drawing *a* shows a detail of the end of the extension frame to illustrate the manner in which the extension pulley is attached to the frame.

Fig. 5. Extension frame at head of bed. Legs abducted so as to form with each other an angle greater than 180°. Picture illustrates the use of a second mattress to keep child from slipping down in bed. Notice rotation straps on left leg, giving marked internal rotation.

Fig. 6 (at left). Degree of abduction in which plaster cast was applied to allow patient to walk.
Fig. 7. Position at present.

hardly be necessary to say that the modification in treatment here suggested does not make the bloodless reduction of hips a method applicable to cases which are not also suitable for the Lorenz method. Both methods are subject to the same conditions, though it is possible that a few cases which cannot be reduced by manipulation in one sitting, may yield to this gradual form of treatment. The limitations of the bloodless method of reduction were clearly understood and stated by Lorenz and he made it plain that in a large group of cases, particularly after the eighth year, a cure in the anatomical sense, could not be obtained, and that only anterior transposition could be hoped for.

The patient reported in this article was a rather poor case on which to try a modification of treatment, for she was eight years old: at the age, that is to say, when the chance of success becomes doubtful. In addition to this the acetabula were so shallow that it seemed unlikely that we would be able to hold the femora in position, even if we could get them there. What I hoped to do was to bring the heads of the bones into their normal positions and then, by an open operation, to enlarge the acetabula. The parents of the child refused to give permission for the open operation and we have, therefore, had to get along with practically no acetabula. We were able, however, to demonstrate on this patient that the head of the femur, even in a relatively unfavorable case of this sort can, by means of the extension method, to be presently described, be put at will in practically any position one wishes.

Fig. 8.

Fig. 9.

Fig. 8. Abduction begun, femoral heads in the dorsa ilii well above the acetabula.

Fig. 9. Abduction complete. The right femoral head is opposite the normal acetabulum; the left femoral head on the dorsum of the ilium and the femur lies in anteversion.

Fig. 10.

Fig. 11.

Fig. 10. Both femoral heads in normal acetabulum: reduction complete.

Fig. 11. Legs brought from position of extreme abduction so as to form with each other an angle of about 35°: femoral heads are opposite the normal acetabula but have been pried outward by the acetabular contents.

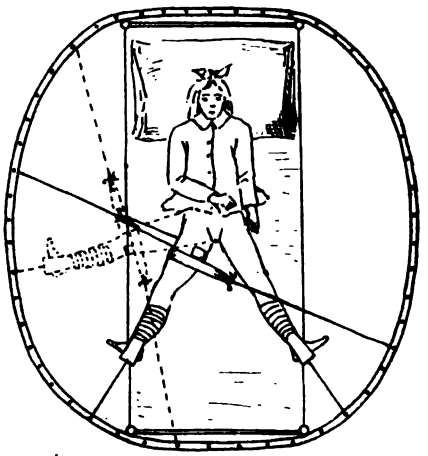

Fig. 12. Extension frame viewed from above, showing extension and rotation straps applied with leg in two different positions.

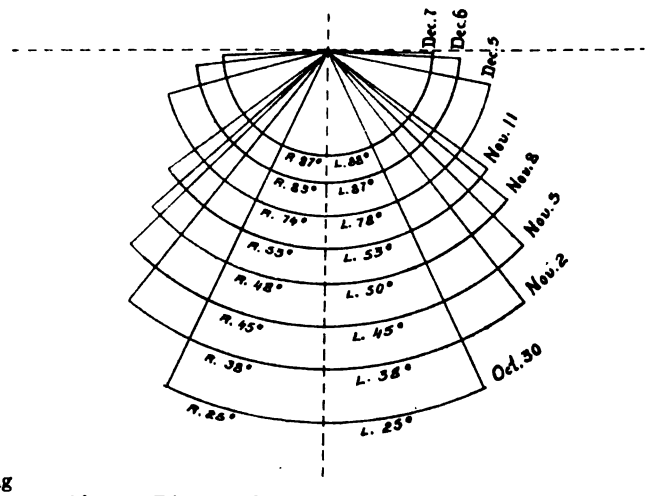

Fig. 13. Diagram showing progress of abduction of the legs.

We kept accurate control of the position of the head by repeated roentgenographs and found that any change of position indicated by these plates as necessary could be readily obtained by changing the direction of the pull of extension or rotation straps. We also demonstrated the value of the extension frame in handling *any* case where extension and rotation were to be applied to a limb at the same time.

The deformity in this patient was typical of a double congenital dislocation, as is shown in Figure 1. The position of the heads in relation to the acetabula is shown in Figure 2, in which it will be seen that on the left side there is a marked anteversion of the neck, probably about 45°, a fact which annoyed us a great deal in handling the case. This degree of anteversion is indeed, according to Durham, a strong if not an insuperable obstacle to the reduction of the deformity.

The extension frame used consisted of a 1¼ inch gas pipe bent into a semicircle. It was perforated at intervals of about two inches with a series of holes for the reception of pins to which were attached pulleys for the weights; these pins were fastened to the frame by nuts and could be in this way placed in any of the holes desired. (See *a*, Fig. 4.) The use of the extension frame when attached to the foot of the bed, is shown in Figures 3 and 4. If abduction beyond a right angle was desired, or if it was found that with abduction nearly at a right angle, the child overcame this abduction by rising in bed, the extension frame was shifted to the *head* of the bed, as shown in Figures 5. In this position abduction to any desired degree could be obtained. For the production of rotation, straps were attached in the usual fashion and these were led to pulleys which could be attached at any point in the frame desired. This description refers to the form of the extension frame which I first used. In its present very satisfactory form it is used as shown in Figure 12, where the frame completely surrounds the bed, and, as one can see at a glance from the diagram, a leg can instantly be put in any position of abduction or rotation. The nursing care of the child may be carried on by having the nurse step within the frame.

By means of an apparatus of this sort the angle of abduction of the two legs, in the patient here described, was gradually increased from October 30 to December 7, as shown in Figure 13. Starting with an angle of 50° we reached by December 7, as will be seen, an angle of practically 180°. During this procedure accurate control of the position of the head of the femur, was kept by means of roentgenographs and the rotation straps thus indicated as necessary were kept constantly applied. As was to be expected the anteversion of the left femur gave us a good deal of annoyance, but I was surprised to find how readily the rotation could be overcome by the continued pull of rotating straps and also to find that when this rotation was finally overcome it seemed to be permanently overcome. It is probably unnecessary to devote so much time as was done in this case to obtaining the degree of right angle abduction required. As we had no experience to go on we proceeded very slowly, but it became evident later that this was an unnecessary waste of time.

A few X-ray pictures taken for control are reproduced to show the progress of the case. The original position is seen in Figure 2. Figure 8 shows abduction begun. Figure 9 shows abduction completed; the right hip is now opposite the normal acetabulum, the left hip still opposite the abnormal acetabulum and in marked position of anteversion. At this stage the patient was given a whiff of chloroform in her bed, and without any difficulty whatever the head of the left femur, by the slightest possible manipulation, was slipped into its proper position. In Figure 10 both heads are shown in their normal position, the dislocation has been reduced and the anteversion of the left hip has been overcome. At this stage it is necessary to begin to reduce the abduction by moving the extension pins on the frame toward the mid-line, and to bring the legs gradually into such position that when the plaster cast is applied the child may be allowed to walk and thus to transmit the body weight through the heads of the femurs to the acetabula. In Figure 11 the abduction has been in this way, to a large extent, reduced. It will be seen that the material with which the acetabula are doubtless filled (this was a point which Lorenz brought out in his study of pathological specimens of this condition) has pried the heads of the bones out and the position is not quite so good as in Figure 10. Undoubtedly operative intervention at this point was indicated in order to hollow out the acetabula, but permission for such intervention was refused by the parents. The position of the hips at this time in the plaster cast, and a few days later when the plaster cast was removed is shown in Figures 6 and 7. In Figure 7 the anterior superior spines and the great trochanters have been marked *a* and *b* and it is seen that a fairly good anatomical result with an excellent cosmetic result has been obtained.

The method here described consists briefly in:

1. Application of extension in the lines of the legs as they rest in their deformed position.
2. Gradual abduction until the legs form with each other an angle of 180.°
3. When maximum abduction has been produced, digital manipulation of the heads of the femurs to drop them into place.
4. Maintenance throughout of rotation necessary to keep the toes pointing directly upward.
5. Gradual reduction of the maximum abduction produced, until the legs form with each other an angle of about 35.°
6. Application of plaster cast from the waist to the knees.
7. Transmission of the body weight to the acetabula, through the heads of the femurs, by allowing the child to walk.

If a favorable case in a young infant with well developed acetabula is treated in this way, not only will the case be simplified by eliminating the violent manipulations hitherto used, but more accurate results will probably be obtained because it will be found that the head can in this way be at will placed exactly where one wishes it to lie, and that if the position is, by roentgenographs, shown to be not entirely satisfactory, a change in the direction of the extension or rotation straps will make the desired correction.

A GAUZE SPONGE SPONTANEOUSLY EXPELLED FROM THE URINARY BLADDER[1]

By G. PAUL LaROQUE, M.D., F.A.C.S., Richmond, Virginia

THE case herewith reported is interesting clinically from the standpoint of painful spasm of the bladder, pus in the urine and a palpable mass in the right side of the pelvis; academically because of its rarity; and practically interesting from several standpoints.

In April, 1918, Dr. W., of North Carolina, brought to the Memorial Hospital a young widow, age 34, who had never been pregnant, complaining of violent pain of the vesical tenesmus type, in the middle and both sides of the lower abdomen, radiating to both lumbar regions accompanied by the discharge from the bladder in periods varying from every few minutes to an hour, of foul-smelling pus and blood mixed with urine. This woman had been perfectly well since childhood except for dysmenorrhœa and some other pelvic symptoms for which she had been operated upon five years ago by a doctor with some experience in surgery in a North Carolina city. She says that her left ovary was removed on account of a cyst, the uterus suspended and the appendix removed. The wound was completely closed without drainage. The operation was successful in relieving her pre-existing menstrual symptoms and she remained in perfect health ever since until the beginning of the present trouble. She has lived the normal life of a well-to-do woman, she is fond of automobile driving and other outdoor sports. Her menses have been regular, painless and otherwise normal; she has not had leucorrhœa, or irritability of bladder, no indigestion, or other symptoms.

[1] Read before the Southern Surgical Association, Baltimore, December 17, 1918.

Ten days before admission, quite suddenly and without apparent cause, she was seized with a frequent desire to urinate. She had considerable pain before, during, and after urination, constant pain in the lower abdomen. The urine was foul and contained considerable sediment and was passed a little at a time at intervals of one-half to one hour, night and day. She sought relief immediately and Dr. W. after applying the usual remedies without improvement, brought her in for examination and treatment.

During the night on her trip to the hospital two large doses of morphine and hyoscine had to be administered on account of tenesmus. Upon admission to the hospital the pain was agonizing, the foul odor and frequency of urination were equally embarrassing to her refined and modest temperament. In spite of her fortitude she exhibited a distressing appearance. Her temperature was normal, pulse 90. A thorough examination of her entire body revealed no evidence of disease except in the pelvis and a slight amount of tenderness in the right lumbar region.

Vaginal examination showed tenderness most marked in the region of the bladder. The uterus was in normal position and freely movable. In the right vaginal fornix a distinct mass was palpable and quite tender. Examination of a catheterized specimen of urine showed it to be three-fourths pus. Examination of a filtered specimen showed it to be acid in reaction, containing an abundance of albumin, pus and blood, but no casts or other renal elements. The urine was dribbling away constantly, could not be retained and every half hour or so, coincident with a spasm of the bladder, she would expel sometimes as much as three or four ounces. X-ray examination made the next day showed a slight enlargement of the right kidney, a normal left kidney and a vague diffuse shadow in the true pelvis. No stone was present in any part of the urinary tract and there was nothing characteristic about the shadow in the pelvis. Dr. A. L. Gray, the roentgenologist, was quite satisfied when he saw a specimen of the pus containing urine that this in the bladder could easily account for the shadow in the pelvis. Her temperature the next day was 101°, pulse 100. There was at no time any evidence of kidney colic, nor kidney tenderness.

At this point we were quite puzzled. The mass felt in the right vaginal fornix, of course, felt quite like an enlarged ovary or tube. We frequently see pus in urine in cases of inflammation of a tube and ovary, though I have never seen such pus-containing urine as this, caused by such pathology. Moreover she had no vaginal discharge nor menstrual symptoms indicative of disease of the uterus, tubes or ovaries. I tried for two or three days to urge myself into making a cystoscopic examination but the agonizing pain which the woman suffered at all times and especially whenever her bladder contained as much as two or three ounces, caused me to believe it would not have been made without a general anæsthetic, and I continued to postpone it from day to day. With the usual drugs directed to the relief of vesical tenesmus, no relief was obtained and even with morphine sometimes combined with atropine and with hyoscine, there was no relief for more than two hours. Several vaginal examinations revealed the same mass in the right fornix. We were genuinely puzzled as to whether to do vaginal cystotomy or to operate upon the abdomen, and temporized from day to day. Four days after she came to the hospital she suffered retention of urine and an unsuccessful attempt was made by the nurse to catheterize her. I noticed myself, in using the soft rubber catheter, that it had to be introduced about three inches before urine came. I withdrew a quart of foul pus-containing urine. She continued to suffer the same tenesmus, passing the same kind of urine, though at no time was her temperature above 101° and her pulse ranged from 80 to 110.

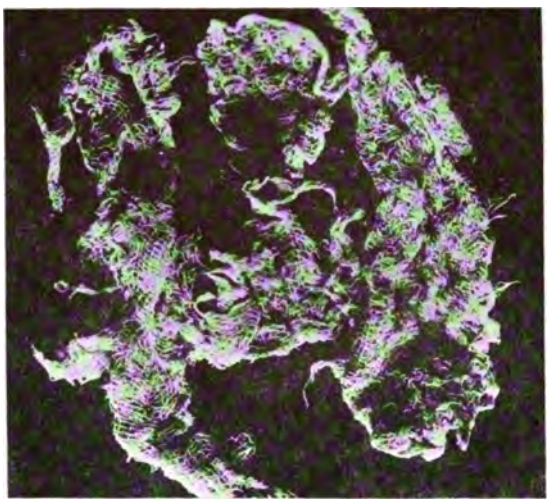

Fig. 1. A gauze sponge 2 inches wide by 10 inches long was spontaneously expelled from the urinary bladder.

Five days later she again had retention and an unsuccessful attempt was made by a nurse to catheterize her. Upon inspection of the meatus I noted a white substance, close examination of which revealed a piece of gauze in the urethra. Twisting this into a rope with my fingers the gauze rag two inches wide and ten inches long here exhibited was removed. Within 12 hours her symptoms were distinctly improved and from day to day the improvement was rapid. In six days she was apparently well, she had no urinary symptoms of any kind, and the urine was clear. Microscopic examination showed only a small quantity of pus. She was walking about and enjoying life as usual. In the meantime a perfectly normal menstrual period had appeared, lasted four days, and ceased. Five days after removing the sponge a cystoscopic examination, painlessly made, showed no evidence of any foreign material in the bladder and no cystitis. The only evidence that the bladder had ever been diseased was shown by a small area to the left of the right ureteral orifice which looked like an almost healed fistula. No mass or other evidence of disease could be detected by vaginal examination. One week after the gauze was removed and three weeks after coming to the hospital she returned to her home a perfectly well woman and has remained well ever since.

SUMMARY

1. A clean small gauze sponge was left in a clean pelvis.

2. No symptoms of any kind resulted during an after period of five years.

3. Sudden apparently causeless onset of bladder tenesmus and suppuration was followed in three weeks by spontaneous expulsion of the sponge to the meatus and easy delivery was accomplished by traction with the fingers.

4. Instant relief of tenesmus and rapid and complete subsidence of all symptoms and in a week spontaneous closure of the fistula through which the gauze had ulcerated into the bladder.

TRANSACTIONS OF SOCIETIES

CHICAGO SURGICAL SOCIETY

REGULAR MEETING, DECEMBER 6, 1918, WITH DR. THOMAS J. SULLIVAN, PRESIDING

PAPILLOMA OF THE LARGE BOWEL

DR. JACOB FRANK: I wish to report a case of a rare type of papilloma, and my reason for doing so is that at a previous meeting of the society Dr. Bevan reported a case of papilloma that he had removed from a patient in the Presbyterian Hospital, which was diagnosed by Dr. Sippy.

A peculiar thing about this case is that the patient, a man, 49 years of age, did not have any hæmorrhages, and hæmorrhage was one of the main features in making the diagnosis in Dr. Bevan's case. This man suffered from a large mass situated in the left iliac region. The sigmoid was attached to the abdominal wall and was firmly fixed there by a hard mass. I asked the patient whether he had had any hæmorrhage from the bowels and he replied, no; but his condition became so serious, that he was anxious to have an operation. I removed the mass, practically dug it out, and made an end-to-end anastomosis with one of my bone couplers, with Lembert sutures over it. About the tenth day after the operation, in looking for the rubber to pass, instead of the rubber, I removed with my fingers from the rectum the softened collars made of bone which was incorporated in fæces. I removed so much of the abdominal wall with the peritoneum which left such a large space uncovering the ileum that I had to use drainage. In order to close the abdominal cavity it was necessary to do a plastic of the peritoneum. I put in a Mikulicz drain in the iliac space. The man had no trouble at first, but twelve days afterwards he developed an abscess on the opposite side, which was a colon infection and involved the abdominal wall, and which was not from the abdominal cavity. At the time I removed this specimen, believing it to be a carcinoma, I looked for enlarged glands, and I remarked at the time that it seemed strange there was none.

The patient has as you will see a postoperative abdominal hernia. He has normal bowel movements.

From the appearance of the tumor, I believe it would not be long before it would have become cancerous from irritation. I believe very soon there would have been a stoma formed to relieve this condition so that the fæces could pass out.

HERNIA

DR FRANK: This man, 56 years of age, presented himself with a hernia, as I thought, larger than my head. He said he had had a hernia for twenty-five years. On examination there seemed to be an impulse about the ring. By percussion I could elicit a thrill through the middle part. Artificial light would not pass through. I was careful to notice whether it was a case of hydrocele with the intestine floating in it. I desired to make a positive diagnosis, but was unable to do so. I thought the patient had a hernia, because he said he had had one, and I could feel a faint impulse on coughing just at the ring. He was anæsthetized. A small trocar was introduced and blood fluid was withdrawn. When the tumor became relaxed I could feel a normal testicle on the opposite side, but on the side with the tumor the testicle was flattened and hard after removing considerable fluid and organized blood clot. Some of the fluid was sent to the laboratory and it was found sterile. The part was isolated and a regular herniotomy incision made.

I worked around the sac. Within the sac were the cæcum, the appendix, and part of the small intestines. Fortunately there were no adhesions. I put clamps on the neck of the sac, cut it off, pushed it down and finished the operation with modified Bassini technique. I removed the entire sac with the testicle and cord high up.

With your permission, Dr. Sweeney will report on the pathology and the literature.

DR. SWEENEY: This specimen Dr. Frank has brought down is very rare. We became intensely interested in it and devoted considerable time in seeking the origin of the tumor. We have here the testicle and on the surface apparently, the cæcum, the appendix and the rectum passing through the inguinal canal. On opening up the testicle we find several areas. We notice a dark circular cyst-like area throughout the whole organ. There is a white fibrous band. The tunica vaginalis is filled with partially clotted blood and hæmatocele. The epididymis is very much enlarged, and I will pass the specimen around so you can examine it for yourselves.

Sections taken from four different areas show various structures, such as a cartilaginous formation, myxomatous tissue, smooth and striated muscular fibers.

STONE IN THE BLADDER

DR. JACOB FRANK: I removed this kidney containing a stone from a woman, 43 years of age, who had been passing blood continuously for sixteen months. She claims never to have had any pain

The stone, a large one, resembles a monkey wrench. Her urine was examined microscopically since the operation but contained no blood. The patient left the hospital the third week.

DISCUSSION

DR. ARTHUR DEAN BEVAN: I have had but a limited experience in handling cases of papilloma of the large intestine. Dr. Frank has referred to a case of which I recently reported in the *Surgical Clinics of Chicago*. That was a single papilloma in the sigmoid and it interested me more from the standpoint of diagnosis than from anything else. I am glad Dr. Sippy is here, because it was his diagnosis which, to my mind, made the case particularly interesting.

I went to the hospital one morning and Dr. Sippy wanted me to remove a papilloma from the middle of the sigmoid. I asked him if he had seen it with the proctoscope and he said he had not; that the diagnosis had been made definitely from a careful analysis of the clinical findings. This woman had for a long time blood in the stool. The blood was not evenly intermixed with the stool, but was blood that would come in clots, and as I remember from the careful analysis which he made, he limited it to that portion of the bowel in which hardened fæcal matter is first formed, and he therefore made the diagnosis of polypus of the sigmoid, excluding definitely, on account of its long standing, carcinoma.

I made a laparotomy at his suggestion, picked up the sigmoid, ran it through my fingers, and could not find anything at first but finally stripping it back and forth I found a good-sized polypus, about the size of the end of my thumb, with a long pedicle. It was easily removed. It was a single polypus, and after its removal the hæmorrhage ceased entirely.

Multiple polypi I have seen several times. I have one case of polypus which produced invagination of the transverse colon. I operated on this case and it presented a very interesting picture. Multiple polypi of the colon present a very serious lesion for the patient because many of these cases terminate fatally. Quite a number of patients live long enough for these polypi to become carcinomatous, hence they are among the most serious lesions of the large bowel.

DR. A. J. OCHSNER: I would like to call attention to a method that I have used for disposing of these large intestinal polypi. The method consists in slitting open the intestine, putting a clamp at the base of the polypus and excising it with the cautery as one would remove a polypus in the rectum, through a proctoscope. The wound in the intestine is then closed. I have tried this method and it works well.

DR. CARL B. DAVIS: A year or more ago a patient that came under my observation was passing blood in the stools at irregular intervals. We made an examination with the proctoscope, but were unable to make a definite diagnosis. We could find nothing. We opened the abdomen and found the ascending, transverse and descending colon studded with polypi. There was hardly any place that was not covered with these polypi. The bowel was not removed. The patient still has polypi of the ascending, transverse, and descending colon; there are probably several hundred in that area. The patient is a man, 35 years of age.

DR. EMIL G. BECK read a paper entitled, "A Simple Method of Arresting Tuberculous Spondylitis, with Demonstrations of Patients and Radiograms."

REGULAR MEETING, JANUARY 3, 1919, WITH DR. THOMAS J. SULLIVAN, PRESIDING.

OSTEOMYELITIS OF THE CLAVICLE

DR. CARL B. DAVIS: A year ago this man was struck by an automobile and developed an osteomyelitis of the clavicle, which was treated from time to time, and the condition finally subsided, leaving him unable to raise the arm. The deltoid muscle has been detached from its clavicular region and has slipped down into the arm. An incision was made parallel with the clavicle below the line of the old scar. A second incision at right angles was carried down over the top of the shoulder until the deltoid was exposed to view. The muscle was found retracted to about one-half its length. A fascial flap was taken from the thigh with a thick layer of subcutaneous fat adherent. The flap was sewed over the shoulder-joint and with the fatty surface down to avoid adhesion of the fascia to the underlying structures. The upper end of the fascia was attached to the trapezius and clavicle. The arm was elevated to as high a point as we could get it, the deltoid pulled up and stitched into the fascia with chromic gut. At the completion of the suture the deltoid did not reach to the clavicular level by three-quarters of an inch. The cast was adjusted with the arm in complete abduction. The man has been out of the cast for a week, and it is gratifying to see the amount of motion he has already. We have started him on wand exercises hoping to speed the function.

NOTE.—On checking over these notes one month later, we might state that the man is able to lift his arm to a horizontal position.

DISCUSSION

DR. CARL BECK: The case of fascial plastic is very interesting, first, because the fascia healed in without reaction, and second, because the patient has a good functional result. This result will improve in the course of time. Unfortunately, fascia is not used as often as it should be in plastic work, and most of the men who use it, do so without the use of fat. Fat is a splendid lubricant, especially when the fascia is used to wrap tissues to protect tendons or nerves that adhere by cicatricial tissue.

ARTERIOVENOUS ANEURISM AFFECTING THE BRACHIAL PLEXUS

DR. LAWRENCE RYAN reported a case of arteriovenous aneurysm affecting the brachial plexus.

E. T., Italian, male, age 27, unmarried; occupation, watchman; has always been well and strong. He has had occasional nycturia but no venereal infection. He drinks wine with his meals, uses very little tea, coffee, or tobacco. He keeps good hours and eats and sleeps normally. On August 5, 1916, while on duty as a watchman, he was shot, the bullet entering the chest at the lower angle of the scapula on the right side. The bullet did not leave the body. He walked about 10 yards and fell unconscious. Profuse hæmoptysis occurred. Several hours later he regained consciousness. His right arm was completely paralyzed. By December, 1916, he had good use of his arm and partial use of the forearm. The hand remained almost useless. Since December, 1916, there has been no improvement in the hand. On August 20, 1916, the right pleural cavity was opened and drained. The empyema cleared up rapidly. On September 16, 1916, an attempt was made to remove the bullet but without success. In December, 1916, a second attempt was made to remove the bullet by another surgeon but again without success. These operations were performed in Pennsylvania. On September 1, 1916, a right sided tinnitus aurium made the patient very uncomfortable. He then noticed a marked thrill in his neck on the right side.

Examination revealed a well nourished man weighing 135 pounds; 5 feet 6 inches tall. The skin and mucosa are normal. No dryness, œdema, or pigmentation are present. There are many distended veins on the neck and head—possibly not abnormal. The right external jugular vein becomes greatly enlarged on compression above the clavicle. The right pupil is smaller than the left. Both react to light and accommodation. The fundi show no abnormal vessels, exudate or hæmorrhage. There are scars of previous operations in the cervical region. A definite, continuous thrill is felt over the vessels on the right side of the neck. The purring sound is continuous and cannot be identified with the heart beat. It appears somewhat more marked on systole. The teeth are good, the tongue is clear, presents no tremor and does not deviate. The throat and nose are clear. The chest is well developed, there is no change on respiratory excursion. There are two scars, one in the right post axillary line and one at the angle of the right scapula. There is no abnormal tactile or vocal fremitus. Breath and bronchial sounds are not pathological. There are no râles. The heart shows no enlargement. The sounds are clear and present no accentuation. Functional test shows no alteration in rhythym and gives a good return to normal. The heart muscle and the endocardium are normal. The pulse is even and compressible. The abdomen is normal. The liver edge is felt at the costal border. The kidneys and spleen are not palpable. There are no prominent veins. The abdominal reflex is normal. The inguinal canals are empty and the rings normal. There are a few bean-sized glands here. The genitals are normal, there are no scars and no urethral discharge. The scrotal reflex is present. The prostate is normal, likewise the rectum. The extremities are normal except the right arm. There is no clubbing of the fingers, scars, pigmentation or œdema. The reflexes react normally. Muscle tone and skin sensation are normal.

The osseous and glandular systems show no changes.

The temperature is 98.6°; pulse 72; blood pressure systolic 120, diastolic 70.

Blood: hæmoglobin, 90 per cent (Tallquist); coagulation time 5 minutes; white blood cells 6,000; red blood cells 4,800,000; no achromia, poikilocytosis or anisocytosis; platelets normal; no parasites. The blood (Wassermann reaction) is negative. The blood nitrogen is 25 mg. per 100 cubic centimeters of blood.

Urine: quantity, normal; reaction, acid; specific gravity, 1.020; no albumin; no sugar, white cells, red cells, casts or bacteria. Renal function: phenolphthalein test, appearance time 10 minutes, 90 per cent in 2 hours.

Stool: guaiac negative.

X-ray shows bullet close to vertebra in the right upper cervical region.

Diagonsis: Arteriovenous aneurism of right cervical vessels. Complicated paralysi of the brachial plexus involving the sixth, seven h, and eighth cervical and the first dorsal nerves producing motor paralys s, sensory, vasomotor and sympathetic changes.

The sympathetic involvement can be accounted for by injury to the rami communicantes of the first dorsal producing the contraction of the right pupil.

The ulnar disturbance is explained by diminished flexion of the hand, especially on the ulnar side. Flexion of the last three fingers is imperfect. The little finger can be moved only slightly. Paralysis of the interossei and the last two lumbricals is evident. There is a suggestion of the claw hand. Sensation of the volar surface of the last two fingers and dorsal surface of last three fingers is lost.

The median nerve shows involvement by reason of the deficient pronation of the forearm and the inability to flex the terminal phalanges of the fingers.

The shiny, bluish condition of the hand, the thermic changes, account for the vasomotor alteration.

The last operation was performed with the indications in view of first benefiting the paresis of the right hand, through the location or correction of a lesion of the right brachial plexus or second, what seemed more probable, the location of the arteriovenous aneurism and its removal, or a possible ligation. It was hoped that this would effect a cure by relief of the pressure caused by the aneurism.

This latter view was strongly favored by a report

of a very similar case, the result of gunshot, reported to this society at its March meeting of 1918 by Dr. Paul Morf.

The operation was performed by the writer, June 10, 1918, at the Frances Willard Hospital and was prolonged and tedious on account of the great amount of scar tissue—the result of the two previous operations, in this locality, and because of the pernicious hæmorrhage that accompanied the slightest cut. This was due to the extreme dilatation of the internal jugular and all its branches and communications even to the smallest venule.

The incision was carried down the right side of the neck from a point about the center of the right cervical region, anterior to the sternocleidomastoid muscle, to the clavicle and then along the upper surface of the clavicle toward the median line. This V-shaped trapdoor of skin and subcutaneous tissue was retracted upward and inward, and an attempt made to isolate the internal jugular vein and the common carotid artery.

The dissection over the upper part of this area located the bullet that could be readily felt through the unbroken skin. It was a soft lead 36-calibre ball. The "nose" had a decided split in it, the result probably of hitting a process lower down and then being deflected upward.

The internal jugular vein was enlarged to 3 or 4 times its normal size. The common carotid was pulseless, small and cord-like from one end of the wound to the other. The thrill was still present and was more marked at the root of the neck.

The operation could not be completed, nor the source of the trouble reached without enlarging the wound area. An additional incision was made across the center of the clavicle and downward for 4 inches below it. The clavicle was then resected at the junction of the inner and central thirds and the inner one third of the clavicle was turned inward.

The thrill was still palpable as far down behind the first rib as the index finger could reach. The communication between the internal jugular vein and the common carotid was in the common carotid artery very low down. It was close to the origin of the subclavicular artery, or may have been lower down. The subclavian pulsations were normal. The right common carotid artery was pulseless, small and cord-like, proximal to the communication with the internal jugular vein. It was then decided to ligate the internal jugular as low down as possible. This was done by two ligatures. The subclavian vein was also ligated on account of hæmorrhage. The internal jugular was clamped and cut off above the ligatures at the root of the neck and removed as high up as the center of the cervical region. The upper ligation was very difficult on account of the great dilatation of the jugular and the thinness of its walls.

In this attempt a severe hæmorrhage occurred. It would probably have been safer as regards the immediate result to have tied at intervals the internal jugular, instead of resecting it. Its resection was undertaken on account of the report on vessel ligation, read before this society some years ago by Dr. Donald McClain of Detroit. He advocated, at that time, the removal of a section of a vessel rather than to trust to a ligation or multiple ligations for the occlusion of the vessel.

After this loss of blood artificial respiration had to be resorted to and the wound was exposed to some contamination.

The fifth, sixth and seventh nerve roots were exposed in the open wound before the closure and also a portion of the eighth root. They were wholly normal in appearance. Whether they may have been injured distally from the wound areas is only conjecture.

The clavicle was reunited by means of chronic catgut and the wound closed in the usual manner.

The patient's recovery was uneventful except for some necrosis of one end of the resected clavicle. This readily cleared up resulting in fibrous union and considerable deformity of the clavicle at the point of resection. The function of the shoulder is perfect.

January 4, 1919, examination shows the thrill and pulsation absent.

The nerve condition as relates to the hand is unchanged—I can see no improvement and the patient sees none.

Two recent similar cases have been brought to my notice. The case of Dr. Morf and a case reported early in 1918 by Dr. Richard Cabot in his case records. The case is reported in detail. This was possible because he had access to the autopsy records. Dr. Cabot's case was the result of a gunshot, that produced almost identical nerve degenerations with those found in Dr. Morf's case and in the present case. In the Cabot case an aneurism of the injured vessel was found. A consultant staff of six surgeons of the Massachusetts General Hospital advised against an operation six months before. The persistence and growth of the aneurism caused them to reverse their former advice.

An attempt was made to ligate the internal jugular proximal to the aneurism. A severe hæmorrhage occurred. The patient died a few hours later from shock. The postmortem showed no gross lesion of the roots nor of the plexus other than the degenerative changes caused by pressure.

CORRESPONDENCE

ACCIDENTS FROM LOCAL ANÆSTHESIA

To the Editor: In 1913, I observed a death following the injection of novocaine.

A man, age 42, had suffered for some time with stomach trouble, probably caused by an epigastric hernia. His general condition was good. The man was not very fat, his lungs, heart, and kidneys were normal. On percussion the liver was found to be palpable and enlarged. Six centimeters above the umbilicus there was a swelling in the middle line. The swelling could be reduced by pressure but it was painful. An opening of about 1.5 centimeters was felt in the linea alba. I planned to operate on this patient on April 25. At 7:30 a.m., an injection of 10 milligrams of morphine was given in the forearm. At 8:30 the man was placed on a horizontal table. The skin was disinfected with iodine. An injection of ½ per cent novocaine with 1:100,000 adrenalin was given. When my assistant put in the needle the patient seemed to be nervous. His face and limbs turned pale and the pulse was small and weak before more than 1 or 2 cubic centimeters were injected. My assistant, who was an expert in administering local anæsthetics, then waited a moment. After a few minutes he continued the injection and the man grew miserable again. At this moment a quantity of not more than a half cubic centimeter was injected. My assistant again waited and the patient seemed to recover, but not for long. He soon became miserable again and suddenly rolled off the table and fell on the floor hurting his nose. He was very cyanotic and breathed convulsively. The pulse was very small and weak. In spite of injections of ol. camphoratum, massage of the heart and artificial respiration with my special apparatus, the patient died in a few minutes.

Postmortem examination. The patient is of normal stature. There is a swelling in the linea alba, 4 fingers above the umbilicus, around which are eight stab wounds from the needle, extending in a circle from the umbilicus halfway to the xiphoid process of the sternum. The swelling consists of preperitoneal fat and slips through an opening in the fascia. Situs viscerum normal. The omentum is free throughout the intestines. The peritoneum looks bright. No ascites present. The diaphragm on the right side is at the fourth rib and on the left at the fifth rib. The left lung collapses and is totally free. The right lung has many soft adhesions to the costal pleura and collapses not so well as the left lung. No hydrothorax is present. In the precardium there is slight hydrops. The left venous orifice three fingers, the left four. The foramen oval is open and is about 1.5 centimeters in diameter. The heart is soft. The valves are normal. Both lungs are very plethoric. There is no œdema or signs of tuberculosis or inflammation. The stomach is large, the appendix normal. The kidneys are very lobed, but the inner surface is normal (450 gr.). The spleen is large (230 gr.). The liver is large, the intersection normal. The testicles are small and in the scrotum. The thyroid is not enlarged; no thymus persistens. No swollen glands. Number of papillæ circumvallatæ normal.

The cause of death is not easy to explain. Was it due to nervous shock or to an acute intoxication? There was a slight indication of so-called status lymphaticus, the kidneys being lobed and the foramen ovale open. Therefore, we may suppose that with these conditions present the narcotic would have a greater effect than in a normal case. However, the nervous shock caused by the prick of the needle had already passed and the injection was completed before the real collapse occurred. If death was due to an intoxication, the time between the injections and death was very short and the dose of novocaine small.

In more than 6,000 cases I have injected the same or larger doses, and I have observed in cases of a serious nature — such as in gynecological operations where it is necessary to anæsthetize the pelvic region — a kind of shock one or two hours after the operation, and sometimes, even when smaller doses were used, there was a reaction during the operation. In such cases the patient turns pale and the blood pressure is diminished. I take it that these symptoms are the effect on the circulatory system of the combination of the intoxication and the reaction from the operation. Such phenomena often appear just at the moment when the surgeon pulls the intestines out of the abdomen or hugs the peritoneum during a herniotomy and sometimes when the mesenteriolum of the appendix is squeezed together. In all of these cases a reflex is to be expected, the nerves not being blocked at all.

Even in making skin incisions and in cutting the subcutaneous tissue, when there is no perception of pain at all, I have sometimes observed the same reaction. In the case reported the whole procedure took place some time before the operation. It is possible that some novocaine was immediately injected into the vein. This is not probable, however. The veins near the linea alba are not very large and the technique used by my assistant prevents such an accident, as he moves the needle during the injection.

The Hague — DR. J. SHOEMAKER.

ANNUAL SUBSCRIPTION: UNITED STATES AND CANADA, $10.00; FOREIGN, $12.00 (£2 10s.)

Volume XXVIII JUNE, 1919 Number 6

Surgery, Gynecology and Obstetrics

WITH

International Abstract of Surgery

EDITORIAL STAFF

FOR AMERICA

William J. Mayo, M.D.

E. Wyllys Andrews, M.D. J. Clarence Webster, M.D.

L. L. McArthur, M.D. E. C. Dudley, M.D. Frederic A. Besley, M.D.

A. J. Ochsner, M.D. C. S. Bacon, M.D. Carl Beck, M.D.

Thomas J. Watkins, M.D. John L. Porter, M.D. William R. Cubbins, M.D.

FOR THE BRITISH EMPIRE

Sir Arthur Mayo-Robson, C.B., C.V.O., D.Sc., F.R.C.S.

Sir Berkeley Moynihan, C.B., M.S., F.R.C.S. Thomas W. Eden, M.D., F.R.C.S.

Sir Harold J. Stiles, M.B., F.R.C.S. (Edin.) Henry Jellett, M.D., F.R.C.P.I.

James Rutherford Morison, M.B., F.R.C.S.

Franklin H. Martin, M.D., Managing Editor

Allen B. Kanavel, M.D., Associate Editor

EDITORIAL AND BUSINESS OFFICES: 30 N. Michigan Ave., Chicago, Illinois, U. S. A.

PUBLISHERS FOR GREAT BRITAIN: Bailliere, Tindall & Cox, 8 Henrietta St., Covent Garden, London, W. C., England

A New Edition

Graves' Gynecology

Nearly 500 Illustrations—100 in Colors

SAUNDERS, *Publishers*

SEE PAGE 13

Entered as second-class matter May 22, 1913, at the postoffice at Chicago, Ill., under the Act of Congress, March 3, 1897.
Published monthly. Copyright, 1919, by The Surgical Publishing Company of Chicago.

FINEST X-RAY WORK

IS EASY TO SECURE

Proper Technique, the Latest Type Tubes, and Fast, Rich Plates Like the Paragon Produce

We furnish the highest grade supplies at money-saving prices and technical information that enables even the beginner to produce fine radiographs.

DIAGNOSIS? You can read clear, brilliant plates at a glance. No other kind should be permitted.

Send For New Complete Price List—
It will save you money.

Some of our lines—We have many others:

X-Ray Plates. Three brands in stock for quick shipment. PARAGON BRAND for finest work, UNIVERSAL BRAND where price is important.

Barium Sulphate. (For stomach work.) Highest grade. None better at any price; 5, 10 or 25-pound cans.

Coolidge Tubes. The new 30 milliamp RADIATOR TYPE, also 10 milliamp small bulb; and fine, medium, or broad focus large bulb tubes, all $125.00.

Dental Films and Mounts
X-Ray Gloves and Aprons
Intensifying Screens **Filing Envelopes**

Developing Tanks to end hot weather troubles. Four or Six Compartment styles, also single tanks.

PARAGON X-RAY PLATES

Write us the kind of machine you use and we will send you our new instruction book when issued.

YOU CANNOT AFFORD
TO OVERLOOK US

GEO. W. BRADY & CO., 756 South Western Ave., Chicago, Ill.

SAVE TWO-THIRDS

Sherman's Bacterial Vaccines, when administered early, will reduce the average course of acute infections like Pneumonia, Broncho-pneumonia, Sepsis, Erysipelas, Mastoiditis, Rheumatic Fever, Colds, Bronchitis, etc., **to less than one-third their usual mortality and duration.**

Sherman's Bacterial Vaccines are prepared in our specially constructed Laboratories, devoted exclusively to the manufacture of these preparations and are marketed in standardized suspensions.

Write for literature.

MANUFACTURER OF BACTERIAL VACCINES

C. H. SHERMAN M.D.
Detroit, Mich.
U.S.A.

"Sutures fit for Surgery!"
Surgeons of Discernment
care not who WAS first in the Suture field, but who has BECOME first
DAVIS & GECK, INC.
217-221 Duffield Street, Brooklyn, N.Y.
Seattle San Francisco London
© 1918, DAVIS & GECK, INC.

CONTENTS—JUNE, 1919

ORIGINAL ARTICLES

1. THE EXPERIMENTAL PRODUCTION OF PANCREATITIS IN ANIMALS AS THE RESULT OF THE RESISTANCE OF THE COMMON DUCT SPHINCTER. *Edward Archibald, M.D., F.A.C.S., assisted by Mr. Brow, Montreal, Canada* 529

2. TREATMENT OF PURULENT ARTHRITIS BY WIDE ARTHROTOMY FOLLOWED BY IMMEDIATE ACTIVE MOBILIZATION. *Dr. C. Willems, Ghent, Belgium* 546

3. ROENTGENOGRAPHIC DIAGNOSIS IN RENAL TUBERCULOSIS. *W. F. Braasch, M.D., and F. A. Olson, M.D., Rochester, Minnesota* 555

4. ACUTE INTESTINAL OBSTRUCTION FOLLOWING APPENDECTOMY. *Anthony H. Harrigan, M.D., New York* 561

5. THE STATUS OF THE VESICAL SPHINCTER AFTER PROSTATECTOMY. *Ernest M. Watson, A.M., M.D., Buffalo, New York* 569

6. THE ACUTE ABDOMEN. *F. Gregory Connell, M.D., F.A.C.S., Oshkosh, Wisconsin* 583

CONTENTS CONTINUED OPPOSITE NEXT PAGE

Connell
GAS OXYGEN APPARATUS

Some of Its Features

Meter measure of the gas and oxygen. Accuracy. Economy of gases. Convenience of anesthetist. Safety and comfort of patient.

Simplicity and durability. The entire apparatus is compact and is manufactured without complicated springs, valves, etc.

Mechanically perfected ether dropper with sight feed; a safety lamp that is always safe, with a coil principle vaporization of ether that completely vaporizes in any quantity of administration.

Many other individual features which appeal to the surgeon looking for efficiency are explained in our booklet "Scientific Anesthesia." *Write for a Copy.*

"The Machine With the Meter"

SCIENTIFIC APPARATUS CO.
162 WEST 34th STREET NEW YORK

Graduated Low Tone Tuning Forks

Devised by DR. W. G. REEDER

Important Announcement

WE are now able to deliver the first graduated low tone tuning forks manufactured in America. These forks are graduated in four tone intervals from 16 to 64 double vibrations per second. They are free from overtones and guaranteed to be perfect. Otologists who have been unable to obtain such a set of instruments at any figure since the war, are now offered a superior product at a nominal price. These forks are indispensable in accurate functional testing of the ear, especially in cases of incipient conduction deafness and those in which the lower tone limit is disturbed.

No. 1 Reeder's Tuning Fork, 16 to 20 double vibrations, is 23½ inches long and weighs 7½ lbs. . . . . Price $35.00

No. 2 Reeder's Tuning Fork, 24 to 28 double vibrations, is 19½ inches long and weighs 7 lbs. . . . . Price $35.00

No. 3 Reeder's Tuning Fork, 32 to 44 double vibrations, is 17 inches long and weighs 7 lbs. . . . . Price $32.50

No. 4 Reeder's Tuning Fork, 48 to 64 double vibrations, is 14 inches long and weighs 6 lbs. . . . . Price $32.50

SHARP & SMITH

Manufcturers and Exporters of High Grade Surgical Instruments and Hospital Supplies

65 E. LAKE ST. Between Wabash Ave. and Mich. Blvd. CHICAGO, ILL.

Established 1844 Incorporated 1904

Your Pharmacist Knows

Send for beautifully illustrated catalog, in four colors, showing the complete line of Lilly Aseptic Metal Pocket Cases

YOUR pharmacist knows the care required to make a snow-white hypodermatic tablet of even texture, accurate grainage and dependable solubility.

Hand moulding hypodermatic tablets is more than a matter of routine; it is a definite responsibility. A hypodermatic injection is often an emergency measure; the physician relies upon it to produce results—quickly.

Ask your pharmacist for something more than a tube of hypodermatic tablets—specify Lilly's.

Drop One In Water; Watch It Disappear

ELI LILLY & COMPANY, Indianapolis, U. S. A.

NEW YORK CHICAGO ST. LOUIS KANSAS CITY NEW ORLEANS

Success in Treating Infections

Light rays are now recognized to be the most effective means for producing the active hyperemia essential to increased leukocytosis for relief of infections and pain.

Treating a Bullet Wound

Ask for free copy of the reprint by A. J. Ochsner, M.D., LL.D., F.A.C.S., Chicago, entitled "Practical Value of Electric Light in the Treatment of Infections."

Radio-Vitant Applicators

Are extensively used in both the surgeon's office and hospital.

Specially adapted for use in the patient's home under supervision of the surgeon.

Standardized in the Surgeon-General's Office for use in the Military Reconstruction Hospitals.

Proven by practical experience to be far superior to vibrators, high frequency currents, "high candle-power lamps," etc., for local applications in the relief of pain and inflammation.

Type L4 Applicator $27.50

Our guarantee, entire satisfaction or money back

BURDICK CABINET COMPANY

614 Venetian Bldg. Chicago, Ill.

201 Madison Ave. Milton, Wis.

Who Uses A Dull Blade Is Himself Dull

OPERATING with the Bard-Parker Knife makes the operation safer, surer. The blade is sharp, the cut is clean.



Blades Nos. 10 and 11 fit No. 3 handle only.
Blades Nos. 20, 21 and 22 fit No. 4 handle only.
Handles $1.00 Each. Blades $1.50 per dozen.
Case for two handles and two dozen blades, 75 cents.
Blades are packed in envelopes containing ½ dozen blades of one size.

Your Dealer Can Supply You

BARD-PARKER CO., Inc. 37 E. 28th St., New York

EYNARD CATHETERS

Ureteral Catheters, graduated in centimeters and non-graduated.
Ureteral Catheters, X-ray, graduated in centimeters and non-graduated.

Whistle, Round and Olive Tips.

Urethral Catheters and Bougies in rubber and gum.
— Drains —

C. R. BARD 37 E. 28th St. **New York**

Prestige

Four years' active service in the conservation of human lives with the U. S. Government, American Red Cross, Bellevue Hospital, Standard Oil Co. and over 5000 other hospitals, cities, doctors and industries has established beyond question the efficiency of the *Lungmotor*.

Lungmotor protection in your hospital, community, industry is essential. They look to you for the recommendation of *Lungmotor* installation. Send for new descriptive literature.

THE Lungmotor

Ask about the "New-Born" Infant Lungmotor

LUNGMOTOR COMPANY

710 Boylston St., BOSTON, MASS.

URETHRITIS

Specific and Non-Specific

Treatment by the application of heat is not a new principle, but has remained undeveloped for lack of a proper method.

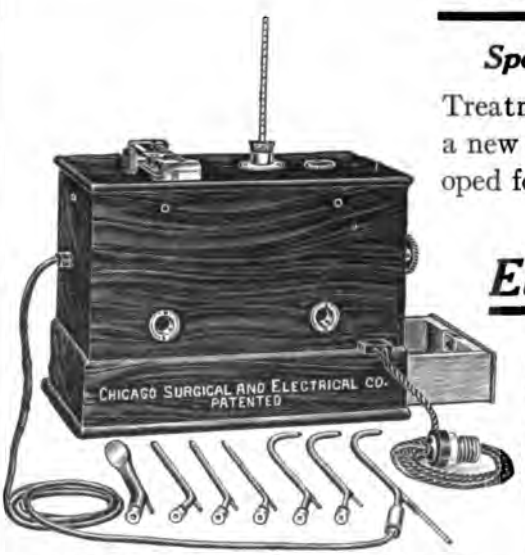

The

Electro-Thermophore

is a new scientific apparatus that supplies the missing link and furnishes controlled, uniform heat within a fraction of a degree.

Write for Detailed Information

CHICAGO SURGICAL AND ELECTRICAL CO.

Manufacturers

316 W. SUPERIOR ST. CHICAGO, ILL.

Public Health Officials Condemn Poisonous Antiseptics

Chlorazene used as a gargle

Chlorazene used for wounds

Chlorazene used as a douche

DR. WM. McNALLY, Chemist to the Coroner of Cook County, Illinois, reports 781 recorded deaths due to Phenol and 110 deaths due to Mercuric Chloride in Cook County, during the years 1905 to 1917 inclusive. Many of these deaths were accidental.

Accidents are made impossible by the use of CHLORAZENE, Dakin's water-soluble, non-poisonous antiseptic, FIFTY TIMES stronger in its germicidal action than Phenol. CHLORAZENE is non-irritating, safe and stable. For these reasons, it is fast becoming the universal antiseptic.

CHLORAZENE solution is used with excellent results as a gargle in sore throat, mouth and nose infections and as a prophylactic.

CHLORAZENE is also successfully used in surgery, eye infections, wounds, burns, as a vaginal douche and as a powerful, effective antiseptic for general use.

Solutions are quickly and conveniently made by simply dissolving CHLORAZENE Tablets or Powder in a glass of water.

For Sale at all Druggists—Specify "Abbott's"

Chlorazene Tablets in bottles of 100, 500 and 1000.
Chlorazene Powder in hospital packages No. 1 and No. 2.
Chlorazene Cream, Chlorazene Surgical Powder, Chlorazene Surgical Gauze.

A postal card will bring literature and prices. Also ask for Prices of Dichloramine-T, Chlorcosane, Parresine and Parresined Lace-Mesh Dressing.

The Abbott Laboratories

Home of the Dakin Products

ALL AMERICAN **ALWAYS AMERICAN**

Home Office and Laboratories

DEPT. 82, CHICAGO, ILL.

NEW YORK **SAN FRANCISCO** **TORONTO**
SEATTLE **LOS ANGELES** **BOMBAY**

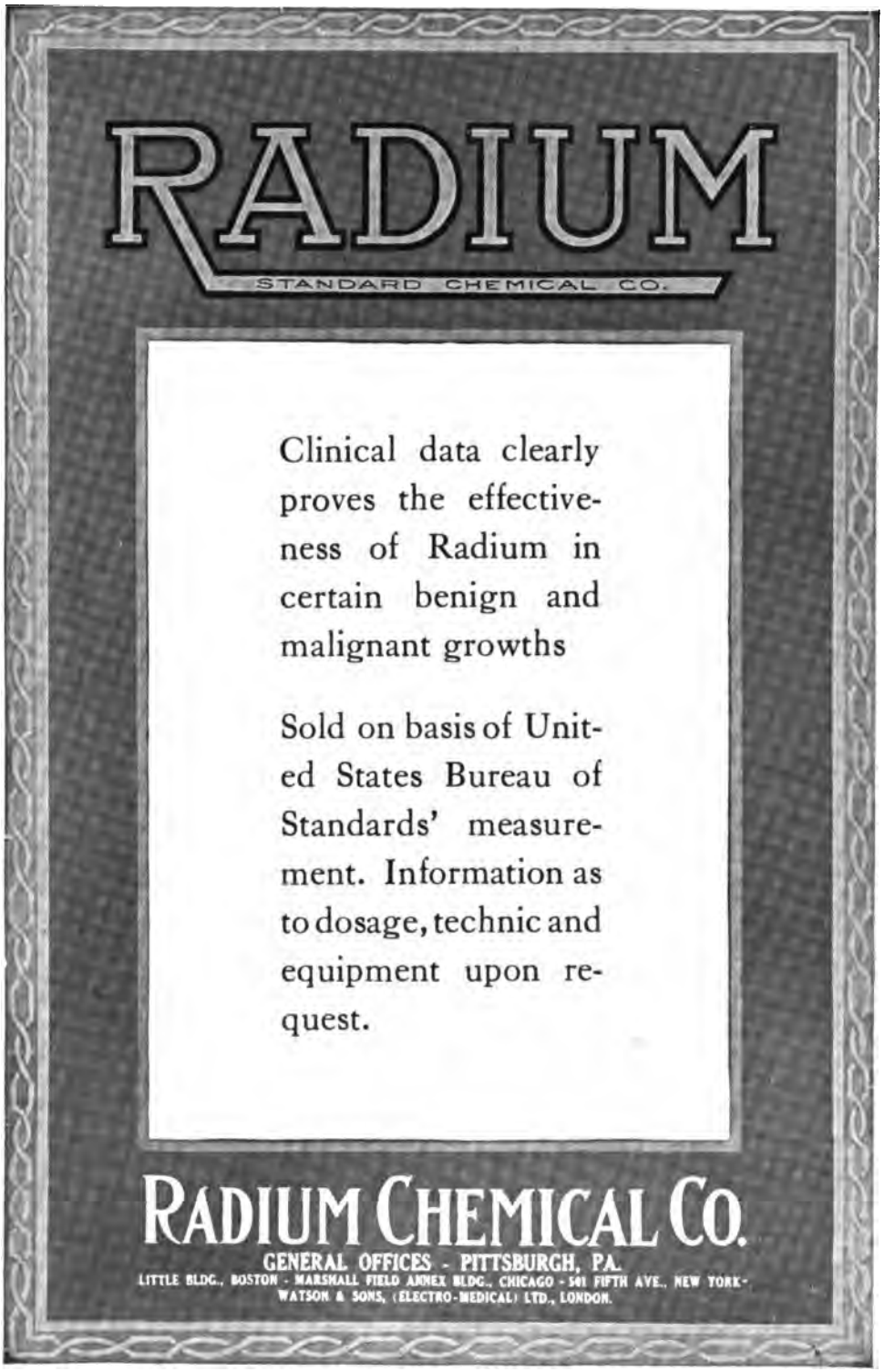
RADIUM
STANDARD CHEMICAL CO.
Clinical data clearly proves the effectiveness of Radium in certain benign and malignant growths
Sold on basis of United States Bureau of Standards' measurement. Information as to dosage, technic and equipment upon request.
RADIUM CHEMICAL CO.
GENERAL OFFICES - PITTSBURGH, PA.
LITTLE BLDG., BOSTON - MARSHALL FIELD ANNEX BLDG., CHICAGO - 501 FIFTH AVE., NEW YORK -
WATSON & SONS, (ELECTRO-MEDICAL) LTD., LONDON.

Pratt-Lowman Self-Retaining Retractor

for use in the open method of repairing fractures especially in connection with the Albee Motor Saw method.

Devised by Major John B. Lowman, M.C., and Captain R. B. Pratt, M.C., U. S. Base Hospital No. 38.

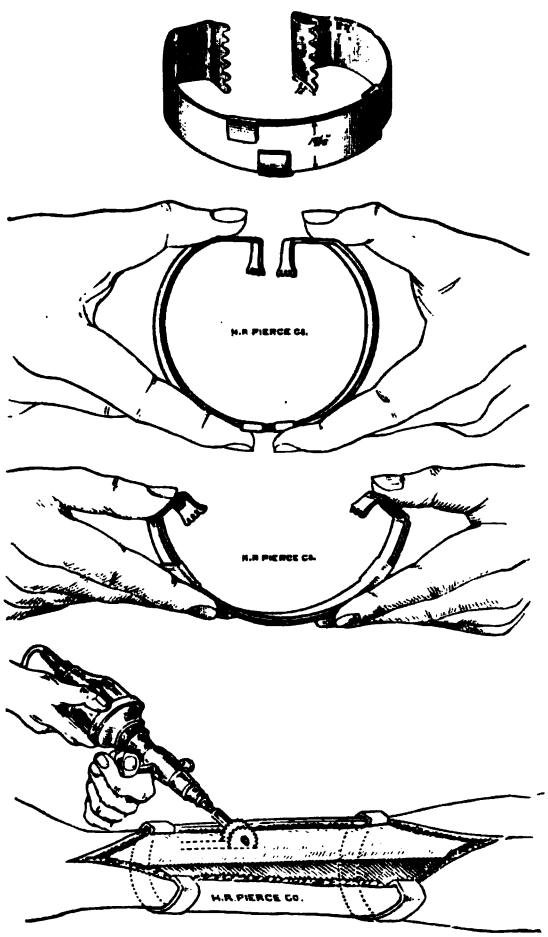

It affords the following advantages:

SIMPLICITY

No parts to be lost. Easy to clean, sterilize, manipulate.

DURABILITY

It not only gives RETRACTION of tissues, but also DEPRESSION of them with an uncomplicated automatic lock in any degree of retraction. Pressure upon its lower surface by the weight of the limb forcing it against the operating table only serves to increase retraction and locking.

It does away with retraction by assistants and with this the danger of extra hands in the operative field and leaves the operator unhindered in the use of the electric saw and drill.

It leaves the bone in a higher plane than the surrounding tissues and so obviates the danger of the saw, drill or spinning shaft engaging with the soft tissues or toweling.

In conjunction with an orthopedic table, assistants can be dispensed with during that stage of the operation in which the saw or drill is in use.

It is a useful addition in a teaching clinic in that it renders the field of operation more visible to spectators.

Made in two sizes; larger size for femur; smaller size for tibia and humerus. Used in pairs. Either size per pair, $8.00.

Manufactured by

HARVEY R. PIERCE COMPANY

1801 Chestnut Street *The Modern Surgical Instrument Store* **PHILADELPHIA**

PITTSBURGH SALES OFFICE: 3030, 3031, 3032, 3033 JENKINS ARCADE



New Quarters for the

Hollister-Wilson Laboratories

THIS NEW HOME of the Hollister-Wilson Laboratories was planned and built with the basic idea of having easy access to the raw material from Wilson & Company, Packers, to whom we are subsidiary, while at the same time isolating our actual manufacturing processes.

This first unit of our new buildings contains 30,000 square feet of floor space and is designed particularly to answer the manufacturing requirements of a very exacting line.

In addition to Ligatures, Sutures and Surgical Material, we manufacture a complete line of Animal Derivatives used in medicine and surgery including Digestive Ferments, Glandular Autacoids, Organic Extracts and Abattoir Pharmaceuticals.

THE most up-to-date manufacturing and scientific equipment has been installed and every step in the manufacturing processes will be in charge of experienced technical experts.

In the general promotion of this enlarged line, attention is directed to our resources in the way of raw materials, original methods of handling, physiologic, biologic and chemical assay which insures the identity and activity of the autacoid principles represented in the finished product.

We offer the resources of this splendidly equipped laboratory for co-operation with individuals or institutions interested in research work.

Our complete Illustrated Catalogue will be sent upon request. Send for it **Today.**

THE

HOLLISTER-WILSON LABORATORIES

4221-23-25 S. WESTERN BLVD. CHICAGO, U. S. A.

The Radium Company of Colorado, Inc.

Denver, Colorado

Announcing an Exhibit

of Special Interest

to the

RADIUM THERAPEUTIST

at the

American Medical Association

June 9th to 13th, 1919

Atlantic City

Space 133-134, Balcony Ballroom

near A M.A Exhibit

Mines

Naturita, Colo.

New York Office

50 Union Square

Reduction Works

Laboratories

Denver Colo.

New (2d) Edition

Graves' Gynecology

For this edition Dr. Graves has given his book a thorough revision and brought it completely up to date. New matter has been added to the extent of 115 pages, and 66 additional illustrations included. The illustrations in this work form a feature. There are 491 of them, 100 in colors—microscopic, gross pathologic, and operative technic step by step.

Some of the New Matter Added

The section on the relationship of gynecology to internal secretions has been rewritten and considerably amplified. Much new matter has been added under ovarian organotherapy and ovarian transplantation, the radium treatment of cancer, radium therapy in non-malignant gynecologic diseases. A new section discusses the relationship of gynecology to the sex impulse, based chiefly on the theories of Freud regarding infant sexuality. A number of new operations are described and illustrated, most of which have not before appeared in text-books.

Dr. Graves presents gynecology along new lines. An entire section is devoted exclusively to the *physiology* of the pelvic organs and to *correlated gynecology*—the relationship of gynecology to organs of *internal secretion*, breast, skin, organs of sense, digestion and respiration, blood, circulatory apparatus, abdominal organs, nervous system, bones and joints.

The section devoted to *surgical gynecology* is most complete, the detailed descriptions being shown by beautiful illustrations. Dr. Graves' work has always been noted for its lucid and forceful text, its broad conception, and the wealth and instructive nature of its illustrations.

"In the work of Graves we have a new era. The woman herself is considered—her femininity—and gynecology is elaborated. It is a masterly work on the woman with a womb—not from the old viewpoint of a womb and a woman secondary."—Dr. G. K. Dickinson, *Jersey City, N. J.*

Octavo of 885 pages, with 491 illustrations, 100 in colors. By WILLIAM P. GRAVES, M. D., Professor of Gynecology at Harvard Medical School. Cloth, $7.75 net.

W. B. SAUNDERS COMPANY, West Washington Sq., Phila.

London: 9, Henrietta St., Covent Garden Australian Agcy: Centreway, 263 Collins St., Melbourne

SAFETY GAS-OXYGEN APPARATUS

SIMPLIFIES

the administration of

NITROUS OXID and OXYGEN

with or without an ETHER sequence in

MAJOR or MINOR SURGERY—
OBSTETRICS—DENTISTRY

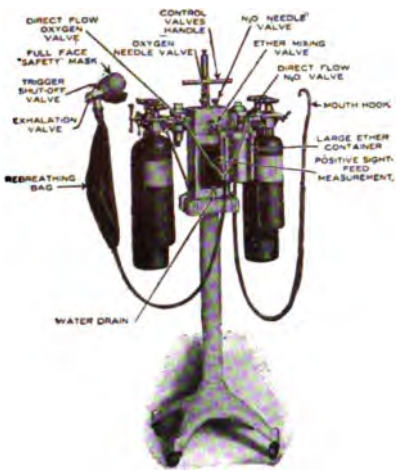

Model "F," with large ETHER Container and Mouth Hook. Style "B" and "C" Cylinders Attached.

The IDEAL HOSPITAL APPARATUS. This is the Outfit supplied all American Government mobile operating rooms in France, and many Military Hospitals and Cantonments in the United States. Uses from 40 to 60 gals. of N_2O per hour of profound anæsthesia.

The old TROUBLE points ELIMINATED.

No high pressure bags. No spring gauges. No delicate mechanisms to get out of order.

The "Safety" employs HYDROSTATIC regulation which is *always* dependable and accurate.

Simple to operate. Minimum gas consumption. Ideal Anæsthesia and Analgesia.

Perfectly controlled smooth mixtures assured by

THE NEW

Positive Sight-Feed-Measurement

YOU SEE 1 The flowing of the separate gases.
2 That you obtain the desired mixtures.
3 That your mixtures are accurately maintained as long as required.

Gases delivered *Washed*, *Moistened* and *Heated* to body temperature.

Manufactured in three models, "D," "E" and "F;" truly portable and complete outfits for Private and Hospital use.

Write for illustrated booklet containing full information



Cut showing Sight-Feed-Measurement, 3/7 actual size. The water-level "A" in the Oxygen Feed Tube, and the water-level "B" in the Nitrous Oxid feed tube fall or rise as a greater or less volume of the respective gases is admitted to the mixing chamber, by the needle valves. Accuracy of mixture and VISIBLE PROOF OF ACCURACY are thus assured.

SAFETY ANAESTHESIA APPARATUS

Ogden Ave. & Randolph St. CON CERN CHICAGO, ILLINOIS

Medico-Mechanical Treatment in Cases of Motor Disturbances and Muscular Debility

There is no remedy which, in cases of accidents and affections of the joints and muscles, will restore the regular use of the limbs more quickly than early Medico-Mechanical treatment.

It is obvious that active exercise of the entire musculature will essentially change the conditions of the circulation, hence necessarily also act favorably upon a part in which an obstruction to the circulation is manifest (engorgement, œdema, change of tension due to pressure, with all its consequences).

This apparatus for the upper extermities is used for: Bending of the Hands, Stretching of the Hands, Lowering of the Arms, Raising of the Arms, Extension of the Arms, Rotation of the Arms, Rotation of the Forearms, Rotation of the Arms in Alternation, Bending of the Forearms, Extension of the Forearms.

In the next issue we will show the apparatus for the Lower Extremities

Send for Our Booklet on Combination Apparatus

The Kny-Scheerer Corporation

404-410 West 27th Street - - - - - NEW YORK, U. S. A.

RADIUM

OVER $4,000,000.00 invested by physicians and hospitals in radium demonstrates conclusively its value in the treatment of malignant and other conditions.

May we furnish you information in respect to clinical data, etc.?

THE W. L. CUMMINGS CHEMICAL CO.

Works and Laboratories

LANSDOWNE **PHILADELPHIA**

The Surgeon

is generally called upon for advice as to

Artificial Limbs

Why not recommend one that is sure to be SATISFACTORY?

Our Latest Model

with Adjustable Leather Socket, Cordless Ankle, Felt or Sponge Rubber Foot, Ball-bearing Joints

assure the patient of comfort and perfect locomotion.

Our GUARANTEE Covers All Repairs

Write for Catalogue

FEICK BROS. COMPANY

809 Liberty Ave. **Pittsburgh, Pa.**

SKELETONS

We have secured a large stock of

Selected Skeletons

Prices and descriptions gladly furnished on application

TRUAX

CHARLES TRUAX, Incorporated

141 N. Wabash Ave. **CHICAGO**

The Eclipse Door in
DEANE'S STERILIZERS

insures efficiency and safety. The slightest pressure within the chamber prevents the escape of the sterilizing reagent, or the opening of the door. This guarantees doctors, nurses and attendants against injuries such as have occurred with outwardly opening doors.

Our Advisory Department, with sixty years experience equipping the leading hospitals, is at your service and our catalogues are yours for the asking.

BRAMHALL, DEANE CO., 263 N. West 36th St., New York, N.Y.

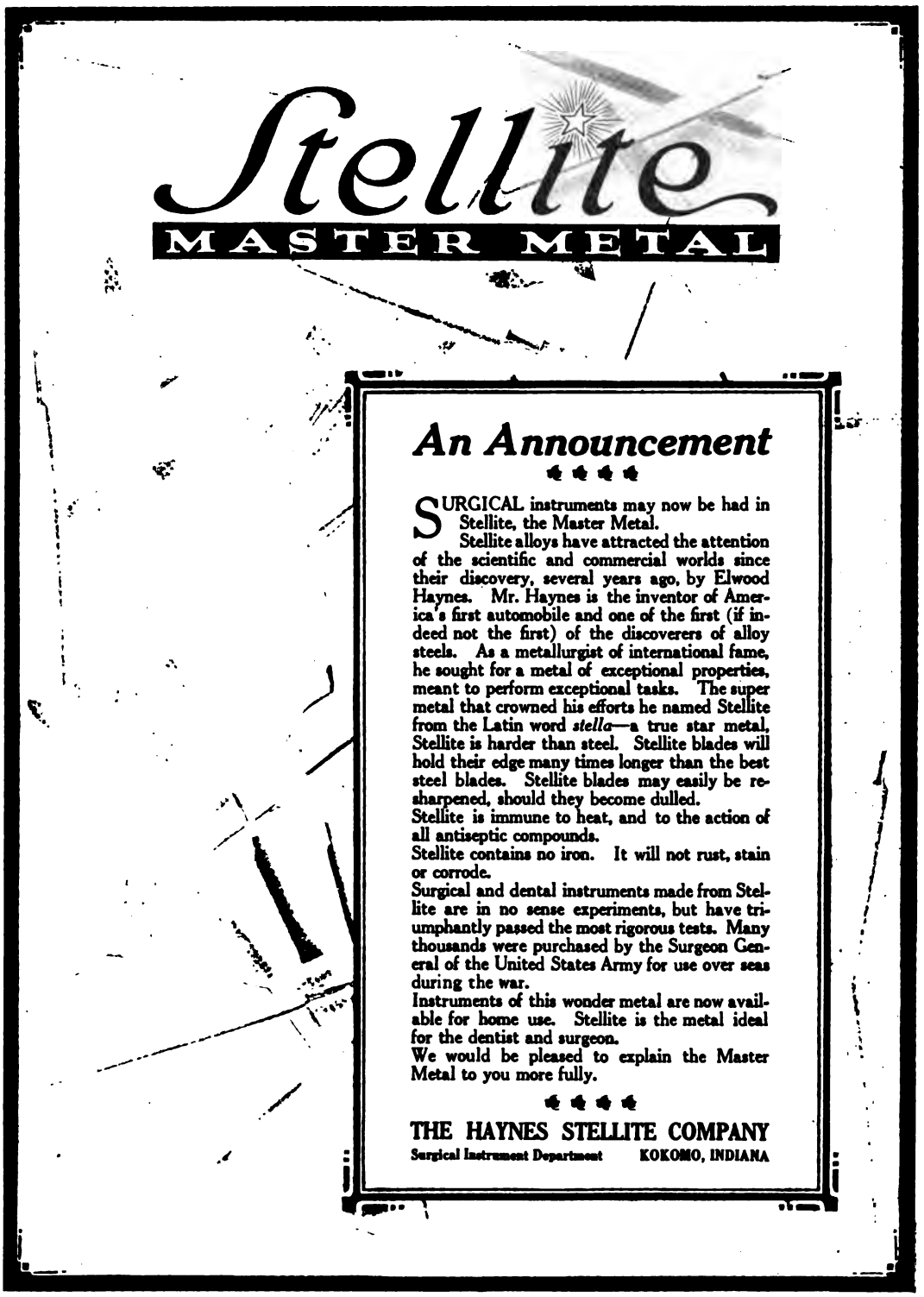

An Announcement

SURGICAL instruments may now be had in Stellite, the Master Metal.

Stellite alloys have attracted the attention of the scientific and commercial worlds since their discovery, several years ago, by Elwood Haynes. Mr. Haynes is the inventor of America's first automobile and one of the first (if indeed not the first) of the discoverers of alloy steels. As a metallurgist of international fame, he sought for a metal of exceptional properties, meant to perform exceptional tasks. The super metal that crowned his efforts he named Stellite from the Latin word *stella*—a true star metal. Stellite is harder than steel. Stellite blades will hold their edge many times longer than the best steel blades. Stellite blades may easily be resharpened, should they become dulled.

Stellite is immune to heat, and to the action of all antiseptic compounds.

Stellite contains no iron. It will not rust, stain or corrode.

Surgical and dental instruments made from Stellite are in no sense experiments, but have triumphantly passed the most rigorous tests. Many thousands were purchased by the Surgeon General of the United States Army for use over seas during the war.

Instruments of this wonder metal are now available for home use. Stellite is the metal ideal for the dentist and surgeon.

We would be pleased to explain the Master Metal to you more fully.

THE HAYNES STELLITE COMPANY

Surgical Instrument Department KOKOMO, INDIANA

Three Sizes—
Doctor's $60
Medium $85
Hospital $145

Ask Your Dealer

At Home and "Over There"

—in public and private hospitals, physicians' and surgeons' offices, dispensaries, laboratories, and in U. S. Army and Red Cross field and base hospitals, the National High Pressure Steriliser has demonstrated its rapidity and efficiency by furnishing sterilised "bone dry" dressings in half the usual time required by more expensive high pressure sterilizers.

National HIGH PRESSURE Sterilizers

are durably constructed of the highest grade steel plate, semi-steel castings and polished copper. Simple to operate—no complicated valve system. Perfect sterilisation guaranteed, more capacity for one-fourth the cost. The "National" is sold by surgical supply houses everywhere. Ask your dealer.

NORTH-WESTERN STEEL & IRON WORKS
835 SPRING STREET EAU CLAIRE, WIS.



The
Pad Without a Fault

It has none of the drawbacks of other electric pads. It is so near perfection that it is

Guaranteed For One Year

The Goodwill Thermostatic control gives positive temperatures ranging from 100° to 180°. Used and endorsed by leading hospitals and physicians. *Money back if not satisfied.* Price $7.00. Order to-day.

GOODWILL ELECTRIC CO.
59 E. VAN BUREN ST. DEPT. A CHICAGO

"Vanta" Abdominal Binder

KNITTED of soft wool—firm but elastic—it gives just the protection and abdominal support needed, yet always adjusts itself to the full or empty stomach.

A big improvement on the old-fashioned inelastic strip of flannel. Ties with three little bows of *twistless* tape—no dangerous pins—no troublesome sewing.

We would like you to know, Doctor, what an excellent binder this is. Mail us your card, or write on professional letterhead, and we will gladly send you a sample binder free.

EARNSHAW KNITTING COMPANY
1401 West Jackson Blvd - Chicago

The Abdominal Binder illustrated above is only one of the many Vanta Garments that enable baby to be dressed from top to toe without a single pin or button. Our booklet, "Baby's Outfit," describes and illustrates the entire line. May we send you a copy?

McIntosh Universalmode
(Trade Mark)

FREE - "Electro-Therapeutics Condensed"

A handy manual containing the latest clinical data on electro-therapeutical treatment and shows where the use of this modern agency is indicated. Also shows the very latest development in electro-therapeutical apparatus.

It Tells You Why

THE UNIVERSALMODE IS SUPREME

Galvanic, Faradic, Sinusoidal, Cautery, Vibration, Air Diagnostic Light in Their Highest Efficiency.

The result of over forty years of experience as manufacturers of Electro-Therapeutical and X-Ray Apparatus.

McINTOSH BATTERY & OPTICAL CO.

Eastern Office and Service Station 1777 Broadway, New York

Main Office and Factory 217-223 N. Desplaines Chicago, Illinois

Please send a copy of "Electro-Therapeutics Condensed" and complete details regarding your special offer on the Universalmode

Name_____

Address_____

Why Not Have That Satisfaction

of knowing your blood pressure readings are taken with an instrument that ***proves*** its readings? That instrument is the

Tycos Fever Thermometers

Tycos Urinary Glassware

Tycos
Self-Verifying Sphygmo-manometer
$25.00

The Tycos is absolutely self-verifying. It has no adjustments; requires no checking. If the pointer returns to zero, the reading is ***correct.***

Have a demonstration at your dealer's. It will gain your good will, as will the daily use hold it.

Taylor Instrument Companies
ROCHESTER, N. Y. 700
There's a Tycos and Taylor Thermometer for every purpose.

HYCLORITE

HYCLORITE

For Infected Wounds

The results obtained from the use of Hyclorite in the treatment of infected injury cases are daily demonstrating the efficacy of this antiseptic in the oxidizing of toxins, and in the removal of necrosed tissue through solvent action. In these respects, according to the work reported by Milroy and also Austin and Taylor, hypochlorites are decidedly superior to the chloramin and dichloramine type of antiseptic.

Accepted by the Council on Pharm. and Chem. for inclusion in N.N.R.

Hyclorite is always ready for immediate use.

Just add water and apply.

Hyclorite is prepared to a definite hypochlorite strength and alkalinity.

Solutions made from Hyclorite keep much longer than ordinary Dakin's solutions.

There is no waste, testing, or waiting in making a Dakin's solution from Hyclorite.

Price, 32 oz., $1.25

Order from Your Supply House

GENERAL LABORATORIES
4714 South Dickinson St.
MADISON - - - WISCONSIN

A Wonderful Advance

WE conduct a Pasteur Institute, which furnishes Pasteur Treatment by Mail, plus the advantage of expert consultation by letter or long distance telephone. This saves the patient the expense and time of coming to the city, and gives him Efficient Treatment at a Nominal Cost.

Our Proposition: Full Course of Treatment, one glass 5cc, syringe and needles, full advice and directions complete for $50,00.

Keep this before you. Rabies is a common disease. Investigate every dog bite and avoid disaster.

We make all other Laboratory Tests

THE PASTEUR INSTITUTE OF ST. LOUIS

The Gradwohl Biological Laboratories

928 N. Grand Ave. ST. LOUIS, MO.

R. B. H. Gradwohl, M. D., Director, on leave in service.
Carl Powell, M. D., Acting Director.

Gwathmey Apparatus

The advantage of the "Sight Feed"

is not—to ***set*** the proportion,

it is—to ***get*** the proportion.

Nor is it—to know the amounts in liters or gallons,

but it is—to know what you are doing.



As an indicator for the quick obtainance and safe maintenance of uniform anesthetic conditions the visible gas flow of the "Sight Feed" is absolutely reliable and permanently so.

Write for Our 1919 Catalog

THE FOREGGER CO.

47 West 42nd St. New York

Sani-Dri

See the demonstration of this

Non-Rubber, Water-Proof and Acid-Proof Fabric

at the A. M. A. Convention, Atlantic City
June 9-13, 1919

A Remarkable Fabric

Waterproof Fabric Company 6423-25 N. Clark St., Chicago, U. S. A.

Applied in a Minute and Holds Forever!

The E-Z
Self-Cementing
Self-Vulcanizing
PATCH

A Permanent, Economical Patch for Repairing Rubber Gloves

The E-Z Patch is applied so easily and quickly that its very simplicity will appeal to you — to say nothing of the many dollars it will save. A little sandpaper and a drop of gasoline are the only things required.

The moment the E-Z Patch is subjected to heat, it vulcanizes and becomes an integral part of the object. Repeated sterilization only makes the patch hold better. There's no danger of infection.

THE E-Z PATCH COMPANY
AKRON, OHIO

Send for Trial Envelope Containing 6 for 25c
Hospital Size Package, 50 for $1.00
Samples on Request

WE CAN SUPPLY YOU WITH

Gauze and Bandages

Prices upon request

The Good Manufacturing Co.
156 N. Wells Chicago

Cash for Back Numbers

Will pay 50 cents each for copies of the following back numbers of *Surgery, Gynecology and Obstetrics*, if in good condition for binding.

August, 1905
January, 1906
March, 1906
March, 1908

Surgical Publishing Company
30 No. Michigan Ave. CHICAGO

Electrically Lighted Instruments

From the best material obtainable and by skilled workmen E. S. I. Co. instruments are made. Not alone are we the originators, but, as well, we are exclusive manufacturers of the most valuable diagnostic instruments in use. Their position is firmly established among the profession and their usefulness is unquestioned.

All our instruments may be operated upon our tungsten battery or upon commercial current by means of the socket current controller here illustrated.

Koch, Swinburne, Young, Gordon and MacGowan Urethroscopes
Braasch Cystoscopes, E. S. I. Co. Vaginal Specula

These and many other instruments are described and illustrated in our Catalogue, a copy of which will be mailed on request.

For your own protection be sure every instrument is marked "E. S. I. Co."

ELECTRO SURGICAL INSTRUMENT CO.
ROCHESTER, N. Y.

DAVIS'
Plastic and Reconstructive Surgery

By JOHN STAIGE DAVIS, Ph. B., M.D., F.A.C.S.

Captain, Medical Corps, U. S. Army; Instructor in Clinical Surgery, Johns Hopkins University; Assistant Visiting Surgeon, Johns Hopkins Hospital; Plastic Surgeon, Union Protestant Infirmary, Hospital for Women of Maryland and Children's Hospital School, Baltimore, etc.

Upwards of 1,000 Illustrations

P. Blakiston's Son & Co., Publishers. 1012 Walnut St., Philadelphia

ON APPROVAL ORDER

P. BLAKISTON'S SON & CO., Philadelphia, Pa. Date_____

Please send me for 10 days' examination Davis' Plastic and Reconstructive Surgery. I will remit in 30 days if I keep the book.

Name_____

Address_____

_____

S. G. & O. June
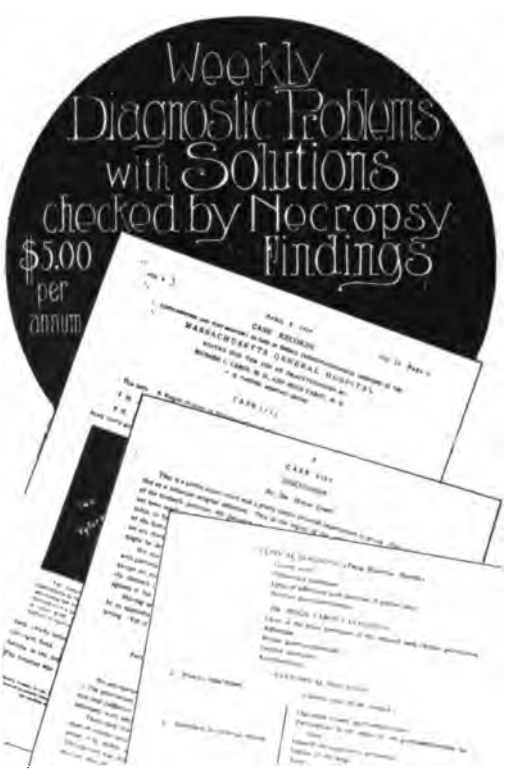
Every Practitioner May Join This Class in Diagnosis

The Case Records of the Massachusetts General Hospital, edited by Richard C. Cabot, M.D., and Hugh Cabot, M.D., carry to the busy or the isolated physician or surgeon the essential spirit and stimulus of the hospital clinic. These are practical problems in diagnosis.

Bringing the Hospital to the Practitioner

hospital patients, operating rooms, laboratories, necropsy table, amphitheatres, clinicians, pathologists, and discussions. Every week the subscriber receives three Records, each consisting of two parts: (1) the complete *clinical history* on one sheet; (2) on a separate sheet the *discussion*. Medical cases are discussed by Dr. R. C. Cabot.

Surgical Cases Discussed by Dr. Hugh Cabot

The *diagnosis made in the wards* is given, then *Dr. Cabot's diagnosis;* finally the *necropsy findings*. By making your own best diagnosis from the first sheet and then checking it up by the data in the second, you work out an absorbing problem and share much of the stimulus of the original exercise at the hospital. Groups of physicians and surgeons, both in and out of war service, have reported that they found in the Records a basis for their most stimulating and profitable discussions. Published by

The Massachusetts General Hospital
Boston Massachusetts

Subscription $5.00 per annum in advance. Sample copies and rates to medical societies sent on application.

The 1919 Practical Medicine Series

of Year Books

Published at monthly intervals beginning in May.

Vol. I now ready

$2.50 $2.50 $1.75 $1.50 $1.75 $1.75 $1.50 $1.50

EVERY PAGE of every volume is direct and to the point, yet covering with the utmost completeness what one wishes to know in the wide range of recent medicine and surgery.

The subscription price for the eight volumes is $10.00. Individual volumes are sold at the prices shown under the cut. *Carriage charges prepaid.*

THE YEAR BOOK PUBLISHERS

304 S. Dearborn St., Chicago

NOW READY

Third Edition *Thoroughly Revised*

With New Illustrations

Munro Kerr's

Operative Midwifery

A Guide to the Difficulties and Complications of Midwifery Practice

Royal Octavo. Pp. xvi. + 725. With 308 Illustrations. Price in Britain 25/- Net.

By J. M. MUNRO KERR, M.D., C.M., Glasg., Fellow of the Royal Faculty of Physicians and Surgeons, Glasgow; Hon. Fellow, American Gynæcological Society; Professor of Obstetrics and Gynæcology, Glasgow University (Muirhead Chair); Obstetric Physician, Glasgow Maternity Hospital; Gynæcologist, Royal Infirmary; Past President of the Glasgow Obstetrical and Gynæcological Society.

"We regard this book as the most considerable addition to English obstetrical literature that has been made for a long time."—*British Medical Journal.*

New York - Wm. Wood & Co.
Fifth Avenue

London - Bailliere, Tindall & Cox
8 Henrietta Street, W. C. 2

50% BETTER

Prevention Defense Indemnity

1 All claims or suits for alleged civil malpractice, error or mistake, for which our contract holder,

2 Or his estate is sued, whether the act or omission was his own.

3 Or that of any other person (not necessarily an assistant or agent).

4 All such claims arising in suits involving the collection of professional fees.

5 All claims arising in autopsies, inquests and in the prescribing and handling of drugs and medicines.

6 Defense through the court of last resort and until all legal remedies are exhausted.

7 Without limit as to amount expended.

8 You have a voice in the selection of local counsel.

9 *If we lose, we pay to amount specified, in addition to the unlimited defense.*

10 The only contract containing all the above features and which is protection per se. *A sample upon request.*

The MEDICAL PROTECTIVE CO.
***of* Fort Wayne, Indiana**

Professional Protection Exclusively

In Two Volumes, with many Illustrations and Plates. Large 8vo. Cloth Gilt, Bevelled Boards, $10.00 net.

SURGICAL CONTRIBUTIONS from 1881-1916

By RUTHERFORD MORISON, M.B., F.R.C.S. (Edin. and Eng.)

With a PREFACE and FULL SUBJECT INDEX, Contributed by W. D'OYLEY GRANGE, M.D., C.M.

VOL. I.—GENERAL SURGERY, $3.50 net. **VOL. II.—ABDOMINAL SURGERY, $6.50 net.**

"The Author has brought his views up to date.....We are surprised with the vast amount of original work.....The author's teaching aims primarily at the attainment of the thorough grasp of the principles of surgery.....these are put in a helpful way..... The book will be widely read and used as a book of reference."—BRIT. MED. JOURN.

"There are few who will not profit from an examination of these volumes; on nearly every page are to be discovered points of utmost importance."—LANCET.

"These volumes show that their author was not only a very capable surgeon, but a clear thinker and a lucid writer."—MED. JOURN. OF AUSTRALIA.

New York: WM. WOOD & CO. **Bristol, Eng.: JOHN WRIGHT & SONS, Ltd.**

REBMAN COMPANY

141 W. 36th St.
NEW YORK

NOTED BOOKS

ANATOMY

BARDELEBEN and HAECKEL—Applied Anatomy—One volume—204 colored wood cuts, with explanatory text.....$8.00

MORTON — The Abdomen Proper — Colored plates—Analytical—Synthetical—(Constructive—Destructive)—With explanatory text—One volume.....$6.00

TOLDT—Atlas of Anatomy for Students and General Practitioners.—*Revised Edition.*—1505 illustrations.

VOLUME I

A.—The Regions of the Human Body (Figures 1 to 5).
B.—Osteology (Figures 6 to 377). With Index.
C.—Arthrology (Figures 378 to 498). With Index.....$6.00

VOLUME II

D.—Myology, with a Supplement on the Anatomy of Hernia (Figures 499 to 640). With Index. E.—Splanchnology (Figures 641 to 932). With Index.....$7.00

VOLUME III

F.—Angeiology (Figures 933 to 1123). With Index. G.—Neurology. H.—The Organs of the Senses (Figures 1124 to 1505). With Index.....$11.00

Three Volumes complete, $24.00

BLOOD

EHRLICH — Anemia — Many colored illustrations..... $4.00

STERN—Bloodletting, Theory and Practice $2.50

SCHLEIP—Hematological Atlas..... $6.00

DIAGNOSIS

ABRAMS—Diagnostic Therapeutics—Illus.$6.00

ADAM — Ophthalmoscopic Diagnosis—18 illustrations in the text. 86 colored figures... $7.00

BASS and JOHNS — Practical Clinical Laboratory Diagnosis—117 textual figures and 19 plates in colors..... $6.50

CORNWALL — A Clinical Treatise on Diseases of the Heart—Diagnosis and Treatment.. $1.50

BING—Regional Diagnosis..... $3.00

FOSTER — Diagnosis from Ocular Symptoms..... $6.00

HART — The Diagnosis and Treatment of Abnormalities of the Myocardiac Function—248 illustrations..... $4.50

SCHMIDT—Malignant Tumors..... $4.00

EAR

BRAUN and FRIESNER—The Labyrinth—50 textual figures. 34 half-tones on 32 plates $4.50

KOPETSKY — Surgery of the Ear—63 half-tones and line drawings, 8 charts and 4 colored plates..... $4.00

RUTTIN—The Labyrinth..... $2.50

EYE

ADAM — Ophthalmoscopic Diagnosis—18 illustrations in the text. 86 colored figures... $7.00

FOSTER—Diagnosis from Ocular Symptoms $6.00

GREEFF — External Diseases of the Eye—84 colored illustrations. (*New Edition*).... $7.00

HIRSCHBERG — The Treatment of Shortsight—12 illustrations..... $1.50

ROEMER — A Text-Book of Ophthalmology in the Form of Clinical Lectures—186 black and white illustrations in the text and 58 figures in colors. 896 pages. (*New Edition*) .. $6.00

SCOTT — Refraction and Visual Acuity—18 illustrations, 190 pages..... $2.00

FOOD

CARRINGTON — Vitality, Fasting, and Nutrition—Illustrated..... $5.00

COMBE — Intestinal Auto-Intoxication... $4.00

GOULEY—Dining and its Amenities..... $2.50

GOURAUD—What Shall I Eat?..... $2.00

STERN—Fasting and Undernutrition in the Treatment of Diabetes..... $2.00

WEGELE —Therapeutics of the Gastro-Intestinal Tract..... $3.50

HISTOLOGY

KRAUSE—(Rudolf) Normal Histology, Including Microscopical Anatomy—502 pages, 30 figures in the text, 208 magnificent illustrations in many colors on 98 plates. Part I.....75c
Part II..... $5.50

KRAUSE (Rudolf)—Textbook of Histology. Illustrated..... $3.00

Archives of Diagnosis.
Quarterly.....$2.00 per annum
Foreign, $2.50 Single copies, 75 cents

Archives of Radiology and Electro-Therapy
Monthly.....$7.50 per annum
Single copies, 75 cents including postage.

Our books are printed from plates made in this country from type set in the United States and* PAID FOR SOLELY BY AMERICAN CAPITAL. *There are no foreign interests represented therein.

OXFORD
MEDICAL PUBLICATIONS

THE 220 titles listed in the Oxford Catalogue—the largest medical offering of any publisher—enjoy peculiar advantages in their scholastic and traditionary associations. Oxford books are published under the direction of the Delegates of the Press—the Heads of Colleges of Oxford University with Sir William Osler acting as the Medical Member. The traditionary associations are equally as favorable to these publications. Oxford books are collected in Great Museums, Galleries and Guild Halls for the connecting links in Ars Typographica. Centuries of artists and designers leave models and atmosphere to Oxford Productions.

ALTHOUGH this Press is under academic supervision it competes with the great commercial plants of the world as one of the largest printing establishments, making their book materials in their own foundries, mills, ink and roller factories. The press rooms are equipped with 270 presses, 250 of these are power machines, therefore in addition to these associations the materials for book-making are under Oxford control.

APPLY for circulars of the Oxford Loose-Leaf Medicine and Surgery. The demand is such that the new printing of the Surgery gives a total of over one half million dollars worth of this work printed before its advance sale is delivered.

OXFORD UNIVERSITY PRESS *American Branch*

35 WEST THIRTY-SECOND STREET

NEW YORK CITY

A New Book on an Important Subject

THE PERITONEUM

Its structure, and Function in Relation to the Principles of Abdominal Surgery—Its Diseases and their Treatment.

In two volumes of over 900 pages, 6 x 9, with 230 original engravings made from drawings by Tom Jones and Ivan F. Summers, and 4 color plates.

Price, silk cloth binding, per set, $10.00

By ARTHUR E. HERTZLER, A.M., M.D., F.A.C.S.

Surgeon to Halstead Hospital, Halstead, Kansas; Associate Professor of Surgery, University of Kansas School of Medicine; Formerly Professor of Pathology, Experimental Surgery, and Gynecology, University Medical College, Kansas City, Mo.

Hertzler's New Work will be Welcomed by Surgeons and Physicians

THE surgeon and internist are alike vitally interested in obtaining all the information available on the Peritoneum. There has been a dearth of literature on this subject in the past, and Doctor Hertzler's monumental work, embodying years of research into the embryology, histology, and pathology of the peritoneum, with the clinical manifestations and the treatment of diseases affecting it, will be especially welcomed at this time. The book represents the work done during an active practise of 25 years and consequently partakes of the practical viewpoint of the subject.

CONTENTS VOL. I

Physiology of the Peritoneum — Histology of the Peritoneum — Development of the Peritoneum — Gross Anatomy of the Peritoneum — Wound Healing (the Formation of Fibrous Tissue) — Nature and Genesis of Peritoneal Adhesions—The Prevention of Adhesions —Changes in the Circulation—Inflammatory Reaction of the Peritoneum.

CONTENTS VOL. II

Classification of Peritonitis — Etiology of Peritonitis — Pathogenensis of Peritonitis — General Symptomatology of Peritonitis — Diagnosis of Peritonitis — Prognosis of Peritonitis — Cause of Death in Peritonitis — Treatment of Acute General Peritonitis — Operations on the Peritoneum — Appendicitis — Cholecystitic Peritonitis — Gonococcic Peritonitis — Pneumococcic Peritonitis — Puerperal Peritonitis — Traumatic Peritonitis Without Rupture—Fetal Peritonitis — Tuberculosis of the Peritoneum — Thrombosis and Embolism of the Mesenteric Vessels — Diseases and Injuries of the Great Omentum — Tumors of the Peritoneum.

☛ You should not deny yourself the benefit to be derived from a study o this epoch-making work. Make up your mind now to order a set. No use writing, just sign the attached coupon and mail, but do it NOW, before you lay aside this journal.

The C. V. Mosby Co., Publishers

801-809 Metropolitan Bldg., St. Louis, U. S. A.

Our new 88-page illustrated catalog is now ready—send for a copy today

Canadian Agency: McAinsh & Co., Ltd., Toronto, Canada
Great Britain House: Hirshfield Bros., Ltd., London

TEAR OFF AND MAIL TODAY

Surg. G.&O.

THE C.V. MOSBY COMPANY
St. Louis, Mo.

Send me *Hertzler* (2 Vols.) *"The Peritoneum"* for which I enclose $10.00, or you may charge to my account.

Name.....

Street.....

Town.....State.....

The Medical Annual, 1919

A Year Book of Treatment, and Practitioner's Index:

Being a Review of the World's Progress in Medicine and Surgery. Arranged in Alphabetical order for easy consultation.

CONTRIBUTORS:

E. WYLLYS ANDREWS, A.M., M.D., Chicago
JOSEPH BLOMFIELD, B.A., M.D.
FRANCIS J. CHARTERIS, M.D., B.Ch.
JOHN D. COMRIE, M.D., F.R.C.P.
CAREY F. COOMBS, M.D., F.R.C.P.
W. H. DOLAMORE, M.R.C.S., L.D.S.R.C.S.
W. E. FOTHERGILL, M.A., M.D.
JOHN S. FRASER, M.B., F.R.C.S.
HERBERT FRENCH, M.A., M.D.
EDWARD W. GOODALL, M.D., B.S.
MAJOR E. W. HEY GROVES, R.A.M.C. (T.)
C. THURSTAN HOLLAND, M.R.C.S., L.R.C.P.
J. RAMSAY HUNT, M.D., New York
ROBERT HUTCHISON, M.D., F.R.C.P.
FREDERICK LANGMEAD, M.D., F.R.C.P.
ARTHUR LATHAM, M.A., M.D., F.R.C.P.
E. G. GRAHAM LITTLE, M.D., F.R.C.P.
C. F. MARSHALL, M.D., F.R.C.S.
R. FOSTER MOORE, M.A., F.R.C.S.
CAPT. MAURICE NICOLL, R.A.M.C.
HERBERT S. PENDLEBURY, M.A., F.R.C.S.
BEDFORD PIERCE, M.D., F.R.C.P.
JOSEPH PRIESTLEY, B.A., M.D., D.P.H.
SIR LEONARD ROGERS, LT.-COL. I.M.S., M.D., F.R.C.S.
J. D. ROLLESTON, M.A., M.D.
A. RENDLE SHORT, M.D., F.R.C.S.
J. W. THOMSON WALKER, F.R.C.S.
W. I. DE COURCY WHEELER, F.R.C.S.
P. WATSON WILLIAMS, M.D.
S. A. KINNIER WILSON, M.A., M.D., F.R.C.P.

Associate Editors: (*Medicine*) CAREY F. COOMBS, M.D., F.R.C.P.; (*Surgery*) A. RENDLE SHORT, M.D., F.R.C.S

Thirty-Seventh Year. 700 pages, Fully Illustrated in Colours and Black and White. Bound in muslin in conformity with previous issues. Price $5.00 net. A few Copies left of 1915, 1916, 1918 which we will sell at $3.00 net per copy if ordered with 1919.

THE new volume of the *Medical Annual* will be of unusual value and interest. unavoidably coloured by the War, yet the experiences thus gained have produced advances in medical science and practice which, under ordinary conditions, would have required many years to reach: these are of great value to the practitioner and to his patients.

This progress will be found chronicled in the *Annual*, and adapted in every way possible to the requirements of the Civil as well as the Military practitioner.

It is certain that no doctor can escape from the War, however much he may desire to. In the immediate future he will be confronted more and more often by after-war problems in the treatment of the broken, wounded, nerve-shattered men now being discharged from the military hospitals in ever-increasing numbers to be dealt with by the Civil practitioner. The *Medical Annual*, gives unrivalled assistance in this direction.

Explaining the increase in the price of the 1919 issue, we quote the English Publishers as follows:

"Costs of production have increased by leaps since the outbreak of the War. Printed literature has doubled in price. For four years the price of the *Annual* has remained unchanged: we regret that this is possible no longer, and we are confident our friends will understand it when we state that the simple printing of the 1918 volume cost £800 more than previous years, and that the edition for 1919 will show a greater increase. We shall gladly reduce the price again when conditions permit."

There will be a corresponding reduction in the price of the American edition.

WILLIAM WOOD & COMPANY, 51 Fifth Ave., New York

The Sum Total of Today's Knowledge on Tuberculosis and Urology

UROLOGY—PEDERSEN

This book represents many years' experience in urological work in New York City. The author's able exposition of modern methods of treatment is the most striking feature of the work.

Three hundred and forty-one pages are devoted to Acute and Chronic Urethritis and Complications and Sequels covering Etiology, Bacteriology, Pathology, Symptomatology, Treatment and Diagnosis in general. Not only is treatment by drugs and chemical methods fully discussed, including a number of prescriptions, technic of irrigation, instillation, etc., but also physical treatment—hydrotherapy, heliotherapy, electrotherapy, roentgen rays, etc. Far more space and detail is given to Complications and after treatment then can be found in most works. *Seventy pages* are given to Treatment of Stricture and its Complications, *fifty-five pages* to General Principles of Diagnosis covering Physical Examination; Laboratory Examination, including multiple glass tests; Urinalysis, Serum Diagnosis, Complement Fixation, etc. ; Diagnosis of Acute and Chronic Complications, etc.

Then General Principles of Treatment are taken up, including Preventive Treatment, Abortive Treatment, Palliative Treatment, Curative Treatment, Management, Physical Measures, Technic and Indications, Medicinal Measures, Surgical Measures, Serum and Vaccine Therapy, etc.

Gonococcal Infection in the Female and Complications and Sequels are covered in two separate chapters. *Sixty-six pages* are given to Urethroscopy and *fifty-eight pages* to Cystoscopy, covering thoroughly indications, equipment and technic. Separate chapters are devoted to the Bladder—Ureters and Renal Functional Tests, including Hematology, etc.—Acute and Chronic Suppurative Inflammations of the Renal Pelvis and Parenchyma—and Diseases of the Prostrate.

In all diseases the standard of cure is stated in separate paragraphs.

By Victor C. Pedersen, M.D., F.A.C.S., Major, M.C., Visiting Urologist to St. Mark's Hospital, etc., etc. Octavo, 991 pages, with 362 engravings and 13 colored plates. Cloth, $7.00 net.

PULMONARY TUBERCULOSIS—FISHBERG (*New 2nd Edition*)

The first edition of this work was used by all governmental hospitals and by the Army. In fact, the problem of tuberculosis in soldiers was handled along the lines laid down in this book.

Nearly every chapter has been revised and several have been rewritten. New chapters on tuberculosis of the pleura, and on the differential diagnosis of pulmonary tuberculosis have been added. Additional plates have been inserted, illustrating the pathology of pulmonary tuberculosis, all drawn from autopsies of cases under the author's care. Many of the radiographic plates have been replaced and several new ones added so that these illustrations represent practically *an atlas of radiography of pulmonary tuberculosis*. The author has had an experience of twenty years with tuberculosis problems in New York and he supplies full and clear information on etiology, diagnosis, prognosis and treatment. The general practitioner is called upon to treat the great majority of cases of tuberculosis at home. In this work particular stress is laid upon the home treatment and care. It gives you the methods of treatment best adapted to the individual case and the conditions under which that treatment must be given to secure the best results. The book is thoroughly up-to-date throughout and stands out as an authoritative and practical exposition of the subject.

By Maurice Fishberg M.D., Clinical Professor of Tuberculosis, University and Bellevue Hospital Medical College; Attending Physician, Montefiore Home and Hospital for Chronic Diseases, New York. Octavo, 744 pages, with 100 engravings and 25 plates. Cloth, $6.50 net.

Tear this page out. Check book or books wanted—sign your name and we'll charge your account

PHILADELPHIA
706-10 Sansom St.

LEA & FEBIGER

NEW YORK
2 West 45th St.

Lukens Sterile Catgut

TRADE (Bartlett Process) MARK

Make the Test Yourself

Compare It Point for Point With Any Other Catgut

We Will Send the Samples

It is sterile, antiseptic, strong, supple, elastic; free from excess oil; will not untwist in using and is more than usually resistant to absorption.

Sizes 00-4 Plain *Sizes 00-4 Tanned*

C. DE WITT LUKENS CO.
4908 Laclede Avenue
ST. LOUIS MO., U. S. A

FOR SALE BY ALL DEALERS.

The thought behind the tube—
"the patient on the table"
Van Horn
Not "good enough"-but the best from every standpoint-alone assures that degree of "Catgut Safety" demanded when the patient on the table is "ONE OF MY OWN FAMILY."
Only on this peculiarly personal basis is
"Van Horn" Catgut
supplied to the profession.
VAN HORN and SAWTELL DEPARTMENT
NEW BRUNSWICK, N.J.

RADIUM RENTAL SERVICE

By The Physicians' Radium Association of Chicago

(Incorporated under the laws of Illinois, "Not for Profit")

BOARD OF DIRECTORS

William L. Baum, M. D.
N. Sproat Heaney, M. D.
Frederick Menge, M. D.
Thomas J. Watkins, M. D.
Albert Woelfel, M. D.

MANAGING DIRECTOR

Albert Woelfel, M. D.

ESTABLISHED to make Radium more available in the *Middle States* and to furnish advice based on extensive observations, about its approved therapeutic uses. Maintains the equipment, large and complete in its makeup, that is needed to meet the special requirements of any case in which radium therapy is indicated. Radium loaned to any responsible physician. Moderate rental fees charged.

For Full Particulars Address

THE PHYSICIANS' RADIUM ASSOCIATION

1104 Tower Bldg., 6 N. Michigan Ave., Chicago **Telephones, Randolph 6897-6898**

Some New Light on Fumigation

We ask to hear from doctors who desire new light on gaseous disinfection.

Our latest pamphlet on the subject is written by Dr. J. E. Kelley, ex-captain in the Medical Corps of the United States Army. It deals largely with the use of aerial fumigation by the Medical and Sanitary Corps of the Army, especially in combating Influenza.

The facts are interesting. More than five million men were quartered for varying lengths of time in our Army Camps and Cantonments here and abroad. Never before in an American army has the death rate from disease been so low. Never before has the number dead from disease been less than the number killed in action or dead from wounds.

The use of Formaldehyde gas in attaining this result is dealt with in this pamphlet. Ask us for it and for other compiled information.

Formaldehyde— The Best Gaseous Germicide

There can be no question that Formaldehyde is the best gas germicide. It is non-poisonous. It does not injure fabrics, colors, metals, furnishings, or anything save plants. And plants are easily removed.

It is efficient. That has been proved by many scientific tests. It has also been proved that it penetrates sealed envelopes, destroying germs inside.

It is easily applied. With a B & B Formaldehyde Fumigator one simply lights the wick. The Formaldehyde gas is protected from the flame, which would make it ineffective.

The Proper Amount

Fumigation after contagious diseases cannot be too effective. The only economy lies in maximum security. The amount of solidified Formaldehyde commonly employed has been one ounce per thousand cubic feet of air space. That, in our opinion, is too little. And it is very evident that using too little is responsible for any doubts about the efficiency of Formaldehyde fumigation.

The United States Public Health and Marine Hospital Service recommends not less than two ounces for each thousand cubic feet—twice the common standard. That is the basis we have adopted in all sizes of B & B Formaldehyde Fumigators. Any comparison of prices should consider that difference.

Sulphur Dioxide— The Best Insecticide

Sulphur is best to kill insects and rodents. But it must be in a form to be quickly and completely ignited. This is accomplished in the B & B Sulphur Fumigators.

The U. S. Public Health Bulletin No. 42 states that one pound of sulphur burned for each 1000 cubic feet kills flies and mosquitoes within two hours. Two pounds should kill rats within four hours, and five pounds should destroy bed bugs, roaches, lice, etc., within six hours.

For many years we have made a study of gaseous fumigation. We have conducted many experiments and had many conducted for us. Our standards are based on these exacting scientific tests. Our methods of accomplishing this fumigation are right and convenient.

When you use or recommend a B & B Fumigator you are getting the best that is made. In B & B Formaldehyde Fumigators you are getting twice the ordinary efficiency.

Write us for authoritative pamphlets on this subject.

BAUER & BLACK
2500 S. Dearborn St., Chicago

BAUER & BLACK, LIMITED
96 Spadina Ave., Toronto, Canada

B&B Formaldehyde Fumigators

Made in four sizes — ½ ounce, 1 ounce, 2 ounces and 6 ounces. According to our standards two ounces are required for each 1000 cubic feet of air space. That is, for a room 10 x 12 x 8 feet.

Seal the cracks around the doors and windows. Open drawers and closets. In a bedroom remove the sheets and blankets and scatter them about. Remove nothing but live plants. Nothing else is injured by Formaldehyde.

Moisten the air of the room by boiling water in the room, by placing shallow pans of water on the radiators or by sprinkling the floor.

Place the B & B Fumigator in a saucer partly filled with water. Light the wick, close the door and let the gas remain there for four hours.

The room should be warm—70 degrees or above.

In comparing cost of B & B Formaldehyde Fumigators with others remember our double strength. There is no economy without efficiency.

B&B Sulphur Fumigators

To Kill Insects and Rodents

One Pound Each — Four Wicks

BAUER & BLACK Chicago, New York, Toronto

Manufacturers of Sterile Surgical Dressings and Allied Products

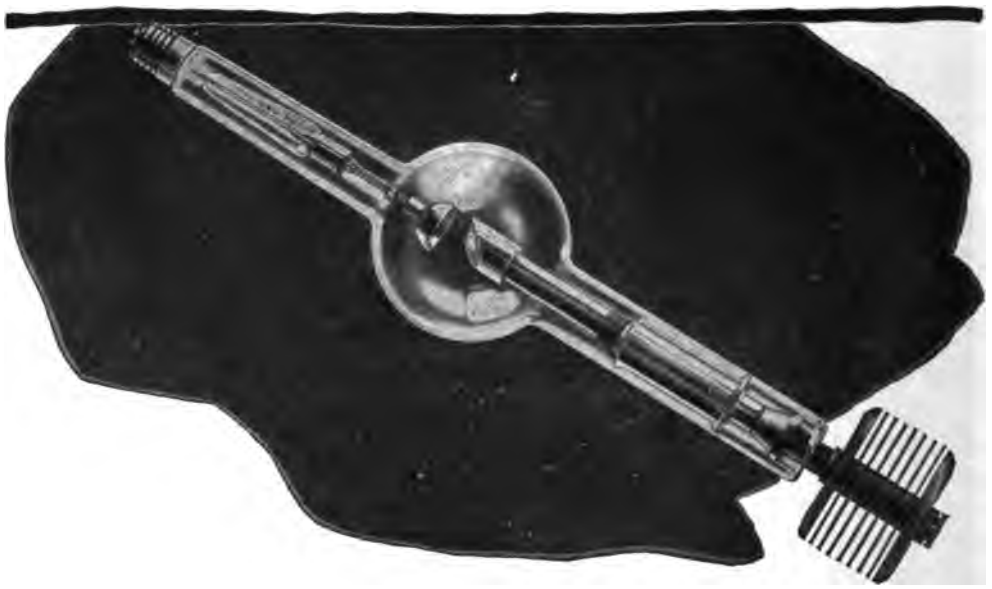

A New Radiator Type Coolidge X-Ray Tube

30 Milliamperes Capacity for Diagnostic Work

The capacity of this tube is 30 milliamperes, at a voltage corresponding to a 5-in. parallel spark between points.

It is self-rectifying and can be operated directly across the terminals of a high tension transformer and will operate equally well on interruptless machines or induction coils.

The physical characteristics of this tube are identical with those of the Radiator Type tube of 10 milliamperes capacity with the exception of a slightly larger focus spot.

This tube is now available. For details write to the address below.

General Electric Company

General Office Schenectady, N.Y.

35-B-13

For Gastro-Intestinal Diagnoses

Eastman Dupli-Tized X-Ray Films

THIS negative was made in ¼ second with 40 M. A., 6-inch gap at 24 inches with Coolidge Tube (medium focus), using two intensifying screens. You can shorten the exposure and improve the result by using Dupli-Tized Film with one or two intensifying screens.

Ask your dealer for Eastman Dupli-Tized X-Ray Films.

EASTMAN KODAK CO., ROCHESTER, N. Y.

"That's Why I Bought A "Victor""

A physician contemplated the installation of quite an elaborate x-ray equipment. Before placing his order, he made a tour of inspection of the factories of several of the x-ray manufacturers.

In placing his order with the Victor Electric Corporation for his entire equipment, he made the following comment:

"I frankly admit that I do not know much more about the details of the numerous technical problems, that are pertinent with x-ray apparatus, than I did before I started to investigate.

"I am frank to confess, however, that in the Victor factory, right amongst the men 'in the overalls' I found a spirit of loyalty and co-operation that was a pleasant inspiration — a 'something' which convinced me right then and there that I would not be disappointed if I bought a Victor equipment.

"The mechanics appeared to be skilled, conscientious, contented, and really proud of their share in the work. Everyone in the organization with whom I talked was not only thoroughly posted on his own work, but also was generally aquainted with the interweaving of the various tasks which, co-ordinating with his own, made Victor Service a tangible thing.

"That's why I bought a 'Victor'."

VICTOR ELECTRIC CORPORATION

Manufacturers of Roentgen and Electro-Medical Apparatus

CHICAGO
236 S. Robey St.

CAMBRIDGE, MASS.
66 Broadway

NEW YORK
131 E. 23rd St.

PLUS SPEED—

Diagnostic X-Ray Plates assure the Roentgenologist a clear cut contrast, keen delineation and a wealth of detail—*plus speed.*

In stomach, obstetric and gastro-intestinal cases where rapidity of action is most essential, the superior speed of the Diagnostic Plate is invaluable.

Unsurpassed in their qualities of contrast and density, they possess a longer scale of gradation and a greater capacity for distinct differentiation.

Diagnostic Plates are made from new glass only—fix out absolutely clear and stainless. Equally good for direct and screen work.

AMERICAN PHOTO CHEMICAL COMPANY
ROCHESTER NEW YORK

For Sale by Leading Supply Houses

DIAGNOSTIC

Campbell

EXPERIMENT AND UNCERTAIN RESULTS ARE ELIMINATED WHEN YOU INSTALL

Campbell Roentgen Apparatus

Sure-X Interrupterless Transformer
Tube Tilt Table
Stereoscopic Tube Stand
High Frequency Coils
Electro-Therapeutic
and Roentgen Accessories

Send for Literature

CAMPBELL ELECTRIC CORPORATION
LYNN, MASSACHUSETTS

THE

RADIUM INSTITUTE

1604 Mallers Bldg., 59 E. Madison St.
Cor. Wabash Ave., Telephone Randolph 5794
C H I C A G O

DR. FRANK E. SIMPSON

COUNCIL

DR. F. A. BESLEY — DR. E. C. DUDLEY
DR. A. R. EDWARDS — DR. O. T. FREER
DR. M. HERZOG — DR. L. E. SCHMIDT
DR. G. F. SUKER

TREATMENT of Malignant and Benign Growths with Radium; Postoperative Prophylactic Radiations following the Surgical Treatment of Cancer.

Radium is indicated in inoperable malignant conditions. By its use an inoperable case may become operable.

We desire to confer and co-operate with surgeons, assuring them adequate amounts of. Radium to meet the requirements of patients referred to us.

THE MEYER MULTOSCOPE

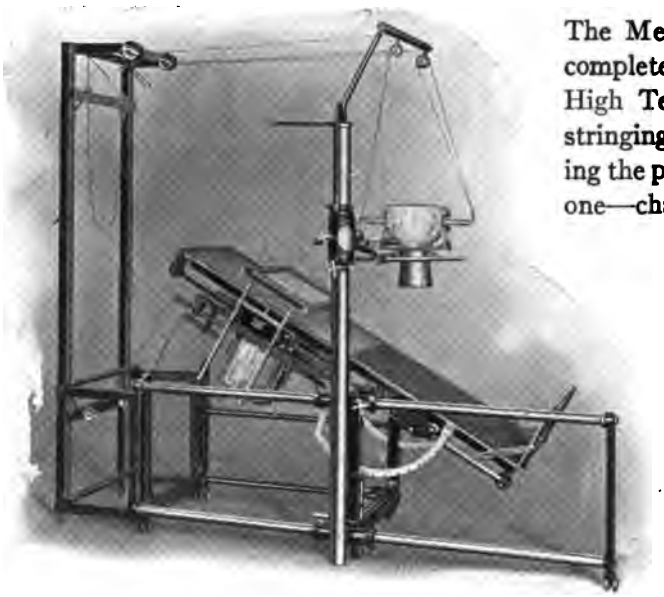

The Meyer Multoscope is furnished complete with Self Contained Aerial and High Tension Switch, eliminating the stringing of wires in a room and making the placing of the apparatus a flexible one—changeable as desired. No current wasted in excess wiring. The last word in classiness.

It covers every phase of Modern X-Ray Work.

Send for the
MULTOSCOPE BULLETIN

Price complete $1100.00

THE WM. MEYER COMPANY

817 WASHINGTON BLVD. CHICAGO, ILL.

ANNOUNCEMENT

AN EPOCH-MAKING ADVANCE IN THE ROENTGEN ART

The Wappler Electric Company announces the production of a new Roentgen Ray Tube known as

NITROKEN

This new gas tube remains stable during heavy prolonged exposures and cannot be over-reduced

Full technical and commercial information will be sent upon request

WAPPLER ELECTRIC COMPANY, Inc.
173 E. 87th Street, NEW YORK. U. S. A.

An Unparalleled Success

Camp Physiological Belts

have been established and proven a positive essential as an aid in the treatment of abdominal prolapse and in post-operative conditions. This System of rigid, non-elastic supports has been adopted by eminent specialists in surgery and gynecology throughout the world.

In addition to the specific types already tested and approved by the profession, we present herewith still another form, one of great interest to all obstetricians.

The accompanying photographic illustration shows a Maternity Belt; the graphic feature of which is an even, well-distributed support, without constriction.

The "block-and-tackle" system of lacing applied to Camp Belts, together with the extra lacing over the abdominal wall, give unusual flexibility of adjustment and gradual adaptability in increase of size.

This Maternity Belt may be worn with perfect comfort during the entire period of pregnancy.

New York, 373 Fifth Ave.
San Francisco, 330 Sutter St.
Buffalo, 70 W. Chippewa St.
St. Paul, 422 Peoples Bank Bldg.
Portland, Ore., Woodlark Bldg.
Rochester, 1141 Granite Bldg.
Columbus, 104 N. High St.
Utica, 314 Kempf Bldg.
Houston, 203 Foster Bldg.

Goodwin Corset Shops

Boston, 637 Boylston St.
Los Angeles, 220 W. 5th St.
Davenport, 209 Main St.
Cincinnati, 433 Race St.

Philadelpia, 1120 Walnut St.
St. Louis, 513 Olive St.
Omaha, 1704 Douglas St.
Minneapolis, 816 Nicollet Ave.

Chicago, 57 E. Madison St.
Pittsburgh, 2006 Jenkins Arcade Bldg.
Detroit, 313 David Whitney Bldg.
Kansas City, 413 Altman Bldg.
Jamestown, 514 Prendergast Ave.
Toledo, 219 Superior St.
Spokane, 827 Sprague Ave.
Indianapolis, 55 Monument Place
Denver, 1764 Broadway

Address all correspondence to

S. H. CAMP & COMPANY, Manufacturers, Jackson, Michigan

HAVE YOUR

Colostomy Patients

wear a comfortable and effective appliance which lies flat and does not show through the clothing.

Devised by DR. J. COLES BRICK

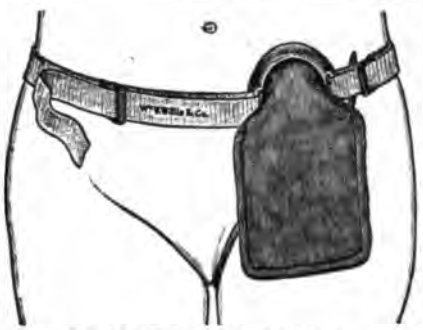

Brick's Colostomy Appliance

Price $5.00, including two rubber bags and an adjustable strap to fit any patient. Discount to physicians.

WM. V. WILLIS & CO.

Surgical Instruments

134 So. 11th St. Philadelphia, Pa.

Storm Binder and Abdominal Supporter

(Patented)

Adapted to use of men, women and children, for any purpose for which an abdominal supporter is needed. High and Low Operations, Ptosis, Pregnancy, Obesity, Hernia, Relaxed Sacro-Iliac Articulations, Floating Kidney, etc.

Folder on request—with prices, materials and physicians' testimonials

Mail Orders filled at Philadelphia—within 24 hours

Katherine L. Storm, M. D.

1541 Diamond Street, Philadelphia



Whole-Grain Bubbles

Every Food Cell Exploded

Puffed Grains are scientific foods invented by Prof. A. P. Anderson. Sealed in guns the grains are given an hour of fearful heat. The trifle of moisture inside each food cell is thus changed to steam.

When the guns are shot that steam explodes. Every food cell in the whole grain is thus blasted. And the grains are puffed to bubbles, eight times normal size.

The object of the process is easy, complete digestion. No other form of cooking so breaks up the granules. But the result is also food confections—thin, crisp, flavory morsels with a taste like toasted nuts.

You will recognize, we think, that such foods are ideal for children. And in some conditions they will serve your purpose better than anything else.

The Quaker Oats Company

Sole Makers

Puffed Wheat
Puffed Rice
Corn Puffs

All Steam-Exploded Grains

(3069)

THE GROWTH OF BACTERIA

Producing Fermentation and Putrefaction in the Intestines May be Inhibited by Bacilli Bulgarici

BULGARA TABLETS, H. W. & D.

Present Active Viable Bacilli Bulgarici

A Convenient Form for Administration **A Stable Form for Marketing**

"Drying B. Bulgaricus. The great demand for cultures of this group to use in fermenting milk or for direct consumption for therapeutic purposes has given special interest to attempts to produce an active powder by the freezing method. Our results have shown that it is possible to make a dry culture of B. Bulgaricus containing over 1,000,000,000 cells per gram." — Dr. L. A. Rogers, Chief of the Research Division of Bacteriology, Department of Agriculture.

Literature and Material for Investigation Upon Request.

HYNSON, WESTCOTT & DUNNING - Baltimore

Making Real Pharmaceuticals

is not all cold, mathematical, pharmaceutical Science; there's no little Art in it.

And in our laboratories there's still something more—quite as important and far-reaching.

It's Conscientiousness!

It's the ever-present thought in every mind:

> "I am going to make this so well, so carefully, that if my own life were in the balance and this very medicine were prescribed, I would have the keen satisfaction of knowing that it was made just right."

And that's what you get when you use the products of

SINCE 1860 *Sharp & Dohme*
CAREFUL CONSCIENTIOUS CHEMISTS

Salvarsan
(Arsphenamine-Metz)
AND
Neosalvarsan
(Neoarsphenamine-Metz)

WE have greatly improved the methods of manufacture of these standard remedial agents. Official tests show they possess a relative fixity of arsenic content entirely in keeping with the original formulas.

We have no hesitation in asserting that Salvarsan and Neosalvarsan are now THE arsenical preparations *par excellence.*

With this great improvement in quality we have reduced the prices to such an extent that these valuable drugs are now available for much more extended use in private practice.

SALVARSAN
(Arsphenamine-Metz)

0.1 gram	$ .60	per ampule
0.2 "	.75	" "
0.3 "	.85	" "
0.4 "	1.00	" "
0.5 "	1.25	" "
0.6 "	1.50	" "
1.0 "	2.00	" "
2.0 "	3.75	" "
3.0 "	5.50	" "

In Cartons containing 10, 25 or 50 Ampules
(May be assorted sizes)
10 per cent discount

NEOSALVARSAN
(Neoarsphenamine-Metz)

Dosage I, 0.15 gram	$ .75	per ampule
" II, 0.3 "	1.00	" "
" III, 0.45 "	1.25	" "
" IV, 0.6 "	1.50	" "
" V, 0.75 "	1.75	" "
" VI, 0.9 "	2.00	" "
" X, 1.5 "	3.00	" "
" XX, 3.0 "	5.50	" "
" XXX, 4.5 "	8.00	" "

In Cartons containing 10, 25 or 50 Ampules
(May be assorted sizes)
10 per cent discount

NOVOCAIN is again obtainable in any required amounts, both in powder form and tablets.

If your druggist cannot supply you with Salvarsan, Neosalvarsan or Novocain, forward order direct to us.

H. A. METZ LABORATORIES, Inc.
122 Hudson Street **NEW YORK**

New York Post-Graduate

Medical School and Hospital

Courses arranged for the general practitioner in all branches of medicine. Separate courses on every subject and Special Practical Courses, where individual instruction is given in the following subjects:

Anaesthesia; Colon and Rectal Diseases; Complete Eye Seminar, embracing seven Special Courses; Ear Operations (Cadaver); Nose and Throat Operations on the Cadaver and in the Operating Rooms; Bronchoscopy; Nose and Throat Pathology; Abdominal Diagnosis; Physical Diagnosis; Diagnosis and Treatment of Constitutional Diseases of the Adult; Dietetic and Metabolic Problems; Infectious Diseases; Neurology; Stomach Diseases; Infant Feeding and Diagnosis; Intubation and Lumbar Puncture; Practical Pediatrics; Cystoscopy—Male and Female; Diagnosis and Office Treatment of Gynecological Cases; Gynecological Operations on the Cadaver; General Surgery on the Cadaver; Genito-Urinary Surgery on the Cadaver; Military Orthopedic and Bone and Joint Surgery; Treatment and Care of Fractures; X-Ray and Laboratory Work.

The Hospital has a bed capacity of over 400. The average number of patients admitted daily to the Dispensary is 800. The Hospital and teaching facilities are as extensive during the summer months as during the winter session. Cadaver courses omitted during June, July, August and September.

Through the courtesy of the Secretary, a two-day complimentary ticket is given, which enables the visiting physician to decide upon the courses best suited to his purpose and to meet the instructors in the various departments before registering for any work.

For Further Particulars Address

SECRETARY OF THE FACULTY

305 East Twentieth Street **NEW YORK CITY**

PLATE I.—Painting of specimen preserved in Kaiserling, showing stomach laid open as far as the pyloric ring; the duodenum not opened. The whitish area around the pancreas represents mesenteric fat. *A*, liver; *B*, gall-bladder; *C*, bile-ducts; *D*, approximate entrance of common bile-duct; *E*, duodenum; *F*, pancreas; *G*, pylorus; *H*, stomach.

(*Experimental Production of Pancreatitis in Animals.—Edward Archibald.*)

SURGERY, GYNECOLOGY AND OBSTETRICS

AN INTERNATIONAL MAGAZINE, PUBLISHED MONTHLY

VOLUME XXVIII JUNE, 1919 NUMBER 6

THE EXPERIMENTAL PRODUCTION OF PANCREATITIS IN ANIMALS AS THE RESULT OF THE RESISTANCE OF THE COMMON DUCT SPHINCTER

BY EDWARD ARCHIBALD, M.D., F.A.C.S., MONTREAL, CANADA
ASSISTED BY MR. BROW, MEDICINE, 1920

A REVIEW of the literature concerning the etiology of pancreatitis which has appeared in the last twenty years reveals the somewhat remarkable fact that observers have apparently been content to remain satisfied with the general idea (well-founded, so far as it goes) that the cause of pancreatitis in some way is closely connected with gall-stones and inflammations of the biliary tract. That this conception of the etiology of the disease fails to account for a large proportion of the cases has, I am sure, been noticed by those who have had any experience in the matter, and have stayed to think about it. On the other hand I am confident it will be generally admitted that this still largely unsolved problem concerning the immediate cause of pancreatitis, and its *modus operandi*, is of great importance; and this because, lacking this key, the door to rational treatment can hardly be opened, or at any rate, opened wide.

In what follows I desire, first, to review, as briefly as may be, the work hitherto accomplished along this line; second, to set down an account of certain experiments and observations which seem to afford a reasonable explanation of the immediate cause of pancreatitis, whether acute or chronic; and, finally, to suggest, as a corollary, the rational treatment.

The history of our knowledge of the etiology of pancreatitis has been summarized in a number of articles during the past few years, and particularly well by Opie (1), by Opie and Meakins (2), and by Guleke (3); so that it is hardly necessary to repeat it here in any detail. If one were to attempt a résumé of our knowledge in this field, it might not unfairly be stated somewhat as follows: The essential *pathological* lesion is necrosis of the pancreatic cells or masses of cells. This is *primary* (Opie and Meakins, 2). Hæmorrhage, inflammation, infection, are all secondary. What has for long been called acute hæmorrhagic pancreatitis ought to be called acute hæmorrhagic necrosis of the pancreas (Opie and Meakins, 2), or better still, simply acute pancreatic necrosis (Guleke, 3). Hæmorrhage, gangrene, and suppuration are merely complications, and frequently do not appear at all. A limited necrosis, remaining aseptic, may be replaced by fibrosis. Extensive mass necrosis results in pancreatic sloughs or sequestra. Chance infection of the necrotic area may result in pancreatic abscess, but is infrequent.

As to the *mode of causation*, a large number of experiments has shown that a variety of irritating substances—practically all of which have been injected into the pancreatic duct or the parenchyma, by means of syringe and

needle—are capable of causing, in animals, the same lesions that are observed in human cases that come to autopsy. The first of these substances was a mixture of bile and sweet oil, which Claude Bernard, in 1856, injected into the pancreatic duct of the dog, causing death in 18 hours from acute hæmorrhagic pancreatitis. A partial list of other substances includes gastric juice (Hlava, 4, 1890); duodenal contents (Polya, 5, 1906); weak solutions of a number of acids such as hydrochloric, nitric, and chromic acids, as also of alkalies (Flexner, 6, 1900); formalin, sweet oil, fatty acids and sodium soaps of the fatty acids; and finally bile (Opie, 7, 1901); the bile salts in pure solution (Flexner, 8, 1906). On the other hand certain substances, which from their bland nature one might anticipate would be unlikely to cause trouble, have been found to do little or no harm; such are blood, blood serum, agar agar, gelatine, paraffin, starch emulsion, and also cultures of certain bacteria when not too virulent or in too great quantity.

Now it is obvious that of all these substances the most natural one to think of as a possible cause of the disease in the human is bile; and as regards this substance we owe the bulk of our knowledge to Opie and to Flexner. In 1901 Opie (7), demonstrated that injection of bile into the pancreatic duct of an animal would cause necrosis of the organ, and at the same time he proved by a now celebrated autopsy observation (from Professor Halsted's clinic) that a *small* gall-stone lodged at the duodenal orifice of the bile papilla might divert bile from the common duct into the pancreatic duct, and in this way set up a fatal hæmorrhagic pancreatitis. A few similar observations have since been recorded (Bunting, 9, 1906; Crowell). In 1906 the solution of the problem was materially advanced by Flexner (8), who demonstrated that the essential constituent of the bile responsible for the necrosing effect in the pancreas lay in the bile salts, of which the taurocholate was much more active than the glycocholate. He also showed that the colloids, that is the mucin and nucleoproteins of the bile, were not only innocuous, but even protective. The mucin, he affirmed, modified the action of the bile salts, the effect being shown in a less fatal character of the experiment, and a less acute and destructive inflammation. That this was due to the colloid nature of the mucin, and not to any directly antagonistic substance contained in it, he proved by using such other colloids as agar, gelatine, and gum arabic, which, being mixed with solutions of the bile salts, secured the pancreas against necrosis in the same way as when the bile contained the proper proportion of mucin and nucleoprotein. He went on to point out that in the human the composition of bile, when imprisoned in the gall-bladder, changes in favor of the mucin constituent, and in the direction of a loss of diffusible salts as the result of inflammatory processes; and he thought that such bile would theoretically be apt to cause subacute or chronic lesions, rather than acute ones. Whether Flexner was correct in either of these assumptions has not yet been demonstrated, and, indeed, there is something to be said against them.

The experimental work of Nordmann (13) came nearest to imitating the conditions of nature. He closed the papilla by purse string suture and then forced bile, or infectious material, into the common duct and so into the pancreatic duct. After purse string suture alone, without injection of anything into the common duct there developed only jaundice, dilatation of bile and pancreatic ducts, and occasionally a few small fat necroses. He also found that bile often entered the pancreatic duct without doing any particular harm. He then added bacteria in the shape of a broth culture, 24 hours old, obtained from the fæces of a dog. Of this he injected one-half a cubic centimeter into the gall-bladder. All such animals died in 48 to 65 hours, with vomiting. In fourteen cases there was typical pancreatitis, with bloody serous exudate, numerous fat necroses, and greatly swollen pancreas, colored dark gray to black, with small and large hæmorrhages. He believed that the necrosing effect on the gland tissue was caused by stagnating infected pancreatic juice, sometimes mixed with bile, and that probably the disturbance was of a chemical nature. He thought the necrosing action

attacked chiefly the interstitial tissue, but sometimes also the gland lobuli.

The theory that duodenal contents might be forced back through the papilla and thence into the pancreatic duct had been maintained in particular by Hess (10), and by Williams and Busch (11), who demonstrated a sort of paralytic dilatation of the mouth of the common duct immediately after a fair sized gall-stone had passed through into the duodenum. They assumed that through this temporarily opened door the duodenal contents might be dammed back by irregular peristalsis into the common duct and the pancreatic duct. This theory still remains theory. In any case, under normal circumstances it has been found impossible, by experiment, such as the complete obstruction of the duodenum below the papilla, to force back the duodenal contents into the common duct (12). Early experiments of the writer, using an iron solution, introduced into a small loop of the duodenum, closed by ligatures from just above to just below the bile opening, under a pressure of 1000 millimeters of water maintained for an hour, demonstrated that none of the solution would enter the bile or the pancreatic ducts.

From the clinical side there soon came apparent support of Opie's hypothesis of the retrojection of bile into the pancreas through gall-stone obstruction at the papilla. Statistics concerning the coincidence of pancreatitis with gall-stone disease, and the location of stones in the various parts of the biliary tract in cases of pancreatitis, were published by Opie, Halsted, Koerte, Ebner, Mayo-Robson, Egdahl, and others. Thus Egdahl (14), for instance, in a series of 105 cases of pancreatitis, found gall-stones present in 44, but only in three was a stone in or near the ampulla. Robson says that the pancreas is involved in 60 per cent of gall-stone cases. Quénu and Duval (15) put it at 50 per cent.

Finally there should be mentioned the theory of Maugeret (16), supported in Germany by Arnsperger (17), and in this country strongly by Deaver (18), to the effect that the cause of pancreatitis is in many cases to be sought in a spread of infection from the gall-bladder wall through lymphatics to the cystic lymph node, thence by a periductal lymphangitis through the nodes along the common duct to those at the head and margin of the pancreas, and thence to the regional lymphatic distribution in the head of this organ. Deaver points out that out of 79 patients with chronic pancreatitis 72, or 91 per cent, showed evidence of infection in the bile passages; 42, or 53 per cent, had gall-stones, and 30, or 38 per cent, had none.

The arguments of a high authority, such as Professor Deaver, demand close examination, and can not lightly be set aside. Yet, to the writer, this conception is difficult of acceptation. It is probably true that cancer cells, say in the breast, when their natural course to the axilla is blocked, may be transported or, as is more likely, may grow in lines by contiguity, backward against the lymph stream, and so produce metastases, apparently anomalous, in the other side of the chest wall or in the epigastric lymph routes. But does this occur in infections? Possibly it does, again by contiguous growth. But does it occur when there is a barrier of lymph nodes to pass? The swollen glands lying above the pancreas are surely more reasonably to be regarded as the result of a primary pancreatic inflammation than as the sign of an infection coming from the gall-bladder and breaking through their guard to reach the pancreas. In cats in which I have caused a pancreatitis, these glands are found acutely swollen, obviously as the *result* of the pancreatic lesion. The demonstration of the possibility of injecting the lymphatics of the head of the pancreas from those of the gall-bladder, or cystic duct, is but small proof of the assumed fact that infectious material actually does take such a route. The lymph nodes draining any organ serve as a barrier to retrograde infection coming to that organ from elsewhere. It is most unlikely that the pancreas should be invaded by the lymph route. Not only is this the case, but a further argument is found in the fact that rarely is the pancreas the seat of a bacterial inflammation. Cultures from all but the frank abscesses, which are rare, are usually sterile, and sterile also from some of the abscesses. An infection

coming by way of the lymphatics would usually, to judge from analogous experience, be bacterial in origin and in type, and pancreatitis would much more often than is the case be suppurative.

For the sake of completeness, it should be mentioned that there exists a small amount of experimental evidence, and of clinical evidence also, to show that an inflammation of the pancreas can be hæmatogenous in origin. There are, for instance, a few cases on record in which suppurative pancreatitis has been observed as a complication of general infections. Then, again, in such a disease as mumps, observers (Edgecombe, 20; Simourin) have seen symptoms of acute pancreatitis in a few instances. Similarly, in typhoid, influenza, and in one case of mastitis (Dreesmann) has pancreatitis been found. Such clinical evidence is far from convincing as proof of the hæmatogenous origin of the disease. Now that we know how frequently the bile becomes infected, presumably through the liver, in generalized infections, it is quite as legitimate to suppose that the pancreatitis resulted by way of the bile tract as by the blood. Rosenow's recent work, indicating that bacteria can invade the wall of the gall-bladder by way of the blood, and that this localization is very often selective, is extremely suggestive; but even admitting this, it is obvious that the causative factor in pancreatitis is not thereby explained. The infection of the gall-bladder can at most be regarded only as a first step, and not even a necessary step, in the production of pancreatitis.

As a net practical result of all this work, it is probably not unfair to say that clinicians generally have combined, rather loosely, the experimental with the clinical and autopsy, evidence into the general conclusion that pancreatitis is caused by the retrojection of bile into the pancreatic duct, as the result of obstruction by a gall-stone at the outlet of the common duct; and that, when that mechanism is inadmissible, by reason of the absence of stones, the pancreatitis is in some way due to infection of the biliary tract, either by a plug of shreddy mucus blocking the papilla just as a stone might block it, or by a direct spread of infection along lymphatics from the infected gall-bladder wall into the substance of the head of the pancreas—(Deaver, 18).

Now, the fact above mentioned (concerning the large proportion of cases of pancreatic swelling in which stones, and even infection, are absent) has been becoming increasingly obvious to clinicians, and especially to surgeons accustomed to routine palpation of the pancreas in upper abdomen operations. In any case, the writer's attention was forcibly attracted to it by an analysis of some 34 cases of pancreatitis (19) which revealed the fact that in over 50 per cent operation demonstrated the absence of either gall-stones or cholecystitis. The conclusion imposed itself that there must exist some cause of the pancreatic swelling other than those indicated in the foregoing résumé. It seemed obvious that bile, which in experiments reproduced so accurately the pathological lesions of pancreatitis as observed in the human, must be the one altogether likely cause. The problem, therefore, was how to explain its entrance into the pancreas, in the absence of any mechanical obstruction such as a gall-stone or a plug of mucus at the outlet of the common duct. Clearly the obstruction would have to be an anatomical or a physiological one. The problem being thus stated, it seemed only natural to postulate the existence of a sphincter at the outlet of the common duct. At this point the writer was unaware that the existence of such a sphincter had long ago been demonstrated. There was nothing in surgical literature at the time (1911) to indicate that surgeons generally knew of such a thing. As a matter of fact the observation had been made by a physiologist and had remained, like many other physiological observations, of which the bearing on clinical medicine is obvious once they become widely known, more or less hidden in physiological textbooks. A little reflection was sufficient to convince one that there must be a sphincter at that point. For one thing there was the well-known fact that the discharge of bile into the duodenum is intermittent, while the secretion of bile is continuous. There was

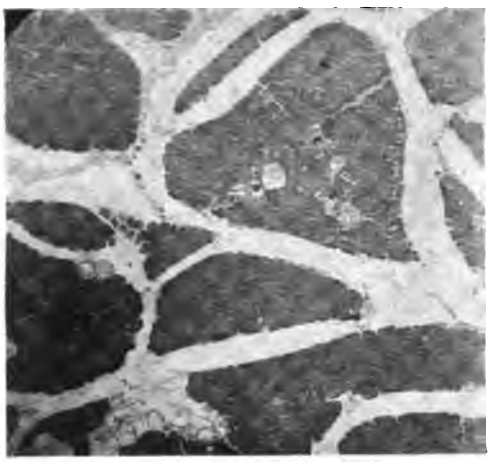

Fig. 1. Cat 86. Low power microphotograph. Many of the vacuolar spaces seen inside the lobules contain, in the stained specimen, yellow, amorphous substance, which represents very possibly the bile forced into the finer ducts of the pancreas. In other spaces there are capillaries showing pinkish-red, presumably representing blood, although blood elements are indistinguishable in the general necrosis. Some of the spaces seem to represent total necrotic cells, or groups of cells, of which only the cell outline remains as shadows. The lack of all definition seen in the photograph represents total necrosis.



Fig. 2. Cat 90. Low power microphotograph. In this specimen the definition is a shade better than in Cat 86, but the necrosis is still seen to be quite marked. Nuclei can be seen but the protoplasm of the cells of whole lobules is so necrotic that it looks as if it has been melted. Cell outlines can no longer be made out. The cells have run together and the tissue looks smudgy.

also the fact that the bile ducts dilate after the gall-bladder is removed, a result which could only be attributed to some normal obstructing action at the end of the common duct. Acting on this assumption, an experiment was performed on a dog, which demonstrated in a few moments the existence of such a sphincter. With a cannula in the gall-bladder, attached to a funnel holding a methylene blue solution, and with the duodenum open exposing the bile papilla, the fluid was observed to run through into the duodenum intermittently at any pressure which was not a paralyzing one; and, indeed, the muscular contraction of the sphincter, when it braced itself from time to time against the pressure of the fluid behind, could be perfectly well seen with the naked eye.

Some time later a search of the literature revealed the fact that this sphincter had been discovered, and thoroughly described, by the Italian physiologist, Oddi (21, and 22) who published two or three papers on the subject in the years 1887 and 1888. Appearing as it did in an Italian journal, and not in one of the better known, Oddi's very important observations escaped general notice. A reference to it is found in the larger textbooks of physiology, but clinicians, both in Europe and America, apparently knew nothing of it, or, if they did, failed to see that it had any bearing on clinical problems. It may, therefore, be of some interest to review briefly his work.

Oddi studied this muscle both physiologically and anatomically. In brief, he found that the sphincter in dogs was able to resist a pressure of 50 millimeters mercury, which equals about 675 millimeters of water. He demonstrated in microscopical sections that the sphincter was composed of a special bundle of circular fibers. He found that the common duct, outside its course through the bowel wall, possesses no muscular fibers. From the physiological side he discovered that this sphincter could be put into spasm by a mechanical irritation of the duodenal mucosa, or by the application of dilute hydrochloric acid in either the duodenum or the stomach; and that even mere cutting of the bowel to expose the papilla would cause spasms lasting from twenty to thirty seconds. Stimulation of the vagus apparently provoked a very prompt and intense contraction of the sphincter. A like result was obtained

by stimulating the central end of the cut sciatic, while stimulation of the sphlancnics had no effect. He also observed dilatation of all the extrahepatic ducts in dogs deprived of their gall-bladder. He thought a catarrhal condition in the duodenum was a stimulus to the sphincter, and that this might explain some cases of icterus where other causes could not be found.

It may be said that, at the time that the writer's experiments were begun, there was no opportunity of becoming acquainted with the original articles of Oddi, so that a considerable number of the earlier experiments were undertaken independently, and, in the result merely served to confirm his work. They were first begun in the fall of 1911, were continued intermittently during 1912 and 1913, and have been resumed during the past year. In a paper published in the *Canadian Medical Association Journal*, July, 1912(23) the early results were recorded very briefly. They amounted to this: that the hydrostatic pressure in the common duct, that is, the pressure which the sphincter at the papilla of Vater will oppose to a column of water, was surprisingly high. The sphincter was rarely completely overcome by any pressure less than 600 millimeters. In this paper the hypothesis was first suggested that small quantities of bile might be forced back into the pancreatic duct by the resistance of the sphincter, and there either cause, or help to maintain, the condition of pancreatitis. In April, 1913 (24) further experiments were recorded in the *Canadian Journal of Medicine and Surgery*, and the suggestion was made that in the operation for pancreatitis, instead of doing a cholecystostomy or cholecystenterostomy, it would be more rational to abolish the sphincter action at the papilla of Vater. It was demonstrated in dogs that this operation reduced hydrostatic pressure in the common duct from a level of 500 to 650 millimeters of water, before the procedure, down to 70 millimeters or less after it; and that this reduction was permanent for as long as eight weeks, at least, after operation. In this way the possibility of the sphincter damming bile back into the pancreatic duct would be permanently obviated.

In this article it was also shown that the operation of cholecystenterostomy, which had been advised by some, as a form of bile drainage, or rather, as a means of diverting the flow of bile from the common duct in the idea of preventing the passage of infected bile past the open mouth of the pancreatic duct, was based on faulty physiology. A cholecystenterostomy, as was shown by experiments, would fail to divert more than a very minute quantity of bile so long as the common duct was not blocked; and inasmuch as in the great majority of cases of pancreatitis the obstruction to the common duct is slight and transitory, the operation of cholecystenterostomy is ordinarily contra-indicated. This by the way.

In an article published in the *Canadian Medical Association Journal*, for February, 1913 (19) upon the diagnosis and treatment of subacute and chronic pancreatitis, it was maintained that the keynote of the treatment of pancreatitis consisted in the insertion of a safety valve in the biliary system in order to obviate any excessive rise of pressure in that system, thus giving the pancreatitis a chance to subside naturally; and that, in cases of considerable swelling and hardness of the gland such a safety valve, preferably a cholecystostomy, ought to be maintained for a much longer period than was generally done. Three months might be considered as not too long, though in milder cases a shorter period might suffice.

The experiments of the year 1913 were directed toward the demonstration of the possibility of driving a solution, introduced by way of the gall-bladder, into the pancreas, through the resisting action of the sphincter. It was found possible, in cats, to flood the pancreas with a solution containing iron, introduced into the gall-bladder at a water pressure of anything from 300 up to 800 millimeters, the iron being found in the pancreas at autopsy by appropriate staining reactions. These results were embodied in a paper read at the 17th International Congress of Medicine, in London, August, 1913 (25). The bearing of this work upon the problem was of course both clear and close.

After a prolonged absence abroad the



Fig. 3. Cat 94. High power microphotograph. Note the extraordinary degree of necrosis with formation of vacuoles, in which nothing is left but the nucleus, the protoplasm having disappeared. In the denser parts the protoplasm in the stained specimen shows absolute granular necrosis and looks as if melted. Cell outlines are broken down and have largely disappeared.

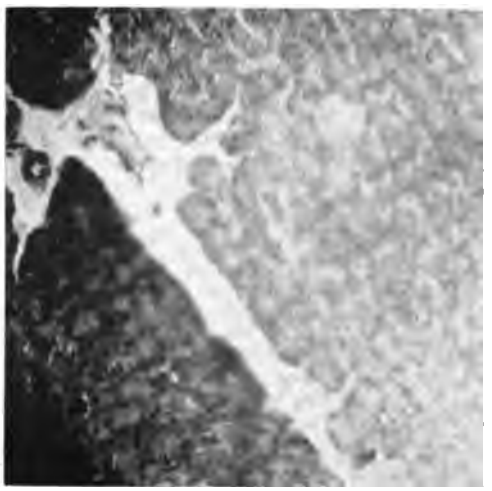

Fig. 4. Cat 96. High power microphotograph. The same necrosis is seen in most of the specimen. At the edge is tissue partly preserved.

problem was again taken up in the Laboratory of Experimental Medicine, of McGill University, in January, 1918, and the present paper records this last group of experiments.

It seemed natural to proceed from the point at which previous work had stopped. The problem now was to induce pancreatitis with bile, by forcing this bile into the pancreas in the same manner as had been done with the iron solution. It may be said that almost as once the experiment was successful, and we were able to produce an acute hæmorrhagic pancreatitis, with death in half an hour. This was in cat No. 86.[1] Certain outstanding experiments will be set down in detail, while the others can be abbreviated. At this point it may be well to indicate that the experiments as a whole may be grouped in three classes, according to the nature of the bile used.

I. Ox-bile infected with various organisms.

II. Human bile from a cholecystostomy case, passed through a Berkefeld filter and autoclaved.

[1] Previous experiments have shown that the dog is an unsuitable animal for experiments of this nature, probably on account of the anatomical fact that the large pancreatic duct in this animal opens directly into the duodenum and not, as in the cat and the human, into the common duct.

III. Solutions of bile salts.

Group 1. Those in which infected ox-bile was used.

Cat No. 86. April 3, 1918. With a cannula tied into the gall-bladder and attached to a funnel with rubber tubing, there was allowed to run in ox-bile which had been inoculated with staphylococcus flavus and incubated for forty-eight hours. Pressure was immediately raised to 500 millimeters. (The normal pressure of bile as secreted in the liver is not over 100 to 150 millimeters.) It was kept at 500 for 45 seconds, after which bile obviously began to run through into the duodenum, as shown by the decreasing level in the funnel. The pressure was then lowered to 100; then raised to 300 for 20 seconds; then to 400 for 20 seconds; at this point the gall-bladder was found to become distended. It was then raised to 500 for 30 seconds, and bile was now observed to run through freely into the duodenum. It was then lowered to 100 and the sphincter thus given a rest for one minute. It was then raised to 200 for 2 minutes, during which time there was no flow into the intestine. Then to 250, and now the flow began into the intestine, but slowly, and in small quantities. It was then lowered to 100 for 30 seconds; then raised to 250 again, when the flow began again in small quantities. It was then lowered to 100 for 30 seconds and raised to 300 for 3 minutes. At this level there was practically no flow. Particles in the glass cannula could be seen, sometimes going into the gall-bladder, at others being forced back; obviously there was intermittent sphincter action. Pressure was now lowered to 100 for 45 seconds, then raised to 350 for 45 seconds and then without further lowering raised suddenly to 600. At this point the sphincter obviously gave

way quickly and there was a free, rapid flow into the duodenum. After 30 seconds it was lowered to 100 and the operation was terminated. The whole procedure lasted about 25 minutes and 80 cubic centimeters of bile were used. It was noticed 20 minutes later that the cat had stopped breathing though the heart was still beating. Measures of resuscitation failed. Immediate postmortem showed a complete hæmorrhagic pancreatitis, from end to end (see frontispiece). The stomach was found to contain about 20 cubic centimeters of the bile used, but it was not congested or abnormal. The duodenum was practically empty, the common duct was not dilated and there was nothing otherwise of note to be found. A culture was taken from the pancreas, with precautions, and a pure growth of the staphylococcus flavus was recovered.

The histological appearances were as follows:

The pancreatic tissue has undergone hyaline necrosis over a large extent. Whole lobules are necrotic; in other places only part of a lobule, the fairly healthy cell passing over gradually into the hyaline masses. Apparently the necrosis has extended from the center of a lobule outward, as the periphery is the best preserved. In many of these areas there is practically no hæmorrhage; in others the capillaries are choked with blood, even into the finest ramifications of vessels, separating individual tubules, but actual escape of blood into the tissue spaces is seen only in a few places and is there not extensive. There are areas of half-way necrosis, indicated by loss of staining of the cytoplasm and of nuclei. The necrosis extends through probably three-fourths of the gland, and it is obvious that a great part would ultimately have been cast off as slough. The individual lobules are enormously separated by clear spaces which represent, probably, an intense œdema. It would seem as if necrosis were the primary lesion and hæmorrhage, preceded by congestion, the secondary lesion.

The same section was stained by Gram's, and it is remarkable how few of the staphylococci are to be seen. In the areas of solid necrosis they are almost entirely absent, except for an occasional capillary, in which one can see a plug of polynuclear cells and cocci. In the congested capillaries cocci are conspicuous by their absence. A few small plugs are found here and there between acini, or between lobules, and these are not in blood-vessels. Search was made for a branch of the pancreatic duct, and in one a clump of extruded cells was found, containing numerous staphylococci, indicating that the entrance path of the infected bile was by way of the pancreatic duct. The same was found in a very minute branch of the pancreatic duct, lying in the center of a lobule. A capillary, containing blood, running just beside it contained no bacteria. Many of the cells lining this small duct were necrotic.

In the hæmotoxylin section it is seen that the branches of the pancreatic duct are lined with necrotic cells, with great loss of nuclear staining, and breaking up of cytoplasm. Even the fibrous tissue of the wall of such ducts stains badly, and is obviously necrotic. At the splenic end the section shows, in general, the same changes as those just described, but if possible, even more extensive. Practically the whole tissue has undergone hyaline necrosis, and the fibrous stroma also is necrotic to a less extent.

Here, then, we have a clear instance of sudden death within 20 minutes of the close of the operation, from a fulminating pancreatitis caused by the forcing of infected bile into the pancreatic duct through the resistance of the common duct sphincter, without there being any other factor whatever in the causation of the lesion. The proof seems complete as regards the rôle which the sphincter of the common duct may take in the causation of pancreatitis.

In another cat we were fortunate enough to reproduce the condition of subacute pancreatitis with death in sixteen days. The experiment was as follows:

Cat No. 84. March 30, 1918. Cannula in the gall-bladder. Ox-bile inoculated with staphylococcus aureus on March 27, incubated for two days, and the third day kept at room temperature. The duodenum was opened for observation. The bile was run in at a pressure of 500, quickly raised to 700. It appeared immediately in the duodenum. Pressure lowered to 100 and flow stopped. Then raised by 50's up to 250, when a little bile came through at the papilla at intervals; then raised to 450, at which a quiet, small flow became continuous. Lowered to 100, flow ceased; raised quickly to 700, and there was an immediate flow of bile through the papilla; lowered to 100, flow ceased; raised quickly to 400, which gave a slight flow, ceasing shortly, so that the sphincter was obviously holding; pressure was then kept at 400, the sphincter still holding, for from 1 to 2 minutes. This ended the experiment, the duodenum and the gall-bladder were closed, and abdominal wound sutured. About 25 cubic centimeters of bile were used and the experiment lasted about 25 minutes. It was considered that the sphincter resisted well at 400 but gave way at 450. At the end of the experiment it was observed that all the pancreas in the neighborhood of the duodenal opening over a length of 1 to 1½ inches was dark red, contrasting strongly with the normal pink color toward the splenic and the lower duodenal end. The cat recovered well and seemed normal for some days. Toward the middle of the second week it refused food, but was not apparently suffering pain. On the morning of April 16 it was found dead but still warm. Postmortem was done within two or three hours. There was marked jaundice in the sclerotics and mucous membranes, which

had probably, to judge from its depth, been present for several days, although the orderly had not noticed it. On opening the abdomen the whole abdominal cavity in front of the omentum and over the anterior surface of the liver was found to be covered with a layer of yellow mush, which could be scraped off very easily, but which, on the liver left in places a rawish surface, indicating a several days' old inflammation. There was a small amount of thick yellow fluid in each flank. In the omentum there were a few spots of fat necrosis; while in the mesentery, behind the pancreas, and especially close to the duodenum, these were quite numerous. The pancreas was diffusely thickened, nodular and hard, being enlarged to about twice its normal size. The thickening was diffuse throughout the organ, but especially marked in the portion adjoining the entrance of the pancreatic duct into the duodenum. The pancreatic tissue looked pale, but also dull and opaque. There was no obvious obstruction in the common duct, but it is probable that the jaundice was due to obstruction at the site of the sphincter, either from pancreatic swelling or from spasm of the sphincter, inasmuch as the yellow mush, found free in the abdomen, was also found in the common duct and a considerable quantity of it in the gall-bladder, while the duodenum was absolutely empty, as also the rest of the small bowel. The escape of this yellow inspissated bile can only have occurred through the fundus of the gall-bladder where a ligature had been applied to close the cannula opening. But this was not clearly demonstrated, as the gall-bladder was cut open carelessly, before this point was determined. The black silk ligature could not be found, but the bile tract from the gall-bladder out to the dome of the liver was continuous, and the dome of the liver also showed the oldest lesions. The liver was yellow, pale, and fatty, and one small abscess was found upon cutting it open. Death was probably due rather to this infective hepatitis and to the peritonitis, caused by the exit of infected bile, than to the pancreatitis. A smear from the peritoneal exudate, stained with methylene blue, revealed no pus cells but only amorphous débris, with many minute needle crystals.

Microscopic sections showed the following: (1) At the duodenal end there is marked œdema with great separation of acini. In parts the tissue seemed well preserved but over a large portion of it the cells and the acini are much degenerated, and loosened from their basement membrane; they have lost their nuclei and lie scattered and independent. The structure of the gland is broken up with loss of the acinar arrangement. There are no foci of necrosis in mass. Inflammatory signs are lacking. A section stained by Gram's does not show bacteria. (2) Section opposite the pylorus resembles, in general, that of the duodenal end just described, but there is also a patchy infiltration with small round cells, and considerable thickening around blood-vessels, indicating a subacute inflammation which has subsided. It is a picture of early cirrhosis in patches. (3) At the splenic end, there is œdema, increase of the fibrous tissue in the septa, and considerable cell necrosis. The architecture of the gland is partly disorganized.

A section of the swollen gland, lying above the pancreas, shows an acute catarrh with much exudate, and a large proliferation of endothelioid cells, together with some fatty degeneration of cells. The liver shows multiple, small recent abscesses. A section of the omentum shows massive necrosis, together with signs of inflammation, much more marked than in the pancreas.

Cat No. 80. March 16, 1918. Injection with syringe directly into the gall-bladder of about 10 cubic centimeters of a solution of inspissated ox-gall (commercial sample) inoculated with bacillus coli communior and incubated for 48 hours, Specific gravity 1.08. Duodenum opened. Fluid injected several times with short sharp rises in pressure. Application of 5 per cent hydrochloric acid on duodenal mucosa. Sphincter was seen to hold for several seconds, then gave way.

March 17th, found dead, but warm, at 11 a. m. without rigor. Immediate postmortem, probably three to four hours after death. Peritoneum clean and dry. Pancreas adjacent to papilla congested and firmer than rest of organ; otherwise nothing of special interest, except for a large acutely swollen lymph gland at the upper border of the pancreas. Microscopic sections show (1) at *splenic end of* pancreas, numerous hyaline necrotic areas, densely packed. Parenchyma between these areas is œdematous and shows beginning necrosis with loss of cell outline. (2) At the *duodenal end* diffuse, œdematous swelling throughout; marked swelling of cells with many cell necroses, but no mass necrosis, except that a whole alveolus may be necrotic. Vessels filled with coagulated amorphous stuff. (3) At *one inch below pylorus*, little change; merely a slight cloudiness in some areas. (4) Liver shows numerous focal necroses. Cultures taken from the interior of pieces of the pancreas, after thorough cauterization of the surface, gave positive growths of gram negative and gram positive bacilli, with staphylococci. These were found in all parts of the organ; and bacteria could be seen in the stained sections.

Cat No. 81. March 20, 1918. The same bile as used in Cat No. 80, standing for past four days at room temperature; introduced through funnel with cannula in the gall-bladder. Bile run in at a measured pressure, varying from 200 to 800 millimeters, pressure being kept up for 10 to 30 seconds, with intervals of one to five minutes to allow sphincter to recover.

Cat died 1¾ hours after commencement of experiment. Immediate postmortem. Pancreas dull greyish, with faint shade of pink, and on cross section showed slight congestion of capillaries. Toward the tail nearly normal in color; not enlarged. Stomach much congested and filled with bile. Bile in the small intestine down to within a foot of the

cæcum. Lungs: upper lobes clear, right lower very much congested; left lower slightly so. Blood stained fluid in moderate amount in the peritoneum. Cultures, from the peritoneal fluid and from three different areas in the pancreas, remained sterile. One loop culture from the pancreas, near pylorus, gave a growth of a gram positive coccus. There was a much engorged and swollen lymph gland lying on the upper border of the pancreas.

Microscopic sections of the pancreas are in general normal, but in places the cells look as if they had melted or run; they are elongated and fused. The outlines are hazy and the protoplasm dirty-looking, but there are no mass areas of necrosis. The liver shows irregular focal necroses.

Cat No. 82. March 23, 1918. Injection into gall-bladder of ox-bile, inoculated two days previously with bacillus coli communior, and kept in incubator. Specific gravity of bile 1024. With cannula in gall-bladder, and duodenum opened for observation, the bile was introduced, from a funnel, under manometric control. The sphincter, in this case, was very weak, and let bile through in small amounts and in a quiet, almost steady, flow even at 200 millimeters, but not at 150 millimeters; at 250 millimeters, more freely; at 300 rapid steady flow; at 400 profuse flow. Stimulation of duodenal mucosa with 5 per cent hydrochloric had no special effect, save perhaps raising resistance by about 50 millimeters. The funnel was raised slowly and rapidly about eight times, up to 300, 400 or 700. The flow through the papilla always started immediately, showing lack of power in the sphincter, and entrance of bile into pancreas was hardly expected. Cat appeared fairly well at 5 p. m., March 25. Was found dead at 9 a. m. next morning. The postmortem revealed conditions as follows: The liver was very dark, engorged with blood and quite soft. The pancreas was pinkish-grey, slightly swollen, and soft, and showed a few bloody streaks on the surface. There were pin-point specks, of a dull white color, over the posterior surface, possibly minute fat necroses. The other organs appeared normal. Microscopic sections showed, in the duodenal end, œdema with considerable necrosis, granular, not hyaline, in patches, while in the splenic end one necrotic area was found. Cultures taken from the substance of the pancreas in various parts yielded gram negative bacilli, and a gram positive coccus. A small amount of fluid was found between the lobes of the liver, and a culture from this gave the same results. Small portions of the pancreas, thoroughly cauterized in a Bunsen flame, yielded, in broth, similar organisms.

Cat No. 85. April 3, 1918. Cannula in gall-bladder; duodenum not opened. Bile emptied from gall-bladder. A little saline run through at pressure of 700 millimeters. This passed into duodenum. Pressure lowered to 100 millimeters. Ox-bile, alkaline to litmus, inoculated with bacillus subtlis 28 hours previously, run into gall-bladder, at pressure of 600 millimeters, during 30 seconds. Lowered to 100 millimeters for 1½ minutes. Raised to 400 for two minutes. Lowered to 100. Raised to 500 for half a minute. Lowered to 100 for two minutes. Raised to 600 for 45 seconds. Lowered to 100 for four minutes. Raised to 300 for 30 seconds. Cannula removed, leaving some bile in the gall bladder. April 4th, cat found cold and stiff in the morning. Postmortem done at noon, probably fourteen to fifteen hours after death. About 40 cubic centimeters deeply hæmorrhagic serum free in abdominal cavity; none in pleura or pericardium. Pancreas showed slight patches of hæmorrhage in the substance of the pancreas adjoining the papilla, for 1 to 1½ inches on either side. The whole organ was of a dull grayish pink hue, and very soft. One greatly enlarged, congested, and œdematous gland lying on the pancreas at its upper border in the duodenopyloric angle. Stomach contained about 40 cubic centimeters of the bile and a lot of mucus. Duodenum filled with glairy mucus for a foot or more from pylorus, obviously an acute catarrhal inflammation. The lungs were very œdematous and congested in all lobes, with ecchymoses here and there, but air-containing, indeed foamy. Other organs show nothing particular. Death apparently due to acute toxæmia with pancreatitis. The urine at postmortem gave a strong reaction to sugar.

Microscopic examination showed extensive areas of necrosis, but without hyaline change. Many of the nuclei do not stain. This necrosis is definitely ante-mortem; the protoplasm looks coagulated, as if it were "boiled"; the cells are swollen. In the liver there is a very marked parenchymatous swelling, not postmortem in type, together with focal necroses, and small hæmorrhages. There is no particular congestion in the vessels. Part of the gland is well preserved. Sections of the swollen gland show great œdema, and considerable congestion in the capillaries. A piece of the pancreas attached to the gland shows some congestion, some œdema, and partial necrosis in some areas, with much disintegration of the gland structure and loosening of cells.

In sections from the pancreas and from the gland, stained by gram's, bacteria could be found.

Cat No. 87. April 6, 1918. Ox-bile, inoculated 48 hours previously with bacillus pyocyaneus, used. Bile was markedly alkaline. Same procedure followed as in Cat No. 86. Cat found dead at 11:30 a. m., April 7. Immediate postmortem. The pancreas is pinkish, but not particularly swollen. On section there were seen numerous punctate hæmorrhages, especially near the splenic end. The lymphatic glands, above the pancreas, leading to the hilus of the liver, were very much enlarged and congested. The gall-bladder was practically empty. In the duodenum a great deal of mucus, and a small hæmorrhagic area in the submucosa, close to the papilla, were found.

Microscopic sections from the splenic end, show parenchymatous swelling of the cells and degeneration but no definite necrosis. At the duodenal end and at the angle opposite the common duct

there are numerous patches of moderately advanced necrosis, in parts hyaline. In some areas there are also inflammatory foci and one small infarct. The lymph gland lying above the pancreas shows a very acute inflammation, with great œdema, catarrh, necroses, and purulent infiltration. The liver shows numerous focal necroses, and also small, multiple, very early abscesses.

Cat No. 88. April 10, 1918. Ox-bile, inoculated with bacillus prodigiosus six days previously, incubated for 48 hours and afterward kept at room temperature. With a syringe and fine needle 6 to 8 cubic centimeters of this bile was injected slowly into the gall-bladder. The gall-bladder did not become tense to any appreciable extent. Immediately before this 2 cubic centimeters of a 3 per cent hydrochloric acid solution were injected through a fine needle into the duodenum. The cat had fasted for the previous 24 hours. Death followed in three hours. Immediate postmortem showed the pancreas markedly congested, of a deep pink color, involving body and both ends, but trailing off to natural color toward the spleen and the extreme duodenal end. Bloody fluid in abdomen in quite large amount. Thorax normal, except that both sides of heart were dilated. A large amount of mucus, filling stomach and duodenum and upper jejunum, but no submucosal hæmorrhages. Mucosa of duodenum, from papilla to stomach, and also that of stomach of a whitish color, probably due to the hydrochloric acid. Urine gave positive sugar reaction.

Microscopic section shows considerable areas of swollen cells and of possible beginning necrosis, although this is not quite certain. As a whole the pancreas is normal. No bacteria are seen in sections stained by Gram's.

Comment. Death in this case can hardly be said to be due to pancreatic destruction, but there was clearly some very acute toxic process at work, sufficient to kill in a little over three hours. The congestion of the pancreas and the large amount of bloody fluid in the abdomen point in that direction. Presumably the toxine was contained in the infected bile. Whether its path of quickest absorption lay through the pancreas or through the intestinal mucosa can only be guessed.

Cat No. 89. April 10, 1918. Same procedure as in cat No. 88 except that bile used was that which had been inoculated with staphylococcus flavus, and had been standing at room temperature for a number of days. Bile was alkaline. April 15, the cat had recovered easily and was in good condition. Abdomen opened for examination and the animal then killed with chloroform. Immediate postmortem showed nothing of note, except the presence of two large, swollen lymph glands, obviously inflamed, lying on the upper edge of the pancreas just below the pylorus. The pancreas itself was not definitely swollen, but perhaps of a deeper color than normal.

Microscopic sections showed nothing abnormal in the pancreas. In the liver there were small areas of early inflammation, with small focal necroses, and some hyaline thrombi.

GROUP II. EXPERIMENTS WITH FILTERED AND STERILIZED HUMAN BILE

Cat No. 90. April 13, 1918. Human bile, not grossly infected, from a case of cholecystostomy, filtered through a Berkefeld filter, to get rid of bile mucin, then sterilized in autoclave for fifteen minutes. The reaction slightly alkaline. Injection of 2 cubic centimeters of this bile filled the gall-bladder without tension. Then 2½ cubic centimeters of 3 per cent hydrochloric acid injected into the body of the stomach followed by 2½ cubic centimeters of the same into the antrum pylori. Then about 8 cubic centimeters of the bile injected into the gall-bladder through a hypodermic needle; this seemed to pass on into the duodenum, as the gall-bladder did not distend. The cat recovered well and remained in good health.

On April 20, it was chloroformed. Immediate postmortem. The pancreas near the duodenal end was fairly normal; opposite the papilla and from there on to the splenic end, it was definitely thickened and the lobules stood out prominently. No areas of fat necrosis. The gall-bladder contained clean-looking bile and mucosa was healthy. The common duct was not dilated. The duodenum was normal. The urine showed a marked quantity of sugar. Otherwise there was nothing particular to be found.

Microscopic sections show large areas of necrosis in the pancreas with beginning hyaline change. The central area, around the ducts, is especially involved, while the periphery is often preserved. In some parts, especially close to the papilla, there is acute parenchymatous degeneration but no necrosis. Sections of the liver show focal necroses.

Comment. Note the effect of sterile bile deprived of its mucin and consequently containing a disproportionate amount of bile salts. Note also the lack of high pressure from the gall-bladder side and the resistance of the sphincter provoked, probably, by the hydrochloric acid. Also note the presence of marked microscopical changes, without obvious gross lesion.

Cat No. 91, April 15, 1918. Injection of human bile into the gall-bladder with a syringe and a large needle. Bile the same as that used in previous experiment. After expressing gently most of the bile found in the gall-bladder, the bile used in the experiment was injected and the gall-bladder was distended. This was followed immediately by the injection of ½ cubic centimeters of 3 per cent hydrochloric acid into the duodenum, close to the pylorus, which was then milked gently down toward the papilla; then immediate injection of ½ cubic centimeters of hydrochloric acid as before, followed by 4 or 5 more squirts of bile into the gall-bladder, using altogether 13 cubic centimeters of bile. The gall-bladder was not emptied between the injections,

but was relaxed somewhat, so that some bile clearly escaped into the duodenum or the pancreas. The pancreas, examined immediately upon opening the abdomen, was seen to be of a pale pinkish color. Examined again at the close of the experiment, it was found much deeper in color and with blood-vessels standing out prominently. There were also one or two small ecchymoses. One area, in the body of the pancreas, stood out pale by contrast with the deep red of the rest of the organ.

The cat was rather sick for two or three days after the operation, but then regained normal health. On May 30 it was chloroformed. The organs were all apparently normal. The pancreas was moderately pink, but not thickened or otherwise abnormal. There was nothing else of note. No sugar was found in the urine.

Microscopic sections show at the duodenal end very extensive areas of mass necrosis, with hyaline change. In two places apparently small infarcts. At the splenic end no definite necrosis, but in some areas a melting of cell outlines giving a sort of "boiled" look to the tissue. Considerable congestion. In the liver very extensive fatty change chiefly in the periphery of the lobules.

Cat No. 92. April 17, 1918. Injection of 3 cubic centimeters of human bile filtered and sterilized but standing for past week at room temperature, acidulated with 1 drop of hydrochloric acid, C. P. (reaction of bile, previously alkaline, made definitely acid), into gall-bladder, after partial expression, with finger, of bile in the gall-bladder; immediately followed by injection of 1 cubic centimeter of 3 per cent hydrochloric acid into the duodenum, just below the pylorus.

May 31st, chloroformed. The cat had been well since the operation. Pancreas and the other organs were found to be normal.

Microscopic section shows, at the duodenal end, normal appearances, except that in certain areas cell outlines are fused, nuclei stain poorly, and the tissue generally looks as if it had melted. There seems to be definite parenchymatous degeneration, if not necrosis. In some sections these areas are quite extensive.

At the splenic end the appearances are similar to those in the duodenal end. In the center, opposite the papilla, there is a good deal of small cell infiltration and also of young fibrous tissue, chiefly between the acini. Some areas are quite sclerosed, presumably a replacement of former areas of necroses.

These two experiments show that the coincidence of bile deprived of its mucin, with sudden pressure from the gall-bladder side, and increased acidity in the duodenum, is not always sufficient to bring about an injury to the pancreas. Doubtless there must occur a particular combination or sequence of these conditions and activities to cause pancreatitis.

GROUP III. EXPERIMENTS WITH SOLUTIONS OF BILE SALTS

Cat No. 94. May 31, 1918. A solution of sodium glycocholate was made in salt solution of a strength corresponding to the strength of the salt in human bile, and a few cubic centimeters were injected through a fine syringe into the gall-bladder after aspirating the bile present in it. The gall-bladder was not put under tension by the injection. The animal seemed unaffected by the operation. It was chloroformed after 48 hours and postmortem showed the absence of any gross change in the pancreas or other organs. On microscopic examination, however, there was found extensive mass necrosis of the parenchyma, with loss of cell outlines, fusion of the protoplasm, loss of nuclear staining, but without hyaline change. In the liver fairly numerous focal necroses were found.

Comment. The gross appearance of the pancreas was apparently so normal that the discovery of extensive cellular necrosis in the microscopical sections was a great surprise. The fact has been noted by Polya. The necrosing effect of the glycocholate, in this instance, is opposed to the observations of Flexner, who found that the injection of this bile salt into the pancreas caused but little disturbance.

Cat No. 96. May 31, 1918. A solution of sodium taurocholate in the strength normal in human bile was injected into the gall-bladder after aspiration of its bile, using about 6 cubic centimeters in three lots separated by an interval of some ten minutes. The animal did not appear to suffer from the operation. It was chloroformed after 48 hours and postmortem showed the pancreas apparently normal save for slight congestion; but the remarkable finding was a row of fat necroses stretching along the upper margin of the pancreas almost in its entire length. Here again, as in Cat No. 94, the comparatively normal gross appearance of the organ was belied by the discovery of extensive necrosis in the microscopical sections, and moreover, the necrosis was quite as advanced at the splenic end as it was in the neighborhood of the papilla of Vater. The picture was similar to that seen in sections of Cat No. 94.

This case would seem to prove the possibility of the occurrence of fat necroses without gross inflammatory obstruction of the main excretory ducts; also the possibility of mild grades of pancreatitis with symptoms so slight as to escape observation, at any rate in the animal. It suggests the likelihood that there occur cases in the human of mild pancreatic swelling accompanied even by fat necroses, later absorbed, giving clinically indefinite symptoms of epigastric pain lasting only for a short while, such as we see so

frequently in practice, and of which the cause so often remains undiagnosed. Both these operations (Cats No. 94 and No. 96) indicate the possibility, and indeed the probability, that there occur in the pancreas isolated or even extensive necroses, resulting from the entrance of bile into the pancreatic duct, which go on quietly to replacement fibrosis, ending in a moderate sclerosis of the organ which is not sufficient to interfere materially with its function. The condition is found not infrequently at autopsies in patients who have died from other causes, without there being noted in the case histories anything suggestive of a previous pancreatitis. Whipple has called attention to this fact in his animals, and has emphasized the extraordinary capacity of the pancreas to recover in this way from extremely serious necrosing lesions.

From a review of the experiments related above, certain outstanding facts may be deduced. Of these the main one is that the lesions produced in the pancreas by these methods of experimentation were brought about entirely through the action of the common duct sphincter, combined usually, but not always, with some increase of pressure in the biliary system behind the sphincter. That this increase in pressure need be very slight, indeed but little over normal bile pressure in the common duct, or may be even quite absent, is seen in the results obtained in Cat No. 82; also in Cats No. 90, 92, 94, and 96. I would suggest, indeed, that this is the ordinary mechanism at work in human cases, even when gall stones are present. In these animals there was no question of any mechanical obstruction to the outflow of bile into the duodenum. The obstruction was purely a physiological one. While the application of hydrochloric acid to the duodenal mucosa will definitely stimulate the sphincter to a heightened resistance, it is obvious that such hyperacidity is not necessary for the forcing of the bile into the pancreas. Many lesions of the organ were produced without it.

The second fact is that we have been able to produce in this way most of the main types of lesions in the pancreas found in clinical practice. Cat No. 86 is an example of the acute fulminating hæmorrhagic necrosis of the gland with death inside the hour. Cat No. 90 is an example of the generalized increase in size and hardness of the organ so frequently found at operation, with or without fat necrosis. The amount of necrosis in the pancreatic tissue is not so great as to cause sequestration, and it is without doubt replaced gradually, being aseptic, by fibrous tissue. This would represent the ordinary cure of pancreatitis of that grade of severity. Cat No. 96 represents the very mild type of the disease, going on to cure, with a small amount of fat necrosis spontaneously reabsorbed. Cat No. 84 is an example of subacute pancreatitis, with diffuse thickening and some fat necrosis, ending in death after two weeks, and with extensive necrosis of the parenchyma of the pancreas in microscopic sections.

Another interesting point concerns the immediate cause of the necrosis of the pancreatic parenchyma. Some have stated that, in whatever way the initial cell was destroyed, further destruction must be caused by activation of the trypsinogen in the pancreas, presumably by the introduction of enterokinase from the duodenum, or, possibly, by some other activating agent, such as calcium, derived from the blood, the bile, or inflammatory exudate. The experiments, however, above recorded, and also those carried out by previous observers, seem to show very clearly that the necrosis of the pancreas is the direct result of the action of substances entering the duct of Wirsung, such as the bile salts, unmixed with bile colloids, or such as artificial gastric juice, or a whole series of acids and strong alkalies. Recent observations of Tatum(26)and Bradley and Taylor(27) show that bile, or its salts, has a very marked cytolytic effect on the cells of various organs, and that this disintegrating effect is quite distinct from autolysis; that is, that it is not due to the activation of enzymes by bile or to a co-ferment in bile, but represents a straight destructive effect presumably of a chemical nature. The microscopic picture of diffuse parenchymatous necrosis, most marked in the center of lobules surrounding the ramifying ducts, and the hyaline

nature of the necrosis, differing markedly from the picture seen in postmortem autodigestion, would apparently suffice to prove this contention. Thus the necessity of accounting for the entrance of an activating ferment through the papilla and into the pancreas falls to the ground, though it need not be denied that activation and consequent autodigestion may occur secondarily and so increase the original necrosis caused by the entrance of bile. The theory of Williams and Busch, (11) assuming the flow of duodenal contents containing enterokinase back through the papilla dilated by the recent passage of a calculus, would provide the conditions for activation of the trypsinogen. In a like manner the "mucous currents" described by Mr. Bond (28) (who found carmine granules, given by mouth, appearing in the bile from a cholecystostomy—an observation, which, by the way, has been confirmed by the writer in one case out of three) might carry enterokinase up into the common duct. As a matter of fact the writer believes that the extent of necrosis is determined at the very outset of the disease by the grade of virulence and extent of permeation of the noxious agent, very much as in acute osteomyelitis the size of the sequestrum is fixed in the first few hours of the infection. It is possible, of course, that succeeding invasions of bile may increase the extent of necrosis.

A few other points of interest may be noted without discussion in this place. Liver necroses, of the type now well-known as focal necroses (Fischler, 29) occurring in the course of pancreatitis, were found with great regularity, both in fatal and in light cases; and were present within 20 minutes of operation.

The severe cases with early death were all in the series in which infected bile was used. Sterilized mucin-free bile, and the bile salts in solution caused, it is true, necrosis of the gland, but of a degree easily consistent with recovery; while the infected ox-bile almost regularly caused early death, usually with, occasionally without, severe lesions in the pancreas. Possibly the pancreas formed a route of particularly easy absorption. There is here an interesting comparison to be made with the cases of sudden death described by Symmers (30), in which moderate pancreatic necrosis was almost the only lesion found. Note especially in this regard Cats Nos. 81, 82, 85, 87, and 88. Fat necrosis (see Cat No. 90) is possible without acute changes in the pancreas of a reactionary inflammation and without infection.

The histological lesions correspond accurately with those produced by the injection with a syringe of bile, acids, alkalies and other irritants, as carried out by Flexner, Pearce, Hlava, and a number of other observers.

That alteration in the constitution of bile, which, once it is forced into the pancreatic duct, will set up necrosis and inflammation, is fairly well known. It is such as to leave the bile salts, particularly the taurocholate, in undue strength, whether this is accomplished by filtration or, possibly, by the action of bacteria. But the exact combination of circumstances under which such a bile, so altered as to be irritating to the pancreatic cell, is driven into the pancreatic duct is still somewhat unclear. I imagine that normal bile must frequently be forced into the pancreas by the action of the sphincter without doing any harm or causing any symptoms. The conditions for actual damage to be done must pretty certainly be three: first, a change in bile composition, increasing the proportion of bile salts; second, undue resistance, perhaps often amounting to spasm, of the common duct sphincter; and third, abnormal rise of pressure in the biliary system behind, either in the gall-bladder or in the common duct.

Our problem, therefore, is to discover in the facts of clinical experience circumstances fulfilling these postulates. Here we come on to uncertain ground. It is probable that hyperacidity may have a good deal to do with it. Symptoms indicating hyperacidity are frequently found in the previous history of patients with pancreatitis (Egdahl, 14). Certainly the injection of hydrochloric acid into the duodenum or even into the stomach (Oddi) will cause a spasm of the sphincter. In man we are still unacquainted, so far as I know, with the condition of the duodenal

contents as regards the length of time which is necessary for neutralizing the acid chyme of the stomach. In alcoholics, anyhow, and in patients who have duodenal ulcers, it would seem probable that the duodenal contents might remain acid for some time, and in these two classes pancreatitis, is rather frequent. One recalls in this connection three cases published by Dr. William J. Mayo, in which acute pancreatitis was present, without gall-stones anywhere, but with, in each instance, a duodenal ulcer situated close to the papilla, presumably causing hyperacidity.

In the second place, that change in bile which results in a high concentration of bile salts and a diminution of bile mucin is probably brought about by the effect of gall-stones, especially when associated with inflammation. In infected bile, it is pretty certainly not the bacteria acting in their infecting capacity that cause the pancreatic lesion, but rather the chemical change in the bile produced by the action of bacterial growth. This at least was strongly suggested by the work of Flexner, of Carnot, Hlava, and others; and the present experiments, in which sterile bile and a solution of sodium taurocholate caused the lesion equally with infected bile, tend to confirm this view. I am unacquainted with any work upon the chemical composition of infected bile, but it may be presumed that the action of bacteria is to precipitate the mucin of bile; and indeed we see the evidence of it in the shreds observed in the bile in cases of cholecystitis and cholangitis. If this is the case, it is probably contrary to the assumption of Flexner that the relative proportion of the bile salts is increased. I may add that Dr. Harding, Associate Professor of Chemistry in McGill University, is beginning work along this line. It must be pointed out, however, that the effect of bacteria upon the bile seems to increase very greatly the destructive effect of that bile upon the pancreas; and while this is still probably due to some chemical change in the bile it seems likely that there come into play, in addition to the bile salts, new substances possessing necrosing properties.

It may be noted also that any obstruction in the cystic duct would likely deprive the bile of a part of its mucin content normally provided by the gall-bladder mucosa; and in such cases, theoretically at least, the occurrence of a pancreatitis may be rendered more likely.

In the third place the condition of increased pressure in the biliary system is presumably brought about partly by an increased resistance of the sphincter, set in motion by hyperacidity or by neighboring ulcers; partly by a sudden blocking of the cystic duct by stone or inflammation; and finally, perhaps, by any unusual increase in the amount of bile secreted by the liver. The effect of a full meal, two or three hours after which, as we see in so many case reports, the attack of pancreatitis is apt to come on, may be in the direction of increased bile production rather than in that of increased pancreatic secretion.

TREATMENT

In conclusion I would like to say a few words about the bearing of these experiments upon treatment. Accepting this conception of the action of the sphincter, I think it may be concluded that the surgical treatment of pancreatitis must chiefly lie in a prevention of any further retrojection of bile into the pancreas. The damage already done to the organ will often be cured by the processes of nature, absorption, replacement, or even sequestration. On the other hand, if gangrene, abscess, or total slough has occurred, it may require a direct attack upon the pancreas itself. But to prevent recurrence or extension the cardinal point would seem to lie in the prevention of any heightened pressure in the biliary system, and secondly in the restoration of an altered bile to its normal chemical condition, or of an infected bile to sterile bile. This can only be done by a drain in the gall-bladder or in the common duct. Whether one should do a cholecystostomy or a cholecystectomy, with drainage of the common duct, is still a moot question, altogether apart from the condition of the biliary passages and the situation of gall stones in the individual case. Without pronouncing one way or the other in this matter, I would like to point out that in my opinion the essential thing lies in prolonged drainage; that is, prolonged

prevention of any rise in pressure in the bile system. This is more completely done by a drain in the common duct than by one in the gall-bladder, and possibly explains, what we now are inclined to believe is the case, that a cholecystectomy gives a better result than a cholecystostomy. I still think, as suggested in a paper a few years ago, that, in certain cases, the object of preventing a rise of pressure in the biliary system for a long time, or permanently, would be best secured by cutting the common duct sphincter. The after history of a duodenostomy for removal of stone, which always cuts the sphincter, seems to be very good. Such cases might form a middle class between those in which the gall-bladder is apparently normal, and those in which it is so diseased as to demand removal. But in any case, if the pancreas is materially affected, we must assume that nature will require at least three or four weeks, and often two or three months of protection in order to complete her repair work in the pancreas. I, therefore, adopt as a rule prolonged drainage of bile, from one to three months, in all cases of pancreatitis save the very lightest. And I may add that a recent investigation into the late results of our pancreatitis cases at the Royal Victoria Hospital has brought out in a very striking way the value of a drainage kept up for over three weeks, and up to three months; while on the other hand it has shown that a drainage of two weeks and less is followed by a large proportion of recurrences of the pancreatic attacks.

Parenthetically, accepting for the present the conclusion of Judd (31), that a cholecystectomy will more certainly cure pancreatitis than a cholecystostomy, one may hazard the guess that the reason lies in the cutting out of the only muscular force of any strength in the biliary system, thus preventing the rise in pressure associated with the contraction of a muscular organ, and substituting the big capillary system of the liver, capable of absorbing a considerable amount of back pressure, when brought on slowly, as would be the case with the continued resistance of the sphincter.

The interested reader should consult, in this connection, the very excellent clinical and experimental work done in the last two years by Dr. Judd and Dr. Mann, of the Mayo Clinic (31, 33, 34 and 35).

The opinion of some surgeons to the effect that a direct attack in the acute and subacute lesions should be made on the pancreas itself, with the idea of draining that organ, by incisions through its capsule, or by blunt poking into it, is, I think, an erroneous one, founded on a misconception of the pathological condition. One cannot drain a diffuse necrosis. Only in the cases in which such an interference can evacuate collections of pus, or of aseptic turbid fluid, representing the liquefaction of necrotic tissue plus reactionary exudate, can such a procedure be justified. Whipple and Goodpasture(32) have shown that the reactionary peritoneal exudate in acute pancreatitis has protective value; and the frequent recovery, without operation, of cases of a degree of severity less than that of the hyperacute or fulminating form, tends to confirm this view. Whipple, and other investigators, have shown, as a matter of fact, the great capacity of the pancreas to repair damage done to the organ, and it is possible that an excessive zeal in the operative attack upon the pancreas itself has pushed over the brink some cases that might otherwise have got well.

Practically speaking, it is the writer's opinion that surgical intervention should run along the following lines. In hyperacute or fulminating cases, in which death is obviously likely to occur within the first twelve to twenty-four hours, the patients being in collapse, it is better to wait; the shock of operation may turn the scale against them, and it is impossible, short of cutting out all or most of the pancreas, to prevent that absorption of split products from the necrosed tissue of the organ which is the immediate cause of death. These patients cannot be saved. If they do survive it is because the dose of poison stops short of the fatal amount, and not because incisions into the pancreas divert to the exterior a sufficient amount of the poison to turn the balance. It is only fair to add, however, that the administration of ether, in animal work, seems to

mitigate the toxic effects of split product absorption.

In all cases of less severity it is advisable to operate. In the acute cases the object is not to remove peritoneal exudate, which is rather protective than otherwise, or to "coffer-dam" the pancreas (an impossibility it seems to me), but rather and chiefly to drain the biliary system, and so prevent further entrance of bile into the organ. If there is a collection of fluid in the pancreas, this may be incised and drained; otherwise the pancreas should be left alone. The type of operation on the bile passages will vary according to degree of involvement of pancreas.

If the latter is only slightly enlarged and hard, and the gall-bladder is comparatively healthy a cholecystostomy may be done and the bile drained for not less than three weeks. If the pancreas is moderately large and hard, bile drainage should be kept up from four to six weeks. If it is very large and hard, drainage should be maintained for three months, with the alternative (proposed, but not established on a definite clinical basis) of a cutting of the sphincter of Oddi through an opening in the duodenum. In all these cases the gall-bladder should be removed, if, in the opinion of the operator, it is likely to remain a source of infection, in which case the common duct should be drained. In the acute cases, with the patient in a precarious condition, the least degree of interference is probably the best, and that would obviously consist in a cholecystostomy.

In the chronic sclerosing type of pancreatitis, following late after a severe acute attack, with fatty stools and glycosuria, and occasionally jaundice, I believe, on theoretical grounds, that it would be wise to cut the sphincter of Oddi in order to make quite sure that there will be no interference with the easy exit of bile and of whatever small amount of the pancreatic external secretion that may still be produced. A small amount of pancreatic juice will suffice for digestion, and the presence of bile in the intestine is necessary to fat absorption. In one such case in the writer's experience a chronic sclerosis of the gland ended in rapid death from a hyperacute pancreatitis. Jaundice is usually absent in such cases, but if present, and of long standing, and apparently due to obstruction by the enlarged head of the pancreas, a cholecystenterostomy would clearly be better than cutting the sphincter.

REFERENCES

1. Opie. Diseases of the Pancreas, 1910, 2d ed.
2. Opie and Meakins. J. Exper. Med., 1909, xi, No. 4.
3. Guleke. Ergebn. d. Chir. u. Orthop., 1912, iv.
4. Hlava. Bull. internat. de l'Acad. des sc. de Bôheme, 1890, iv, 139.
5. Polya. Berl. klin. Wchnschr., 1906, xliii, 1562.
6. Flexner. Johns Hopkins Hosp. Reports, 1900, ix, 743.
7. Opie. Johns Hopkins Hospital Bull., 1901, xii, 182.
8. Flexner. J. Exper. Med., 1906, viii, 167.
9. Bunting. Johns Hopkins Hosp. Bull., 1906, xvii, 265.
10. Hess. Muenchen. med. Wchnschr., 1903, i, 1905.
11. Williams and Busch. Tr. Ass. Am. Phys., 1907, xxii, 304.,
12. Maugeret. Recherches sur la pathogenie des pancreatites infectieuses.
13. Nordmann. Arch. f. klin. Chir., cii, No. 1.
14. Egdahl. Johns Hopkins Hosp. Bull., 1907.
15. Quénu and Duval. Rev. de chir., 1905, xxxii, 401.
16. Maugeret. Thèse de doct., Paris, 1898.
17. Arnsperger. Muenchen. med. Wchnschr., 1911, p. 729.
18. Deaver. Internat. Clinics, 1914, 24 ser. iii, 208.
19. Archibald and Mullaly. Canadian M. Ass. J., 1913, Feb.
20. Edgecomb. Practitioner, Lond., 1908, Feb.
21. Oddi. Arch. per le sc. med., Torino, 1888, xii, 333.
22. Oddi. Arch. ital. di Biol., 1887-8, ix.
23. Archibald. Canadian M. Ass. J., 1912, July.
24. Idem. Canadian J. Med., 1913, April.
25. Idem. A new factor in the causation of pancreatitis, Internat. Cong. of Med., Lond., 1913, August.
26. Tatum. J. Biol. Chem., 1916, xxvii, 243.
27. Bradley and Taylor. J. Biol. Chem., 1917, xxix, 281.
28. Bond. Brit. M. J., 1913, March 29.
29. Fischler. Arch. f. klin. Med., c, Nos. 3 and 4, 338.
30. Symmers. Dublin J. M. Sc., 1917, cxliii, 244.
31. Judd. Ann. Surg., 1918, April.
32. Whipple and Goodpasture. Surg., Gynec. & Obst., 1913, xvii, 591, 17.
33. Mann. Am. J. Physiol., 1918, xlv, 572.
34. Judd. Boston M. & S. J., 1916, clxxiv, 23, 815.
35. Judd and Mann. Surg., Gynec. & Obst., 1917, xxiv, 437.

TREATMENT OF PURULENT ARTHRITIS BY WIDE ARTHROTOMY FOLLOWED BY IMMEDIATE ACTIVE MOBILIZATION

By DR. C. WILLEMS, Ghent, Belgium
Honorary Professor of the University of Ghent, Director of the Hoogstade Military Hospital (Belgium)

NO therapeutic law has been more firmly established than that which has made immobilization obligatory for every joint injury, from the mild to the most severe. Nevertheless we all know its consequences; muscular atrophy which is rapid for certain muscles such as the femoral quadriceps, and stiffness of the joint. Also we know that such complications when once established are extremely tenacious and that frequently they do not yield completely to varied and very prolonged physiotherapeutic treatment. Even in the more fortunate cases it is necessary to continue such treatments for some months before getting the required results. Immobilization has been considered a necessary evil. It alone was believed to be capable of stilling the pains and obviating aggravation of the lesions, of preventing irritations and inflammations. In the case of purulent arthritis there was the stronger reason for carefully placing the joint at rest in order to avoid "dispersion of the germs" and extension of the infection.

It must, however, be recognized that in recent years there has been a mild reaction against systematic and prolonged immobilization. Many surgeons are now of opinion that for non-infected articular lesion at least, the joint ought be mobilized "as soon as possible." Although vague, this phrase is significant and shows a certain evolution of ideas produced by the force of events.

It is now some years since my attention was directed to this problem, and I have freed myself by degrees from practicing the law of immobilization. I commenced with evacuatory punctures to drain traumatic effusions of the knee, hemarthroses and hydarthroses, and by making the patient walk immediately. Not only could they do this without any difficulty but their lesion cured in a few days without leaving any trace. My method of treating traumatic effusions by puncture followed by immediate movement was rapidly adopted by practitioners dealing with industrial accidents owing to the rapidity and perfection of the recovery and also owing to its great simplicity.

Since the war the great frequency and infinite variety of articular lesions gave me the opportunity of applying this new method on a large scale. In the simplest and most severe conditions I have used immediate active mobilization after the operations for penetrating joint wounds with or without an included projectile, and for all varieties of intra-articular war fractures. I have not confined myself to non-infected fresh cases. I have also treated cases of purulent arthritis and it is perhaps in these difficult infected cases that the method has given the most astonishing success. But the object pursued differs. In simple lesions immediate active mobilization obviates atrophy and ankylosis. In purulent arthritis it seeks on the contrary to drain the articulations. In the first case the joint must be completely closed; in the second it must be left widely open.

A word as to the technique. It is practically the same whether the wound is aseptic or infected. In the case of recent injuries we commence by excising the soft parts of the wound, proceeding with the eventual esquillectomy of the fracture area, extracting projectiles and hermetically closing the joint. In purulent arthritis on the contrary; we must first execute an arthrotomy and leave the wound largely open. But starting from this movement we always proceed in the same way for mobilization.

The expression "immediate active mobilization" must be taken in its literal sense. The mobilization must be *active*, that is to say, made by the patient himself by muscular contractions. The movements ought reproduce the essential normal movements: ex-

tension, flexion, and rotation. The goal to be reached is to restore the physiological function of the articulation as much as possible, and in the case of the knee this function is walking. When complete functional restoration is not immediately possible, for instance in case of very extensive fracture, we must be contented with causing the chief active movements to be executed with the patient lying down.

Active mobilization cannot in any way be replaced by a *passive* mobilization, which does not call into play either the muscles of the limb or its nutrition, and which tends to restore mobility alone.

Mobilization must also be *immediate*, that is, commenced as soon as the patient awakens from anæsthesia. The patient must not be permitted to rest. The movements must be pushed to the maximum in every direction and must be kept up, so to speak, uninterruptedly. The treatment requires from the patient an effort which he will only make if he is kept at it all the time. He, therefore, needs supervision by a personnel in touch with the necessities of the treatment.

Fig. 1. Case 1. Roentgenogram taken on admission. Penetrating wound of left elbow by bullet with fracture of coronoid process. Purulent arthritis.
Fig. 2. Same as Fig. 1.



Figs. 3 and 4. Case 1. Two days after arthrotomy.
Figs. 5 and 6. Thirteen days after arthrotomy.
Figs. 7 and 8. Twenty days after arthrotomy.
Figs. 9 and 10. One month after arthrotomy.
Figs. 11 and 12. Two months after receipt of wound, 15 days after beginning of infection.
Figs. 13 and 14. Two months and a half after infection.

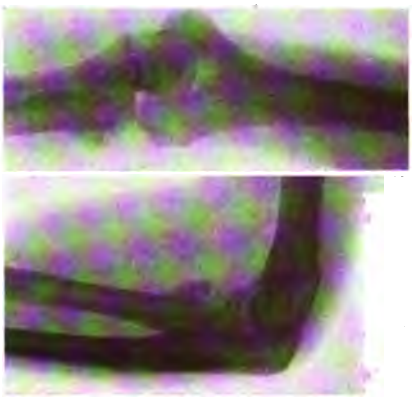

Fig. 15. Case 2. Compound fracture of external face of elbow by piece of grenade. Purulent arthritis. Roentgenogram taken on admission.
Fig. 16. Same as Fig. 15.

Active mobilization is always possible. It becomes more or less easy according to the extent of the lesions, the courage of the patient, and his aptitude in directing his efforts to the muscles which must be contracted and not wasting his strength in contracting other muscles than those necessary. Movements become easy according as they are repeated.

Active mobilization is not painful in the true sense of the term, except when it displaces large bone fragments and in such a case it is contra-indicated. But the movements are laborious and call for effort. It is found that a patient treated by active mobilization uses his limb in a variety of non-prescribed ways which he would not employ if the movements were painful. Many have stated that when a little pain is felt in periods of rest the best way of stopping it is to resume the movements.

Active mobilization gives the most surprising results in purulent arthritis. I do not hesitate to assert that against this formidable infection the new method is more efficacious than any of the means hitherto at our disposal.

In applying mobilization to the treatment of articular suppurations, my chief aim was to realize a satisfactory drainage after arthrotomy. We know that efficacious drainage of a joint by the ordinary means is an utopia. No kind of tube, no system of tampons, no means of irrigation, obviates retention nor stops the progress of infection. And it is on account of this insufficiency of drainage that arthrotomy has been almost abandoned and replaced by resection. But I have always been under the impression that to resect for the purpose of drainage alone is to go too far; and I have endeavored to empty the joint by expression, thanks to active movements. My earliest attempts convinced me. When a suppurated articulation has been opened by a large uni- or bilateral arthrotomy (a U-arthrotomy is never necessary) this is what is observed: At each extension and at each flexion the synovial surfaces are forced together by muscular contraction and pus is

Figs. 17 and 18. Case 2. Extent of movements during infection.
Figs. 19 and 20. Movements before the complete closure.

Figs. 21 and 22. Movements seven months after receipt of wound.

expressed often in the form of a jet. When the movements are very extensive and the muscles contract more vigorously the expression of pus is so much the more complete. If the movements are repeated a sufficient number of times the secretions are eliminated in accordance with the movements, retention is prevented, and articular drainage profoundly influences the local and general conditions. Locally, suppuration evolves like an ordinary abscess, but slowly. It lasts for a few weeks, abundant at first, then less, and finally disappears completely. During this period the arthrotomy opening or openings cicatrize. A species of fistula persists which closes from time to time and must be periodically opened. Œdema of the peri-articular tissues diminishes very rapidly and the tissues remain supple. Peri-articular abscesses are, so to speak, unknown.

With regard to the general state it is rapidly modified. From the commencement of active mobilization fever falls, not completely, as the patient may show 38° C. for some time. But the feverish aspect disappears; such patients do not look like badly infected cases.

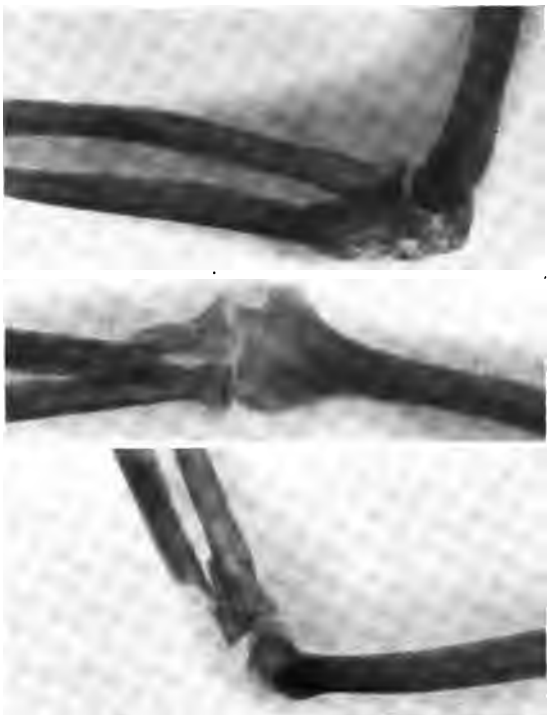

Fig. 23. Case 3. Compound fracture of olecranon and fracture of lower part of ulna; taken on admission.
Figs. 24 and 25. Case 3. After esquillectomy.

Figs. 26 and 27. Case 3. Two days after operation.
Figs. 28 and 29. Six days after operation, showing beginning of infection.
Figs. 30 and 31. Ten days after operation. Purulent arthritis.
Figs. 32 and 33. Four months after operation.
Fig. 34. Six and one-half months after operation.

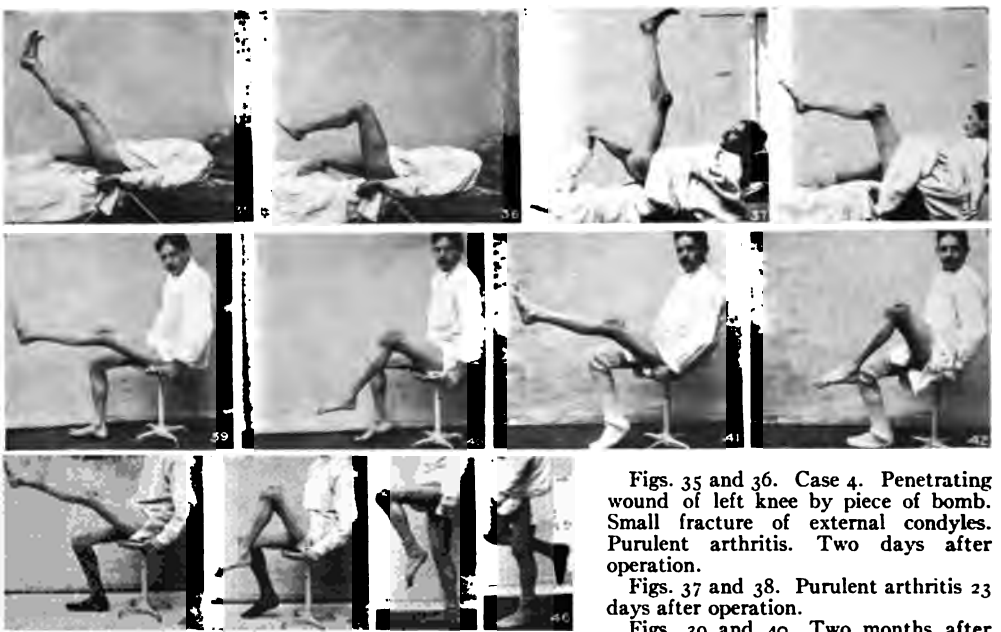

Figs. 35 and 36. Case 4. Penetrating wound of left knee by piece of bomb. Small fracture of external condyles. Purulent arthritis. Two days after operation.

Figs. 37 and 38. Purulent arthritis 23 days after operation.

Figs. 39 and 40. Two months after operation.

Figs. 41 and 42. Two and one-half months after operation.

Figs. 43 and 44. Three months after operation. Figs. 45 and 46. Four months after operation.

Drainage is therefore realized in an ideal manner without a tube, and without irrigation of any kind. I am of the opinion that irrigations are more harmful than useful.

Drainage was my aim at first. But I obtained more. I have obtained preservation of the articular mobility. Unquestionably we must consider the recovery of a purulent arthritis with ankylosis as satisfactory, and be thankful that the patient has escaped resection; but it is evident that a mobile joint is much better than the best kind of ankylosis.

Owing to the movements the arthritis has but little effect on the musculature. The quadriceps, which rapidly atrophies in purulent arthritis of the knee, remains astonishingly vigorous; and in the final reckoning there is but a negligible degree of atrophy.

Preservation of the articular mobility seems due to the fact that the perfect drainage limits infection to the synovia alone and prevents its propagation to the cartilage and bone. This is what is observed.

If the procedure is followed in the manner indicated, mobility of the joint will always be preserved. From the moment that suppuration notably diminishes we sometimes see a tendency to stiffness. This is why I now partially and progressively close the arthrotomy wounds from this moment, and only leave such opening as is strictly necessary for the discharge of pus which is still forming. Proceeding in this way, mobility will be perfect and absolutely normal in the great majority of cases, no matter what the causative microbe may be. The limb will show no functional disturbance after an infection as terrible as purulent arthritis was formerly considered.

In my earlier cases there remained sometimes a slight defect in flexion or extension. But I have the impression that according as one becomes familiar with the method we more and more regularly obtain complete successes.

In purulent arthritis still more than in non-infected lesions it is difficult to realize the possibilities of active mobilization. It is so contrary to classical ideas that we must see the patients move their limbs in order to understand. The truth is that movements are perfectly possible in purulent arthritis treated

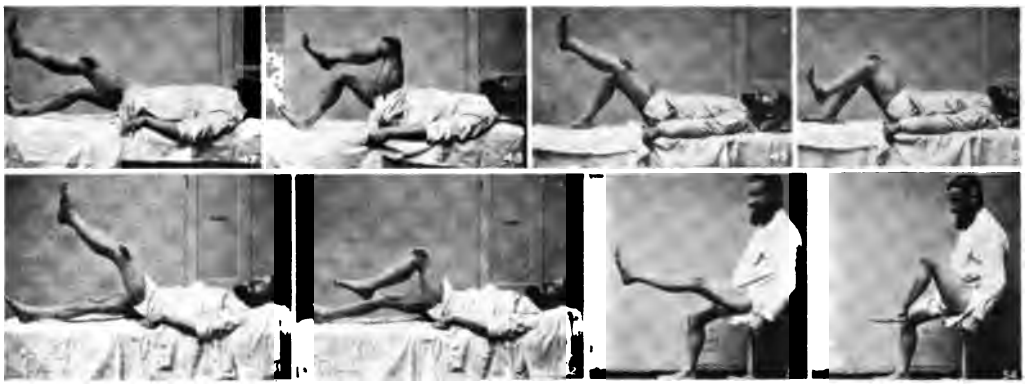

Figs. 47 and 48. Case 5. Multiple wounds by pieces of shell. Purulent arthritis of left knee from a small wound in the popliteal hollow. Twenty-five days after receipt of wound, 2 days after arthrotomy.
Figs. 49 and 50. Seven days after arthrotomy.
Figs. 51 and 52. Thirteen days after arthrotomy.
Figs. 53 and 54. Twenty-five days after arthrotomy.
Figs. 55 and 56. Six weeks after arthrotomy.

by arthrotomy, to the same extent as in non-infected articular lesions treated by excision of the damaged tissues and total primary suture. Movements are no more painful in the first case than in the second. They are equally laborious in the two cases. True pain appears only when the drainage is insufficient; and then it becomes necessary to drain more completely to cause an immediate cessation of pain. Whenever a patient complains of pain, especially in the popliteal space, it is almost certain that there is retention. The patients themselves soon learn to recognize this cause of pain and stop it by means of some movements.

In order to be convinced that movements are not painful, there is nothing better than to observe a patient when he does not know he is being watched. It is then seen that far from fearing movements, as was the case with the classic treatments, he constantly moves the joint without apparently being concerned about it, or preoccupied with the position of the limb. This fact, easily verified, proved quite clearly that if the articulations were even feebly painful, the patient would instinctively keep the part at rest.

Patients with purulent arthritis of the knee can walk early, even before cicatrization of the arthrotomy wound. It is the same with purulent tibiotarsal arthritis. It is a curious experience to see them walk with the joint widely open, expelling a little pus at each step.

Figs. 57 and 58. Case 6. Multiple wounds of both legs and eyes by pieces of grenade. Penetrating wound of left knee. Purulent arthritis. Three weeks after arthrotomy.
Figs. 59 and 60. Four months after arthrotomy.

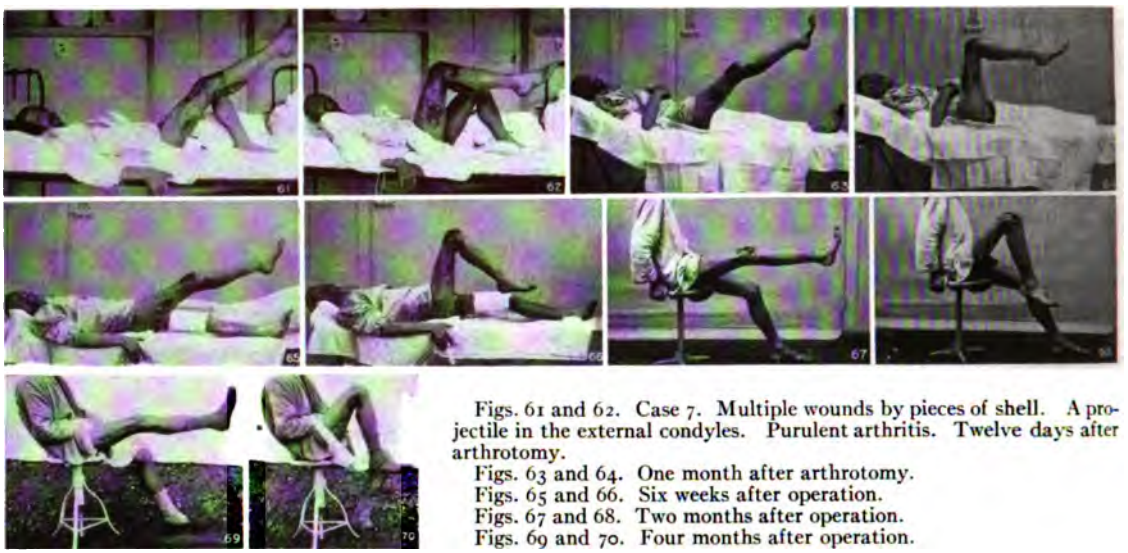

Figs. 61 and 62. Case 7. Multiple wounds by pieces of shell. A projectile in the external condyles. Purulent arthritis. Twelve days after arthrotomy.
Figs. 63 and 64. One month after arthrotomy.
Figs. 65 and 66. Six weeks after operation.
Figs. 67 and 68. Two months after operation.
Figs. 69 and 70. Four months after operation.

With regard to the question whether immediate active mobilization is applicable to cases in which purulent arthritis accompanies an intra-articular fracture, it can be answered affirmatively. As in non-infected lesions mobilization can be effected in purulent arthritis with fracture on condition that there is no fear of displacing the fragments. If there is, movements are contra-indicated because they might dislocate the joint.

A second circumstance which renders this method inapplicable is primary destruction of the ligaments and of the articular capsule. When the means of union have disappeared it is evident that the joint can no longer be mobilized by muscular contraction. But it is well to know that a partial destruction of the means of union does not render the method quite inapplicable.

I give here the history of some cases of purulent arthritis of the elbow, knee, and instep, due either to the diplococcus, staphylococcus or the streptococcus, with or without intra-articular fracture. These have been treated by simple arthrotomy followed by immediate active mobilization without any other means of drainage and without lavage. In all these patients drainage has been perfect, the temperature has not been high, the general state has remained excellent, infection has been confined to the synovia, there has been little or no atrophy, and articular mobility has been intregrally preserved.

CASE 1. Van D., Auguste. Perforating gunshot wound of the left elbow with comminutive fracture of the coronoid process. Bilateral arthrotomy with clearance, and excision of soft parts. Total closure of the two wounds.

The patient began to move his elbow two hours after operation. After a week extension and flexion were effected without difficulty and in a wide extent. Recovery continued and the movements became almost normal; then toward the seventh week, after an accidental torsion of the elbow, hemarthrosis was produced, then peri-articular abscess, and finally a purulent arthritis. An external arthrotomy was done. Pus showed staphylococci.

Movements were continued without interruption; they soon resumed their primary extent which had been much reduced owing to the infection. One month after the arthrotomy, the secretion was clear. The wound had been partly closed after 18 days. Two and a half months after infection the movements became very extended. There still persists some thickening of the epiphyses (Figs. 1 to 14).

CASE 2. L., Alphonse. Grenade wound of the external face of the right elbow. Loss of substance of external condyle and of the cupula of the radius. No projectile included.

Excision of the musculocutaneous wound. Ablation of fragments. Total closure. Active immediate mobilization. Redness and swelling the following day. Wound reopened. Movements continued and serosanguineous fluid expressed. On the next day the fluid was purulent. Staphylococci. Movement continued without much difficulty and extended. Temperature did not exceed 38.4°.

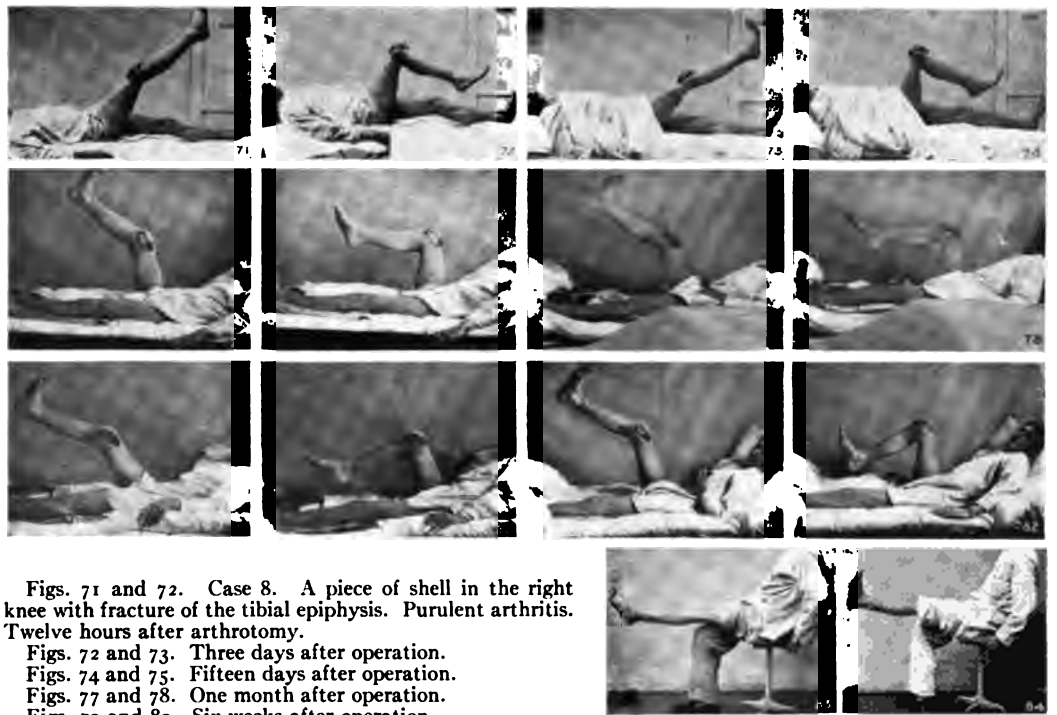

Figs. 71 and 72. Case 8. A piece of shell in the right knee with fracture of the tibial epiphysis. Purulent arthritis. Twelve hours after arthrotomy.
Figs. 72 and 73. Three days after operation.
Figs. 74 and 75. Fifteen days after operation.
Figs. 77 and 78. One month after operation.
Figs. 79 and 80. Six weeks after operation.
Figs. 81 and 82. Two months after operation.
Figs. 83 and 84. Case 9. Compound fracture of peroneus by piece of shell. Infection. Purulent arthritis. Three months after operation.

After a month, without any irrigations, secretion was reduced to a minimum, and the wound began to close. The extent of the movements increased each day, and they were easily accomplished, although they were more difficult after the night's rest. It required 4 months for definite closure of the wound. At present all movements are complete. The musculature is superb (Figs. 15 to 22).

CASE 3. R., Victor. Right elbow traversed by piece of bomb. Olecranon shattered and comminutive fracture of cubitus.

External arthrotomy. Complete clearance; the whole olecranon removed. Ether lavage of joint and complete closure. Immediate active mobilization which the patient does very well. By the third day a right angle of flexion was reached with complete extension. But by the sixth day there was swelling and redness and the movements diminished. Then some pus squirted between the sutures. Wound reopened. Movements continued without interruption with very complete expression of pus. No fever and the general state excellent. Streptococci in pus. Cicatrization after 3½ months of suppuration. The definite results showed that movements of the elbow are intact and the muscles in excellent state (Figs. 23 to 34).

CASE 4. Z., Henri. Penetrating bomb wound of left knee. The projectile entered the external side of the knee through the articulation producing a comminutive fracture of the external condyle and lodged higher up in the femur.

External lateral arthrotomy. Excision of soft parts, clearance of the bone area, total closure. Immediate active mobilization. From the second day flexion reached a right angle and extension was complete. There was a heavy hemarthrosis discharging between the sutures during movements. On the sixth day the temperature increased; the knee swelled and became painful; movements were less extensive. Arthrotomy wound reopened. Discharge of a large quantity of thick pus. Wound was left open and movements continued. In the pus large numbers of small diplococci and staphylococci were found. During the following days the discharge being insufficient an internal arthrotomy was added. From this on the drainage was good and the movements increased in amplitude.

After 4 weeks the secretion took a serous aspect and notably diminished. The two wounds were partly closed. The remaining part of the external wound closed very rapidly and did not reopen.

Examination 4½ months after injury shows walking absolutely normal, integral mobility and the muscles in excellent state (Figs. 35 to 46).

CASE 5. H., Louis. Multiple shell wound of the limbs and abdominal wall. A projectile deeply em-

bedded in the popliteal space, which had passed unnoticed, set up a purulent arthritis of the knee 3 weeks after entrance.

Bilateral arthrotomy. Immediate active mobilization. The pus contained diplococci. Two days after the arthrotomy flexion reached a right angle and extension was complete. Toward the seventh week suppuration having much diminished the arthrotomy wounds were partly closed. Cicatrization terminated 2½ months after the arthrotomy. The knee function is absolutely normal and the musculture intact (Figs. 47 to 56).

CASE 6. R., Romain. Multiple grenade wounds of the limbs and the two eyes. Penetrative wound of the left knee. General state at entrance too bad to permit an immediate operation. External arthrotomy of the left knee the next day. Ablation of a large intra-articular piece of projectile and a piece of cartilage embedded in the soft periarticular parts.

Total closure. Immediate active mobilization. Movements were good, but progressive tumefaction of the articulation followed, with pain; temperature, and gush of pus between the sutures.

The arthrotomy wound was reopened giving issue to a seropurulent fluid containing numerous diplococci. Movements continued. Evacuation of the fluid being incomplete, an internal arthrotomy was added and the knee drained more completely.

The first attempt at suture made when the flow diminished did not hold. A second suture held partly. During all this time the movements were continued.

As the suppuration cleared the remaining part of the wound closed. At the end of 4 months, after partial retentions, which each time necessitated large opening of the wound, complete recovery was obtained with absolute integrity of the muscles and of the articular mobility (Figs. 57 to 60).

CASE 7. G., Leonard. Penetrating shell wound of the right knee. Projectile embedded in the external condyle and cartilaginous covering of the condyle torn. Large muscular wound of calf and popliteal space communicating with the joint.

Multiple wounds.

External arthrotomy. Ablation of projectile. Curetting of bone parts. Total closure and immediate active mobilization.

The next day movements were well executed. But gaseous gangrene, invaded the wound of the calf and popliteal space. The joint, although communicating with this wound was then re-opened with an abundant flow of purulent serosity containing staphylococci, diplococci and some rod-like bacilli.

CASE 8. D., Albert. Shell wound of right knee. Projectile embedded in tibial plateau pushing into the articulation.

The suppuration continued abundant for several weeks. Movements were continued without interruption and became more and more extensive in spite of great apathy on the patient's part. At intervals there was retention with immediate diminution of mobility and rise in temperature.

After 4 months, the arthrotomy wounds, which had been partly sutured, were almost cicatrized. Movements were integrally preserved and the muscles remain in excellent state (Figs. 61 to 70).

Operated upon 15 hours after injury. External arthrotomy. Evacuation of a large quantity of seropurulent fluid. Ablation of projectile; owing to time elapsed since injury wound is left largely open.

Mobilization was commenced 4 hours after operation. Flexion to right angle. Complete extension Fluid found sterile at first. The next day it contained staphylococci. After some days, the pus being very thick and the evacuation being insufficent, an internal arthrotomy was added. Streptococci were now found in the pus.

Abundant suppuration persisted 3 months; then subsided. During all this time movements were easy and extended, except when there was some retention, always attended by pain, temperature, and diminution of mobility.

At present moment cicatrization is not yet complete. There are still some streptococci. Articular moblization is perfect and the musculature is in excellent condition (Figs. 71 to 82).

CASE 9. M., Joseph. Shell wound of left leg with comminutive fracture of fibula, cleansing and scrupulous clearing of fracture area. Infection of wound. Abundant suppuration. Purulent tracts toward the foot.

Five weeks after injury the infection spread to the tibiotarsal articulation. Staphylococcic purulent arthritis. External arthrotomy. Wound left completely open. Immediate active mobilization.

During 8 to 10 days the articular suppuration was abundant and temperature remained high. Then the secretion began to diminish as well as the fever.

At present, 3 months after injury and about 2 months after the beginning of the purulent arthritis, the wound is cicatrized. The movements and the musculature are normal (Figs. 83 and 84).

ROENTGENOGRAPHIC DIAGNOSIS IN RENAL TUBERCULOSIS[1]

By W. F. BRAASCH, M.D., and F. A. OLSON, M.D., Rochester, Minnesota
From the Mayo Clinic, Section on Urology and the Mayo Foundation

SEVERAL articles have appeared in European literature in recent years concerning the value of roentgenographic findings in the diagnosis of renal tuberculosis. Probably the most comprehensive of these is one written by Burchard who has made a thorough review of previous literature on the subject. In this country the method has had only limited use, and its importance does not seem to have been appreciated by American observers. Articles referring to the subject have been published by Krotoszyner and by one of the writers (Braasch).

The roentgenographic data in renal tuberculosis are regarded of such importance at the Mayo Clinic that it is a rule to make a complete roentgenographic examination of the urinary tract in every case in which renal tuberculosis is suspected. The frequency with which positive data may be obtained in the roentgenogram is evidenced by the fact that in the years 1916 and 1917, 131 patients were operated on for renal tuberculosis, and roentgenographic examination of the urinary tract had been made of all. Of this number positive shadows suggestive of renal tuberculosis were found in thirty patients, a percentage of 22. It may be stated, therefore, that approximately one out of five patients with renal tuberculosis will have positive roentgenographic data of definite diagnostic value. Such data are of particular value in conditions as follows:

1. When, because of the contracted condition of the bladder or impassable stricture of the ureter, the cystoscopic findings are inadequate.

2. When the cystoscopic findings are not typical of renal tuberculosis.

3. When the clinical findings are not suggestive of renal tuberculosis or of any involvement of the urinary tract, as may occur with a closed tuberculous pyonephrosis.

4. In the presence of bilateral renal tuberculosis when the typical shadows frequently render cystoscopy or further clinical examination unnecessary.

The roentgenographic shadows are caused by the deposit of calcium in the tuberculous area and may assume a variety of forms. To one who has had considerable experience in roentgenographic interpretation, such shadows will have characteristics that are usually recognized. They may be differentiated from a stone shadow by (1) the variability in its density, as the shadow is irregularly concentrated in different portions, (2) by a shadow of lesser density throughout than that usually observed with stone, and (3) by its irregular and indefinite outline. The calcareous area may, however, simulate the shadow of a renal stone in every particular, and it may be quite impossible to differentiate it without further clinical data. The same is true of renal stones that are occasionally seen of such consistency that the shadow will be fully as irregular and hazy in outline as a typical tuberculous shadow. It may be said, however, that approximately 75 per cent of tuberculous renal shadows may be recognized as such in the roentgenogram.

On resection of the kidney, an examination of the areas casting shadows in the roentgenogram will show a considerable variability in the nature of the calcareous deposit. Usually two definite types are recognizable, namely, actual deposits of lime encrusting the ends of the calyces, and caseated areas containing a sufficient deposit of calcium to cast a shadow. Tuberculous shadows may be roughly classified under three groups: (1) multiple scattered small areas, (2) single or a few localized areas of one centimeter or more in diameter, and (3) large irregular, diffuse areas involving either a large portion or the entire kidney.

In the first group the small scattered areas are generally caused by lime deposits. They are occasionally seen singly, and appear as elongated, irregular faint streaks, or as multiple punctate areas, scattered over a large portion of the kidney, usually in one of

[1] Paper presented before the Chicago Urological Society, Chicago, April, 1918.

Fig. 1. Shadows in Group 1 which consist of multiple small calcified areas in the lower pole of the kidney.

Fig. 2. Several calcified areas of larger size with some characteristics of Group 2.

the poles. Unless the renal area in the roentgenogram is carefully examined such areas may easily be overlooked.

The second group representing single or several isolated areas of concentrated calcareous deposit is the type most easily confused with stone. The shadows are usually of several varieties: (1) a shadow of irregular outline with a consistency dimmer than that seen with renal stone and varying in size from 1 to 3 or 4 centimeters; (2) a shadow characterized by great irregularity in its consistency and outline, somewhat resembling filigree work; and (3) definite shadows with a density and contour suggestive of stone. The size of the shadow in no way indicates the extent of the tuberculous lesion. A shadow of only a centimeter or two in diameter may be present in a tuberculous lesion involving the entire pole or even the complete kidney.

The third group is characterized by large, regular rounded shadows of variable density in their various portions. As a rule, on section, the kidney is of a putty-like consistency in the area which causes the shadow. It is, however, impossible to say from the appearance of such caseated areas whether or not a shadow will be present in the roentgenogram. In two caseated areas of similar appearance one may cast a shadow and the other none at all. Occasionally the calcium deposit is so slight that a soft diffuse shadow will be seen only on careful plate reading, and it may be easily confused with similar shadows cast by the bowel.

Shadows caused by complete caseation of the kidney are most striking. They may assume the outline of a complete cast of the kidney and are usually irregularly lobulated. The shadow may vary in density in different portions of the kidney, some of which may be so dim as to be scarcely discernible while others may be definitely and strikingly outlined. Occasionally, with complete or extensive calcification, the calcium deposit may be so slight that the X-ray simulates that of accentuated normal renal outline, and it may be difficult to determine whether or not it is an actual pathologic shadow.

Actual renal stone formation is rare in tuberculous kidney. When it does occur it is generally a phosphatic stone, formed in a localized abscess with necrosis and secondary infection. We have observed this in several cases. Stone formation in the opposite kidney in cases in which a tuberculous kidney had been removed occurred in but two instances that came under our observation. One patient

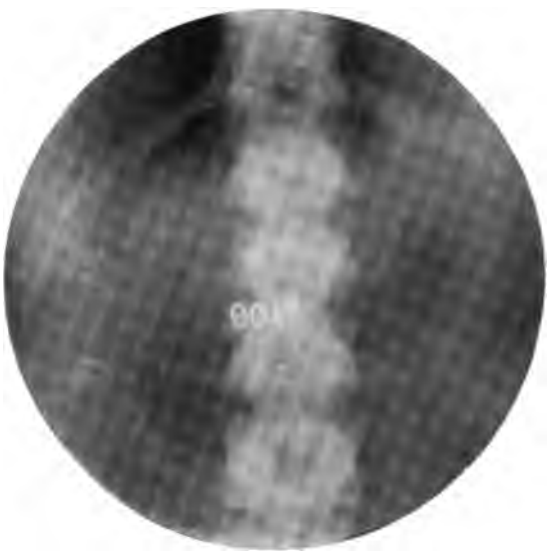

Fig. 3. Single large calcified area in the lower pole of the kidney which belongs to Group 2, suggestive of renal stone.

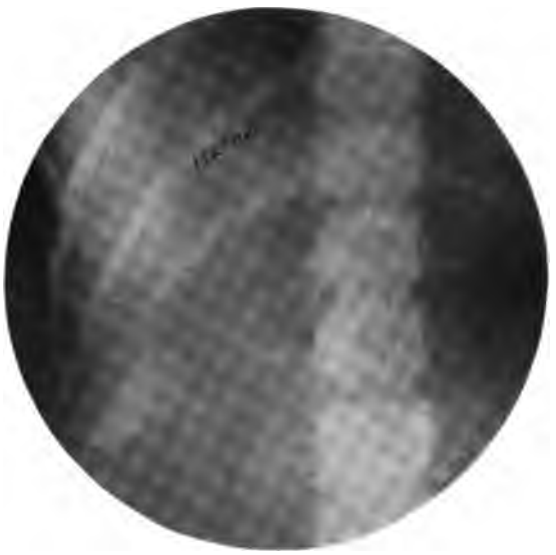

Fig. 4. Typical "filigree" shadow belonging to Group 2.

passed a small renal calculus from his remaining kidney two years after the other kidney had been removed for tuberculosis. It may be inferred that primary stone formation is unusual in patients with renal tuberculosis.

Extrarenal shadows. Calcareous deposits of the kidney may be confused with renal stone. They must also be differentiated from various extrarenal shadows which frequently appear in the roentgenogram. The most common cause of confusion is the deposits in glands situated in the perirenal tissues. Calcified tissues situated in the pleura, subdiaphragmatic and retroperitoneal areas are especially likely to cast shadows closely simulating intrarenal calcification. Next to be considered is the possible confusion of shadows caused by substances in the bowel. These may be readily identified, however, by disappearance or change in position while subsequent roentgenograms are being made. Gall-stones may also occasionally cast a shadow which will closely simulate renal tuberculosis.

Ureteral shadow. Calcareous deposit may occur with tuberculosis in the ureter, although less frequently than in the kidney. When it is present a considerable portion of the ureter, usually the lower portion, is involved. The shadow may be several centimeters or more in length and outline the dilated ureter to a greater or less extent. The shadow is caused either by calcareous deposits in the thickened wall of the ureter or by intra-ureteral calcareous deposits. Such deposits are generally accompanied by similar caseation in the kidney. Considerable peri-ureteritis may accompany this calcification of the ureteral wall. The peri-ureteral infiltration together with the thickened ureter will often cause a tumor-mass which can easily be palpated on rectal or vaginal examination. Often calcified glands in the bony pelvis will cast shadows suggestive of either stone or tuberculous deposit in the lower ureter. They, however, usually occur with no clinical evidence of tuberculosis in the urinary tract or other portions of the body, and are therefore of no diagnostic significance.

Calcareous deposits in the prostate gland. Occasionally calcium deposits secondary to tuberculosis in the prostate gland cause roentgenographic shadows suggestive of prostatic stone. Although the clinical findings should differentiate the two conditions, a chronic healed tuberculous infection may be overlooked.

Renal outline. Interpretation of the outline of the kidney itself in the roentgenogram is

Fig. 5. Two areas of calcification of the lower pole with shadows suggestive of stone, Group 2.

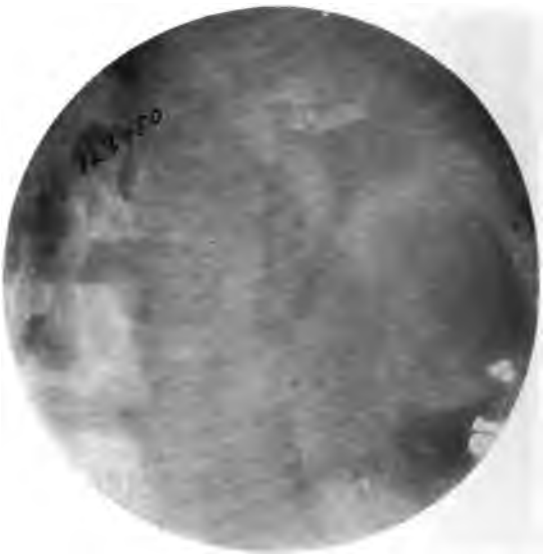

Fig. 6. Irregular calcified area in the upper pole of the kidney easily confused with calcified tissues in the pleura.

not of much practical value. Some observers have claimed that irregularity of outline of a tuberculous kidney may be demonstrated in the unaided roentgenogram. However, the possibilities of error are so great that these data are not to be relied on. It is well-known that bowel contents, the outline of surrounding organs, change in position of the kidney, etc., cause factors which interfere seriously with accurate interpretation of the renal outline. Occasionally, as Casper has stated, the outline of a greatly hypertrophied kidney on the opposite side of a tuberculous shadow may be of value in indicating hypertrophy subsequent to destruction of the diseased kidney. However, one would be loath to remove a definitely tuberculous kidney without further proof to demonstrate that the hypertrophied kidney is otherwise normal.

Bilateral involvement. Roentgenographic evidence of renal tuberculosis may be of value in determining the existence of bilateral involvement or that the patient is otherwise inoperable. With shadows of definite tuberculous calcification present in both kidney areas, cystoscopic and further clinical investigation is usually unnecessary. It must be remembered, however, that bilateral renal tuberculosis may exist even though a tuberculous shadow may be found only in one kidney area. This is particularly true with a chronic tuberculous infection in one kidney, and a recent involvement of the other. If the bladder is in such a state that it is impossible to make a satisfactory cystoscopic examination, a shadow of calcification in one kidney area might be of considerable diagnostic value. This is illustrated in conditions as follows: (1) when the healthy kidney has been catheterized and it is impossible to find or catheterize the other side; (2) when neither meatus is found but the patient's general condition, and the renal functional tests indicate the existence of one healthy kidney; and (3) when evidence of disease is found in the kidney that is catheterized, and there is a shadow of calcification in the kidney which cannot be catheterized.

Pyelography. A common source of error in diagnosis is the confusion of shadows caused by renal stone and by tuberculosis. The clinical findings may be identical. At operation instead of finding the expected stone and performing a lithotomy the surgeon will be called on to do a nephrectomy for tuberculosis. Although the cystoscopic and laboratory findings will usually identify the tuberculous shadow occasionally they too, will fail.

Fig. 7. Outline of a completely caseated kidney, Group 3.

Fig. 8. Calcified areas in both kidneys, a condition which is found in bilateral renal tuberculosis.

In the identification of such shadows, as well as of renal infection of a doubtful nature, pyelography will frequently afford valuable information by demonstrating the pathologic changes in the pelvic and ureteral outline peculiar to tuberculosis.

The changes in the pelvic outline regarded as characteristic of tuberculosis consist of one or more of the following: (1) irregular inflammatory dilatation of the pelvis, (2) areas of cortical necrosis, and (3) stricture in the ureter.

Inflammatory dilatation of the pelvis as the result of tuberculosis in its early stages is largely confined to the calyces. The dilatation is differentiated from ordinary inflammatory dilatation by the greater irregularity in outline of the calyces and by the variability of degree of dilatation among the different calyces. A peculiarity often noted is marked dilatation at the uretero-pelvic juncture.

When the process is advanced, so as to cause necrosis of the renal parenchyma adjacent to the calyces, the pelvic outline becomes irregular and indistinct to a variable degree. When the necrotic areas are confined to one or two calyces the outline of the latter will have a moth-eaten appearance at the apices, and the pyelographic medium is visible as a hazy shadow extending into the parenchyma. When the necrotic process is advanced, it may either assume irregular forms scattered through the parenchyma or it may coalesce to form a large irregular sac.

Occasionally the outline of the necrotic area is apparently detached from the pelvis,

Fig. 9. Calcification of the lower portion of a tuberculous ureter.

Fig. 10. Calcification of tuberculosis which occurs in the prostatic gland.

Fig. 11. Pyelogram showing inflammatory dilatation and necrosis of calyces, which occurs in tuberculosis.

or connected with it by a narrow isthmus. When the area of necrosis is confined largely to the cortex and is not directly communicating with the pelvis, the pelvic outline may occasionally become contracted in a manner resembling certain forms of pyelonephritis.

As a result of the infective process in the kidney, inflammatory dilatation of the ureter will follow and may be demonstrated in the ureterogram. Should the ureteral mucosa become ulcerated, however, and a stricture ensue, mechanical dilatation may also be present. Ureteral dilatation resulting from tuberculous stricture in the ureter may be confused with that resulting from a benign stricture, or obscure lithiasis. If the clinical and cystoscopic findings are insufficient with which to identify the lesion, pyelography will usually demonstrate abnormality in the pelvic outline that is suggestive of tuberculosis.

The cystogram may also occasionally be of diagnostic value. This is particularly true when it is impossible to find either one or both meatus. The bladder outline will be variably contracted and usually more in one half of the bladder. The demonstration of a dilated ureter by making a cystogram with the patient in the Trendelenburg position is suggestive of renal involvement on that side. Demonstration of a widely dilated internal bladder sphincter and posterior urethra in the presence of a severe cystitis is also suggestive of tuberculosis.

CONCLUSIONS

1. The value of roentgenographic diagnosis of renal tuberculosis does not appear to be fully appreciated.

2. Routine roentgenography in every case in which there is evidence of infection in the urinary tract is adviasble.

3. Shadows may be found in approximately 20 per cent of patients with renal tuberculosis. Such shadows may require the aid of cystoscopic data in their interpretation.

4. Positive evidence of tuberculosis may be obtained by this method when all other clinical data fail, and when cystoscopic examination is impossible.

5. Shadows due to renal tuberculosis may be arranged into three definite groups.

6. Caseated areas in the ureter and prostate may also be outlined.

7. Pyelography is occasionally valuable (1) in the identification of renal infections of doubtful nature and (2) in the identification of doubtful shadows in the renal area.

8. The cystogram may also give data of value (Figs. 1–11).

REFERENCES

1. Braasch, W. F. Recent developments in pyelography. Ann. Surg., 1910, lii, 645-653.
2. Idem. Clinical observations from 203 patients operated on for renal tuberculosis. J. Am. M. Ass., 1912, lviii, 397-401.
3. Idem. The results of the early diagnosis of urinary tuberculosis. Interst. M. J., 1912, xix, 863-869.
4. Idem. Pyelography. Philadelphia: Saunders, 1915, 172-182.
5. Burchard, A. Die roentgenologische Nierendiagnostik. Fortschr.a.d. Geb.d. Roentgenstrahl., Hamb, 1913, xx, 244-288.
6. Casper, L. Diagnosis and treatment of tuberculosis of the kidneys. Am. J. Urol., 1904, i, 46; 87.
7. Idem. Nierentuberculose. Deutsche Klinik, 1904, li, 1274.
8. Krotoszyner, M. Upon the early diagnosis of renal tuberculosis by the general practitioner. Calif. St. J. M., 1914, xii, 195.
9. Idem. J. Am. M. Ass., 1914, lxiii, 2006-2009.

ACUTE INTESTINAL OBSTRUCTION FOLLOWING APPENDECTOMY

By ANTHONY H. HARRIGAN, M.D., New York
Associate Visiting Surgeon, Fordham Hospital

DESPITE the development of greater proficiency, postoperative intestinal obstruction occurs sufficiently often to warrant occasional discussion. Acute intestinal obstruction, secondary to appendectomy, is one phase of the general topic demanding critical attention, as to the manner of causation and production. It is a demonstration that the last word has not been said concerning appendicitis, despite the voluminous literature existing on the subject, a fact evident to those engaged in active surgical service, where the mortality of acute appendicitis is still a matter of serious concern.

The special point in the discussion is the prevention of the condition. An analysis of the methods of treatment, merely detailing one aspect of the general subject of intestinal obstruction, would not permit so practical treatment of the question, as an investigation of the manner of production of the obstruction. It will not be necessary to analyze the personal cases herein reported regarding the special lesions produced in each instance for the specific causes can be obtained from a general reading of the literature. Certain distinct mechanisms, however, come to mind at once. I refer, particularly, to the rôle played by the omentum, and that taken by adhesions. The omentum, owing to its migratory nature in abdominal inflammation, may contract a firm adhesion to an organ, especially, the tube or uterus, producing, as a result, a sling or hammock over or beneath which an intestinal loop may be constricted. If the omentum is lax or loose, intestinal occlusion does not occur. On the other hand, if the omentum, from any cause becomes taut, for example, from elevation of the transverse colon or from a twist or torsion in the omentum itself, it acts as a tightly drawn string playing on the face of the intestinal loop. When the obstruction acts intermittently, there results, secondary to strangulation, transudation into the peritoneal cavity. An omental band, from anatomical reasons, is more likely to obstruct the small than the large intestine. A history of a previous abdominal operation adds a confusing element. Pelvic operations, performed at a period when peritonization of pedicles and raw surfaces was not generally practiced, furnish numerous instances of postoperative intestinal obstruction, due to bands, adhesions and false ligaments.

The artificial and experimental production of adhesions lends itself readily to a study of their prevention. A review of the histology of the peritoneum, however, fails to bring out any vital points. There exists, no doubt, a distinctive peculiarity of the mesothelial cell which favors its proliferation. Also, the lymphatic current of the peritoneum, of which so little is known, may be important. The tendency of the peritoneum to agglutinate, appears as a reaction to irritation.

physical or chemical. It is a primary and characteristic manifestation of a cell, and, in this instance, is an indication of a defensive mechanism. The mere presence of the operator's fingers may, occasionally, be sufficient to produce adhesions. On the other hand, a prolonged operation, with considerable handling and manipulation of the intestine, may occasion no essential change in the peritoneum. The extent of the infection appears negligible. A gangrenous appendicitis, associated with diffuse peritonitis, may lead to no discernible sequelæ; whereas, an interval appendectomy, with a minimum amount of peritoneal contact may rapidly produce proliferative changes and band formation.

There are individuals, in whom a tremendous degree of intestinal matting may exist, without the slightest personal discomfort or objective indication. In a young married woman, who came under my observation at St. Francis Hospital, I opened the abdomen with the intention of correcting a retroverted uterus, the main and sole symptoms being backache. At operation, there was found an intestinal matting and agglutination, almost indescribable in its complexity. In a word, it is evident there exist compensatory mechanisms which overcome the stenosing effects of these knots and twists. Doubtless, this is associated with the degree and vigor of the peristalsis, but the physiology of the intestinal movements is still, in many respects, a closed chapter.

In the past, the subject of postoperative obstruction has been largely discussed from the point of view of the effect of drainage. There is no question regarding the objectionable reaction of abdominal drainage. It is manifest that a foreign body left in the peritoneal cavity must inevitably act as an irritant. Not only its actual presence, but the respiratory movement of the abdominal wall and the peristaltic activity of the intestine, increase the deleterious consequences of the drain. This point having been unduly emphasized, has, perhaps, led surgeons to show a tendency to discard drainage, or, at least, to reduce it to a minimum. A few years ago, this practice became almost perilous in its consequences, when the custom to close the incision in acute gangrenous and acute suppurative appendicitis, with small amounts of exudate, became general. This was but a natural reaction from the principle of so-called sequestration, when large quantities of gauze were inserted surrounding the field of operation. The gauze was permitted to remain, letting the house surgeon assume the responsibility, and, incidentally, the censure for its removal. This method of drainage, aptly called taxidermy by a facile writer, has been discarded. The small cigarette drain, or split rubber tube, is now the usual method of drainage. It is easily improvised, and apparently, causes a minimum amount of peritoneal reaction. One cannot leave this phase of the question, however, without speaking a word in favor of gauze. There are distinctive types of cases in which gauze drainage is indispensable; I refer, specifically, to those in which the ligation of the meso-appendix is insecure or uncertain, or in which hæmorrhage has taken place during the delivery of the appendix. Moreover, gauze drainage is imperatively needed in the cases associated with impending gangrene or perforation of the cæcum. Through its capacity to stimulate adhesions, gauze tends to localize the infection.

The method employed of treatment of the stump — simple ligation or inversion — seems to be immaterial. One should attain a degree of asepsis extreme as possible. Any extraneous leakage favors the development of plastic adhesive peritonitis. When alcohol and carbolic acid are used to sterilize the stump, care is needed to prevent accidental contact of the solutions with the intestine. Naturally, in a case demanding drainage, the element of peritoneal irritation and reaction is uncontrollable. Here the sequelæ of band formation, intestinal matting and kinking are inevitable, as no method exists which entirely obviates these objectionable end-results.

A possible cause of adhesion formation is suggested in the widespread use of iodine in the preliminary sterilization of the field of operation. It is known, in fact, has been experimentally proved, that iodine is a peritoneal irritant. The intestine, particularly, the

small intestine, should not come in contact with the skin. I use dry laparotomy pads to wall off the appendix. They are more apt to maintain their position when spread out flat and do not crumple to form a ball-like mass. They preserve a dry field and absorb the pus and blood with greater ease and rapidity. There is experimental evidence which tends to demonstrate that laparotomy pads soaked in hot solution are less liable to create intestinal adhesion; but, as the formation of intestinal adhesions is not clearly understood, and subject to many interpretations, this theoretical objection may be overlooked.

The symptoms of acute intestinal obstruction are so well-known, that it is needless to repeat them. Of course, the type of obstruction considered here, is the purely mechanical or dynamic type, usually due to a band or kink. The most common form of postoperative obstruction is concomitant with the extension of the infection to the peritoneum. This produces the most intractable type of intestinal paralysis. The underlying pathology is evident. The wall of the intestine is saturated with the toxins and products of the bacteria. As a result, the local neuromuscular mechanisms are poisoned and paralyzed. The administration of powerful cathartics, under these circumstances, is not only useless but stupid. There is a rare type of obstruction, due to a functional paresis, or, perhaps, inhibition of the intestinal musculature. This type responds readily to liberal doses of pituitrin. Eserin salicylate, widely heralded at one time as a panacea, is an uncertain drug, and moreover, known to depress the circulation. I have seen several instances when death promptly followed its use. It has been stated that one of the most important signs of intestinal obstruction is the rise in the leucocyte count. In order to estimate properly the value of this sign, it would be necessary to have the blood examination before, and a daily count following, operation. In a busy hospital, this procedure is not feasible. Moreover, as the blood count is modified by so many factors incidental to an operation, as hæmorrhage and infection, its significance is susceptible to various interpretations. A bimanual examination aids in the diagnosis. It occasionally happens that an incarcerated or strangulated loop may fall or even lie in the pelvis. Bimanual examination then discloses a tense cystic swelling behind the posterior fornix.

Intestinal obstruction is rarely so sudden in onset as to mimic internal hæmorrhage. Yet an acute strangulation of an intestinal loop may cause shock and collapse so severe as to suggest the diagnosis of internal hæmorrhage. In a woman who had been operated on by a colleague for chronic appendicitis and salpingitis, strangulation was so sudden that severe shock took place at once and collapse rapidly supervened. The traditional symptoms of internal hæmorrhage were clearly simulated. Yet, at operation, I found no evidence of hæmorrhage. A loop of ileum was strangulated beneath a pelvic peritoneal band.

Acute obstruction of the small intestine, particularly, when the obstructing force acts intermittently, is insidious in its effects. I have found it hard to determine the intrinsic gravity and seriousness of the condition. The error lies, unquestionably, in underestimation. One is apt not to intervene until the intestine becomes the seat of infarcts. The conclusion is unescapable that immediate operation is indicated. Caution must be exercised in calling a case subacute in character.

When the obstruction takes place during convalescence, the question arises whether one should enter the abdomen through the original incision. If this incision is still draining, or though primarily closed, has reopened from infection, the new incision should be placed elsewhere; otherwise infection may be transmitted to the central abdomen and peritonitis rapidly engendered. Ample room is needed to deal satisfactorily with the lesion. Naturally, if a short-circuiting operation is chosen, generous exposure is requisite. If a concomitant pelvic lesion is suspicioned, the lower extremity of the right rectus incision is curved downward and inward, forming a modified hockey stick incision. This extension permits a larger exposure of the pelvic organs and grants sufficient freedom for the proper operative treatment of the tubes. If the distention is severe, caution is exercised in divid-

ing the peritoneum, for the intestine may be firmly pressed against the anterior abdominal wall. One should endeavor to avoid evisceration, as the prolapse of the distended coils increases the likelihood of shock, entails excessive manipulation, and favors peritoneal infection. Evisceration is distinctly objectionable. It is a positive excitant to shock; in point of fact, nothing produces shock so quickly in dogs, as evidenced by physiologists in experimental animal work. In order to lessen the likelihood of the occurrence of shock, it is the custom to cover the protruded intestinal coils with towels of hot saline solution. This is done to lessen the loss of heat. Though this step is necessary under these circumstances, it introduces the principle of wet operating which is so productive of peritonitis. Moreover, there is not only the danger of losing or enclosing towels and sponges, but one finds that constant pressure from an assistant's hands is needed to prevent the intestine from sliding from the abdominal wall. A short primary incision decreases the possibility of evisceration; but, a generous use of laparotomy pads, rapidly introduced, is the best method to prevent the protrusion of the intestines.

The large intestine is palpated in a systematic manner. Beginning with the cæcum, the examining hand passes in sequence to the flexures and ends at the rectum. This is a crucial step. The large intestine is not easily mobilized, and can, only with difficulty, be brought to the margin of the incision for inspection. It is essential, however, to determine definitely the state of the sigmoid and the rectum. The technique thus outlined is followed when the small intestine is distended, for this inevitably proves that the obstruction is at a lower level. When a loop of small intestine is seen, collapsed and ribbon-like in appearance, the operator should grasp and follow it to the site of obstruction, which must, inevitably, be at a higher level. It is difficult, at times, to know whether one is passing up or down the small intestine. This can occasionally be determined by the direction and inclination of the mesentery, for the mesentery of the small intestine, it will be recalled, passes, in general, from above, downward, and to the right, across the vertebral column. If the surface of the mesentery can be seen, one can easily determine whether a twist or a torsion is present. A reddening of the peritoneum is most intense at the site of obstruction.

In the simpler cases the division of a band or the releasing of a kink may be curative. On the other hand, these minor procedures may not be sufficient to relieve the obstruction, or though the obstruction is relieved, distention persists. Following the surgical relief of an obstruction of the small intestine, it is not an uncommon experience for the patient to succumb with symptoms indicative of severe toxæmia. Despite the relief of obstruction, the complete technical success, and the evident immediate improvement, a complete change in the patient's condition may take place within a few hours. The exact mechanism underlying this form of postoperative death is not accurately understood. The usual explanation is that, following the relief of the obstruction, the highly toxic material dammed behind the obstruction passes quickly into the unobstructed segment, where its rapid absorption causes death. It is still a mooted question whether the cause of death is chemical or bacterial.

It is probable that active processes in the wall of the intestine may play a part in the mechanism. In operations for acute obstruction, involving the small intestine, it is a matter of general observation to note that the segment oral to the point of obstruction is usually markedly distended and the color greatly changed. The color, as a rule, is a cherry red, or perhaps, dark brown or black, according to the degree and state of the arterial or venous obstruction. These appearances are in marked contrast to the size and color of the aboral intestine. This segment is generally collapsed, resembling a flat tape; it is pale pink in color and void of contents. Keeping these two diverse conditions in mind, it is evident that when the obstruction is relieved, the contents of the oral segment pass rapidly into the collapsed bowel, the absorbing capacity of which must be augmented. While the relief of the obstruction is an advantage from the mechanical view-point, it

is patent that a possible injury may result, in that, the toxic material is permitted to flow to a fresh intestinal surface, where absorption is rapid and fatal. Thorough post-mortem studies are needed to explain these cases. At operation, one is struck with the numerous areas of dark discoloration on the wall of the distended intestine. It is possible that these represent infarcts, of greater or less extent, caused by an obstruction of the mesenteric arteries and veins. From the macroscopic examination of the intestine at operation, it is difficult owing to lack of time to decide whether this infarct is arterial or venous. No doubt exists that these lesions must be considered as possible factors in the sudden death of the patient.

The occurrence of sudden death is indeed so striking that in order to obviate this result, surgeons have advised the incision and drainage of the distended loop before the relief of constriction. From a practical view-point, the procedure is not always easy to accomplish. There constantly exists the danger of accidental contamination of the peritoneum, during the process of emptying a coil. A short-circuiting operation, might, conceivably, eliminate the danger of rapid absorption, provided the anastomosis was made to some part of the colon, for this part of the intestine appears to possess inherent means of defense against bacterial and toxic absorption, a function, no doubt, acquired through heredity, or explained by the fact that the toxic material is more quickly evacuated. It is in this connection that the operation of ileocolostomy is available.

The terminal ileum, if the site of adhesions, is apt to present a characteristic appearance. The last few feet of the intestine are folded in a more or less continuous pleated manner, the individual arms of the pleat being comparatively short. It is manifest that the matted condition should remain untouched and no attempt be made to disentangle the tortuous loops. An elaborate dissection would inevitably lacerate the intestine or injure a mesenteric vessel. Any operative manipulation would expose the patient to the dangers of peritonitis and hæmorrhage. If these accidents were of moment, a resection would be indicated. Moreover, a dissection of the adhesion would prove valueless, for, within a few hours, the process of agglutination would recur, resulting perhaps, in a form of adhesion more complicated than the original state. No attempt, therefore, should be made to dissect extensive adhesions of the terminal ileum. Another procedure must be employed. In the operation of ileotranscolostomy, there exists an ideal technical procedure for obstruction of the lower ileum, due to a matted, twisted or adherent ileum. The prevention of toxæmic absorption and the necessity of avoiding an extensive dissection of the terminal ileum present the two main indications for a short-circuiting operation.

Ileotranscolostomy signifies the union of the terminal ileum to the beginning of the transverse colon. The indication for this operation is furnished by an insuperable obstruction located in the terminal ileum, the cæcum, or the ascending colon. It obviates the performance of an enterostomy or a cæcal fistula. An enterostomy, though highly recommended by eminent surgeons, makes no general appeal. It is, admittedly, a makeshift. I refer, specifically, to the disadvantages accruing from the irritation of the skin and the loss of nutritive fluids in a patient already weakened and debilitated. The main objection consists in the uncertain technique. To secure the intestine to the margin of the peritoneum, is merely to invite the development of peritonitis. To draw the loop outside the abdomen, means a secondary operation, possibly a resection. To find and verify the lower ileum requires considerable handling. In my experience, opening of the bowel has caused collapse of but a few feet of intestine. Personally, I have discarded this practice, for its so-called advantages appear purely chimerical. The operation can be easily performed through a right rectus incision. As a rule, the ileum, at a point about six inches from the ileocæcal valve, can be apposed without undue tension or traction, to the first one-third of the transverse colon. It will be recalled, in this connection, that the transverse colon is exceedingly mobile, and that the weight of the attached omentum acts as a downward pulling force. The ileum, at two points, is

united with linen traction sutures to a longitudinal band of the transverse colon. It is often difficult during the performance of an operation for intestinal obstruction, from distention of the intestine, accurately to determine the location of the small intestine, selected to be opened. Naturally, if the band selected is the jejunum, or upper part of the ileum, there will exist grave danger to the patient from malnutrition and exhaustion, caused by the loss to the body of nutritive fluids.

In order to prevent the escape of the intestinal contents, occlusion is obtained by the use of gauze tapes. Though intestinal holding clamps with blades ensheathed in rubber tubing are widely used for this purpose, increasing experience proves that they are cumbersome and inconvenient, particularly during the necessary turning and manipulation of the intestine. Moreover, they have a tendency to slip and are difficult to apply with the proper degree of pressure. On the other hand, gauze tapes are usually available, but, if not, can be quickly improvised. They are easily applied. With a blunt nose hæmostat, the mesentery is pierced close to the intestinal border, the jaws of the clamp are partially opened, and a thin, flat tape passed through the hole. The tape is tied with a simple bow-knot which permits its ready release.

The anastomosis is of the antiperistaltic type. In order to make an isoperistaltic anastomosis, it is necessary to turn the ileum in a direction the reverse of its normal course. This step, consequently, would occasion a twist in the mesentery, and possibly cause an interference of the circulation of the mesenteric vessels. Moreover, there is a probability that so extreme a torsion would favor the occurrence of volvulus. The technique of the suture is the same as that of a lateral anastomosis. The method suggested by William J. Mayo, for posterior gastrojejunostomy, is, perhaps the best. The omentum, fortunately favorably placed, may be utilized in the protection of the suture line. By disposing it in front of the suture line, at the completion of the anastomosis, considerable security is granted.

In a young man with acute intestinal obstruction, caused by an occluding carcinoma of the cæcum, I performed an anastomosis, with immediate relief, between the ileum and the transverse colon. Several weeks following, intermittent attacks of abdominal pain hastened the secondary operation for the removal of the growth, which operation I had hoped, in order to improve nutrition, to postpone for a longer period. At this secondary operation, a large mass of the small intestine was found herniated to the right, beneath the loop passing to the colon for the anastomosis. The reduction was simple and did not interfere with the subsequent resection of the cæcum and ascending colon. The accident demonstrated, however, the need to obliterate any potential opening in the peritoneum, in the performance of a lateral anastomosis (short-circuiting) operation. It will be recalled that Arbuthnot Lane experienced a similar difficulty in his operation of ileosigmoidostomy, which to overcome, the small intestine is entirely eviscerated, in order to suture its mesentery to that of the descending colon. A remedy consists in approximating and suturing the ascending colon, or hepatic flexure, to the anastomosing loop. In case of a subsequent resection of the cæcum and the ascending colon, the outer end of the transverse mesocolon may be directly united to the divided mesentery of the ileum.

Appended are the author's personal cases. Case 5 is inserted because of its close relationship from a technical view-point.

CASE 1. Acute intestinal obstruction caused by a band strangulating the lower ileum. Appendectomy two years previous. J. P., age 16, admitted with the diagnosis of acute intestinal obstruction, December 24, 1913; discharged January 10, 1914. Two years ago the appendix was removed at another hospital. The present illness began three days ago with severe abdominal pain, situated mainly in the right lower quadrant. There was vomiting and obstipation. The abdomen was slightly distended. There was a soft mass in the right iliac fossa. The scar of a previous right rectus incision could be seen. Immediate operation. A right rectus incision disclosed an intestinal obstruction of the lower ileum. The distal end of the ileum was purple in color, thickened and distended. The mesentery was greatly swollen and presented several lacerations. A band, 2½ inches long and ¾ inches wide passed between the cæcum and the parietal peri-

toneum. The ileum was strangulated by this band. The band was ligated and divided. Hot towels applied to the ileum quickly restored the circulation. The abdominal wall was closed in layers. Primary union. Recovery.

CASE 2. Acute intestinal obstruction of the ileum following appendectomy. Ileocolostomy. Recovery. M. H., female, age 19, admitted, August 18, 1914. Discharged, September 26, 1914. Eleven months previous to admission an appendectomy was performed for acute appendicitis. The ligation method, with cauterization of the stump with phenol and alcohol, was used. The patient remained in the hospital 16 days. Primary union. Discharged cured. Since this operation she has been perfectly well, until about two weeks before admission, when she experienced severe and constant pain in the abdomen. One week before admission constipation was marked, cathartics and enemas failing to give relief. She vomited several times each day, and on the day of admission, fæcal vomiting was noted. On examination, symptoms of grave toxæmia were detected. The pulse was exceedingly rapid and the abdomen distended. No visible peristalsis; no mass felt. Operation on August 18, 1914. Right rectus incision. The small intestine was found greatly distended. Many adhesions existed around the terminal ileum. An attempt was made to separate these adhesions, but was abandoned because of the technical difficulty. A free loop of the ileum, immediately above the area of the adhesions was anastomosed to the transverse colon. The abdomen was closed with through-and-through sutures. The postoperative course was smooth until on August 24, sixteen days following operation, when nausea and constant vomiting began. The following day the abdomen became distended and the bowels could not be moved. On the 26th, the vomiting was constant, the abdomen distended, and the pain severe. The patient improved slightly the following two days. An X-ray showed an obstruction of the small intestine in the afferent loop. A secondary operation was performed August 29, 1914. The anastomosis was found in an excellent condition. A portion of the transverse colon was adherent to the small intestine, close to the anastomosis. The adhesion was divided and the obstruction relieved. Wound resutured. Primary union. Discharged cured.

CASE 3. Acute appendicitis with spreading peritonitis. Appendectomy. Acute intestinal obstruction. Enterostomy. Death. S. T., age 26, admitted, November 20, 1914, died, November 29, 1914. The present illness began with severe pain in the abdomen two days previous to admission. She has had two former attacks, one six months ago, and one two months ago. On examination, there were found the typical symptoms of acute appendicitis. A mass was felt in the right lower quadrant. An intermuscular incision. The appendix was about three inches long, gangrenous and perforated at the tip. There was considerable free pus with a marked fæcal odor. The patient did not do so well. The pulse increased in rapidity, became small, and the patient vomited constantly. On November 28, the distention was great, the obstipation complete, and the vomiting profuse. Immediate operation. Median incision. A kink was found in the ileum about six inches from the cæcum. The kink was relieved by dividing numerous adhesions. As complete stasis of the upper bowel existed, an enterostomy was done. The patient died twenty-four hours following operation.

CASE 4. Acute appendicitis with abscess. Drainage operation. Acute intestinal obstruction, from two constricting bands. Ileotranscolostomy. Recovery. J. B., admitted, November 20, 1916, discharged, February 2, 1917. Has had several previous attacks. The patient was well up to nine days prior to admission. The pain in the abdomen has become generalized, radiating to the right iliac fossa. The patient has vomited three times. No obstipation. On examination, there was felt in the right iliac fossa, a dense globular mass. Dullness could be elicited over the same area. There was considerable pain on palpation. Pelvic examination was negative. Right rectus incision. An appendicular cavity containing foul pus was entered. The appendix was not sought as it formed part of the wall of the abscess. The cavity was packed with plain gauze and the abdominal incision partially closed in layers. The patient did well for four days. On the fifth, the abdomen showed marked distention and hiccoughs appeared. The symptoms continued several days and were finally relieved by colonic irrigation. The wound edge, however, was widely opened. Twenty days following operation, distention and pain and visible peristalsis were noted. It was evident that symptoms of obstruction were present. Operation on December 15, 1916. Median incision. Small intestine greatly distended, especially the jejunum and upper portion of ileum. A band, ¼ inch thick, was ligated and divided. A second band was found and cut. The lower portion of the ileum was collapsed. In the right iliac fossa there were dense adhesions between the ileum and the cæcum. A distended loop of small intestine was isolated and anastomosed to the transverse colon. The abdominal wall was closed. An intravenous injection was given on the table. The patient made a slow but a constant recovery. Discharged, cured, February 2, 1917.

CASE 5. Volvulus of cæcum with Jackson's membrane. Ileotranscolostomy. Later resection of the cæcum, ascending colon and ileum. Age 31, admitted to hospital August 7, 1913. Family and personal history negative. The present illness began with severe cutting pain in the right side of the abdomen, and vomiting. On admission to the hospital, a mass could be felt in the right lower quadrant; rigidity of the recti and dullness on percussion, in the right iliac fossa. Temperature 99.4.° Pulse 80. Ether narcosis. Exploratory laparotomy. A large cystic mass was felt occupying the right iliac region

and the upper part of the pelvis. At first, it appeared like an ovarian cyst with a twisted pedicle. On closer examination, the cæcum, the ascending colon, and the terminal ileum were found intimately bound together and rotated in a longitudinal direction; in other words, a partial volvulus. On closer examination a membrane was found which passed down over the cæcum, covering and enclosing the appendix. This membrane also passed down over the terminal ileum. An attempt was made to free the ileum by dissecting the adhesions but it was given up for fear of wounding the small intestine. A short-circuiting operation was done. The ileum was divided; the oral end closed with four layers of sutures and a lateral anastomosis made with the beginning of the transverse colon. The aboral ileum was closed and lightly sutured to the lower end of the incision. No tension or dragging was necessary in order to bring the ileum to the colon. Uneventful recovery took place. On August 21, the ascending colon, the cæcum, and terminal ileum were removed in one mass. Complete recovery.

CASE 6. This patient had been ill thirty-six hours before admission, with the classical symptoms of acute appendicitis. Operation August 14, 1918. A short right rectus incision revealed a moderately inflamed appendix. It was removed by the ligation method and cauterization of the stump with phenol and alcohol. The post-operative course was smooth until the fourth day, when severe abdominal pain occurred. The pain rapidly increased in intensity and vomiting took place. Enemata were without result. In view of the presence of severe abdominal pain, vomiting and complete obstipation, an immediate operation was performed. A loop of ileum was found adherent to the cæcum. The adhesion was divided and the intestine liberated. Uneventful recovery.

CASE 7. A young married woman had had an appendectomy done the year before. A right rectus incision had been used. The method of treatment of the stump was not ascertained. The patient complained of severe abdominal pain. There seemed to be an element of hysteria present but the attending neurologist, Dr. Joseph Byrne, reported that he believed the pain to be of organic origin. Operation, February 2, 1918, revealed a loop of the ileum adherent to the parietal peritoneum. Uneventful recovery.

CASE 8. Mr. F., age 35, admitted to St. Francis Hospital, December 27, 1918. He was operated on seven years ago in Bellevue Hospital for acute, suppurative appendicitis. Drainage was evidently employed, for the appendix scar is broad. For the past six months he has suffered from gastric symptoms. Complains of pain after eating. No history of the vomiting of blood. Present illness: Today, he was taken suddenly ill with severe and agonizing abdominal pain and vomiting. The pain is referred to the central part of the abdomen. The patient appears pale and weak. The condition looks as if it were perforation of a duodenal ulcer, or a secondary obstruction due to the previous operation. The abdomen is rigid. Immediate operation. Right rectus incision. A small amount of clear fluid escaped from the peritoneal cavity. The transverse colon and the cæcum were contracted and empty A loop of the small intestine brought up was empty. A second loop was greatly distended and contained fluid. The surface of the intestine presented numerous areas of dark discoloration. Diagnosis: Acute intestinal obstruction. In the region of the previous operation, a thin band was found, which passed from the parietal peritoneum, in the region of the scar, upward and inward, to the convex border of an intestinal loop. This band compressed and completely obstructed a second loop of small intestine. The band was divided and excised. The abdomen was closed without drainage. Primary union. Discharged cured.

CASE 9. A young woman age 30, single, admitted to Fordham Hospital, March 18, 1919. An appendectomy had been performed, May, 1918. No drainage employed at that time. Since the operation, she has suffered from more or less abdominal pain and constipation. March 17, she was taken suddenly ill with severe abdominal pain, located in the right lower quadrant. She had been constipated for two days previous and had vomited several times during the day. On admission, the patient presented a right rectus incision, about three inches long. The abdomen was distended and there was more or less rigidity, particularly, in the lower half of the right rectus. A point of extreme tenderness was situated immediately over the scar. Temperature normal. Diagnosis: Acute intestinal obstruction. Immediate operation. Ether narcosis. Right rectus incision, four inches long, one inch internal to the old scar. Upon opening the abdomen, clear fluid escaped in a large amount. A loop of small intestine projected itself at once into the wound. It was distended and filled with gas and fluid. At the same time, a second loop of small intestine, completely collapsed, appeared in the lower angle of the incision. It was evident by the marked difference in the appearance of the two loops of intestine, that a complete obstruction existed. Upon pulling gently on the collapsed intestine the obstruction was reached. This was caused by a loop of the small intestine being firmly adherent to the parietal peritoneum, immediately behind the old incision. The point of adhesion was about 1¼ inches long and attached to the convex border of the intestine, in a direction corresponding to the long axis of the intestine. Separation of this adhesion tore slightly the peritoneal coat of the bowel. This laceration was repaired with two layers of interrupted linen. Further examination revealed a thickened band passing from the cæcum to the parietal peritoneum. This band was at least three inches long and appeared to be an extension of an appendix epiploica. Ligation and excision of the band. Closure of the abdomen without drainage. Complete recovery and discharge.

THE STATUS OF THE VESICAL SPHINCTER AFTER PROSTATECTOMY

By ERNEST M. WATSON, A.M., M.D., Buffalo, New York
From the James Buchanan Brady Urological Institute, Johns Hopkins Hospital, Baltimore, Maryland

THE functioning result of prostatectomy may candidly be stated as good in by far the majority of cases. The occasional instance in which this is not so may be due to one or more of several reasons. The two chief factors that should be considered in explanation of unsatisfactory function after prostatectomy are: (1) the incomplete removal of the obstruction, and (2) the too extensive trauma to adjacent parts incident to removal of the hypertrophied lobes. In this latter group the resulting condition of the sphincteric fibers about the vesical orifice and posterior urethra may be considered.

The part played by the internal or vesical sphincter and the external or urethral sphincter has long been a subject of much diversity of opinion. It is only during recent years that sufficient evidence has been brought forth to establish definitely which normally constitutes the closing muscle of the bladder. Finger (1) has consistently maintained that the internal sphincter is far too weak a muscle to withstand the pressure of urine and prevent its escape from a distended bladder. Likewise Ultzman (2) and Guyon (3) have shared the same opinion, i.e., that the vesical or internal sphincter gives away under marked bladder distention and that the posterior urethra virtually becomes a part of the bladder cavity; at this juncture the external sphincter or compressor urethræ muscle forms the closing point of the bladder. Rehfish (4), on the other hand, was one of the first to point out that the action of the external sphincter is really very slight. In his experiments he placed a catheter in the prostatic urethra of an individual with a distended bladder (beyond the external sphincter) and obtained no urine. When the patient voided, urine came both through and around the catheter and on stopping all urine ceased to flow. From this observation he concluded that the internal or vesical sphincter was the normal closing muscle of the bladder. The method of studying the bladder outline by means of collargol cystograms first introduced by Voelcker and Lichtenberg (5) has done much to settle our views as to which muscle normally forms the true urinary sphincter. The above observers found that in the normal bladder the shadow is always sharply delineated as an uninterrupted segment of a circle and no collargol escapes beyond the internal vesical sphincter into the posterior urethra even with a greatly distended bladder. The subsequent work of Leedham-Green (6), Barringer and MacKee (7), Uhle (8), Hyman (9), and others have amply confirmed this view. At the present time it is generally accepted that the internal sphincter marks the normal closing point of the bladder.

In prostatectomy whether by the suprapubic or perineal route there is always the possibility of a certain amount of trauma to the sphincteric fibers about the bladder orifice and posterior urethra. This is of varying extent dependent upon the size of the prostatic lobes removed, upon the care exercised in their enucleation and also upon the method of prostatectomy, i.e., suprapubic or perineal. Some observers, notably Wallace (10), go so far as to state that in marked hypertrophy the adenomatous mass sometimes works its way through and distends the sphincter to such a degree as to render it probably useless. If that is true the vesical sphincter is atonic in certain extreme cases even before operation is undertaken. Regarding the fate of the vesical sphincter after operation, Squier (11) is of the opinion that the internal sphincter remains intact and soon contracts to its normal caliber. Speaking of the loss of urinary control after prostatectomy Hagner and Fuller (12) state that the subject is a debatable question but is unquestionably due to the destruction of the muscle at the neck of the bladder (internal sphincter), in the prostatic urethra or in the membranous urethra. Hyman has recently given us a very conclusive study of the resulting changes at the bladder outlet following suprapubic prostatectomy by means of collargol cystograms. In a series of 38

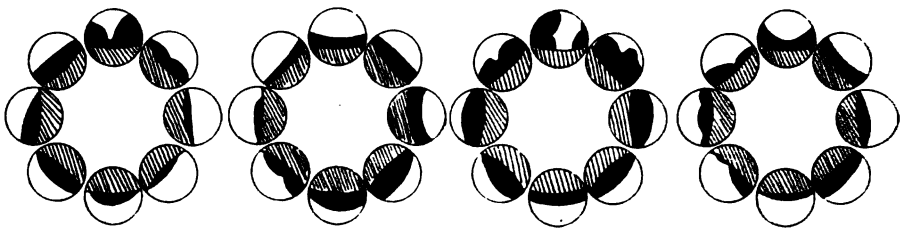

Fig. 1. Fig. 3. Fig. 5. Fig. 7.

Fig. 1. Case 1. Both lateral lobes are hypertrophied, the right more that the left. There is also some enlargement of the middle lobe.

Fig. 3. Case 2. The middle lobe is enlarged. The left lateral lobe shows only moderate hypertrophy and the right very little.

Fig. 5. Case 3. Both lateral lobes are markedly enlarged with margins somewhat irregular. The middle portion is also enlarged and continuous with the lateral lobes.

Fig. 7. Case 4. Slight median enlargement (form of a bar) with also a definite hypertrophy of both lateral lobes.

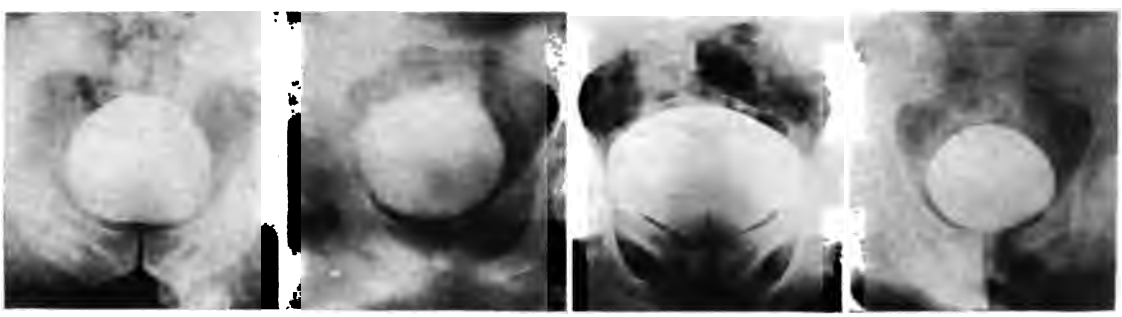

Fig. 2. Fig. 4. Fig. 6. Fig. 8.

Fig. 2. Case 1, roentgenogram No. 608. Cystogram taken three weeks after operation shows the bladder outline round with margins regular. The vesical orifice is regular and shows no dilatation of the internal sphincter. Residual urine 0; bladder capacity 400 cubic centimeters.

Fig. 4. Case 2, roentgenogram No. 536. Cystogram taken three and a half weeks after operation. The bladder shadow is rounded, and somewhat irregular. The bladder orifice is normal with no dilatation of the internal sphincter. Residual urine 0; bladder capacity 475 cubic centimeters.

Fig. 6. Case 3, roentgenogram No. 585. Cystogram taken three and one half weeks after operation. The bladder outline is rather wider than normal. The prostatic orifice is regular, no dilatation of internal sphincter. Residual urine 0; bladder capacity 200 cubic centimeters.

Fig. 8. Case 4, roentgenogram No. 530. Cystogram taken four weeks after operation. The bladder outline is normal. The orifice is normal and shows no dilatation of the internal sphincter. Residual urine 0; bladder capacity 375 cubic centimeters.

cases he found that 28 showed two distinct cavites after operation, the bladder cavity and continuous with it the one from which the prostatic adenoma was removed. In these cases the external sphincter marked the closing point of the bladder. Of the remaining 10 cases, a few showed a very slight funnel formation and the rest no change from the normal. He states that the internal sphincter has been destroyed by operation or its function so impaired that it could not have had any effect in retaining the fluid in the bladder.

From Hyman's study it is readily seen that though the internal or vesical sphincter is destroyed in the majority of cases of suprapubic prostatectomy, still no incontinence follows. Yet under normal conditions this same vesical sphincter is the muscle which holds the urine in the bladder. Occasionally we meet with an individual that has continued incontinence following the above type of operation. Our only explanation for this is that in removing the hypertrophied lobes an unwarranted amount of trauma has been done to the posterior urethra, i.e., its involuntary musculature, in addition to permanently injuring the internal sphincter. These involuntary muscles of the posterior urethra composed of two layers, an inner longitudinal and an outer circular, innervated by branches from the prostatic and cavernous plexus, inferior mesenteric ganglion and ganglia of the sympathetic, the same as

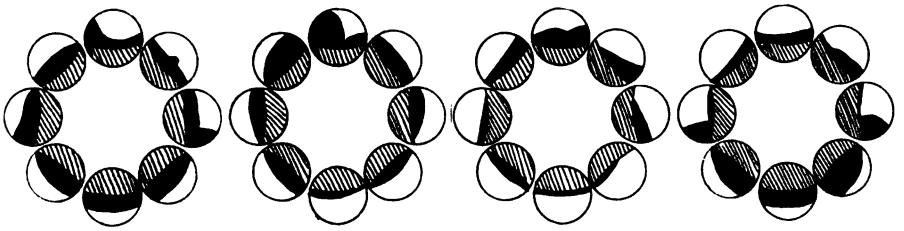

Fig. 9. Fig. 11. Fig. 13. Fig. 15.

Fig. 9. Case 5. Both lateral lobes are enlarged. The middle portion is definitely lobular as shown by the cleft between it and the left lateral lobe.

Fig. 11. Case 6. Marked right lateral lobe enlargement. The left lateral is moderately enlarged with only slight increase in size of the middle lobe.

Fig. 13. Case 7. Moderate enlargement anteriorly with very slight involvement of the lateral lobes. The middle portion is definitely hypertrophied.

Fig. 15. Case 8. Definite middle lobe hypertrophy with practically no involvement of the lateral areas.

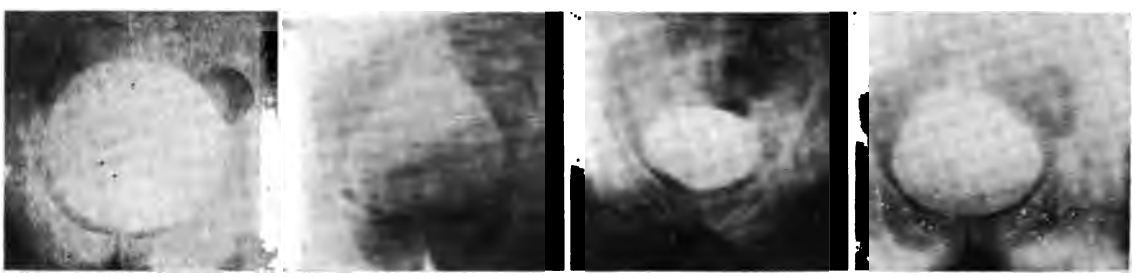

Fig. 10. Fig. 12. Fig. 14. Fig. 16.

Fig. 10. Case 5, roentgenogram No. 605. Cystogram taken five weeks after operation shows the bladder shadow round with margins slightly irregular. In the region of the prostatic orifice the shadow is normal and shows no dilatation of the internal sphincter. Residual urine 0; bladder capacity 375 cubic centimeters.

Fig. 12. Case 6, roentgenogram No. 588. Cystogram taken four months after operation. The bladder outline is somewhat larger than normal and pyramidal in shape. The vesical orifice is regular and shows no dilatation of the internal sphincter. Residual urine 0; bladder capacity 300 cubic centimeters.

Fig. 14. Case 7, roentgenogram No. 498. Cystogram taken five months after operation. The bladder shadow is oval in outline, with lateral margins somewhat irregular. The vesical orifice is normal and shows no dilatation of the internal sphincter. Residual urine 0; bladder capacity 175 cubic centimeters.

Fig. 16. Case 8, roentgenogram No. 515. Cystogram taken six months after operation. The bladder outline is somewhat oval, with margin regular. The vesical orifice is normal and shows no dilatation of the internal sphincter. Residual urine 40 cubic centimeters; bladder capacity 400 cubic centimeters.

the internal sphincter itself, unquestionably exert a very definite supporting action to the function of the vesical sphincter (13). Not every case of suprapubic prostatectomy has a permanently dilated vesical sphincter as was shown by Hyman. We know this must be so also from an occasional complete occlusion of the internal vesical orifice following suprapubic enucleation as has been reported by Gordon (14), Denslow (15) and others, and as has been once observed by the writer. In this complication the mucous membrane in its growth bridges over the internal orifice and completely occludes it which occurrence is hardly possible with a permanently dilated vesical sphincter. The action of the external sphincter, a purely voluntary muscle and directly under the control of the will, can hardly be accredited with the power of remaining tonically contracted for a period long enough to give normal urinary continence. The method of removing the prostate through the perineum, by reason of the approach through incisions in the posterior lobe, and oftentimes its successful enucleation without rupturing the bladder mucosa at all seemed to offer possibilities for observations on the vesical outlet under conditions quite different than after suprapubic prostatectomy.

For the purpose of this study 25 cases were obtained from the clinic of the James Buchanan Brady Urological Institute. The recent cases

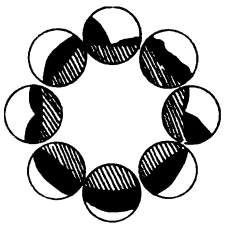

Fig. 17.

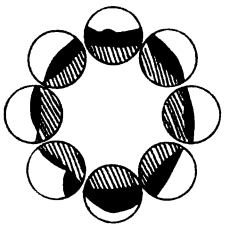

Fig. 19.

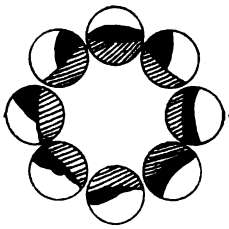

Fig. 21.

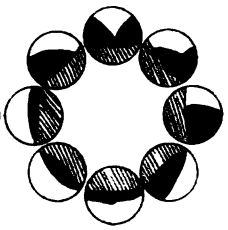

Fig. 23.

Fig. 17. Case 9. Mostly a middle lobe hypertrophy with moderate enlargement of the right lateral. Practically no left lateral lobe involvement.

Fig. 19. Case 10. Marked middle lobe hypertrophy with relatively little enlargement of either lateral lobe.

Fig. 21. Case 11. Somewhat distorted right lateral lobe hypertrophy. The middle portion is slightly elevated and the left lateral lobe only moderately involved.

Fig. 23. Case 12. Enlargement of both lateral lobes with also a median lobe hypertrophy.

Fig. 18.

Fig. 20.



Fig. 22.

Fig. 24.

Fig. 18. Case 9, roentgenogram No. 570. Cystogram taken eight months after operation. The bladder shadow is round in outline with margins regular. The vesical orifice is normal and shows no dilatation of the internal sphincter.

Fig. 20. Case 10, roentgenogram No. 540. Cystogram taken seven months after operation. The bladder outline is normal. The vesical orifice is regular and shows no dilatation of the internal sphincter. Residual urine 0; bladder capacity 375 cubic centimeters.

Fig. 22. Case 11, roentgenogram No. 607. Cystogram taken ten months after operation, shows a bladder somewhat oval with margins somewhat irregular. The region of the vesical orifice is smooth and shows no dilatation of the internal sphincter. Residual urine 0; bladder capacity 325 cubic centimeters.

Fig. 24. Case 12, roentgenogram No. 523. Cystogram taken eleven months after operation. The bladder outline is normal. The vesical orifice is regular and shows no dilatation of the internal sphincter. Residual urine 0; bladder capacity 300 cubic centimeters.

were obtained during the convalescence of the patients in the hospital. The older cases were taken from those living near by and the first 25 cases thus obtained will be reported in detail. The description of these includes the salient points in the rectal examination made by one of the staff on the patient's admission to the hospital, recording the amount of prostatic hypertrophy noted per rectum. This is supplemented by a cystoscopic examination and study of the prostate intravesically. In these examinations a cystoscope giving an inverted image was used, usually the Nitze photographic model. Only the descriptions of the prostate itself are taken from the records and each of these is supplemented by a drawing on a cystoscopic chart as suggested by Young (16) made at the time of examination graphically to represent the intravesical prostatic hypertrophy. The normal prostatic margin is here outlined in diagonal lines, while the superimposed pathological hypertrophy is recorded in black. The operation performed in every case has been Young's (17) conservative perineal prostatectomy done by Young or one of his staff. This operation in brief is a perineal dissection, through an inverted V skin incision, the patient being placed in the exaggerated lithotomy position. After cutting through the central tendon of the perineum, the membranous urethra is exposed, and with the bulb and external sphincter muscle drawn forward, is incised on a sound previously placed in the urethra. A prostatic

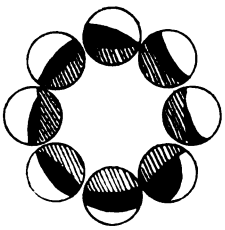

Fig. 25.

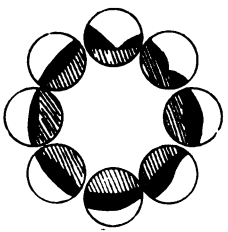

Fig. 27.

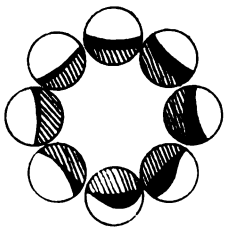

Fig. 29.

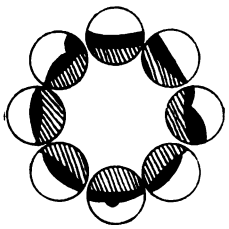

Fig. 31.

Fig. 25. Case 13. Globular median lobe continuous with a definite right lateral lobe hypertrophy. The left lobe is not enlarged.

Fig. 23. Case 14. "Collar" type of hypertrophy including both lateral lobes joined by an enlarged middle lobe.

Fig. 29. Case 15. Mostly a middle lobe enlargement with no enlargement of the right lateral lobe and only slight involvement of the left lateral lobe.

Fig. 31. Case 16. Globular middle lobe with slight hypertrophy of the right lateral lobe. The left lateral lobe is not appreciably enlarged.

Fig. 26.

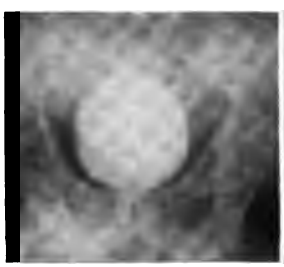

Fig. 28.

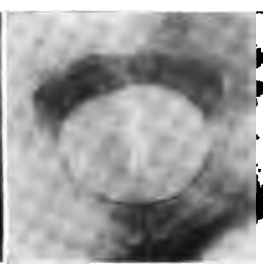

Fig. 30.

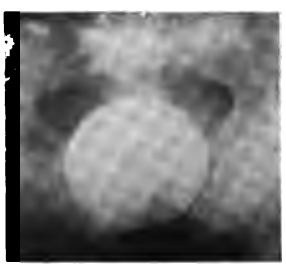

Fig. 32.

Fig. 26. Case 13, roentgenogram No. 517. Cystogram taken thirteen months after operation. The bladder is round in outline with margins regular. The vesical orifice is normal, and shows no dilatation of the internal sphincter. Residual urine 0; bladder capacity 300 cubic centimeters.

Fig. 28. Case 14, roentgenogram No. 511. Cystogram taken fourteen months after operation. The bladder is normal in outline. The vesical orifice is regular and shows no dilatation of the internal sphincter. Residual urine 0; bladder capacity 225 cubic centimeters.

Fig. 30. Case 15, roentgenogram No. 563. Cystogram taken fourteen months after operation, shows bladder outline normal with margins irregular. Region of vesical orifice smooth, no dilatation of internal sphincter. Residual urine 0; bladder capacity 400 cubic centimeters.

Fig. 32. Case 16, roentgenogram No. 544. Cystogram taken fifteen months after operation shows bladder outlines normal with prostatic margin smooth and there is no dilatation of the internal sphincter. Residual urine 0; bladder capacity 400 cubic centimeters.

tractor is then placed through the urethrotomy opening into the bladder and with this the prostate drawn up into the wound. The rectum is then pushed back and the prostate exposed covered only with the anterior layer of the fascia of Denonvillier. Two perpendicular incisions are then made through the capsule and posterior lobe, on either side of the mid line, avoiding in this way the ejaculatory ducts. Through these incisions the hypertrophied lateral and middle lobes are enucleated. A large catheter is then placed through the urethrotomy wound into the bladder and the lateral cavities of the prostate packed with gauze. The levator ani are then brought together with a single stitch and the skin approximated.

In every case is noted the beginning of interval urination, indicating from a functional standpoint the return of control in the internal sphincter. The study of the vesical orifice was made in these cases by means of cystograms taken some time subsequent to operation, i.e., three weeks to thirteen years. These were made after filling the bladder with 10 per cent thorium solution through a catheter as recommended by Burns (18) and studying the bladder outlines and particularly the region of the prostatic orifice for evidences of dilatation, as shown by the escape of the thorium solution into the posterior urethra.

CASE 1. G. M. G.— B. U. I. No. 5237, 63-W. Complaint: difficulty in urination.

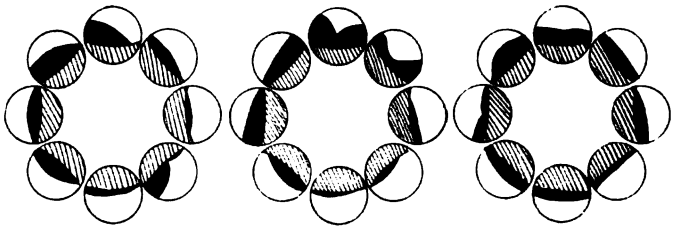

Fig. 33. Fig. 35. Fig. 37.

Fig. 33. Case 17. Definite right lateral lobe hypertrophy with also a globular middle lobe. No appreciable enlargement of the left lateral lobe.

Fig. 35. Case 18. Hypertrophy of both lateral lobes which masses are joined together by a small "median bar" formation.

Fig. 37. Case 19. Moderate hypertrophy of both lateral lobes which masses are joined by a small middle lobe enlargement.

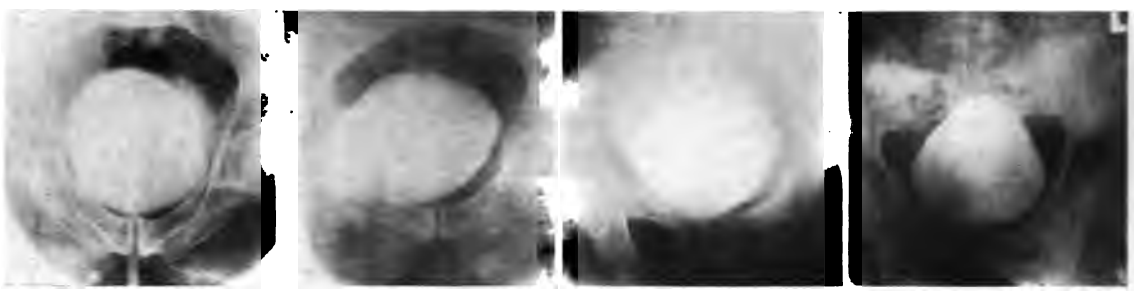

Fig. 34. Fig. 36. Fig. 38. Fig. 40.

Fig. 34. Case 17, roentgenogram No. 573. Cystogram taken sixteen months after operation shows bladder outline normal with margins regular. The region of the vesical orifice is smooth and shows no dilatation of the internal sphincter. Residual urine 0; bladder capacity 225 cubic centimeters.

Fig. 36. Case 18, roentgenogram No. 679. Cystogram taken twenty months after operation. The bladder outline is oval and regular. The region of the vesical orifice is sharply delineated and shows no evidence of dilatation of the internal sphincter. Residual urine 0; bladder capacity 350 cubic centimeters. In a cystogram of this patient taken fourteen months after operation the internal sphincter was found to be dilated. See roentgenogram, Fig. 38, No. 508.

Fig. 38. Case 18, roentgenogram No. 508. Cystogram taken fourteen months after operation. The bladder outline is oval and regular. The internal sphincter is dilated and posterior urethra is funnel shaped as shown by the escape of thorium into the prostatic urethra. Residual urine 0; bladder capacity 325 cubic centimeters. A later cystogram of this patient twenty months after operation shows the internal sphincter tightly closed, demonstrating that the internal orifice may return to normal even after a considerable interval of relaxation.

Fig. 40. Case 19, roentgenogram No. 525. Cystogram taken 21 months after operation, shows bladder outline oval with margins regular. Region of vesical orifice smooth, no dilatation of the internal sphincter. Residual urine 0; bladder capacity 300 cubic centimeters.

Rectal examination. The prostate is considerably enlarged, being a great deal broader than normal and more prominent toward the rectum. Its long diameter is also apparently increased. The median furrow is very shallow, almost obliterated. The right lobe is smooth, everywhere elastic, there being no suspicious areas felt, although it is impossible to reach the upper limit. The left lobe is somewhat irregular, but its consistency is everywhere elastic.

Cystoscopy. Residual urine. Retention. Bladder capacity 300 cubic centimeters. Study of the prostatic orifice shows a shallow cleft a little to the left of the midline anteriorly. The right lateral lobe is quite irregular and shows some intravesical enlargement. It is continuous with a fairly enlarged median which obscures practically all of the trigone. The median joins and is continuous with the left lateral lobe which is slightly enlarged. The trigone is normal in appearance except for some elevation and hypertrophy, there being a shallow pouch behind it.

Operation. Two lateral incisions were made into the posterior lobe. The right lobe was delivered in one piece. The left lateral and median were removed in one piece, the median being adherent to the left lateral. On exposing the surface of the prostate a small lobule was noted, which had also been noticed before operation. This was apparently a cyst measuring 4 millimeters in diameter. After removing the prostate the finger was introduced into the wound and the internal orifice felt to be intact. The sphincter was also felt. The patient voided at intervals on the fourth day after operation.

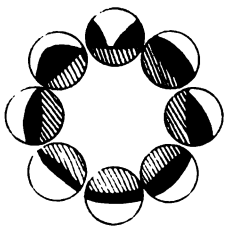

Fig. 39.

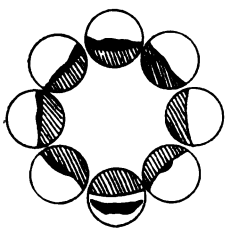

Fig 41.

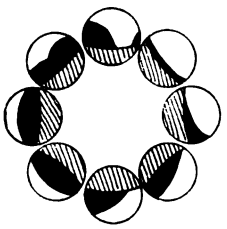

Fig. 43.

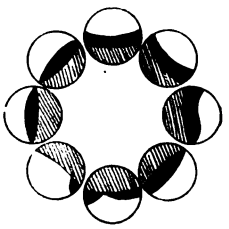

Fig. 45.

Fig. 39. Case 20. A triple lobe hypertrophy including the two lateral lobes joined by a considerably enlarged middle lobe.

Fig. 41. Case 21. Very slight hypertrophy of the right lateral lobe with a normal left lateral lobe. A definite enlargement of the subtrigonal or "Holmes" group of glands.

Fig. 43. Case 22. A large right lateral lobe confluent with a large middle lobe. The left lateral lobe is only slightly enlarged.

Fig. 45. Case 23. Hypertrophy of both right and left lateral lobes. These join an enlarged middle lobe which is bifurcated.

Fig. 42.

Fig. 44.

Fig. 46.

Fig. 48.

Fig. 42. Case 20, roentgenogram No. 543. Cystogram taken 2 years and 4 months after operation. The bladder outline is somewhat oval and margins very irregular. The vesical orifice is smooth and shows no dilatation of the internal sphincter. Residual urine 0; bladder capacity 425 cubic centimeters.

Fig. 44. Case 21, roentgenogram No. 522. Cystogram taken 2 years and 4 months after operation. The bladder outline is oval with margins regular. The region of the prostatic orifice is smooth and shows no dilatation of the internal sphincter. Residual urine 0; bladder capacity 300 cubic centimeters.

Fig. 46. Case 22, roentgenogram No. 575. Cystogram taken 4 years after operation shows bladder outline round with margins quite regular. The region of the vesical orifice is smooth and shows no dilatation of the internal sphincter. Residual urine 0; bladder capacity 250 cubic centimeters.

Fig. 48. Case 23, roentgenogram No. 526. Cystogram taken 8 years after operation shows bladder outlines oval with margins regular. The vesical orifice is smooth and shows no dilatation of the internal sphincter. Residual urine 25 cubic centimeters; bladder capacity 525 cubic centimeters.

CASE 2. T. D.— B. U. I. No. 5025, 63-W. Complaint: frequency, urgency with some burning on urination.

Rectal examination. Prostate is apparantly not much hypertrophied— is about normal width. Median furrow and notch shallow. The right lobe is possibly a little indurated and adherent, otherwise negative. Left lobe is the same, no nodules and no tenderness made out.

Cystoscopy. Residual urine 300 cubic centimeters. Bladder capacity 800 cubic centimeters. Study of the prostatic orifice shows no cleft anteriorly. There is slight rounding of the right lateral lobe, which is continuous with a fairly pronounced median lobe as shown in chart. On the left there is a slight depression between it and the left lateral— the left lateral lobe—is only slightly larger than normal intravesically.

Operation. On exposing the prostate it was found to be small and no larger than normal. The usual two incisions were made into the capsule and two small pieces of nonhypertrophied tissue removed from each lateral cavity. The finger was introduced into the bladder and there was found a flat slightly irregular lobe lying on the trigone. This was freed with the finger and subsequently delivered into the left lateral cavity. The lobe was flat and definitely hypertrophied and rather firmly adherent to the bladder wall beneath. This was undoubtedly an Albarran lobe and did not communicate with the lateral cavities, there being no hypertrophy of the lateral lobes nor in the suburethral or median lobe.

Patient voided at intervals on the seventh day after operation.

CASE 3. W. B. F.— B. U. I. No. 5136, 53-M. Complaint: Retention of urine.

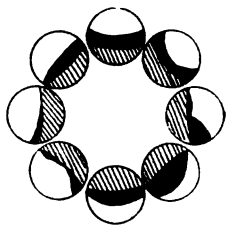

Fig. 47.

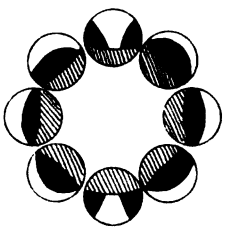

Fig. 49.

Fig. 47. Case 24. An enlarged middle lobe with very slight involvement of the lateral masses.

Fig. 49. Case 25. Two large rounded lateral lobes with practically no middle lobe. The cleft at the site of the median portion was unquestionably caused by the previous Bottini operation.

Fig. 50.

Fig. 52.

Fig. 50. Case 24, roentgenogram No. 585. Cystogram taken 12 years after operation shows bladder outline round with margins regular. The region of the vesical orifice is smooth and shows no dilatation of the internal sphincter. Residual urine 20 cubic centimeters; bladder capacity 300 cubic centimeters.

Fig. 52. Case 25, roentgenogram No. 590. Cystogram taken 13 years after operation shows bladder outline oval and margins regular. The region of the vesical orifice is smooth and shows no dilatation of the internal sphincter. Residual urine 125 cubic centimeters; bladder capacity 425 cubic centimeters.

Rectal examination. On rectal examination the prostate is definitely enlarged, firm, elastic and bulges moderately into the rectum. It does not suggest malignancy.

Cystoscopy. Bladder capacity 200 cubic centimeters. The vesical orifice shows a very peculiar condition. On looking anteriorly there is seen a very deep cleft. The tissue to the left of this cleft is lobular, œdematous and at first sight makes one think there is present a tumor. This, however, is continuous with smooth tissue which is denser and evidently the median portion of the prostate. On the right the same condition is present but to less degree. The condition is evidently two large intravesical lateral lobes joined by a median commissure, due to the fact that the mucous membrane of the median portion is markedly depressed.

Operation. On making incisions into the posterior capsule the posterior lamella was comparatively thick but not indurated. The left lateral lobe was first freed and removed and then the right lateral lobe and with the right lateral was removed also, a broad, flat, adherent median lobe, which lay beneath the trigone. The specimen was removed practically complete in two pieces; one small piece was subsequently removed which was part of the median.

The patient voided at half hour intervals on the third day after operation.

CASE 4. A. G. L.— B. U. I. No. 5018, 60-M. Complaint: pain, burning on urination. Occasional hæmaturia.

Rectal examination. Prostate not markedly enlarged per rectum. Median furrow well marked. Right lateral lobe is rounded, smooth and elastic. No induration made out. The left lobe is the same.

Cystoscopy. Residual urine 75 cubic centimeters; bladder capacity 375 cubic centimeters. No cleft anteriorly. Right lobe is a little more prominent and a little more rounded than normal. There is unquestionably a rounded median bar which obscures the anterior part of the trigone. The left lateral is a little more rounded than normal and it is evident that the lateral lobes are hypertrophied. With the finger in rectum and cystoscope in urethra the median part is a little thickened. The lateral lobes are definitely hypertrophied.

Operation. Prostate freely movable not markedly enlarged. The left lobe was easily enucleated through the incision into the left lateral cavity. The right lobe was exposed in a similar way. This lobe was removed without difficulty. The median portion was then pushed into the cavity on the left side. this was dissected free and finally delivered through the left lateral cavity. Digital examination showed a slight thickening of the suburethral and subtrigonal portions. This was removed by means of a curette through the left lateral cavity. The internal sphincter was rather tight and was moderately dilated with the finger. The patient voided at intervals four days after operation.

CASE 5. C. M. B.— B. U. I. No. 5141, 63-M. Complaint: retention of urine.

Rectal examination. The prostate shows a moderate grade of hypertrophy. The left lobe is smooth and elastic somewhat adherent above and externally. The right lobe is also smooth and elastic and adherent above and externally. The median notch and furrow are practically obliterated. No areas of stony hardness.

Cystoscopy. Retention, bladder capacity 350 cubic centimeters. Study of the prostatic orifice shows a broad cleft anteriorly, some convexity of the left lateral margin down to position L at which point is seen a cleft as shown in the chart, and projecting from the left lateral margin in this region there is a large rounded mass which has a somewhat mottled surface and in places seems to be rather cystic. The median portion of the prostate is definitely elevated so as to obscure practically all of the

trigone. There is also hypertrophy of the right lateral lobe.

Operation. After incisions into the posterior capsule on either side of the midline a larger lateral lobe was shelled out from the left side, this lobe measured about 5x4x4 centimeters. A similar lobe from the right side, probably containing some median lobe was also enucleated. The sphincter was felt to contract tightly around the finger and there was no further prostatic tissue obscuring the orifice.

The patient voided at intervals on the fifth day after operation.

CASE 6. J. M. W.— B. U. I. No. 4876, 60-M. Complaint: retention of urine.

Rectal examination. Finger immediately encounters a soft bulging mass, surface smooth, contour rounded. The prostate is very soft, quite elastic. One reaches with difficulty the base of the prostate and there is considerable increase in the breadth of the prostate.

Cystoscopy. Examination of the vesical orifice shows a good sized intravesical enlargement. Directly anterior there is a shallow cleft with a very large right lateral which projects very markedly into the bladder, particularly anteriorly. The right lobe is continuous with the median, there being apparently no cleft separating the lateral from median portion. The left lateral lobe is distinctly enlarged, projects into the bladder as a rounded edge, but it is very much smaller than the right lateral.

Operation. The prostate was exposed without much difficulty, and was only slightly enlarged. The lateral lobes were enucleated each in two or three pieces, being small. The median portion came away partly through the left lateral with the assistance of the finger in the bladder.

Examination showed a well preserved sphincter, a very small lobule about as big as a pea on the left side which we did not succeed in removing.

Patient voided at intervals on the seventh day after operation.

CASE 7. H. G.— B. U. I. No. 4576, 67-M. Complaint: painful and frequent urination.

Rectal examination. Prostate is flat, a little broader than normal. Median furrow and notch shallow. The left lobe seems to be definitely hypertrophied, being lobular but small and enlargement is present. On the right side the lobe is flat and if there is hypertrophy present it is small. Both lobes are adherent externally, both moderately indurated.

Cystoscopy. Residual urine 50; bladder capacity 200 cubic centimeters. Shows slight rounding anteriorly with a very shallow cleft just to the left of the mid line. There is practically no intravesical enlargement of either lateral lobe and the median is not intravesically enlarged. Further study shows slight rounding of the median lobe which may account for the residual. With finger in the rectum and the cystoscope in the urethra there is considerable median thickening with definite collar around the beak of the cystoscope, so that the outlines of the beak cannot be definitely felt.

Operation. The lateral lobes were small and were removed with difficulty. The left was removed first. It was the larger of the two and measured roughly about 2x1x½ centimeters. The right was smaller and more adherent. Both were hypertrophied. Attempt was made to remove a suburethral portion which lay beneath the ejaculatory bridge. Difficulty was encountered because of fibrous adhesions and it was decided to cut through the ejaculatory bridge above. The suburethral portion was peeled off from the mucosa apparently without injury to it. This showed definite hypertrophy and was somewhat larger than the two laterals together. The ejaculatory bridge was stitched back in position.

Patient voided at intervals on the fifteenth day after operation.

CASE 8. E. C. W. — B. U. I. No. 4626, 47-M. Complaint: frequency of urination associated with pain and burning.

Rectal examination. Bladder evidently considerably dilated and presses well back toward the rectum. The prostate is pressed downward by the greatly distended bladder and is apparently not much hypertrophied. Median furrow and notch shallow. Right lobe is slightly irregular, moderately indurated but not much enlarged. Left lobe is similar to the right.

Cystoscopy. Residual urine 1125 cubic centimeters; bladder capacity not obtained. No cleft anteriorly. Right lateral lobe is not enlarged, middle lobe enlarged in the shape of a sessile, rounded intravesical hypertrophy of fairly considerable size and a deep sulcus on either side, as shown. Most of the trigone is obscured.

Operation. The prostate was easily exposed without injury to the triangular ligament, external sphincter or rectum. Posterior surface was only moderately larger than normal and the lateral lobes were small showing very little evidence of hypertrophy. The median lobe which came away through the right lateral cavity and through a rent in the urethra was about 3 centimeters in diameter, very adherent and entirely intravesical. The sphincter was somewhat dilated but not injured.

Patient voided at intervals on the ninth day after operation.

CASE 9. J. S.— B. U. I. No. 4613, 66-M. Complaint: retention of urine. Hæmaturia.

Rectal examination. Prostate moderately enlarged, smooth, elastic, moderately indurated, not nodular, slightly adherent on each side.

Cystoscopy. Retention. Residual urine 175 cubic centimeters. Study of the prostatic orifice looking anteriorly shows a globular lobe as the right which is apparently a right lateral which is rounded and moderately hypertrophied intravesically. The median lobe is irregular and projects well into the bladder with a shallow sulcus between it and the right lateral. The middle lobe projects more to the left and there is a fairly deep sulcus between it and the left lateral lobe which does not seem to be intravesically hypertrophied.

Operation. Prostate was moderately enlarged and was removed with some difficulty owing to the deep adhesions. The median portion of the prostate came away partly through the right and partly through the left lateral cavity. Examination then showed a sphincter somewhat dilated, no remaining enlargement present.

Patient voided at intervals on the third day.

CASE 10. J. D. P. — B. U. I. No. 4578. 59-W. Complaint: difficulty in urinating, hæmaturia and painful voiding.

Rectal examination. Prostate is much broader than normal, does not project much into the rectum. The right lobe is drawn outward and down and adherent, smooth, moderately indurated, particularly along the outer edge, no nodules, no tenderness. The left lobe is also moderately enlarged, smooth, elastic, firmer than normal, slightly adherent externally.

Cystoscopy. Retention. Bladder capacity 200 cubic centimeters. Orifice is a little irregular, no cleft anteriorly. The right lobe is slightly rounded but not much intravesically hypertrophied. The median portion of the prostate is elevated in the shape of a median sized, fairly globular lobe with a fairly deep sulcus between it and the right lateral. Left lobe obscured by blood, apparently not much intravesically hypertrophied.

Operation. Prostate moderately enlarged. The right lateral lobe was easily removed in one piece measuring 1½x2x3 centimeters. The left lobe came away in numerous small pieces, curette being required. Part of this lobe projected anteriorly in front of the urethra. The intravesical portion of the prostate came away in two pieces, one apparently a globular lobe projecting from the right into the bladder but probably median in character and the other pedunculated intravesical lobe which projected into the bladder apparently from the left side. Internal sphincter was dilated but apparently not torn.

Patient voided at intervals on the seventh day after operation.

CASE 11. W. L. F. — B. U. I. No. 4490, 78-W. Complaint: frequency, pain and burning on urination.

Rectal examination. The prostate is moderately enlarged. Median furrow and notch are shallow. The right lobe is moderately hypertropied. The left lobe of the prostrate is similar to the right, slightly indurated, globular, moderately adherent. There is nothing to suggest malignancy.

Cystoscopy. Retention. Bladder capacity 250 cubic centimeters. Study of the prostatic orifice shows no cleft anteriorly. On looking upward to the right a globular mass probably a middle lobe appears and this is seen directly to the right and also posteriorly. The median portion is elevated in the shape of a sharp thin elevated ridge which is continuous with the left lateral lobe as shown. The left lateral lobe and anterior margin are both quite hyperæmic. Further study of the globular lobe, which is evidently pedunculated and largely intra-urethral would seem to indicate that is more right lateral than median—though it is so movable that it is difficult to tell just where it springs up.

Operation. Prostate was easily exposed. The lateral lobes were moderately enlarged and each removed largely in one piece. Two or three small lobules were removed later. The median portion of the prostate came away with the deeper part of the right lateral and was about 2 centimeters in diameter. Examination showed a sphincter which was hardly at all dilated. There was no fibrosis about it.

Five days after operation patient voided at regular intervals.

CASE 12. H. M. — B. U. I. No. 4399, 63-M. Complaint: retention of urine.

Rectal examination. Prostate is very much broader than normal, presents a considerable grade of hypertrophy. The median furrow is almost obliterated. The right lobe is prominent, with a slightly irregular surface, very elastic, much more so than is usually found in these cases; laterally it is quite adherent. The left lobe is about the same size as the right, it is irregular over its surface and more indurated than on the other side, although it is quite elastic.

Cystoscopy. Bladder capacity 400 cubic centimeters. Study of the prostatic orifice shows a very wide cleft anteriorly. Both lateral lobes are about equally enlarged intravesically and continuous with a median which obscures practically all of the trigone. Except for the cleft anteriorly there are no other clefts made out.

Operation. Prostate moderately enlarged. The lateral lobes were removed each in one piece, and the median lobe measuring about an inch in diameter was easily removed through the right lateral cavity. Internal sphincter well preserved though dilated.

Patient voided at intervals on the nineteenth day after operation.

CASE 13. A. B. — B. U. I. No. 4304, 52-M. Complaint: painful urination with occasional retention and increasing frequency.

Rectal examination. Prostate is considerably enlarged. Median furrow and notch wide and shallow. Right lobe is slightly irregular, moderately indurated, in some places more than in others, nothing suggesting malignancy, no adhesions. The left lobe is larger than the right, quite prominent, considerably enlarged, moderately indurated but still elastic, slightly adherent externally.

Cystoscopy. Residual urine 0; bladder capacity 250 cubic centimeters. Study of the prostatic orifice shows a globular median lobe, somewhat duplex in character, and more closely associated with the right than the left lateral. The left lateral is not intravesically hypertrophied.

Operation. Prostate was difficult to expose owing to a great deal of bleeding and marked adhesions. The prostate was moderately enlarged and the lateral lobes were removed each in one piece, measuring about 2x2x3.5 centimeters. The middle lobe came away through the right lateral cavity, being

smaller, about 1.5 centimeter in size. Examination showed the vesical sphincter slightly dilated but otherwise uninjured.

Patient voided at intervals on the sixteenth day.

CASE 14. J. H. L.— B. U. I. No. 4249, 67-W. Complaint: difficulty in urination— irritability of bladder.

Rectal examination. Prostate is a great deal broader than normal. Median furrow and notch deep and wide. The right lobe is moderately enlarged, irregular moderately indurated, considerably adherent externally; induration not of stony hardness, compressible and elastic on deep pressure. The left lobe is smoother than the right, globular, moderately enlarged and indurated, compressible on deep pressure.

Cystoscopy. Residual urine 60 cubic centimeters; bladder capacity 250 cubic centimeters. No cleft anteriorly. Prostate is enlarged in the shape of a collar hypertrophy, consisting of fairly large median bar continuous without intervening sulci with the lateral lobes. There is a peculiar anterior lobe which lies to the right of the median line when the handle of the cystoscope is elevated. There is no enlargement of the left lateral lobe. The median portion of the prostate is considerably enlarged, elevated, well above the trigone, so that it is difficult to see the ureters.

Operation. The prostate was easily exposed without injury to the external sphincter or triangular ligament. It was markedly enlarged. The left lateral lobe was removed almost completely in one piece. The right lobe was smaller. It was removed in several small pieces. The median portion of the prostate came away in two portions through the right and left lateral cavities. Examination showed that the sphincter was well preserved.

Patient voided at intervals on the fourteenth day after operation.

CASE 15. W. E. — B. U. I. No. 4281, 69-W. Complaint: difficulty and frequency of urination.

Rectal examination. The prostate is a little broader and more prominent than normal. Median furrow and notch are shallow and broad. The right lobe is slightly enlarged, moderately indurated and adherent, not nodular, not tender. Left same as right.

Cystoscopy. Residual urine 40 cubic centimeters; bladder capacity 175 cubic centimeters. No enlargement of the lateral portions. The median portion is elevated in the shape of a small rounded bar with a shallow sulcus on each side, as shown. The right lateral lobe is not enlarged. The trigone is obscured in its anterior third by the median bar. With finger in rectum and cystoscope in urethra, the median portion of the prostate is only slightly thicker than normal, the lateral lobes are very little larger than normal and not markedly indurated.

Operation. The lateral cuts were made through the indurated tissue, the lateral lobes were covered with a few small spheroids each lateral lobe being very little larger than normal and not encapsulated as usual. Each came away in two or three small pieces measuring 1½x2x2 centimeters in size. The median portion was removed partly through the left and partly through the right lateral cavity. A slightly sclerotic sphincter was made out and dilated with the finger and also with the glove stretcher.

Patient voided at intervals on the twenty-seventh day after operation.

CASE 16. A. Y.— B. U. I. No. 4220, 66-M. Complaint: hesitancy, slight frequency and urgency.

Rectal examination. Prostate moderately enlarged, consistency elastic, no areas of marked induration felt. No stony hardness felt. The right lobe seems slightly more hypertrophied than the left. Off to the side of the left lobe are felt one or two small shot lime masses which are apparently glands. These, however, do not seem particularly hard. Median furrow shallow.

Cystoscopy. Residual urine 40 cubic centimeters; bladder capacity 450 cubic centimeters. Study of the prostatic orifice shows at once the presence of a large globular median lobe. There is no cleft anteriorly. The right lateral lobe is somewhat rounded and between it and the median is a cleft of moderate depth. The left lateral lobe is not intravesically hypertrophied but there is a cleft between it and the median lobe. The median covers the entire trigone obscuring both ureteral orifices. On looking directly posterior a small globular swelling apparently attached to the enlarged median can be seen, probably a small prostatic lobule or thick walled cyst.

Operation. A suburethral lobe, spherical in shape and measuring 1 inch in diameter was first discovered. It was brought into the right lateral cavity and enucleated without difficulty. Examination showed no lateral enlargement. A large subtrigonal median lobe, however, was found. This extended quite far anteriorly both on the right and left side, and was densely adherent. This was removed only after considerable difficulty. Examination of the vesical orifice now showed the complete removal of all obstruction.

Patient voided at intervals on the twenty-eighth day.

CASE 17. E. F. S— B. U. I. No. 4212, 76-W. Complaint: retention of urine.

Rectal examination. Prostate is moderately hypertrophied, placed rather high. It is smooth, elastic, symmetrical. Median notch and furrow obliterated. Somewhat adherent externally and above; no areas of stony hardness made out.

Cystoscopy. Residual urine 700 cubic centimeters; bladder capacity 225 cubic centimeters. Study of the prostatic orifice shows intravesical enlargement of the right lateral and median portion, being in the shape of a rounded globular median bar.

Operation. Two lateral lobes each measuring 1x¾x½ inches were removed from their respective cavities. Examination showed the presence of an intravesical median lobe which extended laterally well up on the right side. By manipulating the prostatic tractor this lobe was brought into the

right lateral cavity, its mucous membrane stripped off and the lobe removed without much difficulty.

CASE 18. M. F— B. U. I. No. 4176, 60-M. Complaint: Burning and frequent urination.

Rectal examination. Prostate high, moderately hypertrophied in both lobes, both are symmetrical, smooth and elastic. Median notch and furrow distinctly made out. Both lobes of prostate adherent externally and at either upper pole. There are thick bands of adhesions growing out to lateral wall of pelvis on the left.

Cystoscopy. Residual urine 25 cubic centimeters; bladder capacity 350 cubic centimeters. Study of the prostatic orifice shows a cleft anteriorly which contains a small lobule between the two lateral lobes. The rest of the prostate is hypertrophied in the shape of a collar which includes both laterals and median bars. No cleft between the lateral and median.

Operation. The right lateral lobe was first removed, it was very adherent and friable and came away in six small pieces, the weight of which was 9 grams. The left lobe, slightly larger than the right was next removed. Considerable difficulty was encountered here, owing to the gland being so friable, it was removed in five pieces and the total weight was 12 grams. The prostatic tractor was now removed and the finger introduced into the bladder through the urethra. It lay very deep, the tip of the finger just passing within the internal sphincter. The margins of the orifice were grasped with clamps and the structure pulled down into the wound. Examination showed the presence of a small middle lobe and also some tissue anteriorly. This was removed, the total weight of median and anterior portions being 4 grams.

Patient urinated at regular intervals on the twenty eighth day after operation.

CASE 19. R. H. B— B. U. I. No. 4111, 55-W.. Complaint: urinary retention. Hæmaturia. Pain.

Rectal examination. Prostate enlarged and bulging per rectum, left lobe elastic, regular in outline, moderately indurated and adherent. Right lobe is the same. Median furrow and notch shallow. Right lobe is somewhat larger than left and quite adherent externally.

Cystoscopy. Retention. Bladder capacity 600 cubic centimeters. Study of the prostatic orifice shows no cleft anteriorly. The right lateral is hypertrophied and between it and the median is a shallow cleft. The left lateral also enlarged though not as marked as the right, and is continuous below with the elevated median lobe.

Operation. Two lateral incisions were made. Prostate was very fixed in position, being very small. Right lobe removed and afterward the left and the median in one piece. Sphincter contracted well about the finger. The patient urinated at intervals on the fourteenth day after operation.

CASE 20. J. J. J.— B. U. I. No. 3795, 73-W. Complaint: frequency of urination, poor stream, nocturnal dribbling.

Rectal examination. Prostate is a peculiar small globular hypertrophy. Median furrow and notch shallow. The right lobe is larger than the left, quite prominent, smooth rounded elastic, but distinctly firmer than normal, few adhesions— no marked tenderness. Left lobe flat and probably broader than normal, smooth, firmer than normal, elastic, few adhesions, no nodules.

Cystoscopy. Residual urine 170 cubic centimeters; bladder capacity 310 cubic centimeters. Cystoscope shows a collar hypertrophy with a fairly large lateral lobe and median bar continuous with the two laterals elevated considerably above the trigone, the upper half of which is visible. Behind the trigone is a fairly deep pouch.

Operation. Two lateral incisions made one on each side of the ejaculatory bridge. Two rather large lateral lobes about 4x5 centimeters in size removed. A large median lobe was removed with the curette in two pieces. The internal sphincter was felt to be intact.

Patient voided at intervals on the fourth day after operation.

CASE 21. J. B.—B. U. I. No. 4388, 60-M. Complaint: frequency and burning on urination.

Rectal examination. Right lobe moderately hypertrophied, firm but not hard, very little evidence of hypertrophy. Left lobe about the same, but just to left of median furrow there is a hypertrophied spheroid about 1 centimeter in diameter moderately firm but not hard.

Cystoscopy. Residual urine 40 cubic centimeters; bladder capacity 300 cubic centimeters. Apparently not much hypertrophy except a thickening of the glands in the subtrigonal region, but with very little bar formation. No clefts seen. A marked rounding of the laterals.

Operation. Prostate was seen to be very small. Two lateral incisions made through the posterior lobe. A small spheroid was removed from each lobe and a median enlargement came away with the right lateral piece. The internal sphincter seemed to be greatly dilated.

Patient voided at intervals on the sixth day after operation.

CASE 22. G. W. S.— B. U. I. No. 3208, 66-M. Complaint: retention of urine.

Rectal examination. Prostate considerably enlarged, smooth, globular, uniform. Both lobes about equally enlarged. Consistency of the right lobe is distinctly firmer than normal, but still compressible; nowhere of stony hardness. Left lobe smaller, consistency being distinctly indurated but not of very marked degree. Upper end of prostate cannot be passed. Median furrow and notch shallow.

Cystoscopy. Residual urine 85 cubic centimeters; bladder capacity 600 cubic centimeters. Cystoscope rides up over a considerable median enlargement and the urethral length is greatly increased. Cystoscopy shows at once a very large right lobe projecting far into the bladder. Left lobe does not seem to be very much hypertrophied. Median lobe runs at

once into the right lateral lobe. Median lobe evidently in the shape of a bar.

Operation. Prostate was easily exposed. It was considerably enlarged and enucleated without difficulty, but apparently completely. The sphincters were apparently not injured.

Patient voided at intervals on the twentieth day after operation.

CASE 23. E. C.— B. U. I. No. 1174, 52-M. Complaint: frequency and burning of urination. Difficulty in starting stream.

Rectal examination. Prostate is considerably enlarged, much broader than normal. It is a little irregular, in places soft, at others hard, nowhere of dense induration. Median furrow and notch very indefinite. There are no adhesions, no tenderness.

Cystoscopy. Residual urine 230 cubic centimeters; bladder capacity 500 cubic centimeters. The cystoscope shows moderate enlargement of both lateral lobes and a large median lobe which is divided into two folds with a deep cleft between them as shown in the drawing. When the beak of the instrument is turned down and the shaft depressed you see the right lobe. The right portion of the median and the left portion of the median as shown.

Operation. Two incisions were made on each side of the urethra and two lateral lobes enucleated with the finger— a small median lobe was also removed in this case.

Interval urination started on the fifth day.

CASE 24. M. R— Gen. No. 16296, 54-M. Complaint: retention of urine.

Rectal examination. Prostate much enlarged and bulging posteriorly into rectum. Symmetrical— fairly hard, not tender. Palpating finger cannot reach over it.

Cystoscopy. Cystoscopy attempted, but unsatisfactory on account of sharp hæmorrhage from prostatic urethra. With cystoscope in the urethra and finger in the rectum the median mass is found to be quite considerable.

Operation. The two lateral lobes were pressed out through the incision by blunt dissection. Median enlargement was turned to the right and pressed out last.

Patient voided at intervals on the twenty-first day after operation.

CASE 25. W. F. S— B. U. I. No. 173, 55-M. Complaint: retention of urine.

Rectal examination. Prostate considerably enlarged and both lateral lobes and median furrow is broad. Notch at upper end obliterated. Lateral lobes bulge moderately toward the rectum but their upper ends can be easily reached by finger; consistence, soft, elastic, contour smooth and no nodules present.

Cystoscopy. Cystoscope shows a large rounded intravesical outgrowth from each lateral lobe; between these two the urethra is compressed laterally, and with the cystoscope looking downward a narrow chink is seen between the two enlarged lobes in the urethra. Superiorly the lobes do not press together so tightly. The left lobe is larger and projects farther into the bladder than the right. In the median portion there is a thin fold of mucous membrane which connects the two lateral lobes. The hypertrophy therefore consists of two bulging lateral lobes which compress the urethra between them.

Operation. The capsule was divided on either side of the median furrow by means of blunt dissection and the finger; the enormously hypertrophied lateral lobes of the prostate were stripped out. Each lobe seemed lobulated and was removed in several pieces, each piece in turn being drawn into the wound by aid of the tractor and stripped out. The lobes were very adherent to the bladder mucosa where the Bottini operation had been previously done.

Patient voided at intervals on the thirteenth day after operation.

SUMMARY OF CASES

1. G.M.G.— B.U.I. No. 5237. Cystogram No. 608, 3 weeks after operation. Internal sphincter closed.
2. T.D.— B.U.I. No. 5025. Cystogram No. 536, 3½ weeks after operation. Internal sphincter closed.
3. W.B.F.— B.U.I. No. 5136. Cystogram No. 585, 3½ weeks after operation. Internal sphincter closed.
4. A.G.L.— B.U.I. No. 5018. Cystogram No. 530, 4 weeks after operation. Internal sphincter closed.
5. C.M.B.— B.U.I. No. 5141. Cystogram No. 605, 5 weeks after operation. Internal sphincter closed.
6. J.M.W.— B.U.I. No. 4876. Cystogram No. 588, 4 months after operation. Internal sphincter closed.
7. H.G.— B.U.I. No. 4576. Cystogram No. 498, 5 months after operation. Internal sphincter closed.
8. E.C.W.— B.U.I. No. 4626. Cystogram No. 515, 6 months after operation. Internal sphincter closed.
9. J.S.— B.U.I. No. 4613. Cystogram No. 570, 8 months after operation. Internal sphincter closed.
10. J.D.P.— B.U.I. No. 4578. Cystogram 540, 7 months after operation. Internal sphincter closed.
11. W.L.F.— B.U.I. No. 4490. Cystogram No. 607, 10 months after operation. Internal sphincter closed.
12. H.M.— B.U.I. No. 4399. Cystogram No. 523, 11 months after operation. Internal sphincter closed.
13. A.B.— B.U.I. No. 4304. Cystogram No. 517, 13 months after operation. Internal sphincter closed.
14. J.H.L.— B.U.I. No. 4249. Cystogram No. 511, 14 months after operation. Internal sphincter closed.
15. W.E.— B.U.I. No. 4281. Cystogram No. 563, 14 months after operation. Internal sphincter closed.
16. A.Y.— B.U.I. No. 4220. Cystogram No. 544, 15 months after operation. Internal sphincter closed.
17. E.F.S.— B.U.I. No. 4212. Cystogram No. 573, 16 months after operation. Internal sphincter closed.
18. M.F.— B.U.I. No. 4176. Cystogram No. 679, 20 months after operation. Internal sphincter closed; Cystogram No. 508, 14 months after operation. Internal sphincter dilated.
19. R.H.B.— B.U.I. No. 4111. Cystogram No. 525, 21 months after operation. Internal sphincter closed.
20. J.J.J.— B.U.I. No. 3795. Cystogram No. 543, 2 years 4 months after operation. Internal sphincter closed.
21. J.B.— B.U.I. No. 4388. Cystogram No. 522, 2 years 4 months after operation. Internal sphincter closed.
22. G.W.S.— B.U.I. No. 3208. Cystogram No. 575, 4 years after operation. Internal sphincter closed.

23. E.C.— B.U.I. No. 1174. Cystogram No. 526, 8 years after operation. Internal sphincter closed.
24. M.R.— Gen'l. No. 16296. Cystogram No. 585, 12 years after operation. Internal sphincter closed.
25. W.F.S.— B.U.I. No. 173. Cystogram No. 590, 13 years after operation. Internal sphincter closed.

SUMMARY

From a study of the cases herewith reported it is seen that following perineal prostatectomy the internal or vesical sphincter returns to its normal tone and function in every instance. This takes place within a few weeks as demonstrated by the accompanying cystograms. From clinical observations we are led to suspect an even earlier return of function judging from the establishment of definite intervals of urination a few days after prostatectomy has been performed with a perineal urethrotomy in the membranous urethra back of the internal sphincter as it should be. Not infrequently urine is voided at three and four hour intervals at this period both through the urethra and through the urethrotomy wound, while during the intervening time the patient is perfectly dry. These rather long periods of complete continence could not occur under the above conditions if the vesical sphincter were not functioning normally.

One interesting case, 18, in which the vesical sphincter was found closed and functioning normally twenty months after operation (cystogram No. 679), at an earlier examination fourteen months after operation was found to be dilated (cystogram No. 508), with the posterior urethra funnel-shaped and virtually forming a part of the bladder cavity. During this time the patient had periods of incontinence which, however, had entirely disappeared at his last examination. In referring to the operative note in this case it is seen that the operator states of the vesical orifice: "— it lay very deep, the tip of the finger passing just within the internal sphincter. The margins of the orifice were grasped with clamps and the structure pulled down into the wound." This procedure undoubtedly injured the sphincter to a degree sufficient to account for the long delay in its restoration of function. It is of interest to note in this instance, however, that even after an interval of over a year there was complete recovery of function and anatomical relationship.

My thanks are due Hugh H. Young, director of the James Buchanan Brady Urological Institute, for his kindness in placing the above material at my disposal, and to Charles A. Waters of the Department of Roentgenology for his painstaking care in making the roentgen plates.

BIBLIOGRAPHY

1. FINGER. All. Wien. med. Ztschr., 1893.
2. ULTZMAN. Die Krankheiten der Harnblase. Stuttgart. 1890.
3. GUYON. Lécons chirigue sur les maladies des voies urinaires. 1896.
4. REHFISH. Virchow's Arch. f. path. Anat., etc., Berl., 1897, No. 150.
5. VŒLKER and LICHTENBERG. Muenchen., med. Wchnschr., 1905; Der Anatomischen Gesellsch., 1905; Beitr. z. klin. Chir., 1907, lii.
6. LEEDHAM-GREEN. Brit. M. J., 1906, xi, 297.
7. BARRINGER and MACKEE. Tr. Am. Urol. Ass., 1912, vi.
8. UHLE. Tr. Am. Ass. Genito-Urin. Surg., 1913, viii.
9. HYMAN. Ann. Surg., 1914, lix, 544.
10. WALLACE. Prostatic Enlargement. London: 1907.
11. SQUIER. Surg., Gynec. & Obst., 1912, xv, 599.
12. HAGNER and FULLER. Surg., Gynec. & Obst., 1913, xvii, 110.
13. WATSON. J. Urol., 1917, i, 543.
14. GORDON. Surg., Gynec. & Obst. 1916, xxii, 620.
15. DENSLOW. J. Am. M. Ass., 1918, lxx, 441.
16. YOUNG. Johns Hopkins Hosp. Reps., 1905, xiii.
17. YOUNG. J. Am. M. Ass., 1903, xli, 999.
18. BURNS. J. Am. M. Ass., 1915, lxiv, 2126.

THE ACUTE ABDOMEN[1]

By F. GREGORY CONNELL, M.D., F.A.C.S., Oshkosh, Wisconsin

THE acute abdomen might seem a subject, upon which, at the present time, but little remains to be said; but increasing experience seems to justify its careful consideration and division into two classes as follows:

1. Those that may be remedied by abdominal operations.

2. Those that may not be remedied by abdominal operations.

The first class is, of course, in the majority; as a general rule, it does not necessitate differential diagnosis, as it makes no difference to the patient, and it makes no difference in the first steps of the treatment, whether the cause of the trouble is a ruptured appendix, a perforation of a gastric or duodenal ulcer, a cholecystitis or one of the many other causes of such symptoms, as long as the condition is remediable by an operative procedure, subsequent to laparotomy. The symptoms call for exploratory laparotomy which is automatically followed by the proper diagnosis and in turn rational therapeusis. In such cases the problem is absurdly simple, and the fate of the patient rests not so much with the operator who repairs the lesion as with the physician who first sees the case, and suspects serious damage.

The repair of reparable damage of the abdominal viscera (granting the presence of surgical judgment on the part of the operator) is comparatively simple; on the other hand the cure of peritonitis, the result of such damage, is difficult.

This class of cases, comprising the majority of abdominal emergencies, will not be discussed, because the principles of treatment are well outlined, and the conditions are recognized and discussed freely in textbooks and current literature.

The second class demands attention, serious consideration, and emphasis, because these conditions are but rarely differentiated from class 1, with the resultant ineffectual, if not detrimental, line of treatment. The lesions may be divided into (1) extraperitoneal which may simulate intra-abdominal disease; and (2) intraperitoneal (non-operable) which may simulate operable conditions.

The extraperitoneal lesions may include thoracic, retroperitoneal, nervous, and others.

THORACIC LESIONS

Pneumonia. Confusion between the early stages of pneumonia and acute appendicitis is not so uncommon as might be expected. The general statement is frequent that pneumonia may, in its early stages, be mistaken for acute abdominal complaints, but detailed reports of such instances are not frequent. Some cases of pneumonia, after operation for acute appendicitis, in which the operative findings are not quite characteristic, might possibly have been cases of obscure and undetected pneumonia, before operation. Postoperative pneumonia should be lobular not lobar.

One of the reasons for this confusion is that often during the first 24 hours of pneumonia the pulmonary symptoms and physical signs in the chest may be entirely absent.

Pneumonia of the right lower lobe can, especially in children, by irritating the tenth, eleventh, and twelfth intercostal nerves produce pain, rigidity and tenderness in the right side of the abdomen which accompanied by the fever, leucocytosis and vomiting of the pneumonia will closely simulate an acute appendicitis.

In pneumonia, the abdominal tenderness is less characteristic and usually situated higher, the resistance is less marked but may be the same as in appendicitis. On the other hand severe inflammation of the appendix may cause diminution of the respiratory excursion and in the breath sounds of the right lower lobe, in this way tending to make the diagnosis still more difficult.

The important point is to *think* of the possibility of pneumonia giving rise to the symptoms in question, notably in children

[1] Read before the Scranton Academy of Medicine, March, 1917.

with rapid respiration and pulse, high temperature and dilatation of the alæ nasi. Such symptoms call for a careful chest examination, not confined to the *anterior* aspect. In most cases, such an examination settles the diagnosis.

Diaphragmatic pleurisy. Capps has found that the *visceral* pleura is not sensitive to pressure or scratching of a wire, that such irritation of the *parietal* pleura produced pain, but that irritation of the outer margin of the diaphragmatic pleura supplied by the lower six intercostal nerves is followed by reflex pain in the hypochondrium, and often in the abdominal wall as far down as the navel or even the groin, and when the central portion is irritated the pain is referred by the phrenic to the neck by the third and fourth cervical nerves. Capps presents a study of 61 cases of diaphragmatic pleurisy: 39 of right side, 21 left side, 1 bilateral, in which referred abdominal pain occurred in 54 cases and there was referred neck pain in 33 cases or about 50 per cent.

While aspirating fluid from the pericardial sac in a recent case I was able to cause pain in the left side of the neck by irritating the lower portion of the pericardial sac.

The following 23 mistaken diagnoses were made in the series of 61 cases of diaphragmatic pleurisy: 9 appendicitis, 6 cholecystitis, 2 perforation of ulcer of the stomach, 2 liver abscess, 1 peritonitis, 1 renal calculus, 1 infectious lumbago, and 1 brachial neuritis.

Capps' conclusions are as follows:

The skin and muscles of the abdomen are more sensitive to pain in referred pleural pain than in visceral disease. This is best elicited by the pinching of the wall and the scratching of the skin.

The cutaneous reflexes are more lively in referred pain than in visceral disease, as a rule.

Deep pressure, with the flat surface of the fingers, is well borne in referred diaphragmatic pleural pain, while it elicits a dull, deep pain when applied over an inflamed organ, e.g., an appendix or gall-bladder.

Evidences of respiratory infection are usually present in diaphragmatic pleurisy; such as a cough, expectoration, herpes of lips, sore throat, high leucocytosis, rapid respiration, etc.

Appearance of a sharp, definitely localized pain in the neck, on the same side as the abdominal pain, often reveals the true condition, since it points to irritation of the phrenic nerve.

The referred pain in the neck and abdomen are usually induced, or aggravated, by cough and deep respiration.

Nausea and vomiting are more constant in visceral abdominal inflammation, but may be pronounced in diaphragmatic pleurisy.

Hiccough is not a common symptom in diaphragmatic pleurisy contrary to the current belief. It was present only 5 times in 61 cases. It is more often seen in visceral disease of the abdomen than in diaphragmatic pleurisy.

CARDIAC LESIONS

Angina pectoris is characterized by epigastric pain after eating or after exertion, and is relieved by belching; because of these characteristics the milder types of the disease are frequently mistaken for attacks of acute indigestion, and more rarely, and under rather unusual conditions, the more severe attacks may be confused with acute abdominal conditions. In angina pectoris the pain is due to exertion, not food, the blood pressure is usually high, and the heart rarely normal. The attack is accompanied by great fear or apprehension of approaching death. The pain is usually referred to the left arm, but may be referred to the back, epigastrium, testes, leg or right arm.

The appearance of the facies is characteristic, the features are sunken, the face pale and cold, with an expression of agony, anxiety, and distress, quite similar, on superficial examination, to the "facies hippocratica."

Emphasis should be laid on the resemblance of some of these cases to surgical accidents. The sudden onset, with pain over the lower sternal and epigastric region, the nausea and vomiting, the tympany, the feeble pulse, ashy color, cold sweat and other signs of collapse, make one think of certain acute abdominal conditions.

Where there is arteriosclerosis, enlarged heart, a history of previous angina, typical radiation of the pain in the neck and arm, the diagnosis will not be so difficult as where these suggestive aids are lacking.

Pericarditis. In acute pericarditis the symptoms are those of an acute infection. The disease is characterized by pain in the region of the heart. This pain may be referred to the abdomen, to the region of the stomach, gall-bladder, or appendix. A careful examination will usually reveal tumultuous heart

action: dyspnœa, cyanosis, dysphagia, friction rub, and with effusion, enlarged cardiac dullness. Fluoroscopic examination is of great value.

Fussell has seen pericarditis mistaken for appendicitis, but states that the mistake rarely occurs in the reverse way. (I have been called to operate upon a case for cholecystitis in which the examination revealed a pericarditis with friction rub.)

RETROPERITONEAL LESIONS

Renal. Among the renal conditions that might be confused with intra-abdominal lesions should be mentioned (1) stone, (2) Dietl's crises, (3) unilateral hæmatogenous infection of the kidney, the septic infarct of Brewer, (4) uræmia, (5) perinephritic abscess, and (6) pyelonephritis. The most frequent is stone. Renal colic is characterized by severe pain, usually calling for morphine, with tenderness in the loin, and vesical tenesmus, with nausea or vomiting and hæmaturia, with no increase in temperature or leucocytosis. The symptomatology of renal lithiasis has been very exhaustively studied by Braasch, who found great variations in the usually accepted signs and symptoms. For example, typical pain and tenderness in the kidney region was present in only 117, of 251 cases: in 26 pain was general abdominal; in 30, pain referred to gall-bladder; in 32, pain referred to lower abdomen; in 56, pain referred to both sides of abdomen; in 40, pain referred to affected sides of abdomen; in 16, pain referred to non-affected side of abdomen. Thus one is justified in concluding that the pain of renal lithiasis may be very atypical.

Braasch, likewise found that hæmaturia was present in 141 of 251 cases, or 56 per cent, a rather indefinite percentage, and, to make matters worse, in 500 consecutive routine examinations in cases without symptoms of renal trouble, 146 showed microscopic blood in the urine.

Cabot, in 150 cases of renal and ureteral stone, found the urine persistently normal in 14 per cent, hæmaturia absent in 32 per cent.

The presence of microscopic blood in the urine may be due to pathology in any part of the genito-urinary tract. The mere fact that there is an acute abdominal inflammation may cause microscopic hæmaturia.

The contact of an acutely inflamed appendix with the ureter or bladder may give rise to blood in the urine. Eising reports two such cases of pericystitis complicating acute appendicitis, and I have seen two cases in which symptoms suggestive of appendicitis, with a mass in the pelvis, were relieved by the removal of bloody urine from the distended bladder. Laparotomy disclosed a gangrenous appendix in contact with the fundus of the bladder.

Such cases are not uncommon, and too much stress must not be placed upon the presence of a few red blood-cells in the urine, as indicative of renal colic.

The X-ray failed to reveal urinary calculi in 10 to 15 per cent of Cabot's and in 11 per cent of Braasch's cases.

Confusion between abdominal conditions and kidney stone was emphasized by the late Maurice Richardson who wrote an extensive article, the last before his death, on "The Error of Overlooking Ureteral Stone Under a Diagnosis of Appendicitis," and Hugh Cabot reported 157 cases of stone in the kidney and ureter, in 26 of which unnecessary abdominal operations had been performed. These operations were distributed as follows:

Appendectomy without relief	10
Exploratory laparotomy	7
Fixation of kidney	4
Operation for gall-stones	1
Decapsulation of kidney	1
Salpingo-oophorectomy	1
Suprapubic cystostomy	1
"Adhesions"	1
	26

And in a recent contribution, Braasch states that 143, or practically one-third of the total number in his series of cases of nephrolithiasis had had previous laparotomies performed elsewhere for relief of pain: 83 with stone in right kidney; 55 with stone in left kidney; 5 with stone in both kidneys; twenty-one patients with stone in left kidney had had previous operations on the appendix or gall-bladder.

Dietl's crises is characterized by symptoms that simulate renal colic, or intra-abdominal

disease, such as severe abdominal or lumbar pain, nausea, vomiting, distention, rigidity, with enlarged tender kidney, and variable bladder symptoms with a usual absence of temperature and leucocytosis. This condition is supposed to be due to an acute obstruction of the ureter by kink or torsion of a floating or wandering kidney. It was first described by Dietl in 1864, and its frequency is decreasing with more painstaking examination and more accurate diagnosis.

Acute hæmatogenous infection of kidney, acute septic infarct of kidney. Brewer, in 1906, analyzed 13 cases, and found 11 in women and 11 on the right side. Chill at onset was present in 4. Sudden high temperature, 104°, at first examination was found in 12. In three cases there were marked remissions; in others, the temperature was constantly high. In all cases the pulse was rapid, over 120. In 12 the chief complaint was abdominal pain, in 4 in the right iliac region. The costovertebral angle was tender in all. Muscular rigidity was a frequent finding as was leucocytosis. Microscopic blood was found in the urine of all but one.

In these cases, with the sudden onset, severe general pain, localizing on the right side, vomiting, with profound constitutional toxic disturbances and few definitely renal symptoms, the condition is often mistaken for intra-abdominal infection.

In Brewer's 13 cases, an abdominal incision, under mistaken diagnosis, was made three times. In Cobb's 8 cases, the same mistake was made in 3 instances.

That this type of case is not as uncommon as was previously supposed, is shown by the fact that Mason in 1912 collected 28 cases, and Cunningham in the same year reported 8 additional cases.

In a personal case, 2 days after an unsuccessful abdominal operation, nephrectomy was followed by a satisfactory outcome.

Disease of the suprarenal capsule. Addison's disease, or syndrome, is characterized by (a) physical and mental inertia, (b) pigmentation, (c) gastro-intestinal symptoms.

In the last we find anorexia, nausea, vomiting, constipation and later diarrhœa, enteroptosis, pain in lumbar and iliac regions, with slight rigidity and tenderness on palpation in right iliac fossa, which may, at times, be attributed to intra-abdominal disease.

Study of the suprarenal gland has taught that there is a *cortical* portion that concerns the sexual function; and a *medullary* portion that seems to have a double function; one concerning pigmentation, and the other, in the production of suprarenin or adrenalin. This medullary portion consists of connective tissue, nerves and cells, the most important is the chromaffin cell. This chromaffin is found in the medullary portion of the adrenal, in the sympathetic ganglia, in the substance of the epididymis, and all these combined constitute what is known as the chromaffin system, which seems in some way, as yet not understood, to be intimately connected, either as a hypo- or hyper-function, with these atypical abdominal complaints.

Addison's syndrome, because of the gastro-intestinal symptoms, in which the pain at times may be severe, may be confused with intraperitoneal disease.

The symptom-complex characteristic of Addison's syndrome is not uncommon. The pigmentation will be found very frequently with the other two, if it is intelligently looked for. One meets this syndrome frequently in cases that come under observation with a diagnosis of chronic appendicitis, but one hesitates to diagnose Addison's disease.

That there may be *acute* pain in this class of cases is beyond question; and Tice cites a case in point. The diagnosis of Addison's syndrome and *appendicitis* was made. In a "subsequent note" it is stated that there was exacerbation of the appendicitis which led to transfer to the surgical service and laparotomy was performed, at which the findings were negative, except for "an old adherent appendix" which was removed. Death occurred the following day and an autopsy was not permitted. This "exacerbation of the appendicitis" was evidently a misinterpretation of the symptoms.

Brodnitz calls attention to the "violent intestinal colic occurring in attacks, failure of the peristalsis, and isolated intestinal distention." And Ebstein says that in the terminal stages there is excessive vomiting,

abdominal pain and constipation, the abdomen is retracted and the walls tense, the pulse becomes small and there exists *in toto*, the picture of peritonitis.

Hæmorrhage, or suppuration, may lead to sudden destruction of the suprarenal glands. This condition is but rarely recognized, was first described by Virchow, and is characterized by very severe symptoms together with peritonitis which ends rapidly in death.

Uræmia. In certain cases of uræmia, acute abdominal pain, distention, with severe vomiting and fever may be present. Differential points are urine examination, blood pressure, hypertrophy of heart.

The acute abdominal pain of nephritis particularly of the hæmorrhage type, has been emphasized by Osler.

Perinephritic abscess. Perinephritic abscess may simulate peritoneal disease, but careful history and examination will usually prevent confusion.

Pyelonephritis. Pyelonephritis is undoubtedly a cause of pain in the right side of abdomen, that may lead to erroneous diagnosis. In 90 cases of proved pyelonephritis entering Cook County Hospital, in 1917, Culver found that the entrance diagnosis included almost every possibility. In two personal cases in which symptoms persisted after appendectomy, catheterization of the ureter showed a pyelitis of the right kidney.

Genito-urinary tract in the male. Inflammation of the epididymis, prostate gland, or the seminal vesicles may cause pain and tenderness in the right iliac fossa, as likewise may small hernia.

Orthopedic conditions. Orthopedic conditions such as caries, spondylitis deformans or hypertrophic arthritis of the vertebræ, subluxations of the sacro-iliac or lumbosacral articulations, or the presence of an abnormal transverse process of the fifth lumbar vertebra, are all of importance in a consideration of atypical abdominal pain. They usually give rise to chronic symptoms but, occasionally may cause acute pain, and other symptoms that may simulate intra-abdominal lesions. They may be suspected by limitation of motion of the spine, with local tenderness over vertebræ or lumbar regions.

R. C. Cabot reports 17 cases of vertebral tuberculosis (Pott's disease) that came to autopsy; only 4 were recognized in life. He says that knuckle in the spine, pressure signs, muscular rigidity, limitation of motion, and secondary abscess are not common.

The important diagnostic point is X-ray examination which may show erosion, arthritis or deformity; but these roentgenograms must be given careful study before arriving at conclusions, as the normal X-ray picture is not yet definitely accepted.

Cotton in a very concise article on "Fractures of the Transverse Processes of the Vertebræ," makes the statement that, "within a year a certain amount of loose literature has appeared concerning fractures of the transverse processes of the vertebræ. It does seem to me that we should refrain from diagnosis, or at least from prognosis and cures, and even from expert testimony until we have more facts."

In 22 cases classed as fracture of the transverse process of the vertebra, in the X-ray Department, of the Boston City Hospital, Cotton was able to find a fracture in only 12, and after briefly abstracting these cases and presenting outline drawings of the roentgenograms in 6, of which the traumatic origin was doubtful, concludes that "anomalies in this region are frequent; often ill shown by average routine X-ray plates, are not always properly interpreted, and are apt to be called fractures.

"More than that, it is suggested that real fractures of the transverse processes may not improbably unite by fibrous union without persistent symptoms, and be chanced on later.

"There is no doubt that real fractures of the transverse processes of the vertebræ in the lumbar region do occur; probably not very infrequently. How important they are, does not yet appear, nor will their importance be manifest until other series are studied, and some of them carried on, to investigation of end-results."

Subperitoneal or retroperitoneal cellulitis or infection. Acute abdominal pain in the right lower quadrant, rapidly spreading and becoming general, with tenderness, rigidity,

increased pulse rate, elevation of temperature often with a chill and leucocytosis, during the course of an attack of influenza with pharyngitis or tonsillitis, may be streptococcal infection of the subperitoneal areolar tissue, secondary, or metastatic, to a primary focus in the pharynx or tonsil, in which the appendix is invaded merely as an incident in the course of the general infection. As the appendix, in these cases, is not a causative factor its removal will have but little influence upon the course of the disease. Such cases call for careful differentiation; if they are retroperitoneal streptococcal infections, appendectomy is not of much avail. Many such cases continue to death after operation by general bacteræmia, pneumonia or nephritis.[1]

As radical an operator as Murphy was, he advocated a non-operative treatment, noting that such cases fared better without operation, that the resistance of the patient was lowered by futile operation, and that a fatal termination was liable to follow instead of cure. He says: "The greatest stress should be laid on the differential diagnosis between intra- and subperitoneal infections, and in addition, the fact should be forced on the profession that subperitoneal cellulitis is not in the range of operative treatment, and that the proper treatment of intraperitoneal peritonitis is, primarily, a surgical one. Cases of subperitoneal cellulitis are not remedied at all by opening and draining of the peritoneal cavity, as this does not attack the field of infection, namely the subperitoneal cellular tissues."

Anderson cites a number of cases of acute appendicitis as a sequel of tonsillitis and he emphasizes the fact that this type of case is prone to be atypical.

A personal case of this type, in abstract, is as follows:

A. R., servant, female, single, age 17 years. The patient had always had "stomach trouble" but it was never sufficiently severe to warrant consulting a physician.

On April 9, 1911, she had tonsillitis, with the usual symptoms; onset of menses the day before. On April 11, she had pain, swelling and tenderness of the right knee. On April 12, the knee became worse and she had the same symptoms in the right ankle and both wrists, which necessitated her ceasing work, going to bed and calling a physician. Dr. Neil Andrews made a diagnosis of polyarthritis secondary to tonsillitis. On April 13, the joints improved, but she complained of abdominal pain, nausea and vomiting. These symptoms with temperature persisted and on April 16, the pain and tenderness in the abdomen became localized in the right iliac fossa. Examination revealed tenderness and rigidity of right rectus. The thigh was flexed and extension caused pain in the right iliac fossa. Pulse 130 and temperature 103° F. Leucocytosis 20,000. Diagnosis: acute appendicitis.

Operation revealed visceral and parietal peritoneum congested, blistered, swollen, œdematous; straw colored free fluid; pelvic and abdominal viscera negative; appendix congested, similar to other peritoneum with no adhesions, mesenteriolum infiltrated, mesenteric glands enlarged and a pericolic membrane. Typical appendectomy was performed, followed by the closure of the abdomen without drainage.

The convalescence was very stormy; for four weeks the temperature remained high, with elevation to over 103° F. with new joint manifestations. The abdominal wound healed *per primam*. Since then the patient has been in perfect health, and examination in December, 1916, confirmed the report. In my opinion the recovery in this instance was in spite of, and not because of, the removal of the appendix.

J. S. Evans presents the result of observation upon the relationship between pyogenic infections of the upper respiratory tract and the morbidity curve of acute appendicitis, during fifty-nine months, among the students of the University of Wisconsin and evidently encountered no such cases. During this period there were 236 cases of acute appendicitis in over 16,000 students, 214 of which were primary attacks. In 86 per cent there were observed definite primary infections of the upper respiratory tract. The primary respiratory infection preceded the acute appendiceal attack on an average of 16 days, the minimum interval being 1 day, the maximum 60 days.

In studying the morbidity curve of appendicitis from month to month we find that at eight periods during the six years there were marked increases above the expectant rate. Since similar increases above the expectancy of acute upper respiratory infections attended these same periods, we consider the evidence

[1] The above was written before the recent pandemic of influenza and subsequent experience has seemed to emphasize the importance of this point.

of an etiologic relationship between the two diseases the more definite. The total number of cases in these eight periods was 113 and the total number of days involved was 226, or an average of one case of appendicitis every two days. This is in such sharp contrast to both the average monthly rate and to the expectant rate for each of the 59 months that one is justified in considering each group of cases as a definite epidemic.

Evans suggests: "In this group of 113 cases we were dealing with micro-organisms of the streptococcus group possessing a definite tropism for the appendix."

The condition of subperitoneal inflammation subsequent to puerperal infection of the uterus, and designated as "dry-peritonitis," has been recognized for some time.

Peritoneal operations and radical procedures in such circumstances have been so unsatisfactory that they are no longer considered, and conservative measures are now indicated.

Enlarged mesenteric lymph glands, usually tubercular, as in "tabes mesenterica" or abdominal Hodgkin's disease, in the right iliac fossa at the lower end of the root of the mesentery, may be palpable through the abdominal wall. Such a finding on palpation, in conjunction with acute abdominal symptoms and temperature may lead to confusion with an acute appendicitis.

Carson, in a consideration of "The Clinical Aspects of Tuberculous Mesenteric Glands," recommends the removal of any caseating or calcareous glands, which he admits may be rather a tedious procedure; and that it is not devoid of danger is shown by a personal case.

Exploratory laparotomy was performed upon a child of 6 years with a temperature, right iliac mass, pain and tenderness, and a history of so-called "chronic appendicitis," to settle a diagnosis of tuberculosis or appendicitis. At operation the appendix was found to be normal and was not removed. The mesenteric lymph glands were enlarged and one was removed for diagnosis. This was followed by meningitis and death.

Enlarged mesenteric lymph glands are frequent in cases of so-called chronic appendicitis, but in a careful histologic study of many such glands, I have been unable to find any evidence of tuberculosis.

NERVOUS LESIONS

In a study of *abdominal* pain, it may be of interest to make a comparative review of pains within the *cranial* cavity.

According to Fussell, headaches may be due to (a) reflex irritation; (b) toxæmia, infectious or chemical; (c) circulatory disturbances; (d) neuroses; (e) organic diseases of the brain, its membranes, or skull (the brain is insensitive and pain is due to involvement of the meninges either actually or by pressure); (f) indurative or muscular, due to the pressure of rheumatic nodules in the muscles of the scalp or neck; (g) neuralgia or neuritis.

With this formidable and confusing array of possible causes of pain in the head, one might well pause and consider before jumping at a conclusion without careful investigation of the possibilities in cases of pain in the abdomen.

The nerves of the abdominal wall are as follows: anterior divisions of the lower six intercostal (dorsal) nerves, called the abdominal intercostals. (The twelfth dorsal is larger and communicates with the iliohypogastric branch of the first lumbar, and the hypogastric branch of the first lumbar nerve.)

The *twelfth dorsal* nerve leaves the spinal canal below the last dorsal vertebra and rib, running at first behind the psoas muscle and in front of the quadratus lumborum. It pierces the transversalis and passes between it and the internal oblique, *two inches above the iliac spine*, in a downward and inward direction to the edge of the rectus, where it pierces the sheath and runs behind it to about the middle of the belly of the muscle. It pierces the muscle and the anterior rectus sheath, some branches becoming cutaneous and supplying the skin below the umbilicus. It also supplies branches to the transversalis, the internal and external oblique, the rectus and the pyramidalis muscles.

The *hypogastric branch* of the first lumbar nerve, runs between the transversalis and internal oblique, *about an inch above the crest of the ilium*; it continues downward and inward parallel to the twelfth dorsal, pierces the internal oblique about an inch in front of the anterior superior iliac spine and lies about

half an inch above the inguinal canal under the aponeurosis of the external oblique; pierces the aponeurosis of the external oblique an inch and a half above the external inguinal ring, becomes cutaneous, and supplies the skin above the pubes below the level of the twelfth dorsal. It gives off branches to the transversalis, oblique, and pyramidalis muscles.

Neuritis and neuralgia. Neuritis and neuralgia are differentiated clinically, but most neuralgias are probably due to a mild perineuritis.

In neuralgia, the pain is sharp shooting and paroxysmal limited to the course of a nerve, and is made worse by peripheral irritation. In neuritis, the pain is constant, burning or boring, and worse at night; with tenderness over the course of the affected nerve and aggravated by pressure; there may be trophic changes, with anæsthesia, paralysis or atrophy.

A localized neuritis or neuralgia of one or more of the nerves of the abdominal wall might be characterized by pain, varying in intensity of boring or stabbing character along the course of the nerve and its distribution, with local tenderness and pain on pressure or motion. Elevation of temperature is rare, and constitutional symptoms slight. There may be anæsthesia, tactile sensation lessened though pain sense increased; paræsthesia with numbness, tingling or formication; atrophy or paralysis, with absence, exaggeration or diminution, of reflexes.

Such disturbances, if they exist in the nerves of the abdominal wall and there is reason to believe that they do, have been given but little consideration, and demand study, because they have undoubtedly led to erroneous diagnosis. Such a group of symptoms with a crop of vesicles is classic in herpes zoster. Head and Campbell conclude that herpes zoster is a specific infective disease in which the virus has an affinity for the nervous system, particularly the ganglia, and considers the disease as an acute posterior poliomyelitis, in contradistinction to acute *anterior* poliomyelitis. Rosenow concludes that this disease is due to a streptococcus having elective affinity for the ganglia and posterior roots.

Herpes zoster of the face and upper intercostals is recognized, and comparatively frequent; but, of the lower intercostals and the first lumbar, if as frequent, is but rarely recognized. The location of the pain and symptoms often lead to a diagnosis of intra-abdominal disease and the hot applications which are frequently applied may cause one to misinterpret the presence of vesicles. Such cases have undoubtedly been operated upon for acute appendicitis. The occurrence of "zoster" of the viscera may no longer be questioned, as such cases are cited in the literature, and the knowledge of such a possibility adds greatly to the difficulties and uncertainties of proper interpretation of the significance of acute abdominal pain.

A local neuritis near the abdominal wall, which, if imitated in the nerves of the right iliac fossa, would cause great confusion is the "meralgia paræsthetica" which is well recognized, and a definite clinical entity. It was described first, by Bernhardt in 1895. In 1900 Musser and Sailer collected 99 cases; and W. J. Rutherfurd reports a dozen cases in the last ten years. The symptoms are caused by a mononeuritis of the external cutaneous nerve of the thigh. (A branch of the second and third lumbar nerves.) There is a local paræsthesia of which the cause is unknown and the treatment unsatisfactory.

Other forms of neuralgia or neuritis which lead one to admit the possibility of a local right side abdominal painful affection of the nerve are: occipitocervical neuralgia with induration and tender spots. If such areas of induration occurred in the abdominal wall near McBurney's spot erroneus conclusions might be drawn.

Pain such as that of tic douloureux, or intercostal neuralgia if occurring in the distribution of certain abdominal nerves might lead to unnecessary laparotomy. Migraine, sciatica, or lumbar neuralgia, coccodynia, pododynia and other similar affections, if appearing in different locations, might give rise to confusion.

Myositis and myalgia. The fact that localized pain, tenderness and rigidity may be due to pathological conditions within the substance of the abdominal wall seems to

have been consistently overlooked. A myositis in a certain location in the abdominal wall, if unrecognized, might readily be confused with intra-abdominal lesions.

The myalgias, rather loosely defined as painful affections of the voluntary muscle, fascia or periosteum to which they are attached (many authorities claim it to be a neuralgia of the sensory nerves of the muscle) are recognized in certain anatomical locations as lumbago, torticollis, pleurodynia.

Pain is the prominent symptom. The constitutional symptoms are mild, there is no fever and no leucocytosis. An abdominal type of this condition is admitted but it has not been given due attention, and if unrecognized would lead to confusion and error.

The headaches that are accompanied by areas of "induration" usually at the origin or insertion of muscles in the scalp and neck, might well be studied more carefully, and the occurrence of similar phenomena in the abdominal wall might clear up some of the uncertain cases of abdominal pain.

Lead colic. The colic of lead poisoning has frequently led to unnecessary laparotomy because of its very close simulation of intra-abdominal disease. The abdominal pain is general and associated with marked muscular rigidity, noteworthy in being relieved by pressure. Vomiting and constipation are present, the pulse is slow and of high tension with an absence of elevation of temperature. The blood count shows anæmia with stippled red cells and usually no leucocytosis.

Characteristic Burton's lead line, unfortunately is present in only half of the cases, but if discovered the diagnosis is confirmed. A false lead line may be found on the gums of any person working in dirty metallic dusty surroundings. This may be removed by cleaning the mouth and teeth. The true lead line is not *on* the gum, but is *in* the gum, and in its incipiency is not a line, but a series of dots, the result of chemical changes between the lead and sulphur of decomposing particles of food, and will not be removed by cleaning. It is best seen with the aid of a magnifying glass.

In securing the history, it is well to remember that plumbism may occur in occupations other than that given as painter.

Tabes. Nuzum has made a most important contribution to the literature of tabes, in which he quotes from the classic description of this condition by Charcot as follows:

"But of all the visceral symptoms which may display themselves from the period of lightning pains, one which is at once the most remarkable and the least known, if I mistake not, is that which I have proposed to designate by the name of gastric crises. Very often their real signification remaining misunderstood, they are the occasion of grave errors of diagnosis.

"But it is time to tell you in what these gastric crises consist. Suddenly and generally at a period when a paroxysm of shooting pains has seized upon the extremities, the patient complains of pain which, starting from the groins, seems to ascend both sides of the abdomen and to become fixed in the epigastric region. At the same time they complain of pains situated between the shoulders which radiate around the base of the trunk in a lightning-like manner. Then the pulsation of the heart commonly becomes violent and precipitated. Rapidity of the pulse without fever is, in truth, a very common incident. Almost incessant and extremely distressing vomiting is often associated with gastric crises. Food is first ejected, then a mucous, colorless liquid sometimes mixed with bile or tinged with blood. An intense feeling of sickness and vertigo are superadded to the vomiting and cardialgic pains. Many a time I have seen this symptom diverting the attention of the physician and causing him to misapprehend the real nature of the disorder. I also have several times fallen into the snare in other days."

The gastric crises of tabes has, until very lately in the minds of many physicians, been considered a rare, unusual, and late manifestation of cerebrospinal syphilis.

That many cases of gastric crises have been mistaken for acute abdominal lesions has been more or less imperfectly realized, but Nuzum's article entitled, "Needless Surgical Operations from Failure to Recognize Tabes Dorsalis," is of great value in attracting attention to the frequency of the slipshod or careless methods taken to arrive at a diagno-

sis. Nuzum collected and analyzed the records of 1000 cases of tabes treated in Cook County Hospital during the four years, 1910–1915. In these 1000 cases, 97 needless operations had been performed upon 87 patients.

"In estimating the number of operations, only those have been included in which the patients were told by the surgeon that nothing wrong was found, and in which the old symptoms returned following the operation. Cases have been excluded when scars of previous operations were found in the epigastrium, kidney or appendix region, with no record of what was found or done at the operation, recorded on the history sheets, or when this could not be learned from the surgeon.

The surgeon's diagnosis in these cases was as follows:

Gastric ulcer	19
Gall-stones or cholecystitis	19
Appendicitis	18
Salpingitis	13
Exploratory laparotomy	9
Renal calculi	7
Postoperative adhesions	7
Tumor of cauda equina	1
Sciatica (nerve stretching)	1
Meningocele	1
Ectopic gestation	1
Peritonitis	1
Total number of operations	97

The occurrence of real bona fide abdominal pathology in conjunction with tabes must not be lost sight of. Nuzum recognizes this fact and excludes such cases, and reports a case of perforation of a duodenal ulcer in a tabetic that was discovered, at autopsy, by LeCount.

Just because a person has tabes it in no way eliminates the possibility of an acute abdominal emergency, or any other type of an emergency, and it is just such possibilities that make the personal equation of the diagnostician of so much importance. A study of the cerebrospinal fluid is of value, as an increase in the cells is quite a constant finding, even in the early stages. A positive Wassermann is of great value but is not conclusive, as there is a percentage of error variously estimated from 1 per cent up. False positives may occur in cancer, tuberculosis, scarlet fever and Hodgkin's disease; 25 per cent to 30 per cent of luetics are negative in tertiary stages, as also are the so-called "parasyphilitics."

A provocative dose of antiluetic treatment will reduce this percentage of error materially. In all doubtful cases, both the blood and the spinal fluid should be examined.

Cabot summarizes the matter by saying: "What we are learning in the last few years, since lumbar puncture and Wassermann reactions in the blood and spinal fluid have become matters of routine in doubtful gastric cases, is that any type of stomach trouble, acute or chronic, mild or severe, sharply painful, or merely distressing, may be due to cerebrospinal syphilis. Until within the last few years, one was on the lookout, if he were conscientious, for so-called gastric cases in tabes. What we have learned lately is: (a) That we must suspect the possibility of tabes even when the pupils are normal and must investigate this possibility by means of spinal puncture; (b) that any sort of gastric abdominal pain or distress may be due to tabes."

I shall merely present Nuzum's conclusions, which represent the concensus of opinion on the subject at this time, and urge that this article be not only read, but carefully studied, by every one who presumes to perform laparotomy:

It is believed that with a careful examination to exclude tabes, in the future more tabetics will be spared useless surgical operations, and more acute abdominal symptoms will be proved of spinal origin.

1. Of 1,000 tabetics, 8.7 per cent have been subjected to laparotomy under mistaken diagnosis one or more times.

2. The "crisis" of tabes has largely influenced the surgeon in his decision to operate. This statement is supported by the fact that 65 per cent of the 87 patients operated on presented visceral crisis. In 17 per cent of these the "crisis" was the initial symptom of their disease.

3. Mistaken diagnosis and resulting operations occur chiefly through failure to examine the nervous system.

4. Gastric ulcer, gall-bladder disease, and appendicitis are the diagnoses most frequently made.

5. Tabetics subjected to several successive laparotomies have, as a rule, been operated on by as many different surgeons.

6. A history of paroxysmal attacks of vomiting, rheumatism, paræsthesias, bladder disturbances, or fractures without physical violence, should excite interest to exclude tabes dorsalis.

7. The cytodiagnosis of the cerebrospinal fluid, together with the Wassermann reaction with the spinal fluid, are of inestimable value in doubtful cases.

Hysteria, with its protean manifestations may, of course, be mistaken for intra-abdominal lesions. Clavus hystericus, so well known, if transferred to the right iliac fossa would many times be operated upon with a diagnosis of appendicitis. Still there is no reason why the same severe pain may not occur in the abdomen, instead of the head.

Such tender spots do occur in the hysterogenetic points, viz., the breast, trunk, spine and upper and lower abdomen, and it is the type of painful spot in the lower abdomen that has been responsible for the ovariotomy furor, and now the appendectomy craze.

Tympanites or phantom tumor may likewise confuse the issue.

Careful history taking and complete examination with the discovery of anæsthetic areas, or superficial tenderness greater than that elicited by deep pressure with an absence of temperature or leucocytosis will usually prevent error.

INTRA PERITONEAL LESIONS

Intraperitoneal lesions that may simulate surgical conditions may include: cardiospasm, cirrhosis of liver, acute dilatation of stomach, acute gastritis, acute enteritis, ptomaine poisoning, typhoid fever, angioneurotic œdema, gastroptosis, mucous colitis, chronic intestinal stasis, salpingitis, dysmenorrhœa, pregnancy and others.

Cardiospasm. It is but a comparatively few years since abdominal operations were performed for various conditions in which undetected and unsuspected cardiospasm was the real cause of the symptoms. Smithies reports 34 cases, in but 5 of which had the possibility of cardiospasm been considered. X-ray, careful history, and examination will prevent such error.

Cirrhosis of liver. Biliary or hypertrophic cirrhosis (Hanot) is characterized by jaundice, an enlarged liver, attacks of pain in the region of liver, that may be severe and associated with nausea and vomiting, possibly with slight fever, and leucocytosis. The negative features are absence of ascites and dilatation of the blood-vessels.

Because of the gastric attacks, jaundice and enlargement in the region of the gall-bladder, this condition is not infrequently confused with cholecystitis.

Portal or atrophic cirrhosis (Laennec) is characterized by small contracted liver, ascites, and portal obstruction manifested by the caput medusæ, hæmatemesis or melæna.

According to Rolleston, and confirmed by Cabot, acute symptomless hæmatemesis occurs in 20 per cent of gastric and duodenal ulcer and in 20 per cent of cirrhosis of liver.

"Dyspepsia" is a common symptom as is the "hepatic facies," viz., eyes sunken, conjunctiva watery, nose and cheeks showing distended vessels and the complexion muddy and ichteroid. Cerebral toxic symptoms may develop any time and are usually mistaken for uræmia. The ascites may lead to a diagnosis of tuberculosis of the peritoneum or malignancy. The disease is not rare.

The Talma-Morrison omentopexy has not been accepted as superior to tapping, and the establishment of Eck's fistula, i.e., portocaval anastomosis has met with little favor since its first performance on man, by Widal, in 1903.

Mayo states that his experience with splenectomy in cases of splenic anæmia has been such as to encourage him to splenectomize in suitable cases of portal cirrhosis, especially when the spleen is enlarged.

Acute dilatation of the stomach may be mistaken for peritonitis or ileus. Laparotomy is rarely indicated, as gastric lavage will not only make the diagnosis, but will serve as a very effectual therapeutic measure.

"Acute indigestion" is a term used rather loosely to indicate a condition in which the usual gastric symptoms present, but this name can, consistently, be applied only to those in which the symptoms end by the emptying of the stomach.

In acute gastritis there may be temperature; the usual absence of a leucocytosis will aid in differentiation. The abdominal pain may be intense, and the attacks may be confused with cholecystitis or appendicitis. This differentiation may be at times extremely difficult.

Acute enteritis may be accompanied by abdominal pain; but a temperature and leucocytosis is usually absent. The pain and tenderness are not localized.

In ptomaine poisoning, there is no fever and no leucocytosis; but there is abdominal pain, cold sweats, vomiting, continued diarrhœa and subnormal temperature.

As a general proposition, with infection, there is fever; but with poisoning there is no fever. Many "gastritis," "enteritis," and "ptomaine poisoning" cases are gastric ulcer, gall-bladder or appendiceal infections.

An acute abdominal pain in the course of typhoid fever must always be given serious consideration. A coincident appendicitis is not rare. Perforation varies greatly in frequency but it has been estimated to be the cause of death in about 12 per cent of the fatalities. Perforation occurs in about 3 per cent of all cases; 80 per cent in the lower ileum and usually during the second and third week. Characteristic of perforation, we find acute abdominal pain, rise of blood pressure, increase of leucocytosis. This may be a comparative increase and still be below normal; therefore the necessity of a close observation of the blood during the course of the disease.

With these symptoms exploration is indicated. They may be found to be due to conditions not remediable by operation, but to await more conclusive signs of peritonitis is to await a time at which treatment is usually unavailing.

In the literature we find many cases in which exploratory laparotomy was not followed by disastrous consequences. The diagnosis is most difficult because, to quote Remsen: "The unraveling of such a complication involves some of the prettiest diagnostic problems in acute abdominal surgery, for it involves, not merely the diagnosis of an acute abdominal condition *per se*, but rather its diagnosis through the veil of signs and symptoms pertaining to another existent acute abdominal condition, if we may class typhoid fever as such."

Typhoid fever must always be excluded in doubtful cases. Of great value is a history of temperature previous to the attack of pain. The enlarged pericæcal glands may simulate an appendiceal abscess and may give rise to pain and tenderness.

The leucopenia, the Widal, and the other typical signs of typhoid or paratyphoid, should be looked for.

Angioneurotic œdema. The appearance of this disease in the skin has been well known since Quincke's description of it in 1882, at which time it was known by his name.

It is only recently that attention has been drawn to the fact that visceral occurrence of exudative phenomena similar to those observed upon the visible surfaces of the body, such as urticaria, erythema, purpura, all belong to the angioneurotic group, an angioneurosis, that may give rise to abdominal pain which may cause even experienced observers to open the abdomen in the belief that some acute surgical pathology exists.

This condition may be due to chemical or toxic irritation, to faulty metabolism or to anaphylaxis. William Osler has given this subject considerable attention and in a report of 29 cases cites Henoch's purpura in which intense agonizing attacks of colic have occurred with no cutaneous manifestations. The decrease in red cells and hæmoglobin in these cases is most striking, though there may be elevation of temperature and increase in leucocytosis. Because of the variability of the skin lesions, and of their absence in some attacks, patients rarely associate the skin conditions and the abdominal symptoms. In children particularly, careful history taking should attempt to bring out previous attacks or lesions of the skin, inflammation of joints, or abdominal colic or crises. In adults, one is often struck by what may be called a neurotic tendency of the patient and one will note the indefiniteness of the nature of the abdominal pain, which does not conform to the type found in the usual surgical lesions.

There is one type which lasts a few hours. This may be mistaken for gall-stone colic, or, with hæmatemesis it may be confused with gastric or duodenal ulcer. Another type of longer duration, is frequently associated with a swelling in the right iliac fossa, and may suggest appendiceal abscess.

Such cases have been frequently operated

upon, and a brawny induration of the entire cæcum, appendix, and lower ileum is encountered. The appendix does not show sufficient change to be the primary cause of the condition. Harrington cites 1 case of this type, Osler 3, Riggs 4, and Mayo 3.

In cases seen for the first time, in which there is large tumefaction of recent duration in the cæcal region, severe pain without local peritonitis and with the patient in good general condition, out of all porportion to the suspected lesion, a history of previous swelling should be carefully sought, and, if found, watchful waiting is good surgery.

Crispin, in an article entitled "Visceral Crises in Angioneurotic Œdema" considers this subject *in extenso* and cites cases from the Mayo Clinic. His conclusions are as follows:

"When a history of severe abdominal pain is given which does not conform to true surgical types, careful inquiry should be made as to the presence at any time of urticarias, erythemas, purpuras, and swellings of angioneurotic œdema types."

A history of recurrent severe abdominal pains with constancy in the nature and duration of the attacks with skin manifestations of any of the exudative erythemic forms, with or without noticeable association with the abdominal pains, should excite suspicion as to the presence of crises of angioneurotic type.

A diagnosis of visceral crises of angioneurotic type should not be made until careful examination has excluded or made independent surgical causes. In this, roentgenologic examination of the gastro-intestinal tract is valuable negative evidence. Syphilis and tuberculosis should be excluded.

The constancy in the recurring attacks of the pain, not conforming to surgical types, in patients who have had skin manifestations of the exudative erythema group and whose general condition does not account for the suffering they have had to bear, will warrant a diagnosis of visceral angioneurotic œdema.

Repeated, or even single attacks, of intestinal colic with tumefaction in which the patient's general condition is too good for the extent and severity of the trouble, and in which history of the swellings can be obtained, may be of this type. To wait is good surgery. The rapid return to health is strongly suggestive of visceral angioneurosis.

Having determined the medical nature of these angioneurotic visceral crises, we should endeavor to work out the sources of toxæmia. There may be foci of pus in the upper respiratory tract and sinuses, bacterial absorption, idiosyncrasies to heat, cold, chemicals, parasites, carbobydrates or proteins that are the causes for anaphylaxis.

Removing the cause for anaphylaxis, whether it be idiosyncrasy in one patient for ice cream, some constituent, such as cold bananas in another, alcohol in a third or any anaphylactic base or source of exogenous or endogenous irritation or poison, may give the patient relief that the advised surgery would not have given him.

Appert, from France, likewise calls attention to this pseudoperitoneal syndrome due to urticaria-purpura or polymorphous erythema.

Since the work of Richert, and others, Appert considers urticaria to be an anaphylactic phenomenon, and that the cutaneous troubles are only the outward and visible manifestations of sudden changes in the blood called by Widal a "hæmoclassic crisis."

Visceroptosis. The important phase of surgery in which visceroptosis has caused symptoms leading to unnecessary abdominal operations has been handled in a masterly fashion by Albert J. Walton. Thirteen cases were operated upon under the impression that the condition was an acute abdominal lesion — appendicitis, the remainder of the total 67 were mistaken for chronic abdominal disease — chronic appendicitis, gall-bladder disease or gastric ulcer or cancer. Differing from appendicitis one finds a previous history of repeated attacks of a mild character and short duration. There may be a slight increase in temperature and slight rigidity. Walton well says, "If in doubt always better to diagnose appendicitis and operate."

Archibald MacLaren in a consideration of "Chronic Appendicitis and Visceroptosis," says: "The neurasthenic or visceroptosis case sometimes simulates the *acute* but usually is mistaken for *chronic* appendicitis."

Constipation-stasis. This subject, despite its enormous literature, is still unsettled and obscure. It is more intimately connected with the chronic than with the acute abdomen, but as these cases are being operated upon and are being advised to undergo operations for acute abdominal conditions, it must be mentioned at this time.

This error in diagnosis also occurs in other countries; for example, in London, as shown by the report of Walton; in Germany, by that of Wilms; in Amsterdam, by that of Laewen, in Norway, by that of Widore. The latter reports 23 cases of intestinal stasis occurring in 1912, in 16 of which the family doctor had sent the patient to the hospital urging immediate operation, but in all the trouble was merely intestinal stasis.

In view of the above citations, from England, Holland, Germany, Norway, and I suppose a search would reveal similar reports from other countries, it would seem that some reason for this diagnostic error must be looked for, that is general, geographically, and that may be effective in all communities regardless of the type of education or the traditions, and customs of the profession.

And such a cause will be found, it seems, in nothing more obscure than sheer laziness, in which acceptable diagnoses are made without sufficient data, the so-called "snap shot" diagnosis, which it seems is quite universal; an international and not a national failing.

Mucous colitis. Colica mucosa of Nothnagel is such a large and little understood subject that I shall not attempt to present a consideration of the topic but merely call to your attention the fact that this disease is quite common, though frequently unrecognized, that it is characterized by attacks of very severe abdominal pain with great tenderness that has many times been mistaken for intra-abdominal inflammation. The condition is associated with neurasthenia. The relation of one to the other like that of the chic to the egg, is not as yet determined.

In mucous colitis there are localized spots of cutaneous hyperæsthesia.

"The areas of cutaneous tenderness pointed out by Head as corresponding to disease of internal organs have been verified in most particulars by subsequent observers. Those which correspond to the intestines as far down as the upper part of the rectum, are the ninth, tenth, eleventh, and twelfth dorsal segments. Their respective positions are: left costal margin above the center and one inch from the end of the rib; just to the right of the umbilicus; just above the left anterior superior spine; and just above the middle of the right Poupart's ligament."

The presence of one of these spots last mentioned has been sufficient many times for the removal of an unoffending appendix. There is likewise a tenderness with rigidity on palpation along the course of the colon. There is in conjunction, a gastroptosis, enteroptosis, nephroptosis, a so-called "habitus enteropticus." Constipation is usual; though diarrhœa may alternate with constipation. At times, usually before evacuation of the bowel, there is a colic which may be very severe. The passage of thick glairy mucus in variable amounts is characteristic. This mucus may be rolled into worm-like masses that may be looked upon, by the patient, as worms.

This condition is a neurosis and not an inflammation; consequently there is usually an absence of leucocytosis and temperature.

Van Norden and Nothnagel have described the condition, and Henschell and Abraham have published a large monograph, Spitzig of Cleveland has considered the subject and Capperoani in a recent article dwells particularly upon the pseudo-appendicitis attacks that may occur in this condition.

This is a very obscure question and greatly in need of elucidation. Therefore it will not be considered further than merely to mention the fact that it is a frequent source of error in hasty examination and hurried diagnoses.

Salpingitis may be confused with appendicitis but a vaginal examination, with careful history, will usually clear up the diagnosis.

The question of the advisability of delaying operative interferences in acute pelvic infections until the acute inflammation has subsided, has, it would seem, been definitely settled by the observations of Simpson.

In but very rare instances is surgery indicated, danger to life is slight, the danger of

non-operative treatment is largely one of continued morbidity and recurrent infections. A coincident acute appendicitis should, of course, be treated by accepted radical measures. Simple dysmenorrhœa may be mistaken for acute abdominal inflammation. The history and close observation will prevent such confusion.

During the course of pregnancy there is sometimes a tendency to complain of pain and tenderness; sometimes a severe colic, in the right iliac fossa, which has been responsible for operation with a diagnosis of appendicitis, in which the findings did not coincide with the subjective symptoms.

An explanation has been offered by DeLee as follows: "This pain is almost always in some relation to McBurney's point, and is due to the dextrotorsion of the uterus, throwing the right tube and ovary forward, with a resultant compression of these delicate organs between the utero-abdominal walls."

But, whether or not this is the proper explanation, the clinical fact is well worth remembering. The frequency of appendicitis in pregnancy has been variously estimated, but I shall merely quote from two prominent obstetricians in a recent discussion. R. W. Holmes says, "I wish to take issue with Dr. Beck in his statement that appendicitis in pregnancy is very common. It naturally falls out that the findings of the general surgeon on this question will give a higher proportion than would be the case of the obstetrician. I have repeatedly had women complaining of right-sided pain, *but that is not appendicitis*, although I am sure many a pregnant woman has had her appendix removed hurriedly on account of such pain."

Dr. DeLee says: "I am quite confident that many a so-called appendicitis in pregnancy is merely a mild toxæmia of pregnancy: the physiologic leucocytosis of pregnancy, coupled with nausea. Epigastric, or perhaps right-sided pain, misleads one into operating erroneously for an appendicitis which does not exist."

CONCLUSIONS

These remarks have been rather brief and sketchy; in fact a mere running commentary upon a certain phase of surgery that is becoming more and more important. Other confusing conditions should have, in all probability, been included; differential points may not have been sufficiently and properly emphasized but the effort has been to direct attention to the fact that these various conditions may simulate intra-abdominal lesions; some of which may have slipped your mind; and that a diagnosis to be worthy of the name, must be based upon a careful history of the case, complete observation, and accurate interpretation of the data so acquired.

As showing the importance of careful history taking, Behlow says: "From a careful history one can make a positive diagnosis of the primary or major conditions in 53 per cent of the cases."

The same care in taking a history will make possible a positive diagnosis of the secondary condition in 41 per cent of the cases.

If the above possibilities are kept in mind and each case given careful study, our unsatisfactory results will decrease. This fact has been well recognized for centuries and has been consistently neglected, as has been shown by DaCosta in an article on "Principles of Surgical Diagnosis," in which he quotes Benjamin Franklin: "Want of care does more damage than want of knowledge"; and Sir William Gull: "We make more mistakes from not looking than from not knowing."

The coincidence of curable surgical lesions in individuals afflicted with non-surgical and incurable disease must be recognized, and the fact anticipated, that the cure of a definite surgical disease in a chronic neurasthenic does not necessarily mean a cure of the neurosis. Or in the trite words of Deaver: "The abdomen will be found to be a veritable Pandora's box of troubles, which do not, however, always fly away when the box is opened."

LAPAROPLASTY BY A NEW METHOD

By WELLER VAN HOOK, A.B., M.D., Chicago

THERE is a vast number of people whose intra-abdominal organs are improperly housed on account of defects of the walls bounding and maintaining the cavity of the abdomen. These people await rational and generally applicable methods of reconstruction of the greatest cavity of the body.

The abdomen is a walled space in which are housed various highly important structures. The spinal column, supporting the head, neck and trunk, passes through the posterior wall of the abdomen and forms a part of that wall. The muscles of the abdominal walls have the duty of maintaining the tension of those walls, but this is only one of their important functions, since they steady the spinal column and flex in the various directions the entire trunk. These walls may be encumbered with fat deposits and they may be weakened; stretched; torn; destroyed by wounds, inflammation or neoplasms; pouched or paralyzed. These changes themselves and the lesions of the intra-abdominal structures consequent upon or associated with them make necessary great efforts on the part of surgeons to devise methods of re-fashioning the abdomen so that the form and cubic contents of the *cavum abdominis* may be remodeled, the walls strengthened, the defects made good, the muscles given better lines of action, and the distance diminished between the origin and insertion of certain muscles, while encumbering tissues are removed.

The simplest and most obvious laparoplasty is that of J. Clarence Webster[1] who has operated in a large series of cases of defective abdomens, with and without diastasis of the recti. He removes by incisions parallel to and including the median line from ensiform to pubes, a long strip of skin and subcutaneous fat; then, opening the sheaths of the recti muscles, he sutures together the posterior plates of the sheaths and, separately, the anterior plates. He has had excellent results, the abdomen becoming narrower, burdened with less fat and far more under the patient's control.

Depage in 1893 proposed and carried out a laparectomy and a laparoplasty. By the first term is meant the removal of redundant tissues from the abdominal wall. This is especially desirable when the patient is burdened with an enormous fat deposit. Far more important is his laparoplasty. His operation is as follows:

An incision is made across the abdomen from the tip of the eleventh rib of one side to the tip of the eleventh rib of the other side. From the extremities of this incision two incisions run obliquely to points at the level of the umbilicus and 5 centimeters from the median line. From the two lower ends of these incisions two outwardly curved incisions are carried downward to a point

[1] Textbook of Gynecology.

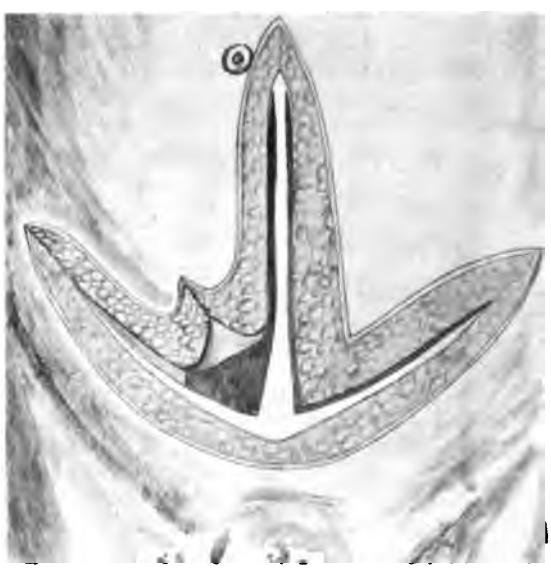

Fig. 1. Drawing showing the incision and the raising of the flap on the right side.

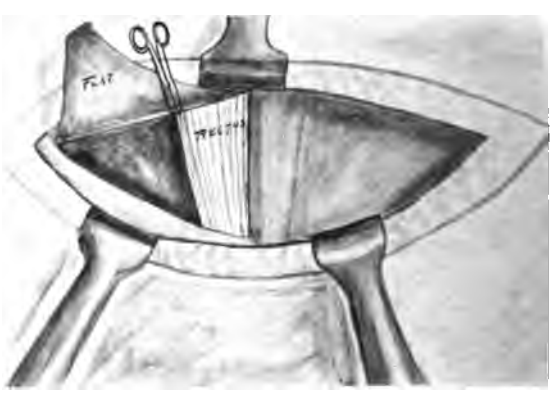

Fig. 2. Raising the flap for the right side, cutting through the right lateral wall of the rectus sheath.

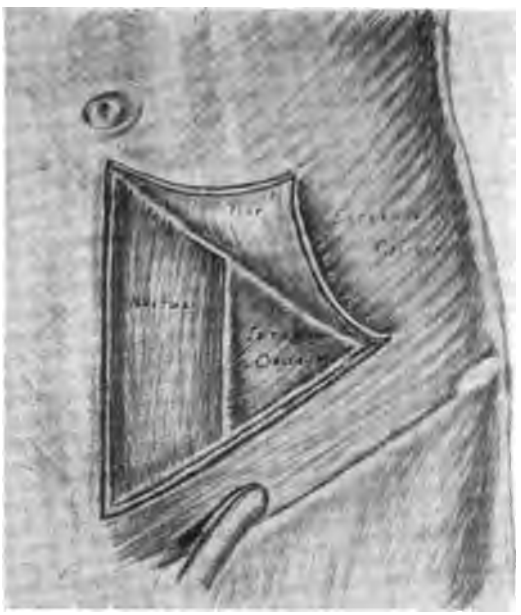

Fig. 3. The relation of the raised flap to the three muscles concerned.

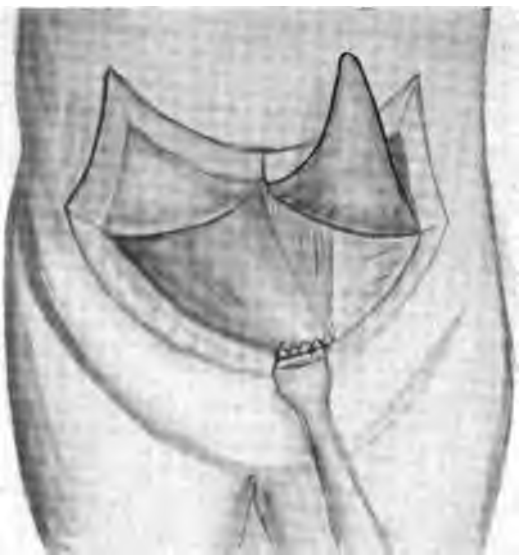

Fig. 4. The two abdominal wall flaps have been formed. The right hand flap has been carried across the median line and sutured nearer the level of the pubic bone. The flap for the left side is raised and beneath it are seen the bodies of the rectus and internal oblique muscles.

above the pubes. Then follows excision of the skin and connective tissue of the included area, the median line and the peritoneum, back to the edges of the recti muscles. Three layers of sutures close the abdominal wall, leaving a T-shaped scar. Depage's operation has been frequently performed by others as well as by himself with reports of satisfaction.

Coffey's operation[1] consists in making an incision through the external oblique muscle parallel to Poupart's ligament, lifting up that muscle from its bed and carrying it over the outer part of the muscle to a lower level, where it is stitched down. This very valuable operation is open to some objections, which are the facts that, for lesions involving the entire lower abdomen, the retrenchment is local and may be inadequate, and that the new abdominal muscle stress is laid upon the external oblique muscle alone and that, too, in a direction *perpendicular to the course of its fibers*.

The writer's laparoplasty for relaxed, pouching, or pendulous abdomens is as follows:

A median laparotomy wound is made in the lower abdomen and if necessary this may be extended well above the umbilicus, which is best excised. A median hernia, if present, is managed by severing adhesions, replacing organs and closing the retrenched peritoneum. The deeper wound is well protected by hot compresses. Laparoplasty is then carried out. From a point in the median line about one or two inches above the *symphysis pubis* incisions to the right and left are made starting at right angles to the median line but, at the outer edge of the recti, turning upward and outward in the direction of the fibers of the external oblique muscle and extending to a distance of six or more inches on each side, splitting that muscle.

Next, each of the triangular flaps thus produced, of which the apices point downward, is lifted carefully by separating the external oblique muscles (bearing their aponeuroses) up to the recti from the underlying internal oblique muscles. Then the anterior plates of the rectus sheaths are dissected up from the muscle-bodies. These powerful connective-tissue membranes lifted off from the bodies of the muscles, leave the recti bodies in their normal beds. The raised rectus sheath-flaps are now in continuity with the bodies and aponeuroses of the external oblique muscles. The effect of this work is to provide us with two triangular flaps pointing toward the pubes and consisting of parts of the sheaths of the recti and a large part of the external oblique muscles.

The next step is the crossing and reattachment

[1] Surg., Gynec. & Obst., 1912, xv, 365.

Fig. 5. Showing the sternopubic line of the pendulous abdomen in the erect posture.

of these flaps at points much lower than those to which they extended previously. To effect this one puts the patient in the Trendelenburg posture, then flexes the knees and moderately flexes the thighs upon the abdomen, providing under the legs a suitable support. The effect of these maneuvers is to diminish the pressure within the lower abdomen, thereby relaxing the muscles of the abdominal wall and also, by anteriorly flexing the spine, to lessen the distance between the ensiform cartilage and the pubic bone.

We can now draw the left flap downward to the right of the pubic bone across the median line until it is almost taut. It is carefully sutured to the apnoeurosis of the right external oblique, to Poupart's ligament and to the anterior sheath of the right rectus muscle at a level much nearer the pubes than that from which it was raised. The flap of the right side is similarly carried downward and to the left over the left rectus muscle and over the first flap and sutured in position.

The skin and subcutaneous fat are extensively retrenched and the T-shaped skin incision closed.

It will be observed that in this laparoplasty the T-shaped incision is inverted; in Depage's operation the T is upright.

This operation has been performed by the writer in two cases of large postoperative hernia in women, with the most gratifying results. The hernias were cured, the abdominal walls were given what physical trainers call a tucked-up appearance and the patients felt distinctly the improvement in voluntary control of the lower

Fig. 6. The sternopubic line in the Trendelenburg position.

part of the trunk, while the viscera were obviously held better in position.

The nerve- and blood-supply of the tissues involved are not compromised by the incision recommended and careful attention to strictest asepsis should yield primary healing.

The operation is recommended for plastic purposes (1) where, as in military practice, or in case of sloughing inflammations or of neoplasms requiring excision, loss of tissue has occurred; (2) where hernias through the anteromedian structures are too extensive for simple plastics; and (3) where relaxation due to fat deposits, to lordosis, to paresis etc., has resulted in pendulous abdomens causing weakness, inconvenience or interference with the function of the viscera.

ACUTE APPENDICITIS COMPLICATING EPIDEMIC INFLUENZA

With Report of Eight Cases[1]

By MOSES BEHREND, M.D., Philadelphia

THE recent epidemic of influenza accompanied often with its most lethal complication, pneumonia, has furnished many occasions for the physician to make a differential diagnosis of a chest or abdominal condition. It is a well known fact that the referred pain of a right-sided pneumonia often simulates the pain of an acute appendicitis. Many mistakes have been made in the past and many no doubt will continue to be made on account of the intimate relation of the nerve distribution covering the lower part of chest and abdomen. Numerous cases of pneumonia have been operated on in the past for pneumonia, and vice versa cases of appendicitis have been treated for pneumonia with disastrous results in the majority of cases. In patients in whom the two cannot be separated it is better to operate with the aid of nitrous oxide gas and oxygen anæsthesia. In case a mistake has been made the course of the pneumonia in my experience has not been altered. All the cases pursued their natural course and ended in resolution.

Close inspection without the aid of any other physical signs will often make the diagnosis. Other signs are not of much value because early in pneumonia practically nothing is elicited on auscultation and percussion. The one sign which more than any other differentiates pneumonia from appendicitis is rapid breathing and playing of the alæ of the nose. These signs are absent in acute appendicitis.

During and after the epidemic of 1888 and later also in the milder epidemics, many cases of appendicitis were reported. It has been a constant observation of physicians that appendicitis occurs in increased numbers after epidemics of influenza. The period of time between cause and effect varies. Many cases have been reported during the height of an epidemic but most of the cases of appendicitis occur some time after the patient is well. In 1888 several cases with pain in the right iliac region were diagnosed typhlitis. These cases were probably appendicitis.

Leichtenstern believes we are not dealing with acute appendicitis but rather with a typhlitis; that exceptional cases of true appendicitis may occur especially when the Pfeiffer bacillus has been isolated; that coincidental appendicitis, when it does occur, simply accompanies an attack of influenza. In only one of the eight cases observed by me was there any history of several previous attacks of appendicitis. Nor can I subscribe to the theory of typhlitis advanced by this author. Such cases were primarily appendicitis, the inflammation spreading to the cæcum by continuity.

About ten years after the epidemic of 1888 when appendicitis was better understood as a distinct entity several cases were reported.

Merklin reported three cases which were not operated upon. One of the cases however discharged the abscess per rectum.

In 1901 Charpentier observed 5 cases of appendicitis in an epidemic of grip that

[1] Read before the Philadelphia County Medical Society, October 23, 1918.

affected a regiment of soldiers in France in 1899. These cases were not operated upon and recovered. In only one case was there a previous history of appendicitis.

Franke believes there is a causal relation between influenza and appendicitis. He states that appendicitis has become very common since the great epidemic of influenza in 1888. Some of his cases occurred in two to three weeks, others in as many months after influenza. Again he has seen cases simultaneously in the same family, a condition observed by other physicians. He also believes that in influenza, appendicitis is often simulated—a pseudo-appendicitis.

Jolaguier has noted cases of appendicitis in the course of influenza as has also Faisant who goes so far as to state that grip is the main cause of appendicitis. He bases his opinion on the fact that there has been a large increase in the number of cases of appendicitis since the last great epidemic, and that there is a recrudescence of appendicitis after each annual epidemic of influenza.

Weitlaner found in his cases now and then Pfeiffer bacillus influenzas but the pneumococcus influenzas predominated in the locality under his observation in 1909. Curschman quoted by Weitlaner confirms this statement. Weitlaner believes that a pneumococcus influenza associated with a pneumococcus angina forms the basis of a series of cases of appendicitis. He states that the pneumococcus had been found in the appendix and peritoneum by a series of investigators. He quotes especially Jensen who found pneumococci in the circulating blood in ten cases of appendicitis. Jensen himself found the pneumococcus in appendicitis in 20 cases, never, however, in pure culture as had been found by Krogius in one case. Weitlaner is a firm believer in the infection of the appendix by the hæmatogenous route, at least so far as the pneumococcus influenza is concerned.

The occurrence of appendicitis in influenza is not mentioned at all by Althous in his fine treatise on the subject of influenza.

The writer has seen in all 8 cases of acute appendicitis complicating influenza. Seven of these were seen in consultation with other physicians. Three were operated on and found to be pus cases. Not any of these gave a previous history of appendicitis. In one the appendix ruptured while in the other two pus was contained in the appendix. All the cases recovered. The other five cases were not operated upon because it was feared that the prevalence of râles in the lungs would eventually result in pneumonia. This may seem contradictory to the statement made earlier in this paper, but the wide diffusion of moist râles in the lungs reminded one more of an extensive œdema than a characteristic pneumonia. On account of the "wet" lung the administration of an anæsthetic was feared.

Of these cases six were adults and two were children. All were taken sick during the height of the epidemic and had been in bed on an average of four days before the symptoms of appendicitis developed. In those not operated on the symptoms gradually subsided.

It will be interesting now to observe whether there will be an appreciable increase in the number of cases of appendicitis following the recent virulent form of epidemic influenza.

REFERENCES

ALTHOUS. London: 1892, 2d. ed.
ANDRÉ. La Grippe ou Influenza, 1908.
LEICHTENSTERN. 2d. ed., edited by Sticker.
MERKLIN. Bull. et mém. Soc. de hôp. de Par., 1897, xiv, 399–405.
CHARPENTIER. Bull. méd., 1901, xv, 239–240.
FRANKE. Mitt. a. d. Grenzgeb. d. Med. u. Chir., 1899–1900, v., 263–328.
FAISANT. Bull. et. mém. Soc. méd. d. hôp., Par., 1899, pp. 335–339.
WEITLANER. Wien. med. Wchnschr., 1909, lviii, No. 8, 377–378.
JENSEN. Arch. f. klin. Chir., lxix and lxx, 108.
KROGIUS. Quoted by Jensen.

PRIMARY SUTURE OF WAR WOUNDS

By GEORGES GROSS, Nancy, France
Graduate Professor of the Medical University of Nancy; Consulting Surgeon to the Fifth Army

PRIMARY suture of war wounds is certainly one of the burning questions of the day and quite justly so. At the outbreak of the war, the theory of expectant treatment was the accepted rule. Those of us who had the greatest number of consecutive cases to deal with saw almost at once that in many of the wounded, fatal accidents would sometimes occur. The practice of large, open incisions systematically made and followed by rigorous drainage which I was one of the first to advocate[1] was the next step as opposed to the "wait and see" policy. This practice had proved its value, but however excellent it may have been, it certainly had its disadvantages. War wounds which are infected remain so after wide incisions are made, even when they are followed by irrigation with antiseptics, let them be what they may (ether, peroxide of hydrogen, Dakin solution). From our desire to improve the results obtained by disinfection with antiseptics has been evolved mechanical disinfection. At first efforts were made to obtain mechanical disinfection by scrubbing and brushing the wounds; later by *l'epluchage*, or the cutting away of all infected tissue, a procedure which is really better named excision, for it is by wide excision that one must remove all bruised, infected and dead tissue, together with the projectile and all dirty extraneous material. In spite of excellent technique a certain number of wounds widely opened would suppurate for a long time, either from the persistence of the primary infection or from secondary infection. Others equally carefully excised, would clear up so readily and perfectly that one was tempted to believe in the possibilities of primary suture. The results obtained were often favorable, but it is true that there was a certain number of failures, even accidents, which caused many to regard primary suture in most cases as an exceptional method of treatment and in others a dangerous proceedure. As regards myself, I was an enthusiastic advocate of it, since my colleague Loubot showed that, after scrupulous disinfection of the fractured bone surfaces, an open joint could be completely closed, and in nearly every case union by first intention was easily obtained.[2]

The well known treatise by Loubot has certainly had a great deal to do with the triumph of this method. During the summer of 1915, with the army before Verdun, then afterward on the Somme, primary suture began to have numerous advocates. Since June, Houdard and myself[3] used with almost constant success the suturing of cerebrocranial wounds. Wounds of the soft parts, even in the presence of fractures, were also sutured during this period. Grégoire and many surgeons at the front hospitals believed, and rightly, that primary suture would be the coming method.

What is essential in deciding as to whether primary suture should be used in treating war wounds: (1) the time that has elapsed between the receipt of injury and the period of operation; (2) the anatomical possibility of making a complete and perfect removal of all damaged and crushed tissue and of extracting the projectile; (3) clinical experience which would enable the surgeon to decide from the general aspect of the wound whether reunion would be successful.

When for one reason or another one has not dared to do a primary suture, he could, at the end of 15 or 20 days, when the wounded man has become afebrile and the wound has a clean look, perform secondary suture. Secondary suture which can be carried out very well, as I have demonstrated, on a wound treated with aseptic dressings, is generally followed by a course of treatment with the Dakin solution according to Carrel's tech-

[1] Bull. et mém. Soc. de Chir., 1915, Jan. 27.

[2] Loubot. Bull. et mém. Soc. de chir., 1916, June 28; and G. Gross, ibid., 1916, Oct. 18.

[3] G. Gross and Houdard. Bull. et. mém. Soc. de chir., 1917, May 30, and Dec. 5.

nique. In order to determine when it is possible to perform secondary suture, Carrel and after him Depage, made bacterial counts of the wound discharge. During treatment of the wound it was found that the number of bacteria gradually decreased and finally assumed negligible proportions. Only then was secondary suture done. This technique marks the appearance of bacteriological control in the treatment of war wounds.

Primary suture, the ideal method of treatment of war wounds, reached this point but did not gather many disciples in spite of its evident advantages, when Tissier, in the course of investigations began at the end of 1915, in Flanders, and published in 1918[1] discovered that one never had severe infection in a war wound (particularly gas gangrene), when in the wound one could not demonstrate the presence of an anaerobic and aerobic infection. The nature alone of the germs living in a wound is important, Tissier claims; their number gives one no useful information. The works of Tissier can be summed up as follows: Each war wound contains a special microbial flora of its own on which depends its future development. The bacterial growth varies; it differs not only in different wounded men but even in different wounds of the same individual. Each microbe growing in a wound follows its own evolution and this process never varies. The microbe multiplies for a period, then the number remains constant, then decreases more or less rapidly, and at last disappears according to the power of resistance of the body to infection.

Infection of wounds is sometimes primary, sometimes secondary. In war times, as a wounded man passes through several hands in the course of his evacuation, it is difficult not only to control but also not to increase the primary infection. In every wound left open and uncovered, the number of new bacterial infections cannot help but increase.

Infection of war wounds usually pursues a purulent course of a type caused by the presence of quantities of putrefactive anaerobic organisms. Two conditions are necessary to cause these anaerobes to flourish in living tissue: (1) the presence of tissue either bruised or deprived of its blood supply; (2) the presence of one or several species or aerobic organisms.

The rate of tissue-destruction by anaerobic infection (gangrene) depends on the kind of aerobe with which it is associated and which seems to start the ball rolling. Thus, with the ordinary saprophytes, only slightly virulent, the anaerobic pus formation remains local; in conjunction with the staphylococcus pyogenus it extends slowly, whereas with the true streptococcus it spreads rapidly even attaining a fulminating type.

Infection of war wounds may also become of a purulent type when the wound has not become infected by anaerobes or when these bacteria are not able to develop. Under the conditions the type of aerobic microbe gives a special character to the wound. With the ordinary saprophyte there is hardly any reaction; with the staphylococcus local reaction, more or less marked; with the streptococcus there is at the same time a local and general reaction. It is in these latter cases that one meets those long-standing suppurations, metastatic abscess formations, bone lesions following febrile crises with marked temperature oscillations, and the slow cachexia which wears out the wounded man.

In these two kinds of wound infections, putrefactive or purulent, it is necessary to establish the nature of the aerobic infection present in order to form a prognosis. In serious cases it is always the streptococcus that is present.

The following rules may be deduced from these investigations:

1. Try, as a matter of course, primary suture, if removal of the foreign body and excision of dead tissue is possible. Establish at the same time the nature of the aerobic germ in the primary discharge in order to confirm your method of procedure. If the staphylococcus is present keep close watch of the wound for fear of the appearance of a slow form of pus formation which it will be easy to check, but which will not appear if the original dissection has been well done. A little pus may collect, necessitating the removal of a stitch or two. If one finds the streptococcus,

[1] H. Tissier. Bull. de la méd., 1918, Oct.; Ann Inst. Pasteur, 1915, Dec., 1917, Apr.; Arch de méd. milit., 1918, Dec.

remove the stitches at once and by widely opening the wound combat the further spread of the infection. Anaerobic growth hardly ever takes place before 30 hours. As you can secure a bacteriological report about 6 hours after culture in ordinary broth, there is no reason to fear that you will be too late in opening up the wound.

2. When primary suture has not been done, you must as quickly as possible perform secondary suture, being guided only by the nature of the aerobic infection. Here, also, you should take no notice of the presence of anaerobes. Their decrease begins about the third day and their development becomes impossible on the appearance of the phagocytes.

If the common saprophyte is found the wound must be sutured the second or third day. Results are always favorable. If the staphylococcus is present one must wait for its decrease between the fifth and eighth days. If the streptococcus is present one must wait for the period of spontaneous isolation of the organism. This is shown by a fall in temperature which usually commences about the twenty-first day, but sometimes earlier. The temperature remains down only when the wounded man becomes a mere germ carrier, without general reaction or, better still, when the streptococcus has definitely disappeared.

The practice of primary suture and early secondary suture (delayed primary suture) is thus built on definite, exact scientific lines which are founded entirely on Tissier's researches. It is only necessary to know the nature of the bacteriological infection; of the different types of infection the streptococcus alone contra-indicates primary suture of war wounds.

Since June, 1917, my collaborators and myself in the Twelfth Mobile Surgical Ambulance have depended on bacteriological reports. Our results were presented in two lengthy communications before the *Societe de Chirurgie*.[1] These results were such that they permit me to confirm the soundness of the theory of Tissier and to sum up thus: "Every war wound in which streptococcus is not present ought to be closed."[2] The results may be summed up as follows: 78.3 per cent of wounds met with were sutured; of the sutured wounds 88.8 per cent healed by first intention.

Several points should be studied in turn, in order to understand the technique of primary suture as it is practised. They are the following:

1. How do the sutured wounds progress?
2. How do we know whether a war wound contains streptococcus (bateriological technique)?
3. What surgical technique is to be followed to obtain constant results?
4. When must the suturing be done?
5. Its advantages.

How do the sutured wounds progress? Three things may happen. The wound may heal by first intention as in the ordinary aseptic operation, slight redness may appear, a stitch may cut out, or other insignificant thing happen to disturb the wound course; but regardless of this, healing finally takes place. Or again certain symptoms appear or bacteriological information is obtained which causes one to reopen the wound.

Sutured wounds may heal by first intention and this is the result in by far the greatest number of cases; 88.8 per cent was the result obtained in my ambulance. The stitches are removed about the tenth day and the scar is perfect.

Certain facts strike one in dealing with these wounds, the absence of pain being the most noticeable. Wounded men with unsutured wounds always suffer. Those with sutured wounds on the contrary never complain and certainly not after the second day, just as is the case with patients operated on in civil practice. In this manner they differ very greatly from the cases with wounds which have not been sutured. After the second day, in the sutured case, the patient, even if suffering from multiple wounds or fractures, feels perfectly well and begins to get up if he is wounded only in the upper arm. The facial expression is good, the color normal, the tongue clean, the pulse regular, and of good

[1] Bull. et mém. Soc. de chir., 1917, July 4, Oct. 10; Acad. d. méd., Paris, 1917, Oct. 23.

[2] Bull. Acad. de méd., Paris, 1917, Oct. 23.

volume. The temperature in most cases is slightly above normal, but often normal. In the majority of cases, it varies between 37° and 38° and falls to 37° rapidly. In some cases, however, it remains high for some time and rises above 38° for 4 or 5 days. Examination of the temperature chart is the only check necessary to keep on these patients who, however badly wounded, have the appearance of slightly wounded cases.

The dressing done at the operation is not removed before the tenth day. It is necessary to make sure that the suturing and the skin around look perfectly normal. Healing is perfect and when the stitches are removed we find perfect apposition of the edges of the wound. A simple protective dressing is applied and, as in all aseptic operations, the wounds cicatrize under the two dressings, and the patients are evacuated cured on the fifteenth and twentieth days. It must not be supposed that this healing will succeed only in minor wounds and that in them alone will one see healing take place with such ease. I have sewed up and have seen closed, wounds of the soft parts which were certainly 20 centimeters in length and of a really serious nature—such as amputations for crushes, resections of the thigh, arm, torn wounds of the buttock with the foreign body against the ischium, foreign bodies in the neck, various ligatures of the large vessels, wounds of large extent and very foul, dating back 24 hours or more. In a large number of cases the injuries consisted of fractures of which several were badly smashed up. In a number of these fractures (300), one sees better than in a sequence of ordinary wounds the splendid results obtained by primary suture. Such a large series of cases has never before been published.

Primary sutured wounds running an abnormal course. Side by side with wounds healing by first intention, one finds others pursuing a less normal course, which in spite of setbacks end by healing; in some cases normally and in others after a slight infection of limited amount. This fact has been evolved by careful attention to the temperature chart. The general condition of the patient remains good, the facial expression is bright, and the wounded man has a good appetite and is cheerful. The pulse is good in volume and tension, and in no case does it become small and rapid. Attentive study of the temperature chart alone gives one warning of coming events.

In the first type the temperature which during some days remained elevated to 38° or even 39° at night, falls slowly in 8 or 10 days or better still, with only a slight rise toward the fifth or sixth day, falling slowly afterward. I have already stated these facts in relation to joint wounds.[1] If the closed wound is examined there is found a little localized redness around one or several stitches. The region is slightly tense and swollen, but the findings remain quite local, and soon little points of pus appear at the stitch holes. The whole condition subsides and the wound remains closed, and the healing is but slightly delayed by this small superficial infection.

In the second type, the symptoms are not so mild; they present a more severe picture. On the one hand the temperature on the day of operation rises to 39° or 40°, remaining there two or three days and then falling suddenly to 37°, there remains or again mounts to 39° or 40°, falls to 37° not so rapidly, but in five or six days by degrees. If, however, during this rise in temperature, the dressing is removed the wound is usually found to be swollen and painful; but the skin remains normal in color. If between two horsehair sutures the point of a Kocher forceps is inserted and the blades are slowly opened, a little blood-stained fluid containing a few gas bubbles escapes. The healing will be none the worse for this, even if from a sense of prudence one has thought it wise to remove a stitch. The small wound resulting from this useless opening up prolongs the healing time a few days. These incidents, however, rarely occur (in about 5.01 per cent of cases).

In other cases, not only the vicinity of the sutures is a little distended and swollen but there appears a cherry red color extending some distance, giving an appearance which is disquieting to any one not acquainted with the course in such cases. The erythematous flush spreads toward the extremities of the limb and is sometimes accompanied by the presence of

[1] Soc. de. chir., 1916, October 18.

gas under the sutures, giving a resonant note on percussion, an unpleasant smell, and a blood-stained discharge which escapes between the stitches. But the wound has this characteristic appearance. Locally the erythematous flush is more cherry colored at the beginning than that of a gas gangrene and in general there is complete discord between the temperature on the one hand and the pulse and general condition of the patient on the other. Both remain excellent and this at once attracts the attention of the most experienced observer. In spite of these symptoms, it remains none the less true that only bacteriological examination giving assurance that the wound does not contain the streptococcus prevents the surgeon who understands the symptoms from opening up the wound. These cases are quite rare; in my experience there were not more than 1.18 per cent. However, following these acute symptoms we sometimes see develop a little suppuration and a gas abscess forms and must be opened up.

Voluntary opening up of wounds already sutured. This is necessary in a special kind of wound in which bacteriological examination has disclosed the presence of the streptococcus. Whenever the streptococcus has been definitely found, the wound must be opened up. Sometimes this is done at once after examination. In other cases there will be no symptoms which indicate what procedure to follow and the bacteriological report alone will be the guide. In such cases, the general condition of the patient is good, the temperature is only slightly raised, and the skin adjoining the wound has a normal appearance; for the infection has as yet had no time to develop. Some of these wounds which are not opened continue to heal without any great disturbance and untoward incident, and the skin keeps its color and texture. Toward the tenth day the stitches are taken out. Often the thickened edges of the wound gape a little and when the stitches are removed the wound opens spontaneously like a book. This is a sure sign of the presence of the streptococcus. It is then practically certain that if the wound is not voluntarily opened up, it will open itself and it is only running risks to leave it sutured. Usually at the end of a few hours, the wounded man is suffering and complains. His general condition is quite different from that of previously described cases. His expression is drawn, his pulse more rapid. The skin of the injured region is port wine red in color, with marbling (motley lines) spreading far and wide and gas escaping from the wound. This is the local gangrenous form. Destruction of the tissue has already spread though the wound has been widely excised. Can we assume that the suturing has caused this serious condition? I think not. This development well known to all surgeons at the front, is the same in wounds opened widely, drained, and left open. The suturing, too, may have been done only a few hours, but the wound so badly infected at the time of treatment has widely opened. In short, these fatal accidents ought to be the exception. I have seen but three such accidents in 759 sutured wounds, or 0.39 per cent. Men with such wounds die in the same way as do the cases with acute toxæmia, even before suturing can be done after an amputation, and the same symptoms and the same temperature curve are present. No surgical intervention can save them.[1] We are familiar with this form of virulent toxæmia which leads to a rapid and fatal termination, sometimes almost without development of gangrene and against which we are powerless.[2]

The wounded infected by the streptococcus present a typical picture: their facial expression is the same as that in long-standing seriously wounded and infected cases, they are pale, the pulse is rapid, the temperature fluctuating, and the appetite poor. The look of the ward where they are isolated is markedly different from the other wards. This, however, is to be expected. Since infection due to the streptococcus is all we have to fear, the wounded suffering with it should be isolated. It is strange that all surgeons still will not adopt this precaution although they isolate systematically and have for a long time each patient suffering with erysipelas, and the erysipelatous streptococcus is certainly much

[1] The general mortality of my ambulance, which like each surgical motor ambulance received only the seriously wounded, before doing sutures was 14.25 per cent. (G. Gross. Arch. méd. milit., 1916, October.) Since we do primary suture systematically the mortality is 10 per cent.

[2] Gross, G. 134 cases of gas gangrene. Soc. de chir., 1917, March 7.

less virulent than the streptococcus of war wounds.

Bacteriological reports upon which some light has been thrown by Tissier easily explain the incidents which may happen in primary sutures of war wounds. His investigations prove that the incidents come from a special pre-existing germ. There are exacerbations which can originate only in the wounds incompletely cleared of dead tissue.

How do we know whether a war wound contains the streptococcus? Primary suture of war wounds is based entirely upon the works of Tissier. It can be carried out systematically under bacteriological control. In my mind, the bacteriologist is as indispensable to the surgeon as is the radiologist. Besides, the report from the laboratory must be returned quickly so that the sutures can be taken from the wound a few hours after they are put in if the cultures have revealed the presence of the streptococcus.

The technique is the simplest: In the first place, as smears of pus and serum do not give exact indications, one should proceed only after cultural examinations. In fact, the only danger to be feared in primary suture of war wounds is the appearance of a putrid infection, which makes rapid progress. The cause of these terrible forms of infection is always an association of anaerobes and streptococci; it is quite necessary to inform the surgeon, as quickly as possible, of the presence or absence of the streptococcus. The only medium in which the streptococcus grows quickly is a liquid medium at 37°C. Within 5 or 6 hours there appears in the liquid lumps of long rolled up and absolutely characteristic chains.

Bacteriological specimens should be liberal and taken from all parts of the wound, chiefly from the deep parts near the bone when it is injured. It is best to use a pipette in order to collect a great deal of serum and particularly of blood as often as it is possible. The most convenient time for collecting the germs from a wound is between the tenth and eighteenth hours after the soldier is wounded. Sooner the bacteriological specimen would probably not contain all the different kinds of germs; and later, the considerable and predominant growth of anaerobes may hide the presence of aerobes, particularly of the streptococcus.

The inoculations should be made in broth upon slanted agar with litmus and lactose, and into deep agar of Veillon. Common broth is sufficient in the majority of cases; nevertheless, in order to facilitate the growth of streptococcus, it has been proposed that Sacqueppe's medium (that is, albumin of egg with soda—Raymond) or other albuminous medium such as ascites be added. Weinsenbach advocates water with peptone, glucose, and alkaline egg albumin; and Boyer a bone maceration with peptone.

These proceedings make it possible to obtain results most quickly if the wound contains the streptococcus—between the fourth and sixth hours; the streptococcus with its classical characteristics is more clearly demonstrated within the following hours. The broth remains clear, but a deposit is seen which, by shaking, changes into characteristic clots. When one has collected some blood there is hæmolysis, a very important phenomenon to establish. One can see much the same it is true among cultures of bacillus mesentericus or anaerobes; but, in these cases, the appearance of the cultures is different; there are no clots and the microscope permits a solution of the question. The slanted agar, with litmus and lactose, is turned red, is covered with tiny colonies, more or less transparent, fine, rather equally strewn upon the surface and, generally, separated from each other.

After staining one sees some gram-positive cocci, *in chains* of at least twenty cocci. As these are short in solid media, one will search for them preferably in liquid media (broth clots and water of condensation from slanted agar, at the bottom of the test tubes), where they are most often typical, very long, particularly rolled up and entangled. Short chains might be "enterococcus" but generally, this germ is more polymorphous; it does not produce hæmolysis and uniformly clouds the medium with a mucoid, thick deposit which rises up like a gimlet when one shakes the tube.

Within agar of Veillon, one will find the streptococcus very frequently; it grows easily in the presence of oxygen; but particularly

one will find the bacillus perfringens which is one of the first to appear, and also the most frequent.

The streptococcus is rather less frequent in recent war wounds (10 to 15 per cent), and the association of the streptococcus and the anaerobes even less frequent (6 to 8 per cent). It is important to bear these facts in mind for during the periods of intense work it is possible to examine only the wounds which are more likely to contain these infectious germs, i. e., deep ragged wounds, among thick masses of muscular tissue. Afterward, during more calm periods, systematic examinations can be made of all wounds.

What technique should be followed to obtain constant results? In most cases well done *exerese.* How is excision of war wounds best done? First the entire wound of entrance should be thoroughly excised. Then for a "seton" (the projectile having crossed the whole part of the limb), the cutting away of both orifices. The first is easy to do with an elliptical "incision," one circumscribes the orifices, sufficiently enlarging the "incision" so that later it will be possible to excise the deep part of the passage. The uncovered aponeurosis is laid open. By following the passage of the projectile, a broad excision of the muscular tissue which limits it can be done.

Exploration of the passage should be avoided whenever possible. Even with a smooth instrument, the end may penetrate the neighboring tissues and infect them. It is preferable to explore with the finger which acts as a guide in following the tract. Usually this questionable practice is useless for the direction of the passage can be demonstrated by radiology.

Excision, preceding suture, must be done with full knowledge of the conditions present. All blind exploration at the end of the finger must be avoided. When the track is outlined and after the projectile has been extracted, one practices wide "excision" layer by layer. The technique called *epluchage* is certainly inadequate; the word is badly selected; it instils in the surgeon's mind ideas of false security. With *epluchage* primary suture does not bring success but disasters. One must practice wide *exerese* of the devitalized tissues. It is quite useless in order to determine the amount of tissue to be excised to color the wound with methylene blue; the experienced surgeon will stop the excision in time; that is to say he will cease to excise when he reaches muscular fiber which is not deprived of its blood, which has not the dark port wine color or has not the well known soft consistence; in other words when the tissue has become firm, is contractile, and is red in color; in short when it bleeds.

Three typical procedures may be employed:

1. Opening and laying open of a "seton" (the projectile having crossed through all the soft tissue); or of a wound with projectile included under the skin. One cleaves the track if it is not too deep, then extirpates it completely, *en bloc.*

2. Extirpation *en bloc* of the entire wound when it is superficial or even when deep and widely laid open.

3. Usually the lesion is deep and the incision must be conical, the top of the cone being beyond the projectile or upon the fracture. This excision systematically made, with scissors, takes away layers of devitalized tissues. It must be made thoroughly, carefully, systematically, reaching the seat of injury where the projectile is lodged. For a deep "seton" (in the upper part of the thigh, for instance), one must do a double conical excision, the tops of which will join. Bony lesions neither can nor must cause a total *exerese.* In a fracture one must always be satisfied to remove carefully all the free splinters not adherent, and sometimes with one stroke of the bone forceps to make regular the sharp fragments. One must always leave the adherent splinters which are so useful. I plainly condemn removing large pieces of bone, a procedure I have, alas, so often seen practiced. Tissier showed that the cutting away of free splinters is sufficient. Clinically, we have already learned that the bones become infected slowly, through the soft parts, and consequently operations upon bones must not always be extensive ones.

If the projectile is situated within a diaphysis or an epiphysis, the tract and chamber shall be carefully hollowed out, enlarged, and if possible laid flat. The cavity should be

touched with iodoform ether. It can be filled in different ways. No one among my collaborators ever tried plastic pastes; but one of them (Houdard) used, with good results in four cases, fat grafts taken from the buttock.

In the treatment of injured joints, as often as it is anatomically possible, the ideal method is the operation of Loubat. Primary resection is the best method in the majority of lesions, typical or atypical resection according to the extent of the lesions. No matter what the anatomical lesion, or how thoroughly excision has been done, it will not be complete, naturally, without the extraction of the projectile and bits of clothing. The useful antiseptics are: ether for flesh wounds (soft parts) (ombredanne) and iodoform ether for bone injuries. The technique of the suture itself remains to be described. Sometimes it is useful to suture the deep muscular layer with catgut. I do not like this method as I have noticed that these catgut sutures easily become infected. Two conditions are most important in order to obtain a good suture; perfect hæmostasis and care not to leave a dead space under the sutured skin. One can perform a good closure with rolled-up gauze and three or four bronze wires. After the bronze wires are carefully placed, approximation of the skin edges is brought about with horse hair. Then there is placed over the suture line a pledget of rolled up gauze (called in French a *bourdonnet*) and the bronze wires are tightened over it. The *bourdonnet*, when it is not soiled by oozing, is taken off only when the cutaneous horsehair suture is removed. It is preferable to remove the horsehair suture slowly, about the tenth or twelfth day, for the process of healing of the war wound is slower than is that of aseptic wounds in civil practice.

When should the suturing be done? In any case where no streptococcus is found in the wound and when there exists no anatomic or pathologic contra-indication. Practically every wound may be sutured upon arrival of the wounded man; but one must always reopen those wounds in which within 6 hours, the bacteriologist has found the presence of the streptococcus.

Does the time elapsed between the receipt of the wound and the arrival at the hospital contra-indicate operation? I do not think so. Certainly the longer the interval that has elapsed the more infection could develop; but with thorough excision I have myself sutured and have seen sutured wounds which had been received 12, 24, and more hours before, and correct and simple reunions resulted. It seems to me one can find in these facts a greater proof that, in deciding upon the technique to follow, one need bear in mind only the type of infectious germ found in the wound; a wound containing the streptococcus must not be sutured after a few hours, those containing only common saprophytes can be sutured after 24 hours or more. Where suturing is contra-indicated the wounds should be left open. In my mind, suture is contra-indicated in the following cases:

1. In multiple wounds when the patient is suffering from shock, yet in condition to be operated upon, but where it is necessary to do the operation very quickly.

2. In deep wounds, the complete excision of which is impossible; wounds which appear to be badly infected; very old wounds or wounds communicating with septic cavities, and wounds with increasing gaseous gangrene.

3. In wounds with projectiles remaining in them.

4. In wounds with great vascular lesions.

5. In wounds producing extensive injury to the skin.

6. In wounds which do not require suturing (enucleation of the eye).

Most of these contra-indications do not need explanation. Certainly suture lengthens the time of operation. When it is necessary to operate quickly upon the multiwounded man who is in a serious general condition, it is preferable to save his life. The final results will be a little less brilliant. However, one can operate and suture the multiwounded man if he is not suffering from shock. In those suffering from shock one should be satisfied to suture the principal lesion (joints or bones) only incising and draining, or even neglecting the less important lesions, which will be treated later. The correct and complete excision of infected and devitalized tissue is the principal requisite for a successful primary

suture. When the operator cannot do this, he must leave the wound open. When the projectile has not been extracted, the same contra-indication exists, if the projectile is small (green pea); or if it is extremely small, one can suture leaving within the tissues one or several projectiles. I have often done this, and have seen it done. I do not think one can advise against suturing wounds in a period of intense activity; in my ambulance, three operators sutured 49 gravely wounded men within 24 hours.

Nevertheless, when a considerable number of wounded men overflow the ambulance and when one has not sufficient room for keeping all the wounded men, it might be well not to perform primary suture, but follow Pierre Duval's technique,[1] i.e., delayed primary suture. At first the wound is widely opened and the excision is done. Then, the wounded man is evacuated to another sanitary center situated at the base (*Zone des Etapes*) where the wound can be sutured after two or three days. According to the author's advice delayed primary suture is founded also upon the works of Tissier. In these cases it remains only a necessity; primary suture is preferable. Certainly delayed primary suture has some disadvantages, the principal one being the necessity of giving two anæsthetics and of doing two successive operations. Time and money are lost. If such a procedure is necessary in certain cases, we must practically always try to do primary suture.

ADVANTAGES

The advantages of primary suture are unquestionable. The wounded men do not suffer so long; they completely escape the grave danger of secondary infection, so frequent among open wounds. One can state a comparison: in the hospitals of the interior 80 per cent of the wounded men showed streptococcus in their wounds, while among the recently wounded they were found in only 10 to 15 per cent. Among cerebrocranial wounds within the first months after suture, the mortality descended from 14 to 10 per cent, since we have systematically performed primary suture. Functional restoration is likewise obtained more completely and quickly. It is obvious that a flexible, non-adherent scar would not be likely to produce a neoplasm and this has been rather frequently seen in cases with old adherent scars. Besides, these first advantages, from the economical standpoint, there are several factors of first importance. Fewer attendants are necessary, there is less shock, as most of the wounded men become cured with only one dressing, as in civil practice; nowadays due to the great necessity of recovering cotton, it is easier to recover unsoiled cotton and the outlay of cotton is less; there is considerable economy of hospital days and annuities as the wounded men are cured more quickly and the end-results are better. Finally, from the military point of view, this method is of capital importance. All the cases, with large wounds of the soft parts, are entirely cured about the twentieth day and are able to resume work. Those with fractures leave the ambulance with closed fractures often already united. One of my evacuations contained 59 primary reunions among 61 wounded. The requisites for obtaining constant results are as follows:

Place by the side of a competent surgeon (having correct technique) a competent bacteriologist. Let them keep their wounded men a sufficient length of time to follow them until they are completely healed—about fifteen days. In proving that all war wounds containing no streptococcus can be sutured and thus cured Tissier has permitted us to realize the greatest progress obtained in war surgery since the beginning of hostilities. Until then primary suture was an uncommon procedure. Thanks to these works it is now a regular routine: in the future I am certain it will be the rule.

[1] Pierre Duval., Soc. de chir., Par., 1917, Oct.

DEPARTMENT OF TECHNIQUE

A METHOD OF EXPOSING THE MUSCULOSPIRAL AND THE POSTERIOR INTEROSSEOUS NERVES

By BYRON STOOKEY, A.M., M.D.[1]
Captain, Medical Corps, U. S. Army; Chief of Neurosurgical Service, General Hospital No. 2, Fort McHenry, Baltimore
Captain (rel.) Royal Army Medical Corps, 1915-1916
AND
STACY GUILD, PH.D.
Assistant Professor of Anatomy, University of Michigan

IN the repair of extensive injuries of the musculospiral nerve it is frequently necessary to expose the nerve in the greater part of its course. Many times, both above and below the injury, the nerve must be identified and followed in order to find the severed ends. The more usual method is the spiral incision beginning below and following the line of the nerve. There are certain disadvantages to this incision. Unless it is made precisely over the nerve, considerable difficulty may be met in locating it and further dissection of the tissues becomes necessary. It is sometimes extremely difficult thus to find the nerve even when the incision approximates fairly closely its position. Such is the disadvantage of any incision which runs parallel to a nerve, particularly if it follows a winding course. Furthermore, the spiral incision cuts the triceps transversely. If it is directly over the nerve it places a scar down to the nerve throughout the greater part of its course. When nerve graft or tubulization is to be done the danger of infection and further scar formation is thus increased. For the above reasons the spiral incision usually employed is unsatisfactory.

The authors present the three following incisions for the exposure of the musculospiral nerve from the lower border of the teres major muscle down to the antecubital fossa.

The first incision lies in a line from the tip of the olecranon to the posterior angle of the acromion. The incision should begin three fingers, breadth below the acromion and continue directly downward along the above line to 5 centimeters below the level of the insertion of the deltoid. The incision is carried directly through the deep fascia. At the upper angle of the wound the posterior border of the deltoid and the long and outer heads of the triceps can be identified. These heads of the triceps are separated in their fascial plane by blunt dissection. The deltoid is retracted. If necessary, a small part of the latter muscle may be cut. The separation of the two heads of the triceps is carried down to the lower angle of the wound, following as closely as possible their line of junction. After separating the muscle fibers a glistening aponeurosis presents; this is incised and the nerve exposed up to the lower border of the tendon of the teres major muscle. The exposure thus gained is excellent and little damage is done.

The second incision runs parallel to the first except in its lower part, where it is slightly curved toward the anterior side. This incision should begin about 12 centimeters above the antecubital fossa external to the brachialis anticus and between it and the almost longitudinal fibers of the supinator longus (the usual incision is generally not sufficiently perpendicular and lies too far anterior — near the belly of the biceps). If this second incision is correctly placed, it will fall over the interspace between the brachialis anticus and the supinator longus in which the lower third of the musculospiral nerve is to be found. By careful dissection the nerve can be traced into the antecubital fossa to the point at which it divides into the radial and the posterior interosseous.

The nerve in its upper and lower thirds is thus exposed. By carefully following the course of the nerve in the fascial space beneath the triceps and through the intermuscular septum by means of a blunt dissector a groove may be opened. By utilizing the canal thus opened, severed ends of the musculospiral nerve might be united by means of nerve grafts or other procedures without further dissection. However, should a more complete exposure be required, a third incision may be made midway between the other two and par-

[1] On special detail in experimental nerve surgery under Dr. Huber, Director of Anatomy, University of Michigan.



Fig. 1. Lines of incision for exposure of the musculospiral nerve.

A. The position of the skin incision for exposure of the upper third of the musculospiral nerve is here seen. It is placed on a line from the lateral part of the posterior angle of the acromion to the tip of the olecranon and extends from three fingers' breadth below the acromion directly downward in the long axis of the arm for about 12 centimeters. The incision for exposure of the middle third of the nerve may also be seen. (The apparent curvature of this line is due to perspective — it is actually a straight line parallel to the first.)

B. The lines of incision for exposure of the lower and middle thirds of the musculospiral nerve are here shown. The lower incision is made very nearly perpendicular, except in its lower fourth where it turns slightly anteriorly. It should be external to the brachialis anticus and between it and the perpendicular fibers of the supinator longus. Generally this incision is placed too far anteriorly and is curved more than the nerve. The incision for the middle third of the nerve lies midway between those made for the upper and lower thirds and parallel to the former. It is placed upon the outer head of the triceps and extends from a point 3 centimeters above level of insertion of the deltoid directly downward for about 12 centimeters.

allel to the first. It should extend from 3 centimeters above the level of the insertion of the deltoid directly downward for about 12 centimeters. The incision is carried through the triceps, separating the fibers longitudinally until the aponeurosis on its deep surface is seen. This is carefully incised and the nerve exposed directly beneath. A complete new skin incision need not be performed. Either of the above incisions may be prolonged in an oblique or curved manner and the skin edges undermined. The additional exposure is then obtained by carrying the incision as above described, longitudinally through the deep structures. This incision is close to that given by Schwartz and Kuess. Both of them alone give free exposure of the musculospiral nerve only in its middle third.

These three parallel longitudinal incisions expose the musculospiral nerve from the lower border of the teres major muscle to the antecubital fossa with the least possible damage to the overlying tissues. The muscle fibers when cut longitudinally are damaged but little, and the sensory skin supply, frequently completely destroyed by a spiral incision, is in a great measure retained. Thus the main objections to a spiral incision are avoided and a free and easy exposure obtained.

The rather perpendicular course of the musculospiral nerve is not anticipated from the usual anatomical descriptions. The nerve is essentially perpendicular in its upper and lower thirds, being spiral only in a small portion of its middle third. Perhaps this is the reason why a spiral incision frequently does not lie over the course of the nerve, the precise position of which it is difficult to estimate. In such cases considerable dissection in further efforts to find the nerve must be undertaken.

Posterior interosseous nerve. This nerve is not infrequently severed or involved in callus following injuries of the radius, particularly in explosive wounds of the elbow-joint in which the radius may be shattered. When injured it causes considerable disability due to paralysis of the extensors of the thumb and fingers. The extensors of the wrist receive their nerve supply by branches above this level. The technique of suturing the posterior interosseous is rendered difficult both by its relatively small size and by its inaccessibility.

For this exposure the arm is slightly flexed across the lower abdomen with the hand semipronated. The prominence of the external condyle and the radial border of the extensor communis digitorum are identified. By rapidly mov-

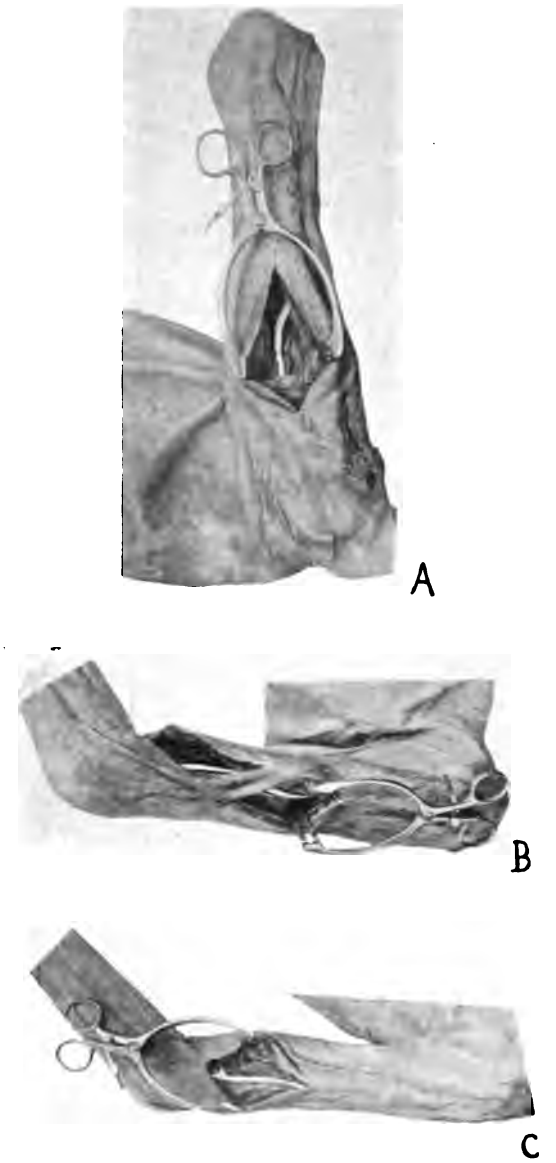

Fig. 2.[1] The musculospiral nerve exposed in its upper, middle and lower thirds.

A. This shows the exposure of the upper third of the musculospiral nerve. The outer and long heads of the triceps are retracted. The tendon of the teres major can be seen lying across the nerve in the upper angle of the wound. Beside the nerve are the superior profunda vessels. Note the almost perpendicular course of the nerve in its upper third.

B. This shows the exposure of the middle third, and most of the lower third, of the musculospiral nerve. In the upper wound the fibers of the outer head of the triceps are split longitudinally and separated. The inferior incision shows the lower third of the nerve lying between the brachialis anticus and the supinator longus.

C. The lower third of the musculospiral nerve is exposed into the antecubital fossa to the level of its terminal branches. Note the comparatively perpendicular position of the nerve. It does not have the spiral direction in this part of its course that most descriptions indicate. The nerve here lies between the brachialis anticus internally and the supinator longus externally.

[1] The illustrations in Figures 2 and 3 are from photographs of exposures of the nerve in a cadaver.

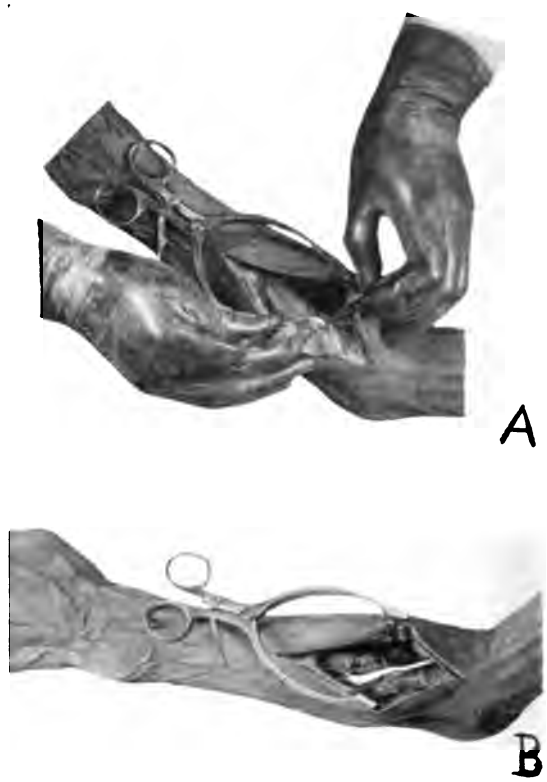

Fig. 3. Exposure of the posterior interosseous nerve.

A. The extensor communis digitorum, including its deep aponeurosis, and the extensores carpi radialis are widely separated, exposing the supinator brevis. At a point two fingers' breadth below the external condyle the fibers of the supinator brevis are separated with two tissue forceps in the direction of their course. The posterior interosseous nerve is thus found running at almost right angles to the fibers of the muscle. From this point the nerve can be readily followed in its course.

B. The posterior interosseous nerve is here shown as finally exposed. It has been followed from its point of exposure shown in *A* both upward and downward by a careful incision of the supinator brevis along the line of the nerve. Danger of cutting the nerve before it is located is avoided by this procedure. The nerve may be followed until it breaks up into its main branches. By also making the incision shown in Figure 2, *C*, the posterior interosseous and the lower third of the musculospiral may both be exposed. It is in the lower angle of the latter wound that the posterior interosseous branches from the musculospiral.

ing the various fingers, without extension of the wrist, the common extensor may be recognized. External to it lie the extensores carpi radialis. An incision 12 centimeters long is carried from the external condyle directly downward along the line between the extensor communis digitorum and the extensores carpi radialis through the deep fascia. Beginning at the lower angle of the wound, the interspace between these muscles is identified and they are separated by blunt dissection as far as their common origin. Here the muscle fibers are cut longitudinally up to the external condyle. This last step is essential in order to obtain adequate exposure. The muscles are then widely retracted and the common extensor aponeurosis on the deep surface of the muscle mass exposed. Its free medial border can be readily found, freed by blunt dissection and retracted with the extensores carpi radialis, thus exposing the obliquely running fibers of the supinator brevis. These fibers run anteriorly and downward toward the flexor surface of the forearm. The posterior interosseous nerve is within or beneath this muscle. It runs at almost right angles to the muscle fibers diagonally across the radius toward the extensor surface. At a point two fingers' breadth below the condyle, the fibers of the supinator brevis are separated in the direction of their course by blunt dissection with two tissue forceps. In the opening thus made the flat posterior interosseous nerve will be seen (see Fig. 3, *A*). Having thus found the exact position of the nerve the supinator brevis is cut both above and below, thus exposing it freely without danger of injury. The posterior interosseous nerve is thus laid bare in the main portion of its course. Without the step involving the separation of the muscle fibers by blunt dissection at right angles to the nerve, difficulty may be encountered in finding it. It should be a principle of nerve surgery never to attempt an incision parallel to a nerve having a spiral course. The slightest error in placing the incision necessitates further difficult dissection and needless destruction of tissue. Should it become necessary to expose the posterior interosseous nerve higher than this incision affords, the lower incision described above for the musculospiral nerve should also be made.

The authors believe that this technique for exposure of the musculospiral and posterior interosseous nerves from the teres major muscle to the termination of the main stem of the latter has distinct advantages over the usual spiral incision. By longitudinal incisions running across the course of the nerve it is immediately found without additional search.

NECESSITY FOR SPECIAL POSITIONS IN THE ROENTGENOGRAPHIC STUDY OF SHOULDER CASES

By W. W. BOARDMAN, M.D., and M. DONOVAN, M.D., San Francisco
Stanford University Medical School

In the roentgenographic study of the shoulder-joint, the usual routine anteroposterior plates are not sufficient, and a negative diagnosis based upon such plates is open to severe criticism.

George[1] has recently emphasized the necessity of multiple plates and especially plates in abduction and external rotation for the recognition of shadows occurring in so-called subdeltoid bursitis. The position he found most valuable was as follows: "With the patient in the recumbent posture, the affected shoulder flush on the plate, the upper arm abducted to a right angle, rotated outward, the forearm flexed at the elbow to about 45 degrees and the opposite shoulder slightly elevated by a sandbag."

[1] George. Am. J. Roentgenol., 1918, v, 187.

For the past five years, we have been using, as a routine in the examination of shoulder cases, a somewhat similar position, differing only in the degree of abduction. With the patient supine, the forearm has been flexed at the elbow and the upper arm fully rotated externally. By this procedure, there is some abduction of the humerus, but not to the degree recommended by George. This would seem to be an advantage as the degree of pain produced is apt to be proportional to the degree of abduction.

The especial value of this position of extreme external rotation is that the greater tuberosity of the humerus and the tissues attached thereto are brought into profile, whereas in the ordinary position the greater tuberosity lies on the anterior